

---

# Postmortem Animal Attacks on Human Corpses

---

Zerrin Erkol and Erdem Hösüklér

Additional information is available at the end of the chapter

<http://dx.doi.org/10.5772/intechopen.72929>

---

## Abstract

Postmortem animal activity is an important step in incorporating protein, fat, and carbohydrates in corpses to the food chain. Many animal species are members of this food chain. Outdoor corpses may be attacked by many predacious and scavenger animals and exposed to complete destruction, and bones and belongings of the dead person may be scattered all over a large area due to postmortem animal activity. Indoor corpses may be attacked by pets, domestic dogs, cats, ants, and rodents during postmortem period. Besides, if the corpse is in shallow water, other terrestrial predators may harm the corpse. The most important issue in the presence of lesions on the corpse caused by animals is to accurately discriminate between antemortem and postmortem wounds. The extent of the lesions caused by the animals varies according to the sizes of their dentition and jaws, but they share some common characteristics. Lack of bleeding from bitten tissue excepting small amount of extravasated blood, absence of active bleeding, edema, and erythema on the edges of the wound are among these shared characteristics. In this chapter, the subject of postmortem animal attacks on human corpses will be evaluated by revising the recent references.

**Keywords:** forensic sciences, crime scene investigation, decomposition, postmortem animal attacks, postmortem animal injury, animal scavengers, carnivores, postmortem artifacts, teeth marks, dispersed remains

---

## 1. Introduction

### 1.1. Postmortem animal scavenging activity, motivation, pattern and forensic problems

Animal activity on corpses during postmortem period plays an important role in the integration of protein, fat, and carbohydrate contents of the corpse into the food chain and constitutes an important part of the taphonomic process experienced by the body after death [1, 2]. Many animal species are members of this food chain. In order to identify the animal that attacked

the corpse, the location of the corpse, geographic conditions, season, animal species found in the area, types of animal feeding, and behaviors should be known [3]. Indoor corpses may be attacked by many predacious and scavenger animals and exposed to complete destruction, and bones and belongings of the dead person may be scattered all over a large area due to post-mortem animal activity [4, 5]. Outdoor corpses may be attacked by pets, domestic dogs, cats, ants, and rodents during postmortem period [6–13]. If the corpse was immersed in water, then many aquatic animals as fish, water rats, crabs, and amphipods may attack the corpse [14–16]. Besides, if the corpse is in shallow water, other terrestrial predators may harm the corpse [1].

Devouring the remains of human corpses by animals may cause many problems concerning forensic pathology and forensic anthropology:

1. If serious destructive changes occur especially on the face of the corpse and teeth, then identification of the corpse may be difficult [6, 7, 9–12, 17].
2. Even if the individual died because of natural consequences, when the internal organs are devoured by animals, then it might be impossible to identify the precise cause of death [17–19].
3. During postmortem period, lesions caused by animal attacks may be evaluated and misinterpreted as antemortem lesions as ligature mark, firearm wound, or stab wound [2, 7, 9, 10, 13, 20].
4. At the time of dying, clothes may be opened, and exposed genital organs may be depredated by animals during postmortem period, which may raise the suspicion of sexual mutilation [17, 21].
5. In posttraumatic deaths, open wounds may be the first target of scavengers, and within a very short time, precise identification of antemortem wounds may become seriously complicated [22, 23].
6. During postmortem period, existence of living beings such as ants, which feed on both the corpse, and adult and larvae of flies and insects, putrefaction of the corpse may be delayed because of devouring of eggs, and larvae. Faunal succession of insects and flies, which is especially used to determine the postmortem interval, may change leading to erroneous estimation of the postmortem interval [4, 24].
7. Loss of skin may lead to disappearance of tattoos and old surgical scars, which may be used for identification of the victim [18].

Hunger is the main factor for animal motivation in outdoor postmortem animal scavenging. The odors pervading from the corpse due to natural putrefaction process attract the attention of wild animals [25]. This condition differs slightly for domestic animals. Domestic animals frequently do not feel the need to hunt for nutrition. It has been indicated that for postmortem scavenging activity of domestic cats and dogs living in confined spaces, the corpse should belong to a socially isolated individual living alone at home and also there should be a pet (cats and dogs) moving freely at home, but cannot reach its food [26]. In contrast, dogs feeding on their owner's corpse during postmortem period as reported in some cases cited in the literature

cannot be solely explained by only starvation. Rothschild and Schneider [27] presented a case of a 31-year-old male who was living with his mother and an Alsatian dog. The victim had postmortem scavenging wounds on his face and neck formed by his dog after he had committed suicide with a firearm. Interestingly, only 45 minutes had elapsed from the time the man shot himself to the head and the discovery of the corpse. This time interval was not considered to be long enough for the dog to become hungry. Besides, near the bed of the victim's corpse, a half-filled canned food and a bowl full of dog food were found. According to Rothschild and Schneider [27], the most probable explanation of this condition was that the pet began to lick and poke its unconscious owner with the intention to help him. However, when its attempts failed, the authors claimed that the dog had become more aggressive and had bitten its owner so as to arouse him, and they defined this as displacement behavior. In a case presentation, a man died due to a coronary problem was wounded by his hunting dog only a few hours after his death, which according to authors' opinions could not be explained by hunger of the dog or deficient food [28]. Buschman et al. [12] presented three cases that had been attacked by pet dogs during postmortem period, and they reported that dog foods were accessible in all these three events. Rossi et al. [29] presented a case in which the victim's nose and mouth were injured by her dog during postmortem period. Witnesses said that they had seen the victim had drunk a lot and had become unconscious when she was alive, and her red setter dog had bitten her legs and licked her face to arouse her. If the animal is locked for a long time, as a "displacement" behavior, its postmortem scavenging activity starts from the face of the victim and proceeds toward the lower part of the body, and finally, the abdomen is devoured [30]. In other words, initially, scavenging activity starts as a "displacement" behavior, and then as a result of the animal confined in a closed space, it continues as a result of starvation. Besides longer periods of confinement may induce aggressive behaviors in dogs, which may contribute to postmortem mutilation [11]. Furthermore, concerning human being-dog hierarchy, in case of weakness of its owner, dominancy may change in favor of the dog. In this case, a type of "mental disease" develops in the dog, and the dog may feel itself compelled to attack its owner and display aggressive behaviors against him/her to prove its leadership [25, 27, 29, 31, 32].

If postmortem feeding is prolonged, then the scavenger may have left teeth marks on the victim's bones. Basically, bite marks caused by predatory animals include pits, punctures, scores, and furrows [33]. Pits are caused by collapsing of the bone under masticatory forces created by the tip of the teeth during chewing act, but they do not penetrate into the bone cortex [34–37]. Punctures are formed by greater force exerted by teeth on bone with resultant penetration of the tip of the teeth into cortical bone. Frequently, it is seen in thin and flat bones as scapula, and it is caused by canine and carnassial teeth [21, 34, 37]. A score is a bite mark longer than three times its width. It is formed by dragging or rotatory movement of the tooth on the bone after formation of a pit [5, 21, 34, 38]. Scorings are scratches extending parallel to the long axis of the bone, which are seen as "V" or cube-shaped marks on cross section of the bone [23]. Furrows are deeply formed channel-like grooves that extend longitudinally along the long bones as femur and formed by molar and premolar teeth of the animals that repeat jaw movements with the intention to reach the bone marrow [21, 25, 33, 34]. However, if a scavenger spends lots of time in chewing, then it creates furrows and pits on the bone, which makes it impossible to discern individual teeth marks due to its continuous mumbling of the bone between its upper and lower jaws [6, 21, 25].

When the outdoor corpses are left out for a sufficient period of time, then scavengers may devour the corpse leaving only bones [33, 39, 40]. In such cases, analysis and interpretation of defective skeletal remains are requested from forensic anthropologist [19, 34, 40, 41]. Indeed, during or after feeding, these animals may change the anatomical location of bones. However, studies performed have indicated that scavenging behavior and pattern of these animals are not usually coincidental [4, 5, 25, 42–44]. Haglund et al. [41] investigated destructive changes induced by jackals and pet dogs on partially or completely skeletonized remains of human corpses created within a period ranging between 4 hours and 52 months so as to search for scavenging activity. As a result, they defined stages of disarticulation secondary to scavenging behaviors of jackals and dogs. Accordingly, the following disarticulation sequence was defined: Stage 0: No evidence of disarticulation and loss of soft tissues at an early phase (post-mortem 4 hours–14 days); Stage 1: Fragmentized ventral thorax characterized by loss of sternum, destruction of sternal ribs, evisceration, loss of scapula, partial/total loss of clavicle, and loss of one or both upper extremities (postmortem 22 days–2.5 months); Stage 2: In addition to stage 1, it also involves the lower extremities (postmortem 2–4.5 months); Stage 3: All parts of the skeleton excluding the vertebra are fragmentized, seriously injured, and destroyed. During this stage, bones are scattered at a distance varying between 3 and 91 m (postmortem 2–11 months); Stage 4: Total disarticulation (postmortem 6–52 months). However, some disarticulation patterns do not fit into these categories (18). Indeed, only three cases of four postmortem attacks by pet animals presented by Rossi et al. [29] are in concordance with disarticulation sequence defined by Haglund, while in the third case, where the culprit was a German shepherd dog, face, neck, intrathoracic organs, upper right extremity, scapula, and multiple number of cervical and thoracic vertebrae of the victim had been reportedly devoured.

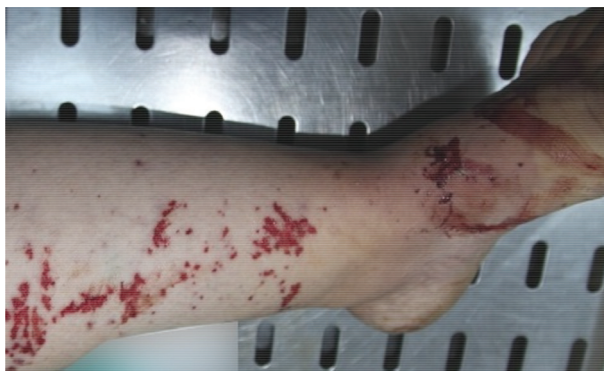The most important issue in the presence of lesions on the corpse caused by animals is to accurately discriminate between antemortem and postmortem wounds. In postmortem injuries, any defense wound on the victim's corpse is not present [26, 45, 46]. However, absence of defense wound on the deceased does not always signify wounds created during postmortem period. Salem et al. [47] presented a 27-year-old epileptic woman found dead at her home. Wide lesions on the neck of the corpse created by the domestic mongrel dog were found without any defense wounds on her body. However, on histological analysis of the wound, specimen hemorrhagic reactions were found in cutaneous, subcutaneous, and muscle tissue, which are signs of vitality. The authors asserted that the dog attacked the victim during an epileptic attack when she had lost her consciousness. Only a little amount of blood extravasated passively from the vessels of the tissue of the wound created during postmortem period [7, 9, 12, 19, 21, 48]. Besides, edema and redness on the edges of the wound that are signs of vitality are not observed [2, 21, 31, 49, 50]. Numerous histological, histochemical, and immunohistochemical methods can be used to determine whether animal attack occurred during antemortem or postmortem period. Cell types functioning in wound healing and changes in the wound with time may be determined using histological examination [51]. During histochemical examination, fibroblastic enzymes (esterases, acid phosphatase, and ATPase) may be analyzed. However, these tests have a lower reliability [52]. It has been indicated that in immunohistochemical analysis adhesion molecules as P-selectin, E-selectin, ICAM-1, VCAM-1 [53–55], inflammatory cytokines as fibronectin [56], IL-1, IL-6, TNF [57], and transforming growth factor (TGF) [58] can be used to discriminate between antemortem and postmortem

wounds. Hernández-Cueto et al. [59] indicated that levels of D-dimer are significantly higher in antemortem skin wounds relative to postmortem wounds. Ortiz-Rey et al. [60] reported that fibronectin and tenascin increase in most of the antemortem wounds. They indicated that still it was not a specific finding and yielded positive results in association with passive extravasation of these molecules from damaged blood vessels in postmortem wounds. He and Zhu [61] investigated 13 antemortem and 7 postmortem skin lesions of 7 forensic cases and determined that leukotriene B<sub>4</sub> (LTB<sub>4</sub>) was found in all antemortem wound samples, while it was not detected in any one of the postmortem wound samples.

## 1.2. Attacks of land animals during postmortem period

Consequences of postmortem animal attacks at the corpse on land differ depending on whether the corpse is in outdoor or indoor environment. Outdoor corpses may be devoured by many animals because they are defenseless. Flies and worms are most prevalently associated with decomposition of the body [2, 17, 62]. Adult insects leave their eggs on moist regions of the body, namely on wounds, eyes, lips, and genital region of fresh corpses, and with time, many herds of larvae of specific species come out of the eggs and develop [1]. Larvae may cover the corpse completely, erase potentially diagnostic cutaneous marks such as tattoos and surgical scars, and damage internal organs making determination of precise cause of death impossible [17]. Worms release proteolytic digestive secretions and thus soften tissues and create subcutaneous tunnels and sinuses during their passage, which accelerate putrefaction of the corpse [1]. These holes opened by worms may sometimes resemble wounds created by bullets [2, 63]. Although rare, enzymes secreted from salivary glands of fly larvae may puncture bone lamellae (i.e., orbital ceiling) [63]. However larvae may cause skin defects, which may be confused with penetrating stab wounds formed by sharp objects [1, 17, 49]. Moreover, some authors have claimed that swelling only due to decomposition and decay incurred by worms may disarray clothes, which can be seen as attempts of sexual assault [64]. Via evaluating developmental stages of insects and insect genome sequences on the corpse, postmortem interval can be determined [65–70]. Besides, in severely decayed corpses, DNA of the deceased can be identified by analyzing gastrointestinal contents of worms feeding on the corpse [71, 72].

Ants, which are among one of the dominant insect groups, belong to *Formicidae* family of *Hymenoptera spp.* [24]. Ants feed on outdoor corpses, but they may damage indoor corpses such as in homes and garden cottages [8]. Typically, ants start to appear a short time after death, and they may also be seen on the corpse or in its close vicinity during advanced decomposition phases of the corpse. Ants feed on adult flies and insects and their larvae, flesh, and exudates of the corpse, and they may decrease the decomposition rate significantly [24]. Ants also form colonies of queen, soldier, and worker ants and may become the dominant arthropods on the corpse. Goff and Win [73] estimated postmortem interval of a corpse based on minimum colony forming period of *Anoplolepis Longipes* (*Hymenoptera: Formicidae*) species of ants as 12 months. Postmortem ant feeding causes formation of generally superficial, serpiginous, parchmentized, and irregular-shaped skin lesions [8, 17, 24] (**Figure 1**). Besides, small punctate and scratch-type lesions that can be confused with antemortem abrasion and acid wounds may be seen [24]. Injuries caused by ants generally leave behind orange-pink wound marks scattered on the skin surface [24]. Ants usually feed on exposed areas of the body and

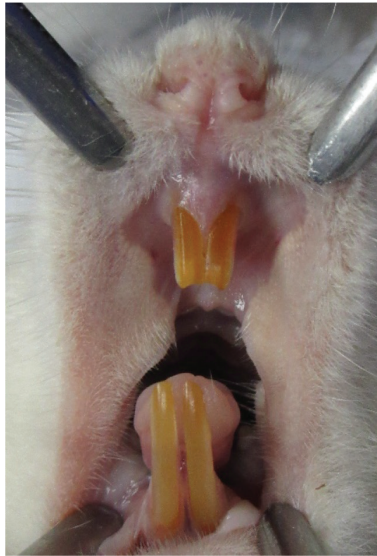


**Figure 1.** Serpiginous, parchmentized, and irregular-shaped superficial skin lesions were associated with postmortem ant activity on the left leg (Archive of Council of Forensic Medicine, Turkey).

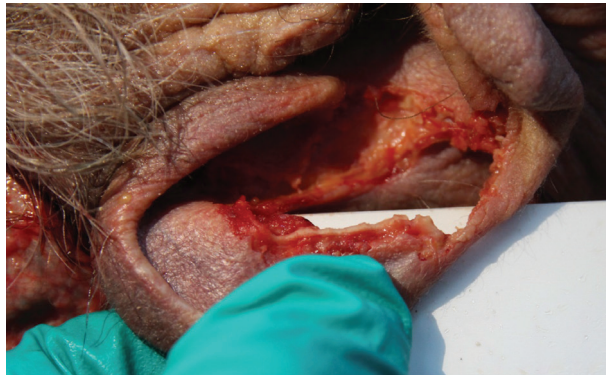edges of the clothes. Most frequently, the areas they prefer are lips, eyelids, and joints [1]. However, it has been asserted that removal of eyelashes is the characteristic activity of ants [17]. Ant bites remove the most upper layer of the skin and dermis, and underlying structures are exposed. In other words, ant bites generally cause lesions characterized by absence of only epidermal layer. This skin damage does not lead to bleeding excepting passive oozing of the blood from the ends of traumatized dermal capillaries [8]. When lesions associated with postmortem ant activity are localized on the neck, it might be erroneously interpreted as hanging marks [1, 2, 17, 24]. Besides, from regions of congestion developed because of remaining of the corpse at the same position for a long term, terminal ends of dermal capillaries bitten by ants may seriously bleed, which may be misinterpreted by investigators as signs of trauma [8, 17]. Byard presented a case of a 59-year-old victim whose autopsy revealed ischemic heart disease as the cause of death. At the incident site, lesions at the right side of the victim's forehead due to ant bites, ants moving on his face, and blood around his head had been reported [17]. Byard [8] detected congested face due to hanging, widespread lesions around neck and chin caused by ant bites, and diffuse blood spots on the face and shirt of a 51-year-old hanging victim. These cases demonstrate that recording the presence of ants especially at incident site will facilitate the work of the physician who will perform the autopsy.

Postmortem wounds caused by cockroaches are typically seen on extremities covered by tunnel-like clothing. Cockroaches may cause superficial dermal abrasions resembling skin diseases [2].

Predators as rodents also devour tissues of the dead body most dramatically as insects [13, 48]. Rodents (mouse, rat, hamster, etc.) have a total of 16 teeth, including 2 incisors and 6 molar teeth both in the upper and lower jaws [74] (**Figure 2**). Parallel cutaneous lesions and fine serrated wound contours on corpses caused by upper and lower incisor teeth of the rodents during postmortem feeding are observed [9, 10, 13, 48, 74] (**Figures 3 and 4**). Irregular edges of wounds due to repetitive gnawing may be seen [10]. If the bone is also gnawed, then parallel scratches or furrows may be formed at the edges of the bone [13, 25, 37]. Rodents may feed on corpses both in the open air and in confined space as home [9, 13, 25, 37, 48, 74]. Rodent

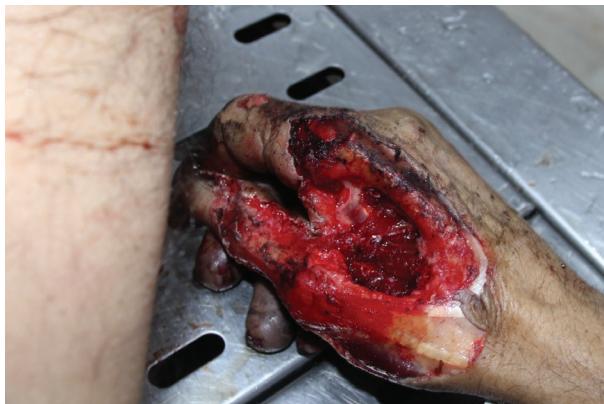

**Figure 2.** Two incisor teeth both in the upper and lower jaws in a rat.



**Figure 3.** Soft and cartilaginous tissue loss due to postmortem rodent activity in right ear and irregular serrated appearance at wound edge (Archive of Council of Forensic Medicine, Turkey).

activity has been reported more frequently in lower socioeconomic living conditions and among homeless people [26]. At the incident site, the presence of rodent feces should suggest postmortem rodent activity [9, 13]. Especially when indoor postmortem rodent interference is suspected, searching for rodent nest at the incident site facilitates establishment of accurate diagnosis [13, 74]. Ropohl et al. [74] presented a case of a 43-year-old woman whose hip and lower abdominal and genital regions were naked, which raised the suspicion of a sexual assault. At the incident site, widespread tissue defects on the face of the victim and rodent feces and in a drawer a golden hamster wrapped in paper towels were found. In the nest of



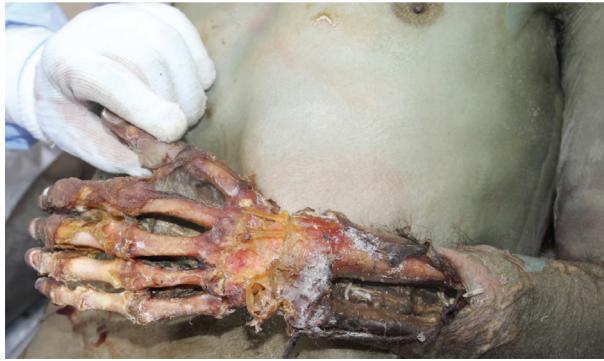**Figure 4.** Soft tissue defect of the right hand due to postmortem rodent activity. Irregular wound margin and disclosed underlying muscle and tendon (Archive of Council of Forensic Medicine, Turkey).

the hamster made up of these paper towels, pea-shaped tissue and muscle fragments were detected. When the rodent has enough time for feeding, it devours naked, unclothed, easily accessible parts of the body such as face and arms, till bones, (**Figure 5**) and this situation may create problems in identification of the victim. In the author's own case, a 75–80-year-old solitary woman in bad socioeconomic status was found dead at home. Widespread soft tissue and muscle loss on face, neck, and upper extremities that exposed the underlying bone tissue were observed. Both of her hands were amputated from the wrists. On the edges of the wounds, teeth marks peculiar to rats were detected, and pneumonia was implicated for her cause of death [75] (**Figure 6a, b**).

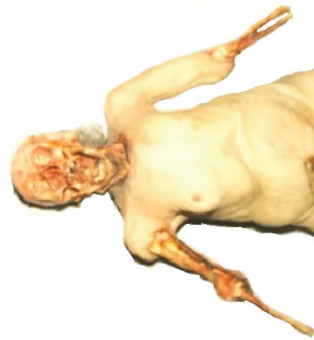Rodents may harm the corpse within a very short time. A 41-year-old homeless victim was found dead inside an arbor. It was determined that postmortem rodent injuries, detected at autopsy but not in the photographs taken at the scene and in the reports of the scene investigator, had taken place within a short time as approximately 45–60 minutes [13]. Byard [17] reported two victims who had bullet entry holes on the nasal root, which deformed with post-mortem rodent activity, and lesions on hands caused by rodent activity had been confused with defense wounds.

Vultures, eagles, ravens, magpies, and many species of birds can feed on corpses [4, 5, 39, 62, 76, 77]. Birds primarily tend to feed on eyes of the corpses. This condition may lead to misinterpretations by crime scene investigators as a sadistically committed crime or ritual mutilation performed on the corpse [17]. Scavenger birds as magpies and crows peck and tear the corpse during feeding, which causes characteristic triangle-shaped holes on the corpse [76]. Dettling et al. [78] demonstrated unusual patched areas of epidermal lesions on naked unclothed parts of a dead woman caused by scavenging activity of songbird characterized by “pecking and dragging.” In another case, loss of eye globe and earlobe due to crow feeding was reported [79]. Variations in beak morphologies of birds may cause different lesions. Vultures and falcons may leave wounds with smooth contours resembling surgical cuts after plucking the skin [76]. Birds can tear away intact skin, but they primarily prefer to feed on





**Figure 5.** Widespread muscle and soft tissue loss disclosed skeletal tissue due to long-term postmortem rodent activity (Archive of Council of Forensic Medicine, Turkey).

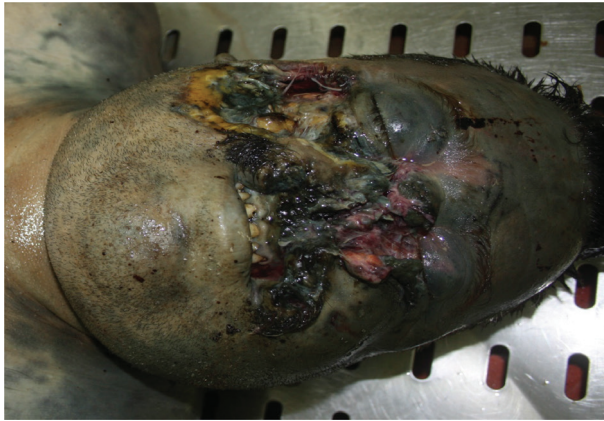

**Figure 6.** The incident site of the corpse of a 75–80-year-old woman who was living alone in low socioeconomic level is shown in (a). Amputated hand, extensive soft tissue, and muscle loss that exposed bone tissue of head, neck, and upper extremity caused by postmortem activity of rodents are seen in (b).

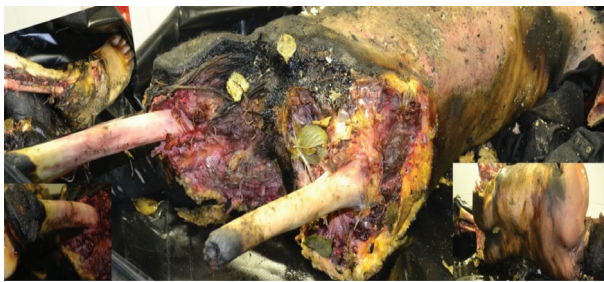the places where skin integrity is disrupted or eroded. If the corpse is exposed to penetrating trauma during perimortem period, then birds frequently focus on this injured region, and a large round hole may occur due to feeding [76]. In a study on the most known scavenger bird, namely vultures, it was reported that vultures observe the corpse for 24 hours before feeding on it, and during 4–5 hours of active feeding period, they can skeletonize the corpse [80]. Conversely, in an observational study, Beck et al. [5] left pig carcasses in an open field and indicated that vultures had started to feed on the corpse 17 days later, which they attributed to raining that suppressed the spread of odor of the carcass. In addition, some studies with 37 days of follow-up period have been also cited [39]. If crows and magpies want to feed on larvae in cancellous bone, they will remove outer cortical layer of the bone and cause cone-shaped lesions in the cancellous bone. These cone-shaped lesions caused by beaks of the birds do not demonstrate any symmetry. These lesions are haphazardly placed, and frequently they overlap. Destructive changes seem to focus on a certain area. Birds focus on an area of soft tissue to create a round hole, and also they target a certain part of the bone, remove the

cortical layer, and create a collapsed area on the cancellous bone. Birds frequently leave their teeth marks on the center of the long bones or flat parts of irregularly shaped bones as scapula and innominate bone [76]. Vultures frequently feed on body openings as anus, enlarge them, and try to reach internal organs through them. After consuming soft tissues of the head, they feed on cervical region and try to access into fatty brain tissue through foramen magnum. As a result, while vultures try to access into brain during feeding activity, cervical vertebrae are consumed, and bone tissue around foramen magnum is damaged. Since intra-abdominal organs are tried to be accessed through anus, lumbar vertebrae are frequently spared [5]. Asamura et al. presented two carbonized corpses. In their cases, crows had caused bulgings on head and extremities while they were pulling and stretching attached nerve fibers, tendons, and ligaments with their beaks during their feeding activities, and in one case, defective areas with serrated contours corresponding to the configuration of the beaks of crows in lungs, liver, spleen, and kidneys were found [62]. Behavior pattern of birds and bird species exerting scavenging activity demonstrate seasonal and regional variation [77]. In West Australia, the dominant scavenger bird is raven [4, 77], while in Arizona-Texas, it is the vulture [5, 39]. It has been determined that ravens prefer to feed on corpses at sunrise and sunset during summer months, while during cold winter months, they prefer to feed during hot daytime hours [77]. After scavenging activity of birds, bones and personal belongings of the deceased may scatter around a large area. It has been determined that vultures visit skeletonized corpse and scatter the bones after they skeletonize the corpse. It has been indicated that the vultures scatter bones and personal belongings 25 m far away from the first location of the corpse, so it has been suggested that in these cases area of investigation should encompass at least an area of 100 m<sup>2</sup> [5].

The common characteristics of postmortem wounds caused by carnivorous animals are the presence of lesions resembling stab wounds because of their canine teeth and frequently linear scratches created by paws near these wounds [2, 26]. Punctured, irregular, partially curled "V" or rhomboid-shaped wound edges in soft tissue caused by bites of Canidae (wolf, pet dogs, jackal, fox, etc.) are seen [7, 9, 10, 12, 25] (**Figures 7 and 8**). Canidae uses its mandibular and maxillary canine teeth during feeding and create punctures and multiple numbers of adjacent tears in the soft tissue caused by shear-bites, which are termed as "one hole-one tear" combination [81]. The animal uses this region as a fulcrum, counteracts the weight of the corpse, and rapidly shakes its head repetitively from right to left and vice versa to pluck the tissue and creates stretch-rupture defects [25]. Canidae may cause pit, puncture, score, and furrow-type bite marks on the bone surface [33]. Various breeds of dogs in the same family may have diverse teeth size, jaw, bite strength, scavenging behavior, and pattern, which affect the configuration of bite marks on the bone surface [82-84]. Carnivorous animals frequently cause destructive changes on epiphyseal ends of long bones; transverse and spinous processes of vertebrae; and distal ends of ribs, scapula, and hip bones [33, 37]. Postmortem scavenging lesions caused by animals belonging to the Canidae family are most frequently seen in nose, mouth, neck, and upper and lower extremities and least frequently in anus, penis, and abdomen [25]. Wounds caused by animals belonging to the Felidae family have sharper and smooth edges just as cut by a knife, and on the edges of the wounds, linear, scratch-type lesions formed by paws may be detected [10, 29, 44, 85]. Rippley et al. [44] investigated scavenging behavior of bobcats (*Lynx Rufus*). They observed these animals for 32 days and reported that bobcats consumed



**Figure 7.** Common soft and muscle tissue loss on right cheek, nose, and upper lip due to postmortem Canidae scavenging (Archive of Council of Forensic Medicine, Turkey).



**Figure 8.** A corpse of a 17-year-old man who died because of stabbing and was burned after death. Amputated left limb, extensive soft tissue, and muscle loss that exposed bone tissue of lower limbs and hip caused by postmortem Canidae scavenging activity.

soft tissues of the forearms, hips, thighs, and abdominal region and left multiple puncture marks on the ulna and radius with an attempt to disarticulate the arm. Besides, it was demonstrated that lynx tried to hide the corpse with a heap of mud, grass, and pine needles after it consumed the corpse for future feeding process, which might create complications as for the identification of the corpse by forensic medicine and forensic anthropology. Bears are one of the biggest carnivorans, which cause postmortem injuries [40]. Carson et al. [40] indicated the presence of significant differences in scavenging models of bears and canid family and argued that discrimination between bears and dogs based on the presence or absence of remains of human skeletons found in and around the incident site is possible. Bears usually devour axial skeleton and tend to consume, extract, or damage vertebrae, ribs, and sternum, while members of the canid family frequently damage extremities and through opened body holes devour internal organs incurring little injury on vertebral column. If only skeletal tissue was left behind because of scavenging activity of carnivores, the attacking animal may be identified looking on the length and width of the bite marks on the bone [33, 34]. It has been claimed

that the average length (<2.5 mm) and width (<1.5 mm) of the pit created by red fox could discriminate the red fox from larger-sized members of the Canidae family [33]. Dominguez-Rodrigue and Piqueras [86] categorized the carnivorans based on pit lengths and widths they created on cancellous bone as follows: pit length < 4 mm, small-sized canines (jackals), and medium-sized Felidae (leopard and cheetah); pit length: 4–6 mm: (medium-large sized carnivorans (members of the Felidae family, excluding lion); pit length: > 6 mm: large-sized carnivorans (hyena and lion); pit width: < 2 mm small-sized members of the Felidae family; pit width: > 4 mm: hyena, bear, lion, and dog. Murmann et al. [84] suggested that when bite mark measurements of lower and upper jaws of animals are evaluated in combination, then discrimination between members of Canidae and Felidae is possible. Furthermore, Foust [34] claimed that when dimensions of bite marks and measurements of upper and lower jaws of the animals are evaluated in combination, then the species of scavenging carnivorans will be predicted accurately at a rate ranging between 75.5 and 78.3%.

Among scavenger carnivorans, pet dogs and cats that are responsible for attacks on corpses especially in indoor settings should also be mentioned. The wounds they create mislead the forensic investigator, and result in misinterpretation of the event as a criminal case. Postmortem attacks by pet dogs have been reported more frequently when compared with domestic cats [6, 7, 9, 10, 12, 17, 25, 27, 29]. When teeth marks of an animal were detected on a corpse in indoor settings, if on the incident site Pitbulls, Rottweiler, and German shepherd dogs are found, then the possibility of an antemortem attack should also be considered. Indeed, these dog breeds are “convicts” [49, 81, 87, 88]. It has been thought that pet dogs have regular food sources and do not feed on corpses; however, when they take a walk outside, they can also feed on corpses, and it has been indicated that in some circumstances, they may be unknown but important members of fauna consume corpses in the open air [5]. Antemortem dog attacks may cause wounds resembling those created by postmortem dog attacks. Therefore, signs of vitality on wound site, presence of bleeding, and results of histological examinations to be performed are very important in discrimination between antemortem and postmortem dog attack [21]. In indoor setting, attacks of dogs at corpse may start soon after death, in other words within hours [27, 28]. “V” shaped and rhomboid lesions occurred by the attacks of domestic dogs cause puncture-type wounds [9, 12], and domestic cat bites create small, round wounds with smooth edges [10]. Serious damages may be incurred on corpses leading to decapitation secondary to dog consumption of the corpse [12]. Bones and animal feces may be scattered all over the rooms of the home in scavenging activities occurred in confined places [6, 7, 9, 11, 12, 27]. The stomach of the offensive dog may contain personal belongings and body parts such as teeth of the victim that may be helpful in the identification of the corpse [12]. Chute et al. [7] presented a putrefied corpse of a 63-year-old female, and they detected amputation at the level of elbow joints of both upper extremities, diffuse soft tissue, and bone defects exposing underlying bone tissue caused by scavenging activity of a dog. X-ray of the Pitbull Terrier found at the incident site revealed radiolucent material (jewelry and teeth) in its stomach. From dog feces, 6 teeth, 3 earrings, and 10 finger nails were removed, which confirmed the identity of the corpse when compared with dental records. If the dog stays at home with the corpse for a sufficient time period, excluding a small part of the body or even a few bone fragments, all of the corpse may be consumed [6, 12]. In a case report presented by Steadman et al. [6], a 54-year-old woman who remained at home with

her two dogs had died probably 4 weeks ago. When her corpse was discovered, only a calvarium and bone fragments of various lengths belonging to 60 different long bones had been detected. Rarely, it has been reported that in cases of death due to poisoning, domestic animals feeding on the corpse may be found dead at the incident site. Rossi et al. [29] presented a case of a 32-year-old male who was found dead at home, and tissue losses of his head, neck, and upper right extremity related to scavenging activity of a cat had been reported. Dead bodies of 10 cats of a victim had been also found at the incident site. Toxicologic analysis of the corpse revealed dothiepin intoxication as a cause of death, and the death of the cats had been also attributed to dothiepin poisoning.

In order to identify the species of the offending animal that demonstrated postmortem scavenging activity, it is very important to know scavenging animals peculiar to this region [5, 20]. Gunawarden [20] reported two cases taken out from water canal and two cases from the river in Sri Lanka. On various parts of the corpses, cuts, erythematous lesions, and soft tissue loss that did not demonstrate vital reactions without any bone defects had been found. Autopsies had disclosed the presence of postmortem wounds, which had been attributed to a large water monitor, i.e., kabaragoya (*Varanus salvator salvator*), and which is the second largest lizard after Komodo monster living in Sri Lanka. This animal has sharp claws; however, its claws and jaws are not strong enough to harm the bone. However, it creates cuts in soft tissues of the corpse as if formed with a sharp tools.

### 1.3. Postmortem animal attacks in water

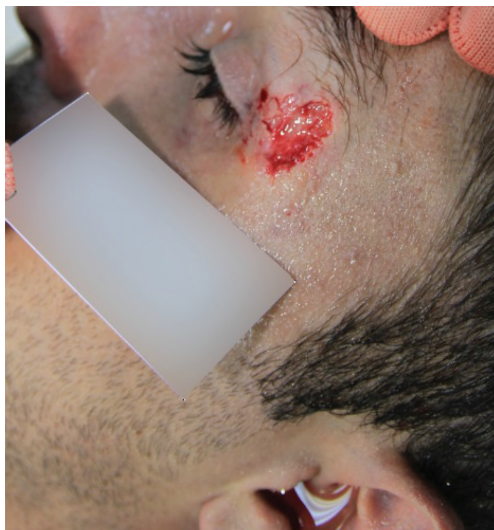If the corpse is immersed in deep waters, then it may be attacked by many sea creatures including fish, water rats, crabs, and amphipods [14–16]; however, if it is in shallow water, then predators living on land may damage the corpse [1]. In deep waters such as ocean and sea, many small fish species feed on corpses [14, 16, 89]. The best-known scavengers that feed on corpses in deep waters are sharks [1, 2, 89]. Shark bites cause clean cuts in skin and underlying soft tissue. Shark bites may cause flap-type elevations from soft tissue, which correspond to easily recognized triangular dental configuration of the shark [2, 17]. Besides owing to their strong jaw bones, they may cause extensive tissue defects together with fractures of underlying bone tissue [1]. If no one witnesses attacks of the shark, and only a part of the corpse could be obtained, then it is generally impossible to detect whether the wound is related to postmortem feeding or antemortem fatal attack of the shark [2, 17]. However, similar bite marks may be detected on clothes, and shark teeth buried in the bone can be found [90]. Byard presented a case report concerning the corpse of a 17-year-old male who had been drown, which demonstrated clean cuts and elevated triangular skin defects in the form of flaps on the left side of his neck, hips, and upper thighs caused by scavenging activity of a large-sized shark [17]. Teeth marks of the shark may change depending on the species and size of the shark. Hayashi et al. presented a case of a 50-year-old drowned female who had demonstrated circular, elliptic postmortem soyabean-sized (3.7 × 5.1 cm) wounds with relatively sharp edges on the anterior aspect of her neck [91]. They suggested that spoon-like concave bases of these wounds were associated with adipose tissue or superficial layer of the muscle, which were formed by cookiecutter shark (*Isistius brasiliensis*). These sharks are only 50 cm in length. With their thick lips and modified pharynx, they hold on their victims, and

they rub sharp teeth of their lower jaw on the wound and create characteristic circular and concave lesions. Makino et al. presented a 60-year-old woman who had committed suicide and whose corpse had been found 6 days later in the ocean. The authors reported the presence of circular and "C"-shaped wounds on her corpse caused by a bite of a shark belonging to the *Isistius* species [92].

Relatively smaller fish can incur serious destructive changes in the corpse [1, 14, 16] (**Figure 9**). The most commonly known members of this group are piranhas [1]. Sazima et al. presented three cases of postmortem piranha feeding [93]. The first case belonged to a 25-year-old woman who had been found 4 days in a nearly skeletonized state after she had drowned. The second case was of a 50-year-old male. His corpse had been found within hours after he had been drowned with manifestation of diffuse loss of cranial soft tissue. The third corpse belonged to a 70-year-old male who was found 20 hours after he had fallen into water following a heart attack. The authors indicated that only a small amount of fresh flesh had been detected on his abdomen, while the remaining parts of his body had been completely skeletonized.

Crocodiles and alligators attack living beings with fatal outcomes and also assault corpses as well. Characteristic bite marks of crocodiles include holes pairing with each other and gradually getting closer to each other toward the nose [94]. Crocodiles have conic teeth and cause deep puncture and slash wounds [95]. Missing extremity parts and bone fractures including cranial fractures can be seen after attacks by crocodiles. Multiple punctate wounds with irregular edges can be seen secondary to crocodile bites [96].

Sea lice (*Natatolana woodjonesi*) are isopods nearly 2.5 cm in length that live on sand surface and in shallow waters. They move actively when they search for food [2]. Sea lice may surround corpses immersed in ocean very rapidly. Under appropriate conditions, they can quickly

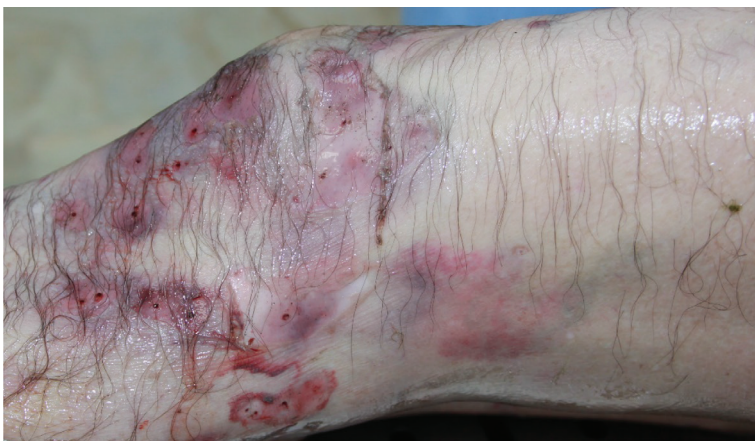

**Figure 9.** Soft tissue loss of  $2 \times 1$  cm with semilunar-shaped notches of 0.1 cm in the edges due to postmortem small fishes scavenging on the left temple (Archive of Council of Forensic Medicine, Turkey).

multiply and open holes on the corpses, enter into subcutaneous layer, and devour muscle and subcutaneous tissue. However, the uppermost skin tissue remains intact excepting holes created [17]. Tsokos reported a case where sea lice caused a dramatic mutilation of the corpse's face within a short time as 12 hours [2]. Oval punctate lesions opened by sea lice so as to enter into subcutaneous layer may appear as shotgun wounds on exposed body parts such as the face [17].

Apart from fish, small sea creatures as amphipods, gastropods, and decapods also actively participate in postmortem scavenging activity in deep waters [14, 16, 89] (**Figure 10**). If in corpses taken out from deep waters, bones are not damaged markedly, and any bite mark is not detected on the surfaces of the bones, then the feeding of small sea creatures as amphipods, which easily move in tunnel-shaped clothes as pants, without displacing bones, and damage bone cortex, is conceived [16]. In deep waters, scavengers' consumption rate of the corpse may differ based on the depth of the sea where the corpse was found, latitude, and type of food [14]. It was reported that in North Atlantic a corpse of a whale weighing 50–100 kg found at 4000–8000 m deep might become a mere skeleton due to postmortem feeding within 15 days. Dumser et al. [16] presented case reports of two corpses belonging to one pilot who had a jet plane accident offshore of Namibia and another pilot whose helicopter crashed into the Mediterranean Sea. They indicated that in the Mediterranean Sea main scavenger species are decapods such as crabs and fish, while in the Atlantic Ocean, amphipods species are also involved in the scavenging activity, which speeds up consumption of the corpses. Just like sea lice, amphipods may invade all over the corpse and open tunnels in the corpse [14]. In addition, skeleton of the corpses found in deep waters may be damaged by gnawing of decapods such as crabs, apart from sharks, and great predators [16].

Sea stars live on the seafloor and cannot swim actively. During early postmortem period, sea stars cause development of hematomas by sucking action, which may be easily confused with antemortem hematomas. However, the discovery of a sea star on the corpse demonstrates that the corpse had remained at the seafloor for a while [2].



**Figure 10.** Oval, hemorrhagic lesions of 0.2 cm in diameter in the middle of red-colored ecchymosis of 1 cm in diameter due to postmortem small sea creature scavenging (Archive of Council of Forensic Medicine, Turkey).

## Author details

Zerrin Erkol<sup>1\*</sup> and Erdem Hösükler<sup>2</sup>

\*Address all correspondence to: zerrinerkol@gmail.com

1 Department of Forensic Medicine, Faculty of Medicine, Abant İzzet Baysal University, Bolu, Turkey

2 Directorate of Bolu Forensic Medicine Branch, Council of Forensic Medicine, Bolu, Turkey

## References

- [1] Saukko P, Knight B. The pathophysiology of death. In: Knight's Forensic Pathology, 3rd ed., London: Arnold; 2004. pp. 73-76
- [2] Tsokos M. Postmortem changes and artifacts occurring during the early postmortem interval. In: Forensic Pathology Reviews. Vol. 3. New Jersey: Humana Press Inc.; 2005. pp. 183-236
- [3] Ozer E, Sam B, Tokdemir MB, Yildirim A, Cetin G. Medicolegal autopsy artefacts. Bulletin of Legal Medicine. 2010;**15**(2):68-74
- [4] O'Brien RC, Forbes SL, Meyer J, Dadour I. Forensically significant scavenging guilds in the southwest of Western Australia. Forensic Science International. 2010;**198**:85-91
- [5] Beck J, Ostericher I, Sollish G, De Le J, Desert S. Animal scavenging and scattering and the implications for documenting the deaths of undocumented border crossers in the Sonoran Desert. Journal of Forensic Sciences. 2015;**60**:11-20
- [6] Steadman DW, Worne H. Canine scavenging of human remains in an indoor setting. Forensic Science International. 2007;**173**:78-82
- [7] Chute DJ, Bready RJ. A case of postmortem canine depredation. The American Journal of Forensic Medicine and Pathology. 2017;**38**(2):100-102
- [8] Byard RW. Autopsy problems associated with postmortem ant activity. Forensic Science, Medicine, and Pathology. 2005 Mar;**1**(1):37-40
- [9] Tsokos M, Schulz F. Indoor postmortem animal interference by carnivores and rodents: Report of two cases and review of the literature. International Journal of Legal Medicine. 1999;**112**:115-119
- [10] Tyagi A, Tyagi S, Malik N, Chawla H. Postmortem cadaveric depredation by animals – A diagnostic dilemma. International Journal of Forensic Medicine and Toxicological Sciences. 2016;**1**(1):20-23
- [11] Weeratna J, Amararathna S, Rask R, Vidanapathirana M. Indoor postmortem animal scavenging. Sri Lanka Journal of Forensic Medicine, Science & Law 2014;**5**(1):2-8



- [12] Buschmann C, Solarino B, Pu K, Czubaiko F, Heinze S, Tsokos M. Post-mortem decapitation by domestic dogs: Three case reports and review of the literature. *Forensic Science, Medicine, and Pathology*. 2011;**7**:344-349
- [13] Tsokos M, Matschke J, Gehl A, Koops E, Puschel K. Skin and soft tissue artifacts due to postmortem damage caused by rodents. *Forensic Science International*. 1999;**104**:47-57
- [14] Jones EG, Collins MA, Bagley PM, Addison S, Priede IG. The fate of cetacean carcasses in the deep sea: Observations on consumption rates and succession of scavenging species in the abyssal north-east Atlantic Ocean. *Proceedings of the Royal Society of London. Series B*. 1998;**265**:1119-1127
- [15] Petrik MS, Hobischak NR, Anderson GS. Examination of factors surrounding human decomposition in freshwater: A review of body recoveries and coroner cases in British Columbia. *Canadian Society of Forensic Science Journal*. 2004;**37**(1):9-17
- [16] Dumser TK, Türkay M. Postmortem changes of human bodies on the Bathyal Sea floor – two cases of aircraft accidents above the Open Sea. *Journal of Forensic Sciences*. 2008;**53**(5):1049-1052
- [17] Byard RW. Diagnostic problems associated with cadaveric trauma from animal activity. *The American Journal of Forensic Medicine and Pathology*. 2002;**23**(3):238-244
- [18] Tokdemir MB, Cetin G, Sam B, Ozer E, Yildirim A, Butun C. The challenges in autopsy cases exposed to animal attack. *MediScience*. 2014;**3**(2):1209-1223
- [19] Haglund WD. Rodents and human remains. *Journal of Forensic Sciences*. 1992;**37**:1459-1465
- [20] Gunawardena SA. Artefactual incised wounds due to postmortem predation by the Sri Lankan water monitor (kabaragoya). *Forensic Science, Medicine, and Pathology*. 2016;**12**(3):324-330
- [21] Fonseca GM, Mora E, Lucena J, Cantin M. Forensic studies of dog attacks on humans: A focus on bite mark analysis. *Journal of Forensic Medicine Science*. 2015;**5**:39-51
- [22] Willey P, Snyder L. Canid modification of human remains: Implications for the time-since-death estimations. *Journal of Forensic Sciences*. 1989;**34**:894-901
- [23] Moraitis K, Spiliopoulou C. Forensic implications of carnivore scavenging on human remains recovered from outdoor locations in Greece. *Journal of Forensic and Legal Medicine*. 2010;**17**(6):298-303
- [24] Campobasso CP, Marchetti D, Introna F. Postmortem artifacts made by ants and the effect of ant activity on Decompositional rates. *The American Journal of Forensic Medicine and Pathology*. 2009;**30**(1):1-4
- [25] Colard T, Delannoy Y, Naji S, Gosset D, Hartnett K, Anne B. Specific patterns of canine scavenging in indoor settings. *Journal of Forensic Sciences*. 2015;**60**(2):495-500
- [26] Shkrum MJ, Ramsay DA. Postmortem Changes “The Great Pretenders” in Forensic Pathology of Trauma: Common Problems for the Pathologist. New Jersey: Humana Press; 2007. pp. 23-64

- [27] Rothschild MA, Schneider V. On the temporal onset of postmortem animal scavenging. "Motivation" of the animal. *Forensic Science International*. Sep 19, 1997;**89**(1-2):57-64
- [28] Schumann M, Nolte I, Huckenbeck W, Barz J. Post-mortem animal injury – A few hours after death? *Rechtsmedizin*. 1996;**7**:22-24
- [29] Rossi ML, Shahrom AW, Chapman RC, Vanezis P. Postmortem injuries by indoor pets. *The American Journal of Forensic Medicine and Pathology*. 1994;**15**(2):105-109
- [30] Burkhardt S, Lardi C, La Harpe R. Postmortem partial skelitanization of the face and neck by an Appenzell mountain dog. *Archiv fur Kriminologie*. 2009;**223**(3-4):117-122
- [31] Grellner W, Meyer E, Fechner G. Simulation of attempted homicide by dog bite in unconscious state. *Archiv für Kriminologie*. 1998;**201**:165-171
- [32] Hayase T, Yamamoto K, Yamamoto Y. An unusual case of extensive cadaver ingestion by a domestic dog. *Archiv für Kriminologie*. 1994;**194**:177-181
- [33] Young A, Stillman R, Smith MJ, Korstjens AH. Scavenger species-typical alteration to bone: Using bite mark dimensions to identify scavengers. *Journal of Forensic Sciences*. 2015;**60**(6):1426-1435
- [34] Foust Jennifer L. The use of tooth pit and tooth/jaw measurements to identify carnivore taxa responsible for damage on scavenged bone. Graduate Student Theses, Dissertations, & Professional Papers 1102. 2010. Available from: <https://scholarworks.umt.edu/etd/1102> (Accessed: Nov 20, 2017)
- [35] Pickering TR, Dominguez-Rodrigo M, Egeland CP, Brain CK. Beyond leopards: Tooth marks and the contribution of multiple carnivore taxa to the accumulation of the Swartkrans member 3 fossil assemblage. *Journal of Human Evolution*. 2004;**46**:595-604
- [36] Coard R. Ascertaining an agent: Using tooth pit data to determine the carnivores responsible for predation in cases of suspected big cat kills in an upland area of Britain. *Journal of Archaeological Science*. 2007;**34**:1677-1684
- [37] Haglund WD, Reay DT, Swindler DR. Tooth mark artifacts and survival of bones in animal scavenged human skeletons. *Journal of Forensic Sciences*. 1988;**33**(4):985-997
- [38] Selvaggio MM. Carnivore tooth marks and stone tool butchery marks on scavenged bones: Archaeological implications. *Journal of Human Evolution*. 1994;**27**(1-3):215-228
- [39] Spradley MK, Spradley MK, Hamilton MD, Giordano A. Spatial patterning of vulture scavenged human remains. *Forensic Science International*. 2014;**219**(1-3):57-63
- [40] Carson EA, Stefan VH, Powell JF. Skeletal manifestations of bear scavenging skeletal manifestations of bear scavenging. *Journal of Forensic Sciences*. 2000;**45**(3):515-526
- [41] Haglund WD, Reay DT, Swindler DR. Canid scavenging/disarticulation sequence of human remains in the Pacific northwest. *Journal of Forensic Sciences*. 1989;**34**(3):587-606

- [42] Kjorlien YP, Beattie OB, Peterson AE. Scavenging activity can produce predictable patterns in surface skeletal remains scattering: Observations and comments from two experiments. *Forensic Science International*. 2009 Jul 1;**188**(1-3):103-106
- [43] Jeong Y, Jantz LM, Smith J. Investigation into seasonal scavenging patterns of raccoons on human. *Journal of Forensic Sciences*. Mar 2016;**61**(2):467-471
- [44] Rippley A, Larison NC, Moss KE, Kelly JD, Bytheway JA. Scavenging behavior of *Lynx rufus* on human remains during the winter months of Southeast Texas. *Journal of Forensic Sciences*. 2012;**57**(3):699-705
- [45] Lauridson JR, Meyers L. Evaluation of fatal dog bites: The view of the medical examiner and animal behaviorist. *Journal of Forensic Sciences*. 1993;**38**:726-731
- [46] Clark MA, Sandusky GE, Hawley DA, Pless JE, Fardal PM, Tate LR. Fatal and near-fatal animal bite injuries. *Journal of Forensic Sciences*. 1991;**36**:1256-1261
- [47] Salem NH, Belhadj M, Aissaoui A, Mesrati MA, Chadly A. Multidisciplinary approach to fatal dog attacks: A forensic case study. *Journal of Forensic and Legal Medicine*. 2013;**20**(6):763-766
- [48] Patel F. Artefact in forensic medicine: Postmortem rodent activity. *Journal of Forensic Sciences*. 1994;**39**:257-260
- [49] Tsokos M, Byard RW, Püschel K. Extensive and mutilating craniofacial trauma involving defleshing and decapitation. *The American Journal of Forensic Medicine and Pathology*. 2007;**28**:131-136
- [50] Pollak S, Nadjem H, Faller-Marquardt M. Agonal dog bite injuries. *Beiträge zur Gerichtlichen Medizin*. 1992;**50**:351-356
- [51] Ohshima T. Forensic wound examination. *Forensic Science International*. 2000;**113**:153-164
- [52] Grellner W, Madea B. Demands on scientific studies: Vitality of wounds and wound age estimation. *Forensic Science International*. Jan 17, 2007;**165**(2-3):150-154
- [53] Hernández-Cueto C, Girela E, Sweet DJ. Advances in the diagnosis of wound vitality: A review. *The American Journal of Forensic Medicine and Pathology*. 2000;**21**(1):21-31
- [54] Dressler J, Bachmann L, Strejc P, Koch R, Müller E. Expression of adhesion molecules in skin wounds: Diagnostic value in legal medicine. *Forensic Science International*. 2000 Sep 11;**113**(1-3):173-176
- [55] Dressler J, Bachmann L, Koch R, Müller E. Estimation of wound age and VCAM-1 in human skin. *International Journal of Legal Medicine*. 1999;**112**(3):159-162
- [56] Balazic J, Grajn A, Kralj E, Serko A, Stefanic B. Expression of fibronectin suicidal in gun shot wounds. *Forensic Science International*. Jan 17, 2005;**147**(Suppl):S5-S7
- [57] Pakis I, Kaya EA. Evaluation of vitality and wound age in forensic medicine practice. *Journal of Forensic Medicine*. 2011;**25**(2):137-152

- [58] Grellner W, Vieler S, Madea B. Transforming growth factors (TGF $\alpha$  and TGF- $\beta$ 1) in the determination of vitality and wound age: Immunohistochemical study on human skin wounds. *Forensic Science International*. 2005;**153**:174-180
- [59] Hernández-Cueto C, Vieira DN, Girela E, Marques E, Villanueva E, Sá FO. Diagnostic ability of D-dimer in the establishment of the vitality of wounds. *Forensic Science International*. 1995;**76**(2):141-149
- [60] Ortiz-Rey JA, Suárez-Peñaranda JM, Muñoz-Barús JI, Alvarez C, San Miguel P, Rodríguez-Calvo MS, Concheiro-Carro L. Expression of fibronectin and tenascin as a demonstration of vital reaction in rat skin and muscle. *International Journal of Legal Medicine*. 2003;**7**(6):356-360
- [61] He L, Zhu J. Distinguishing antemortem from postmortem injuries by LTB $_4$  quantification. *Forensic Science International*. 1996;**81**(1):11-16
- [62] Asamura H, Takayanagi K, Ota M, Kobayashi K, Fukushima H. Unusual characteristic patterns of postmortem injuries. *Journal of Forensic Sciences*. 2004 May;**49**(3):592-594
- [63] Pollak S, Reiter C. Maggot-induced postmortem changes simulating gunshot wounds. *Archiv für Kriminologie*. 1988;**181**(5-6):146-154
- [64] Komar D, Beattie O. Postmortem insect activity may mimic Perimortem sexual assault clothing patterns. *Journal of Forensic Sciences*. 1998;**43**(4):792-796
- [65] Prahlow J. Postmortem changes and time of death. In: *Forensic Pathology for Police, Death Investigators, Attorneys, and Forensic Scientists*. Springer Science & Business Media. 2010. pp. 162-184
- [66] Anderson GS. Determining time of death using blow fly eggs in the early postmortem interval. *International Journal of Legal Medicine*. 2004 Aug;**118**(4):240-241
- [67] Sharma R, Garg RK, Gaur JR. Various methods for the estimation of the post mortem interval from Calliphoridae: A review. *Egyptian Journal of Forensic Sciences*. 2015;**5**(1):1-12
- [68] Davies K, Harvey ML. Internal morphological analysis for age estimation of blow fly pupae (*Diptera: Calliphoridae*) in postmortem interval analysis. *Journal of Forensic Sciences*. 2013;**58**(1):79-84
- [69] Broen K, Thorne A, Harvey M. Preservation of *Calliphora vicina* (*Diptera: Calliphoridae*) pupae for use in postmortem interval estimation. *Forensic Science International*. 2012;**223**:176-183
- [70] Amendt J, Campobasso CP, Gaudry E, Reiter C, LeBlance HN, Hall MJR. Best practice in forensic entomology-standarts and guidelines. *International Journal of Legal Medicine*. 2007;**121**:90-104
- [71] Chávez-Briones ML, Hernández-Cortés R, Díaz-Torres P, Niderhauser-García A, Ancer-Rodríguez J, Jaramillo-Rangel G, Ortega-Martínez M. Identification of human remains by DNA analysis of the gastrointestinal contents of fly larvae. *Journal of Forensic Sciences*. 2013;**58**(1):248-250

- [72] Wells J, Introna F, Di Vella G, Campobasso C, Hayes J, Sperling F. Human and insect mitochondrial DNA analysis from maggots. *Journal of Forensic Sciences*. 2001;**46**(3):685-687
- [73] Goff ML, Win BH. Estimation of postmortem interval based on colony development time for *Anoplolepis longipes* (*Hymenoptera: Formicidae*). *Journal of Forensic Sciences*. 1997;**42**:1176-1179
- [74] Ropohl D, Scheithauer R, Pollak S. Postmortem injuries inflicted by domestic golden hamster: Morphological aspects and evidence by DNA typing. *Forensic Science International*. 1995;**72**:81-90
- [75] Erkol Z, Cantürk N. The problem of elderly people who live alone: An elderly neglect case. *Turkish Journal of Geriatrics*. 2014;**17**(1):99-102
- [76] Komar D, Beattie O. Identifying bird scavenging in fleshed and dry remains. *Canadian Society of Forensic Science Journal*. 1998;**31**(3):177-188
- [77] O'Brien RC, Forbes SL, Meyer J, Dadour IR. A preliminary investigation into the scavenging activity on pig carcasses in Western Australia. *Forensic Science, Medicine, and Pathology*. 2007;**3**:194-199
- [78] Dettling A, Strohbeck-Kuhner P, Schmitt G, Haffner HT. Animal bites caused by a song bird. *Archiv für Kriminologie*. 2001;**208**:48-53
- [79] Hayase T, Yamamoto K, Yamamoto Y, Nishitani Y, Abiru H, Fukui Y. Analysis of postmortem injuries inflicted by animals and the environment. *Acta Crim Japon*. 1999;**65**:226-234
- [80] Reeves NM. Taphonomic effects of vulture scavenging. *Journal of Forensic Sciences*. 2009;**54**(3):523-528
- [81] De Munnynck K, Van de Voorde W. Forensic approach of fatal dog attacks: A case report and literature review. *International Journal of Legal Medicine*. 2002;**116**:295-300
- [82] Gidna A, Yravedra J, Dominguez-Rodrigo M. A cautionary note on the use of captive carnivores to model wild predator behavior: A comparison of bone modification patterns on long bones by captive and wild lions. *Journal of Archaeological Science*. 2013;**40**:1903-1910
- [83] Young A, Marquez-Grant N, Stillman R, Smith MJ, Korstjens AH. An investigation of red fox (*Vulpes vulpes*) and Eurasian badger (*Meles meles*) scavenging, scattering and removal of deer remains: Forensic implications and applications. *Journal of Forensic Sciences*. 2015;**60**:39-55
- [84] Murmann DC, Brumit PC, Schrader BA, Senn DR. A comparison of animal jaws and bite mark patterns. *Journal of Forensic Sciences*. 2006;**51**(4):846-860
- [85] Cohle SD, Harlan CW, Harlan G. Fatal big cat attacks. *The American Journal of Forensic Medicine and Pathology*. 1990;**11**:208-212
- [86] Dominguez-Rodrigo M, Piqueras A. The use of tooth pits to identify carnivore taxa in tooth-marked archaeofaunas and their relevance to reconstruct hominid carcass processing behaviours. *Journal of Archaeological Science*. 2003;**30**:1385-1391

- [87] Sacks JJ, Sinclair L, Gilchrist J, Golab GC, Lockwood R. Breeds of dogs involved in fatal human attacks in the United States between 1979 and 1998. *Journal of the American Veterinary Medical Association*. 2000;**217**(6):836-840
- [88] Pomara C, D'Errico S, Jarussi V, Turillazzi E, Fineschi V. Cave canem: Bite mark analysis in a fatal dog pack attack. *The American Journal of Forensic Medicine and Pathology*. 2011;**32**(1):50-54
- [89] Dahlgren TG, Wiklund H, Kallström B, Lundalv T, Smith CR, Glover AG. A shallow-water whale-fall experiment in the north Atlantic. *Cah Biol. Mar*. 2006;**47**:385-389
- [90] Byard RW, Gilbert JD, Brown K. Pathological features of fatal shark attacks. *The American Journal of Forensic Medicine and Pathology*. 2000;**21**:225-226
- [91] Hayashi T, Higo E, Orito H, Ago K, Ogata M. Postmortem wounds caused by cookie-cutter sharks (*Isistius* species): An autopsy case of a drowning victim. *Forensic Science, Medicine, and Pathology*. 2015;**11**(1):119-121
- [92] Makino Y, Tachihara K, Ageda S, Arao T, Fuke C, Miyazaki T. Peculiar circular and C-shaped injuries on a body from the sea. *The American Journal of Forensic Medicine and Pathology*. 2004;**25**:169-171
- [93] Sazima I, de Andrade Guimarães S. Scavenging on human corpses as a source for stories about man-eating piranhas. *Environmental Biology of Fishes*. 1987;**20**(1):75-77
- [94] Harding BE, Wolf BC. Alligator attacks in southwest Florida. *Journal of Forensic Sciences*. 2006;**51**(3):674-677
- [95] Gruen RL. Crocodile attacks in Australia: Challenges for injury prevention and trauma care. *World Journal of Surgery*. 2009;**33**(8):1554-1561
- [96] Sinton TJ, Byard RW. Pathological features of fatal crocodile attacks in northern Australia, 2005-2014. *Journal of Forensic Sciences*. 2016;**61**(6):1553-1555