
Class III High Angle Malocclusion Treated with Orthodontic Camouflage (MEAW Therapy)

Paulo Beltrão

Additional information is available at the end of the chapter

<http://dx.doi.org/10.5772/59511>

1. Introduction

The prevalence of skeletal class III malocclusion varies among races. In the white population, the incidence is 1% to 5% and in the Asian population it is up to 14% [1]. This type of malocclusion is considered to be one of the most difficult orthodontic cases to treat. The usual treatment for this type of malocclusion is the use of a face mask (maxillary protraction), chin cap appliance and orthognatic surgery. Severe cases require orthognatic surgery to correct skeletal and dental discrepancies to attain a pleasant profile. In borderline cases, the camouflage treatment is possible to improve facial esthetic and functional concerns of the patient. An effective camouflage treatment of skeletal class III malocclusion is achieved with the use of multiloop edgewise arch wire (MEAW) technique. The MEAW along with short class III elastics should: upright posterior lower teeth, move the lower dentition distally; reconstruct the occlusal plane ; coordinate both arches and decrease the class III discrepancy. The use of long class III elastics is not recommended in order to avoid further proclination of upper anterior teeth and extrusion of upper molars with the undesirable outcome of clockwise mandibular rotation and increase of anterior openbite.

The MEAW (multiloop edgewise arch wire) was created by Dr. Young H. Kim (1967) to treat open bite malocclusions and was further developed by Professor Sadao Sato (Kanagawa Dental College – Japan)

The Skeletal class III malocclusion can be due to mandibular overdevelopment, underdeveloped maxillary, or a combination of both.

The general characteristics of skeletal class III openbite are : a) narrow "cranial angle", b) anteroposterior shortening of maxilla, c) hyperdivergent skeletal pattern (openbite), d)

posterior discrepancy, e) flaring out of upper anterior teeth, f) incline to lingual in lower incisors, g) prognathic mandible, and h) flat occlusal plane.

The patient with class III high angle malocclusion usually has a maxillary increased vertical growth and a poor anteroposterior growth and the result of this is posterior crowding. This produces a “squeezing out effect”, causing a molar over eruption which flattens the upper posterior occlusal plane. The flattening of the occlusal plane is followed by forward adaptation of the mandible, resulting in protrusive displacement.

The objective of the orthodontic treatment is first to eliminate the posterior crowding (extraction of wisdom teeth) and then reconstruct the occlusal plane (steepen occlusal plane) and decrease the vertical dimension. The MEAW technique along with short class III elastics provides an appropriate treatment strategy for patients with class III high angle and openbite malocclusion. The tooth alignment with corrected plane inclination can lead to a physiological mandibular position, which is the key to attain a stable occlusion.

2. The Multiloop Edgewise Arch Wire (MEAW)

The MEAW was developed in 1967 by Young H. Kim to treat openbite malocclusion and proved to be extremely effective.

Studies and further research particularly by Prof. Sadao Sato [2] (Kanagawa Dental College – Japan), have enabled the use of the MEAW technique to treat any type of malocclusion.

MEAWs are constructed with .016 x .022 stainless steel (bracket 0.018 – inch slot) or .017 x .025 ss (bracket 0.022 – inch slot).

The arches have ideal arch form with five loops on each side of the arch (figure 1).

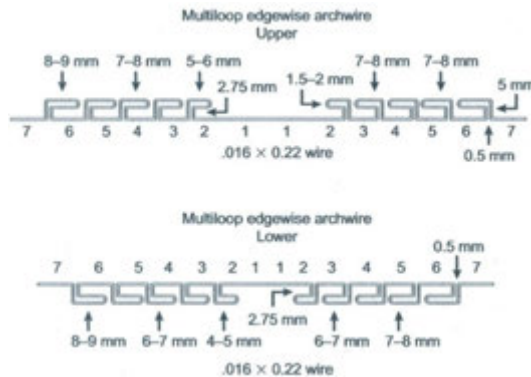


Figure 1. Upper and lower multiloop edgewise arch wires (MEAWs)

The loops between the teeth reduce the load deflection rate (LDR) of the wire significantly, providing a small but continuous orthodontic force on the teeth, and allow individual control

of teeth in the three directions of the space. With the aid of intraoral elastics, MEAW can reconstruct the occlusal plane.

The tip back activation in the posterior segment of the wire produces uprighting of the posterior teeth. The use of vertical short class III elastics is necessary to produce the desired vertical and distal movement of the tooth segment in order to rebuild the occlusal plane and the sagittal relationship of the dentition.

An experimental study by Lee and co-workers (1995) from Seoul National University using the MEAW on Rhesus monkeys showed that marked tooth movement occurred along with considerable bone remodeling cellular activity whereas a control monkey with a standard ideal arch wire of the same size showed insignificant cellular activity with signs of root resorption.

3. Cephalometric analysis

Kim's Method Analysis

The cephalometric diagnosis developed by Kim places special emphasis on determining patterns of vertical and sagittal growth and its close relation with the occlusal plane [3-5].

- ODI (overbite depth indicator)
- APDI (anteroposterior dysplasia indicator)
- CF (combination factor)

3.1. ODI – Overbite Depth Indicator

The ODI is a combined measurement of two angles: the A-B plane to the mandibular plane (MP) and the palatal plane to the Frankfort horizontal (FH) plane. When the palatal plane slopes upward and forward in relation to the FH plane, it is read as a negative angle and this value is subtracted from the A-B to the mandibular plane angle.

There is a norm of 74.5° with a standard deviation of 6.07. A value of 68° or less indicates a skeletal openbite tendency.

3.2. APDI – Anteroposterior Dysplasia Index

The APDI is determined from three angles: the facial plane angle (HF/FP (Na-Pog)), plus or minus the A-B plane angle (Downs), and plus or minus the palatal plane angle in relation to the FH plane, which is geometrically equivalent to the PP-AB.

PP-AB is apparently the anteroposterior relationship of the maxillary and mandible.

The normal mean of the APDI is 81.4°. The smaller the APDI value becomes in relation to the normal mean (81.4°), the greater the probability that a distocclusion exists. On the contrary, as the APDI value increases above the normal mean, the greater the probability that a mesioc-

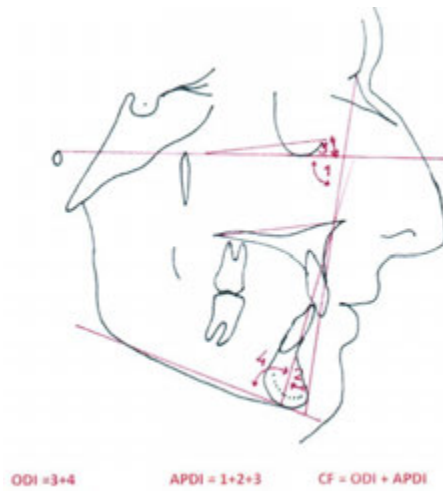


Figure 2. Kim analysis

clusion is present. The APDI is a measure of skeletal class II or III tendency and reflects the horizontal discrepancies of a malocclusion.

3.3. Combination factor

The combination factor (CF) is a combination of ODI and APDI.

A high CF (>155) indicates a tendency for low angle and a skeletal pattern that has the potential to accommodate all the teeth. A high CF of 165 indicates good skeletal volume that will allow movement of the dentition.

A low CF (<155) shows the tendency for high angle, and the need for tooth extraction is higher.

The CF indicates if a patient has the potential to be treated, with an extraction or non-extraction protocol.

4. The dynamic mechanism of the skeleton and the development process of skeletal class III high angle

The craniofacial bones are joined together by sutures or synchondrosis. These sutures allow slight relative movements.

The sphenoid is the main central bone of the cranial base and makes the synchondrosis ethmosphenoidal with the ethmoid (fuses at 7-8 years) and synchondrosis spheno occipital (fuses in late puberty at 18-20 years) with the occipital.

According to Hooper (1986) the sphenobasilar articulation is the most important among the cranial bones, and this is where the movement of flexion-extension occurs.

The degree of basicranial flexion differs in the various types of malocclusion. The cranial base angles (Na-S-Ar) come to approximately 124.2 ± 5.2 in class I patterns.

From this average value, a more obtuse (extension) angle indicates skeletal Class II and a more acute (flexion) angle means skeletal class III (figures 3 and 4).

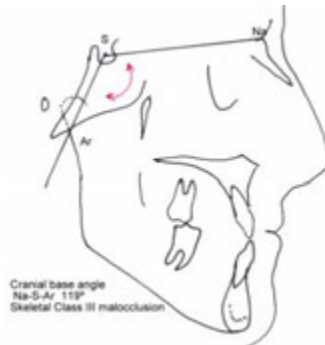

Figure 3. Cranial base angle-skeletal class III

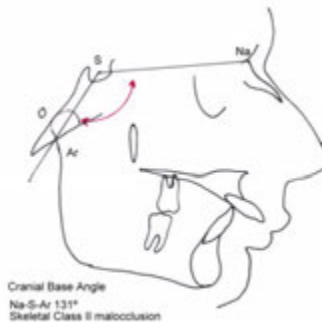


Figure 4. Cranial base angle-skeletal class II

The rotating movement of the cranial base (flexion/extension) occurs at the sphenoccipital articulation, and it is transmitted to the maxilla through the vomer. This dynamic mechanism has a great influence on the growth pattern of an individual.

When the sphenoid makes flexion, the rotating force of the vomer is posteroinferior and the maxilla is pushed inferiorly. This causes vertical elongation of the maxillary complex, short sagittal dimension and posterior crowding. The posterior crowding produces the “push out effect”, an over eruption of the molars that induces a flattening of the occlusal plane, which is

followed by anterior mandibular adaptation. This is related to the development of a class III skeletal frame [6,7].

The consequences of an increased maxillary vertical height are:

- increased height of bite
- interferences in the molar area
- flat posterior occlusal plane

The inclination of the upper occlusal plane is determined by growth and rotation of the sphenoid and maxillary bone, vertical growth of the maxillary alveolar bone and posterior discrepancy.

When the increase in vertical dimension is lesser than the growth of the mandibular ramus, this results in anterior rotation of the mandible (class III low angle malocclusion). When the increase of the vertical dimension is higher than the growth of condyle, the result is backward rotation of the mandible and anterior openbite (Petrovic 1975). According to the cybernetic model of Petrovic, the maxillary growth functionally “shifts” the mandible and the TMJ (temporomandibular joint) adapts to the new position by secondary growth of the condyles.

According to Sadao Sato, in the pubertal and postpubertal period the most important factor that influences the skeletal craniofacial growth is the occlusal function rather than heredity. Sato considers different occlusal planes – the conventional occlusal plane, the anterior and the posterior occlusal plane (Figure 5). The most important is the posterior occlusal plane, which is closely related with the mandibular position. A steep occlusal plane (post) determines a retrognathic mandible and a class II malocclusion. A flat occlusal plane (post) determines a forward mandibular shift, a prognathic mandible and a class III malocclusion [8-11].

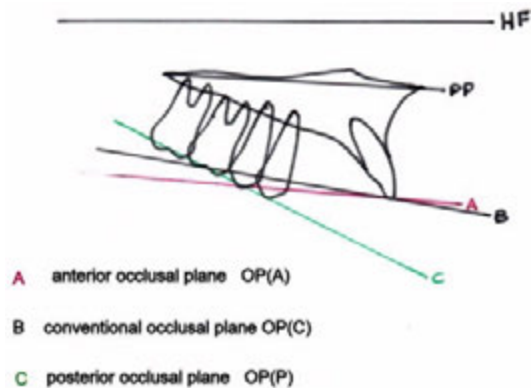


Figure 5. Different occlusal planes

Tanaka and Sato in a study (AJODO 2008) [12] comparing the occlusal plane of class II and class III malocclusion and class I occlusion group (adult age) obtained the following results:

- Group class I – FH-OP (posterior) was 11.3° (average)
- Group class II – FH-OP (posterior) was 13.8° (average)
- Group class III – FH-OP (posterior) was 8.7° (average)

It is very important during the treatment of class III the reconstruction of the occlusal plane (steepen the occlusal plane), to induce posterior mandibular displacement and TMJ remodeling.

5. Class III high angle malocclusion characteristics

- High vertical dimension
- The posterior occlusal plane is flat
- Short maxillary sagittal length
- The FH-MP angle is open
- Narrow cranial angle (flexion of the cranial base)
- The skeletal frame is class III (APDI more than 85)
- Mandibular anterior displacement
- Generally the wisdom teeth are present with posterior discrepancy
- Generally upper anterior teeth are crowded with open bite
- Lingual tipping of the lower incisors (due to dento-alveolar compensation)
- The ODI (overbite depth indicator) is significantly low (less than 74.5)

The skeletal features of the class III malocclusion are closely related to the deviation in the vertical aspect of the occlusion.

6. Treatment of class III High angle based on the dynamics of the craniofacial skeleton

In the 1970s, several studies (Petrovic, Carlson, McNamara, Woodside) [13,14] showed the possibility of modifying the mandibular growth pattern if it was related with its function – McNamara, Graber, Harvold, Bass (1970s) showed that the amount of mandibular growth changes due to cell proliferation in the condyles was related to occlusal function changes.

Fushima et al. (1989) [15] measured the vertical height of posterior teeth in subjects with mandibular asymmetry. They found that the vertical height of posterior teeth on the side toward which the mandible had shifted was lower than the contralateral dental height.

The MEAW philosophy created by Dr. Young Kim and developed by Dr. Sadao Sato considers that the treatment of high angle class III malocclusion must prevent occlusal interferences, intrude upper molars to decrease the vertical dimension and steepen the occlusal plane. Once the vertical dimension changes, the mandible adapts through functional displacement.

The treatment objectives for class III openbite are:

- decrease vertical dimension
- rebuild and steepen the upper posterior occlusal plane
- Coordinate the upper and lower dental arch width
- Reposition the mandible backward in a physiological position
- Improve overbite (openbite) and obtain an appropriate occlusal anterior guidance
- Obtain normal intercuspitation and pleasant profile

The treatment steps of class III openbite are:

1 – leveling, 2 – elimination of occlusal interferences, 3 – establishing mandibular position, 4 – reconstruction of the occlusal plane, 5 – achieving a physiological occlusion.

6.1 – Leveling – leveling starts with superelastic wires or 0.016 ss adapted to the malocclusion.

6.2 – Elimination of occlusal interferences – 0.016"×0.022" or 0.017"×0.025" MEAW with progressive tipback of 5° from premolars to the molar area along with short class III elastics (3/16, 6 oz) (Figure 6A)

6.3 Establishing mandibular position (Figure 6B) – During this stage, the tip back bends in the molar area are increased, removed in the premolar area and step up bends are done in the premolar area. This is necessary to attain a stable mandibular position.

6.4 Occlusal plane reconstruction (Figure 6C and 6D) – During this stage, the tip back bends are removed and step up bends in the lower molar area are added to steepen the occlusal plane.

6.5 Achieving a physiological occlusion (Figure 6E) – During this stage, a good intercuspitation is obtained.

6.1. Case report 1

The patient had already consulted an orthodontist, who proposed her orthognathic surgery to correct the malocclusion, which she refused. Due to this, I proposed her a treatment with MEAW therapy. It was explained that the MEAW treatment does not replaces surgery but could be an alternative in case of refusal to do surgery.

Patient female 14 years old and 7 months of age, with severe skeletal class III and dental class III on a hyperdivergent face pattern, mandibular prognathism, anterior open bite (5mm), overjet (-3mm), flat occlusal plane in the molar area producing interference in the posterior area, posterior crowding. The Kim analysis shows an ODI of 49°, which indicates a severe




Figure 6. (A-E) different steps during the treatment

skeletal open bite, APDI of 90°, which indicates a skeletal class III high angle, and a CF of 139, which indicates the need to extract teeth. The posterior crowding was solved by extraction of third lower molars, upper left second molar and upper right first molar (due to a problem of dental decay) prior to the onset of the treatment. The upper molars were extracted because the third molars were too high in the tuberosity. Before the decision to extract the upper molars, the third molars were radiographically evaluated to check if they had correct size and shape as well as appropriate position and inclination to erupt properly, replacing the extracted molars.

The patient began the treatment when she was 14 years and 7 months, and the treatment lasted 22 months. The type of appliance was an edgewise multibracket 0,022 x 0,028 slot, 0° torque, 0° angulation, and MEAW arch wires along with short class III elastics (3/16, 6 oz).

The treatment objective for this patient with class III open bite was the elimination of the posterior crowding, to intrude and tip the molars, to move distally the lower teeth, to extrude the lower and upper incisors (to close the open bite), steepen the occlusal plane to produce posterior adaptation of the mandible and secondarily to induce condylar remodeling. The retention phase was done with maxillary Hawley plate for night time use (6 months) and bonded lingual wire from 43 to 33.

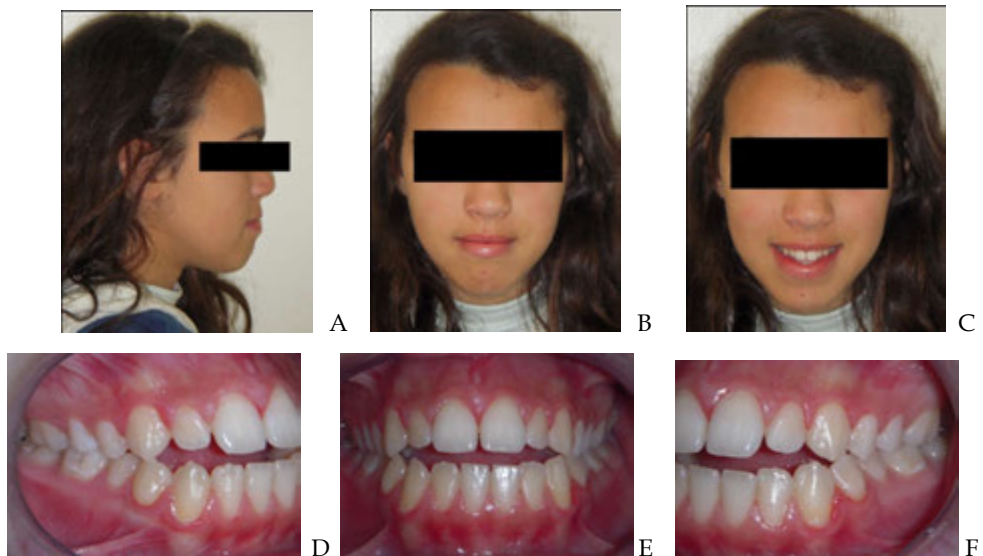


Figure 5- Pretreatment extraoral (a,b,c) and intraoral (d,e,f) photographs

Figure 7. Pretreatment extraoral (A-C) and intraoral (D-F) photographs

| | range | beginning | end of treatment | End of retention |
|--|-----------|-----------|------------------|------------------|
| FMA | 67°+ - 3 | 67 | 75 | 75 |
| The steps of the treatment: | | | | |
| FMA | 25°+ - 3 | 31 | 29 | 29 |
| Step one - Leveling (alignment) started with 0.016 stainless archwires. | 88°+ - 2 | 82 | 76 | 76 |
| Step two - Elimination of occlusal interferences - use of 0.017x0.025 multiloop edgewise arch wires (MEAWs) in both arches, use of short class III, 3/16 inch, 6 oz elastics on both sides. | 82°+ - 2 | 82 | 82 | 82 |
| Step three - Establishing mandibular position, distal construction of the occlusal plane, achieving a physiological occlusion. | 80°+ - 2 | 84 | 82 | 82 |
| Step four - Elimination of occlusal interferences - use of 0.017x0.025 multiloop edgewise arch wires (MEAWs) in both arches, use of short class III, 3/16 inch, 6 oz elastics on both sides. | 82°+ - 2 | 84 | 82 | 82 |
| Step five - Retention phase with maxillary Hawley plate for night time use (6 months) and bonded lingual wire from 43 to 33. | 82°+ - 2 | 84 | 82 | 82 |
| SNB | 80°+ - 2 | 84 | 82 | 82 |
| ANB | 2°+ - 2 | -2 | 0 | 0 |
| Step one - Leveling (alignment) started with 0.016 stainless archwires. | | | | |
| Step two - Elimination of occlusal interferences - use of 0.017x0.025 multiloop edgewise arch wires (MEAWs) in both arches, use of short class III, 3/16 inch, 6 oz elastics on both sides. | | | | |
| Go-Bo | 2mm | -5mm | 3mm | -3mm |
| OP | 10° - 14° | 0 | +3 | +2 |
| Z | 75°+ - 5 | 75 | 77 | 80 |
| PFH | 45mm | 45 | 49 | 49 |
| AFH | 65mm | 77 | 80 | 80 |
| INDEX | 0,69 | 0,59 | 0,62 | 0,62 |

Table- Cephalometric analysis (Tweed- Merrifield)(16-18)

| | Range | Beginning | End of treatment | End of retention |
|-------|---------|-----------|------------------|------------------|
| FMIA | 67°± 3 | 67 | 75 | 75 |
| FMA | 25°± 3 | 31 | 29 | 29 |
| IMPA | 88°± 3 | 82 | 76 | 76 |
| SNA | 82°± 2 | 82 | 82 | 82 |
| SNB | 80°± 2 | 84 | 82 | 82 |
| ANB | 2°± 2 | -2 | 0 | 0 |
| Ao-Bo | 2mm | -5mm | - 3mm | - 3mm |
| OP | 10°-14° | 0 | +3 | +2 |
| Z | 75°±5 | 75 | 77 | 80 |
| PFH | 45mm | 45 | 49 | 49 |
| AFH | 65mm | 77 | 80 | 80 |
| INDEX | 0,69 | 0,59 | 0,62 | 0,62 |

Table 1. Cephalometric analysis (Tweed-Merrifield) [16-18]

| | Beginning | End of treatment | End of retention |
|------|-----------|------------------|------------------|
| ODI | MP/AB 55 | 59 | 59 |
| | FH/PP -6 | -8 | -8 |
| APDI | HF/FP 95 | 93 | 93 |
| | FP/AB +1 | 0 | 0 |
| | HF/PP -6 | -8 | -8 |
| CF | ODI+APDI | 136 | 136 |

Table 2. Cephalometric analysis (Kim)

Step three – Establishing mandibular position: tip back bends (3 to 5°) were done in both arches (use of short class III, 3/16 inch, 6 oz elastics). At the end of this phase, the occlusion was in molar class one.

Steps four/five – Reconstruction of the occlusal plane and achieving a physiological occlusion: steepen the occlusal plane in the molar area – “artistic bends” in the anterior upper area.

The retention phase was done with maxillary Hawley plate for night time use (12 months) and bonded lingual wire from 33 to 43.

The posttreatment results show a better balanced face, better profile and an improved smile, a correct overbite and overjet.

| The intra-oral photos show a normal class I relationship, a correct overbite and overjet. The | Beginning | End of treatment | End of retention |
|---|-----------|------------------|------------------|
| Cephalometric analysis shows a reduction of the negative ANB angle of 2° from -2° to 0°), 51 | MB/AB 55 | 49 | 51 |
| mandibular distal displacement (point B moved back 2°). | PH/PP -6 | -3 | -8 |
| APDI | HF/FP 95 | 90 | 93 |
| | FP/AB +1 | 0 | 0 |
| | HF/PP -6 | -8 | -8 |
| CF | ODI+APDI | 139 | 136 |
| | | | 136 |

Table 2 - Cephalometric analysis (Kim)

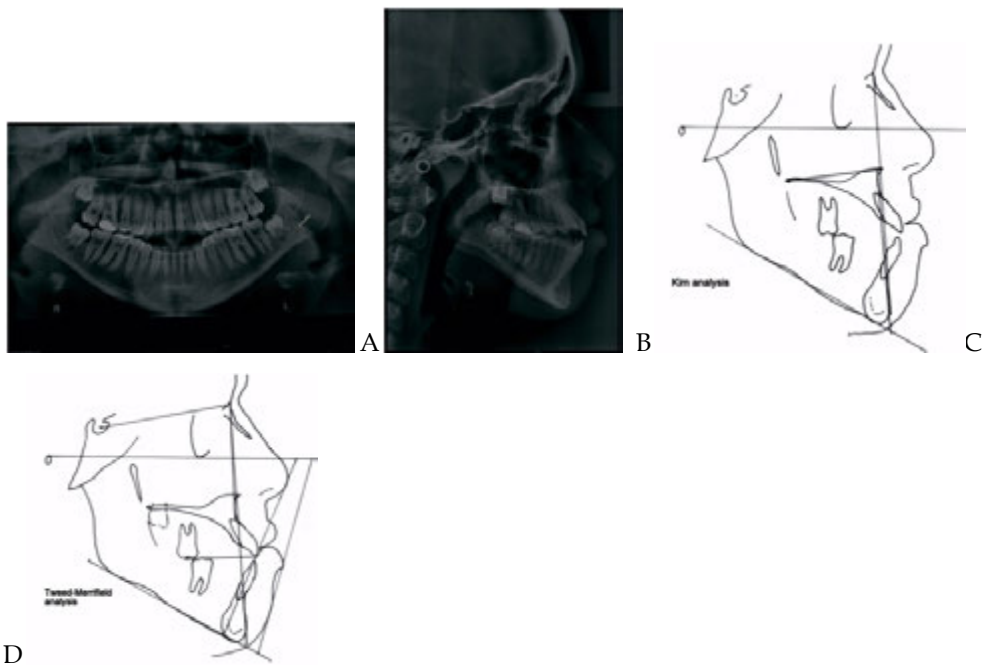


Figure 8 - Pretreatment records (A-D)

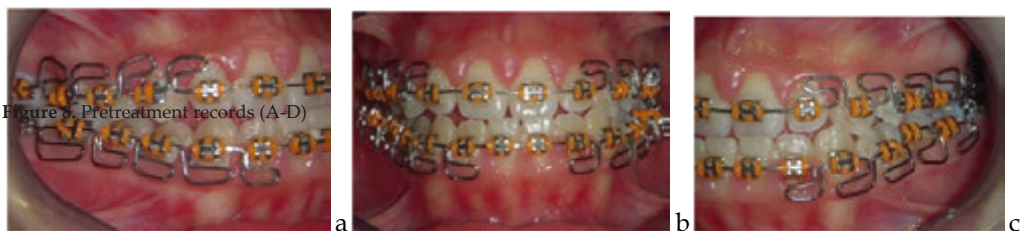

Figure 9. Pretreatment records (A-D)

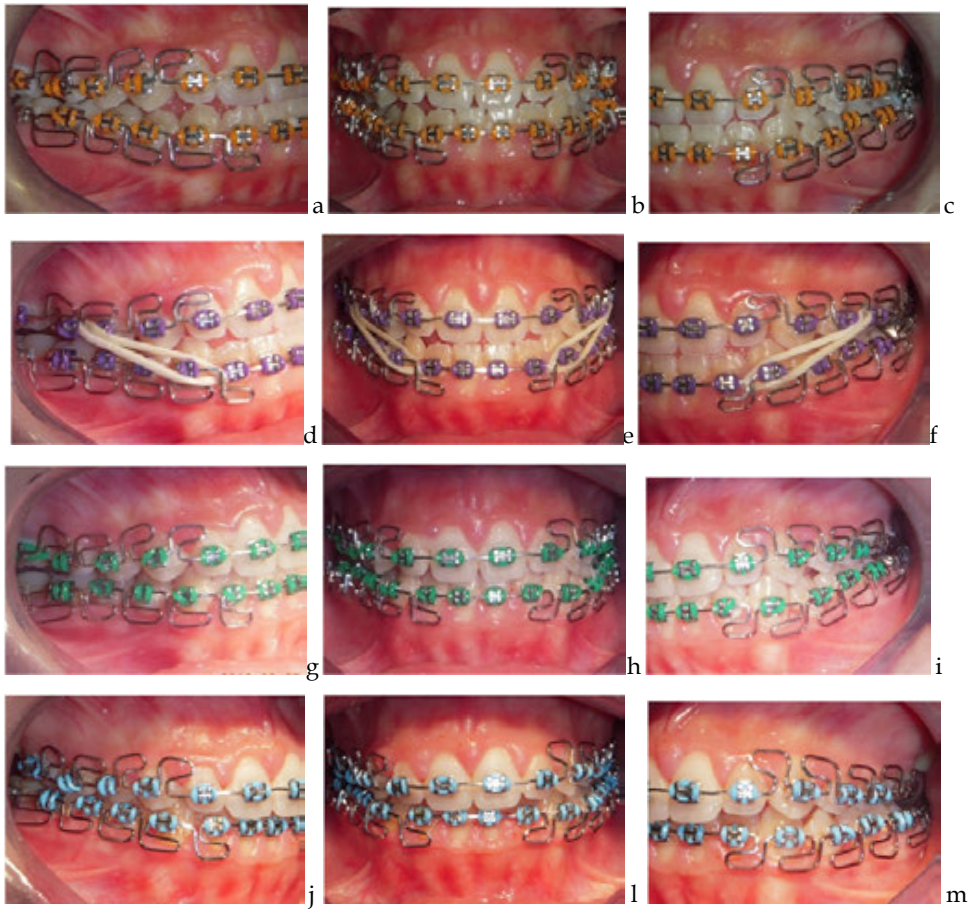

Figure 9 - Photos during the treatment (a-m)

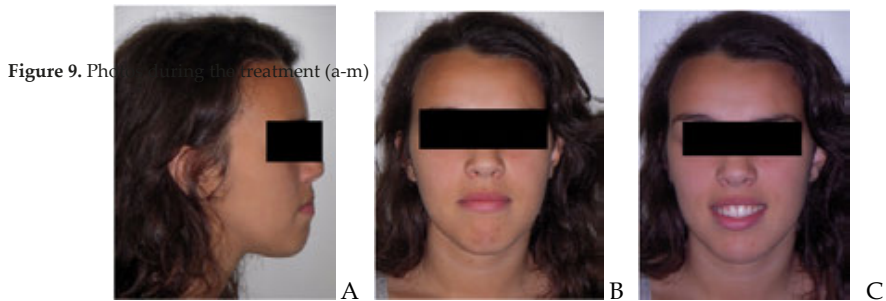


Figure 9. Photos during the treatment (a-m)

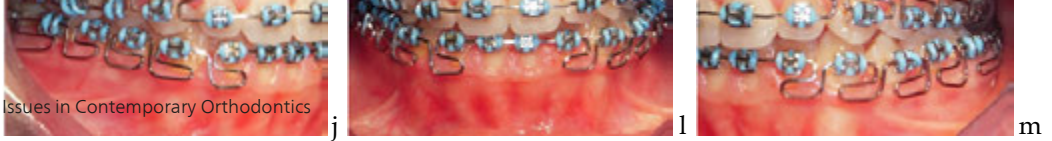

Figure 9 - Photos during the treatment (a-m)

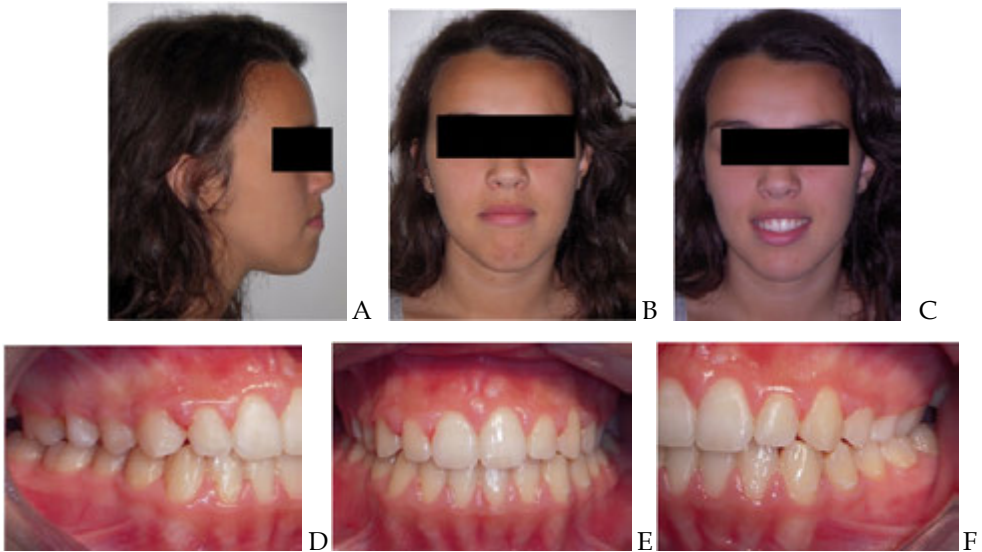

Figure 10. Posttreatment extraoral (A-C) and intraoral (D-F) photos

Figure 10 - Posttreatment extraoral (A-C) and intraoral (D-F) photos

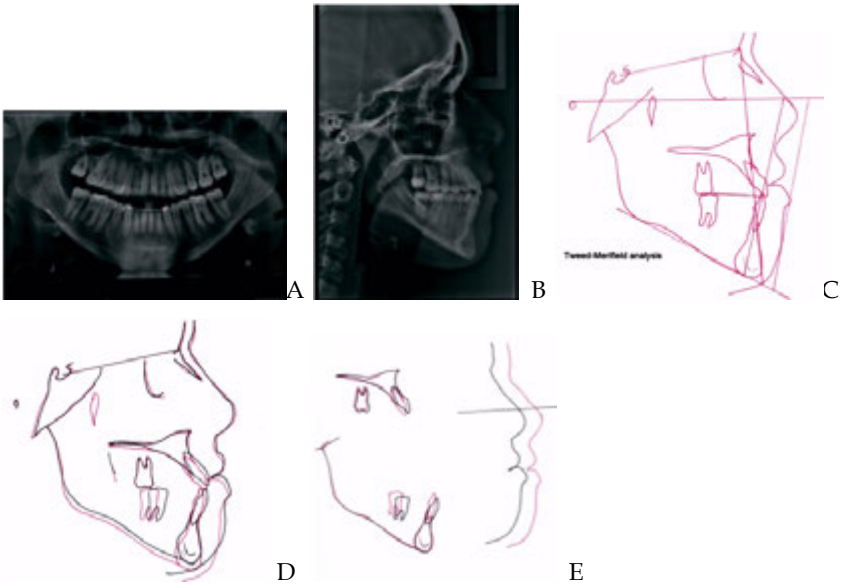
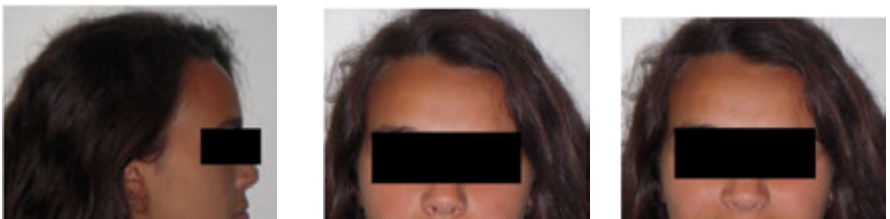

Figure 11. Posttreatment records (A-C), superimpositions (D-E)



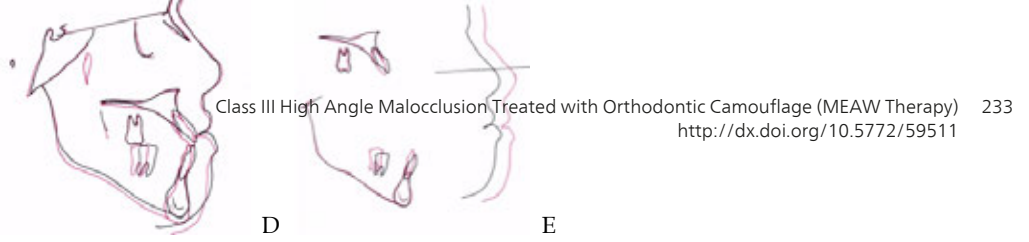


Figure 11 - Posttreatment records (A-C), superimpositions (D-E)

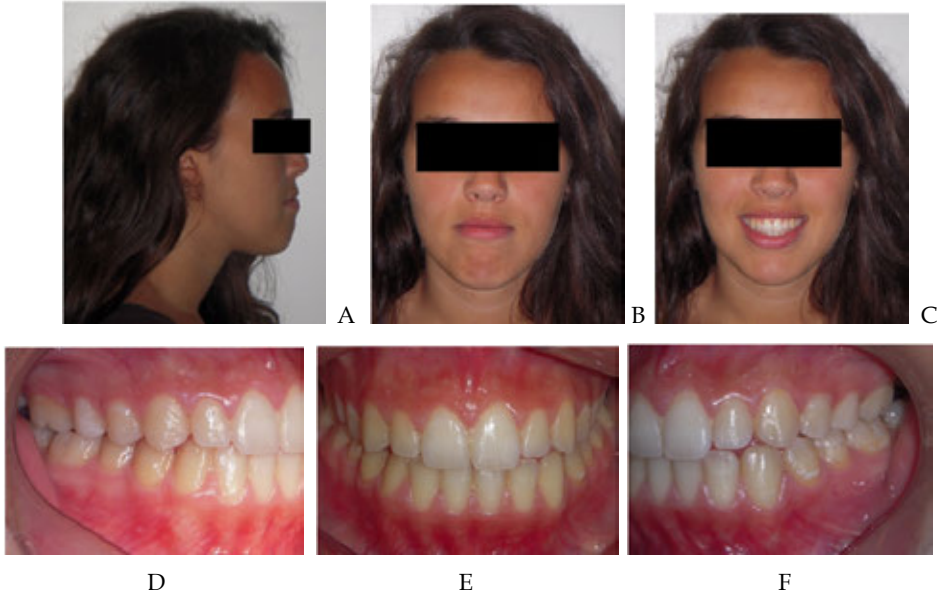

Figure 12 - Postretention extraoral photos (A-B-C) and intraoral photos (D-E-F)
 Figure 12. Postretention extraoral photos (A-B-C) and intraoral photos (D-E-F)

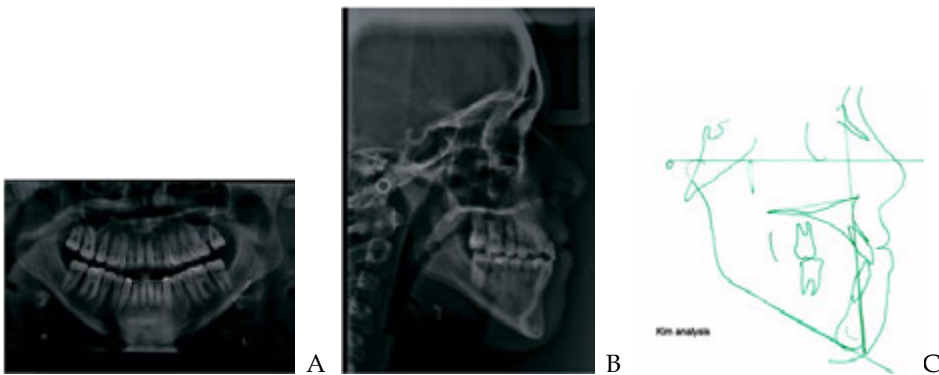
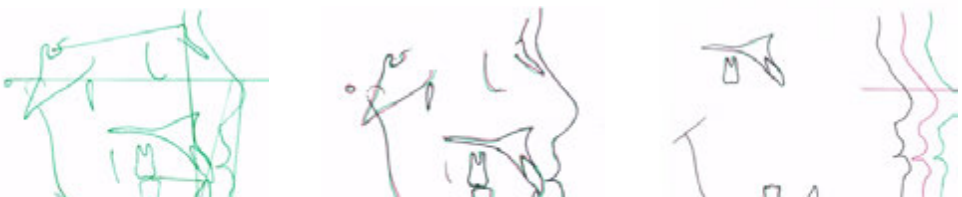

Figure 13 - Postretention records (A - C)
 Figure 13. Postretention records (A - C)





extracted at the end of treatment. The absence of 38 and 48 in the lower arch avoided the need to extract.

Treatment analysis

Treatment began with age (16/2); after 2 months of leveling, the use of MEAW and short class III elastics (3/16 inch, 6 oz) started.

Figure 14 - Superimpositions (A - C)
 Figure 14. Superimpositions (A - C) of the treatment was 13 months. The retention phase was done with maxillary Hawley plate for night time use (6 months) and bonded lingual wire from 43 to 33. At the

6.2. Case report 2

Patient female (16 years old/2 months), anterior facial height increased with skeletal class III and deep bite. Superimposition shows steeper pattern, posterior occlusal plane and with open bite from 10° to 26° mandible (long sagittal) (SNB 88°), overbite (2mm) increased (2mm), flat occlusal plane in the molar area producing interference in the posterior area. III molar dental class II skeletal pattern (MVB, dipping from 25 to 0°). At the

The z angle of 90° confirms an unbalanced face which is based on a prognathic chin from 15 to 26, mandibular prognathism (SNB 88°), open bite (8mm), overjet (-2mm), flat occlusal plane in the molar area producing interference in the posterior area.

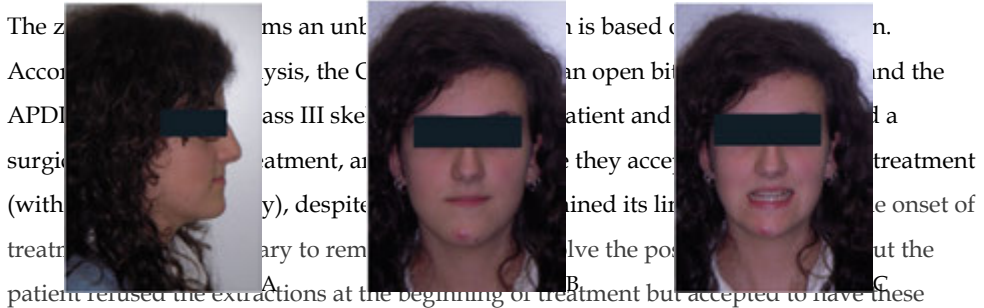

Figure 15 - Pretreatment extraoral (A-B-C) and intraoral (D-E-F) photos
 Figure 15. Pretreatment extraoral (A-B-C) and intraoral (D-E-F) photos

According to Kim's analysis, the ODI (63°) indicates an open bite skeletal pattern and the APDI (93°) indicates a class III skeletal pattern. The patient and her mother refused a surgical/orthodontic treatment, and as an alternative they accepted a camouflage treatment (with MEAW philosophy), despite having been explained its limitations. Before the onset of

treatment, it was necessary to remove 18 and 28 to solve the posterior crowding, but the patient refused the extractions at the beginning of treatment but accepted to have these extracted at the end of treatment. The absence of 38 and 48 in the lower arch avoided the need to extract.

Treatment began with age [16/2]; after 2 months of leveling, the use of MEAW and short class III elastics (3/16 inch, 6 oz) started.

The duration of the treatment was 13 months. The retention phase was done with maxillary Hawley plate for night time use (6 months) and bonded lingual wire from 43 to 33. At the end of treatment, the photographs (Figure 18) illustrate a better balanced face, a better profile and a pleasant smile, a good class I relationship, correct overbite and overjet.

The general superimposition shows steeper upper posterior occlusal plane and simultaneous a distal repositioning of the mandible (SNB changed from 88° to 86° - point b moved back 2°). The skeletal class III was improved (ANB changed from -3° to 0°). At the last control visit, the patient was sent to her dentist to extract 18 and 28.

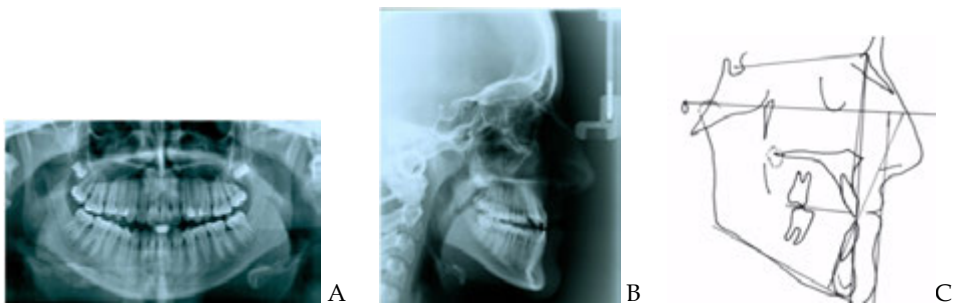


Figure 16 - Pretreatment records (A-C)
 Figure 16. Pretreatment records (A-C)

| | Range | Beginning | End of treatment | End of retention |
|-------|---------|-----------|------------------|------------------|
| FMIA | 67°+ 2 | 70 | 73 | 73 |
| FMA | 25°+ 3 | 29 | 29 | 29 |
| IMPA | 88°+ 3 | 81 | 78 | 78 |
| SNA | 82°+ 2 | 85 | 86 | 86 |
| SNB | 80°+ 2 | 88 | 86 | 86 |
| ANB | 2°+ 2 | -3 | 0 | 0 |
| A6-Bo | 2mm | -4mm | -3mm | -3mm |
| OP | 10°-14° | 1 | 7 | 7 |

| | | |
|--|--|--|
| | | |
|--|--|--|

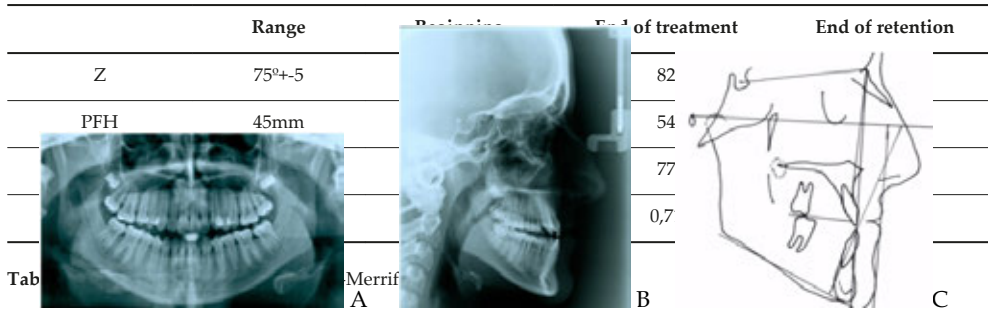


Figure 16 - Pretreatment records (A-C)

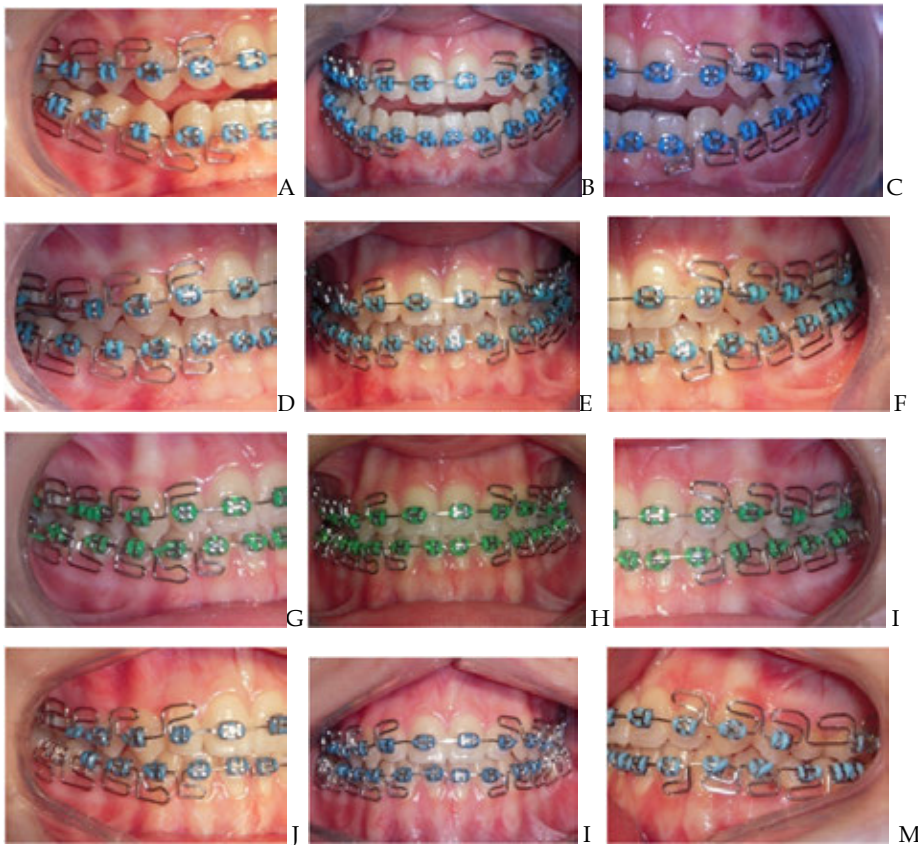

Figure 17 - Photos during the treatment. (A-C) after two months of treatment MEAW was inserted. (D-F) four months of treatment (two months with MEAW upper and lower) and short class III elastics (6 oz, 3/16 inch). (G-I) 10 months of treatment (4 months of treatment with MEAW and 6 months of treatment with short class III elastics (6 oz, 3/16 inch)). (J-M) 12 months of treatment

| | Beginning | | End of treatment | | End of retention | |
|------|-----------|-----|------------------|-----|------------------|-----|
| ODI | MP/AB 63 | 63 | 63 | 63 | 63 | 63 |
| | FH/PP 0 | | 0 | | 0 | |
| APDI | HF/FP 91 | 93 | 89 | 89 | 89 | 89 |
| | FP/AB +2 | | 0 | | 0 | |
| | HF/PP 0 | | 0 | | 0 | |
| CF | ODI+APDI | 156 | | 152 | | 152 |

Table 4. Cephalometric analysis (Kim)

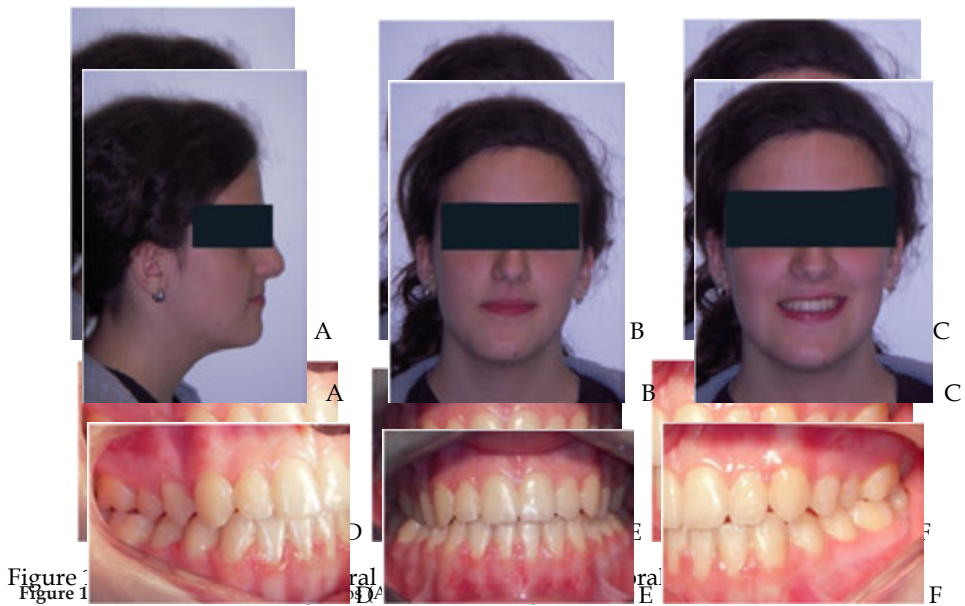


Figure 18 - Posttreatment extraoral photos (A-C) and intraoral photos (D-F)

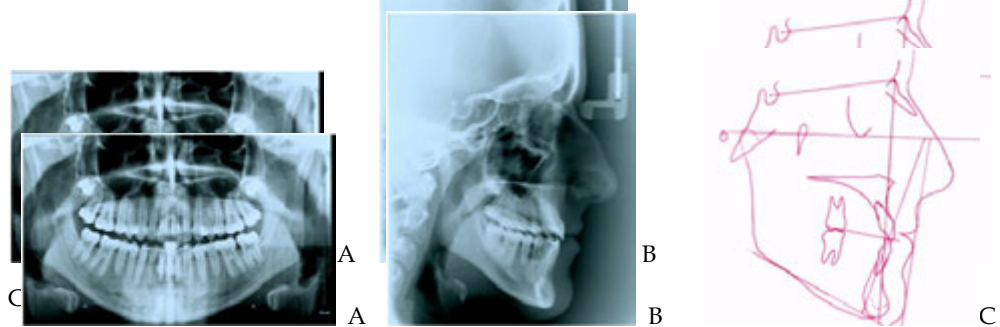


Figure 19 - Posttreatment records
 Figure 19 - Posttreatment records
 Figure 19. Posttreatment records



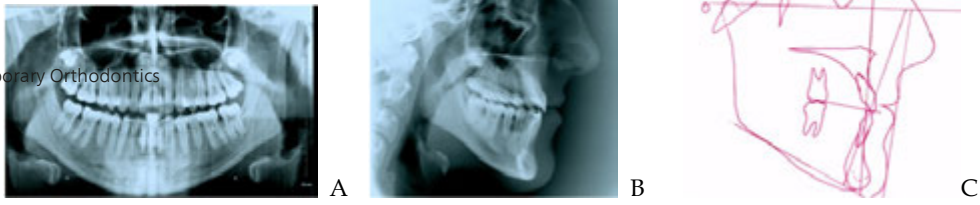

Figure 19 - Posttreatment records

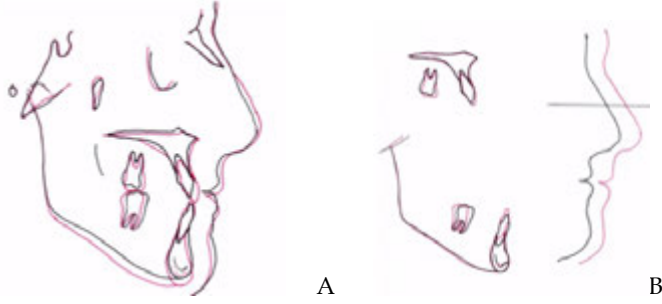


Figure 20 - superimpositions

Figure 20. Superimpositions

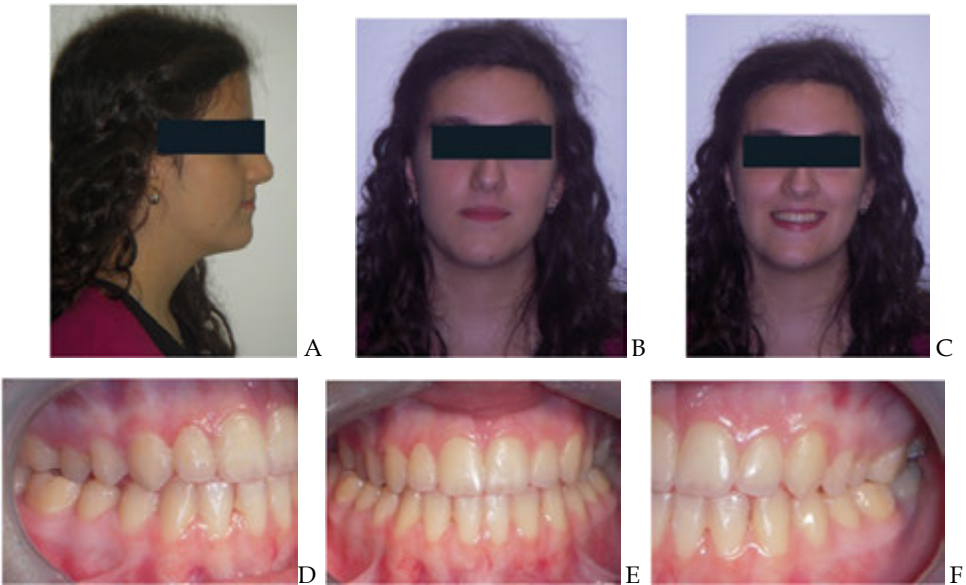


Figure 21. Postretention extraoral photos (A-C) and intraoral photos (D-F)

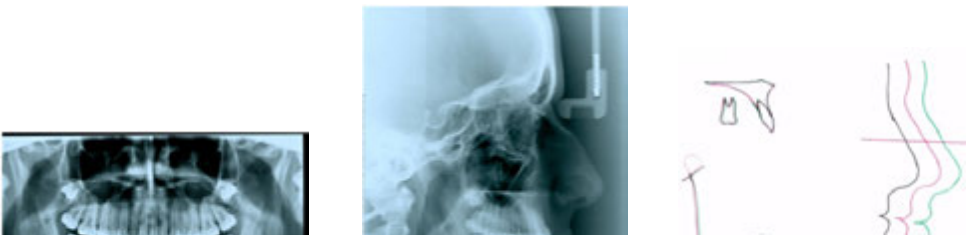

Figure 22. Postretention cephalometric radiographs (A-C)

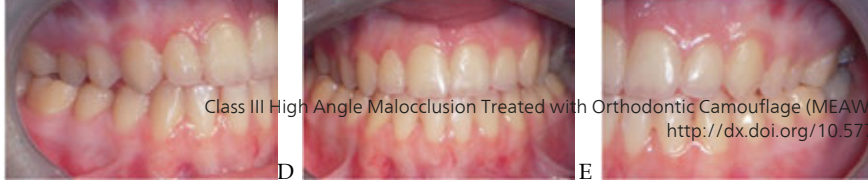

Figure 21 – Postretention extraoral photos (A-C) and intraoral photos (D-F)

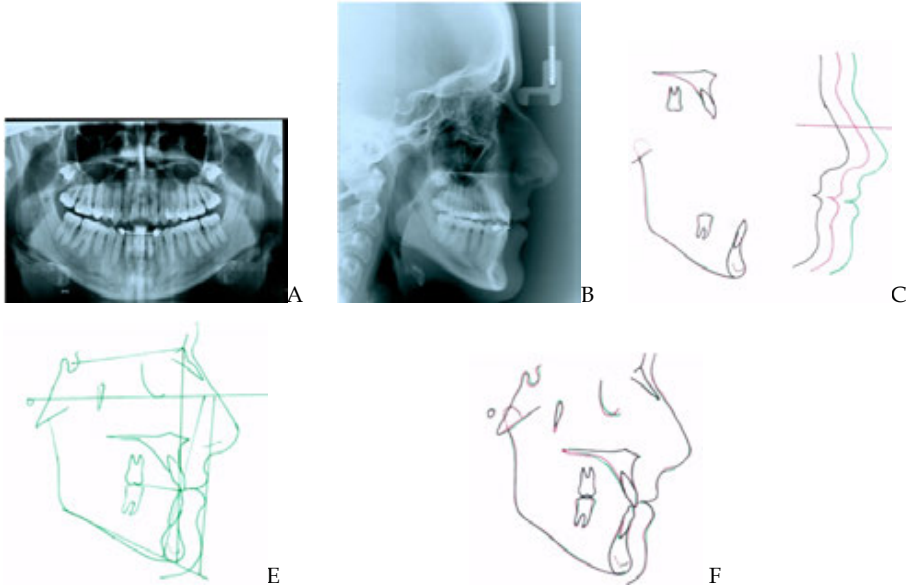


Figure 22 – postretention records (A-F)

Figure 22. Postretention records (A-F)

7. Conclusion

7. Conclusion

The objectives of both treatments were successfully achieved by the use of MEAW therapy. A good functional occlusion and a better profile were attained.

The MEAW technique proved to be effective in the treatment of class III open bite malocclusion and an excellent alternative to the surgical treatment of class III high angle malocclusion when patients refuse surgical treatment.

Author details

Paulo Beltrão

Address all correspondence to: paulobeltrao@sapo.pt

French Board of Orthodontics, Portugal

References

- [1] Shushu, He; Jinhui, Gao; Peter, Wamalwa (2013) Camouflage treatment of skeletal class III malocclusion with multiloop edgewise arch wire and modified class III elastics by maxillary mini-implant anchorage; *Angle orthodontics*,83:630-640
- [2] Sato, Sadao (2001) A treatment approach to malocclusions under the consideration of craniofacial dynamics; Grace printing press,inc
- [3] Kim, Young H (1974) Overbite depth indicator with particular reference to anterior openbite; *AJO*,65:586-611
- [4] Kim, YH; Vietas, JJ (1978) Anteroposterior dysplasia indicator; *American journal of orthodontics*,73:619-633
- [5] Kim, YH (1979) ODI/APDI combination factor; *Angle orthodontics*,49:77-84
- [6] Sato, Sadao (1994) Case report: developmental characterization of skeletal class III malocclusion; *The Angle orthodontics*, 64(2)
- [7] Sato, Sadao; Akimoto (2007) Development and orthodontic treatment of skeletal class III malocclusion without surgical intervention; *The bulletin of Kanagawa dental college*,35(1)
- [8] Beltrão, Paulo (2011) Treatment of class II deep Overbite with multiloop edgewise arch-wire (MEAW) therapy; in Silvano, Naretto ed., *Principles in contemporary orthodontics*, Intech
- [9] Kim, YH (1999) Treatment of anterior openbite and deep overbite malocclusions with MEAW therapy; in James McNamara Jr, ed., *The enigma of vertical dimension-craniofacial growth series*, 36; Ann Arbor: center for Human growth and development, University of Michigan
- [10] Knierim, RW (1999) Diagnosis of openbite and deepbite problems: a clinician's perspective on the Kim approach; in James McNamara Jr, ed., *The enigma of vertical dimension-craniofacial growth series*, 36; Ann Arbor: center for Human growth and development, University of Michigan
- [11] Hyun-Sook, Kim; Seon-Young, Kim (2004) Compensatory changes of a occlusal plane angles in relation to a skeletal factors; *Korea journal of orthodontics*,34(3):229-240
- [12] Eliana Midori, Tanaka; Sadao, Sato (2008) Longitudinal alteration of the occlusal plane and development of different dentoskeletal frames during growth; *AJODO*, 134:602.e1-602.e11
- [13] Petrovic,AG ; Stutzaman, J (1975) Control process in the postnatal growth of the condylar cartilage; in McNamara JA Jr, ed., *Determinants of mandibular growth, monograph 4:craniofacial growth series*, Ann Arbor: Center for Human growth and development, University of Michigan

- [14] Mc Namara, JA jr ; Carlson, DS. (1979) Quantitative analysis of temporomandibular joint adaptations to protrusive function; American journal of orthodontics,76:593-611
- [15] Fushima, K; Kitamura, Y; Mita, H ; Sato, S ; Kim,Y (1996) The significance of the cant of occlusal plane in class II/1 malocclusion; European journal of orthodontics,18:27-40
- [16] Merrifield, LL (1966) The profile line as an aid to critical evaluation of facial esthetics; American journal of orthodontics: 804-822
- [17] Merrifield, LL (1986) Edgewise sequential directional force technology; J.Charles Tweed international foundation,14:22-37
- [18] Ortial, JP (1989) Les modifications faciales par l'orthodontie, Journal de l'edgewise, 20:53-86

