

---

# Neonatal Pneumonia

---

Friedrich Reiterer

Additional information is available at the end of the chapter

<http://dx.doi.org/10.5772/54310>

---

## 1. Introduction

Neonatal pneumonia is a serious respiratory infectious disease caused by a variety of microorganisms, mainly bacteria, with the potential of high mortality and morbidity (1,2). Worldwide neonatal pneumonia is estimated to account for up to 10% of childhood mortality, with the highest case fatality rates reported in developing countries (3,4). It's impact may be increased in the case of early onset, prematurity or an underlying pulmonary condition like RDS, meconium aspiration or CLD/bronchopulmonary dysplasia (BPD), when the pulmonary capacity is already limited. Ureaplasma pneumonia and ventilator-associated pneumonia (VAP) have also been associated with the development of BPD and poor pulmonary outcome (5,6,7). In this chapter we will review different aspects of neonatal pneumonia and will present case reports from our level III neonatal unit in Graz.

## 2. Epidemiology

Reported frequencies of neonatal pneumonia range from 1 to 35 %, the most commonly quoted figures being 1 percent for term infants and 10 percent for preterm infants (8). The incidence varies according to gestational age, intubation status, diagnostic criteria or case definition, the level and standard of neonatal care, race and socioeconomic status. In a retrospective analysis of a cohort of almost 6000 neonates admitted to our NICU pneumonia was diagnosed in all gestational age classes. The incidence of bacterial pneumonia including Ureaplasma urealyticum (Uu) pneumonia was 1,4 % with a median patient gestational age of 35 weeks (range 23-42 weeks) and a mortality of 2,5%. There was only one case of viral pneumonia, due to RSV-infection and no case of fungal pneumonia. The mortality rate associated with pneumonia is in general inversely related to gestational age and birthweight, being higher in cases of early onset compared to late onset, and especially high in low socioeconomic groups and developing countries (2,3,4). Group B Streptococcus accounts for most cases of early onset pneumonia, the commonest bacteria causing late-

onset pneumonia are gram-negative bacilli such as *E coli* or *Klebsiella spp.*(8). Frequently bacterial pathogens found in early and late onset sepsis/pneumonia are listed in Table 1.

### 3. Pathogenesis

Pneumonia may be acquired by intrauterine (e.g. transplacental hematogenous, ascending from birth canal), intrapartum (e.g aspiration) or postnatal routes (e.g. hematogenous, environmental). The pathogens include mainly bacteria, followed by viruses and fungi which induce an inflammatory pulmonary condition (1,8). This may cause epithelial injury to the airways, leakage of proteinaceous fluid into the alveoli and interstitium, leading to surfactant deficiency or dysfunction. Data from a German study (9) suggest that respiratory insufficiency in pneumonia is most likely caused by inhibition of surface-tension-lowering properties of surfactant rather than by surfactant deficiency. Important predisposing factors in the evolution of pneumonia are immaturity, low birth weight, premature rupture of membranes, chorioamnionitis and factors associated with prolonged neonatal intensive care (2, 8).

### 4. Clinical presentation, classification

Depending on the time of manifestation of infection neonatal pneumonia may be classified as early onset pneumonia (within the first 3 or 7 days of life, mostly within 48 hours), or late onset pneumonia (within 4 and 28 days of life). Congenital or intrauterine pneumonia can be considered a variant of early onset pneumonia (2). Other classifications refer to the underlying pathogen, like bacterial or viral pneumonia or the pattern of lung infiltrates (e.g. interstitial pneumonia) on chest radiographs. Clinical signs are unspecific and present as respiratory distress of various degree, suspicious appearing tracheal aspirates, cough, apnea, high or low temperature, poor feeding, abdominal distension, and lethargy. Tachypnea is a predominant clinical sign, present in 60-89 % of cases (2). Persistent fever is rather unusual, but has been reported in neonates with viral pneumonia (10). The radiographical appearance may also vary (11), showing reticulogranular-nodular infiltrates, and bilateral streaky or hazy lungs. As small bronchioli tend to collapse there may be compensatory hyperaeration in areas free of pneumonial infiltration. In addition there may be pleural effusions and/or pneumatocele formation in more complicated cases. Alveolar patterns with coarse, patchy parenchymal infiltrates, consolidation, and diffuse granularity are more typical for bacterial infections while parahilar streakiness, diffuse hazy lungs or reticulo-nodularity are more common in viral disease. The differential diagnoses to be considered on initial presentation are mainly surfactant deficiency syndrome and transient tachypnoe of the newborn, in addition meconium aspiration syndrome (MAS), pulmonary hemorrhage, pulmonary edema, primary pulmonary lymphangiectasis or pulmonary lymphangiomatosis, congestive heart failure (11,12) and Wilson-Mikity-syndrome (13). Additional investigations like echocardiography, high-resolution computed tomography, further laboratory studies, and in rare cases lung biopsy are helpful in the diagnostic work up.

## 5. Diagnosis

The clinical diagnosis of pneumonia is challenging and may not always be correct (over- or underestimated). Early tracheal aspirate cultures obtained within the first 8 to 12 hours of age may help in diagnosing congenital pneumonia (14,15), especially in certain clinical conditions, including maternal fever, clinical chorioamnionitis and leukopenia. But even a positive blood culture or proven airway colonization do not necessarily correlate with the clinical picture of sepsis or pneumonia (16). In the clinical routine pneumonia is diagnosed based on a combination of perinatal risk factors, signs of neonatal respiratory distress, positive laboratory studies, radiological signs and a typical clinical course. Some clinical scenarios are more or less suspicious. For example VAP, reported to be responsible for up to one third of all nosocomial infections, may be suspected two or more days after the initiation of mechanical ventilation when new or persistent infiltrates are noticed in 2 or more chest radiographs (5). Additional definition criteria developed by the Centers for disease control and prevention (17) include an increase in oxygen and ventilator requirements and at least three of the following signs and symptoms: temperature instability, wheezing, tachypnea, cough, abnormal heart rate, change in respiratory secretions, and abnormal peripheral white blood count. The most common organisms in VAP in extremely preterm infants have been shown to be *Staphylococcus aureus* and especially gram-negative organisms like *Pseudomonas aeruginosa*, *Enterobacter* spp. and *Klebsiella* spp. (18). Pneumonia caused by *Ureaplasma* species, *Eubacteria* mainly colonizing the mucosal surface of the respiratory and urogenital tract, may be diagnosed by direct isolation of the organism from endotracheal aspirates using culture or PCR-techniques, by typical chest-x-ray patterns showing disseminated, patchy infiltrates bilaterally with progression to cystic dysplasia, and elevated inflammatory serum-parameters like CRP or an increased white cell count (19,20,21). An organism frequently associated with early onset pneumonia is Group B *Streptococcus*. The clinical manifestation occurs usually within 6 of 8 hours of life and can initially mimic surfactant deficiency syndrome (16, 22).

## 6. Treatment, prevention

As pneumonia is often associated with or non distinguishable from bacterial sepsis initial therapy at the NICU includes broad spectrum intravenous antibiotics according to local protocols. In our unit we start with a combination of ampicillin and a second generation cephalosporine. Although there is no evidence from randomized controlled trials that any antibiotic regime is superior for suspected early onset neonatal sepsis (23), the WHO recommends as first line treatment ampicillin plus gentamycin (24). In cases where we detect pathogens in blood, or in endotracheal aspirates we treat according to susceptibility from antibiogram results. A problem which is increasing worldwide in NICU's is the occurrence of multidrug resistant pathogens, mainly gram-negative bacilli (25). As an alternative to systemic treatment aerosolized antibiotics like colistin have been used successfully in patients with VAP caused by multidrug resistant gram negative bacteria (26, 27). In patients where we suspect or diagnose an U infection we initiate treatment with intravenous clarithromycin (10mg/kg/day), a macrolid antibiotic. In a recently published randomized controlled placebo single-center study clarithromycin treatment resulted in

eradication of Uu in 68,5 % of the patients and a significantly lower incidence of BPD (2.9% vs. 36.4%) in preterm infants weighing between 750 to 1250 g (28). Azithromycin, another macrolid antibiotic, which has good inhibitory activity against *Ureaplasma* in in-vitro studies, may also be beneficial for BPD prevention in *Ureaplasma* colonized/infected preterm infants, especially when used early and for longer duration (29). In general the clinical and microbiological effectiveness of macrolid antibiotics, the most commonly used in the literature being erythromycin, has not yet been shown in adequately powered randomized controlled clinical trials (30). Recommendations for the duration of antibiotic therapy in proven neonatal pneumonia range from 10 to 21 days (8). Surfactant therapy may be beneficial in selected patients by mechanisms improving lung function and decreasing bacterial growth, but may require repeated doses (22, 31,32). However, in a recently published meta- analysis in patients > 35 weeks gestation with proven or suspected pneumonia with onset during the first 28 days of life there was no evidence of a significant effect on the primary outcome death, time to resolution of pneumonia, BPD, pneumothorax and pulmonary hemorrhage (33). There are still open questions related to the surfactant preparation, dosage, optimal treatment frequency, number of doses and patient selection. Severe cases of pneumonia with respiratory insufficiency not responding to conventional therapy may occasionally be candidates for ECMO (34, 35). Preventative measures to be considered include maternal infection control in the prenatal period, prenatal screening and prophylaxis for streptococcal colonization (36), preference of non-or minimal invasive procedures in the neonatal period like respiratory support without intubation (37), immunoprophylaxis against RSV-infection, and general infection control measures in the neonatal unit to reduce the incidence and transmission of health-care-associated infections, the most important being hand hygiene (38,39,40). Preventive strategies that may have a great impact are maternal and infant vaccination programs, as has been already shown in developing countries e.g for pneumococcal polysaccharide vaccines (41).

Early onset (< =7 days)	Late onset (> 7 days)
Group B Streptococcus (g +)	Escherichia coli (g-)
Escherichia coli (g-)	Staphylococcus epidermidis (g+)
Staphylococcus aureus (g+)	Klebsiella-Enterobacter-species (g-)
Listeria monocytogenes (g+)	Pseudomonas aeruginosa (g-)
Enterococcus (g +)	
<i>Ureaplasma urealyticum</i> (g+)*	

g +/- = gram-positive/negative

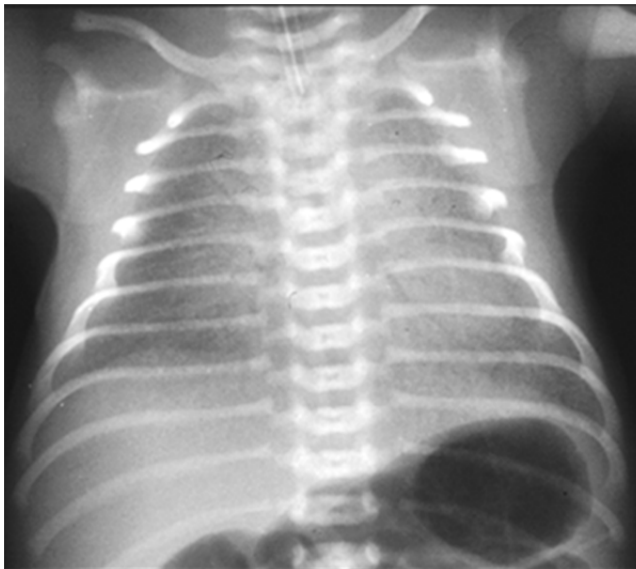\* based on DNA-analysis

**Table 1.** Frequently found bacterial organisms in early and late onset neonatal sepsis and pneumonia

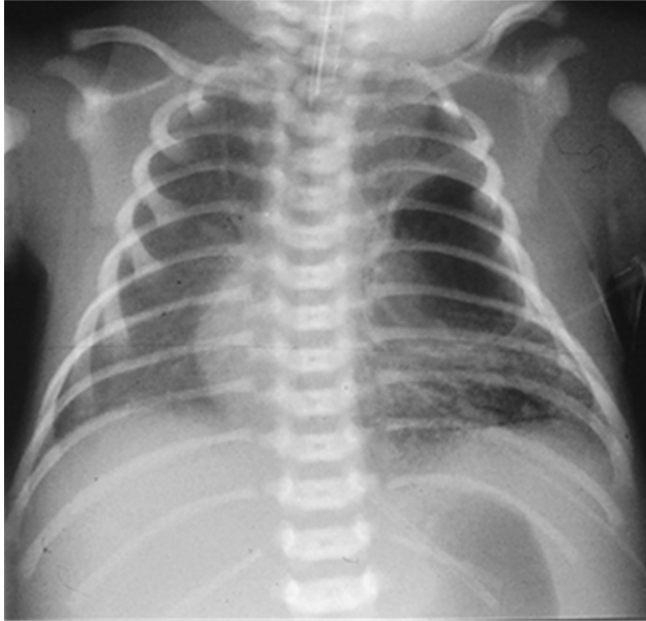## Case 1

A male neonate was born at 42 weeks gestational age to a multiparous healthy mother following spontaneous labor in an external hospital. The membranes ruptured 3 hours before delivery. There was no prenatal maternal screening for group B streptococci disease.

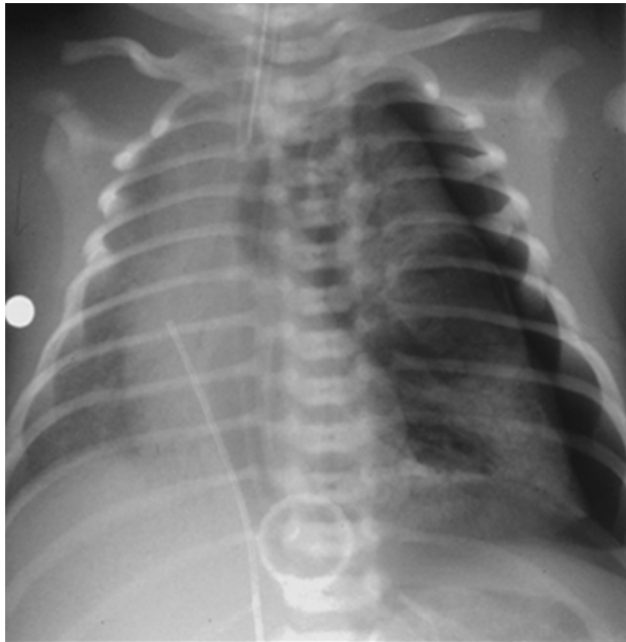After good primary transition, the infant developed clinical signs of respiratory distress with oxygen dependency and respiratory acidosis (6 hours post partum). After initiation of our standard broad spectrum antibiotic therapy the infant was transferred to our NICU. A septic workup showed leukopenia of 2.70 G/L, a left shift in the white cell count (immature/total neutrophils (I/T) 0,33), markedly elevated procalcitonin (303 ng/mL) and interleukin-6 (IL-6 > 400 pg/L) levels, but normal CRP values, and a positive urinary group B streptococcus testing. Blood cultures and tracheal aspirates were negative. Radiographics showed bilateral reticulogranular patterns compatible with the diagnosis of RDS (Figure 1). The patient was first placed on nasal CPAP but had to be intubated and ventilated mechanically due to respiratory deterioration with an increasing oxygen demand up to an FiO<sub>2</sub> of 1,0 and persistent respiratory acidosis. Surfactant therapy showed no sufficient response. Inotropic support was necessary in case of arterial hypotension. Following inhaled nitric oxide therapy a decrease in oxygen requirement from 100 to 50 % was achieved over the following 48 hours, indicative of secondary pulmonary hypertension. On day 5 of life the clinical course was complicated by formation of a large left sided pneumatocele (Figure 2) and a consecutive symptomatic tension pneumothorax (Figure 3), which was successfully treated by insertion of a chest drain. On day 11 of life the patient was extubated, but the chest drain had to be left in situ for 3 ½ weeks due to recurrent air leaks. Laboratory parameters normalized within a week by our standard antibiotic regime. On day 37 of life the neonate had recovered and was discharged home.



**Figure 1.** Bilateral reticulogranular lung pattern in Group B Streptococcus pneumonia mimicking RDS (Case 1)



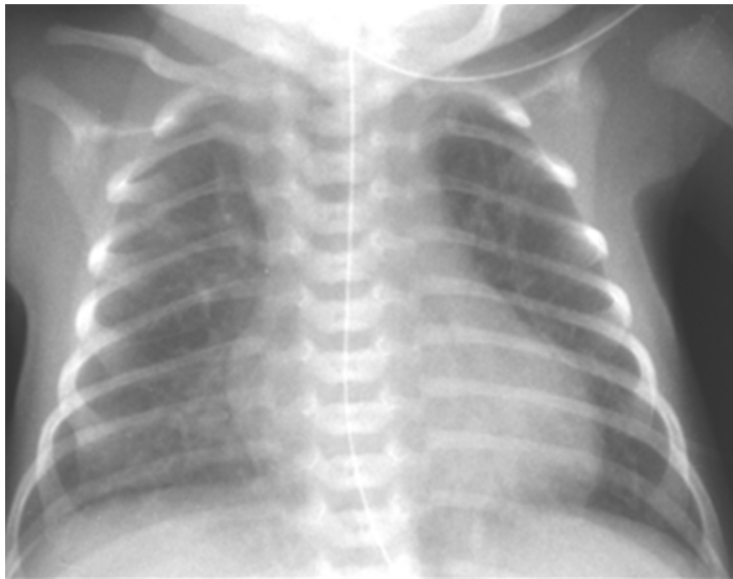
**Figure 2.** Pneumatocele formation on the leftside and streaky-granular infiltrates in Group B Streptococcus pneumonia (Case 1)



**Figure 3.** Leftsided tension pneumothorax complicating Group B Streptococcus pneumonia (Case 1)

## Case 2

A female infant was delivered by vacuum extraction at 37+4 weeks gestational age to a multiparous mother after premature rupture of membranes, meconium stained amniotic fluid and pathological cardiotocogram. Maternal vaginal swabs were tested negative for Group B Streptococcus. Apgar scores and umbilical artery pH were within the normal range. About 12 hours after birth the neonate showed signs of respiratory distress with tachypnea, grunting and an oxygen demand of  $\text{FiO}_2 > 0,3$ . He was intubated and transferred to our NICU. A chest radiograph on admission showed bilateral streaky infiltrates (Figure 4). On day 2 an elevated CRP of 100mg/L, in combination with the findings on chest radiographs and the clinical signs were highly suspicious for the diagnosis of early onset neonatal pneumonia. In the yellowish tracheal aspirates *Listeria monocytogenes* were detected. The asymptomatic mother was tested negative for *Listeria* infection in stool and urine probes. On closer questioning the mother remembered having

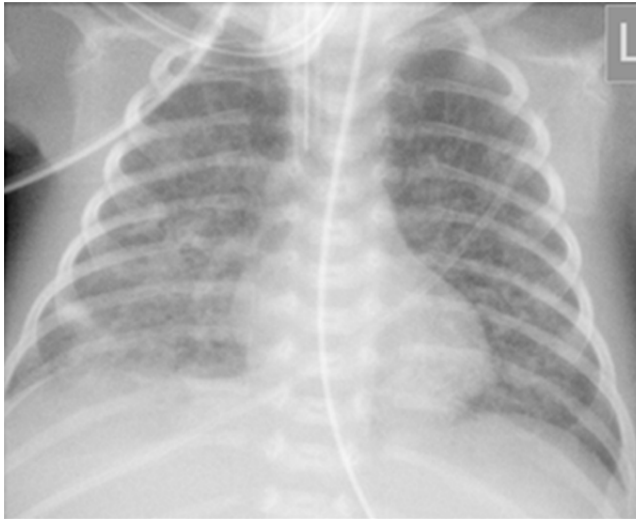

**Figure 4.** Bilateral, streaky and nodular infiltrates in *Listeria* pneumonia (Case 2)

developed gastrointestinal symptoms with diarrhea 2 weeks prior to birth after having eaten some cheese made from unpasteurized milk from a local food store. This led us to assume that the pregnant mother had most likely infected the fetus following ingestion of the bacterium, which had then crossed intestinal cells into the bloodstream and passed the placenta (42,43). After initiation of our standard antibiotic therapy the infant recovered quickly and was extubated on day 4 of life. Antibiotics were given for a total of 14 days. The child had a full recovery.

### Case 3

A female infant was born to a primigravid mother at 28+1 weeks of gestational age. Delivery was by cesarean section due to a pathological cardiotocogram and presumed maternal infection (preterm premature rupture of the membranes 9 hours before delivery, preterm labour, increased neutrophile count and elevated CRP). The mother was treated with



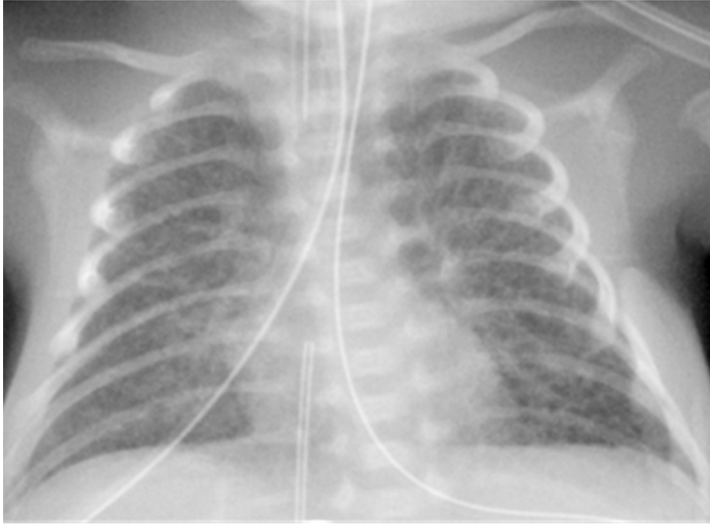**Figure 5.** Bilateral lung infiltrates with consolidation mainly in the middle and right lower lobe in *Enterobacter* pneumonia (Case 3)



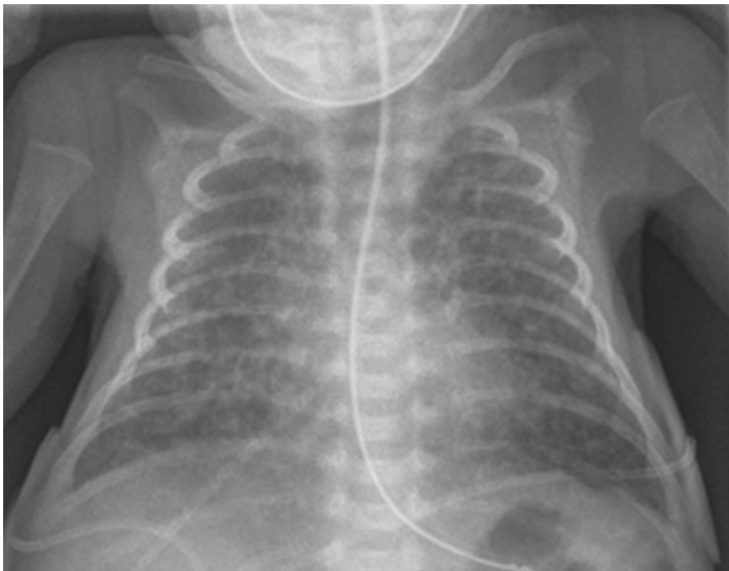antibiotics. The preterm infant showed clinical and radiological signs of RDS and was intubated 15 minutes after birth. Standard broad spectrum antibiotics were started prophylactically but terminated after 3 days when daily white cell counts and CRP levels revealed no signs of infection. The patient was extubated on day 4 of life and placed on nasal CPAP. On day 6 of life the baby appeared septic with new onset of apneas, skin pallor, poor peripheral perfusion, metabolic acidosis and neurological signs like increased muscle tone and extreme irritability. Due to recurrent apneas despite caffeine therapy the infant had to be reintubated. The septic work up confirmed the clinical diagnosis of sepsis. *Enterobacter cloacae*, ESBL positive, was found in the blood culture, liquor cerebrospinalis and tracheal aspirate. Peripheral blood count showed leukocytosis, I/T ratio of 0,54, thrombocytopenia of 38 G/l, and elevated CRP values of 68,4 rising to a maximum of > 200 mg/L. Chest radiographs revealed new parenchymal changes compatible with the diagnosis of late onset bacterial pneumonia (Figure 5). The antibiotic regime was changed to meropenem and teicoplanin. As a further complication of sepsis the patient developed transient renal failure and an intraventricular hemorrhage with consecutive hydrocephalus, which was finally treated by insertion of a ventriculo-peritoneal shunt. After a long complicated neonatal period the patient was finally discharged from the hospital at an age of about 3 months in good clinical condition.

#### Case 4

A female infant was born at 24+3 weeks gestational age by vaginal delivery after the mother had been admitted to our hospital 1 hour prior to delivery with abdominal pain and onset of labors. The neonate developed RDS soon after birth which led to intubation, surfactant application and mechanical ventilation. Broad spectrum antibiotic therapy was started in case of suspected early onset sepsis. Initial laboratory revealed leukocytosis of 52.00 G/L, increased IL-6 (29,2 pg/ml) but normal CRP values. The chest radiograph on admission was typical for mild RDS but the lung pattern worsened during the first 2 weeks of life showing disseminated streaky-patchy infiltrates and partly cystic changes (Figure 6 and 7), accompanied by an increase in ventilatory requirements suggestive of early BPD changes. Therefore a strategy of moderate early BPD-prevention (48) with a one week course of intravenous steroids (hydrocortisone) was started. Results from routine tracheal aspirate screening for *Ureaplasma* infection taken during the second day on mechanical ventilation revealed a positive culture test (10<sup>6</sup>) for *Uu*. In addition the placenta histology showed signs of chorioamnionitis. Under the assumption of early onset *ureaplasma pneumoniae*/ *pneumonitis* we commenced oral macrolid therapy with clarithromycin (10mg/kg), beginning on day 6 of life for a total of 14 days. A repeat *ureaplasma* culture taken during treatment was negative. Mechanical ventilation continued for 18 days followed by a prolonged period of NCPAP lasting 7 weeks. Oxygen dependency for more than 8 weeks but not at a corrected gestational age of 36 weeks was compatible with the diagnosis of mild BPD (44,45). At an age of about 4 months of life she was discharged home.



**Figure 6.** Streaky-patchy lung changes with partly cystic appearance in *Ureaplasma urealyticum* pneumonia on day 6 of life (Case 4)



**Figure 7.** Early BPD changes in *Ureaplasma urealyticum* pneumonia on day 18 of life (Case 4)

## 7. Conclusion

Despite advances in neonatal medicine pneumonia remains a serious problem even in developed countries, mainly due to the increased survival of very preterm births and their susceptibility for early and late bacterial infections. The clinical spectrum of pneumonia is complex, symptoms are often non-specific and laboratory findings may be of limited value, making a rapid and correct diagnosis difficult. Treatment may also be challenging if no organism can be cultivated or in case of multidrug-resistant bacterial pneumonia. There is no clear evidence from randomized controlled trials favoring a specific antibiotic treatment strategy so that treatment decisions are based on local antimicrobial resistance patterns and clinical experience. Surfactant substitution might be beneficial in selected cases. Preventive strategies like health-care associated infection control and vaccination programs might have the greatest impact and should be further evaluated and applied at all levels of perinatal care.

## Author details

Friedrich Reiterer

*Division of Neonatology, Department of Pediatrics, Medical University of Graz, Austria*

## 8. References

- [1] Barnett ED, Klein JO. Bacterial infections of the respiratory tract. In: Remington JS, Klein JO (eds). *Infectious diseases of the fetus and newborn infant*. Philadelphia: WB Saunders, 5th edition 2001: 1006-1018.
- [2] Nissen MD. Congenital and neonatal pneumonia. *Pediatrics Resp. Reviews* 2007; 8:195-203
- [3] Duke T. Neonatal pneumonia in developing countries. *Arch Dis Child Fetal Neonatal Ed.*2005; 90: F2011-F219
- [4] Black RE, Cousens S, Johnson HL et al. Global, regional, and national causes of child mortality in 2008: a systematic analysis, *Lancet* 2010; 375:1969-87
- [5] RM Viscardi. Prenatal and postnatal microbial colonisation and respiratory outcome in preterm infants. In Bancalari E, Polin R. (eds). *The newborn lung*. 2nd edition, 2012; 6: 135-162
- [6] Zhang HZ, Fang J, Su H et al. Risk factors for bronchopulmonary dysplasia in neonates born at < 1500g (1999-2009). *Pediatrics International* 2011; 53: 915-920
- [7] Kotecha S, Hodge R, Schaber J et al. Pulmonary ureaplasma urealyticum is associated with the development of acute lung inflammation and chronic lung disease in preterm infants. *Pediatr Res* 2003; 54: 61-68
- [8] Dear PRF, FIFE A. Pneumonia. In: Greenough A, Milner AD.(eds). *Neonatal respiratory disorders* 2003; London: Arnold: 21: 278-310.
- [9] Rüdinger M, Friedrich W, Rüstow B et al. Disturbed surfactant properties in preterm infants with pneumonia. *Biol Neonate* 2011;79:73-78

- [10] Sert A, Yazar A, Odabas D et al. An unusual cause of fever in a neonate: Influenza A (H1N1) virus pneumonia. *Pediatr Pulmonol* 2010; 45:734-736.
- [11] Swischuk LE. *Imaging of the newborn, infant and young child*. 3rd edition. Baltimore: William and Wilkins, 1989: 59-65
- [12] Costa S, Rocha G, Leito A, Guimaraes H. Transient tachypnea of the newborn and congenital pneumonia: a comparative study. *Journal of Maternal-Fetal and Neonatal Medicine* 2012; 25; 7; 992-994
- [13] Reiterer F, Dornbusch HJ, Urlesberger B et al. Cytomegalovirus associated neonatal pneumonia and Wilson-Mikity-syndrome: a causal relationship ?. *Eur Resp. J* 1999; 13: 460-462
- [14] Booth GR, Al-Hosni M, Ali A et al. The utility of tracheal aspirate cultures in the immediate neonatal period. *J Perinatal* 2009; 29(7): 493-496
- [15] Sherman MP, Goetzman BW, Ahlfors ChE. Tracheal aspirates and its clinical correlates in the diagnosis of congenital pneumonia. *Pediatrics* 1980; 65:2:258-263
- [16] Webber S, Wilkinson AR, Lindsell D et al. Neonatal pneumonia, *Arch Dis Child* 1990;65:207-211
- [17] Centers for Disease Control and Prevention. Criteria for defining nosocomial pneumonia. Available at:  
<http://www.cdc.gov/ncidod/hip/NNIS/members/pneumonia/final/Pneu>
- [18] Apisarnthanarek A, Holsmann-Pazgal G, Hamvas A et al. Ventilator associated pneumonia in extremely preterm neonates in an neonatal intensive care unit: characteristics, risk factors, and outcomes. *Pediatrics*. 2003; 112:1283-1289
- [19] Waites KB, Schelonka RL, Xiao L et al. Congenital and opportunistic infections: Ureaplasma species and mycoplasma hominis. *Seminars in Fetal & Neonatal Medicine* 2009; 14:190-199
- [20] Zotter H, Urlesberger B, Reiterer F et al. Ureaplasmapneumonien und Nachweis von ureaplasma urealyticum im Tubussektret bei Früh- und Neugeborenen. *Gynäkolog Geburtshilfliche Rundsch* 1999; 39:191-194
- [21] Moriokoa I, Fujibayashi H, Enoki E et al. Congenital pneumonia with sepsis caused by intrauterine infection of ureaplasma parvum in a term newborn: a first case report. *J Perinatol*. 2010; 30 (5): 359-362
- [22] Speer Ch, Sweet D. Surfactant Replacement: present and future. In Bancalari E, Polin R. (eds). *The newborn lung. Neonatology questions and controversies*. 2nd edition 2012; 14: 283-299.
- [23] Mtitimila EI, Cooke RW. Antibiotic regimes for suspected early neonatal sepsis. *The Cochrane library* 2004; Issue 4.
- [24] World Health Organization. *Management of the child with a serious infection or severe malnutrition: Guidelines for care at first referral level in developing countries*. Geneva: WHO, 2000.
- [25] Patel SJ, Saiman L. Antibiotic resistance in neonatal intensive care unit pathogens: mechanism, clinical impact, and prevention including antibiotic stewardship. *Clin Perinatol* 2010; 37: 547-563

- [26] IH Celik H, Oguz SS, Demirel G et al. Outcome of ventilator-associated pneumonia due to multidrug-resistant *Acinetobacter baumannii* and *Pseudomonas aeruginosa* treated with aerosolized colistin in neonates: a retrospective study. *Eur J Pediatr* 2012; 171:311-316
- [27] Nakwan N, Wannaro J, Thongmak T et al. Safety in treatment of ventilator-associated pneumonia due to extensive drug-resistant *Acinetobacter baumannii* with aerosolized colistin in neonates: A preliminary report. *Pediatr Pulmonol* 2011; 46: 60-66
- [28] Ozdemir R, Erdeve O, Dizdar EA et al. Clarithromycin in preventing bronchopulmonary dysplasia in ureaplasma urealyticum-positive preterm infants. *Pediatrics* 2011; 128: e1496-e1501
- [29] Ballard HO, Shook LA, Bernard P et al. Use of azithromycin for the prevention of bronchopulmonary dysplasia in preterm infants. *Pediatr Pulmonol*.2011; 46: 111-118
- [30] Mabanta CG, Pryhuber GS, Weinberg GA et al. Erythromycin for the prevention of chronic lung disease in intubated preterm infants at risk for, or colonized with *Ureaplasma urealyticum*. *Cochrane Database Syst Rev*.2003; 4(4): CD003744
- [31] Herting E, Gefeller O, Land M, et al. Surfactant treatment of neonates with respiratory failure and group B streptococcal infection. Members of the Collaborative European Multicenter-Study Group. *Pediatrics* 2000; 106:957-964.
- [32] Finan NN. Surfactant use for neonatal lung injury: beyond respiratory distress syndrome. *Paediatr Res.*2004; 5: Suppl A: S289-97
- [33] Tan K, Lai NM, Sharma A. Surfactant for bacterial pneumonia in late preterm and term infants. *Cochrane Database of Systematic Reviews*. 2012, Issue 2, Art.No.CD008155
- [34] Reiterer F, Kuttinig-Haim M, Maurer U et al. Erfolgreiche Behandlung einer therapierefraktären Schocklunge bei einem Neugeborenen mit connatalen Varicellen mittels Extracorporealer Membranoxygenierung. *Klin Pädiatrie* 1994; 206; 92-94.
- [35] Malhotra A, Hunt R.W, Doherty R.R. Streptococcus pneumoniae sepsis in the newborn. *Journal of Paediatrics Child Health* 2010; 48: E79-E83
- [36] Verani JR, Schrag SJ. Group B streptococcal disease in infants: progression in prevention and continued challenges. *Clin Perinatol* 2010; 37:375-392
- [37] Garland JS. Strategies to prevent ventilator-associated pneumonia in neonates. *Clinics in Perinatology* 2010: 37: 629-643
- [38] Abadesso C, Almeida HI, Virella D et al. Use of palizumab to control an outbreak of syncytial respiratory virus in a neonatal intensive care unit. *J Hosp Infect* 2004; 58(1):38-1
- [39] Graham PL. Simple strategies to reduce health care associated infections in the neonatal unit: line, tube, and hand hygiene. *Clinics in Perinatology* 2010: 37: 645-653
- [40] Kanmaz G, Erdeve O, Oguz SS et al. Influenza A (H1N1) virus pneumonia in newborns: experience of a referral level III neonatal intensive care unit in turkey. *Pediatric Pulmonol* 2011; 46: 201-202
- [41] O'Dempsey BP, McArdle T, Ceesay SJ et al. Immunization with pneumococcal polysaccharides vaccine during pregnancy. *Vaccine* 1996; 14: 963-970
- [42] Jasser-Nitsche H, Reiterer F, Kutschera J et al. Listerienpneumonie bei einem reifen Neugeborenen. *Monatszeitschr Kinderheilkunde* 2009; Suppl 2: 217-218

- [43] Posfay-Barbe KM, Eald E. Listeriosis. *Seminars in Fetal & Neonatal Medicine* 2009; 14: 228-223
- [44] Kugelman A, Durand M. A comprehensive approach to the prevention of bronchopulmonary dysplasia. *Pediatr Pulm* 2011; 1-13
- [45] Kinsella JP, Greenough A, Abmann SH. Bronchopulmonary dysplasia. *Lancet* 2006; 367: 1421-1431.