

---

# Giant Cell Arteritis and Arteritic Anterior Ischemic Optic Neuropathies

---

Dragos Catalin Jianu and Silvana Nina Jianu

Additional information is available at the end of the chapter

<http://dx.doi.org/10.5772/55345>

---

## 1. Introduction

Ischemic optic neuropathies (IONs) are a major cause of blindness or seriously impaired vision in the middle-aged and elderly population, although they can occur at any age. ION is of two types: anterior (AION) and posterior (PION), the first involving the anterior part of the optic nerve (also called the optic nerve head, ONH) and the second, the rest of the optic nerve. Pathogenetically AION and PION are very different diseases. AION represents an acute ischemic disorder (a segmental infarction) of the ONH supplied by the posterior ciliary arteries (PCAs), while PION has no specific location in the posterior part of the optic nerve and does not represent ischemia in a specific artery [1].

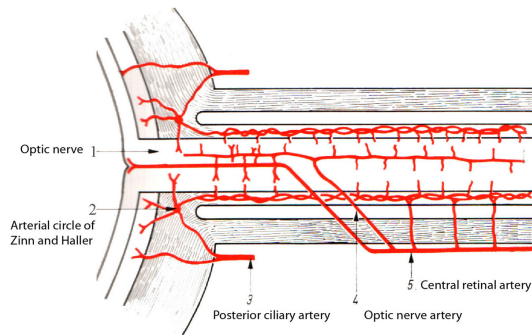
Blood supply blockage can occur with or without arterial inflammation. For this reason, AION is of two types: non-arteritic AION (NA-AION) and arteritic AION (A-AION). The former is far more common than the latter, and they are distinct entities etiologically, pathogenetically, clinically and from the management point of view [1, 2].

A-AION is an ocular emergency and requires immediate treatment with systemic corticosteroids to prevent further visual loss. This is almost invariably due to giant cell arteritis (GCA), which is a primary vasculitis that affects extracranial medium (especially external carotid artery-ECA-branches) and sometimes large arteries (aorta and its major branches)-large-vessel GCA [3, 4]. The diagnosis of GCA requires age more than 50 years at disease onset, new headache in the temporal area, temporal artery tenderness, and/or reduced pulse, jaw claudication, systemic symptoms, erythrocyte sedimentation rate (ESR) exceeding 50 mm/hr, and typical histologic findings (granulomatous involvement) in temporal artery biopsy (TAB) [5]. Approximately 40-50% of patients with GCA have ophthalmologic complications, including visual loss secondary to A-AION, central retinal artery occlusion, homonymous hemianopsia or cortical blindness (uni- or bilateral occipital infarction) [6].

NA-AION is a multifactorial disease with multiple risk factors that contribute to its development: the nocturnal arterial hypotension is the most important risk factor. Often, NA-AION patients have an anatomical predisposition: small discs, where structural crowding of nerve fibers (crowded disk), and reduction of the vascular supply, which may combine to impair perfusion to a critical degree [1, 2].

## 2. Arterial blood supply of the anterior part of the optic nerve

Arterial blood supply of the anterior part of the ONH is presented in figure 1.



**Figure 1.** Arterial blood supply of the anterior part of the optic nerve.

The ONH consists of, from front to back: a). surface nerve fiber layer, b). prelaminar region, c). lamina cribrosa region, and d). retrolaminar region.

- a. The surface nerve fiber layer is mostly supplied by the retinal arterioles. The cilioretinal artery, when present, usually irrigates the corresponding sector of the surface layer [1, 2].
- b. The prelaminar region is situated in front of the lamina cribrosa. It is supplied by centripetal branches from the peripapillary choroid [1, 2].
- c. The region of the lamina cribrosa is irrigated by centripetal branches from the PCAs, either directly or by the so-called arterial circle of Zinn and Haller, when that is present [1, 2].
- d. The retrolaminar region is the part of the ONH that lies immediately behind the lamina cribrosa. It is supplied by two vascular systems: the peripheral centripetal and the axial centrifugal systems. The former represents the major source of irrigation to this part. It is formed by recurrent pial branches arising from the peripapillary choroid and the circle of Zinn and Haller (when present, or the PCAs instead). In addition, pial branches from the central retinal artery (CRA) also supply this part. The latter is not present in all eyes. When present, it is formed by inconstant branches arising from the intraneural part of the CRA. From the account of the arterial irrigation of the ONH given above, it is evident that the PCAs are the main source of blood supply to the ONH [1, 2].

### 3. Pathophysiology of factors controlling blood flow in the optic nerve head

The blood flow in the ONH depends upon: a). resistance to blood flow, b). arterial blood pressure (BP), and c). intraocular pressure (IOP) [1, 2].

- a. resistance to blood flow. It depends upon the state and calibre of the vessels supplying the ONH, which in turn are influenced by: the efficiency of autoregulation of the ONH blood flow, the vascular changes in the arteries feeding the ONH circulation, and the rheological properties of the blood.
- b. arterial blood pressure (BP). Both arterial hypertension and hypotension can influence the ONH blood flow in a number of ways. In an ONH, a fall of blood pressure below a critical level of autoregulation would decrease its blood flow. Fall of BP in the ONH may be due to systemic (nocturnal arterial hypotension during sleep, intensive antihypertensive medication, etc.) or local hypotension.
- c. intraocular pressure (IOP). There is an inverse relationship between IOP and perfusion pressure in the ONH.

The blood flow in the ONH is calculated by using the following formula [1]:

Perfusion pressure = Mean BP minus intraocular pressure (IOP). Mean BP = Diastolic BP + 1/3 (systolic BP - diastolic BP).

AION cases can be broadly classified into two groups [1, 2]:

1. AION due to thrombotic or embolic lesions of the arteries/arterioles feeding the ONH:
  - a. thrombotic lesions: Occlusion of the PCAs is most commonly caused by GCA (resulting in infarction of the ONH and A-AION) and less commonly by other types of vasculitis.
  - b. embolic lesions: Multiple emboli in the vessels of the ONH have been demonstrated histopathologically in NA-AION.
2. AION due to transient non-perfusion or hypoperfusion of the nutrient vessels in the ONH (paraoptic branches of PCAs). A transient non-perfusion or hypo-perfusion of the ONH can occur due to a transient fall of perfusion pressure in its vessels, which in turn in susceptible persons would produce NA-AION. Almost all NA-AION cases belong to this group.

### 4. The major features of arteritic-anterior ischemic optic neuropathies and nonarteritic-anterior ischemic optic neuropathies

For the comparison of major features of A-AION and NA-AION we use a *complex protocol*:

- a detailed history of all previous or current systemic diseases, particularly of arterial hypertension, diabetes mellitus, hyperlipidemia, ischemic heart disease, stroke, transient ischemic attack, and carotid artery disease.
- a physical examination including the temporal arteries (TAs).
- a comprehensive ophthalmic evaluation, including visual acuity with the Snellen visual acuity chart, visual fields with a Goldmann perimeter, relative afferent pupillary defect, intraocular pressure, slit-lamp examination of the anterior segment, lens and vitreous, direct ophthalmoscopy, color fundus photography, and, in acute cases, fluorescein fundus angiography [1].
- color Doppler imaging (CDI) of retrobulbar (orbital) vessels with an ultrasound (US) equipment with a 10MHz linear probe for detecting and measuring orbital vessel blood flow in: the ophthalmic arteries (OAs), the CRAs, the superior ophthalmic veins, and the PCAs [7, 8].

While the patient is supine, the transducer is applied to the closed eyelids using sterile ophthalmic methylcellulose as a coupling gel. During the examination, minimal pressure is applied to the globe to avoid artifacts. The patient is asked to stay still, and not move his eyes.

Blood flow toward the transducer is depicted as red, and flow away from the transducer is colored blue. With the probe resting on the closed eyelids, the US beam is directed posteriorly in the orbit.

After systematic scanning of the orbit, the CRAs, PCAs, and OAs are imaged:

- a. the CRA is identified just below the optic disc (<1 cm), and has a forward red-coded blood flow;
- b. the nasal and temporal trunks of PCA are identified along both sides of the optic nerve. The arteries have a forward red-coded blood flow;
- c. the OA is identified deeper in the orbit, usually before crossing the optic nerve. It has a forward red-coded blood flow.

The Doppler sample gate placed on the detected vessel has 1.5 cm. Sometimes, the orbital vessels are not parallel to the US beam. For this reason, we perform an angle correction between 0-60°.

Also, a spectral velocity analysis is performed. The peak systolic velocity (PSV), and end-diastolic velocity (EDV) are calculated for each vessel.

The Resistance Index (RI), also referred to as Pourcelot Index, is automatically calculated according to the following equation:

$$RI = (PSV - EDV) / PSV.$$

Absent signals not corresponding to carotid occlusive disease are classified as Doppler sonographic findings typical of GCA of the orbital arteries [9].

- extracranial Duplex sonography is performed with an US equipment with a 7.5-10 MHz linear array transducer.

For the examination of TAs, we use a 10 MHz linear probe. Color box steering and beam steering are maximal, and the color covers the artery lumen exactly because using these machine adjustments, sensitivities and specificities with regard to clinical diagnosis of temporal arteritis and histology are high [10]. We examine both common superficial TAs and the frontal and parietal rami as completely as possible in longitudinal and transverse planes. Concentric hypoechoic mural thickening (a so-called halo) is considered to be an ultrasonographic finding typical of GCA. Stenosis is considered to be present if blood-flow velocity is more than twice the rate recorded in the area before the stenosis, perhaps with waveforms demonstrating turbulence and reduced velocity behind the area of stenosis. Acute occlusion is considered to be present if the US image shows hypoechoic material in the former artery lumen with absence of color signals [10].

- fluorescein fundus angiography.
- laboratory findings in the form of a TAB are assessed at 3-7 days when GCA is suspected (based on systemic symptoms, elevated ESR, elevated C-reactive protein-CRP, and suspicion of A-AION). Because of unilateral clinical ocular involvement in all cases, we took a biopsy either from the ipsilateral side (representing 2.5 cm of the tender, swollen segments of the affected artery-“skip lesions”) or from the ipsilateral site targeted by the ultrasonographer. Serial sections are examined, as there could be variations in the extent of involvement along the length of the artery [11].
- Cranial computed tomography (CT) scanning is performed for eventual associated stroke.
- CT-Angiography (CT-A) is performed at presentation, after Extracranial Duplex sonography, only in selected cases. It allows analysis of the arterial wall and the endoluminal part of the aorta and its branches in cases of large-vessel GCA, and/or severe internal carotid artery (ICA) stenosis, or occlusion.
- Transthoracic echocardiography (TTE) is used for eventual cardiac embolic source of NA-AION.

The comparison of major features of A-AION and NA-AION is presented in table I [1-3, 5, 6, 9, 12, 13, 16, 18, 24-26].

#### **4.1. Age and gender distribution**

A-AION, like GCA is almost always seen in persons aged older than 50 years (more often women than men), with a mean age of near 70 years (mean age for NA-AION is approximately 60 years, with no gender predisposition) [1, 2, 6, 12]. In a study of 406 patients with NA-AION [1], the age range was 11-91 years (mean age  $60 \pm 14$  and median 61 years) and 43 (10.5%) of the 406 patients were young (<45 years), 60% were men and 40% women [1].

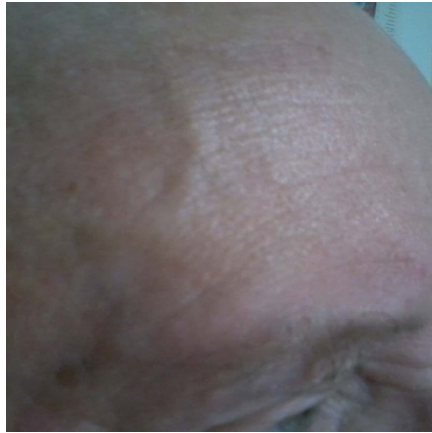## 4.2. Classic clinical symptoms of GCA with A-AION

The majority of GCA patients with A-AION present the classic clinical symptoms of GCA: new moderate bitemporal headache, especially common at night, scalp tenderness (which is first noticed when combing the hair), and abnormal TAs on palpation (tender, nodular, swollen, and thickened arteries) (Figure 2).

A study of Gonzales-Gay aiming to establish the best set of clinical features that may predict a positive TAB in a community hospital disclosed that headache, jaw claudication, and abnormal TAs on palpation were the best positive predictors of positive TAB in patients on whom a biopsy was performed to diagnose GCA [6]. This author established clinical differences between biopsy proven GCA and biopsy-negative GCA patients. Moreover, he observed a non-significantly increased frequency of abnormal palpation of the TA on physical examination in biopsy-proven GCA patients (73.3%) compared with biopsy-negative GCA patients (54.2%). The lack of pulsation is very suggestive of GCA because it is most unusual for the superficial TAs to be non-pulsatile in normal elderly individuals. The jaw claudication is the result of ischemia of the masseter muscles, which causes pain on speaking and chewing [6, 13].

FEATURE	A-AION	NA-AION
Age (mean years)	70	60
Sex ratio	Female > male	Female = male
Associated symptoms	New temporal headache, jaw claudication, abnormal temporal arteries on palpation, with reduced pulse, scalp tenderness	Pain occasionally noted
Visual acuity	Up to 76% < 20/200 (6/60)	Up to 61% > 20/200 (6/60)
Optic disc	Pale edema > hyperemic edema Cup normal	Hyperemic edema > pale edema Cup small
Erythrocyte sedimentation rate (mm/h)	>50	<50
C-reactive protein (mg/l)	> 5	< 5
Temporal artery biopsy	Granulomatous inflammation of the media layer	-
Color Doppler Imaging of the retrobulbar (orbital) vessels	Severe diminished blood flow velocities in the posterior ciliary arteries (PCAs), especially on the affected side, and high resistance index (RI) in all retrobulbar vessels, in both orbits.	Blood flow velocities and RI in PCAs are preserved.
Fluorescein fundus angiography	Disc and choroid filling delay	Disc filling delay
Treatment	Corticosteroids	None proved

**Table 1.** The comparison of major features of arteritic-anterior ischemic optic neuropathies (A-AION) and nonarteritic-anterior ischemic optic neuropathies (NA-AION).



**Figure 2.** Patient MM with giant cell arteritis. Dilated and nodular right superficial temporal artery.

The classic clinical symptoms of GCA cases with A-AION are absent in NA-AION patients [1].

Large vessel GCA is a subgroup of GCA described in at least 17% of cases. In these patients, inflammation occurs also at the level of the aorta and its branches (especially of the subclavian, the axillary arteries, etc), despite the fact that symptoms of aortic involvement (aortic aneurysm rupture) may appear years after the initial diagnosis of this vasculitis [4, 14, 15, 16].

#### **4.3. Systemic symptoms of GCA with A-AION**

The majority of patients with GCA and A-AION present fever, fatigue, malaise, and weight loss. Some patients with GCA develop severe bilateral pain and aching involving the neck, shoulders, and pelvic girdles associated with morning stiffness (polymyalgia rheumatica) [13]. However, a study [17] showed that 21% of the patients with positive TAB for GCA had no systemic symptoms or signs and the only presenting sign was visual loss. This type of GCA is called occult GCA, which is fairly common - a very important fact to be borne in mind when dealing with AION [1].

The systemic symptoms of GCA are absent in NA-AION patients [1].

#### **4.4. Systemic diseases associated with NA-AION**

Nocturnal hypotension seems to be an important precipitating factor in the susceptible patients. It is the most important systemic disease associated with NA-AION [1, 2]. In Hayreh series [1, 2] of 544 NA-AION cases, where the patients could give some information on the time of onset of visual loss, 73.3% gave a definite history of discovering the visual loss on waking up in the morning. When antihypertensive drugs were taken at bedtime, they produced a far more marked degree of nocturnal hypotension than when taken in the morning, because they aggravate the naturally occurring fall of BP during sleep. Hayreh's studies [1, 2] suggest that in an ONH already susceptible to ischaemic disorder, nocturnal hypotension may

act as "the straw that breaks the camel's back". In a healthy ONH with normal autoregulation, a similar fall of BP during the night may have no deleterious effect at all. All these facts indicate that NA-AION may be occurring as an iatrogenic disease in some persons. A combination of arterial hypertension and associated nocturnal hypotension can play an important role in either the development or the progression of NA-AION.

Hayreh [1] showed that, compared with the prevalence reported in the general population, young (<45 years), middle-aged (45-64 years) and elderly (≥65 years) patients with NA-AION showed a significantly higher prevalence of arterial hypertension, diabetes mellitus, and gastro-intestinal ulcer. Development of NA-AION following massive or recurrent haemorrhages has been known for well over twenty centuries. These usually occur from the gastrointestinal tract or uterus. Also, middle-aged and elderly patients showed a significantly higher prevalence of ischaemic heart disease and thyroid disorders. Following NA-AION, patients with both arterial hypertension and diabetes mellitus had a significantly higher incidence of cerebrovascular disease.

As a part of generalized atherosclerosis and arteriosclerosis, the ICAs, OAs, and PCAs may contribute to the development of NA-AION. ICA disease can contribute to development of NA-AION either by embolism or by lowering the perfusion pressure because of marked stenosis. The most likely mechanism of development of NA-AION in cardiac valvular disease is microembolism to the ONH [1, 2].

Patients with NA-AION may give a history of migraine. Hayreh studies have shown that serotonin released by platelets at the site of atheromatous plaques in the atherosclerotic arteries can also produce vasospasm of the PCAs [1, 2].

NA-AION has been reported in patients with haematologic disorders, including sickle-cell trait, polycythaemia, thrombocytopenic purpura, leukaemia and various types of anaemia [1, 2].

#### **4.5. Ocular conditions associated with NA-AION**

The most important ocular conditions associated with NA-AION are: a). absent or small cup in the optic disc, b). raised intraocular pressure, c). marked optic disc edema, d). location of the watershed zone of the PCAs in relation to the ONH, and e). vascular disorders in the nutrient vessels of the ONH [1, 2].

##### *4.5.1. Absent or small cup in the optic disc*

Studies have shown that eyes with NA-AION have no cup or only a very small cup in the optic disc. The overcrowding of the nerve fibers in a small scleral canal may be a precipitating factor in the production of NA-AION, although not the primary factor. The ONH in the prelaminar region is surrounded by a firm, non-yielding Bruch's membrane. When the axons swell, they can expand only at the expense of capillaries in the ONH, so the capillaries are compressed, causing impaired blood flow. When BP falls during sleep due to nocturnal arterial hypotension, there may be little or no blood flow in the ONH capillaries, resulting in hypoxia or



ischaemia of the axons. The patient discovers the visual loss upon waking. If the optic disc has a large enough cup, the axons have sufficient space to swell without significantly compressing the capillaries; thus the presence of a cup is a protective mechanism [1, 12].

#### **4.6. Laboratory findings in GCA with A-AION**

ESR is often very high in GCA, with levels more than 50 mm/hr (fairly suggestive of this disease). In interpreting the ESR it should be emphasized that the levels of 40 mm/hour may be normal in the elderly and cases of biopsy-proven GCA have been reported in patients with ESR levels lower than 30 mm/hr. Approximately 20% of the patients who have a positive TAB for GCA present a normal ESR; hence "normal" ESR does not rule out GCA. CRP is often raised in GCA (the normal range is <5mg/l). It generally runs parallel with ESR, and may be helpful when the ESR is equivocal. However, in some cases there is elevation of ESR but not of CRP. The combination of ESR and CRP together gives the best specificity (97%) for detection of GCA [1, 6, 18].

Patients with NA-AION do not show any of these laboratory abnormalities [1, 6, 18].

#### **4.7. Temporal artery biopsy and the histopathologic picture in GCA with A-AION**

A TAB is the gold standard test for the diagnosis of GCA. Because corticosteroid therapy is required in most cases for more than 1 year in GCA with A-AION, the pathologic confirmation of this vasculitis is advisable. A biopsy result may be negative in 9-44% of patients with clinical positive signs of temporal arteritis, because of segmental (discontinuous) involvement of TA [10, 19-21]. For this reason, the TAB has to be guided in all cases with clinical suspicion of GCA by Doppler Ultrasonography and typical TAs signs (tender, swollen portions of TAs). In all cases with A-AION due to GCA the histopathologic picture is represented by a granulomatous inflammation of the media layer (chronic inflammatory infiltrate with giant cells) with characteristic fragmentation of the internal limiting lamina and intimal thickening.

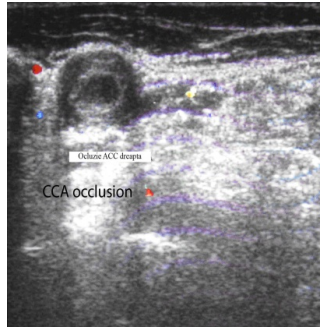
#### **4.8. Extracranial Duplex Sonography in AION patients**

##### *4.8.1. Extracranial Duplex Sonography in A-AION patients*

US of the TAs in temporal arteritis has garnered considerable interest as a GCA diagnosis tool. It indicates segmental inflammation of TAs [14, 22]. Schmidt demonstrated that the most specific (almost 100% specificity) and sensitive (73% sensitivity) sign for GCA is a concentric hypoechogenic mural thickening "halo", which was interpreted as vessel wall edema. Other positive findings for GCA are the presence of occlusion and stenoses. US investigation of the TAs must be performed before corticosteroid treatment, or within the first 7 days of treatment, because the halo revealed by TAs US disappears within 2 weeks of corticotherapy [10, 14, 22].

Similar US patterns can be found in other branches of the ECAs, including the facial, internal maxillary, and lingual arteries.

Interestingly, in some cases with large-vessel GCA, the common carotid arteries (CCAs) and the ICAs are also involved [16] (figure 3).



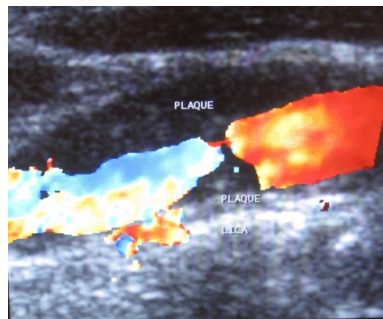
**Figure 3.** Patient MO - B mode insonation in large vessel giant cell arteritis. Transverse view of the left CCA. Hypoechoic wall swelling with CCA occlusion.

After weeks with corticosteroids treatment, the halo revealed by TAs US disappears, but the wall swelling of the larger arteries (subclavians, axilars, CCAs, ICAs, etc.) remains in large-vessel GCA cases [16].

Schmidt compared the results of TAs US examinations with the occurrence of visual ischemic complications in 222 consecutive patients with newly diagnosed, active GCA. However, findings of TAs US did not correlate with eye complications [14].

#### 4.8.2. Extracranial Duplex Sonography in NA-AION patients

Ipsilateral ICA severe stenosis/occlusion can contribute to development of NA-AION either by embolism or by transient nonperfusion or hypoperfusion of the nutrient vessels in the ONH (paraoptic branches of PCAs) (figure 4) [1, 23].



**Figure 4.** Patient AP- Color Doppler ultrasound. Longitudinal view of the left CCA with severe stenosis.

In Hayreh opinion [1, 2], embolic occlusion of the PCAs or of the ONH arterioles seems to occur much less frequently than thrombotic occlusion, but this impression may be erroneous because of our inability to see the emboli in these vessels on ophthalmoscope compared to the

ease with which they are seen in the retinal arterioles. Embolic etiology of NA-AION can be clinically suspected if the patients presents the following features: a). sudden onset of visual loss, definitely later on in the day, and not related to sleep or any other condition associated with arterial hypotension; b). the optic disc has a large cup; c). evidence of occlusion of a PCA on fluorescein fundus angiography, and on CDI of retrobulbar vessels, but d). no systemic symptoms or signs suggestive of GCA and, e). a negative TAB for GCA [1, 24-26].

#### **4.9. Cranial computed tomography, Computed tomography angiography, and transthoracic echocardiography**

CT-scanning identifies associated strokes (including occipital infarction), CT-A confirms cases of large-vessel GCA associated with A-AION, or patients with ipsilateral occlusion/severe ICA stenosis associated with NA-AION. TTE represents a part of the embolic evaluation in AION patients. Cardiac embolic source is rarely detected only in NA-AION cases.

#### **4.10. Ocular symptoms**

Anterior segment examination of both eyes is generally normal in all AION cases. Simultaneous bilateral AION onset is very rare (during cardio-pulmonary surgery with massive blood loss) [1].

##### *4.10.1. Monocular amaurosis fugax and permanent visual loss*

If a patient with AION has a history of amaurosis fugax before the permanent visual loss, it is highly suggestive of GCA associated with A-AION. Other A-AION patients develop permanent visual loss without any warning [1, 12].

However, amaurosis fugax is never found in NA-AION cases [1, 12].

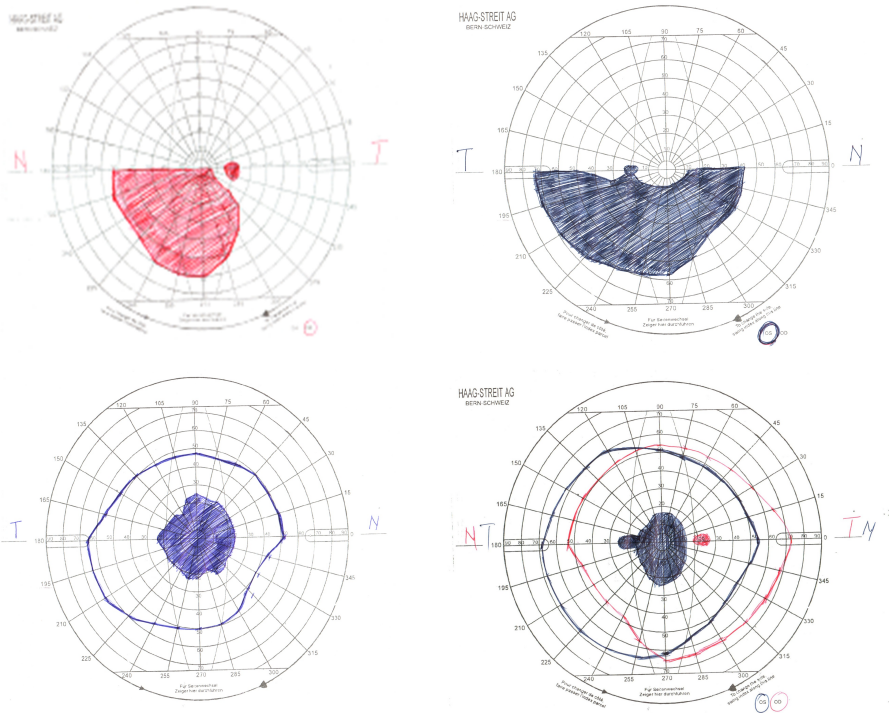
A-AION results from PCAs vasculitis and the consecutive ONH infarction. Human autopsy studies of acute A-AION demonstrated ischemic necrosis of the prelaminar, laminar, and retrolaminar portions of the ONH and infiltration of the PCAs by chronic inflammatory cells. In some cases of these studies, segments of PCAs were occluded by inflammatory thickening and thrombi [12, 23].

In a Hayreh study [1], 54% of patients with A-AION had initial visual acuity ranging from counting fingers to no light perception, as compared to 26% in the NA-AION group, and only light or no light perception in 29% and 4%, respectively. This result shows that sudden, painless, severe permanent deterioration/loss of vision is extremely suggestive of A-AION. However, in Hayreh's series, about 21% of eyes with A-AION had 6/12 or better vision [1]. In NA-AION cases, generally there is progressive visual loss, and the patient usually notices further loss on waking in the morning [1].

##### *4.10.2. Visual fields*

Perimetry usually shows relative or absolute visual field defects. The most common visual field defect in NA-AION is an inferior nasal sectoral defect, which is relative or absolute. The

next most common visual field defect is the relative or absolute inferior altitudinal; other optic disc-related field defects (central scotoma, etc) are less common (Figure 5). While the disc has edema, the visual fields may improve or deteriorate further, but once the disc edema has resolved completely, the visual field defects tend to stabilize [1, 12].

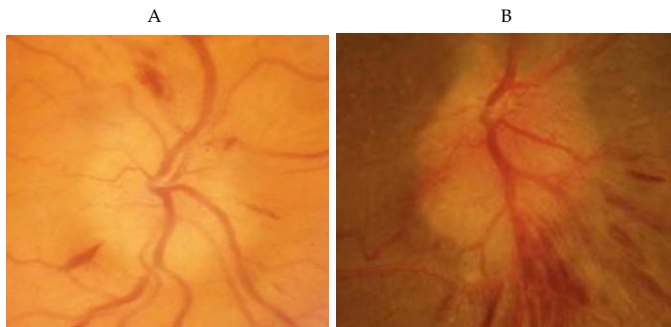


**Figure 5.** Common visual field defects in patients with nonarteritic-anterior ischemic optic neuropathies.

A relative afferent pupillary defect is invariably present in all cases of monocular AION.

#### 4.11. Ophthalmoscopy

The majority of A-AION cases (69 % in Hayreh study [1]) unlike NA-AION patients have optic disc swelling with a characteristic chalky white color (pallor is associated with the edema of the optic disc) (Figure 6.A.).



**Figure 6.** A. Patient TL. Fundus view of the left eye. Arteritic-anterior ischemic optic neuropathy. The optic disc demonstrates pale, diffuse edema. B. Patient AN. Fundus view of the left eye. Nonarteritic-anterior ischemic optic neuropathy. The optic disc demonstrates hyperemic diffuse edema.

Diffuse disc pallor develops 2 weeks after the onset of visual loss. On resolution of optic disc edema within 1-2 months, the optic disc develops cupping in almost all cases. Also unlike NA-AION, all A-AION patients have a contralateral optic disc, with normal diameter/normal physiological cup (absence of “disk at risk”).

Initially, the optic disc is edematous in all NA-AION patients. Sometimes, the edema is more prominent in one part of the disc. Frequently, there are associated splinter hemorrhages at the disc margin. Hyperemia is associated with optic disc edema in the majority of cases (Figure 6.B.). The fellow optic disc shows a very small cup in the majority of cases (>75% of NA-AION patients present a contralateral “disk at risk”, with associated mild disc elevation, and disc margin blurring without over edema) [1,12].

At 2 months, the optic disc edema resolves spontaneously, resulting in generalised or sectoral pallor of the optic disc.

Consequently, ophthalmoscopy indicates that optic disc edema is associated more frequently with pallor (a chalky white color) in A-AION patients, and more frequently with hyperemia in NA-AION patients [1, 2, 24, 25].

#### 4.12. Fluorescein fundus angiography

If angiography is performed during the first few days after the onset of A-AION (acute A-AION) there is almost always evidence of PCA thrombotic occlusion, with absence of choroidal and optic disc filling in its distribution in all A-AION patients. However, later, with the establishment of collateral circulation, this information may be lost. In contrast, there is an impaired optic disc perfusion, with relatively conserved choroidal perfusion in all NA-AION cases.

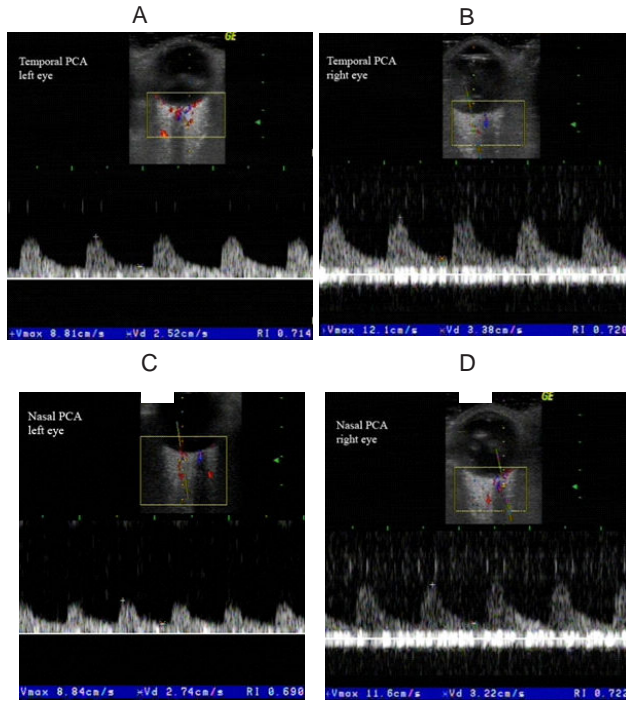
Consequently, extremely delayed or absent filling of the choroid, which was identified in acute A-AION patients, has been suggested as a fluorescein-angiogram characteristic of A-AION. It has been considered as one useful factor to differentiate A-AION from NA-AION [1, 12].

### 4.13. Color Doppler imaging of the retrobulbar (orbital) vessel features

#### 4.13.1. Spectral Doppler analysis of the retrobulbar vessels in A-AION

In acute stage, blood flow cannot be detected in the PCAs in the clinically affected eye of any of the GCA patients with A-AION. Low EDV and high RI are identified in all other retrobulbar vessels (including the PCAs in the fellow eye) of all A-AION patients.

At one week, CDI examination of retrobulbar vessels reveals blood flow alterations in all A-AION patients despite the treatment with high-dose corticosteroids. Severely diminished blood flow velocities (especially EDV) in the PCAs of the affected eye (both nasal and temporal), compared to the unaffected eye, are noted (Figure 7 A., B., C., D.). An increased RI in the PCAs is noted (the RI is higher on the clinically affected eye as compared to the unaffected eye) (Figure 7 A., B., C., D.).



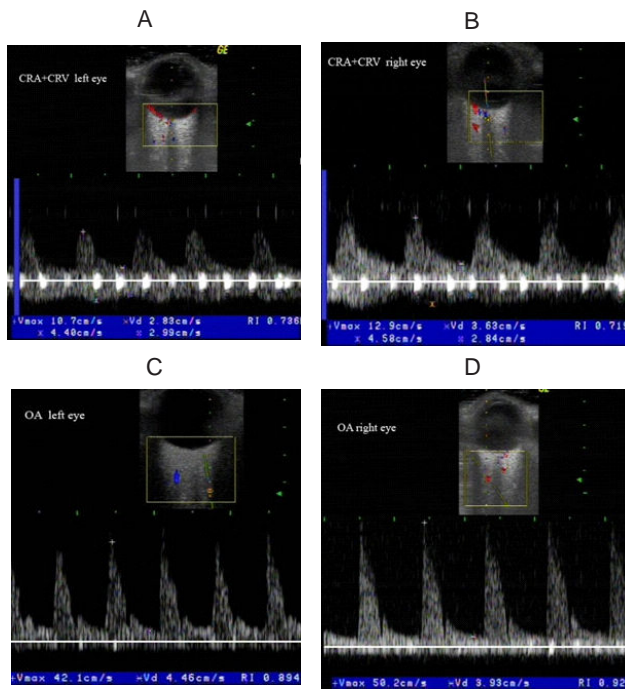
**Figure 7.** A. B. Patient TL with arteritic-anterior ischemic optic neuropathy – Color Doppler Imaging of temporal posterior ciliary arteries (PCAs) of both eyes. Diminution of blood flow velocities (especially end-diastolic velocities) in the temporal PCA of the affected left eye, compared to the other side. C. D. Patient TL with arteritic-anterior ischemic optic neuropathy – Color Doppler Imaging of nasal posterior ciliary arteries (PCAs) of both eyes. Diminution of blood flow velocities (especially end-diastolic velocities) in the nasal PCA of the affected left eye, compared to the other side.

Fewer abnormalities are observed in the CRAs: high RI are measured in both sides, with decreased PSV in the CRA of the clinically affected eye (Figure 8 A., B.).

Similar abnormalities are noted in the OAs: high RI are measured in both sides (Figure 8 C., D.).

At one month, after treatment with high-dose corticosteroids, CDI examinations of orbital blood vessels reveal that blood flow normalization is slow in all A-AION patients.

In conclusion, the Spectral Doppler Analysis of the orbital vessels in A-AION indicates (after a few days of treatment with corticosteroids) low blood velocities, especially EDV, and high RI in all retrobulbar vessels, in both orbits. These signs represent characteristic features of the CDI of the orbital vessels in A-AION.

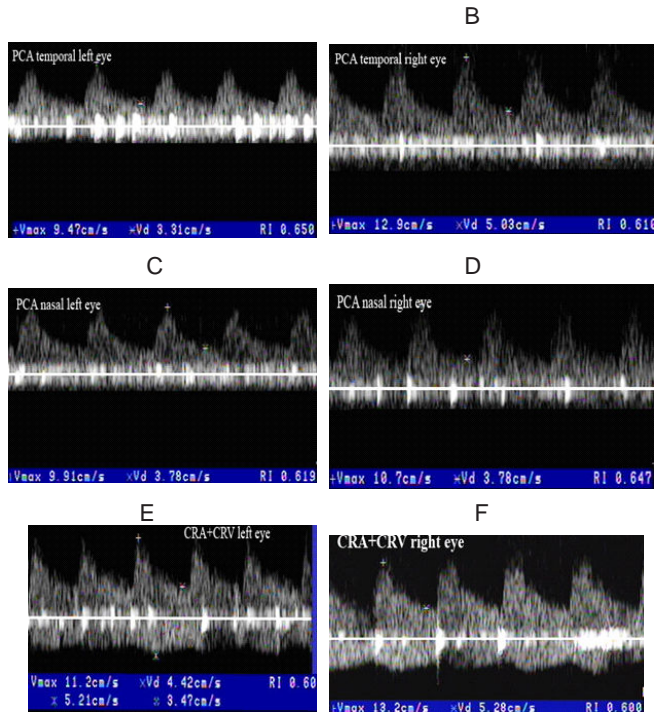


**Figure 8.** A. B. Patient TL with arteritic-anterior ischemic optic neuropathy - Color Doppler Imaging of central retinal arteries of both eyes. High RI in both sides. C. D. Patient TL with arteritic-anterior ischemic optic neuropathy - Color Doppler Imaging of ophthalmic arteries of both eyes. High RI in both sides.

#### 4.13.2. Spectral Doppler analysis of the retrobulbar vessels in NA-AION

In contrast, the patients with NA-AION present the following aspects in acute stage, and at one week of evolution:

- a. slight decrease of PSV in PCAs (nasal and temporal) in the affected eye, compared to the unaffected eye (Figure 9 A., B., C., D.);
- b. slight decrease of PSV in CRA of the affected eye, due to papillary edema (Figure 9 E., F.);
- c. in OAs, PSV are variable: normal to decreased, according to ipsilateral ICAs status. Severe ICA stenosis (>70% of vessel diameter)/occlusion combined with an insufficient Willis polygon led to decreased PSV in ipsilateral OA.



**Figure 9.** A. B. Patient AN with nonarteritic-anterior ischemic optic neuropathy - Color Doppler Imaging of temporal posterior ciliary arteries (PCAs) of both eyes. Slight diminution of systolic blood flow velocities in temporal PCA in the affected left eye, compared to the normal side. C.D. Patient AN with nonarteritic-anterior ischemic optic neuropathy - Color Doppler Imaging of nasal posterior ciliary arteries (PCAs) of both eyes. Slight diminution of systolic blood flow velocities in nasal PCA in the affected left eye, compared to the normal side. E. F. Patient AN with nonarteritic-anterior ischemic optic neuropathy - Color Doppler Imaging of central retinal arteries of both eyes. Slight diminution of systolic blood flow velocities in CRA of affected left eye, due to papillary edema.

At one month, CDI examinations of orbital blood vessels reveal that blood flow normalization is reached. The exceptions are the cases with severe ipsilateral ICA stenosis/occlusion.

Consequently, in NA-AION, blood velocities and RI in PCAs are preserved. Similar results were obtained in other studies [24-26].



CDI of retrobulbar vessels and fluorescein fundus angiography data support the histopathological evidence of involvement of the entire PCA trunk in A-AION (impaired both ONH and choroidal perfusion in these patients) [12, 24, 25].

In contrast, in NA-AION cases, affected flow to the ONH is distal to the PCA trunk, possibly at the level of the paraoptic branches. These branches directly supply the ONH with only one-third of the flow of the PCAs (impaired optic disc perfusion, with relatively preserved choroidal perfusion in NA-AION patients) [12, 16, 23].

CDI of retrobulbar vessels sustains the involvement of the entire PCA trunk in A-AION in a non-invasive manner and in real time and may rapidly point to an A-AION diagnosis. While CDI of orbital vessels does not eliminate the need for fluorescein fundus angiography, hematologic assessment, carotid US, and echocardiography, it does however enhance the precision of the diagnostic evaluation for patients, because it accurately, reproducibly, and safely assesses the vascular supply of the ONH.

There are certain cases where the differential diagnosis between arteritic and nonarteritic AION is difficult: GCA without systemic/clinical symptoms, even a swollen TA, GCA with a normal ESR, and patients with NA-AION that have high ESR levels due to a neoplasm association. When CDI detects a NA-AION, the patient does not have to be subjected to high-dose corticosteroids until a TAB is performed even if the ESR is elevated. Conversely, patients with clinical evidence of A-AION, who have typical signs on CDI of retrobulbar vessels, should be treated before TAB in order to protect the fellow eye from going blind [16].

In our opinion, the results from CDI of retrobulbar vessels and extracranial duplex US (especially of TAs) can substitute the TAB, which is more inconvenient for the patient, more expensive and has up to 40% false negative error data, because of skip lesions [14].

## 5. Conclusions

A history of amaurosis fugax before an abrupt, painless, and severe loss of vision of the involved eye, with concomitant diffuse pale optic disc edema is extremely suggestive of A-AION. None of these symptoms are found in NA-AION patients.

Because findings of TAs US does not correlate with eye complications in A-AION patients, CDI of the retrobulbar vessels is of critical importance. It allows the detection and monitoring of alterations in orbital blood flow, especially of the PCAs, which correspond with the clinical features of A-AION.

Patients with clinical evidence of A-AION, who have typical signs on CDI of retrobulbar vessels, should be treated before TAB, with corticosteroids to protect against blindness of the fellow eye.

Although none of all presented criteria is individually infallible and present in one hundred percent of AION cases, the collective information provided by the various parameters is extremely helpful in diagnosis of A-AION or NA-AION.

## Author details

Dragos Catalin Jianu<sup>1\*</sup> and Silviana Nina Jianu<sup>2</sup>

\*Address all correspondence to: dcjianu@yahoo.com

1 University of Medicine and Pharmacy “Victor Babes”, County Emergency Hospital Department of Neurology, Timisoara, Romania

2 Military Emergency Hospital Department of Ophthalmology, Timisoara, Romania

## References

- [1] Hayreh, S S. Ischaemic optic neuropathy. *Indian J. Ophthalmol.* (2000). , 48, 171-194.
- [2] Hayreh, S S. Management of ischemic optic neuropathies. *Indian J. Ophthalmol.* (2011). , 59(2), 123-136.
- [3] Levine, S. M, & Hellmann, D. B. Giant cell arteritis. *Curr. Opin. Rheumatol.* (2002). , 14, 3-10.
- [4] Martínez-Valle, F, Solans-Laqué, R, Bosch-Gil, J, et al. Aortic involvement in giant cell arteritis. *Autoimmun. Rev.* (2010). , 9, 521-524.
- [5] Hunder, G. G, et al. The American College of Rheumatology criteria for the classification of giant cell arteritis. *Arteritis Rheum.* (1990). , 33, 1122-28.
- [6] Gonzalez-Gay, M. A, Garcia-Porrúa, C, Llorca, J, Hajeer, A. H, Branas, F, Dababneh, A, et al. Visual manifestations of giant cell arteritis: trends and clinical spectrum in 161 patients. *Medicine (Baltimore)* (2000). , 79, 283-92.
- [7] Lieb WE Jr., Cohen SM., Merton DA., et al. Color Doppler imaging of the eye and orbit: Technique and normal vascular anatomy. *Arch. Ophthalmol.*(1991). , 09, 527-531.
- [8] Pichot, O, Gonzalez, B, Franco, A, & Mouillon, M. Color Doppler ultrasonography in the study of orbital and ocular vascular diseases. *J Fr Ophthalmol.*(1996). , 19(1), 19-31.
- [9] Ghanchi, F. D, Williamson, T. H, Liam, C. S, Butt, Z, Baxter, G. M, Mckillop, G, & Brien, O. C. Color Doppler imaging in giant cell (temporal) arteritis: serial examination and comparison with non-arteritic anterior ischaemic optic neuropathy. *Eye* (1996). , 10(4), 459-64.
- [10] Schmidt, W. A, Kraft, H. E, Vorpahl, K, et al. Color duplex ultrasonography in the diagnosis of temporal arteritis. *N. Engl. J. Med.* (1997). , 337, 1336-1342.

- [11] Taylor-Gjevre, R, Vo, M, Shukla, D, & Resch, L. Temporal artery biopsy for giant cell arteritis, *J. Rheumatol.* (2005). , 32, 1279-1282.
- [12] Arnold, A. C. Ischemic optic neuropathy. In: Ianoff M., Duker JS. (ed.), *Ophthalmology*, second edition: Mosby; (2004). , 1268-1272.
- [13] Gonzalez-Gay, M. The diagnosis and management of patients with giant cell arteritis. *J. Rheumatol.* (2005). , 32, 1186-1188.
- [14] Schmidt, W. A. Takayasu and temporal arteritis. In: Baumgartner RW. (ed.) *Handbook on Neurovascular Ultrasound*. Front. Neurol. Neurosci. Basel. Karger; (2006). , 96-104.
- [15] Pipitone, N, Versari, A, & Salvarani, C. Role of imaging studies in the diagnosis and follow-up of large-vessel vasculitis: an update. *Rheumatology (Oxford)* (2008). , 47, 403-408.
- [16] Jianu, D. C, Jianu, S. N, Petrica, L, & Serpe, M. Large giant cell arteritis with eye involvement. In Amezcua-Guerra. (ed.), *Advances in the diagnosis and treatment of vasculitis*, Rijeka: InTech; (2011). , 311-330.
- [17] Salvarani, C, Cantini, F, & Hunder, G. G. Polymyalgia rheumatica and giant-cell arteritis, *Lancet* (2008). , 372, 234-245.
- [18] Lopez-Diaz, M. J, Llorca, J, Gonzalez-Juanatey, C, et al. The erythrocyte sedimentation rate is associated with the development of visual complications in biopsy-proven giant cell arteritis, *Semin. Arthritis Rheum.* (2008). , 38, 116-123.
- [19] Foroozan, R, Deramo, V. A, Buono, L. M, et al. Recovery of visual function in patients with biopsy-proven giant cell arteritis. *Ophthalmology* (2003). , 110, 539-542.
- [20] Breuer, G. S, Neshet, R, & Neshet, G. Effect of biopsy length on the rate of positive temporal artery biopsies. *Clin. Exp. Rheumatol.* (2009). Suppl 52):SS13., 10.
- [21] Gonzalez-Gay, M. A, Garcia-Porrúa, C, Llorca, J, Gonzalez-Louzao, C, & Rodriguez-Ledo, P. Biopsy-negative giant cell arteritis: clinical spectrum and predictive factors for positive temporal artery biopsy. *Semin. Arthritis Rheum.* (2001). , 30, 249-56.
- [22] Arida, A, Kyprianou, M, Kanakis, M, & Sfikakis, P. P. The diagnostic value of ultrasonography-derived edema of the temporal artery wall in giant cell arteritis: a second meta-analysis. *BMC Musculoskelet. Disord.* (2010).
- [23] Collignon-Robe, N. J, Feke, G. T, & Rizzo, J. F. Optic nerve head circulation in nonarteritic anterior ischemic optic neuropathy and optic neuritis. *Ophthalmology*, (2004). , 111, 1663-72.
- [24] Jianu, D. C, & Jianu, S. N. The role of Color Doppler Imaging in the study of optic neuropathies. In: Jianu DC., Jianu SN. (ed.) *Color Doppler Imaging. Neuro-ophthalmological correlations*, Timisoara: Mirton; (2010). , 125-142.

- [25] Jianu, D. C, Jianu, S. N, & Petrica, L. Color Doppler Imaging of retrobulbar vessels findings in large giant cell arteritis with eye involvement. *Journal of US-China Medical Science* (2011). , 8(2), 99-108.
- [26] Tranquart, F, Aubert-urena, A. S, Arsene, S, Audrierie, C, Rossazza, C, & Pourcelot, L. Echo- Doppler couleur des arteres ciliaires posterieures dans la neuropathie optique ischemique anterieure aigue, *J.E.M.U.*, (1997). , 18(1), 68-71.