

---

# Non-Invasive Evaluation of Liver Steatosis, Fibrosis and Cirrhosis in Hepatitis C Virus Infected Patients Using Unidimensional Transient Elastography (Fibroscan®)

---

Monica Lupsor, Horia Stefanescu, Diana Feier and Radu Badea

Additional information is available at the end of the chapter

<http://dx.doi.org/10.5772/52621>

---

## 1. Introduction

### 1.1. The importance of non-invasive evaluation of liver steatosis and fibrosis in virus C infected patients

Chronic conditions of the liver represent an important public health issue. Whatever the nature of the aggression against the liver, it seems that it always follows the same pattern: inflammation -> necrosis -> healing (fibrosis) -> regeneration (cirrhosis) -> dysplasia -> hepatocellular carcinoma. An important link in this course of events is represented by fibrogenesis. On the other hand, there are more and more evidence that, in patients with chronic hepatitis C, steatosis is a risk factor independently associated with necroinflammatory activity and fibrosis progression.

At the moment, the gold standard in the evaluation of both liver fibrosis and steatosis is represented by liver biopsy (LB), an invasive method with possible side effects. As a result, most of the research done worldwide is focused towards developing other alternative, non-invasive diagnosis methods, that would be capable to evaluate fibrosis and steatosis as accurately as possible.

Therefore, the following pages will present an evaluation of unidimensional transient elastography (TE) performance in the assessment of liver fibrosis and steatosis in patients suffering from chronic viral hepatitis type C (HCV).

## 2. Liver biopsy – An imperfect gold standard

Liver biopsy was performed by P Ehrlich in 1883 and became a common exploration method in 1958, when G Menghini introduced the first biopsy technique with a needle that was named after him [1].

*Liver biopsy provides a lot of information [2-6]:*

- it represents the gold standard for a positive and differential diagnosis of diffuse liver diseases;
- provides important etiology data;
- allows for the evaluation of the necroinflammatory activity, evolutive stage (fibrosis) and confirms if cirrhosis is present or not;
- helps establish the prognosis;
- identifies concomitant morphological alterations that may influence therapy response and its evaluation (steatosis, iron overload, etc);
- it can determine treatment efficiency.

At the same time, one can not ignore the fact that liver biopsy has significant limitations: possible complications, including mortality; important sampling errors; high cost; subjective appreciations that may be due to important intra and interobserver variations.

Biopsy complications may vary in magnitude and frequency depending on the subjacent liver pathology. Among these can be listed: pain (epigastric area, right shoulder, right hypochondrium); vagal response; hemorrhagic accidents (hemoperitoneum, hemobilia, liver hematoma); bile peritonitis, bilioma; bacteremia; infections and abscesses; pneumothorax and/or pleural reactions; hemothorax; arteriovenous fistula; subcutaneous emphysema; adverse reactions caused by the anesthetic; breaking of the biopsy needle; penetration of other organs: lung, kidney, colon. The mortality associated with this technique is low, but it is possible in 0.0088-0.3% of the cases [7-11].

The most significant problem encountered when interpreting a biopsy is represented by sampling error. Considering the fact that the tissue sample obtained through liver biopsy represents approximately 1/50.000-1/100.000 of the liver volume, it can be inadequate for the diagnosis of diffuse liver conditions, as the histopathological changes may be spread unevenly [5]. Even though liver biopsy is considered the standard exploration in the evaluation of liver diseases, it has an accuracy of only 80% in staging fibrosis and it can miss cirrhosis in 30% of the cases [12]. For example, Ragev reported that in HCV patients, there is a discrepancy of at least 1 stage between the right and left lobe in 33% of the patients [13]. At the same time, Siddique observed that a difference of at least one stage between 2 samples (15 mm long) cut from the same area occurs in 45% of the cases [14].

Considering all these observations, the results of the studies performed to validate a non-invasive diagnosis method must be interpreted with caution, since they are compared with an imperfect „gold standard“.

Because of the limitations and invasive nature of liver biopsy, other non-invasive means are being tested for the evaluation of diffuse hepatopathies, and implicitly of fibrosis and steatosis as major prognosis factors in the evolution of the hepatopathy. Therefore, there is interest in developing other methods, either serological or imaging, which are all non-invasive, in order to determine the presence and degree of fibrosis, as well as of steatosis. One of these methods is unidimensional transient elastography (Fibroscan).

### 3. The principle of unidimensional transient elastography

The device consists of a special transducer, that is placed in the axis of a mechanical vibrator. The vibrator generates pain-free vibrations that produce a train of elastic waves that will be transmitted through the skin and subcutaneous tissue to the liver. At the same time with activating the vibration, the probe performs a number of ultrasound acquisitions (the same process of emission-reception used in conventional ultrasonography), with a frequency of 4 kHz. Reports on the tissues deformation caused by elastic wave transmission can be formulated by comparing the successive ultrasound (US) signals acquired in this manner. The time necessary for the train of waves to propagate along the area of interest, as well as propagation velocities are being measured. This way liver stiffness can be determined using the following formula:  $E = 3\rho V_s^2$  ( $E$  – elasticity module,  $\rho$  – density, a constant of the material;  $V_s$  – propagation velocity within the liver parenchyma). The more rigid the material, the higher the velocity of propagation [15-17].

During the examination, the patient is lying down, face-up, with his right arm placed in hyperextension and above the head for an adequate exposure of his right hypocondrium. The probe is placed in contact with the patient's skin, at the level of an intercostal space, in an area of full liver dullness and avoiding any large vessels.

When the button on the probe is pushed, the vibration that will be transmitted through the liver is activated. By analyzing tissue deformation report, the software of the equipment will measure the liver stiffness (LS). The results are given in kiloPascals (kPa) and correspond to a median value of 10 valid measurements. The machine can determine values between 2.5 and 75 kPa.

The monitor of the machine will display data regarding the patient's identity, diagnosis, name of the examining physician, the instantaneous value of liver stiffness (CS), the median stiffness resulted from 10 valid measurements, the success rate (SR), as well as the variation of the 10 values compared with the median value (IQR).

To be in agreement with the recommendations of the producer, the success rate must be at least 60% and IQR must not exceed 30% of the median liver stiffness [16], even though it seems that the best concordance with liver biopsy is obtained when this value does not exceed 20% of the median [18].

There are no studies that especially focus on the issue of the variability of LS measurements and therefore the interpretation of the results is done according to the experience of the ex-

aminer and the recommendations of the producer [19]. It is not known whether this variability is encountered only in the diseased liver or whether it is present in the healthy liver as well and to what degree this affects the interpretation of the results. The cause of this problem can be an inadequate technique or the liver pathology itself (for example, in macronodular cirrhosis, liver stiffness can be different in different areas of the liver). When there is a high variability of the results, it is important to check whether the probe is placed perfectly perpendicular on the thoracic wall, if the transmitted vibration does not encounter the ribs and if the waves are transmitted vertically, strictly between the ribs. If the generated wave is large, bifid or angulated, than the software of the machine will reconstruct the velocity curve in different points of the wave and therefore lead to variations of the acquired values. In order to obtain an accurate elastogram the transducer must be placed in the middle area of the right lobe, avoiding contact with the ribs that may lead to vibration distortion and absorption [19].

The technique measures the stiffness of a volume that is equivalent with that of a cylinder of 1 cm in diameter and 4 cm in length (the measurement can be performed on a distance of 25 to 45 cm from the skin). This volume, representing about 1/500 of the liver volume, is at least a 100 times larger than the one obtained through liver biopsy and it is therefore more representative for the whole liver parenchyma [20, 21].

The examination can be performed by a technician following a short period of training (approximately 100 cases) [22-23], while the clinical interpretation of the results must always be done by an expert who would consider the demographic data, the etiology of the disease and the biochemical profile of the patient at the moment of the examination [21].

A multivariate analysis of the relationship between liver stiffness and fibrosis, necroinflammatory activity and steatosis showed, in some studies, that there is a significant correlation with fibrosis, but no correlation with necroinflammatory activity and steatosis [16, 24]. Nevertheless, the authors of the initial concept acknowledged, following *in vitro* studies, that it is unlikely that a single physical parameter (liver stiffness) would describe entirely a complex biological system in which fibrosis is only a part [15].

A prospective assessment of the role of the histopathological parameters seen in LB in explaining the variance of liver stiffness was performed on 345 chronic hepatitis C patients that all underwent liver biopsy [25]. First, LS correlated highly with the degree of fibrosis assessed by liver biopsy, but we also found a weak correlation with hepatic iron deposition and steatosis and a mild correlation with activity. In multiple regression analysis, fibrosis, activity, and steatosis independently influenced LSM. Iron deposition does not seem to influence the liver stiffness in CHC patients. Fibrosis, activity, and steatosis together explained 62.4% of the variance of the LS. The three significant parameters uniquely explained 45.95% of the amount of LS, with fibrosis making the most unique contribution (44.49%); the difference of 16.25% (62.4%-45.95%) was accounted for by the joint contribution of the three parameters. The size and the direction of the relationships suggest that higher LS values are obtained for patients with advanced fibrosis, increased necroinflammatory activity and increased steatosis. Among these three, however, the stage of fibrosis is the single most important predictor, as suggested by the squared partial correlation [25].

The prediction model computed from this study [25] can be expressed as follows:

Liver stiffness (log-transformed) =  $0.493 + 0.180 \times \text{fibrosis stage} + 0.034 \times \text{steatosis} + 0.033 \times \text{activity grade}$ .

Therefore, our studies showed that fibrosis is indeed the main predictor of liver stiffness, but the activity and steatosis cannot be neglected, and may explain the LS variability within the same fibrosis stage.

## 4. Performance of TE for the noninvasive evaluation of liver fibrosis HCV patients

The first condition that benefited from unidimensional transient elastography was chronic hepatitis type C [21, 26].

### 4.1. The diagnosis of liver fibrosis stages

Studies performed on a large number of HCV patients indicate that the LS value is highly correlated with the stage of fibrosis. The practical utility of the method is based on establishing cutoff values for each stage of fibrosis. A diagnosis of stage  $F \geq 2$ ,  $F \geq 3$  and F4 (cirrhosis) is based on measurements of liver stiffness that vary, according to some studies, from 6.2 to 8.8 Kpa, 7.7 to 10.8 kPa and from 11 to 14.8 kPa (Table 1) [24, 26-30].

There are some meta-analyses addressing the issue of diagnosis performance of TE. Fifty studies were included in the analysis performed by Friedrich Rust et al. The mean AUROC for the diagnosis of significant fibrosis, severe fibrosis, and cirrhosis were 0.84, 0.89 and 0.94, respectively [31]. In Stebbing's meta-analysis, a total of 22 studies were selected, comprising 4430 patients, most of them suffering from a virus C liver infection. The pooled estimates for significant fibrosis ( $\geq F2$ ) measured 7.71 kPa (LSM cutoff value) with a sensitivity of 71.9% and a specificity of 82.4%, whereas for cirrhosis (F4) the results showed a cutoff of 15.08 kPa with a sensitivity of 84.45% and a specificity of 94.69% [32].

It must be underlined that, in spite of the very good areas under the ROC curves, overlaps of the stiffness values were registered in adjacent stages, especially for early fibrosis [33]. The increase of liver stiffness is higher between stage F2 (6.6 kPa) and F3 (10.3 kPa) of fibrosis than between F1 (5.5 kPa) and F2 (6.6 kPa), a fact that is in agreement with the morphological data according to which the increase in fibrotic tissue is more significant from F2 to F3 than from F1 to F2 [12].

The diagnosis accuracy of TE is much better in predicting cirrhosis. In Friedrich-Rust meta-analysis [31], the AUROC mean for the diagnosis of cirrhosis was 0.94 and the performance estimated by Talwalkar [34] was also very good: sensitivity 87%, specificity 91%, positive probability rate 11.7, and negative probability rate 0.14 (95% CI 0.10-0.20).

Fibrosis Stage	Author	Cutoff (kPa)	Se(%)	Sp(%)	PPV(%)	NPV(%)	+LR	-LR	AUROC
F <sub>≥1</sub>	Ziol [24]	-	-	-	-	-	-	-	-
	Castera [26]	-	-	-	-	-	-	-	-
	Sporea [27]	-	-	-	-	-	-	-	-
	Nitta [28]	-	-	-	-	-	-	-	-
	Arena [29]	-	-	-	-	-	-	-	-
	Kim SU [30]	-	-	-	-	-	-	-	-
F <sub>≥2</sub>	Ziol [24]	8.8	56	91	56	88	0.63	0.48	0.79
	Castera [26]	7.1	67	89	48	95	6.09	0.37	0.83
	Sporea [27]	6.8	59.6	93.3	98	30.1	-	-	0.773
	Nitta [28]	7.1	82.8	80.3	86	73.6	4.1	-	0.88
	Arena [29]	7.8	83	82	83	79	4.58	0.20	0.91
	Kim SU [30]	6.2	76	97.5	97.4	80	30.4	0.3	0.909
F <sub>≥3</sub>	Ziol [24]	9.6	86	85	93	71	5.76	0.16	0.91
	Castera [26]	9.5	73	91	81	87	8.11	0.29	0.90
	Sporea [27]	-	-	-	-	-	-	-	-
	Nitta [28]	9.6	87.7	82.4	72.5	92.7	5	-	0.90
	Arena [29]	10.8	91	94	92	73	11.27	0.07	0.99
	Kim SU [30]	7.7	100	95.7	87.5	100	0	23.3	0.993
F <sub>4</sub>	Ziol [24]	14.6	86	96	97	78	23.05	0.14	0.97
	Castera [26]	12.5	87	91	95	77	9.66	0.14	0.95
	Sporea [27]	-	-	-	-	-	-	-	-
	Nitta [28]	11.6	91.7	78	41.5	98.2	4.2	-	0.90
	Arena [29]	14.8	94	92	73	98	11.27	0.07	0.98
	Kim SU [30]	11	77.8	93.9	58.3	97.5	12.8	0.2	0.970

**Table 1.** Liver stiffness cutoff values for staging liver fibrosis using TE in HCV patients. Sensibility (Se), specificity (Sp), positive predictive value (PPV) and negative predictive value (NPV) for each fibrosis stage (using Metavir scoring system).

But it must not be forgotten that the cutoff values for predicting the stages of fibrosis were chosen using the ROC curves in such a way that the sum of sensitivity and specificity is maximum. The country where the study was performed was among the factors that influenced the diagnosis performance of TE [31]. Therefore, even though the cutoff values de-

fined for a certain population may be relevant, they may not be applicable in another population where the incidence of fibrosis is different. Because of this, it is indicated that each centre establishes its own cutoff values, in agreement with the prevalence of fibrosis stages in that particular population, and calculates the performance of the method in relation with those cutoff values. According to our experience on a number of 1138 HCV patients that underwent liver biopsy, the predictive cutoff values for stages F1, F2, F3 and F4 are: 5.1kPa, 7.5kPa, 9.1kPa and 13,2kPa, with an AUROC of 0.836, 0.826, 0.933 and 0.973, and diagnosis accuracy between 77 and 92.8% [35]. In table 2 are presented the liver stiffness cutoff values that predict each stage of fibrosis for the Romanian patients suffering from viral C chronic hepatitis. The table also presents the sensitivity (Se), specificity (Sp), positive predictive value (PPV) and negative predicting value (NPV), false positive (FPR) and false negative rate (FNR) the area under the ROC curve (AUROC) as well as the diagnosis accuracy (DA) of these cutoff values. In our study, the adjusted AUROC according to the prevalence of each individual stage of fibrosis did not significantly differ from the observed ones (0.847 for  $F \geq 1$ ,  $p=1.00$ ; 0.893 for  $F \geq 2$ ,  $p=0.06$ ; 0.945 for  $F \geq 3$ ,  $p=0.34$ ; 0.983 for F4,  $p=0.312$ ), therefore the cutoff values that we obtained may have a large applicability.

## 4.2. Monitoring disease progression

### 4.2.1. Diagnosis of liver cirrhosis. Prediction of portal hypertension and related complications

TE has a very good diagnosis accuracy in predicting cirrhosis (stage F4 Metavir), with areas under ROC varying from 0.90 to 0.99 and cutoff values between 9-26.6 kPa [31], but there is a high interest to determine whether the use of the machine's entire specter of measurements (up to 75 kPa) can predict the clinical events characteristic to the evolution of cirrhosis. Some authors [36] indicated, with a negative predictive value of over 90%, that the suggestive values for predicting the presence of various complications are: 27.5 kPa for large esophageal varices; 37.5 kPa for Child B and C cirrhosis; 49.1 kPa for ascites; 53.7 kPa for hepatocarcinoma and 62.7 kPa for bleeding esophageal varices.

Portal hypertension is the main characteristic of liver cirrhosis, and the hepatic venous portal gradient (HVPG) is the best surrogate marker to assess its presence.

A positive strong correlation between liver stiffness and HVPG was reported in HCV patients [37] and, afterwards, independently confirmed in another group of patients with severe fibrosis (Metavir F3-F4) [38]. The correlation was excellent for HVPG values lower than 10 or 12 mm Hg, but the linear regression analysis did not reveal exceptional results for HVPG values  $>10$  mm Hg or  $>12$  mm Hg. This means that, even though TU may detect a progressive elevation of the portal pressure, mainly because of an increase in intrahepatic vascular resistance caused by the accumulation of extracellular fibrillar matrix, this method can not entirely determine the extremely complex hemodynamic alterations that characterize the delayed phase of portal hypertension [39]. As a result, some authors believe it is unlikely that elastography can be useful in monitoring the hemodynamic therapeutic response, as the effect of the treatment is mainly mediated by the splanchnic circulatory changes [40].

	≥ F1; F0vsF1234	≥ F2; F01vsF234	≥ F3; F012vsF34	F4; F0123vsF4
Liver stiffness cutoff				
value (kPa)	5.1	7.5	9.1	13.2
Se (%)	85.09	74.27	86.99	93.59
Sp (%)	65.45	82.95	88.51	92.71
+LR	2.46	4.36	7.57	12.84
-LR	0.23	0.31	0.15	0.07
PPV (%)	97.9	88.8	83.2	83.4
NPV (%)	18.7	63.9	91.2	97.4
FPR (%)	36.36	17.30	12.23	7.41
FNR (%)	13.86	25.59	12.55	6.41
Diagnosis accuracy (%)	85.01	77.34	87.63	92.87
Observed AUROC	0.836	0.860	0.933	0.973
Adjusted AUROC				
according to the prevalence of the fibrosis stages	0.847	0.893	0.945	0.983
$p$ (difference between obs vs adj AUROC)				
	1.00	0.06	0.34	0.312

**Table 2.** Diagnostic performance of different cutoff values of liver stiffness in staging liver fibrosis in HCV Romanian patients [35].

Regarding the relationship between liver stiffness and the presence of esophageal varices, the area under the ROC curve for predicting the presence of varices varied between 0.76 and 0.84 [38, 41, 42]. Using cutoff values of 13.9 kPa, 17.6 kPa and 21.3 kPa, the sensitivity for varices prediction was high (95%, 90% and 79%), but the specificity was relatively low (43%, 43% and 70%) [38, 41, 42]. There are studies that demonstrated a relationship between the value of liver stiffness and the size of the varices [41, 42, 43], while other studies were not able to demonstrate this correlation [38]. Using cutoff values of 19 and 30.5 kPa, the sensitivity of TE for varices prediction was higher, but the specificity and the positive predictive value were modest [41, 42]. TE did not provide better results than the serological markers (like prothrombin time, thrombocytes [44] or FibroTest [45]), neither for varice detection (regardless of their grade), nor for the diagnosis of significant varices [41]. Yet, a predictive role of liver stiffness in anticipating variceal bleeding cannot be excluded [43, 46].

These contradicting results may be caused by the heterogeneity of the studied populations, the variable prevalence of varices (in general, but also of the large ones), the lack of prospective validation (all the cited studies were cross-sectional studies) and the variability of the cutoff values [47]. In conclusion, the evaluation of liver stiffness is not safe enough for the detection and grading of esophageal varices in such a manner that it may replace upper digestive tract endoscopy in patients with cirrhosis, since the specificity and positive predictive value reported until now are too low to allow for a regular use of the method in clinical practice.



The literature data available on this topic are synthesized in table 3

Author	etiology	prev EV	cutoff (kPa)			Se	Sp	VPP	VPN	AUROC
			HVPG	VE	VEM					
Carion[37]	HCV	-	8.7 <sup>a</sup>	-	-	90	81	90	81	0.92
Bureau[43]	toate	-	21 <sup>b</sup>	-	-	90	93	91	90	0.94
Lemoine [48]	HCV	-	20.5 <sup>b</sup>	-	-	63	70	35	88	0.76
	-OH	-	34.9 <sup>b</sup>	-	-	90	88	64	98	0.94
Vizutti [38]	HCV	66%	17.6 <sup>c</sup>	-	-	94	81	91	86	0.92
			-	17.6	-	90	43	66	77	0.76
Kazemi [42]	toate	45%	-	13.9	-	95	43	91	57	0.84
			-	-	19	91	60	95	48	0.83
Castera [41]	HCV	36%	-	21.5	-	76	78	84	68	0.82
			-	-	30.5	77	85	92	54	0.85

HCV = hepatitis C virus; -OH = ethanol; EV = esophageal varices; LEV = large esophageal varices; Se = sensibility; Sp = specificity; P/NPV = positive/negative predictive value; AUROC = area under the ROC curve; HVPG = Hepatic venous pressure gradient (<sup>a</sup> HVPG ≥ 6 mm Hg; <sup>b</sup> HVPG ≥ 10 mm Hg; <sup>c</sup> HVPG ≥ 12 mm Hg).

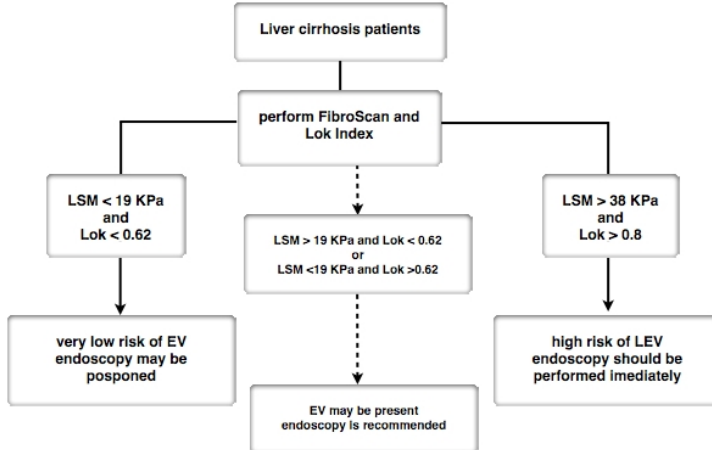
**Table 3.** TE performance in EV diagnosis and HVPG prediction in liver cirrhosis patients.

The huge potential of TE for cirrhosis patients was acknowledged ever since the method was introduced, as it can serve as a fast and non-invasive screening tool in the assessment of actual complications, it can estimate the long term risk and thus place the patient in a certain risk category [49]. The first signs of this possibility were the outcome of a retrospective study which found that the risk of a patient with hepatitis C for developing hepatocellular carcinoma is 5 times higher in patients with a LS value above 25 kPa, at the moment of the diagnosis [50]. Even more, a recent prospective study [51], that evaluated the role of liver stiffness in predicting complications related to portal hypertension in cirrhosis patients, demonstrated that a LS value < 21.1 kPa at diagnosis was as valuable as a HVPG < 12 mmHg in the selection of the patients who will not experiment clinical events.

#### 4.2.2. Optimization of liver stiffness performance in the diagnosis of liver cirrhosis or its complications

Based on the principle enounced by Pinzani et al, which states that a concordance between two distinct noninvasive tests is needed for an accurate diagnosis [52], an association between LS and serum noninvasive tests for liver fibrosis was used to improve the diagnostic accuracy. Such an algorithm was proposed by the Bordeaux group [53] and it is based on the concordance between FibroScan and FibroTest. Using this approach, cirrhosis could be diagnosed with an accuracy of 93% and liver biopsy could be avoided for the diagnosis of cirrhosis in almost 80% of cases.

On the other hand, our group managed to demonstrate that the Lok Score and LS used together as part of a noninvasive algorithm (see figure 1) can improve (78% diagnostic accuracy) the noninvasive estimation of large esophageal varices in cirrhotic patients [54].



**Figure 1.** Proposition for a non-invasive algorithm for the assessment of esophageal varices in patients with liver cirrhosis.

#### 4.2.3. TE efficacy in hepatocellular carcinoma risk assessment

Early detection of hepatocellular carcinoma (HCC) in HCV patients represents an emerging health problem. As a common practice, alpha-fetoprotein (AFP) is widely used for the diagnosis of HCC, despite its low sensitivity and specificity [55]. Tateyama et al report AFP above normal levels as a risk factor for the development of hepatocellular carcinoma in patients infected with hepatitis C virus [56].

Besides AFP, it has been proven that LS values increase as the liver disease progresses, the highest values being specific for cirrhotic patients with associated HCC [36]. The evidence prove that the individual role of increased LS measurements and serological markers are predictive biomarkers of HCC [57, 58]. The first risk evaluation of HCC development in HCV patients using TE was first performed by Foucher et al in 2006, reporting a cut-off value of 53.7 kPa [36]. Also, according to Akima T et al [59] liver stiffness as measured by TE is a good predictor of HCC development in viral hepatitis, with serum total bilirubin  $\geq 1.0$  mg/dL significantly correlated with tumor development. The latest published results report good diagnostic accuracy of LS in HCC prediction, for cut-off values ranging between 12.5 and 53.7 kPa [57,59,60]. However none of these studies have been designed to evaluate the accuracy of more predictive parameters, others than LS. On the other hand, adding biomarkers and other variables (such as variance) to LS measurement could represent confounding factors in the assessment of patients with liver cirrhosis and HCC [61]. This may lead to an over- or under-estimation of the risk assessed by TE, so a new accuracy testing is

needed. Nevertheless, increased LS seems to be a determinant of advanced cirrhosis, being associated with decompensating episodes (high grade esophageal varices, bleeding, development of ascites) as well as with the presence of HCC [62], proving that increased LS alone cannot be a good predictor of HCC.

On the other hand, Japanese studies also suggest that TE could be used as an indicator for the development of hepatocellular carcinoma in patients with virus C hepatitis [58, 63], the risk being 5 times higher in patients with a liver stiffness of over 25 kPa. Yet, these results must be confirmed in prospective studies performed on larger groups of patients, in order to see whether liver stiffness can truly predict complication development in patients with compensated cirrhosis [21]. If this fact is confirmed, elastography may serve as a non-invasive, quick screening modality which could place the cirrhosis patient in a certain risk category [64].

#### *4.2.4. Hepatitis C infection recurrence after liver transplant*

ETU is useful in the appreciation of the severity of hepatitis C recurrence after transplantation, thus reducing the number of liver biopsies [65]. In Carrion's study, for a cutoff value of 8.5 kPa, the sensitivity, specificity, negative predictive value and positive predictive value in anticipating significant fibrosis were 90%, 81%, 79% and 92%. The important thing is that none of the patients with a liver stiffness below that value presented severe fibrosis (F3), cirrhosis (F4) or significant portal hypertension (HVPG  $\geq 10$  mm Hg). Furthermore only 6 (10%) out of the 62 patients, having LS below the established threshold limit value, did develop portal hypertension, but in all cases it was a mild hypertension.

In Rigamonti's study [66], during the follow-up after transplantation, in 40 patients with double biopsies (at 6 and 21 months), the liver stiffness changed in parallel with the stage of fibrosis, having a sensitivity of 86 % and a specificity of 92% in predicting an increase in the stage of fibrosis.

A recently published meta-analysis [67] showed that in patients undergoing transplantation for HCV-related disease, TE appears to be a reliable diagnostic test for the exclusion of liver cirrhosis. Furthermore, low TE values can reliably exclude cirrhosis in patients with recurrent HCV after liver transplantation and liver biopsy may even be avoided in these situations. Among the studies that evaluated significant fibrosis due to a recurrent HCV infection after liver transplantation, the pooled estimates were 83% for sensitivity, 83% for specificity, 4.95 for the positive likelihood ratio, 0.17 for negative likelihood ratio and 30.5 for diagnostic odds ratio. For the studies that assessed cirrhosis, the pooled estimates were 98% for sensitivity, 84% for specificity, 7 for positive likelihood ratio, 0.06 for negative likelihood ratio, and 130 for diagnostic odds ratio [67].

## **5. Confounding factors influencing the interpretation of liver stiffness values**

Since the liver is self-contained in the non extensible Glisson's capsule, stiffness is definitively influenced by pressure that can be either hydrostatic or osmotic [68]. There are a few con-

ditions that may determine false results in situations where other factors, except from fibrosis, are influencing liver stiffness.

*Necroinflammatory activity* proved to influence liver stiffness in patients with viral hepatitis, causing an increase in stiffness in parallel with the grade of histological activity [29, 69, 70]. In agreement with these results, the risk of overestimating the stage of fibrosis may occur in patients with acute hepatitis or reactivated chronic hepatitis, if just the value of liver stiffness is considered. Recent studies demonstrated that tissue alterations associated with acute hepatitis in a patient with no liver disease history produce a significant growth of liver stiffness, sometimes reaching cirrhosis values; this is due either to cellular intumescence or to severe cholestasis [71]. The contribution of these non-fibrotic changes upon liver stiffness was demonstrated by the progressive reduction of liver stiffness parallel with the decrease of the transaminases [72, 73].

On the other hand, in patients with reactivated chronic hepatitis (therefore with preexisting fibrosis), the increased stiffness is not caused by fibrosis alone, but also by the added cellular intumescence [74].

From a practical perspective, it is important that the values of liver stiffness in patients with acute hepatitis or in those with reactivated chronic hepatitis must be interpreted carefully, within the patient's clinical and biochemical context [75]. In these patients, a certain diagnosis of severe fibrosis or cirrhosis cannot be established. The right management in these cases is to wait until the transaminases come back to normal and only when the potential involvement of inflammation is removed, the real status of fibrosis can be determined; it can thus be established whether the event was an acute hepatitis on a diseased liver or a chronic hepatitis with pre-existing fibrosis that was reactivated [76].

At the same time, in patients with acute hepatitis, the evaluation of liver stiffness at various time intervals, can indicate the evolutive pattern of the condition, that may be characterized either by evolution towards fulminant hepatitis (significant increase in LS), or by remission (decrease in LS) [77].

*Liver steatosis.* The influence of steatosis on liver stiffness remains controversial. In some studies, steatosis did not have a significant impact on liver stiffness, even after adjusting for fibrosis stage [16, 24, 28]. Still, in these studies, the proportion of patients with severe steatosis was too low to reliably quantify a possible influence and therefore further studies are necessary to clarify this aspect.

We noticed from our experience that, after performing a stratified analysis of liver stiffness for each stage of fibrosis, for the same grade of necroinflammatory activity (moderate-severe), the presence of steatosis lead to a significant increase in LS from  $5.89 \pm 1.64$  kPa to  $7.15 \pm 2.67$  kPa for those with stage F1 Metavir ( $p=0.004$ ), and from  $7.23 \pm 2.74$  to  $8.55 \pm 4.67$  kPa for those with stage F2 ( $p=0.04$ ) [78]. Besides, our studies have demonstrated that fibrosis is indeed the main predictor of liver stiffness, but activity and steatosis cannot be neglected and may explain the LS variability within the same fibrosis stage [25]. Afterwards, Zioli et al, using computer analysis of the microscopic image on a group of 152 patients, confirmed that steatosis clearly influences liver stiffness independently from fibrosis, an influence that is insignificant in patients with cirrhosis, but important in non-cirrhosis patients [79].

*Extra-hepatic cholestasis.* The impact of extrahepatic cholestasis on liver stiffness was recently demonstrated by Milloning [80] by evaluating cholestasis before endoscopic retrograde cholangiopancreatography as well as 3 and 12 days after the procedure, in a study group of patients with cholestasis caused mainly by a neoplastic invasion of the biliary tree. If initially liver stiffness had values close to cirrhosis values (a mean of 15.2 kPa), after drainage, the LS decreased as low as 7 kPa, in parallel with a decrease in values of bilirubin of 2.8-2.9 mg/dl. In all patients that underwent biliary drainage, the decrease of liver stiffness correlated with that of the bilirubin values, with a mean of decrease of  $1.2 \pm 0.56$  kPa for a reduction of the bilirubin of 1g/dl. The relationship between liver stiffness and cholestasis was afterwards reproduced in the same study on an animal model that underwent ligation of the biliary duct. This resulted in an elevation of liver stiffness from 4.6 kPa to 8.8 kPa in the first 120 minutes after ligation and a decrease in stiffness to 6.1 kPa within the first 30 minutes after decompression. In conclusion, it is indicated that before an interpretation of the stiffness measurements is performed, an eventual extrahepatic cholestasis must be excluded using imaging investigations and lab tests.

*Congestive heart failure* may lead to an increased liver stiffness, with values similar to cirrhosis, because of the elevated blood content of the liver, in 60% of the patients [80-84]. In the context of cardiopulmonary conditions, TE may be relevant for the evaluation of treatment efficacy, as liver stiffness decreases once cardiac compensation is achieved.

## **6. Optimizing the non-invasive diagnosis of portal hypertension using spleen stiffness measurements**

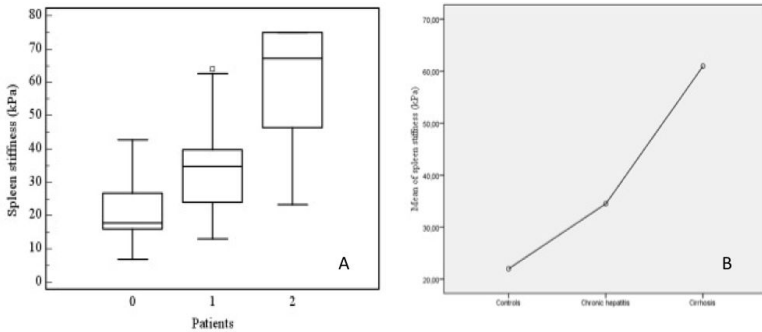
Splenomegaly is a common finding in liver cirrhosis that should determine changes in spleen density as well, because of tissue hyperplasia and fibrosis [85, 86], and/or because of portal and splenic congestion due to the splanchnic hyper-dynamic state [87]. These changes might be quantified by elastography. Until recently, only magnetic resonance elastography (MRE) was used with encouraging results in this respect [88]. The preliminary data showed a highly significant correlation between liver and spleen stiffness in patients with portal hypertension, but, according to the authors, the validity of spleen stiffness as noninvasive measure of portal venous pressure is not reliable enough [89].

### **6.1. Principle of TE for Spleen Stiffness Measurements (SSM) and technique assessment**

Our group proposed for the first time the use of FibroScan® for spleen stiffness measurement (SSM) [90]. For the measurement itself we proposed the same procedure as for the liver stiffness measurement, with the sole exception that the patient had his left arm in maximum abduction and the transducer was placed in the left intercostal spaces, usually on the posterior axillary line. For better locating the splenic parenchyma, we also used ultrasound guidance, so that we could choose the best location for performing the analysis.

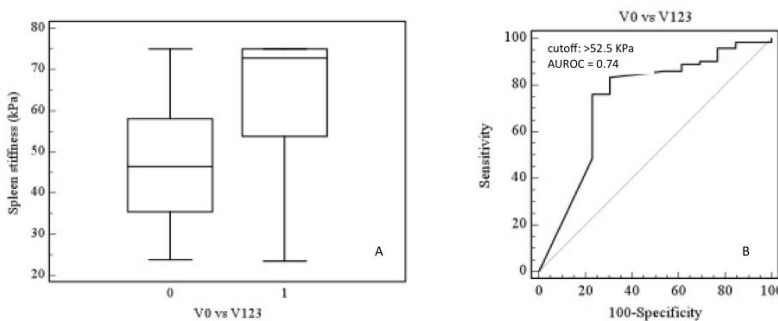
### 6.2. Efficacy of spleen stiffness measurements for the evaluation of the presence and the grade of esophageal varices

In the above mentioned study, we demonstrated that spleen stiffness can be assessed using transient elastography, the sole factor influencing the measurement being the spleen size. Spleen stiffness increases as the liver disease worsens, from normal to chronic hepatitis and to liver cirrhosis (figure 2).



**Figure 2.** A - Box plots of spleen stiffness values for controls (0), chronic hepatitis (1) and cirrhosis patients (2). The top and the bottom of the boxes are the first and third quartiles, respectively. The length of the box thus represents the interquartile range within which 50% of the values were located. The line through the middle of each box represents the median. The error shows the minimum and maximum values (range); B - Graphic representation of the significant increase of SSM in healthy controls and patients with chronic hepatitis and liver cirrhosis, respectively.

In liver cirrhosis patients, the spleen stiffness measurement, can predict the presence, but not the grade of esophageal varices. Therefore, for a cutoff value of 46.4 kPa, we managed to predict the presence of esophageal varices with a diagnostic accuracy of 80.45% and an AU-ROC of 0.781 (figure 3).



**Figure 3.** A - Box plots showing the increase of SSM in liver cirrhosis patients with esophageal varices as compared with those without; B - ROC curve representation of SSM in distinguishing LC patients with or without EV.

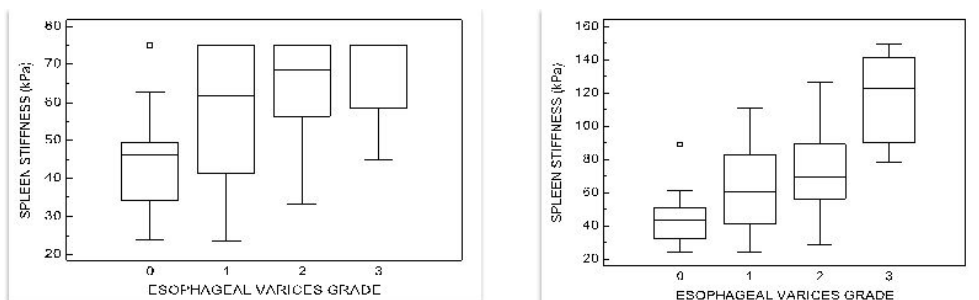
In another more recent study [91], another group demonstrated that SSM also correlates with HVPG values, suggesting that this new elastographic technique may become a valuable noninvasive method for liver cirrhosis patients

### 6.3. Improving diagnostic accuracy for esophageal varices by modifying the SSM calculation algorithm

Regarding the spleen stiffness measurement itself, we observed that the results seem to be influenced by the intrinsic characteristics of the machine (FibroScan). Regardless of the variceal status of the patients, or the grade of the varices, SSM reached the maximum value that can be measured by the machine (75 KPa). This is an important drawback, because we have to face a significant interpolation between the patients groups. If the FibroScan had been able to determine values beyond 75 KPa, we may have obtained better figures. In order to overcome this situation, we cooperated with the manufacturer of the device for developing a new calculation algorithm, not available on the commercial device, which allows stiffness measurements of up to 150 kPa. In a validation study [54], using the new calculation algorithm, we could differentiate between any classes of esophageal varices, except V1 vs V2 ( $p < 0.005$ ) and could select patients with V3 (V012 vs V3 = 63.49 vs 116.08 kPa,  $p < 0.005$ ), the ones that are at higher risk for bleeding (figure 4).

## 7. Noninvasive evaluation of liver steatosis using Controlled Attenuation Parameter (CAP)

Even though liver stiffness provides an alternative to liver biopsy for fibrosis staging, it can identify very important histologic features such as macrovesicular steatosis, ballooned hepatocytes, inflammation, etc [68].



**Figure 4.** Boxplots representing mean SSM values according to the esophageal varices grade using the original (A) or the modified (B) calculation algorithm.

Knowing that fat interferes with ultrasound propagation, a novel attenuation parameter has been developed to detect and quantify liver steatosis. This parameter is based on the ultra-

sonic properties of the radio-frequency back propagated signals acquired by the Fibroscan [92]. It is called controlled attenuation parameter (CAP). This ultrasonic attenuation coefficient is an estimate of the total ultrasonic attenuation (go-and-return path) at the central frequency of the regular or M Fibroscan® probe, i.e. at 3.5 MHz, and is expressed in  $\text{dB}\cdot\text{m}^{-1}$ . CAP is evaluated using the same radio-frequency data and the same region of interest, as the region used to assess the LSM. CAP is only appraised if the acquisition is “valid”. Therefore, CAP is guided by vibration-controlled transient elastography (VCTE), which ensures that the operator automatically obtains an ultrasonic attenuation value of the liver [92, 93]. The device is used to assess, at the same time, LS (which is related to liver fibrosis) and CAP (which is related to liver steatosis).

Even though relatively few studies have been published on this topic [92, 93, 94,95] the preliminary results showed that CAP is a promising non-invasive tool to detect steatosis in CHC patients.

In the study conducted by Sasso et al, the CAP performance was appraised on 115 patients, taking the histological grade of steatosis as reference. CAP was significantly correlated to steatosis with an AUROC equal to 0.91 and 0.95 for the detection of more than 10% and 33% of steatosis, respectively.

A study performed recently on 615 HCV patients, who underwent both Fibroscan (®) and liver biopsy showed in multivariate analysis, that CAP was related to steatosis, independently of fibrosis stage (which was related to LS. The AUROCs of the were 0.80, 0.86 and 0.88 respectively, for predicting a fatty overload of more than 11%, 33%, and 66%, respectively. CAP also exhibited a good ability to differentiate steatosis grades (Obuchowski measure = 0.92) [96].

CAP is evaluated using the same radio-frequency data and the same region of interest, as the region used to assess the liver stiffness for fibrosis quantification. Preliminary studies performed in our department have found significantly different CAP values for different steatosis grades and AUROCs of 0.830 and 0.85 respectively, for the prediction of a hepatic fat content over 33% and 66%, respectively [97].

## 8. The advantages of TE in liver steatosis, fibrosis and cirrhosis diagnosis

Compared with other diagnosis indicators or predictive models based on lab tests, the evaluation of fibrosis using elastography has some important advantages [98,99]:

- It is easy to use; noninvasive; pain-free; does not require anesthesia or hospitalization and is therefore easily accepted by the patient;
- It is quick, the time needed for the examination being very short;
- It is not influenced by concomitant conditions;
- It is operator independent;



- The liver volume used to evaluate fibrosis is 150-400 times higher than the volume obtained through liver biopsy.

As far as the evaluation of liver steatosis is concerned, in comparison to other modalities, CAP is non-invasive, quantitative, non-ionizing, and inexpensive. Furthermore, the procedure is easy to perform, even by an operator who does not have any radiological skills and provides immediate results. The procedure is also machine-independent and does not require corrections to be made for gain, frequency, focusing or beam diffraction, and is also not subject to operator interpretation. In addition, CAP has been shown to efficiently detect steatosis at a level of  $\geq 10\%$ , which is more sensitive than other imaging modalities. Compared to a liver biopsy, CAP is less prone to sampling error as it explores a liver volume  $\sim 100$  times larger [92, 93].

## 9. Limitations of TE

Liver fibrosis can not be evaluated by TE in 5-8 % of the cases. Some of the possible causes for this are listed below [16]:

- obesity (an ultrasound machine may be used in order to find the best window and thus increase the ability to measure liver stiffness in overweight patients);
- a narrow intercostal space;
- ascites (vibrations are not transmitted through fluid);
- the quality of the liver parenchyma and other liver structures;
- large vascular structure present in the acquisition window (may lead to false results).

The failure of TE varies according to different authors from 2.4% to 9.4% [16, 21, 24, 36, 74, 64, 100]. In a study performed on 2114 patients [101], liver stiffness could not be determined in 4.5% of the cases and multivariate analysis showed that the only element associated with measurement failure is a body mass index over 28. Yet, with more experience, one may realize that a thick thoracic wall is more likely to be a limiting factor for a failed measurement than the growth of the body mass index in itself [102].

Technical solutions regarding the design of the probe were investigated lately, in order to overcome these limitations. Recently a new probe became available, that was specially designed for obese patients, with a central frequency of 2.5 MHz (compared with the 5 MHz probe that is usually used), and that is able to determine liver stiffness on a distance of 35-75 mm from the skin (while the normal probe is able to do that on distance of 25 to 45 cm). With the help of this new transducer, it was possible to obtain valid measurements in 49% of the patients with a BMI  $\geq 30$  kg/m<sup>2</sup>, in which the usual probe failed to determine the LS [103].

As far as predicting steatosis in HCV patients is concerned, CAP has further validation in larger populations and by independent teams, since there are rather few studies published

until now. Another important limitation is that CAP cannot be used with measurements taken from the XL probe, which is a novel probe designed to assess liver stiffness in overweight and obese patients [75,76]. Thus, CAP needs to be developed to work with the XL probe.

## 10. Conclusions

The possibility of concomitant assessment of liver fibrosis (using liver stiffness measurement) and of steatosis (using CAP) makes Fibroscan a promising non-invasive tool for assessing and quantifying both fibrosis and steatosis, that may broaden the spectrum of non-invasive methods used for the investigation and follow-up of patients with chronic hepatitis C. But it is important that interpretation of the liver stiffness values be done by an experienced physician and always within the clinical and biochemical context of the patient.

## Acknowledgments

This material is part of the research project no 27020/ 6/ 15.11.2011, entitled “The non-invasive evaluation of fibrosis and steatosis in diffuse liver diseases by unidimensional transient elastography – Fibroscan” from “Iuliu-Hatieganu” University of Medicine and Pharmacy, Cluj-Napoca.

## Author details

Monica Lupsor<sup>1</sup>, Horia Stefanescu<sup>2</sup>, Diana Feier<sup>1</sup> and Radu Badea<sup>1</sup>

\*Address all correspondence to: monica.lupsor@umfcluj.ro

1 Medical Imaging Department, Regional Institute of Gastroenterology and Hepatology Prof Dr Octavian Fodor, “Iuliu Hatieganu” University of Medicine and Pharmacy, Cluj-Napoca, Romania

2 Hepatology Department, Regional Institute of Gastroenterology and Hepatology Prof Dr Octavian Fodor, “Iuliu Hatieganu” University of Medicine and Pharmacy, Cluj-Napoca, Romania

## References

- [1] Menghini G. One-second needle biopsy of the liver. *Gastroenterology* 1958; 35(2): 190-199.

- [2] Maharaj B, Maharaj RJ, Leary WP, et al. Sampling variability and its influence on the diagnostic yield of percutaneous needle biopsy of the liver. *Lancet*. 1986; 1(8480): 523-525.
- [3] Poynard T, Ratziu V, Benmanov Y, Di Martino V, Bedossa P, Opolon P. Fibrosis in patients with chronic hepatitis C: detection and significance. *Semin Liver Dis*. 2000; 20(1): 47-55.
- [4] Desmet VJ. Liver tissue examination. *J Hepatol*. 2003; 39(1): S43-49.
- [5] Guido M, Ruge M. Liver biopsy sampling in chronic viral hepatitis. *Semin Liver Dis*. 2004; 24(1): 89-97.
- [6] Kleiner DE. The liver biopsy in chronic hepatitis C: a view from the other side of the microscope. *Semin Liver Dis*. 2005; 25(1): 52-64.
- [7] Buscarini E, Di Stasi M. Biopsy of the liver. In: Buscarini E, di Stasi M (eds). *Complications of abdominal interventional ultrasound*. Poletto Edizioni 1996, 34-50.
- [8] Nazarian LN, Feld RI, Herrine SK, et al. Safety and efficacy of sonographically guided random core biopsy for diffuse liver disease. *J Ultrasound Med* 2000;19(8): 537-541.
- [9] Farrell R, Smiddy PF, Pilkington RM, et al. Guided versus blind liver biopsy for chronic hepatitis C: clinical benefits and costs. *J Hepatol* 1999; 30: 580-587.
- [10] Schiff ER, Schiff L. Needle biopsy of the liver. In: Schiff ER, Schiff L. *Diseases of the liver* J.B.Lippincott Company, 1993, 216-225.
- [11] McGill DB., Rakela J. A 21-year experience with major hemorrhage after percutaneous liver biopsy. *Gastroenterology* 1990; 99: 1396-1400.
- [12] Bedossa P, Dargere D, Paradis V. Sampling variability of liver fibrosis in chronic hepatitis C. *Hepatology*. 2003; 38(6): 1449-1457.
- [13] Regev A, Berho M, Jeffers LJ, Sampling error and intraobserver variation in liver biopsy in patients with chronic HCV infection. *Am J Gastroenterol*. 2002; 97(10): 2614-2618.
- [14] Siddique I, El-Naga HA, Mada JP, Memon A, Hasan F. Sampling variability on percutaneous liver biopsy in patients with chronic hepatitis C virus infection. *Scand J Gastroenterol*. 2003; 38(4): 427-432.
- [15] Yeh WC, Li PC, Jeng YM, et al. Elastic modulus measurements of human liver and correlation with pathology. *Ultrasound Med Biol*. 2002; 28(4): 467-474.
- [16] Sandrin L, Fourquet B, Hasquenoph JM, et al. Transient elastography: a new noninvasive method for assessment of hepatic fibrosis. *Ultrasound Med Biol*. 2003; 29(12): 1705-1713.
- [17] Carstensen EL, Parker KJ, Lerner RM. Elastography in the management of liver disease. *Ultrasound Med Biol*. 2008; 34(10): 1535-1546.

- [18] Lucidarme D, Foucher J, Le Bail B, et al. Factors of accuracy of transient elastography (Fibroscan) for the diagnosis of liver fibrosis in chronic hepatitis C. *Hepatology*. 2008; 49(4): 1083-1089.
- [19] Del Poggio P, Colombo S. Is transient elastography a useful tool for screening liver disease? *World J Gastroenterol*. 2009; 15(12): 1409-1414.
- [20] Nguyen-Khac E, Capron D. Noninvasive diagnosis of liver fibrosis by ultrasonic transient elastography (Fibroscan). *Eur J Gastroenterol Hepatol*. 2006; 18(12): 1321-1325.
- [21] Castera L, Forns X, Alberti A. Non-invasive evaluation of liver fibrosis using transient elastography. *J Hepatol*. 2008; 48(5): 835-847.
- [22] Kettaneh A, Marcellin P, Douvin C, et al. Features associated with success rate and performance of FibroScan measurements for the diagnosis of cirrhosis in HCV patients: a prospective study of 935 patients. *J Hepatol*. 2007; 46(4): 628-634.
- [23] Boursier J, Konate A, Guilluy M, et al. Learning curve and interobserver reproducibility evaluation of liver stiffness measurement by transient elastography. *Eur J Gastroenterol Hepatol*. 2008; 20(7): 693-701.
- [24] Ziol M, Handra-Luca A, Kettaneh A, et al. Noninvasive assessment of liver fibrosis by measurement of stiffness in patients with chronic hepatitis C. *Hepatology*. 2005; 41(1): 48-54.
- [25] Lupsor M, Badea R, Stefanescu H, et al. Analysis of histopathological changes that influence liver stiffness in chronic hepatitis C. Results from a cohort of 324 patients. *J Gastrointestin Liver Dis*. 2008;17(2):155-63.
- [26] Castera L, Vergniol J, Foucher J, et al. Prospective comparison of transient elastography, Fibrotest, APRI, and liver biopsy for the assessment of fibrosis in chronic hepatitis C. *Gastroenterology*. 2005; 128(2): 343-350.
- [27] Sporea I, Sirli R, Deleanu A, et al. Comparison of the liver stiffness measurement by transient elastography with the liver biopsy. *World J Gastroenterol*. 2008; 14(42): 6513-6517.
- [28] Nitta Y, Kawabe N, Hashimoto S, et al. Liver stiffness measured by transient elastography correlates with fibrosis area in liver biopsy in patients with chronic hepatitis C. *Hepatol Res*. 2009; 39(7): 675-684.
- [29] Arena U, Vizzutti F, Abraldes J, et al. Reliability of transient elastography for the diagnosis of advanced fibrosis in chronic hepatitis C. *Gut*. 2008; 57(9): 1288-1293.
- [30] Kim SU, Jang HW, Cheong JY, et al. The usefulness of liver stiffness measurement using FibroScan in chronic hepatitis C in South Korea: a multicenter, prospective study. *J Gastroenterol Hepatol*. 2011; 26(1): 171-178.

- [31] Friedrich-Rust M, Ong MF, Martens S, et al. Performance of transient elastography for the staging of liver fibrosis: a meta-analysis. *Gastroenterology*. 2008; 134(4): 960-974.
- [32] Stebbing J, Farouk L, Panos G, et al. A meta-analysis of transient elastography for the detection of hepatic fibrosis. *J Clin Gastroenterol*. 2010; 44(3): 214-9.
- [33] Castera L. Assessing liver fibrosis. *Expert Rev Gastroenterol Hepatol*. 2008; 2(4): 541-552.
- [34] Talwalkar JA, Kurtz DM, Schoenleber SJ, West CP, Montori VM. Ultrasound-based transient elastography for the detection of hepatic fibrosis: systematic review and meta-analysis. *Clin Gastroenterol Hepatol*. 2007; 5(10): 1214-1220.
- [35] Lupsor M, Badea R, Stefanescu H, Sparchez Z, Serban A, Feier D. The diagnosis performance of ultrasonic transient elastography for noninvasive assessment of liver fibrosis in 1138 chronic hepatitis C patients. *Ultrasound in Medicine and Biology* 2011; 37 (8S): S81.
- [36] Foucher J, Chanteloup E, Vergniol J, et al. Diagnosis of cirrhosis by transient elastography (FibroScan): a prospective study. *Gut*. 2006; 55(3): 403-408.
- [37] Carrion JA, Navasa M, Bosch J, Bruguera M, Gilibert R, Forns X. Transient elastography for diagnosis of advanced fibrosis and portal hypertension in patients with hepatitis C recurrence after liver transplantation. *Liver Transpl*. 2006; 12(12): 1791-1798.
- [38] Vizzutti F, Arena U, Romanelli RG, et al. Liver stiffness measurement predicts severe portal hypertension in patients with HCV-related cirrhosis. *Hepatology* 2007; 45(5): 1290-1297.
- [39] Lim JK, Groszmann RJ. Transient elastography for diagnosis of portal hypertension in liver cirrhosis: Is there still a role for hepatic venous pressure gradient measurement? *Hepatology* 2007; 45(5): 1087-1090.
- [40] Castera L, Forns X, Alberti A. Non-invasive evaluation of liver fibrosis using transient elastography. *J Hepatol*. 2008; 48(5): 835-847.
- [41] Castera L, Le Bail B, Roudot-Thoraval F, et al. Early detection in routine clinical practice of cirrhosis and oesophageal varices in chronic hepatitis C: Comparison of transient elastography (FibroScan) with standard laboratory tests and non-invasive scores. *J Hepatol* 2009; 50(1): 59-68.
- [42] Kazemi F, Kettaneh A, N'kontchou G, et al. Liver stiffness measurement selects patients with cirrhosis at risk of bearing large oesophageal varices. *J Hepatol*. 2006; 45(2): 230-235.
- [43] Bureau C, Metivier S, Peron JM, et al. Transient elastography accurately predicts presence of significant portal hypertension in patients with chronic liver disease. *Aliment Pharmacol Ther* 2008; 27(12): 1261-1268.

- [44] Sanyal AJ, Fontana RJ, Di Bisceglie AM, et al. The prevalence and risk factors associated with esophageal varices in subjects with hepatitis C and advanced fibrosis. *Gastrointest Endosc.* 2006;64(6): 855-864
- [45] Thabut D, Trabut JB, Massard J et al. Non-invasive diagnosis of large oesophageal varices with FibroTest in patients with cirrhosis: a preliminary retrospective study. *Liver International* 2006; 26(3):271-278
- [46] de Franchis R. Noninvasive diagnosis of esophageal varices: is it feasible? *Am J Gastroenterol* 2006; 101(11): 2520-2522
- [47] Bosch J. Predictions from a hard liver. *J Hepatol.* 2006; 45(2): 174-177
- [48] Lemoine M, Katsahian S, Ziol M, et al. Liver stiffness measurement as a predictive tool of clinically significant portal hypertension in patients with compensated hepatitis C virus or alcohol-related cirrhosis. *Aliment Pharmacol Ther.* 2008; 28(9): 1102-1110
- [49] Pinzani M. Non-invasive evaluation of hepatic fibrosis: don't count your chickens before they're hatched. *Gut.* 2006; 55(3): 310-312
- [50] Masuzaki R, Tateishi R, Yoshida H, et al. Prospective risk assessment for hepatocellular carcinoma development in chronic hepatitis C patients by transient elastography. *Hepatology* 2009; 49(6): 1954–1961
- [51] Robic MA, Procopet B, Métivier S, Péron JM, Selves J, Vinel JP, Bureau C. Liver stiffness accurately predicts portal hypertension related complications in patients with chronic liver disease: a prospective study. *J Hepatol.* 2011; 55(5): 1017-1024.
- [52] Pinzani M, Vizzutti F, Arena U, Marra F. Technology Insight: noninvasive assessment of liver fibrosis by biochemical scores and elastography. *Nat Clin Pract Gastroenterol Hepatol.* 2008; 5(2): 95-106.
- [53] Castera L, Vergniol J, Foucher J, et al. Prospective comparison of transient elastography, Fibrotest, APRI, and liver biopsy for the assessment of fibrosis in chronic hepatitis C. *Gastroenterology* 2005; 128(2): 343-350.
- [54] Stefanescu H, Grigorescu M, Lupsor M, et al. A New and Simple Algorithm for the Noninvasive Assessment of Esophageal Varices in Cirrhotic Patients Using Serum Fibrosis Markers and Transient Elastography. *J Gastrointestin Liver Dis* 2011; 20(1): 57-64
- [55] Zhang G, Ha SA, Kim HK, et al. Combined analysis of AFP and HCCR-1 as an useful serological marker for small hepatocellular carcinoma: A prospective cohort study. *Dis Markers* 2012; 32: 265-271.
- [56] Tateyama M, Yatsushashi H, Taura N et al. Alpha-fetoprotein above normal levels as a risk factor for the development of hepatocellular carcinoma in patients infected with hepatitis C virus. *J Gastroenterol* 2011; 46: 92-100.

- [57] Nahon P, Kettaneh A, Lemoine M et al. Liver stiffness measurement in patients with cirrhosis and hepatocellular carcinoma: a case-control study. *Eur J Gastroenterol Hepatol* 2009;21:214-9.
- [58] Masuzaki R, Tateishi R, Yoshida H, et al. Prospective risk assessment for hepatocellular carcinoma development in patients with chronic hepatitis C by transient elastography. *Hepatology* 2009; 49: 1954-1961.
- [59] Akima T, Tamano M, Hiraishi H. Liver stiffness measured by transient elastography is a predictor of hepatocellular carcinoma development in viral hepatitis. *Hepatol Res* 2011; 41: 965-970.
- [60] Kuo YH, Lu SN, Hung CH. Liver stiffness measurement in the risk assessment of hepatocellular carcinoma for patients with chronic hepatitis. *Hepatol Int* 2010; 4: 700-706.
- [61] Castéra L, Foucher J, Bernard PH et al. Pitfalls of liver stiffness measurement: a 5-year prospective study of 13,369 examinations. *Hepatology*. 2010; 5: 828-835.
- [62] Tapper EB, Cohen EB, Patel K, et al. Levels of Alanine Aminotransferase Confound Use of Transient Elastography to Diagnose Fibrosis in Patients with Chronic HCV Infection. *Clin Gastroenterol Hepatol* 2012; DOI: 10.1016/j.cgh.2012.01.015.
- [63] Masuzaki R, Tateishi R, Yoshida H, et al. Risk assessment of hepatocellular carcinoma in chronic hepatitis C patients by transient elastography. *J Clin Gastroenterol*. 2008; 42(7): 839-843.
- [64] Pinzani M. Non-invasive evaluation of hepatic fibrosis: don't count your chickens before they're hatched. *Gut*. 2006; 55(3): 310-312.
- [65] Carrion JA, Navasa M, Bosch J, Bruguera M, Gilibert R, Forns X. Transient elastography for diagnosis of advanced fibrosis and portal hypertension in patients with hepatitis C recurrence after liver transplantation. *Liver Transpl*. 2006; 12(12): 1791-1798.
- [66] Rigamonti C, Donato MF, Fraquelli M, et al. Transient elastography predicts fibrosis progression in patients with recurrent hepatitis C after liver transplantation. *Gut* 2008; 57(6): 821-827.
- [67] Adebajo CO, Talwalkar JA, Poterucha JJ, Kim WR, Charlton MR. Ultrasound-based transient elastography for the detection of hepatic fibrosis in patients with recurrent hepatitis C virus after liver transplantation: a systematic review and meta-analysis. *Liver Transpl*. 2012; 18(3): 323-331. doi: 10.1002/lt.22460.
- [68] Sandrin L, Oudry J, Bastard C, Fournier C, Miette V, Mueller S. Non-Invasive Assessment of Liver Fibrosis by Vibration-Controlled Transient Elastography (Fibroscan®). *Intech*: p293-414.
- [69] Fraquelli M, Rigamonti C, Casazza G, et al. Reproducibility of transient elastography in the evaluation of liver fibrosis in patients with chronic liver disease. *Gut* 2007; 56(7): 968-973.

- [70] Chan HL, Wong GL, Choi PC, et al. Alanine aminotransferase-based algorithms of liver stiffness measurement by transient elastography (Fibroscan) for liver fibrosis in chronic hepatitis B. *J Viral Hepat.* 2009; 16(1): 36-44.
- [71] Kim SU, Han KH, Park JY, et al. Liver stiffness measurement using FibroScan is influenced by serum total bilirubin in acute hepatitis. *Liver Int.* 2009; 29(6): 810-5.
- [72] Arena U, Vizzutti F, Corti G, et al. Acute viral hepatitis increases liver stiffness values measured by transient elastography. *Hepatology.* 2008; 47(2): 380-384.
- [73] Sagir A, Erhardt A, Schmitt M, Häussinger D. Transient elastography is unreliable for detection of cirrhosis in patients with acute liver damage. *Hepatology.* 2008; 47(2): 592-595.
- [74] Coco B, Oliveri F, Maina AM, et al. Transient elastography: a new surrogate marker of liver fibrosis influenced by major changes of transaminases. *J Viral Hepat.* 2007; 14(5): 360-369.
- [75] Cobbold JF, Taylor-Robinson SD. Transient elastography in acute hepatitis: All that's stiff is not fibrosis. *Hepatology.* 2008; 47(2): 370-372.
- [76] Lupşor M, Badea R, Stefănescu H. Noninvasive evaluation of chronic liver diseases using transient elastography (Fibroscan®). In: Present and perspectives in infectious diseases. Conference proceedings, July 4-7, 2008.
- [77] Panos G, Holmes P, Valero S, Anderson M, Gazzard B, Nelson M. Transient elastography, liver stiffness values, and acute hepatopathy. *Hepatology.* 2008; 47(6): 2140.
- [78] Lupşor M. New ultrasound techniques for non-invasive evaluation of chronic liver diseases. The added value of elastography and computed imaging techniques. Ph thesis, University of Medicine and Pharmacy Cluj-Napoca. 2009.
- [79] Ziol M, Kettaneh A, Ganne-Carrié N, Barget N, Tengher-Barna I, Beaugrand M. Relationships between fibrosis amounts assessed by morphometry and liver stiffness measurements in chronic hepatitis or steatohepatitis. *Eur J Gastroenterol Hepatol.* 2009; 21(11): 1261-1268.
- [80] Millonig G, Reimann FM, Friedrich S, et al. Extrahepatic cholestasis increases liver stiffness (FibroScan) irrespective of fibrosis. *Hepatology.* 2008; 48(5): 1718-1723.
- [81] Pozzoni P, Prati D, Berzuini A, et al. Liver stiffness values measured by transient elastography are increased in patients with acutely decompensated heart failure. *Dig Liver Dis.* 2009; 41(3): A39.
- [82] Lebray P, Varnous S, Charlotte F, Varaut A, Poynard T, Ratziu V. Liver stiffness is an unreliable marker of liver fibrosis in patients with cardiac insufficiency. *Hepatology.* 2008; 48(6): 2089.
- [83] Bioulac-Sage P, Couffinhal T, Foucher J, Balabaud CP. Interpreting liver stiffness in the cirrhotic range. *J Hepatol.* 2009; 50(2): 423-424.



- [84] Hopper I, Kemp W, Porapakham P, et al. Impact of heart failure and changes to volume status on liver stiffness: non-invasive assessment using transient elastography. *Eur J Heart Fail.* 2012; 14(6): 621-627
- [85] Bolognesi M, Boscato N. Spleen and liver cirrhosis: relationship between spleen enlargement and portal hypertension in patients with liver cirrhosis. In TM Chen. *New Developments in Liver Cirrhosis Research.* Nova Science Publishers 2006, pp 49-67.
- [86] Bolognesi M, Merkel C, Sacerdoti D, Nava V, Gatta A. The role of spleen enlargement in cirrhosis with portal hypertension. *Dig Liver Dis* 2002; 34:144-150.
- [87] Kuddus RH, Nalesnik MA, Subbotin VM, Rao AS, Gandhi CR. Enhanced synthesis and reduced metabolism of endothelin 1 (ET-1) by hepatocytes – an important mechanism of increased endogenous levels of ET-1 in liver cirrhosis. *J Hepatol* 2000; 33: 725-732.
- [88] Yin M, Talwalkar JA, Glaser KJ. A Preliminary Assessment of Hepatic Fibrosis with Magnetic Resonance Elastography. *Clin Gastroenterol Hepatol.* 2007; 5(10): 1207–1213
- [89] Talwalkar J. Evaluation of Fibrosis and Portal Hypertension: Non-Invasive Assessment. Oral presentation abstract, Proceedings of EASL Monothematic Conference Portal Hypertension: Advances in Knowledge, Evaluation and Management, Budapest, 2009, p47.
- [90] Stefanescu H, Grigorescu M, Lupsor M, Procopet B, Maniu A, Badea R. Spleen stiffness measurement using fibroscan for the noninvasive assessment of esophageal varices in liver cirrhosis patients. *J Gastroenterol Hepatol* 2011; 26: 164-170.
- [91] Colecchia A, Montrone L, Scaiola E, et al. Measurement of Spleen Stiffness to Evaluate Portal Hypertension and the Presence of Esophageal Varices in Patients With HCV-Related Cirrhosis. *Gastroenterology* 2012; 143(3): 646-654.
- [92] Sasso M, Beaugrand M, de Ledinghen V, et al. Controlled attenuation parameter (CAP): a novel VCTE™ guided ultrasonic attenuation measurement for the evaluation of hepatic steatosis: preliminary study and validation in a cohort of patients with chronic liver disease from various causes. *Ultrasound Med Biol.* 2010; 36(11): 1825-1835.
- [93] Sasso M, Miette V, Sandrin L, Beaugrand M. The controlled attenuation parameter (CAP): a novel tool for the non-invasive evaluation of steatosis using Fibroscan. *Clin Res Hepatol Gastroenterol.* 2012; 36(1): 13-20.
- [94] de Lédighen V, Vergniol J, Foucher J, Merrouche W, le Bail B. Non-invasive diagnosis of liver steatosis using controlled attenuation parameter (CAP) and transient elastography. *Liver Int.* 2012; 32(6): 911-918.
- [95] Myers RP, Pollett A, Kirsch R, et al. Controlled Attenuation Parameter (CAP): a non-invasive method for the detection of hepatic steatosis based on transient elastography. *Liver Int.* 2012; 32(6): 902-910.

- [96] Sasso M, Tengher-Barna I, Ziol M, et al. Novel controlled attenuation parameter for noninvasive assessment of steatosis using Fibroscan(®): validation in chronic hepatitis C. *J Viral Hepat.* 2012; 19(4): 244-253.
- [97] Lupsor M, Badea R, Stefanescu H, Feier D, Tamas A, Sparchez Z. The performance of controlled attenuation parameter (CAP) for the non-invasive evaluation of steatozsis using Fibroscan. Preliminary results. *J Hepatolol* 2012; 56: S514.
- [98] Blanc JF, Bioulac-Sage P, Balabaud C, Desmouliere A. Investigation of liver fibrosis in clinical practice. *Hepatol Res.* 2005; 32(1): 1-8.
- [99] Kelleher TB, Afdhal N. Noninvasive assessment of liver fibrosis. *Clin Liver Dis.* 2005; 9(4): 667-683.
- [100] Ganne-Carrie N, Ziol M, de Ledinghen V, et al. Accuracy of liver stiffness measurement for the diagnosis of cirrhosis in patients with chronic liver diseases. *Hepatology* 2006; 44(6): 1511-1517.
- [101] Foucher J, Castera L, Bernard PH, et al. Prevalence and factors associated with failure of liver stiffness measurement using FibroScan in a prospective study of 2114 examinations. *Eur J Gastroenterol Hepatol.* 2006; 18(4): 411-412.
- [102] Castera L. Non-invasive diagnosis of steatosis and fibrosis. *Diabetes Metab.* 2008; 34(6 Pt 2): 674-679.
- [103] De Ledinghen V, Fournier C, Foucher J, et al. New Fibroscan probe for obese patients. A pilot study of feasibility and performances in patients with BMI $\geq$ 30 kg/m<sup>2</sup>. *J Hepatol* 2009; 50(1): S359.