

Brain Injury in Preterm Infants

Zoe Iliodromiti¹, Dimitrios Zygouris², Paraskevi Karagianni³, Panagiotis Belitsos⁴, Angelos Daniilidis⁵ and Nikolaos Vrachnis⁶

¹Neonatal Unit, ²nd Department of Obstetrics and Gynecology, University of Athens Medical School, Aretaieio Hospital, Athens,

²3rd Department of Obstetrics and Gynecology, University of Athens Medical School, Attiko Hospital, Athens,

³2nd NICU and Neonatology Department, Aristotle University of Thessaloniki, General Papageorgiou Hospital, Thessaloniki,

⁴Department of Obstetrics and Gynecology, Chalkida Hospital, Evia,

⁵Department of Obstetrics and Gynecology, University of Thessaloniki Medical School, Ippokrateio Hospital, Thessaloniki,

⁶2nd Department of Obstetrics and Gynecology, University of Athens Medical School, Aretaieio Hospital, Athens, Greece

1. Introduction

It is well known that the number of surviving preterm infants is today steadily on the increase (Fanaroff, Stoll et al. 2007). Nevertheless, despite the improvements in perinatal medicine, brain injury is still a major clinical problem and remains a significant cause of perinatal morbidity and mortality (Volpe 2009). Moreover, the numerous environmental factors to which the fetal brain is exposed during fetal development, additionally linked to factors of a genetic origin, not only subject the infant to the severe risk of morbidity and mortality, but can also lead to a wide spectrum of functional and behavioral disorders throughout the individual's life.

Recent studies have demonstrated that cognitive and behavioral deficits are significantly higher in preterm neonates (Burd, Chai et al. 2009; Burd, Bentz et al. 2010). Also reported, as concerns long-term consequences, are higher rates of educational difficulties, epileptic seizures, visual damages and reduction in the mean intelligence quotient (Hack 2006). The biggest problem in preterm infants is damage to white matter. This damage involves multifocal necrosis resulting in cystic periventricular leukomalacia (PVL) or a diffuse astrogliosis and loss of myelin-producing oligodendrocytes. Maternal infection and inflammation during pregnancy may also lead to development of cerebral palsy (CP) and, less commonly, to other neuropsychiatric disorders (Yoon, Romero et al. 2000; Wu 2002; Meyer, Feldon et al. 2006; Meyer, Nyffeler et al. 2006). The final result is not only the great distress incurred by the newborn and later the child and adult, but also the considerable burden inflicted on both their families and the national health system.

Although there are a large number of clinical and experimental studies which seek to describe the exact pathophysiologic mechanism involved in perinatal brain injury, this is not as yet completely understood. Further investigation is highly likely to yield pharmaceutical intervention that will achieve prevention or resolution of preterm brain injury.

2. Pathological aspects of preterm brain injury

The most prominent pathological characteristic in brain injury is white matter damage, especially in the periventricular tracts such as PVL (Periventricular Leukomalacia). The damage consists of necrotic areas, with the severe type, namely cystic PVL, being characterized by astrogliosis and microgliosis. However, the incidence of cystic PVL is today ever more rarely encountered due to contemporary advanced perinatal care: nowadays it concerns less than 5% of all cases, (Inder, Warfield et al. 2005) the majority of these involving diffuse cellular loss without any cystic establishment. This damage is referred to as non-cystic PVL and is characterized solely by diffuse necrosis accompanied by activated microglia and reactive astrocytes. Furthermore, in about one third of PVL cases neuronal loss and gliosis in the basal ganglia and dentate cerebellar nuclei (Pierson, Folkerth et al. 2007) and thalamus were detected (Ligam, Haynes et al. 2009).

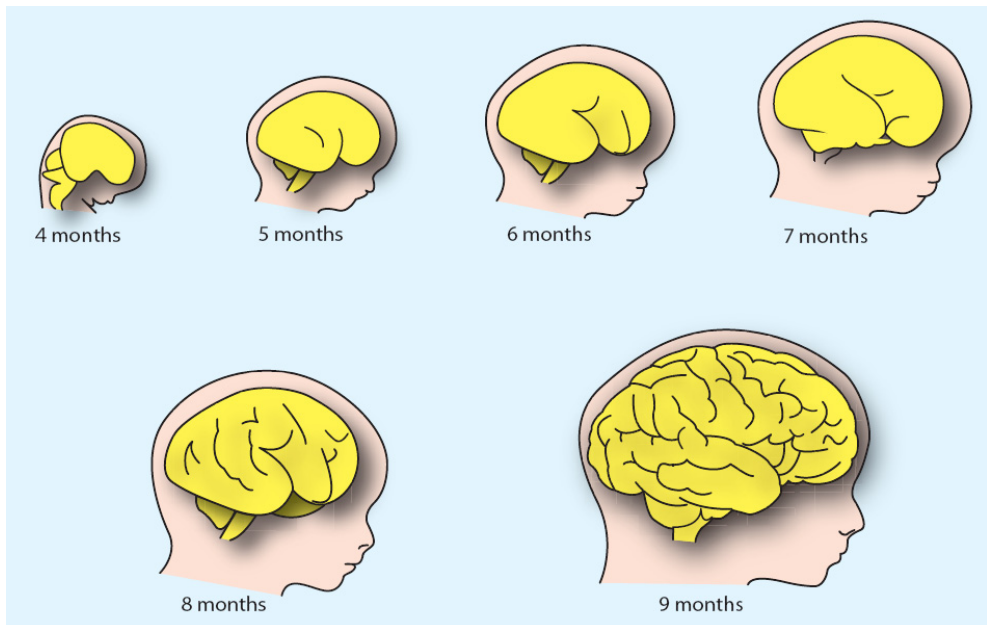


Fig. 1. Development of fetal brain. The third through the ninth month is the fetal stage, while the fourth month marks the beginning of the fetus' motor function. The commissures of brain develop at this stage and the ventricular system is completed. Cerebellar development begins by the sixth month and is completed two years after birth. However, the first eight weeks, defined as the embryonic period, are also crucial for normal brain development. The cerebral hemispheres differentiate around the fifth week, by the end of which period the cerebral cortex has undergone great growth and development.

PVL frequently exists together with intraventricular hemorrhages, this reflecting the vulnerability of the premyelinating oligodendrocytes (Pre-OIs) (Back, Luo et al. 2005). Injury to white matter is most thoroughly investigated via ultrasound and magnetic resonance imaging (MRI), the latter method clearly demonstrating a volume reduction of the thalamus and basal ganglia (Inder, Anderson et al. 2003; Inder, Warfield et al. 2005), the hippocampus (Isaacs, Lucas et al. 2000) and the cerebellum (Allin, Matsumoto et al. 2001).

The fact that injury of grey matter is also a crucial component of preterm brain injury is an additional finding derived from MRI studies (Peterson, Vohr et al. 2000; Lin, Okumura et al. 2001; Woodward, Anderson et al. 2006), which revealed a long-term reduction of gray matter volume and an association between white matter injury and reduction of gray matter volume (Woodward, Anderson et al. 2006). Interestingly, recent data show that the same injury may also be established in term infants (Iwata, Bainbridge et al. 2010).

Brain development in the perinatal period is adjusted by a crucial balance of apoptosis and survival of cerebral cells. In about 70% of the cases the brain injury is established in the early hours and predicts the long-term outcome (Hayakawa, Okumura et al. 1999; Kubota, Okumura et al. 2002). It seems that there is an increase in cell death that causes a crucial loss of the developing brain cell population. The result of this acute neuronal damage will be partly reflected in chronic anatomical deficits, as clinical brain injury develops gradually.

2.1 Glial cells: A protective network in the fetal brain

Glial cells form a defensive network that shields the brain parenchyma, participating in protection, repair and regeneration of damaged neurons during injury or disease (Peterson, Vohr et al. 2000). This network consists of microglia and astrocytes and also plays an important role in removal of dead neurons and inflammatory products.

Microglia, the primary component, penetrates the brain tissue during fetal development and removes the dead neural cells and the toxic deposits that have accumulated, this being a cornerstone function of these vital resident macrophages during neurodevelopment.

Astrocytes are the second major type of glial cells, which have varied influence on epithelial cells. They increase the blood-brain barrier (Girvin, Gordon et al. 2002) and, by activating the circulating T-cells, they regulate the immune response and homeostasis of the fetal brain. This regulation is achieved by secretion of pro- and anti-inflammatory cytokines such as interleukins (IL) and tumor necrosis factor- α (TNF- α).

The main causes of perinatal brain injury are ischemic injury, glutamate injury, cytokine-associated intrauterine infection and inflammation, and cerebral hemorrhage.

3.1 The role of hypoxia / ischemia in brain injury

Nowadays, perinatal hypoxia occurs at a low rate in preterm infants. It nonetheless remains a major problem that is substantially higher in preterm (73 / 1000 live births) than in full term infants (25 / 1000 live births) (Low 2004). Preterm infants are found to be less susceptible than term infants to developing brain injury after fetal hypoxemia (Gunn, Quaedackers et al. 2001). Although the autoregulatory mechanisms of cerebral blood flow are established very early in pregnancy and work efficiently, even in very immature infants with reduced blood supply, adequate oxygen and glucose supply, essential for the normal

functioning and development of the fetal brain, drop either acutely or gradually during intrauterine life, occlusion of the umbilical cord being the main acute cause, with placental insufficiency resulting in chronic blood hypoperfusion. Whatever is the cause of fetal hypoxemia, it results in severe brain injury (Volpe 2009). However, the exact degree of hypoxia that leads to irreversible brain damage has not as yet been determined. The fetal brain has the ability to react in hypoxia by increasing the cerebral blood flow via reflex vasodilatation (Pearce 2006). Moreover, always to be borne in mind is the anatomical vulnerability and relative vulnerability of different areas and populations of oligodendroglia in white matter. This factor would appear to explain recent experimental data that were unable to account for cerebral ischemia by differences in local blood flow.

While postnatal blood pressure has also been regarded as a marker of the induced brain injury, in many studies no relationship was found between hypotension in preterm infants and neurological defects (CPL, CP) (Trounce, Shaw et al. 1988; Perlman, Risser et al. 1996; Cunningham, Symon et al. 1999; Dammann, Allred et al. 2002). Systemic hypotension alone was associated with neurological defects by other researchers (Low, Froese et al. 1993; Murphy, Hope et al. 1997; Martens, Rijken et al. 2003), a discrepancy that can easily be explained by the fact that blood pressure is not a reliable marker of the possible impaired cardiac output and the subsequent cerebral perfusion.

The fact that the crucial moment at which hypoxemia causes brain injury has not yet been defined presents a major diagnostic problem. Moreover, it is still controversial whether brain injury can be induced by hypoxemia alone or whether it arises from a combination of other simultaneous pathophysiological factors.

3.2 Glutamate-induced brain injury

Glutamate is the major excitatory transmitter in the brain and is involved in the majority of the aspects of normal brain function, such as memory, cognition and learning. It is connected to postsynaptic glutamate receptors, its connection to and subsequent activation of these receptors leading to an increase of the free intracellular calcium. This last activates high levels of proteases, endonucleases and lipase enzymes, thus ultimately bringing about cellular death. In addition to activation of proteases, protein synthesis is inhibited as a result of brain hypoxia.

Experimental data show a wide variability in the distribution and composition of the glutamate receptors in the Central Nervous System (CNS), (McDonald, Johnston et al. 1990), this explaining why there is no clear correlation between brain cellular death and glutamate levels (Mitani, Andou et al. 1992). Nevertheless, glutamate, the cornerstone of hypoxia-induced brain injury, plays a highly toxic role, especially with regard to white matter in preterm neonates. Glutamate is produced by the developing oligodendrocytes and axons (Rossi, Oshima et al. 2000; Desilva, Kinney et al. 2007) and is highly toxic *in vitro* (Choi 1992). Moreover, it renders even more vulnerable the premyelinating oligodendrocytes, though not the mature cells (Itoh, Beesley et al. 2002).

Despite the above *in vitro* data, it has not thus far been definitively established *in vivo* that hypoxia results in high and thus toxic concentrations of glutamate. Furthermore, a recent study did not demonstrate any increase in the extracellular glutamate levels in white matter after cerebral hypoxia (Fraser, Bennet et al. 2008). It seems that the extracellular levels of

calcium rise significantly in gray matter (Henderson, Reynolds et al. 1998; Loeliger, Watson et al. 2003; Dohmen, Kumura et al. 2005) in contrast to white matter, where the rise is minimal and declines rapidly.

3.3 Reactive Oxygen Species (ROS) and Reactive Nitrogen Species (RNS)

Oxygen radicals are produced in large amounts after excessive tissue ischemia. In cerebral tissue this is carried out via activation of superoxide dismutase, xanthine oxidase and caspase-9. This activation leads to DNA fragmentation, destruction of the cellular membranes and various degrees of cell damage, eventually resulting in cell death (Davies and Goldberg 1987). Moreover, ischemia in brain tissue induces metabolism of arachidonic acid, causing further production of ROS.

A large number of experimental studies have demonstrated the severe impact of oxygen radicals on brain injury. Immature oligodendroglia, in contrast to mature cells, seems more vulnerable to ROS (Back, Gan et al. 1998). Furthermore, the use of allopurinol (an inhibitor of xanthine oxidase) seems to have a protective effect on cerebral tissue, some studies demonstrating that the neuronal loss was completely inhibited (Palmer, Towfighi et al. 1993). Another study showed that after induced cerebral hypoxia the cerebral ascorbyl radical was increased, leading to white matter injury (Welin, Sandberg et al. 2005). In contrast, in preterm fetal sheep there was no increase of ROS in the periventricular white matter (Desilva, Kinney et al. 2007). It thus appears evident that the receptor-mediated toxicity alone plays a major role in PVL, as excitatory acid levels do not increase even in cases of severe ischemia (Rosin, Bates et al. 2004).

Nitric oxide, also known as nitrogen monoxide (NO), is another free radical implicated in tissue ischemia. During cerebral ischemia, an excessive increase of intracellular calcium takes place, activating the NO-synthetase. The latter enzyme produces NO, which also induces the toxicity of the other oxygen radicals, such as superoxide radicals and hydroxyl radicals. Inhibition of NO-synthetase in animal models was shown to be highly protective in ischemic neural tissue (Hamada, Hayakawa et al. 1994), reducing hippocampal and cortical damage (Ferriero, Holtzman et al. 1996).

3.4 Intrauterine infection / inflammation

Intrauterine infection/inflammation is a major cause of fetal organ dysfunctions in the perinatal period and the fetal brain is one of the most vulnerable organs. Inflammation is a major factor in preterm and term delivered infants (Malamitsi-Puchner, Vrachnis et al. 2006) with regard to perinatal brain damage, including CP (Dammann and Leviton 1997; Volpe 2009). Intrauterine inflammation may lead to fetal inflammatory response syndrome (FIRS), clinical chorioamnionitis or clinically silent histological chorioamnionitis (Vrachnis, Vitoratos et al. 2010). Recent clinical data suggest that inflammatory response in brain tissue is the most significant mechanism causing brain injury. Inflammation reduces brain weight and volume as a result of destruction of white matter, the main loss being found at the level of the lateral ventricles and around the foramen of Monro. Modern neuro-imaging techniques have enabled identification of the foci of necrosis in the white matter around the lateral ventricle, while an inhibition of myelination and astrocytosis after intrauterine infection has also been observed.

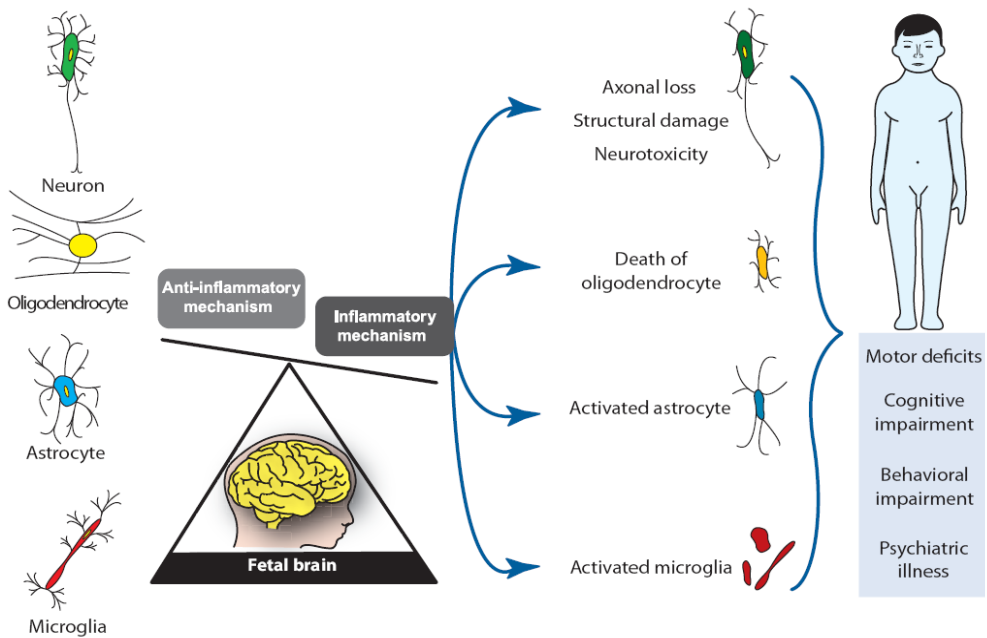


Fig. 2. Mechanisms of brain injury in preterm neonates. Chorioamnionitis is the prime factor triggering the inflammation cascade in the fetal brain, contributing to the pathogenesis of brain injury. Activated astrocytes and microglia play a cornerstone role in white matter damage, leading to functional and behavioral disorders throughout the individual's life.

Proinflammatory cytokines have been found significantly elevated in the amniotic fluid and fetal brain of neonates with infection, including local inflammatory response leading to brain injury (Yoon, Romero et al. 2000; Kadhim, Tabarki et al. 2001). Elevated levels of cytokines have additionally been observed in the amniotic fluid and blood of neonates that developed cerebral palsy (Yoon, Jun et al. 1997; Nelson, Dambrosia et al. 1998). FIRS has also been associated with increased levels of IL-6, IL-8 and TNF- α and implicated in white matter injury and predominantly in PVL development, resulting in later motor and cognitive impairments. In cases of confirmed PVL it was found that the high levels of IL-1b and TNF- α were detected even from the early stage of the injury, up until the late stage of cystic PVL (Kadhim, Tabarki et al. 2001). Moreover, autopsy studies of PVL cases revealed very high levels of TNF- α and hypertrophic astrocytes in the areas of damaged white matter (Deguchi, Oguchi et al. 1997). Experimental data show that lipopolysaccharide (LPS) infection induces TNF- α production from astrocytes and may also cause severe decentralization of fetal circulation, resulting in cerebral hypoperfusion and subsequent ischemic brain injury. Another study showed that in almost 90% of the PVL cases TNF- α , IL-1 and IL-6 were highly expressed (Yoon, Jun et al. 1997). These data are in agreement with the finding that IL-1 β induces in vitro microglial activation (Hailer, Vogt et al. 2005). Activated microglia additionally produce TNF- α IL-1b, inducing apoptosis of oligodendrocytes and their progenitors.

Other inflammatory cytokines, such as IL-12, IL-15 and IL-18, were also found in children with CP (Zupan, Gonzalez et al. 1996). IL-18 is activated by caspase-1 and causes the subsequent production of IL-1, TNF- α and interferon- γ . As a result, IL-18 induces apoptosis and is associated with development of neonatal PVL and CP (Keelan, Blumenstein et al. 2003). IL-18 was found in higher concentrations in vulnerable animal models, indicating its potentially important role in the establishment of brain injury (Hedtjarn, Leverin et al. 2002; Hedtjarn, Mallard et al. 2005).

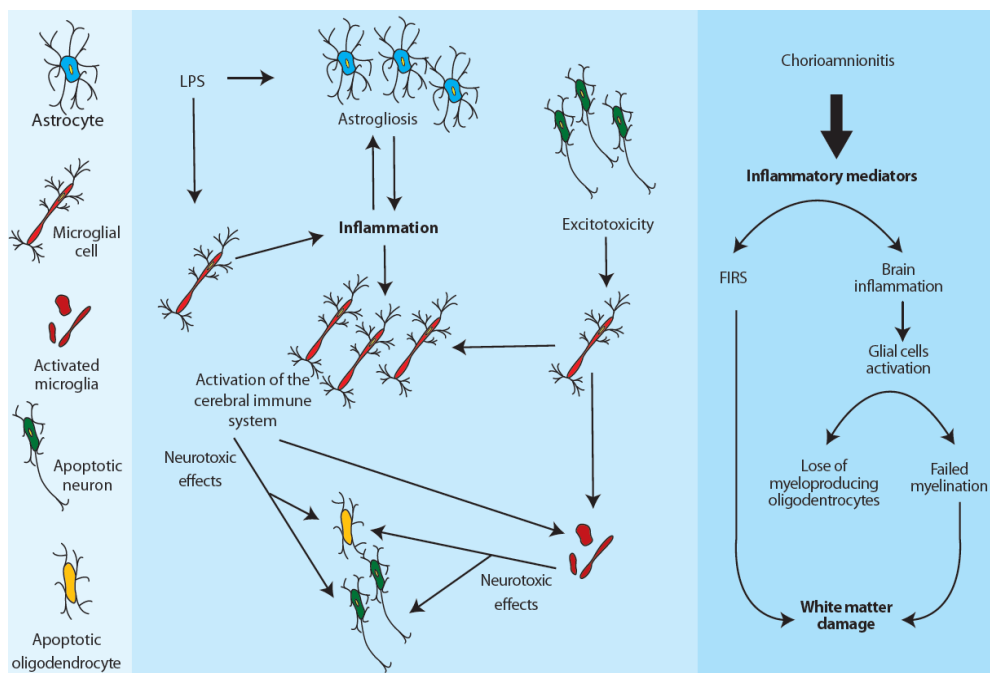


Fig. 3. Molecular pathways leading from intrauterine inflammation to brain injury. Intrauterine infection by LPS induces astrogliosis and inflammation through microglial cells, which subsequently triggers oligodendrocyte apoptosis through inflammatory cytokines such as IL-1 β , IL-6, IL-8, and TNF- α and reactive oxygen species. NF- κ B activation by intrauterine inflammation additionally results in overexpression of TNF- α , IL-1 β , IL-6 and IL-8. This inflammatory cascade results in fetal inflammatory response syndrome (FIRS) or local brain inflammation and finally damage of white matter.

Furthermore, activation of Toll-Like Receptors (TLRs) was found to participate in the intrauterine infection/inflammation that induces inflammatory response and damage in brain tissue (Yuan, Sun et al. 2010). TLRs, membrane-bound proteins used by cells of the innate immune system, play a vital role in the immune response of the central nervous system, their activation in the immune process concerning TLR₁, TLR₂, TLR₃, and especially TLR₆ receptors (Abrahams, Aldo et al. 2008). The activated TLRs receptors induce Nuclear

Factor-kappa β (NF- $\kappa\beta$) production, leading to induction of NO expression in the brain (Chen, Ho et al. 2005). NF- $\kappa\beta$ is also activated by proinflammatory cytokines after exposure to LPS and thereafter induces the expression of TNF- α , IL-1 β , IL-6 and IL-8 (Belt, Baldassare et al. 1999).

3.5 Cerebral hemorrhage causing brain injury

In preterm infants cerebral hemorrhage, mainly peri- and intra-ventricular, is a common finding. In the developing fetal brain the germinal matrix is the main area of proliferation of neuronal and glial precursors and is located in the floor of the lateral ventricle, above the caudate nucleus. This area gradually disappears during development and does not exist in term neonates (Hambleton and Wigglesworth 1976). The great clinical importance of this area is the origination of cerebral hemorrhage through its fragile vascular net, as these vessels can easily be ruptured. Perinatal hypoperfusion and hypotension can cause a rapid hemorrhage from these vessels (Tan, Williams et al. 1992). Extensive brain hemorrhage can lead to infraction ischemic injury and necrosis of the white matter, and hydrocephalus and destruction of the germinal matrix. Preterm fetuses are characterized by neural vulnerability, due to the loss of autoregulation, in contrast to term infants. As a result, increase of the arterial blood pressure can cause rupture in the cerebral vessels, while very low blood pressure can cause ischemic lesions.

4. Future environmental and pharmaceutical interventions

Despite the continuous research being carried out on the pathogenesis of a disorder incurring such very severe consequences, there is no established strategy to prevent or effectively treat fetal brain injury. The major problem is that the cascade of events that takes place is not as yet fully understood. Moreover, proceeding to Randomized Control Trials of possible therapies after experimental results in order to establish a new therapeutic intervention is, needless to say, neither ethical nor legal. Our aim is thus to offer a brief presentation of the strategies currently used and of possible future therapies.

4.1 Hypothermia

A recent meta-analysis (Edwards, Brocklehurst et al. 2010) confirmed the neuroprotective effect of moderate hypothermia, while experimental studies on adult animals show that lowering the brain temperature results in reducing neuronal cell damage (Berger, Jensen et al. 1998; Gunn, Gunn et al. 1998; Garnier, Pfeiffer et al. 2001). However, this procedure does not seem to be fully protective in the injured brain, as it does not induce the neuronal repair that is essential for normal neurodevelopment. The clinical data have merely demonstrated that mild hypothermia is not harmful in infants with perinatal asphyxia, but there was no obvious benefit (Gunn, Gluckman et al. 1998; Azzopardi, Robertson et al. 2000).

4.2 Other potential pharmacological interventions

We have already described above the crucial role of glutamate and reactive oxygen and nitrogen species in the pathogenesis of brain injury. Today, glutamate antagonists and NO inhibitors are being experimentally used to prevent cellular death. Flunarizine is an

antagonist of calcium channels and has been utilized (Garnier, Berger et al. 1998) in sheep models for protection of the fetal brain from ischemic injury, while erythropoietin is also under investigation for its anti-inflammatory, anti-oxidant and neurotrophic action (Campana and Myers 2001) in brain ischemia. Melatonin is another possible therapy as it additionally has an anti-oxidant effect and crosses the placental and blood-brain barrier (Reiter, Tan et al. 2000). It has been proposed (Gitto, Pellegrino et al. 2009) for clinical use during the perinatal period for reduction of oxidative stress (Fulia, Gitto et al. 2001). Finally, a retrospective analysis (Nelson and Grether 1995) showed that application of magnesium significantly decreased the incidence of cerebral palsy.

5. Conclusion

In conclusion, despite the numerous experimental and clinical studies that are ongoing, there is still much debate as to the exact mechanism of brain injury in preterm infants. Further research is needed to clarify the precise part played by intrauterine inflammation and oxygen and nitrogen radicals. Because the role of glutamate is undeniable in brain injury, glutamate inhibition appears to have a promising future in brain injury intervention. Furthermore, the development of therapies targeting astrocytes and activated microglia opens up yet another potential approach. Thus, while to date hypothermia is the sole established therapy, it is clear that future research will focus on a combination of therapies taking into account both pharmacological and molecular factors for the creation of an improved extrauterine environment for preterm infants.

6. References

- Abrahams, V. M., P. B. Aldo, et al. (2008). "TLR6 modulates first trimester trophoblast responses to peptidoglycan." *J Immunol* 180(9): 6035-6043.
- Allin, M., H. Matsumoto, et al. (2001). "Cognitive and motor function and the size of the cerebellum in adolescents born very pre-term." *Brain* 124(Pt 1): 60-66.
- Azzopardi, D., N. J. Robertson, et al. (2000). "Pilot study of treatment with whole body hypothermia for neonatal encephalopathy." *Pediatrics* 106(4): 684-694.
- Back, S. A., X. Gan, et al. (1998). "Maturation-dependent vulnerability of oligodendrocytes to oxidative stress-induced death caused by glutathione depletion." *J Neurosci* 18(16): 6241-6253.
- Back, S. A., N. L. Luo, et al. (2005). "Selective vulnerability of preterm white matter to oxidative damage defined by F2-isoprostanes." *Ann Neurol* 58(1): 108-120.
- Belt, A. R., J. J. Baldassare, et al. (1999). "The nuclear transcription factor NF-kappaB mediates interleukin-1beta-induced expression of cyclooxygenase-2 in human myometrial cells." *Am J Obstet Gynecol* 181(2): 359-366.
- Berger, R., A. Jensen, et al. (1998). "Effect of mild hypothermia during and after transient in vitro ischemia on metabolic disturbances in hippocampal slices at different stages of development." *Brain Res Dev Brain Res* 105(1): 67-77.
- Burd, I., A. I. Bentz, et al. (2010). "Inflammation-induced preterm birth alters neuronal morphology in the mouse fetal brain." *J Neurosci Res* 88(9): 1872-1881.

- Burd, I., J. Chai, et al. (2009). "Beyond white matter damage: fetal neuronal injury in a mouse model of preterm birth." *Am J Obstet Gynecol* 201(3): 279 e271-278.
- Campana, W. M. and R. R. Myers (2001). "Erythropoietin and erythropoietin receptors in the peripheral nervous system: changes after nerve injury." *FASEB J* 15(10): 1804-1806.
- Chen, J. C., F. M. Ho, et al. (2005). "Inhibition of iNOS gene expression by quercetin is mediated by the inhibition of IkappaB kinase, nuclear factor-kappa B and STAT1, and depends on heme oxygenase-1 induction in mouse BV-2 microglia." *Eur J Pharmacol* 521(1-3): 9-20.
- Choi, D. W. (1992). "Excitotoxic cell death." *J Neurobiol* 23(9): 1261-1276.
- Cunningham, S., A. G. Symon, et al. (1999). "Intra-arterial blood pressure reference ranges, death and morbidity in very low birthweight infants during the first seven days of life." *Early Hum Dev* 56(2-3): 151-165.
- Dammann, O., E. N. Allred, et al. (2002). "Systemic hypotension and white-matter damage in preterm infants." *Dev Med Child Neurol* 44(2): 82-90.
- Dammann, O. and A. Leviton (1997). "Maternal intrauterine infection, cytokines, and brain damage in the preterm newborn." *Pediatr Res* 42(1): 1-8.
- Davies, K. J. and A. L. Goldberg (1987). "Oxygen radicals stimulate intracellular proteolysis and lipid peroxidation by independent mechanisms in erythrocytes." *J Biol Chem* 262(17): 8220-8226.
- Deguchi, K., K. Oguchi, et al. (1997). "Characteristic neuropathology of leukomalacia in extremely low birth weight infants." *Pediatr Neurol* 16(4): 296-300.
- Desilva, T. M., H. C. Kinney, et al. (2007). "The glutamate transporter EAAT2 is transiently expressed in developing human cerebral white matter." *J Comp Neurol* 501(6): 879-890.
- Dohmen, C., E. Kumura, et al. (2005). "Extracellular correlates of glutamate toxicity in short-term cerebral ischemia and reperfusion: a direct in vivo comparison between white and gray matter." *Brain Res* 1037(1-2): 43-51.
- Edwards, A. D., P. Brocklehurst, et al. (2010). "Neurological outcomes at 18 months of age after moderate hypothermia for perinatal hypoxic ischaemic encephalopathy: synthesis and meta-analysis of trial data." *BMJ* 340: c363.
- Fanaroff, A. A., B. J. Stoll, et al. (2007). "Trends in neonatal morbidity and mortality for very low birthweight infants." *Am J Obstet Gynecol* 196(2): 147 e141-148.
- Ferriero, D. M., D. M. Holtzman, et al. (1996). "Neonatal mice lacking neuronal nitric oxide synthase are less vulnerable to hypoxic-ischemic injury." *Neurobiol Dis* 3(1): 64-71.
- Fraser, M., L. Bennet, et al. (2008). "Extracellular amino acids and lipid peroxidation products in periventricular white matter during and after cerebral ischemia in preterm fetal sheep." *J Neurochem* 105(6): 2214-2223.
- Fulia, F., E. Gitto, et al. (2001). "Increased levels of malondialdehyde and nitrite/nitrate in the blood of asphyxiated newborns: reduction by melatonin." *J Pineal Res* 31(4): 343-349.
- Garnier, Y., R. Berger, et al. (1998). "Low-dose flunarizine does not affect short-term fetal circulatory responses to acute asphyxia in sheep near term." *Reprod Fertil Dev* 10(5): 405-411.

- Garnier, Y., D. Pfeiffer, et al. (2001). "Effects of mild hypothermia on metabolic disturbances in fetal hippocampal slices after oxygen/glucose deprivation depend on depth and time delay of cooling." *J Soc Gynecol Investig* 8(4): 198-205.
- Girvin, A. M., K. B. Gordon, et al. (2002). "Differential abilities of central nervous system resident endothelial cells and astrocytes to serve as inducible antigen-presenting cells." *Blood* 99(10): 3692-3701.
- Gitto, E., S. Pellegrino, et al. (2009). "Oxidative stress of the newborn in the pre- and postnatal period and the clinical utility of melatonin." *J Pineal Res* 46(2): 128-139.
- Gunn, A. J., P. D. Gluckman, et al. (1998). "Selective head cooling in newborn infants after perinatal asphyxia: a safety study." *Pediatrics* 102(4 Pt 1): 885-892.
- Gunn, A. J., T. R. Gunn, et al. (1998). "Neuroprotection with prolonged head cooling started before postischemic seizures in fetal sheep." *Pediatrics* 102(5): 1098-1106.
- Gunn, A. J., J. S. Quaedackers, et al. (2001). "The premature fetus: not as defenseless as we thought, but still paradoxically vulnerable?" *Dev Neurosci* 23(3): 175-179.
- Hack, M. (2006). "Young adult outcomes of very-low-birth-weight children." *Semin Fetal Neonatal Med* 11(2): 127-137.
- Hailer, N. P., C. Vogt, et al. (2005). "Interleukin-1beta exacerbates and interleukin-1 receptor antagonist attenuates neuronal injury and microglial activation after excitotoxic damage in organotypic hippocampal slice cultures." *Eur J Neurosci* 21(9): 2347-2360.
- Hamada, Y., T. Hayakawa, et al. (1994). "Inhibitor of nitric oxide synthesis reduces hypoxic-ischemic brain damage in the neonatal rat." *Pediatr Res* 35(1): 10-14.
- Hambleton, G. and J. S. Wigglesworth (1976). "Origin of intraventricular haemorrhage in the preterm infant." *Arch Dis Child* 51(9): 651-659.
- Hayakawa, F., A. Okumura, et al. (1999). "Determination of timing of brain injury in preterm infants with periventricular leukomalacia with serial neonatal electroencephalography." *Pediatrics* 104(5 Pt 1): 1077-1081.
- Hedtjarn, M., A. L. Leverin, et al. (2002). "Interleukin-18 involvement in hypoxic-ischemic brain injury." *J Neurosci* 22(14): 5910-5919.
- Hedtjarn, M., C. Mallard, et al. (2005). "White matter injury in the immature brain: role of interleukin-18." *Neurosci Lett* 373(1): 16-20.
- Henderson, J. L., J. D. Reynolds, et al. (1998). "Chronic hypoxemia causes extracellular glutamate concentration to increase in the cerebral cortex of the near-term fetal sheep." *Brain Res Dev Brain Res* 105(2): 287-293.
- Inder, T. E., N. J. Anderson, et al. (2003). "White matter injury in the premature infant: a comparison between serial cranial sonographic and MR findings at term." *AJNR Am J Neuroradiol* 24(5): 805-809.
- Inder, T. E., S. K. Warfield, et al. (2005). "Abnormal cerebral structure is present at term in premature infants." *Pediatrics* 115(2): 286-294.
- Isaacs, E. B., A. Lucas, et al. (2000). "Hippocampal volume and everyday memory in children of very low birth weight." *Pediatr Res* 47(6): 713-720.
- Itoh, T., J. Beesley, et al. (2002). "AMPA glutamate receptor-mediated calcium signaling is transiently enhanced during development of oligodendrocytes." *J Neurochem* 81(2): 390-402.

- Iwata, S., A. Bainbridge, et al. (2010). "Subtle white matter injury is common in term-born infants with a wide range of risks." *Int J Dev Neurosci* 28(7): 573-580.
- Kadhim, H., B. Tabarki, et al. (2001). "Inflammatory cytokines in the pathogenesis of periventricular leukomalacia." *Neurology* 56(10): 1278-1284.
- Keelan, J. A., M. Blumenstein, et al. (2003). "Cytokines, prostaglandins and parturition--a review." *Placenta* 24 Suppl A: S33-46.
- Kubota, T., A. Okumura, et al. (2002). "Combination of neonatal electroencephalography and ultrasonography: sensitive means of early diagnosis of periventricular leukomalacia." *Brain Dev* 24(7): 698-702.
- Ligam, P., R. L. Haynes, et al. (2009). "Thalamic damage in periventricular leukomalacia: novel pathologic observations relevant to cognitive deficits in survivors of prematurity." *Pediatr Res* 65(5): 524-529.
- Lin, Y., A. Okumura, et al. (2001). "Quantitative evaluation of thalamic and basal ganglia in infants with periventricular leukomalacia." *Dev Med Child Neurol* 43(7): 481-485.
- Loeliger, M., C. S. Watson, et al. (2003). "Extracellular glutamate levels and neuropathology in cerebral white matter following repeated umbilical cord occlusion in the near term fetal sheep." *Neuroscience* 116(3): 705-714.
- Low, J. A. (2004). "Determining the contribution of asphyxia to brain damage in the neonate." *J Obstet Gynaecol Res* 30(4): 276-286.
- Low, J. A., A. B. Froese, et al. (1993). "The association between preterm newborn hypotension and hypoxemia and outcome during the first year." *Acta Paediatr* 82(5): 433-437.
- Malamitsi-Puchner, A., N. Vrachnis, et al. (2006). "Investigation of midtrimester amniotic fluid factors as potential predictors of term and preterm deliveries." *Mediators Inflamm* 2006(4): 94381.
- Martens, S. E., M. Rijken, et al. (2003). "Is hypotension a major risk factor for neurological morbidity at term age in very preterm infants?" *Early Hum Dev* 75(1-2): 79-89.
- McDonald, J. W., M. V. Johnston, et al. (1990). "Differential ontogenic development of three receptors comprising the NMDA receptor/channel complex in the rat hippocampus." *Exp Neurol* 110(3): 237-247.
- Meyer, U., J. Feldon, et al. (2006). "Immunological stress at the maternal-foetal interface: a link between neurodevelopment and adult psychopathology." *Brain Behav Immun* 20(4): 378-388.
- Meyer, U., M. Nyffeler, et al. (2006). "The time of prenatal immune challenge determines the specificity of inflammation-mediated brain and behavioral pathology." *J Neurosci* 26(18): 4752-4762.
- Mitani, A., Y. Andou, et al. (1992). "Selective vulnerability of hippocampal CA1 neurons cannot be explained in terms of an increase in glutamate concentration during ischemia in the gerbil: brain microdialysis study." *Neuroscience* 48(2): 307-313.
- Murphy, D. J., P. L. Hope, et al. (1997). "Neonatal risk factors for cerebral palsy in very preterm babies: case-control study." *BMJ* 314(7078): 404-408.
- Nelson, K. B., J. M. Dambrosia, et al. (1998). "Neonatal cytokines and coagulation factors in children with cerebral palsy." *Ann Neurol* 44(4): 665-675.

- Nelson, K. B. and J. K. Grether (1995). "Can magnesium sulfate reduce the risk of cerebral palsy in very low birthweight infants?" *Pediatrics* 95(2): 263-269.
- Palmer, C., J. Towfighi, et al. (1993). "Allopurinol administered after inducing hypoxia-ischemia reduces brain injury in 7-day-old rats." *Pediatr Res* 33(4 Pt 1): 405-411.
- Pearce, W. (2006). "Hypoxic regulation of the fetal cerebral circulation." *J Appl Physiol* 100(2): 731-738.
- Perlman, J. M., R. Risser, et al. (1996). "Bilateral cystic periventricular leukomalacia in the premature infant: associated risk factors." *Pediatrics* 97(6 Pt 1): 822-827.
- Peterson, B. S., B. Vohr, et al. (2000). "Regional brain volume abnormalities and long-term cognitive outcome in preterm infants." *JAMA* 284(15): 1939-1947.
- Pierson, C. R., R. D. Folkerth, et al. (2007). "Gray matter injury associated with periventricular leukomalacia in the premature infant." *Acta Neuropathol* 114(6): 619-631.
- Reiter, R. J., D. X. Tan, et al. (2000). "Actions of melatonin in the reduction of oxidative stress. A review." *J Biomed Sci* 7(6): 444-458.
- Rosin, C., T. E. Bates, et al. (2004). "Excitatory amino acid induced oligodendrocyte cell death in vitro: receptor-dependent and -independent mechanisms." *J Neurochem* 90(5): 1173-1185.
- Rossi, D. J., T. Oshima, et al. (2000). "Glutamate release in severe brain ischaemia is mainly by reversed uptake." *Nature* 403(6767): 316-321.
- Tan, W. K., C. E. Williams, et al. (1992). "Suppression of postischemic epileptiform activity with MK-801 improves neural outcome in fetal sheep." *Ann Neurol* 32(5): 677-682.
- Trounce, J. Q., D. E. Shaw, et al. (1988). "Clinical risk factors and periventricular leucomalacia." *Arch Dis Child* 63(1): 17-22.
- Volpe, J. J. (2009). "Brain injury in premature infants: a complex amalgam of destructive and developmental disturbances." *Lancet Neurol* 8(1): 110-124.
- Vrachnis, N., N. Vitoratos, et al. (2010). "Intrauterine inflammation and preterm delivery." *Ann N Y Acad Sci* 1205: 118-122.
- Welin, A. K., M. Sandberg, et al. (2005). "White matter injury following prolonged free radical formation in the 0.65 gestation fetal sheep brain." *Pediatr Res* 58(1): 100-105.
- Woodward, L. J., P. J. Anderson, et al. (2006). "Neonatal MRI to predict neurodevelopmental outcomes in preterm infants." *N Engl J Med* 355(7): 685-694.
- Wu, Y. W. (2002). "Systematic review of chorioamnionitis and cerebral palsy." *Ment Retard Dev Disabil Res Rev* 8(1): 25-29.
- Yoon, B. H., J. K. Jun, et al. (1997). "Amniotic fluid inflammatory cytokines (interleukin-6, interleukin-1beta, and tumor necrosis factor-alpha), neonatal brain white matter lesions, and cerebral palsy." *Am J Obstet Gynecol* 177(1): 19-26.
- Yoon, B. H., R. Romero, et al. (2000). "Fetal exposure to an intra-amniotic inflammation and the development of cerebral palsy at the age of three years." *Am J Obstet Gynecol* 182(3): 675-681.
- Yuan, T. M., Y. Sun, et al. (2010). "Intrauterine infection/inflammation and perinatal brain damage: role of glial cells and Toll-like receptor signaling." *J Neuroimmunol* 229(1-2): 16-25.

Zupan, V., P. Gonzalez, et al. (1996). "Periventricular leukomalacia: risk factors revisited." *Dev Med Child Neurol* 38(12): 1061-1067.

© 2012 The Author(s). Licensee IntechOpen. This is an open access article distributed under the terms of the [Creative Commons Attribution 3.0 License](#), which permits unrestricted use, distribution, and reproduction in any medium, provided the original work is properly cited.