

Bronchoscopy in Mechanically Ventilated Patients

Angel Estella
*Intensive Care Unit Hospital of Jerez
Spain*

1. Introduction

The origins of bronchoscopy date back to 1897 when Gustav Killian, considered “the father of bronchoscopy”, performed the first airway examination with a rigid esophagoscope to a farmer extracting a piece of bone that had lodged in the main stem bronchus. Shigeto Ikeda in 1964 revolutionized the field of bronchoscopy with the introduction of a flexible instrument that could be introduced to sub-segmental bronchi and allowed the extraction of samples for cytological examination. Endoscopy Machida Company Ltd and Olympus Optical Company Ltd in 1966 built the first prototype of a fiberoptic bronchoscope. Since its introduction in routine clinical practice in the decade of 60 has been improved, increasing its indications. 30 years ago, rigid bronchoscope was the main instrument for the direct examination of the tracheobronchial tree; and even today is considered the choice procedure in two emergencies, haemoptysis and removal of foreign bodies.

Currently, flexible fiberoptic bronchoscopy is an invasive procedure widely applied in pneumology, intensive care and thoracic surgery. It has become the procedure of choice in most examinations of the tracheobronchial tree and it is of significant help in the diagnosis and treatment of pulmonary pathology in critically ill patients. It is increasingly being used in intensive care units (ICU) because it is easy to perform at the bedside, thus avoiding potentially dangerous transfers out of the ICU, and few complications have been described with its use. The procedure revolutionized the management of respiratory diseases and in the critically ill patients is considered a safe procedure. In view of this, it is currently considered to be an essential piece of ICU equipment.

Although, by definition, critically ill patients are a priori more susceptible to developing complications during the procedure, mechanically ventilated patients, because their airway is secured, are paradoxically less at risk than when the procedure is performed on patients breathing spontaneously.

Actually flexible fiberoptic bronchoscopy is a common diagnostic and therapeutic tool for patients admitted in ICU. In the literature flexible fiberoptic bronchoscopy has been scarcely documented in critically ill patients. This chapter summarizes main indications, complications and requirements necessary to perform a bronchoscopy in mechanically ventilated patients.

2. Procedure in mechanically ventilated patients

In mechanically ventilated patients bronchoscopy is performed through the endotracheal or tracheotomy tube by means of a specially adapted valve that facilitates the introduction of the bronchoscope into the airway without disconnection of mechanical ventilation. The adapter connects the endotracheal tube with the ventilator circuit and has a side port to allow entry of the bronchoscope into the endotracheal tube without disrupting the ongoing mechanical ventilation (figure 1). This valve allows continued ventilation and maintenance of PEEP during the technique. This is especially important in patients with adult respiratory distress syndrome.

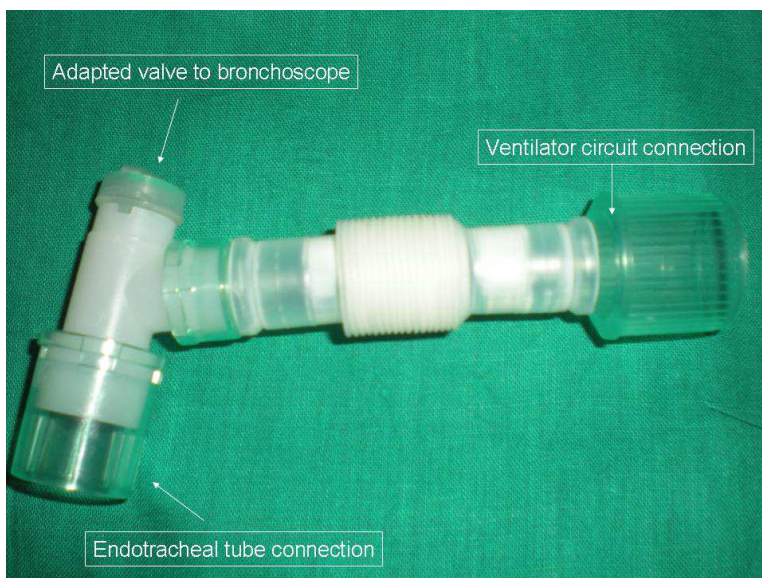


Fig. 1. Adapted valve to perform bronchoscopy in mechanically ventilated patients.

It has been studied that bronchoscope diameter plays an important role in airway flow obstruction in intubated patients. Without the orotracheal tube the bronchoscope only occupies 10% of the trachea. The internal diameter of the endotracheal tube influences the size of the bronchoscope.

In order to maintain the adequate minute volume and to minimize barotrauma it is recommended to use an endotracheal tube with a probe diameter of at least 2 mm larger than the bronchoscope diameter. An adult bronchoscope of 5.7 mm occupies 40% of the orotracheal lumen in a 9 mm endotracheal tube, which equals 51% and 66% of the lumen for 8 and 7 mm respectively. Use of a narrow bronchoscope may avoid the risk of barotrauma but has the disadvantage of less suction capacity through the bronchoscope channel.

Despite all these factors fiberoptic bronchoscopy is considered a safe procedure; patients admitted in the Intensive Care Unit should be considered at high risk from complications when undergoing fiberoptic bronchoscopy. Several recommendations must be applied to guarantee the security of the technique and improve patient safety.

In mechanically ventilated patients several considerations (table 1) are recommended during the peribronchoscopy period to ensure the maintenance of adequate ventilation and oxygenation while minimizing the risk of barotrauma. Continuous physiological monitoring must be continued during and after the procedure. During the bronchoscopy exhaustive ventilator parameter monitoring is required to take care to maintain tidal volume and to control airway pressures. Continuous haemodynamic monitoring with heart rate, arterial pressure and oximetry is mandatory.

- Internal diameter of endotracheal tube at least 2 mm larger than bronchoscope diameter.
- Specially adapted valve, allowing minimal loss of tidal volume.
- Lubricate bronchoscope.
- Inspired fraction of oxygen of 1 prior to and during bronchoscopy.
- Short suction periods.
- Continuous haemodynamic monitoring: heart rate, blood pressure, respiratory rate.
- Continuous pulse oximeter during the procedure.
- Ventilator parameters monitoring: tidal volume, airway pressure.
- Sedation and sometimes muscle relaxation must to be considered.
- To interrupt enteral nutrition during procedure.
- Verbal and written consent form.

Table 1. Recommendations to perform bronchoscopy in mechanically ventilated patients.

Prior to and during fiberoptic bronchoscopy inspired fraction of oxygen (FiO_2) must be increased to 1 and following the procedure the FiO_2 will be adjusted according to the clinical situation of the patient. Pressure-control mode has demonstrated to deliver a greater baseline volume than volume-control mode in a lung model; careful readjustment of the inspiratory pressure level is necessary in Pressure-control mode to maximize exhaled tidal volume. Finally inspiratory pressure level must be reduced to pre-procedure values when the bronchoscope is removed. Effects of fiberoptic bronchoscopy on the respiratory function have been amply analyzed in patients with spontaneous breathing but in mechanically ventilated patients has been scarcely studied. Recently it was documented in a study to analyze the effects on respiratory mechanics of flexible bronchoscopy in mechanically ventilated patients. A transitory deterioration of pulmonary mechanics with a decrease of respiratory system compliance and an increase in airway resistance was observed in fifty mechanically ventilated patients after bronchoscopy with bronchoalveolar lavage (Estella,2010).

Sedation and muscle relaxation may be necessary during the procedure to prevent barotrauma caused by airway irritation reflex and cough; although critically ill patients may be heavily sedated we recommend short-acting benzodiazepines.

Flexible bronchoscopy is an invasive procedure and therefore needs documented informed consent from the patient or legal representative if the patient lacks medical decision-making capacity.

3. Fiberoptic bronchoscopy indications in an Intensive Care Unit

Flexible fiberoptic bronchoscopy is an essential diagnostic and therapeutic tool for management of critically ill patients. The present chapter summarizes the indications of these procedures in the Intensive Care Unit; many indications require both diagnostic and therapeutic objectives simultaneously. It is currently a usual procedure in mechanically ventilated patients. Table 2 summarizes the indications of flexible bronchoscopy in this group of patients.

- Pneumonia diagnosis, mainly ventilator associated pneumonia or immunocompromised patients.
- Atelectasis, mainly caused by a central mucous plug.
- Haemoptysis.
- Bronchorrhea.
- Difficult airway management.
- Percutaneous tracheostomy control.
- Foreign bodies.
- Chest/airway trauma.
- Diffuse lung diseases.
- Acute inhalational injury.
- Others: assessment of glottic damage, insertion of double-lumen endotracheal tube.

Table 2. Indications for bronchoscopy in mechanically ventilated patients.

3.1 Pneumonia diagnosis in mechanically ventilated patients

The most frequent diagnostic indication of flexible bronchoscopy in mechanically ventilated patients is to collect samples for microbiological analysis in patients with suspected pneumonia.

Pneumonia is the most frequent nosocomial infection occurring in critically ill patients in the Intensive Care Unit and is associated with a high mortality rate, prolonged mechanical ventilation and intensive care unit stay. It is associated with a high cost due to extended hospital stay and a greater consumption of antimicrobial agents. It is necessary to distinguish three kinds of pneumonia in mechanically ventilated patients to analyze the role of flexible bronchoscopy: community acquired pneumonia, ventilator associated pneumonia and pneumonia in immunocompromised patients.

In Europe, only in half of patients with community acquired pneumonia requiring hospitalization etiological diagnosis is finally known (Woodhead M, 2002). *Streptococcus pneumoniae* is the most frequent etiologic cause. In community acquired pneumonia invasive techniques are not usually indicated. It is recommended in cases with fulminant evolution or cases without adequate response to empirical antibiotics. In an analysis of the role of bronchoalveolar lavage in 96 mechanically ventilated patients the group with community acquired pneumonia had the lower diagnostic yield compared with ventilator associated pneumonia and immunocompromised patients (Estella, 2008). Our hypothesis is that recent

introduction of antibiotics reduce the diagnostic yield of respiratory samples and empiric treatment is usually administered in a previous admission in the Intensive Care Unit.

Despite prior antibiotic therapy bronchoalveolar lavage is a useful diagnostic tool in immunocompromised patients. In ventilator associated pneumonia, in spite of the number of studies carried out, the diagnosis of pneumonia during mechanical ventilation is still disputed. Actually there are two diagnostic strategies: the "non-invasive" strategy, based on clinical criteria and a culture of secretions from upper airways (Heyland, 2006), and the "invasive" strategy, based on the use of flexible bronchoscopy for microbiological diagnosis using quantitative cultures from samples obtained selectively from the affected area (Fagon,2000). This particular strategy is recommended in the clinical guidelines of leading scientific societies for diagnosing ventilator-associated pneumonia like the American Thoracic Society, yet is one of the diagnostic methods least used in Europe, the tracheal aspirate was the most frequent diagnostic sample used in twenty-seven intensive care units of nine european countries (Koulenti,2009).

The strengths and weaknesses of the use of bronchoscopy comparing with the clinical strategy based in tracheal aspirate samples are shown in Table 3. The explanations for the low use of fiberoptic bronchoscopy in Intensive Care Unit for pneumonia diagnosis are probably the lack of experienced personnel , procedure time spent compared with other samples like tracheal aspirate and the lack of a definitive well designed study that definitively define a gold standard for the diagnosis of pneumonia.

<p>Advantages</p> <ul style="list-style-type: none"> - Lower respiratory tract - Guided sample obtained. - High specificity. - Distinguish between infection and colonization.
<p>Disadvantages</p> <ul style="list-style-type: none"> - Staff need training in bronchoscope use. - Complications. - Relative contraindications.

Table 3. Strengths and weaknesses of bronchoscopy for pneumonia diagnosis.

The year 2009 was characterized in worldwide Intensive Care Units by the Influenza A (H1N1)v pandemic. Initially bronchoscopy was not routinely recommended to obtain respiratory samples for the Influenza A (H1N1)v pneumonia due to critically ill patients presenting with severe hypoxemia and for the risk of generating aerosol. Interestingly bronchoalveolar lavage was described in a short series of patients as a useful diagnostic method in patients with false negatives obtained by upper airway respiratory samples (ANZIC influenza investigators,2009). Future studies are necessary for determining the role of bronchoscopy in the diagnosis of Influenza A (H1N1)v pneumonia. We proposed a diagnostic algorithm with the recommendation to perform bronchoscopic bronchoalveolar lavage in cases with a high clinical suspicion and negative microbiologic results of samples obtained from upper respiratory airway (Estella, 2010).

3.2 Atelectasis

Atelectasis and retention of secretions are common complications in critically ill patients. They usually present with excess airway secretions or inability to generate a cough. Frequently it is due to postoperative state, prolonged mechanical ventilation or sedation. Atelectasis is one of the most frequent therapeutic indications for flexible fiberoptic bronchoscopy in the Intensive Care Unit. For this use the size of the bronchoscope is important as efficient suctioning requires a large bronchoscope with a wide suction channel. In adult mechanically ventilated patients paediatric bronchoscopes are not recommended for this indication.

But the effectiveness of bronchoscopy to resolve it is the subject of controversy. A systematic review of several publications (Kreider, 2003) finding important differences in the effectiveness of flexible bronchoscopy: from 19% to 89%, with the best results found in lobar atelectasis caused by a central mucous plug, and the worst in subsegmental atelectasis. Figure 2 shows the sequence of endoscopic images of a central mucous plug located in the right main stem (1,2,3) and its resolution with the aspiration through the suction channel (4,5,6). Marini et al compared the use of flexible bronchoscopy with intense respiratory physiotherapy for treating atelectasis and found no differences in either group, attributing, in this study, delayed resolution to the presence of air bronchograms in the chest x-ray (Marini, 1979).

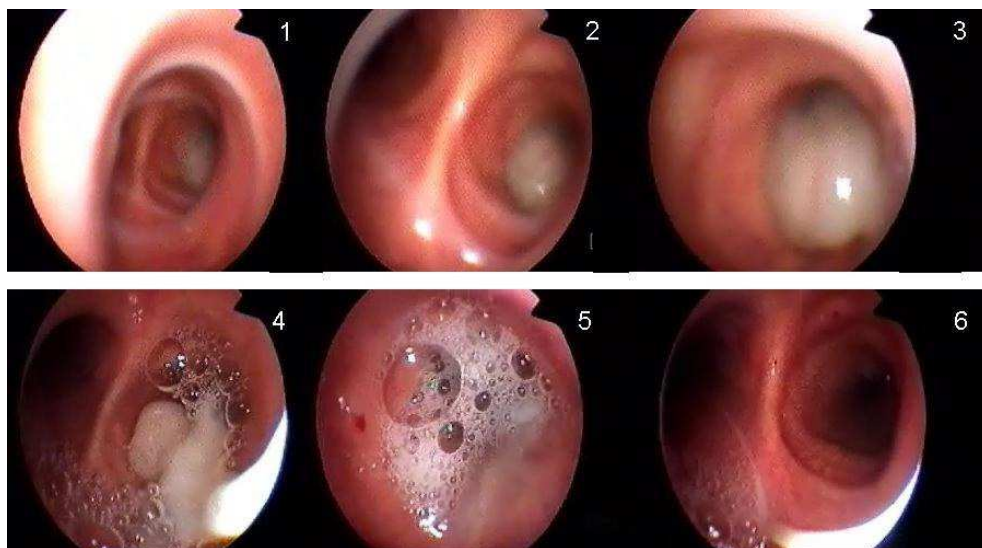


Fig. 2. Endoscopic image of a central mucous plug located in the right main stem and its resolution.

3.3 Hemoptysis

Rigid bronchoscopy is the procedure of choice for acute life-threatening haemoptysis, defined as the expectoration of more than 600 ml of blood over a 48 hour period, or of 400 ml

in 24 hours in an isolated episode. In patients with haemoptysis, flexible bronchoscopy is a useful tool for locating the point of bleeding and also for administering through the bronchoscopic channel cold saline solution and adrenaline 1:10000 to control haemorrhaging. Haemoptysis is one of the commonest situations for which emergency bronchoscopy is indicated.

In cases of life-threatening haemoptysis in intubated patients and in distal locations, flexible bronchoscopy has been shown to be useful, with reports of cases of unrelenting haemorrhage where the source of bleeding has been plugged using a Fogarty catheter placed through the aspiration channel of the endoscope (Gottlieb LS,1975). Likewise, cases have been documented in which plugging was performed using the same technique described, but with a Swan-Ganz catheter. Flexible bronchoscopy can help position double-lumen endotracheal tubes for pulmonary isolation and selective ventilation in cases of massive unilateral haemoptysis. Recently a new way of administration of drugs has been described where a good response to intrapulmonary treatment with activated recombinant factor VII instilled through the channel of the bronchoscope in cases of diffuse alveolar haemorrhage has been documented (Heslet, 2006; Estella,2008).

3.4 Chest trauma

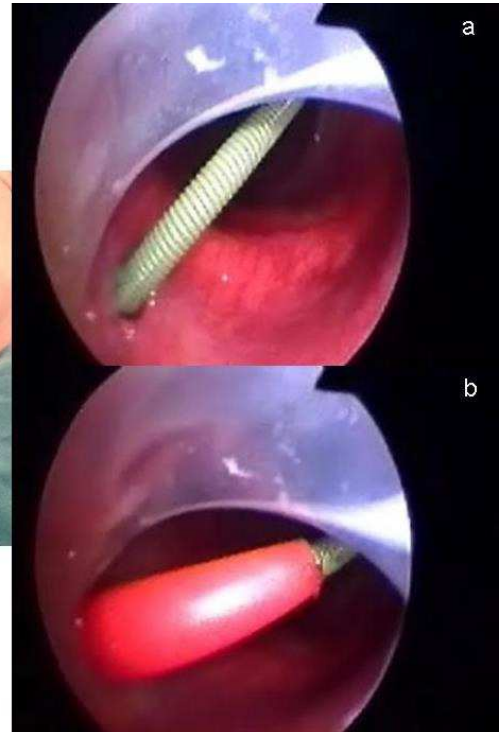
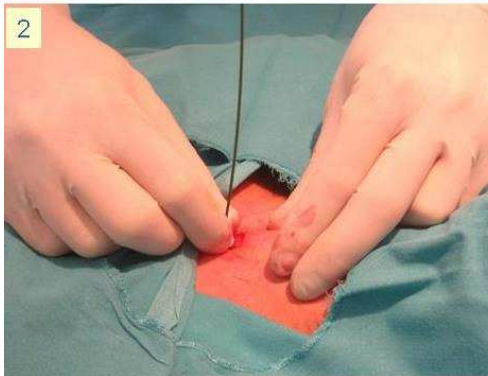
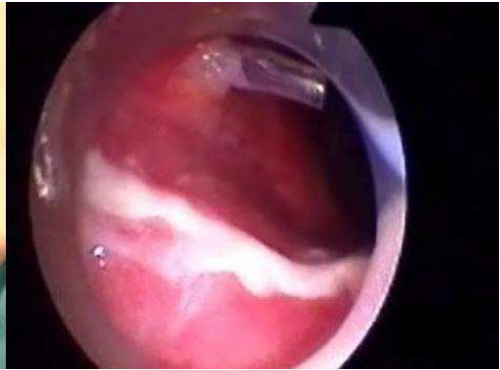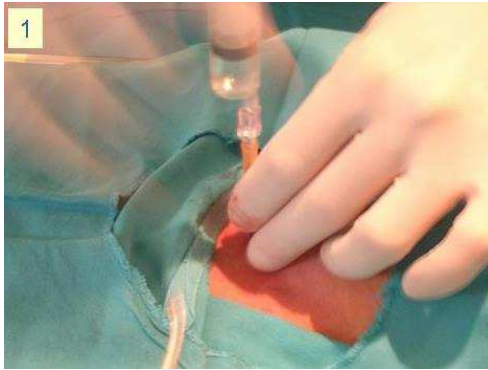
Patients with chest trauma present potential risk of lesions of the bronchial tree. Sometimes several lesions are not clinically evident and flexible bronchoscopy may be indicated to explore the airway and respiratory tract. It can be useful in diagnosis by enabling direct endoscopic visualisation of tracheal lacerations, bronchial transection or lacerations at any point of the bronchial tree, haemorrhage, contusions of the mucous membrane or aspirated material.

3.5 Percutaneous tracheostomy control

Percutaneous tracheostomy is a simple bedside procedure frequently used in Intensive Care Units, it is considered as the airway management of choice for patients with prolonged mechanical ventilation requirements. The procedure is associated with a low complication rate. It does have a few, but potentially life-threatening, complications like creation of a false airway, pneumothorax, subcutaneous emphysema, tracheoesophageal fistula. These complications are mainly associated with failure to visualise the area during the technique.

Bronchoscopic control with direct visualization minimises the complications associated with the procedure. It is recommended particularly in patients with anatomically difficult necks.

Figure 3 shows the different steps of the percutaneous tracheostomy technique and their endoscopic visualization. 1: advancement of the needle until free withdrawal of air into the fluid filled syringe and bronchoscopic visualization confirming the entry of the needle and cannula into the trachea; 2: a) introduction of the guide-wire, b) predilation, passing of the pre-dilator over the guide wire penetrating soft tissues and tracheal wall; 3: tracheal dilation, advancing the guide wire dilating forceps over the guide wire and opening of the forceps to dilate tracheal wall in order to accept the tracheotomy tube; 4: tube insertion, endoscopic image of the advancement of the tracheotomy tube into the trachea.



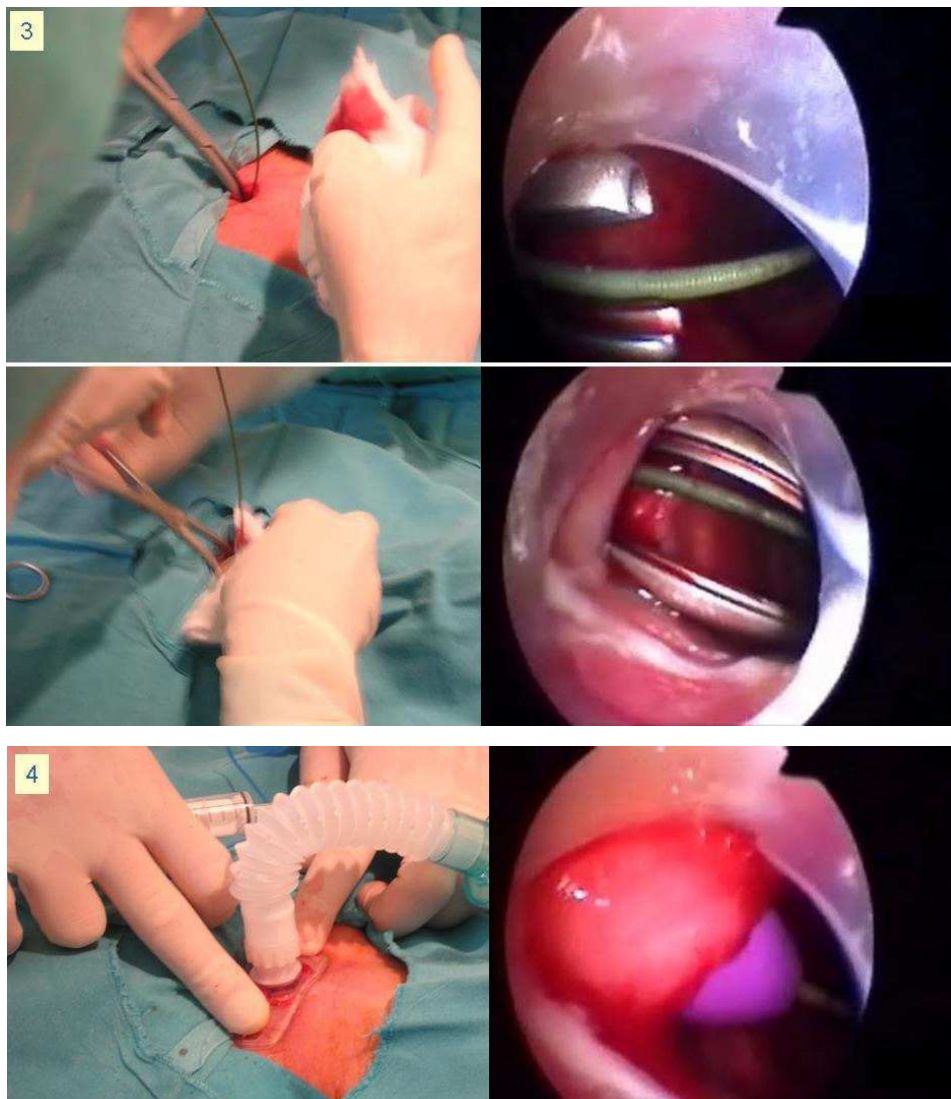


Fig. 3. Bronchoscopic images of different steps of percutaneous tracheostomy technique.

3.6 Management of difficult airway

The availability of flexible bronchoscopy in the Intensive Care Unit is essential for management of so called "difficult airways", although the indication is seen in fewer than 1% of all bronchoscopies performed in critically ill patients. This low percentage may be due to the fact that experience is required to perform the procedure and to the emergence of more easily managed devices for treatment of difficult airways, such as the Combitube, the laryngeal mask and Fastrack mask, which are increasingly used. Really, flexible

bronchoscopy is a very useful tool for management of difficult intubation, usually caused by upper airway obstruction, anatomic disorders that reduce visibility of vocal cords and/or mobility of the head and neck like short neck, protruding incisor teeth or long high arched palate. Moreover in severe bleeding which makes laryngoscope intubation more risky, bronchoscopy is recommended. Finally it should be noted that bronchoscopic endotracheal intubation is contraindicated in apnoeic patients. The oral route is preferred than nasal because of avoiding damage to the nasal mucosa and further nosocomial sinusitis. Moreover it allows intubation with an endotracheal tube with a larger diameter.

Other indication is for changing the endotracheal tube in patients with an expected difficult intubation. The new endotracheal tube is inserted over the bronchoscope and it is passed into the trachea by going outside parallel to the old endotracheal tube after deflation of the old endotracheal tube cuff.

3.7 Extracting foreign body

For extracting foreign bodies, the procedure of choice is the rigid bronchoscope, although flexible bronchoscopy using specialised instruments like hooks, Dormia baskets or biopsy forceps is also possible.

3.8 Other indications

A further use of flexible bronchoscopy is to correctly place double-lumen endotracheal tubes for selective ventilation in cases of massive haemoptysis or bronchopleural fistulas.

In patients who present with acute inhalation injury and burns flexible bronchoscopy is indicated to identify the anatomic level of the injury.

Assessment of glottis damage may be necessary in patients with prolonged mechanical ventilation. Flexible bronchoscopy is indicated to evaluate suspected neoplastic mass and for initiation of independent lung ventilation.

4. Complications of flexible bronchoscopy in mechanically ventilated patients

Taking into account recommendations commented in table 1 flexible bronchoscopy is an extremely safe procedure, if it is performed by a trained specialist. In mechanically ventilated patients it is easier to perform than in spontaneous breathing, as there is no upper airway to traverse. The risk of major complications in Intensive Care Unit is less than 1% and mortality related with the procedure is less than a 1%. Minor complications (table 4) have been associated with the procedure and occur in the first 24 hours within the procedure.

Cardiac arrhythmias, mainly supraventricular tachycardia are more like to occur in critically ill patients. Hypoxemia and insufficient sedation are associated with this complication and patients with cardiovascular disease are at highest risk for this complication.

Hypoxemia is common in mechanically ventilated patients undergoing flexible bronchoscopy, especially in patients with acute respiratory distress syndrome (ARDS). Continuous pulse oximeter during the procedure is recommended, and if a relevant decrease of oxygen saturation is observed the procedure must to be stopped.

Hypercapnia may be due to hypoventilation during the procedure and the monitoring of the tidal volume is necessary to ensure the maintenance of adequate ventilation; sedation and supplemental oxygen must be used with caution.

Bleeding of the mucous membrane occurs uncommonly during flexible bronchoscopy and is rarely harmful and usually transitory with spontaneous resolution. Patients with coagulation disorders or thrombocytopenia have high risk for bleeding. Transbronchial biopsy or brushing has more risk than bronchoalveolar lavage for bleeding with these conditions.

Pneumothorax has been documented especially when a biopsy or brush is performed while with other procedures like bronchoalveolar lavage the incidence is less than 1% (Hertz MI, 1991).

Laryngospasm and bronchospasm rarely occurs after flexible bronchoscopy in mechanically ventilated patients.

Recently we have documented the effects in respiratory mechanics with bronchoscopic bronchoalveolar lavage in mechanically ventilated patients; we conducted a study in mechanically ventilated patients observing a transitory deterioration of the respiratory mechanics with a decrease of respiratory compliance and an increase in airway resistance (Estella A, 2010).

- Anesthesia-related problems.
- Cardiac arrhythmias
- Hypoxemia
- Hypercapnia
- Hemorrhage
- Pneumothorax
- Laryngospasm
- Bronchospasm
- Pneumonia
- Fever
- Hypotension
- Decrease of respiratory system compliance.
- Increase in airway resistance.

Table 4. Complications of bronchoscopy in mechanically ventilated patients.

Post-bronchoscopy complications.

Until now we have commented on complications during flexible bronchoscopy. Complications developing in the hours after the procedure have been scarcely investigated in critically ill patients.

Post-bronchoscopy fever has not been much studied in mechanically ventilated patients, although its appearance has been reported in 16% of the patients (Shennib H, 1996). By contrast, in patients with spontaneous breathing this complication has been sufficiently

documented as self-limited in 24 hours with an incidence between 6 to 19% of the cases. In a large series of 518 patients (Um SW,2004), 5% had post-bronchoscopy fever. It was not demonstrated to be related with bacteremia. A significant increase of leukocytes and neutrophils were observed. The combination of leukocytosis, fever and negative blood cultures supports the theory that fever is due to a systemic inflammatory response; a possible mechanism involves the activation of lung macrophages on contact with the liquid instilled with the bronchoalveolar lavage, which causes a release of proinflammatory mediators into the circulation and thereby triggers a systemic inflammatory response. In mechanically ventilated patients complications in the hours following the procedure has been scarcely investigated. A rise in temperature three hours after and a significant decrease of the arterial pressure five hours after flexible bronchoscopy was documented in patients with pneumonia in a series of 34 procedures in 25 intubated patients (Pugin J,1992). Only one study, (Bauer, 2001), has investigated the cytokine inflammatory response after bronchoalveolar lavage in 30 mechanically ventilated patients. They did not find differences in cytokine concentrations 12 and 24 hours after the procedure.

5. Contraindications to flexible bronchoscopy in mechanically ventilated patients

With adequate training and experienced operators flexible bronchoscopy has few if any absolute contraindications. It is mandatory to have careful patient selection, identifying the situations in which the clinical conditions and/or haemodynamic status do not guarantee the completion of the bronchoscopy safely. The inability to adequately oxygenate or ventilate increase the risk of bronchoscopy in mechanically ventilated patients. The clinical conditions in which the risk in performing a flexible bronchoscopy is increased are cited in the table 5.

Conditions cited in table 5 are relative contraindications because if they are normalized flexible bronchoscopy can be performed.

Even in paralyzed patients increase of intracranial pressure occurs. In patients with increased intracranial pressure it is mandatory to perform the procedure with deep sedation and paralysis with muscle relaxation and continuous monitoring of cerebral hemodynamics.

<p>Endotracheal tube with an internal diameter less than 8 mm with a standard adult bronchoscope (5.8mm).</p> <p>Presence of pneumothorax on chest radiograph.</p> <p>Oxygen saturation below 90% with FiO₂ of 1.</p> <p>Active bronchospasm.</p> <p>Severe acidosis, Ph<7.2.</p> <p>Haemodynamic instability, defined by systolic blood pressure <90 mmHg despite vasoactive drugs.</p> <p>Unstable arrhythmia.</p> <p>Coagulation disorders with indications for brush or biopsy.</p> <p>Increased intracranial pressure.</p>
--

Table 5. Conditions of increased risk of bronchoscopy in mechanically ventilated patients.

Although cardiac ischemia is supposed to increase the risk of flexible bronchoscopy there is no clear data in the literature supporting this consideration. In critically ill patients the risk for developing cardiac arrhythmias is increased.

6. Final considerations

Flexible bronchoscopy must be an essential piece of Intensive Care Unit equipment; it is a safe and useful procedure for the management of several pulmonary disorders in mechanically ventilated patients.

It is relatively easy to perform at the bedside and clinicians trained in its use are necessary in the Intensive Care Unit. This valuable procedure should be available to perform urgently for a wide range of therapeutic and diagnostic indications.

The following features attest to the increasing use of flexible bronchoscopy in mechanically ventilated patients: proven useful for a wide range of respiratory diseases in critically ill patients, easy to achieve at the bedside avoiding potentially dangerous transfers out of the Intensive Care Unit, relatively inexpensive clinical tool, demonstrated safety of the procedure described with careful preparation and close monitoring in selected patients and few relative contraindications.

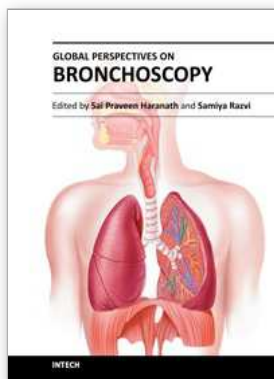
7. References

- Álvarez-Lerma F, Álvarez-Sánchez B, Barcenilla F. Protocolo diagnóstico y terapéutico de la neumonía asociada a ventilación mecánica. Guía de práctica clínica en medicina intensiva. Sociedad Española de Medicina Intensiva y Unidades Coronarias. Barcelona: Meditex, 1996; 1-8.
- American Thoracic Society Documents. Guidelines for the management of adults with hospital-acquired, ventilator-associated, and health care-associated pneumonia. *Am J Respir Crit Care Med* 2005;171:388-416.
- Barba CA, Angood PB, Kauder DR, Latenser B, Martin K, McGonigal MD, et al. Bronchoscopic guidance makes percutaneous tracheostomy a safe, cost-effective, and easy-to-teach procedure. *Surgery* 1995;118:879-83.
- Bauer TT, Arosio C, Monton C, Filella X, Xaubet A, Torres A. Systemic inflammatory response after bronchoalveolar lavage in critically ill patients. *Eur Respir J* 2001;17:274-80.
- British Thoracic Society Guidelines on diagnostic flexible bronchoscopy. *Thorax* 2001;56:(Supl 1):1-21.
- Butler KH, Clyne B. Management of the difficult airway: alternative airway techniques and adjuncts. *Emerg Med Clin North Am* 2003;21:259.
- Davis KA. Ventilator-Associated Pneumonia: a review. *J Intensive Care Med* 2006;21:211-26.
- Dellinger RP, Bandi V. Fiberoptic bronchoscopy in the intensive care unit. *Crit Care Clin* 1992; 8:755-72.
- Dupree HJ, Lewejohann JC, Gleiss J, Muhl E, Bruch HP. Fiberoptic bronchoscopy of intubated patients with life-threatening hemoptysis. *World J Surg* 2001;25:104-7.
- Estella A, Jareño A, Pérez Bello Fontaña L. Intrapulmonary administration of recombinant activated factor VII in diffuse alveolar haemorrhage: a report of two case stories. *Case J*. 2008 Sep 12;1(1):150.

- Estella A, Monge MI, Pérez Fontañá L et al. Bronchoalveolar lavage for diagnosing pneumonia in mechanically ventilated patients. *Med Intensiva*. 2008 Dec;32 (9): 419-423.
- Estella A. Bronchoalveolar lavage for pandemic influenza A (H1N1)v pneumonia in critically ill patients. *Intensive Care Med*. 2010 Nov;36(11):1976-7.
- Estella A. Effects on respiratory mechanics of bronchoalveolar lavage in mechanically ventilated patients. *Journal of bronchology and interventional pulmonology* 2010. 17(3);228-231.
- Fagon JY, Chastre J, Wolff M, et al. Invasive and noninvasive strategies for management of suspected ventilator-associated pneumonia: a randomized trial. *Ann Intern Med* 2000;132:621-30.
- Fagon JY, Chastre J, Wolff M, Gervais C, Parer-Aubas S, Stephan F, et al. Invasive and noninvasive strategies for management of suspected ventilator-associated pneumonia. A randomized trial. *Ann Intern Med*. 2000;132:621-30.
- Fagon JY. Diagnosis and treatment of ventilator-associated pneumonia: fiberoptic bronchoscopy with bronchoalveolar lavage Is essential. *Semin Respir Crit Care Med* 2006;27:034-044.
- Gottlieb LS, Hillberg R. Endobronchial tamponade therapy for intractable hemoptysis. *Chest* 1975;67:482-3.
- Hara KS, Prakash UB. Fiberoptic bronchoscopy in the evaluation of acute chest and upper airway trauma. *Chest* 1989;96:627-30.
- Heslet L, Nielsen JD, Levi M et al. Successful pulmonary administration of activated recombinant factor VII in diffuse alveolar hemorrhage. *Crit Care* 2006; 10 (6):R177.
- Jolliet Ph, Chevrolet JC. Bronchoscopy in the intensive care unit. *Intensive Care Med* 1992;18:160-9.
- Kost KM. Percutaneous tracheostomy: comparison of Ciaglia and Griggs techniques. *Critical Care Med* 2000;4:143-6.
- Koulenti D, Lisboa T, Brun-Buisson C, Krueger W, Macor A, Sole-Violan J, Diaz E, Topeli A, DeWaele J, Carneiro A, Martin-Loeches I, Armaganidis A, Rello J; EU-VAP/CAP Study Group. Spectrum of practice in the diagnosis of nosocomial pneumonia in patients requiring mechanical ventilation in European intensive care units. *Crit Care Med*. 2009 Aug;37(8):2360-8.
- Kreider MD, Lipson DA. Bronchoscopy for atelectasis in the ICU. A case report and review of the literature. *Chest* 2003;124:344-350.
- Lawson RW, Peters JL, Shelledy DC: Effects of fiberoptic bronchoscopy during mechanical ventilation in a lung model. *Chest* 2000, 118(3):824-831.
- Liebler JM, Markin CJ. Fiberoptic bronchoscopy for diagnosis and treatment. *Crit Care Clin* 2000;16:83-100.
- Lindholm CE, Ollman B, Snyder JV et al: Cardiorespiratory effects of flexible fiberoptic bronchoscopy in critically ill patients. *Chest* 1978, 74(4):362-368.
- Marini JJ, Pierson DJ, Hudson LD. Acute lobar atelectasis: a prospective comparison of fiberoptic bronchoscopy and respiratory therapy. *Am Rev Respir Dis* 1979; 119:971-8.
- Moine P, Vercken JB, Chevret S, Chastang C, Gagdos P. Severe community-acquired pneumonia: etiology, epidemiology, and prognosis factors. *Chest* 1995; 107:1182-3.

- Olaechea PM, Ulibarrena MA, Álvarez-Lerma F, Insausti J, Palomar M, de la Cal MA. Factors related to hospital stay among patients with nosocomial infection acquired in the intensive care unit. The ENVIN-UCI Study Group. *Infect Control Hosp Epidemiol* 2003;24:207-13.
- Olopade CO, Prakash UB. Bronchoscopy in the critical care unit. *Mayo Clin Proc* 1989;64:1255-63.
- Olopade CO, Prakash UB. Bronchoscopy in the critical care unit. *Mayo Clin Proc* 1989;64:1255-63.
- Ovassapian A. The flexible bronchoscope. A tool for anesthesiologists (review). *Clin Chest Med* 2001; 22:281-99.
- Pardon R, Ranic V, Rakaric-Poznanovic M. Bronchoscopy in the diagnosis and therapy of chest injuries. *Acta Med Croatica* 1997;51:29-36.
- Poe RH, Israel RH, Marin MG, Ortiz CR, Dale RC, Wahl GW, et al. Utility of fiberoptic bronchoscopy in patients with hemoptysis and a nonlocalizing chest roentgenogram. *Chest* 1988; 93:70-5.
- Polderman KH, Spijksstra JJ, de Bree R, Christiaans HM, Gelissen HP, Wester JP, et al. Percutaneous dilatational tracheostomy in the ICU: optimal organization, low complication rates, and description of a new complication. *Chest* 2003;123:1595-602.
- Pugin J, Suter PM. Diagnostic bronchoalveolar lavage in patients with pneumonia produces sepsis-like systemic effects. *Intensive Care Med* 1992;18:6-10.
- Rello J, Ollendorf DA, Oster G, Vera-Llonch M, Bellm L, Redman R et al. Epidemiology and outcomes of ventilator-associated pneumonia in a large US database. *Chest* 2002;122:2115-21.
- Richards MJ, Edwards JR, Culver DII, et al. Nosocomial infections in combined medical-surgical intensive care units in the United States. *Infect Control Hosp Epidemiol* 2000;21:510-5.
- Shennib H, Baslaim G. Bronchoscopy in the intensive care unit. *Chest Surg Clin N Am* 1996; 6: 349-61.
- Shorr AF, Sherner JH, Jackson WL, Kollef MH. Invasive approaches to the diagnosis of ventilator-associated pneumonia: a meta-analysis. *Crit Care Med* 2005;33:46-53.
- Snow N, Lucas AE. Bronchoscopy in the critically ill surgical patient. *Am Surg* 1984;50:441-5.
- Swanson KL, Udaya B, Prakash S, Midthun DE, Edell ES, Utz JP, et al. Flexible bronchoscopic management of airway foreign bodies in children. *Chest* 2002; 121:1695-1700.
- The ANZIC Influenza Investigators. Critical care services and 2009 H1N1 influenza in Australia and New Zealand. *N Engl J Med* 2009;361:1925-34.
- The Canadian Critical Care Trial Group. A randomized trial of diagnostic techniques for ventilator associated pneumonia. *N Engl J Med*. 2006;355:2619-30.
- Timsit JF, Cheval C, Gachot B, Bruneel F, Wolff M, Carlet J, Regnier B. Usefulness of a strategy based on bronchoscopy with direct examination of bronchoalveolar lavage fluid in the initial antibiotic therapy of suspected ventilator-associated pneumonia. *Intensive Care Med* 2001;27:640-7.
- Turner JS, Willcox PA, Hayhurst MD, Potgieter PD. Fiberoptic bronchoscopy in the intensive care unit. A prospective study of 147 procedures in 107 patients. *Crit Care Med* 1994; 22:259-64.

- Um SW, Choi CM, Lee CT, Kim YW, Han SK, Shim YS, et al. Prospective analysis of clinical characteristics and risk factors of postbronchoscopy fever. *Chest* 2004;125:945-52.
- Vincent JL, Bihari DJ, Suter PM, Bruining HA, White J, Nicolas-Chanion MH, et al. The prevalence of nosocomial infection in Intensive Care Units in Europe. Results of the European Prevalence of Infection in Intensive Care (EPIC) study. *JAMA* 1995; 274:639-44.
- Woodhead M. Community-acquired pneumonia in Europe: causative pathogens and resistance patterns. *Eur Respir J Suppl.* 2002 Jul;36:20s-27s.



Global Perspectives on Bronchoscopy

Edited by Dr. Sai P. Haranath

ISBN 978-953-51-0642-5

Hard cover, 240 pages

Publisher InTech

Published online 13, June, 2012

Published in print edition June, 2012

Bronchoscopy has become an essential part of modern medicine . Recent advances in technology have allowed integration of ultrasound with this tool. The use of lasers along with bronchoscopes has increased the therapeutic utility of this device. Globally an increasing number of pulmonary specialists, anaesthesiologists and thoracic surgeons are using the bronchoscope to expedite diagnosis and treatment. The current volume on bronchoscopy adds to the vast body of knowledge on this topic. The democratic online access to this body of knowledge will greatly increase the ease with which both trainees and expert bronchoscopists can learn more .The contributions from around the world cover the breadth of this field and includes cutting edge uses as well as a section on pediatric bronchoscopy . The book has been an effort by excellent authors and editors and will surely be a often reviewed addition to your digital bookshelf. . In summary, this book is a great testament to the power of collaboration and is a superb resource for doctors in training, ancillary team members as well as practicing healthcare providers who have to perform or arrange for bronchoscopy or the associated procedures.

How to reference

In order to correctly reference this scholarly work, feel free to copy and paste the following:

Angel Estella (2012). Bronchoscopy in Mechanically Ventilated Patients, Global Perspectives on Bronchoscopy, Dr. Sai P. Haranath (Ed.), ISBN: 978-953-51-0642-5, InTech, Available from: <http://www.intechopen.com/books/global-perspectives-on-bronchoscopy/bronchoscopy-in-mechanically-ventilated-patients>

INTECH
open science | open minds

InTech Europe

University Campus STeP Ri
Slavka Krautzeka 83/A
51000 Rijeka, Croatia
Phone: +385 (51) 770 447
Fax: +385 (51) 686 166
www.intechopen.com

InTech China

Unit 405, Office Block, Hotel Equatorial Shanghai
No.65, Yan An Road (West), Shanghai, 200040, China
中国上海市延安西路65号上海国际贵都大饭店办公楼405单元
Phone: +86-21-62489820
Fax: +86-21-62489821

© 2012 The Author(s). Licensee IntechOpen. This is an open access article distributed under the terms of the [Creative Commons Attribution 3.0 License](#), which permits unrestricted use, distribution, and reproduction in any medium, provided the original work is properly cited.