

Aetio-Pathogenesis and Clinical Pattern of Orofacial Infections

Babatunde O. Akinbami

*Department of Oral and Maxillofacial Surgery,
University of Port Harcourt Teaching Hospital, Rivers State,
Nigeria*

1. Introduction

Microbial induced inflammatory disease in the orofacial/head and neck region which commonly arise from odontogenic tissues, should be handled with every sense of urgency, otherwise within a short period of time, they will result in acute emergency situations.^{1,2} The outcome of the management of the conditions are greatly affected by the duration of the disease and extent of spread before presentation in the hospital, severity(virulence of causative organisms) of these infections as well as the presence and control of local and systemic diseases.

Odontogenic tissues include

1. Hard tooth tissue
2. Periodontium

2. Predisposing factors of orofacial infections

Local factors and systemic conditions that are associated with orofacial infections are listed below.

Local factors	Systemic factors
1. Caries, impaction, pericoronitis	Human immunodeficiency virus
2. Poor oral hygiene, periodontitis	Alcoholism
3. Trauma	Measles, chronic malaria, tuberculosis
4. Foreign body, calculi	Diabetes mellitus, hypo- and hyperthyroidism
5. Local fungal and viral infections	Liver disease, renal failure, heart failure
6. Post extraction/surgery	Blood dyscrasias
7. Irradiation	Steroid therapy
8. Failed root canal therapy	Cytotoxic drugs
9. Needle injections	Excessive antibiotics,
10. Secondary infection of tumors, cyst, fractures	Malnutrition
11. Allergic reactions	Anaemia, Sickle cell disease

In addition, low socio-economic status, level of education, neglect, self medication and ignorance are contributory factors to the development, progress and outcome of the infections².

3. The anatomical fascial spaces and spread of soft tissue space infection

Despite the fact that there are fasciae, muscles and bones which not only separate this region into compartments, but also serve as barriers, infections can still spread beyond the dentoalveolar tissues.²⁻⁴

In cases due to highly virulent organisms and also when the defense mechanism of the patient is compromised by systemic diseases, there is usually a fast spread into neighbouring, distant and intravascular spaces

- Presence of teeth and the roots below or above the attachment of the soft tissues to bone
- Density and vascularity of bone
- Presence of contiguous potential spaces in this region which are interconnected.
- Attachment of deep cervical fascia.
 - The deep cervical fascia has three divisions which separate the head and neck into compartments; the divisions include the investing (superficial), middle and deep layers. The investing layer is directly beneath the subcutaneous tissue and platysma, it is attached to the lower border of the mandible superiorly and the sternum and clavicle inferiorly.⁵ The middle layer encircles central organs which include the larynx, trachea, pharynx and strap muscles, it also forms the carotid sheath anteriorly. It extends into the mediastinum to attach to the pericardium.⁵
 - The deep layer is divided into the alar fascia and the prevertebral fascia.⁵ The alar fascia completes the carotid sheath posteriorly and also encloses the retropharyngeal space which extends from the base of the skull to the level of the sixth cervical vertebra. The prevertebral fascia bounds the potential prevertebral space anteriorly. It is attached to the fourth thoracic vertebra. There is an actual space between the alar and prevertebral fascia which extends down to the diaphragm.
 - The floor of the mouth is separated from the anterior part of the neck by the mylohyoid muscle. Above this muscle is the sublingual space and this link directly with the opposite side and at the posterior aspect of the mouth it links with the submandibular space.⁵ The investing layer attached to the mandible is folded into two sheaths, the upper sheath is in close proximity to the mylohyoid muscle above while the lower sheath is above the platysma, between the two is the submandibular space. The two sides of the submandibular space are separated by connective tissue septum. The body of the mandible and maxilla separates the oral cavity and the vestibule. The buccinator muscle limits the vestibule inferiorly and separates the buccal space from the vestibule.
 - Infections commonly start from the teeth or gums and these can spread via the roots or around the crowns of the teeth. It has been documented that infections from the roots of the lower anterior teeth usually spread into the sublingual space because the mylohyoid muscle attachment is below the roots, while that of the posterior teeth usually spread into the submandibular space.⁶⁻⁹ Infections from the

roots of the upper anterior teeth spread into the canine fossa, except from the lateral incisors which pass more into the palatal space intraorally because of the palatal orientation of the roots,⁸⁻¹⁰ while those from the posterior teeth spread into the buccal space.¹⁰

- Infections from the body of the mandible pass more through the relatively thinner lingual plate into the medial spaces while that from the body of the maxilla pass more via the relative thinner buccal plate into the lateral spaces. In addition, the ramus of the mandible serves as attachment on the outer side for masseter muscle which separates the submasseteric and supramasseteric spaces and on the inner aspect, there is attachment of medial pterygoid muscle which separates the pterygomandibular and lateral pharyngeal spaces.⁵
- Infections from the gums around the crowns of the posterior teeth of the mandible and maxilla commonly spread to the submasseteric or pterygomandibular spaces, while that from the roots spread into the submandibular or buccal spaces and from the buccal spaces directly into the sub/supramasseteric spaces.⁶⁻¹⁰ Also there can be spread from the submandibular space posteriorly into pterygomandibular, lateral pharyngeal and retropharyngeal spaces in the upward and downward direction.⁹
- Infections can track upwards into the infratemporal fossa between the attachments of the lateral pterygoid and temporalis muscle and into the supratemporal fossa leading to scalp abscesses. Infections can also spread into the paranasal sinuses and further into the skull, meninges, cavernose sinus/other sinuses and brain via the pterygoid plexus. Infections have also been found to spread downwards via the neck into the chest wall, mediastinum, pericardial and pleural spaces, pre and post vertebral spaces, retroperitoneal and pelvic cavities.⁵⁻¹⁰
- The most alarming spread of these infections is into the blood resulting in the devastating effects of septicemia which has significantly contributed to high mortality figures.^{11,12}

4. Pathogenesis and spread of orofacial bone infections

Rarely does infection from the teeth, periodontium and periapical region spread beyond dentoalveolar tissue because of the vascularity and density of the basal bones. However, spread of exudates and microbes into the Haversian system of bone (cancellous) below the inferior alveolar canal and beyond the maxillary sinus can occur when vascularity of the bone is reduced by excess density and cortication with aging and diseases such as osteopetrosis.

Lacunae space connections between the alveolar bone and basal bone below the inferior alveolar canal as well as connections with trabeculae bone around the maxillary sinuses, enhance spread into the whole mandible or maxilla especially in immunocompromised patients.

Increased pressure within the bone compromises vascularity causing ischaemia, necrosis of both trabeculae and lamella bone, and sequestra formation. Exudates escape through the Volkmann's canal into the subperiosteal space, stripping the periosteum. Inflammatory periosteal reaction causes laying down and formation of new bone (involucrum) around the sequestrum.

In the sclerotic, subperiosteitis ossificans types, chronic inflammation due to low grade infections (less virulent organisms) induces more granulation tissue formation, organisation of fibrous tissue, consolidation and later dystrophic calcification.

5. Classification of orofacial soft tissue space infections

Infections can be classified based not only on the type of organisms, it can also be

Based on the site/space involved

- Spaces related to the mandible include
Submandibular,
Sublingual and
Submental spaces
Sub-, intra- and supramasseteric,
Pterygomandibular,
Lateral pharyngeal and
Infratemporal spaces².
- Bilateral submandibular, sublingual and submental spaces are involved in Ludwig's angina. The incidence of Ludwig's angina has declined over the years with the advent of antibiotics¹ and only 5 cases were recorded in the study of Akinbami 2010.

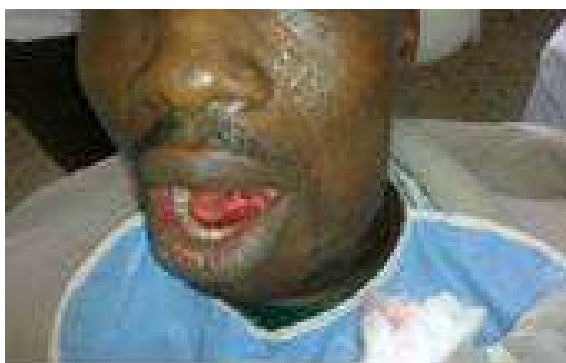


Fig. 1.




Fig. 2.

Fig. 1 and 2 show Pre-operative and Post-operative Photographs of a 31-year-old patient treated for Ludwig's angina, submasseteric abscess and buccal space abscess

- Spaces related to the maxilla
Soft tissue space infections related to the maxilla and middle third of the face include Canine fossa abscess, and Buccal space infections
Infection can be localized in a single space and can also spread to involve multiple spaces.

Based on the pattern/direction

- Below or above the floor of the mouth
- Below or above the palate

Based on the extent of spread

- Dentoalveolar tissues e.g. periapical, periodontium, alveolar bone, in rare cases to the basal bone (osteomyelitis)
- Soft tissue space around the jaws
- Space beyond the jaws e.g. neck, orbit, brain/skull,
- Distant sites; chest/pleura space, heart-endocardium, myocardium and pericardium, diaphragm, vertebra , abdomen and pelvis.

6. Classification of orofacial bone infections

Infections affecting the hard tissues can either be in the form of acute or chronic dentoalveolar abscess and osteomyelitis.

Osteomyelitis is a more severe bone infection and it can be classified into suppurative or sclerosing;

- Acute suppurative osteomyelitis
- Chronic suppurative osteomyelitis,
- Focal sclerosing osteomyelitis (Garre's osteomyelitis)
- Diffuse sclerosing osteomyelitis.

It can also be classified based on the site as

- Intramedullary osteomyelitis,
- Cortical osteomyelitis
- Acute and
- Chronic periostitis
- Subperiostitis ossificans also described by Garre's
- Refractory osteomyelitis

7. Microbial etiology of orofacial infections

The aetiologies of bone, soft tissue and tissue space infections are:

Non-specific bacteria and specific organisms such as viral, fungi, tuberculosis, syphilis and salmonella species⁹.

Other factors include, irradiation, chemicals like mercury and phosphorus.^{2,4}

Most bacteria induce inflammation by producing various antigens e.g, M protein antigen encoded by *emm* - like gene.

Orofacial infections are caused and can be classified based on the causative organisms

- Non specific (acute bacterial; aerobic, anaerobic, mixed) Causative organisms that have been incriminated for these non-specific infections are mixed in nature, that is, facultative anaerobic, strict anaerobic and aerobic organisms.
- Specific (chronic bacterial infection, fungal, viral) Specific infections are caused by organisms like *tuberculosis*, *syphilis*, *actinomycosis* and *viral* organism^{s4}.

Orofacial infections are usually polymicrobial comprising

- Facultative anaerobes, such as non-hemolytic *Streptococci viridans* group and hemolytic *Streptococci anginosus* group especially, Group A beta hemolytic, as well as Group C and Group G.
- Both C and G are occasionally obtained from throat cultures and very responsive to the new antibiotic, Linezolid (Zyvox) of the oxazolidinone class, which blocks protein synthesis by preventing translation. It binds the 23s ribosomal RNA and then hinders formation of functional 70s RNA from 50s RNA subspecies.
- And predominantly strict anaerobes, such as anaerobic cocci, *Prevotella* and *Fusobacterium* species.
- Aerobic organisms like *Pseudomonas* sp, *Proteus* sp., and *Klebsiella* sp. Many of them are actually nosocomial (hospital acquired) organisms . These are enterobacteria that are recently found in orofacial infections.

The use of non-culture techniques has expanded our insight into the microbial diversity of the causative agents, identifying such organisms as *Treponema* species and anaerobic Gram-positive rods such as *Bulleidia extructa*, *Cryptobacterium curtum* and *Mogibacterium timidum*.

- Efforts to identify the causative pathogens involved in the development of the dental abscess have in the past been hampered by inappropriate methods of sampling. The ideal clinical sample from an acute dental abscess is an aspirate through intact mucosa disinfected by an appropriate antiseptic mouthwash or swab, e.g. chlorhexidine, although some researchers have sampled purulent exudates from within infected canals (Lewis et al., 1990; Chavez de Paz Villanueva, 2002). This will reduce contamination from the normal oral flora. Previous studies using swabs of purulent material have demonstrated poor recovery of strict anaerobes and low mean numbers of isolates per sample (range 1.0-1.6) (Lewis et al., 1990).
- Pure cultures from an acute dental abscess are unusual (Reader et al., 1994), and mixed aerobic infections are also uncommon, accounting for 6 % of abscesses (Goumas et al., 1997). Dental abscesses caused solely by strict anaerobes occur in approximately 20 % of cases although there is a wide range depending on recovery conditions (6-63 %) (Brook et al., 1991; Gorbach et al., 1991; Goumas et al., 1997; Khemalelakul et al., 2002).

- A complex mix of strict anaerobes and facultative anaerobes accounts for most infections (59–75 %), which can prove challenging to non-specialist microbiology laboratories (Gorbach et al., 1991; Goumas et al., 1997; Kuriyama et al., 2000a). In mixed infections, strict anaerobes outnumber facultatives by a ratio which varies between 1.5: 1 to 3 : 1, again depending on the recovery and culture conditions (Baumgartner & Xia, 2003; Khemaleelakul et al., 2002; Kulekci et al., 1996; Lewis et al., 1993; Roche & Yoshimori, 1997; Sakamoto et al., 1998). The mean number of species recovered by culture from dentoalveolar aspirates is 4 with a range of between 1 and 7.5 (Fazakerley et al., 1993; Khemaleelakul et al., 2002; Reader et al., 1994).

Facultative anaerobes

The most commonly found facultative anaerobes belong to the viridans group streptococci and the anginosus group streptococci.

- The viridans group streptococci comprise the mitis group, oralis group, salivarius group, sanguinis group and the mutans group (Facklam, 2002).
- The anginosus group (formerly referred to as 'Streptococcus milleri' or Streptococcus anginosus) has also been identified and reported with varying degrees of accuracy ranging. These are alpha, beta and gamma haemolytic streptococci.

Historically, Staphylococcus species have not been considered members of the oral flora or to play a major role in the pathogenesis of oral infections. However, a number of more recent studies have indicated that both 'methicillin sensitive and resistant' staphylococci may indeed be a more frequent colonizer of the oral tissues than previously thought.

Interestingly, Staphylococcus aureus has been reported to occur more frequently in severe dental abscesses from children (Brook et al., 1991; Coticchia et al., 2004; Coulthard & Isaacs, 1991; Dodson et al., 1989; Tan et al., 2001). Recovery rates of coagulase-negative strains of staphylococci (usually reported as Staphylococcus epidermidis) are generally higher with figures ranging from 4 to 65 % (Gorbach et al., 1991; Goumas et al., 1997; Khemaleelakul et al., 2002; Kuriyama et al., 2002b; Lewis et al., 1995; Mangundjaja & Hardjwinata, 1990; Sakamoto et al., 1998; Stroe et al., 2001). Staphylococcus species may also be associated with refractory infections not responding to endodontic treatment (Reader et al., 1994).

Strict Anaerobes

Similar difficulties exist for cross-study comparisons of identification and prevalence of strict anaerobes. The most commonly isolated genera include

- Anaerobic streptococci, Fusobacterium species and
- Black-pigmented anaerobes such as Prevotella and Porphyromonas species (Sundqvist et al., 1989).

The nomenclature and recent changes in taxonomy have complicated the comparison of more recent studies with older studies due to the renaming of several species, specifically the Prevotella, Bacteroides and Porphyromonas species. An important group of pathogens that has undergone much in the way of taxonomic rearrangement, often referred to as the 'oral Bacteroides' and black-pigmenting anaerobes group, has been reclassified.

The *Bacteroides* species have been divided into the

- saccharolytic genus *Prevotella* and the asaccharolytic genus *Porphyromonas*.

The genus *Bacteroides* has been restricted to the

- fermentative *Bacteroides fragilis* and its closely related species.

B. fragilis, a more common isolate from intra-abdominal infections, which has only infrequently been reported from acute dentoalveolar infections, is not regarded as an oral commensal.

The member of the *Bacteroides* genus most likely to be recovered from an acute dental abscess is *Bacteroides forsythus* (now transferred to a new genus as *Tannerella forsythia* (Gomes et al., 2006).

The most commonly reported anaerobic Gram-negative bacilli from acute dentoalveolar infections are species from the

- pigmented *Prevotella intermedia* (comprising *Prevotella intermedia*, *Prevotella nigrescens* and *Prevotella pallens*),
- *Porphyromonas endodontalis* and *Porphyromonas gingivalis* (Jacinto et al., 2006).

The *Prevotella* species are the most frequent isolates, found in

- 10–87 % of dentoalveolar abscesses (Baumgartner et al., 2004; Fazakerley et al., 1993; Kolokotronis, 1999; Kulekci et al., 1996; Kuriyama et al., 2005; Lewis et al., 1993; Riggio et al., 2006; Roche & Yoshimori, 1997; Sakamoto et al., 1998; Siqueira et al., 2001b, d; Wade et al., 1994).

The genus *Fusobacterium* is frequently reported in infections of the head and neck with reports indicating that *Fusobacterium* species can be detected in up to 52 % of specimens (Gill & Scully, 1990; Gilmore et al., 1988; Gorbach et al., 1991; Goumas et al., 1997; Kulekci et al., 1996; Kuriyama et al., 2000a, b, 2005, 2006; Lewis et al., 1993; Mangundjaja & Hardjawanata, 1990; Sakamoto et al., 1998; Wade et al., 1994).

- Taxonomy and nomenclature of the genus *Fusobacterium* also cause difficulties in comparisons across studies. Within the human oral flora,
- *Fusobacterium periodonticum* and *Fusobacterium nucleatum* (which includes subsp. *nucleatum*, subsp. *polymorphum*, subsp. *animalis*, subsp. *vincentii* and subsp. *fusiforme*) are frequently detected with *F. nucleatum* recovered most frequently from the acute dental abscess (Dzink et al., 1990; Chavez de Paz Villanueva, 2002; Sassone et al., 2008).
- Studies utilizing non-culture techniques for analysis of the dental abscess for the presence of *F. nucleatum* have reported a prevalence of 73 % (Baumgartner et al., 2004).

The Clostridia are infrequently reported from odontogenic infections either as a sole pathogen or as part of the abscess flora. Workers have recovered

- Clostridium species from 2–20 % of specimens (Gorbach et al., 1991; Goumas et al., 1997; Khemalelakul et al., 2002; Roche & Yoshimori, 1997). Where speciated, these isolates have included
- *Clostridium hastiforme*
- *Clostridium histolyticum*

- *Clostridium perfringens*
- *Clostridium subterminale* and
- *Clostridium clostridioforme* (Khemaleelakul et al., 2002; Roche & Yoshimori, 1997).

Although other *Clostridium* species such as *Clostridium sporogenes*, *Clostridium bifermentans*, *Clostridium botulinum*, '*Clostridium oedomatiens*' and '*Clostridium welchii*' have been recovered from carious dentine, they appear to be infrequent pathogens in the oral cavity (Van Reenan & Coogan, 1970).

- Analysis of the microflora of the acute dental abscess using molecular biological techniques. Close attention to specimen collection and processing on selective and non-selective agars under appropriate atmospheric conditions has improved the routine diagnostic yield from acute dental abscesses. However, despite meticulous attention to detail, it is apparent that many genera of bacteria have yet to be cultured from many infectious diseases including the acute dental abscess (Siqueira & Rocas, 2005).
- The use of culture-independent or molecular diagnostic techniques has expanded our insight into the microbial ecology of the dental abscess. Genetic methods of identification are now reliable with 16S rRNA gene sequencing frequently being used for research purposes. Broadly speaking, the molecular analysis may take one of two approaches.
- Firstly, the use of molecular cloning and sequencing techniques to identify uncultivable micro-organisms using 16s rRNA or rDNA has led to the identification of several novel species (Dymock et al., 1996).
- Secondly, is the use of Polymerase Chain Reaction (PCR) or DNA-DNA hybridization checkerboard techniques (Siqueira et al., 2001d, 2002a) and more recently 16S rRNA gene sequencing and species-specific primers searching for the presence of specific microbes (Dymock et al., 1996; Riggio et al., 2006; Rocas & Siqueira, 2005; Sakamoto et al., 2006; Siqueira et al., 2001b, c, 2002b, 2003). There is higher prevalence of more fastidious organisms such as *Treponema* species in the acute dental abscess with this second approach.

Treponema species are strictly anaerobic, motile, helically shaped bacteria. Within the oral cavity they are more usually associated with diseases of the periodontium. There are a number of different species described from the oral cavity including

- *Treponema amylovorum*
- *Treponema denticola*
- *Treponema maltophilum*
- *Treponema medium*
- *Treponema pectinovorum*
- *Treponema socranskii* and
- *Treponema vincentii* (Chan & McLaughlin, 2000).
 - The treponemes are difficult to cultivate and differentiate and only *T. denticola*, *T. pectinovorum*, *T. socranskii* and '*T. vincentii*' have been readily cultivated. Recent work using PCR detection has indicated a surprisingly high prevalence of *Treponema* species within the acute dental abscess. Siqueira & Rocas (2004c) found that *T. denticola* was present in up to 79 % of dental abscesses, with lower detection rates reported by other workers (Baumgartner et al., 2003; Siqueira et al., 2001a, c; Gomes et al., 2006; Cavrini et al., 2008).

- Other *Treponema* species were found in lower numbers, including *T. socranskii* (in 26 % of aspirates), *T. pectinovorum* (14–21 % of aspirates), *T. amylovorum* (16 % of aspirates) and *T. medium* (5 % of aspirates). Other species such as *Treponema lecithinolyticum*, '*T. vincentii*' and *T. maltophilum* were not detected.

Improvements in sampling, culture and identification have led to a greater insight into the diversity of the microbial flora in an acute dental abscess. This has resulted in the reporting of micro-organisms which are probably more accurately described as 'unfamiliar' rather than 'new' implying their recent appearance.

These include members of the genus *Atopobium*

- (Gram-positive strictly anaerobic coccobacilli), for example *Atopobium parvulum* and *Atopobium rimae*.
- Anaerobic Gram-positive rods include *Bulleidia extracta*, *Cryptobacterium curtum*,
- *Eubacterium sulci*, *Mogibacterium timidum* and *Mogibacterium vesicum* (Sakamoto et al., 2006), *Pseudoramibacter alactolyticus* and *Slakia exigua* (Siqueira & Rocas, 2003c).

Other unfamiliar species include anaerobic Gram-negative rods such as

- *Filifactor alocis* (Siqueira & Rocas, 2003a, 2004b; Gomes et al., 2006) and
- *Dialister pneumosintes* (Siqueira et al., 2005; Siqueira & Rocas, 2003b, 2004b).
- *Centipeda periodontii* and *Selenomonas sputigena* are multi-flagellated, motile, anaerobic, Gram-negative rods also found recently in the acute dental abscess (Siqueira & Rocas, 2004a).
- *Catonella morbi*, a Gram-negative anaerobe formerly known as *Bacteroides* D42, was found in 16 % of 19 aspirates, and *Granulicatella adiacens*, a facultative anaerobic Gram-positive coccus formerly known as nutritionally variant streptococci, was present in 11 % of 19 aspirates (Rocas & Siqueira, 2005; Siqueira & Rocas, 2006).
 - The detection of these unfamiliar species has opened up a whole new area for possible study into the virulence factors possessed by these bacteria and their relative influence on the pathogenesis of the acute dental abscess and interactions with more commonly isolated and better understood pathogens. These techniques are not without their limitations and meticulous asepsis is required throughout the sampling and analysis procedure to avoid contamination due to the sensitivity of these methods.
 - Furthermore, until recently these techniques could only give semiquantitative analysis of aspirates and indeed some papers cited above can only show the presence or absence of the species in question. This will improve with the advent of quantitative real-time PCR. The use of species-specific primers targeting the 16S rRNA gene or similar is also limited by the fact that they cannot distinguish between transcriptionally active viable cells and those non-vital bystanders. Advanced molecular techniques using reverse transcriptase are finding methods of overcoming these limitations currently. Also, molecular techniques provide little information to guide the clinician in the choice of antibiotic required.

8. Evaluation of orofacial soft tissue space infections

Infections within the soft tissue spaces constitute about 61% of all orofacial infections and they are commoner in males than females in both adult and pediatric age groups¹⁶

Histories of complains such as

- Toothache, pain from any of the site precede that of
 - Swelling
 - Cellulites in these spaces is characterized by severe pain and marked trismus
 - Swelling is more prominent in supramaseteric space than submaseteric space,
 - Trismus is marked in the pterygomandibular, submaseteric and infratemporal spaces³⁻⁵
 - Pain and swelling manifest more intraorally in pterygomandibular and lateral pharyngeal space infections⁶⁻¹⁰
 - Dyspnea and Stridor
 - Difficulty in lying supine; most patients want to sit up, in attempt to get enough breath
 - Systemic signs: Features of systemic spread are fever, chills, rigors, anorexia, nausea

Examine

- Site, size and extent of swelling and restriction in mouth opening; e.g., Infections in the lateral pharyngeal space spread down to the posterior triangle as well as underneath and around the sternomastoid muscle. Buccal space infections are located more anteriorly and extraorally². Infratemporal cellulitis spread more towards the temporal region
- Offending tooth; caries, fracture, failed crown/root filling, tenderness to percussion, loss of vitality, inflamed gingiva, recession, pockets.
- Associated discharge from the gingiva sulci
- Paraesthesia/anaesthesia
- Vital signs: Temperature, pulse rate, respiratory rate. Features of systemic spread are raised temperature, increased pulse rate and increasing respiratory rate.
- Furuichi *et al.* reported gross mandibular deviation in a case pterygomandibular abscess.⁹

9. Evaluation of orofacial bone infections

Dentoalveolar abscess is the commonest bone infection usually secondary to local factors and it is common in all age groups with incidence of 21.7%. Osteomyelitis is about 8.7% and occurs more in the middle age and elderly due to reduced vascularity and increased bone density of bone with age. Similarly, the disease also occur more in the mandible than maxilla². However, acute maxillitis of the newborn is a disease that is due to the primary infection opthalmia neonatarium acquired from organisms in the birth canal².

Dento-alveolar abscess present with

- moderate to severe pain

- moderate swelling of the alveolus more prominent on the buccal side
- tenderness to percussion of the affected teeth
- usually no altered sensation
- mild to moderate mobility of teeth
- occasionally pus discharge from the sulci
- rarely, there may be intraoral sinus formation in chronic cases

Acute osteomyelitis manifests with

- severe systemic signs
- deep-seated pain in the bone
- pus discharge from the gingival sulci
- moderate bone swelling, swelling of the teeth
- severe tenderness to percussion and
- absent sensations (anaesthesia)

Chronic osteomyelitis present with

- a dull pain
- moderate /large bony hard swellings
- altered sensations (paraesthesia)
- persistent discharging extraoral sinuses and
- new bone formation. Formation of involucrum around the sequestrum
 - There have been controversies over the origin and aetiology of diffuse sclerosing osteomyelitis. Some authors believe that it is due to organisms like *propionibacterium acne* and *peptostreptococcus intermedius* found in the deep pockets associated with generalized periodontitis. Others believe that it may be part of a bone, joint and skin {SAPHO; synovitis, acne, pustulosis, hyperostosis and osteitis} syndrome probably due to allergic or autoimmune reaction in the periosteum⁷. Based on this fact, it has been found that corticosteroids have been useful in its management with or without prolonged antibiotic therapy and decortifications

10. Microbiology

Microscopy/Culture/Sensitivity

Different types of agars for culture and sensitivity

- Gram staining techniques for microscopy and identification of organisms
- Blood agar culture: MacKonchey media
- Antibiotic laden vancomycin-kanamycin agar
- Bile agar

Anaerobic culture

- Thioglycolate agar
- Cooked meat broth agar

Sensitivity Test

- Disk diffusion sensitivity tests for antibiotics sensitivity

11. Chemical pathology

- Evaluation for systemic factors, , fasting blood sugar, Electrolyte/urea/creatinine

12. Virology and immunology

- Retroviral screening

13. Hematology

- Packed cell volume
- White blood count; total and differential,
- Blood films and bone marrow aspirates to rule out leukemia, polycythemia, aplastic anaemia
- Erythrocyte sedimentation rate

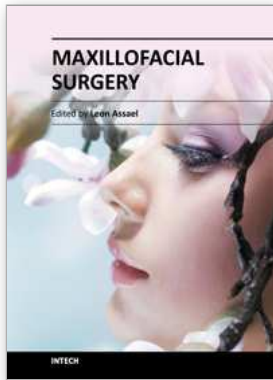
14. References

- [1] Shafer WG. Infectious diseases. In: Hine MK, Levy BM, eds. A textbook of oral pathology. 3rd ed. Philadelphia, USA: WB Saunder's Company, 1974:309-355.
- [2] Killey HC, Kay LW. Orofacial infections. In: Seward GR, Harris M, McGowan DA, eds. An outline of oral surgery Part Two. 4th ed. Oxford, Great Britain: Reed educational and professional publishing limited, 1989:310- 330.
- [3] Contran RS. Infectious diseases. In: Kumar V, Collin Y, eds. Pathologic basis of disease. 6th ed. London, WB Saunders Company 1999:169- 193.
- [4] Soames JV. Pathological basis of infection. In: Southam JC, ed. Textbook of oral pathology. 3rd ed. New York: Oxford University Press, 1995:245-265.
- [5] Sinnatamby R. Anatomy of the Head and Neck region. In: Last RJ, ed. Regional and applied anatomy. 9th ed. Philadelphia: Churchill Livingstone 1998:456-478.
- [6] Cawson RA. Management of infectious diseases In Cawson RA ed. Essentials of oral pathology and oral medicine. 1st ed. London: Micheal Parkinson 1981:88-95.
- [7] Siegert R. Ultrasonography of inflammatory soft tissue swellings of the head and neck region. J Oral Maxillofac Surg 1987;45:842-846.
- [8] Jones KC, Silver J, Millar WS, Mandel L. Chronic submasseteric abscess: anatomic, radiologic and pathologic features: Am J Neuroradiol 2003;24: 1159-1163.
- [9] Furuichi H, Oka M, Takenoshita Y, Kubo K, Shinohara M, Beppu K. A marked mandibular deviation caused by abscess of the pterygomandibular space. Fukuoka Igaku Zasshi 1986;77:373-377.
- [10] Srirompstong S, Srirompotong S. Surgical emphysema following intraoral drainage of buccal space abscess. J Med Assoc Thai 2002;85: 1314-1316.
- [11] Baqain ZH, Newman L, Hyde N. How serious are oral infections? J Laryngol Otol 2004;118:561-565.

- [12] Miller EJ Jr, Dodson TB. The risk of serious odontogenic infections in HIV-positive patients: a pilot study. *Oral Surg Oral Med Oral Pathol Oral Radiol Endod* 1998;86:406-409.
- [13] Ugboko VI, Owotade FJ, Ajike SO, Ndukwe KC, Onipede AO. A study of orofacial bacterial infections in elderly Nigerians. *SADJ* 2002;57:391-394.
- [14] Ndukwe KC, Fatusi OA, Ugboko VI. Craniocervical necrotizing fasciitis in Ile-Ife, Nigeria. *Br J Oral Maxillofac Surg* 2002;40:64-67.
- [15] Hodgson TA, Rachanis CC. Oral fungal and bacterial infections in HIV-infected individuals: an overview in Africa. *Oral Dis* 2002;8(Suppl 2):80-87.
- [16] Akinbami BO. Factors associated with orofacial infections. *Port Harcourt Medical Journal* 2009;3:199-206.
- [17] Iwahara K, Kuriyama T, Shimura S, Williams DW, Yanagisawa M, Nakagawa K, Karasawa T. Detection of cfx a and cfxA2, the β -lactamase genes of *Prevotella* spp. in clinical samples of dentoalveolar infection by real-time PCR. *Journal of Clinical Microbiology* 2006;44:172-176
- [18] Sandor GK, Low DE, Judd PL, Davidson RJ. Antimicrobial treatment options in the management of odontogenic infections. *J Can. Dent Assoc* 1998;64:508-514.
- [19] Parker MI, Khateery SM. A retrospective analysis of orofacial infection requiring hospitalization in AL Madinah, Saudi Arabia. *Saudi Dental Journal* 2001;13:96-100.
- [20] Heimdahl A, Nord CE. Treatment of orofacial infections of odontogenic origin. *Scand J Infect Dis* 1989;46(Suppl):101-105.
- [21] Sandor GKB, Low DE, Judd PL, Davidson RJ. Antimicrobial treatment options in the management of odontogenic infections. *J Canad Dent Asso* 1998;64:508-514.
- [22] Greenberg RN, James RB, Marier RL. Microbiologic and antibiotic aspects of infections in the Oral and Maxillofacial region. *J Oral Surg* 1979;37:873-884.
- [23] Moenning JE, Nelson CL, Kohler RB. The microbiology and chemotherapy of odontogenic infections. *J Oral Maxillofac Surg* 1989; 47:976-982.
- [24] Baker KA, Fotos PG. The management of odontogenic infections. A rationale for appropriate chemotherapy. *Dent Clin North Am* 1994; 36:689-706.
- [25] Sands T, Pynn BR, Katsikeris N. Odontogenic infections: Microbiology, antibiotics and management. *Oral Health* 1995;85:11-28.
- [26] Sands T, Pynn BR. Odontogenic infections. *Univ Tufts Dent J* 1995;32-33.
- [27] Haug RH, Hoffman MJ, Indresano AT. An epidemiological and anatomical survey of odontogenic infections. *J Oral Maxillofac Surg* 1991;47:976-980.
- [28] Hunt DE, King TJ, Fuller GE. Antibiotic susceptibility of bacteria isolated from oral infections. *J Oral Surg* 1978;36:527.
- [29] Peters ES, Fong Brian, Wormuth DW, Sonis ST. Risk factors affecting hospital length of stay in patients with odontogenic maxillofacial infections. *J Oral Maxillofac Surg* 1996;54:1386-1391.
- [30] Van Reenan, J. F. & Coogan, M. M. (1970). Clostridia isolated from human mouths. *Arch Oral Biol* 15, 845-848.[CrossRef][Medline]
- [31] Bonapart IE, Stevens HPJD, Kerver AJH, Rietveld AP. Rare complications of an odontogenic abscess; Mediastinitis, Thoracic empyema and Cardiac Tamponade. *J Oral Maxillofac Surg* 1995;53:610-613.

- [32] Robertson D. and Smith AJ (2009). The microbiology of the acute dental abscess. *Journal of Medical Microbiology* 58 (2): 155-172
- [33] Baumgartner, J. C., Khemaleelakul, S. U. & Xia, T. (2003). Identification of spirochetes (treponemes) in endodontic infections. *J Endod* 29, 794-797.[Medline]
- [34] Baumgartner, J. C., Siqueira, J. F., Jr, Xia, T. & Rocas, I. N. (2004). Geographical differences in bacteria detected in endodontic infections using polymerase chain reaction. *J Endod* 30, 141-144.[Medline]
- [35] Brook, I. (1987). Microbiology of retropharyngeal abscesses in children. *Am J Dis Child* 141, 202-204.[Abstract/Free Full Text]
- [36] Brook, I., Frazier, E. H. & Gher, M. E. (1991). Aerobic and anaerobic microbiology of periapical abscess. *Oral Microbiol Immunol* 6, 123-125.[Medline]
- [37] Cavrini, F., Pirani, C., Foschi, F., Montebugnoli, L., Sambri, V. & Prati, C. (2008). Detection of *Treponema denticola* in root canal systems in primary and secondary endodontic infections. A correlation with clinical symptoms. *New Microbiol* 31, 67-73.[Medline]
- [38] Chan, E. C. & McLaughlin, R. (2000). Taxonomy and virulence of oral spirochetes. *Oral Microbiol Immunol* 15, 1-9.[CrossRef][Medline]
- [39] Chavez de Paz Villanueva, L. E. (2002). *Fusobacterium nucleatum* in endodontic flare-ups. *Oral Surg Oral Med Oral Pathol Oral Radiol Endod* 93, 179-183.[CrossRef][Medline]
- [40] Dymock, D., Weightman, A. J., Scully, C. & Wade, W. G. (1996). Molecular analysis of microflora associated with dentoalveolar abscesses. *J Clin Microbiol* 34, 537-542.[Abstract]
- [41] Gomes, B. P., Jacinto, R. C., Pinheiro, E. T., Sousa, E. L., Zaia, A. A., Ferraz, C. C. & Souza-Filho, F. J. (2006). Molecular analysis of *Filifactor alocis*, *Tannerella forsythia*, and *Treponema denticola* associated with primary endodontic infections and failed endodontic treatment. *J Endod* 32, 937-940.[CrossRef][Medline]
- [42] Gorbach, S. L., Gilmore, W. C., Jacobus, N. V., Doku, H. C. & Tally, F. P. (1991). Microbiology and antibiotic resistance in odontogenic infections. *Ann Otol Rhinol Laryngol Suppl* 154, 40-42.[Medline]
- [43] Goumas, P. D., Naxakis, S. S., Papavasiliou, D. A., Moschovakis, E. D., Tsintzos, S. J. & Skoutelis, A. (1997). Periapical abscesses: causal bacteria and antibiotic sensitivity. *J Chemother* 9, 415-419.[Medline]
- [44] Kulekci, G., Inanc, D., Kocak, H., Kasapoglu, C. & Gumru, O. Z. (1996). Bacteriology of dentoalveolar abscesses in patients who have received empirical antibiotic therapy. *Clin Infect Dis* 23 (Suppl. 1), S51-S53.[Medline]
- [45] Kuriyama, T., Karasawa, T., Nakagawa, K., Yamamoto, E. & Nakamura, S. (2001). Incidence of beta-lactamase production and antimicrobial susceptibility of anaerobic gram-negative rods isolated from pus specimens of orofacial odontogenic infections. *Oral Microbiol Immunol* 16, 10-15.[CrossRef][Medline]
- [46] Siqueira, J. F., Jr & Rocas, I. N. (2004b). Simultaneous detection of *Dialister pneumosintes* and *Filifactor alocis* in endodontic infections by 16S rDNA-directed multiplex PCR. *J Endod* 30, 851-854.[CrossRef][Medline]

- [47] Siqueira, J. F., Jr & Rocas, I. N. (2004c). Treponema species associated with abscesses of endodontic origin. *Oral Microbiol Immunol* 19, 336-339.[CrossRef][Medline]
- [48] Siqueira, J. F., Jr, Rocas, I. N., Favieri, A., Oliveira, J. C. & Santos, K. R. (2001c). Polymerase chain reaction detection of *Treponema denticola* in endodontic infections within root canals. *Int Endod J* 34, 280-284.[CrossRef][Medline]
- [49] Siqueira, J. F., Rocas, I. N., De Uzeda, M., Colombo, A. P. & Santos, K. R. (2002a). Comparison of 16S rDNA-based PCR and checkerboard DNA-DNA hybridisation for detection of selected endodontic pathogens. *J Med Microbiol* 51, 1090-1096.[Abstract/Free Full Text]
- [50] Storie, W., Haug, R. H. & Lillich, T. T. (2001). The changing face of odontogenic infections. *Oral Maxillofac Surg* 59, 739-748.[CrossRef][Medline].



Maxillofacial Surgery

Edited by Prof. Leon Assael

ISBN 978-953-51-0627-2

Hard cover, 86 pages

Publisher InTech

Published online 23, May, 2012

Published in print edition May, 2012

How to reference

In order to correctly reference this scholarly work, feel free to copy and paste the following:

Babatunde O. Akinbami (2012). Aetio-Pathogenesis and Clinical Pattern of Orofacial Infections, Maxillofacial Surgery, Prof. Leon Assael (Ed.), ISBN: 978-953-51-0627-2, InTech, Available from:
<http://www.intechopen.com/books/maxillofacial-surgery/aetio-pathogenesis-and-clinical-pattern-of-orofacial-infections>

INTECH

open science | open minds

InTech Europe

University Campus STeP Ri
Slavka Krautzeka 83/A
51000 Rijeka, Croatia
Phone: +385 (51) 770 447
Fax: +385 (51) 686 166
www.intechopen.com

InTech China

Unit 405, Office Block, Hotel Equatorial Shanghai
No.65, Yan An Road (West), Shanghai, 200040, China
中国上海市延安西路65号上海国际贵都大饭店办公楼405单元
Phone: +86-21-62489820
Fax: +86-21-62489821

© 2012 The Author(s). Licensee IntechOpen. This is an open access article distributed under the terms of the [Creative Commons Attribution 3.0 License](#), which permits unrestricted use, distribution, and reproduction in any medium, provided the original work is properly cited.