

# Safe and Curative Brachytherapy Reirradiation with Organ-Sparing Hyaluronate Gel Injection

Kazushi Kishi, Yasutaka Noda and Morio Sato  
Wakayama Medical University,  
Japan

## 1. Introduction

In radiotherapy, sufficient dose delivery promises local cure [Hayashi, 2002; Okamoto, 2002; Wu, 2007] and reirradiation is as effective as the first radiotherapy. Dose dependency of the effect is also reported in reirradiation [Damast, 2010]. In the clinical situation, however, the use of reirradiation is limited because of the low tolerance level of surrounding normal tissue [Emami, 1991]. A significant incidence of late toxicity attributable to accumulated dose in various at-risk organs is reported [Salama, 2006; Wu, 2007]. In a survey of the attitudes of radiation oncologists, only one third (90 of 271) of participants responded that they would consider reirradiation for in-field failure after previous radical radiotherapy [Joseph, 2008].

Recent advancements in external beam radiation technology have enabled precision by beam set-up in image-guided radiotherapy (IGRT), accuracy in configuring dose distribution by intensity modified radiotherapy (IMRT), and adaptability to internal movements by real-time tracking techniques. However, surgery has been the only option for saving at-risk organs closely attached to the target. It is desirable to establish non-invasive or minimally invasive techniques for preserving these at-risk organs to enable safe and curative high-dose radiotherapy, even in the case of reirradiation.

- For the purpose of reirradiation, we devised a minimally invasive procedure using a modern high-molecular-weight hyaluronate polymer gel, whereby a planned distance is created between the target and at-risk organs by injecting the gel (Fig. 1) [Kishi, 2004 · 2006, 2007a, 2007b, 2009, Prada, 2007, 2009; Vordermark, 2008].

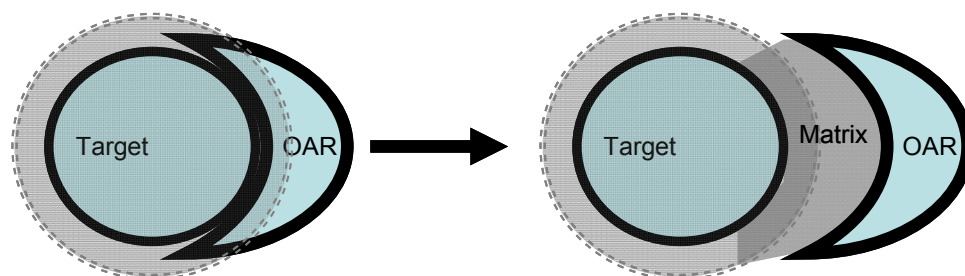


Fig. 1. An organ at risk (OAR) is displaced away from the zone of intensive irradiation (dotted circle) by the space created by an injected matrix.

In the first stage of our strategy, we aimed to treat recurrent disease requiring reirradiation with single-session high-dose-rate brachytherapy (HDRBT), reporting an effective decrease in estimated cumulative normal tissue complication probabilities (NTCP) to safer levels. In the second stage, we established this procedure for various difficult situations such as reirradiation of para-aortic lymphnode metastasis.

## 2. Materials and methods

### 2.1. Native-type hyaluronate as an injectable spacer

#### 2.1.1 Materials for injectable spacer

Historically, saline, autologous blood, olive oil, dextrose, hyaluronate (hyaluronic acid: HA), alginate gels, gelatin hydrogel, polytetrafluoroethylene sheets, and many other others materials have been used for the purpose of separating various tissues. We have used injectable spacers for risk-organ preservation during brachytherapy since 2004 [Kishi, 2004, 2007, 2007b]. Gel dissection has the features of both blunt dissection and hydrodissection, depending on its viscosity and the injection rate. Important considerations in selecting an injectable spacer include its chemical and biological inertness or activity, allergenicity, and the natural or artificial biodegradability of the material; the structure of the injected space is also an important factor, which is discussed later.

#### 2.1.2 Native-type hyaluronate molecules

The numerous roles of innate hyaluronate in the body include as a supportive component of structure, lubrication in joints, tissue protection, and wound healing. Hyaluronate (also called hyaluronic acid or hyaluronan) is an anionic, nonsulfated macromolecular glycosaminoglycan, composed of repeated disaccharide units of glucuronic acid and N-acetylglucosamine (Fig. 2), with a widely variable molecular weight. The native type is a single straight chain and exists widely, mainly as a constitutive molecule in the extracellular space of human and animal tissue. The molecular weight of constitutive hyaluronate is about three million Daltons. Degradation of hyaluronate occurs during inflammation and in the injury healing process, and also during bacterial infection. of innate or bacterial hyaluronidase to lower-molecular-weight hyaluronate and in further biodegradation. The degraded hyaluronate promotes tissue reactions.

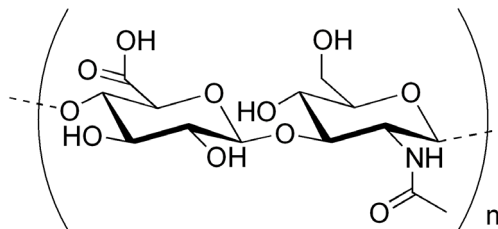


Fig. 2. Molecular structure of hyaluronate

The known cellular surface receptors CD44, RHAMM (receptor for hyaluronic-acid-mediated motility), and ICAM-1 (intercellular adhesion molecule-1) have hyaluronate binding sites that regulate cellular migration, proliferation, and inflammatory responses.

The binding activity is partially regulated by the molecular size of the hyaluronate: high-molecular-weight hyaluronate (HMW-HA) acts to almost completely inhibit the above responses, while low-molecular-weight hyaluronate has a promotional effect. Recent reports state that HMW-HA inhibits the production of matrix metalloproteinases [Hashizume, 2010] as well as vascular leakiness [Singleton, 2010], and that there is a size function of hyaluronate [Wolny, 2010]. It may be speculated that a partially combined huge mass made of ligand masks itself until degradation to a size small enough to interact diffusely with the receptors, and which is constitutively maintained in normal tissue. In contrast, artificially cross-linked hyaluronate may have no or various features of this inhibition-promotion mechanism.

In medical use, the effectiveness of native-type hyaluronate has been previously reported in the management of radiation dermatitis [41] [Primavera, 2006], in the prevention of postoperative adhesions in the pelvis [Kusunoki, 2005], and as antioxidant [Campo, 2008], depending on its molecular weight and concentration [Krasinski, 2009].

A high-molecular-weight hyaluronate that is commercially available for articular space injection (3.4 million Daltons of median molecular weight, 2.2 million of viscosity molecular size; Suvenyl, Chugai/Roche, Tokyo, Japan) is a non-animated native-type produced by genetically engineered bacterial fermentation. Its spacing effect generally lasts for a few to several hours depending on its concentration and the anatomic factors of the injected site. Contrast medium (5% Iopamiron 300mgI/ml, Bayer, Germany) is commonly added to saline mixture for visualization on X-ray CT images. Because its durability is concentration-dependent, enriched gel is prepared on demand.

## **2.2 Assessment of indication and eligibility**

To evaluate indications and the probability of effect and adverse effect, it is important to clarify previously irradiated doses and volumes in the involved at-risk organs, elapsed time after radiotherapy, and the present condition of the organs. In the case of no precise dose being available, a replicative simulation is required. According to published data, in most cases we may expect a certain degree of tissue recovery over the 6 months from the initial radiation [Abusaris, 2011; Nieder, 2006]. In addition to past history, the current status of at-risk organs is thought to be a significant determinant in assessing the vulnerability of the "recovered" status: hyperemia, edema, fibrosis, infection, hypoxia, atrophy, and other local pathophysiological conditions must be clarified and carefully interpreted. When any of these deteriorations is present, sufficient dose reduction is of greater importance.

## **2.3 Techniques of image-guided interventions and radiotherapy**

### **2.3.1 Preparation of hyaluronate gel mixture**

Premedication: Because the procedure is minimally invasive, sedative premedication is not mandatory, and in most cases an ordinary meal is recommended the morning of treatment to promote relaxation in the patient. Anxiolytic use of hydroxyzine pamoate or similar is recommended. However, careful individual medical management is required throughout the procedure in frail patients.

Keeping the patient awake: in terms of safety and precision, it is helpful for the patient to be able to report sensation during crucial needle maneuvers and during injection of the gel; therefore, deep sedation is not recommended if avoidable.

Use of sedatives: after completion of needle deployment, we recommend using benzodiazepam, which is effective in reducing post-traumatic psychological processing of the pain, anxiety, or fear immediately before and during the procedure.

Monitoring: the patient is connected to ECG, respiration, oxygen saturation, and blood pressure monitors, and covered with sterile drapes on the X-ray CT couch.

### **2.3.2 Needle deployment**

#### **2.3.2.1 Procedure**

CT land marking and local anesthesia: puncture points are determined using the first set of plain CT images covering the target, and 10–20 ml of 1% lidocaine solution is then injected into the subcutaneous space at the intended puncture site. As well as superficial skin markings, tentative placement of a few 23 G needles inserted to a depth of 2–6 cm around the target as internal landmarks is useful in geometric planning to a deep target under X-ray CT guidance.

We use Microselectron system applicator needles: 1.1 mm in external diameter and 8–20 cm in length. The applicator needles are inserted following the landmark needles and deployed under X-ray CT or real-time ultrasound guidance. The needles are advanced into (or minimally over, if necessary) the tumor and deployed as indicated. Fine-pitch (2 or 3 mm thick) X-ray CT images are then acquired and transferred to the treatment planning computer (Plato, Nucletron, Veenendaal, Netherlands).

#### **2.3.2.2 Special technical remarks regarding needle deployment**

- a. Bone and perivertebral intervention: Bone involvement is common and is a leading cause of cancer pain, either sensory or neuropathic. It is generally not difficult to pierce the involved bone through a window in which the healthy bony structure has been lost, irrespective of the existence of a calcified zone. A drill (e.g., a 13-gauge bone biopsy needle: Osteosite Bone Biopsy Needle; Cook, Canada) may be required to gain access through hard bone surface. In case of perivertebral needle insertion beneath the pleura, subpleural gel injection produces a safe space for needle insertion avoiding pulmonary.
- b. Needle-tip-eye's view: To negotiate a step-by-step safe path to a deep target, we build a scenario of what the needle-tip encounters (e.g., skin, subcutaneous adipose tissue, muscle fascia, muscle, inter-fascial adipose tissue, and possibly a nerve plexus) before reaching the target.
- c. Superficial lesions: We use a high-precision ultrasound system with 0.7 and 5.0 MHz (mostly 3.0–3.5 MHz) to examine superficial structures such as the dermis, epidermis, subcutaneous tissue, muscle, peritoneum, sub-fascial soft tissues, intestines, intestinal peristalsis, eyes, and vessels, as well as tumors; and to determine the infiltration range.
- d. Nerve plexus: The patient may experience suddenly increased pain when pressure from the needle insertion cause further stimulation to a nerve plexus. A swollen tumor causing pressure may be covered with a layer of irritated nerves; in this case, additional local anesthesia with lidocaine is generally effective. Use of denervative anesthesia with

phenol glycerol may be chosen here, but with the effect of masking future signals of local tumor recurrence.

## **2.4 Hyaluronic gel injection**

### **2.4.1 Preparation**

The appropriate volume, concentration, and timing of injection of hyaluronic acid gel depends on the anatomical structure of the site and the required duration of spacing. Higher concentration provides spacing time. Most commonly, 50–150 mL of 1 mg/ml hyaluronic acid saline solution is prepared. A concentration of 1 mg/mL is sufficient for injection immediately before the start of irradiation, lasting in most cases from 30 minutes to 4 hours, depending on the site and structure of injection.

### **2.4.2 Injection**

Injection into the space between the tumor and the risk organs is continued until a large enough thickness is obtained to create a margin of safety for the risk organ. If necessary, further injection is performed to maintain the space. Patency of the distance should be reconfirmed immediately before and after irradiation.

### **2.4.3 Confirmation**

The space created by the injected gel is monitored by ultrasound or X-ray CT to check for unexpected gel migration and to measure the thickness of the gel space.

## **2.5 Brachytherapy**

### **2.5.1 Trade-off principal**

The individual prescribed dose is generally a trade-off between the target dose and the dose to risk organs to avoid serious complications.

### **2.5.2 Treatment planning**

After contouring the target and surrounding critical organs, and recognizing the needle positions on the X-ray CT images imported into the planning computer, a treatment plan is created using 3D-inverse planning with graphic optimization (Plato version 13.7, Nucletron).

### **2.5.3 Evaluation of dose–volume histogram**

We assessed the desirable separation distances between the target and the risk organs, applying calculated total dose of the risk organs [Burman, 1991]. The target dose, risk organ dose, separation distance, and each patient's condition are individual trade-off factors. When it is difficult to prescribe the desirable dose, due to a low allowance for risk organ dose or due to difficulties encountered in creating a sufficient separation distance, the prescribed dose must be decreased and the distance recalculated step-by-step.

### 2.5.4 Estimation of equivalent dose

Equivalent dose in a conventional 2-Gy fraction schedule is calculated using the linear-quadratic (LQ) model and the linear-quadratic-linear (LQL) model [Astrahan, 2008], and is expressed as  $GyE_{LQ2, \alpha/\beta=3}$  and  $GyE_{LQL2, \alpha/\beta=3}$ , transition dose (DT) = 6, respectively, where  $\alpha/\beta = 3$  and DT = 6 for late effects of tumor and normal tissue. It should be noted that the LQ model may not provide a precise estimation for single-shot irradiation [Brenner, 2008; Kirkpatrick, 2008]. In the setting ( $\alpha/\beta = 3$ ), each single fraction dose of 20, 18, and 16 Gy was calculated to have an equivalent total dose of 92.0, 75.6, and 60.6 Gy, respectively, in a conventional 2-Gy fraction schedule.

### 2.6 Irradiation

After determining an optimal set of prescribed dose and separation distance parameters, the planning data are then sent to a remote after-loader system (Microelectron HDR Ir-192 version 2, Nucletron). In the present case series, a median dose of 18 Gy (range, 16–20 Gy) for GTV and a separation distance of not less than 1 cm was prescribed. The patient is moved to a shielded brachytherapy room and monitored by video-camera during the irradiation; vital data are also recorded. Irradiation generally takes 10–50 minutes, depending on the target size and dose.

### 2.7 Recovery to discharge

After the irradiation, we disconnect the patient from the monitoring equipment and remove the dwelling needles. Hemostasis is usually easy. The patient is moved to a couch to rest before being discharged.

### 2.8 Evaluation and follow-up

Patients are followed up at our outpatient clinic. Follow-up includes individual surveillance and management of adverse effects from the radiotherapy and the development of recurrent or metastatic disease. Tumor status and the patient's general condition are evaluated regularly. The first tumor evaluation is usually done 2 to 3 months after treatment. Any signs or symptoms of radiation-induced late toxicity are recorded and graded according to the latest common terminology criteria for adverse events [Trotti, 2003]. Pregabalin alone or in combination with opioids may be effective for residual or radiation-induced neuropathic pain [O'Connor, 2009].

## 3. Summary of clinical effects in the first 30 patients

We previously reported a series of 30 patients who were treated with reirradiation [Kishi, 2009]. The patients had received previous irradiation with a median dose of 60 Gy (range, 44–70 Gy) in 2-Gy fractions. All patients had subjective symptoms: 25 had pain, of which 21 was refractory to analgesics, and 25 complained of a local mass of which 3 were ulcerated. By location, there were 13 head and neck lesions, 3 breast, and 10 abdominal wall lesions: 2 each of bone, perineum, chest wall, intramuscular, and lymph nodal lesions; and 1 of the pelvic wall. Immediately before reirradiation, the median tumor (target) size was 4.0 cm (range, 2–13 cm), and median tumor volume was 18.8 cm<sup>3</sup> (range, 2.4–646.7 cm<sup>3</sup>).

Of the 30 patients, 15 had locoregional recurrence of the primary disease and 10 had distant metastasis (of which 3 were incision disseminations and 5 were regional nodal relapse). By number of lesions at the time of reirradiation, 13 patients had one, 8 patients had two, 6 patients had three, and 3 patients had four. The at-risk organs involved 29 skin areas, 4 intestinal, 3 mucosal, and 3 retinal areas. The median dose to these at-risk organs in the previous radiotherapy was 50 Gy (range: 40–70 Gy) in 22–35 fractions. A single-fraction dose of 18.0 Gy (median, equivalent to 75.6 Gy at an  $\alpha/\beta$  value of 3; range, 16–20 Gy) was prescribed to the tumor. The median created distance was 10 mm (range, 10–15 mm). Irradiation required approximately 10–50 minutes depending on the target size and dose. Gel injection resulted in a decrease in the dose to at-risk organs from  $9.1 \pm 0.9$  Gy to  $4.4 \pm 0.4$  Gy (mean  $\pm$  standard deviation,  $p < 0.01$ ), and the probability of normal tissue complications decreased from  $60.8\% \pm 12.6\%$  to  $16.1\% \pm 19.8\%$  ( $p < 0.01$ ). We observed distinct tumor shrinkage in 20 of 21 eligible patients, including tumor disappearance in 6 patients; pain reduction in 18 of 21 eligible patients; and no unexpected late toxicity greater than grade 2.

The median observation period was 19.5 months (range, 3–43 months). At the second month, a distinct decrease in tumor volume was observed in 20 (95%) of 21 eligible patients, including 6 (24%) of 25 eligible patients in whom the tumor had disappeared.

## 4. Application to various body sites

### 4.1 Head and neck reirradiation

#### a. General skin and mucosal preservation

Background: Prudent skin and mucosa preservation is generally required in reirradiation treatment for recurrent head and neck cancer after initial radiotherapy. The involved skin and mucosa can be moved away from the target when subcutaneous or submucosal gel injection is available. We can generally expect an additional distance of 1 cm or more, which will decrease the skin/mucosal dose by approximately 50% of that without HGI, and the thickness can easily be increased by further injection.

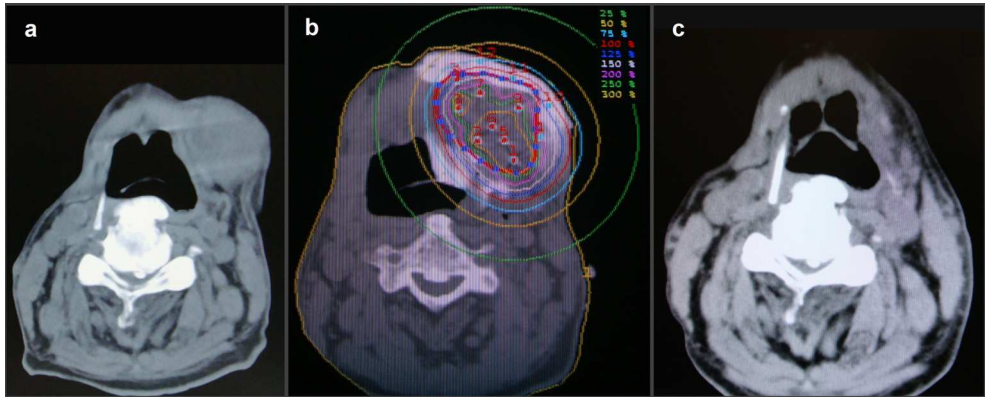
Case and technique presentation: An 84-year-old male patient with hemiparalysis after brain infarction developed a submandibular lymphnode metastasis from oral floor cancer. We injected gel into the submucosal and subcutaneous space surrounding the tumor to create a safe distance, and then delivered 18Gy ( $76.5\text{GyE}_{\text{LQ2}, \alpha/\beta=3}$ ) (Fig. 3).

#### b. Reirradiation to retropharyngeal lymphnode metastasis (mucosal preservation)

Background: Retropharyngeal node metastasis (RPNM) commonly occurs in the clinical course of head and neck cancers. The incidence of RPNM in oropharyngeal cancer has been reported as 27.5% [Gross, 2004], and post-surgical development of RPNM in hypopharyngeal cancer as 13.2% [Kamiyama, 2009]. This involvement has a significantly negative impact on the prognosis [Dirix, 2006], and there has been no safe and effective non-invasive or minimally invasive treatment for recurrence after radiotherapy.

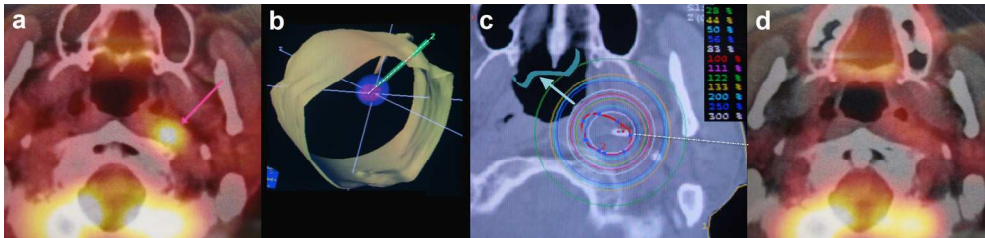
Case and technique presentation: A left retropharyngeal lymph node (Rouviere's node) metastasis was found in a 50-year-old man who complained of an abnormal sensation in his neck 1 year after left neck surgery for pharyngeal pouch cancer followed by 50 Gy of external beam radiotherapy. Despite chemotherapy, the tumor increased in size and the

symptoms worsened. The patient received reirradiation, as shown in Fig. 4, and has been healthy without any evidence of relapse for 4 years.



(a) Submandibular tumour before treatment. (b) The created distance measures approximately 1 cm. Injected gel is contrast enhanced. 18 Gy was delivered in a single fraction. (c) Six months after the brachytherapy.

Fig. 3. Skin and mucosal preservation in HDRBT by HGI.



(a) An applicator needle (dotted line) was inserted from the left side of the neck (b) and a single dose of 20 Gy (100% line) was prescribed (c). Part of the needle can be seen in the target. Note the higher-dose area at the target. The pharyngeal mucosa was shifted to the low-dose area following injection of hyaluronate during irradiation (thick arrow and ribbon). There is a remarkable decrease in FDG accumulation 2 months after the brachytherapy (d). This photograph has been published previously [Kishi, 2009].

Fig. 4. Reirradiation to retropharyngeal lymphnode metastasis. PET study reveals abnormal accumulation of FDG in the metastatic retropharyngeal lymphnode

#### 4.2 Abdominal/chest reirradiation

Numerous sites can be treated with this technique: chest wall, abdominal wall, various metastatic lymph nodes, adrenal gland metastasis, and parenchymal lesions. To date, curative reirradiation to paraaortic lymphnode metastasis has been one of the most difficult to safely achieve.

##### a. Reirradiation to paraaortic lymphnode metastasis:

Background: Paraaortic lymph nodal (PALN) metastasis is a frequent clinical sequel in various abdominopelvic malignancies, including pancreatic cancer, for which the



rationale for surgery is limited [Pavlidis, 2011]. Eradicative PALN reirradiation would be ideal, but a safe dose is usually limited by surrounding radiosensitive organs, particularly the intestines. In reirradiation, the spinal cord and kidneys, as well as the intestines, may narrow the range of available beam angles. To date, only a few reports have described reirradiation in the abdomen, and these report the use of palliative doses [Chou, 2001; Haque, 2009].

Case and technique presentation: We encountered a patient with pancreatic cancer who developed PALN metastasis as an in-field recurrence, 6 months after resection of pancreatic cancer with 50 Gy of preoperative radiotherapy. A single fraction of 18 Gy was delivered to the tumor (75.6 Gy equivalent in a conventional schedule calculated with the LQ model at  $\alpha/\beta = 2$  for the small intestines) and a total estimated D2cc (the minimum dose to the most irradiated volume of 2 cc) in the small intestines of 58.5 GyE<sub>LQ2,  $\alpha/\beta = 3$</sub>  with HGI; and 96 GyE<sub>LQ2,  $\alpha/\beta = 3$</sub>  without HGI. No complications were observed for 6 months. Three months after treatment, there was no FDG accumulation, tumor size had reduced, and the serum CA-19-9 value decreased from 5150 to 36.6 U/mL (normal range, <37.5). We consider that this case conclusively demonstrates that brachytherapy with HGI procedure by the paravertebral approach is safe and effective in reirradiation of PALN recurrence. The dosimetric and technical details of this case are to be published in the *Journal of Radiation Research* [Kishi, 2011b].

The paravertebral brachytherapy approach used in this case involved the application of a safe and reliable interventional procedure [Knelson, 1989] that is substantially unaffected by respiratory movement. This technique, under step-by-step X-ray CT guidance, achieved stable, precise needle deployment and gel injection.

### 4.3 Pelvic tumors

Also in the pelvic area, HDRBT with HGI may facilitate safe and effective reirradiation for recurrent primary lesions, lymph nodal or bone metastasis that have developed after radiotherapy to these areas [Kishi, 2011a]

#### a. Reirradiation to recurrent prostate cancer

In the treatment of prostate cancer, technological advancements in radiotherapy have enabled dose escalation to be performed safely. In intermediate- or high-risk prostate cancers, however, the reported local recurrence rate of 10%–30% remains high. A technique is required for further safe dose escalation for these refractory cancers, as well as a safe reirradiation technique for relapsed prostate cancer. Because the rectum is closely adjacent to the prostate, the radiotolerance limit of the rectum is generally lower than normal following curative external beam radiotherapy.

According to a summary in a review [van Vulpen, 2011] 5-year biological disease-free survival in six studies on reirradiation of prostate cancer was approximately only one third following initial curative dose treatment, and the incidences of grade 3 toxicities in the 11 studies on total 290 patients was approximately 4% of gastrointestinal toxicity and 14% of genitourinary toxicity, respectively. Further increase of toxicity should not be allowed in future attempts of dose escalation.

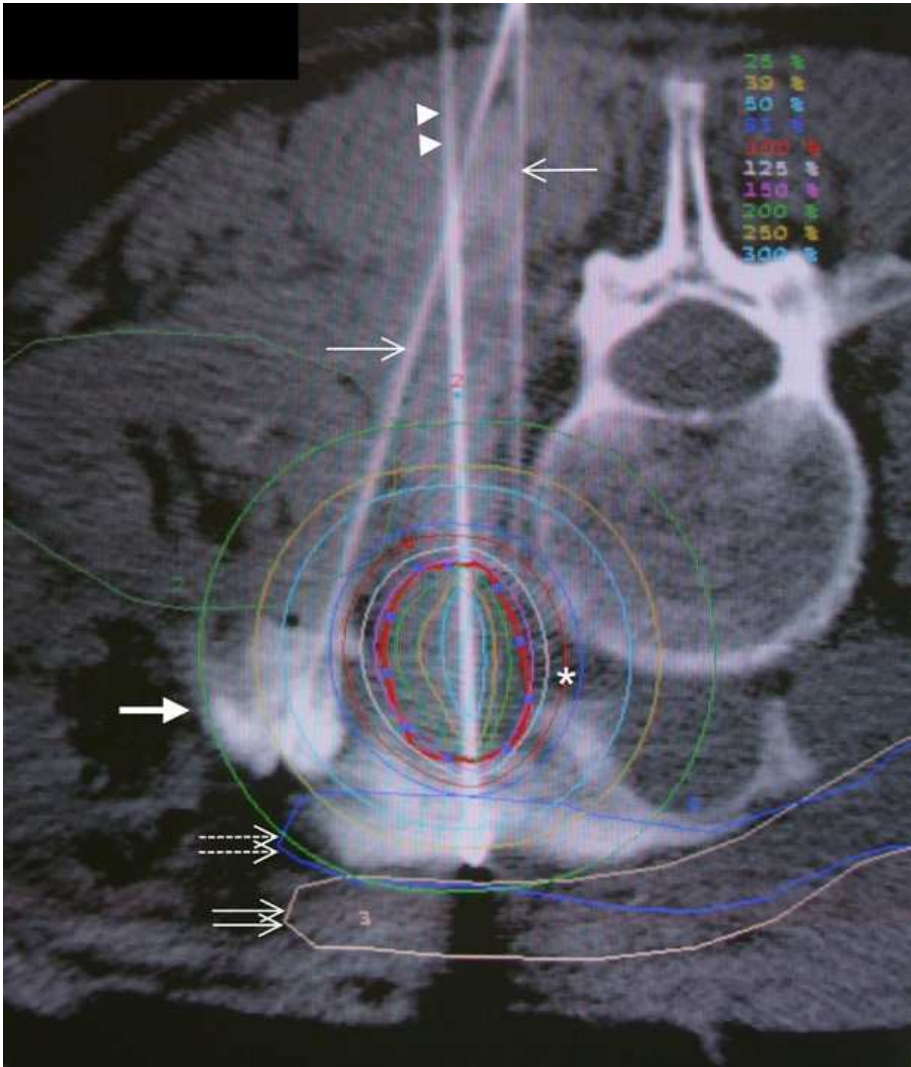

Fig. 5. Paravertebral approach and dose distribution. A small part of intestine was involved with more than 25% of the prescribed dose. Symbols: thick arrow, injected contrast-enhanced gel; thin arrows, injection needles; double arrowheads, brachytherapy applicator needles; double thin arrows, the closest part of small intestine shifted by HGL; double dotted arrows, superimposed lines of the original position of the closest part of small intestine; and thick line with dots, tumor contour. The oblique injection needle was inserted to move the second closest part of the small intestine, which was shifted aside. Isodose curves are 25%, 50%, 75%, 100% (asterisk), 125%, 150%, 200%, 250%, and 300%, in order from outermost to innermost. This figure taken from the original figures to be published in the *Journal of Radiation Research* [Kishi, 2011b].

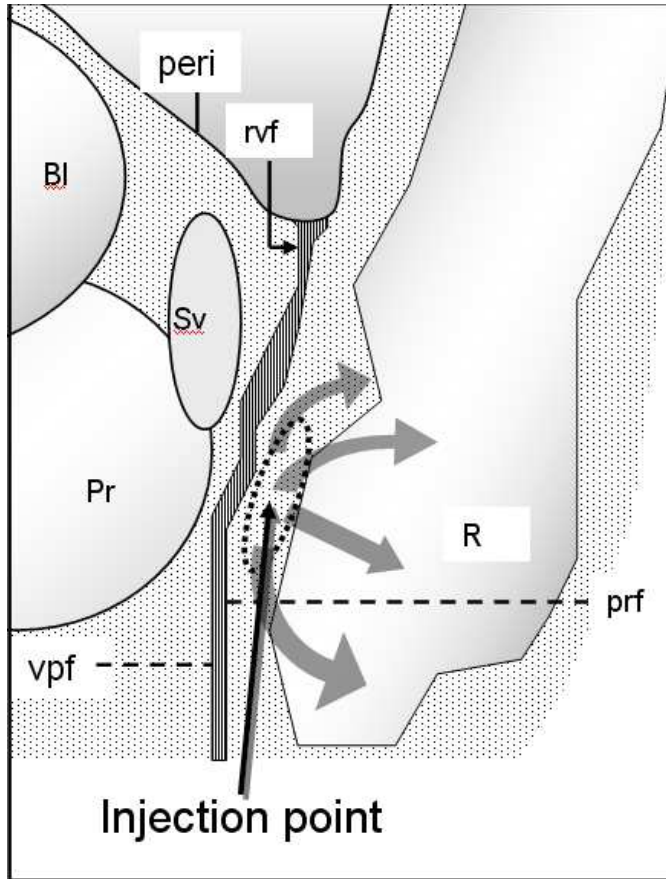


Fig. 6. Diagram showing the track of the injection needle to the injection point (dotted circle) in the anterior perirectal adipose tissue behind the rectal side of the rectovesical fascia (Denonvilliers' fascia). Gel injected from this point (half-tone arrows) flows into the perirectal and pararectal spaces to encase the rectum. Abbreviations (in alphabetical order): Bl, bladder; peri, peritoneum; Pr, prostate; prf, perirectal fascia; R, rectum; rvf, rectovesical fascia (Denonvilliers' fascia); Sv, seminal vesicle; vpf, vesicoprostatic fascia.

Case and technique presentation: In a patient with local recurrence of prostate cancer at 18 months after initial radiotherapy of  $61.8 \text{ Gy}_{\text{E}_{\text{LQ2}, \alpha/\beta = 3}}$  to the prostate, we prescribed  $16 \text{ Gy}$  ( $60.8 \text{ Gy}_{\text{E}_{\text{LQ2}, \alpha/\beta = 3}}$  or  $78.2 \text{ Gy}_{\text{E}_{\text{LQ2}, \alpha/\beta = 1.6}}$ ) of reirradiation HDRBT with HGI (Figs. 6, 7). The procedure was achieved in 10 minutes, without complications. Rectal D2cc for reirradiation was  $5.6 \text{ Gy}$  ( $9.58 \text{ Gy}_{\text{E}_{\text{LQ2}, \alpha/\beta = 3}}$ ). Compared with the initial radiation, the gel injection resulted in an improved therapeutic ratio. The patient was regularly followed up at our clinic: at over 3.5 years after reirradiation there was no evidence of recurrence or radiation-related toxicities greater than Grade 2, maintaining a nadir PSA level of  $0.03 \text{ ng/ml}$  without hormonal therapy. The details and treatment technique in this case have been reported in *Brachytherapy* [Kishi, 2011a].

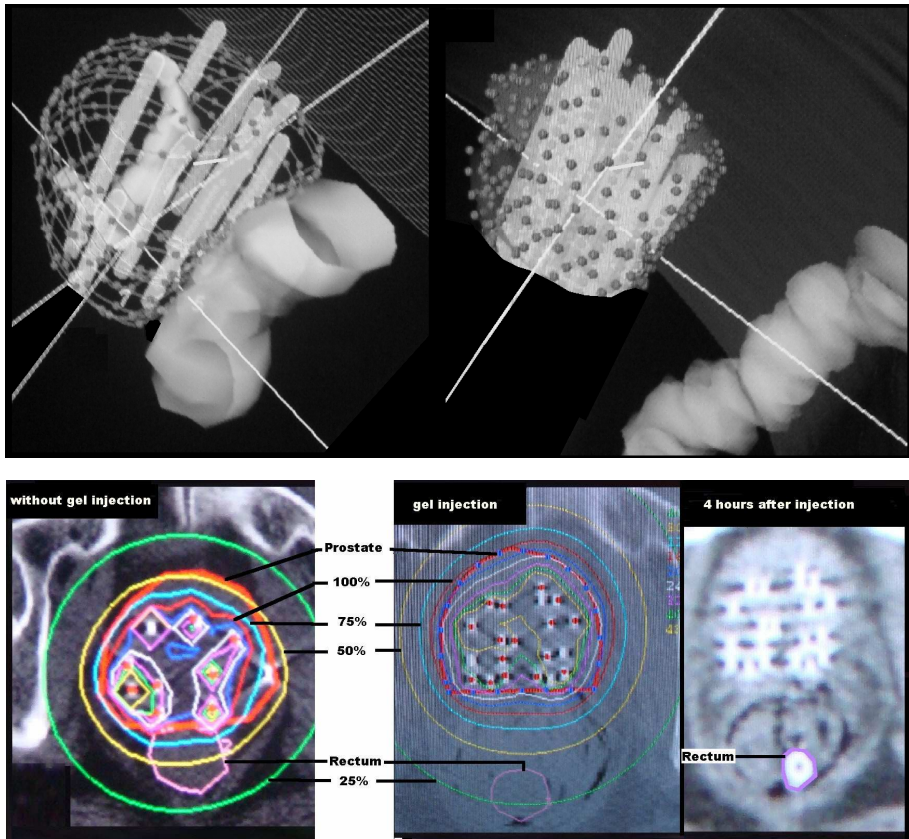


Fig. 7. Upper row: Reconstructed images of the rectum and the prostate for the initial (left) and reirradiation (right) brachytherapy (interval between dots on the prostate is 8 mm). Following gel injection, the rectum is shifted posteriorly and is reduced in size.

Lower row: Dose distribution curves for the initial (left) and reirradiation (middle) brachytherapies. The rectum and prostate are separated more than 25 mm (measurable with the dot interval). Thin layers of air are seen in and along the perirectal fascia. The relative positions of the rectum and prostate are maintained even 4 hours after injection (right). Contrast medium was injected into the rectum. The figures were from the original manuscript for that published in Brachytherapy [Kishi, 2011a].

## 5. Discussion

### 5.1 Problems to be addressed in reirradiation treatment

#### 5.1.1 Hypoxic environment of reirradiation target

Strong hypoxia in recurrent tumor after irradiation: Tumors larger than a certain size (>0.1 mm) usually develop hypoxic areas due to insufficient vascular supply. These areas are also

a sanctuary from hydrophilic chemotherapeutic agents, although launching waves of attacks may be effective. Cellular adaptation to hypoxia includes cell cycle arrest and resulting prolongation of repair deadlines, increased capability of anaerobic glycolysis resulting in lactic acid pooling, and cellular immigration programs towards more oxygen rich environments producing actins and losing cadherins. Previously irradiated tissue tends to be more hypoxic and therefore frequently more radioresistant. Popovtzer et al. reported 92% of the third recurrence was the in-field of the second irradiation (reirradiation), which occurred in 77% of median 68-Gy-reirradiated patients in 154 relapsed squamous head and neck cancer patients [Popovtzer, 2009]. This suggests much higher dose may be biologically required to overcome the reparability of recurrent tumor after initial radiotherapy. In this situation, HDRBT has the important advantage of providing high-dose areas close to the source inserted in the tumor. Furthermore, another possibility that an incomplete reirradiation may promote the immigration capability should be taken into account.

### 5.1.2 Diagnostic jeopardy

Precise judgment of a diagnosis of recurrence can be difficult because of tissue hypoxia induced by the radiotherapy itself and the biological responses that occur in and around the irradiated area. Diagnostic features for tumor recurrence includes, 1) increase in tumor size (especially new nodule protrusion), 2) revascularization in the tumor (not static revascularization around the tumor), and 3) strong increase in FDG-PET accumulation. Swelling of the tumor, emergence of a ring enhancement zone, and persistent weak or moderate appearance of FDG-PET accumulation in or around the irradiated tumor are often observed in reactive inflammatory phenomena, or tumor-related. Currently recommendable approach to make a differential diagnosis in these situations is only to rationally integrate and interpret the time course of PET-CT, enhanced MR, and MR diffusion imaging findings as well as the biological nature of the tumor cells as well as post-irradiation changes of involved normal tissues.

### 5.1.3 Occurrence of complications

In our previous report of reirradiation with a total accumulated target dose of 125.6 Gy (median)[Kishi, 2009], the actual incidence of complications was very low (0% directly related to the radiotherapy) than expected (16.1%) over a 19.5-month observation period. This may have occurred because we had created a sufficient safety margin in the gel spacing procedure, and because of the time interval from the previous radiation effect.

### 5.1.4 The problem of equivalent dose calculation

The LQ model may overestimate a single high-dose effect: the LQ model is well validated, experimentally and theoretically, allegedly up to approximately 10 Gy/fraction, and is reasonable for clinical use up to a large dose of about 18 Gy per fraction in fractionated schedules [Brenner, 2008]. Recent studies revealed the significant overestimation of large single-dose treatment effect calculated by the LQ model, in both clinical and experimental data [Astrahan, 2008; Iwata, 1984; Kirkpatrick, 2008]. Overestimation of the single high-dose effect tends to be greater in a dose larger than  $DT = 2 \times (\alpha/\beta \text{ ratio})$  [Astrahan, 2008]. In the LQL model, a linear function works over the range of DT Gy. The LQL model is currently under evaluation.

### 5.1.5 Interval repair

An interval of more than 6 months was considered to increase spinal tolerance level [Nieder, 2005; 2006]. Several authors reported the effectiveness of reirradiation by external beam [Okamoto, 2002; Oksuz, 2004; Sulman, 2008; Wu, 2007; Wurschmidt, 2008] with a relatively small incidence of grade 3–4 toxicity for a cumulative dose of 110–117 Gy, where the median intervals ranged from 13 to 92 months. However we must be careful to apply some idea of interval repair because an individual tissue tolerance differs not only by the dose and the interval.

### 5.2 Injectable material

1. Artificial cross-linked hyaluronate: There are long-lasting variants of hyaluronate that are artificially cross-linked and resistant to biodegradation, some of which are durable for months (Restylane SubQ, Q-med, Uppsala, SWEDEN)[Restylane®-International] and are used as a filler by subcutaneous injection in cosmetic augmentations. Unlike native-type hyaluronate, no biological research, including the receptor-mediated process, is available for this variant. Use of this type of hyaluronate was reported by Prada et al. for creating and maintaining a space during IMRT, HDRBT, and LDRBT for prostate cancer [Prada, 2007, 2009]. In response, Vordermark et al. proposed that a material with a faster resolution would be suitable for application to HDRIBT [Vordermark, 2008]. These long-lasting hyaluronate implants may cause immune [Hamilton, 2007] or inflammatory reactions [Arron, 2007], or infections [Christensen, 2009] [Arron, 2007; Edwards, 2007; Ghislanzoni, 2006; Wiest, 2009; Wolfram, 2006], and have been surgically removed from some patients [Arron, 2007; Edwards, 2007; Ghislanzoni, 2006; Wiest, 2009; Wolfram, 2006].
2. Dextrose solution: Dextrose solution is one of the most commonly used spacers. The low viscosity of the fluid makes it difficult to create an effective durable space, meaning that a large dose is generally required. A previous study reported that 625 ml (range, 250–1,200 mL) of 5% dextrose in water was required to separate organs (by approximately 1 cm according to the published figures) during radiofrequency ablation [Arellano, 2010]. Electrolyte imbalance and fluid overload must be carefully monitored in this situation.

### 5.3 Time and cost-effectiveness of the present method

The cost of native-type high-molecular-weight hyaluronate is US\$10–US\$15 for a 2.5 ml (2.5 mg) vial, which is approximately one-sixtieth the cost of the artificially cross-linked durable type. The time required to complete the procedure is 10–15 minutes in most cases; thus, HGI is highly time- and cost-effective.

### 5.4 Further possibilities

As well as its use for creating a safe distance, or enabling curative radiotherapy that has been impossible until now, HGI has potential for further development. This spacing method will safely guide the insertion of larger therapeutic devices and/or organs without requiring an intensive surgical procedure. This technique has the potential to affect a profound shift in the manner in which physicians consider retreatment options for previously irradiated tissue, in a manner hitherto unknown.

## 6. Summary and conclusion

### 6.1 Background

In this chapter we describe a technical solution for problems associated with reirradiation. Radiotherapy is singularly effective in cancer control, even in a second treatment (reirradiation). Sufficient dose delivery may promise a local cure, but reirradiation is usually limited due to the tolerance level of surrounding normal tissue.

### 6.2 Method

To safely perform high-dose reirradiation treatment, our radiation oncologists and interventional radiologists cooperated to develop a novel procedure based on a recent advance in molecular science. Our aim was to create a safe distance in critical radiotherapy by injecting native-type high-molecular-weight hyaluronic acid between the target and organs at risk under ultrasound or X-ray CT guidance. The procedure is termed hyaluronic gel injection (HGI). The material protects tissues from injury and inflammation, and is reported in recent studies to inhibit cell migration and proliferation mediated by surface receptors including CD44. The injection is a quick and minimally invasive procedure performed with a 21-gauge needle, which, unlike surgery, enables a stepwise or fractionated schedule of outpatient treatment for multiple lesions.

During the period that the created distance is maintained by the injected gel, typically a few hours, a single-session irradiation is performed by high-dose-rate brachytherapy (HDRBT) with CT-based 3D planning. We reported that this injection procedure provides a significant reduction in normal tissue complication probability (NTCP) in various situations, enabling doses ranging from 15 to 20 Gy to be safely delivered to the target without significantly involving surrounding at-risk organs.

### 6.3 Result

The biological equivalent dose for the dose range was 50.4–92 Gy for a conventional radiotherapy schedule at  $\alpha/\beta = 3$ , fulfilling the individual dose requisition for each curative purpose. In comparative analysis of our clinical records, we found that the therapeutic ratio (TR) of target dose to risk-organ dose was increased by approximately three times by this HGI procedure. To the best of our knowledge, other than that for surgery, this enhancement factor of TR is the largest value found to date. In our published report of 30 patients with recurrent cancer after 60 Gy (median) of previous external beam treatment, reirradiation by HDRBT with HGI resulted in distinct tumor shrinkage in 95%; and significant pain reduction, and Grade 2 or larger early and late toxicity in 95%, 85%, and 0%, respectively, during the 19.5-month observation period. To date, we have reported reirradiation in cases of paraaortic lymphnode metastasis, recurrent lung cancer, uterine cancer, prostate cancer, and head and neck cancer, among others, with long-lasting curative effect.

### 6.4 Conclusion

This risk-organ-sparing preservation procedure offers safe and efficient reirradiation treatment for recurrent cancer patients, in terms of longstanding local cancer control without significant physical stress, as well as providing pain reduction.

## 7. Acknowledgements

This research and publication was supported in part by a Grant-in-Aid for Scientific Research from the Ministry of Education, Culture, Sports, Science and Technology, Japan (MEXT Grant), grant number 23659595.

## 8. References

- Abusaris, H., P.R. Storchi, R.P. Brandwijk, &J.J. Nuyttens, (2011(epub)). Second re-irradiation: Efficacy, dose and toxicity in patients who received three courses of radiotherapy with overlapping fields. *Radiother Oncol*, Vol. 99,No.2, pp. 235-239
- Arellano, R.S., V.L. Flanders, S.I. Lee, P.R. Mueller, &D.A. Gervais, (2010). Imaging-guided percutaneous radiofrequency ablation of retroperitoneal metastatic disease in patients with gynecologic malignancies: clinical experience with eight patients. *AJR Am J Roentgenol*, Vol. 194,No.6, pp. 1635-1638
- Arron, S.T. and I.M. Neuhaus, (2007). Persistent delayed-type hypersensitivity reaction to injectable non-animal-stabilized hyaluronic acid. *J Cosmet Dermatol*, Vol. 6,No.3, pp. 167-171
- Astrahan, M. (2008). Some implications of linear-quadratic-linear radiation dose-response with regard to hypofractionation. *Med Phys*, Vol. 35,No.9, pp. 4161-4172
- Brenner, D.J. (2008). The linear-quadratic model is an appropriate methodology for determining isoeffective doses at large doses per fraction. *Semin Radiat Oncol*, Vol. 18,No.4, pp. 234-239
- Burman, C., G.J. Kutcher, B. Emami, &M. Goitein, (1991). Fitting of normal tissue tolerance data to an analytic function. *Int J Radiat Oncol Biol Phys*, Vol. 21,No.1, pp. 123-135
- Campo, G., A. Avenoso, S. Campo, A. D'Ascola, P. Traina, D. Samr̄□, &A. Calatroni, (2008). The antioxidant effect exerted by TGF-1beta-stimulated hyaluronan production reduced NF-kB activation and apoptosis in human fibroblasts exposed to FeSo4 plus ascorbate. *Mol Cell Biochem*, Vol. 311,No.1-2, pp. 167-177
- Chou, H.H., C.C. Wang, C.H. Lai, J.H. Hong, K.K. Ng, T.C. Chang, C.J. Tseng, C.S. Tsai, &J.T. Chang, (2001). Isolated paraaortic lymph node recurrence after definitive irradiation for cervical carcinoma. *Int J Radiat Oncol Biol Phys*, Vol. 51,No.2, pp. 442-448
- Christensen, L.H., (2009). Host tissue interaction, fate, and risks of degradable and nondegradable gel fillers. *Dermatol Surg*, Vol. 35 Suppl 21612-1619
- Damast, S., J. Wright, M. Bilsky, M. Hsu, Z. Zhang, M. Lovelock, B. Cox, J. Zatcky, &Y. Yamada, (2010). Impact of Dose on Local Failure Rates after Image-Guided Reirradiation of Recurrent Paraspinal Metastases. *Int J Radiat Oncol Biol Phys*, Vol.
- Dirix, P., S. Nuyts, B. Bussels, R. Hermans, &W. Van den Bogaert, (2006). Prognostic influence of retropharyngeal lymph node metastasis in squamous cell carcinoma of the oropharynx. *International Journal of Radiation Oncology\*Biolog\*Physics*, Vol. 65,No.3, pp. 739-744
- Edwards, P.C. and J.E. Fantasia, (2007). Review of long-term adverse effects associated with the use of chemically-modified animal and nonanimal source hyaluronic acid dermal fillers. *Clin Interv Aging*, Vol. 2,No.4, pp. 509-519




- Emami, B., J. Lyman, A. Brown, L. Coia, M. Goitein, J.E. Munzenrider, B. Shank, L.J. Solin, &M. Wesson, (1991). Tolerance of normal tissue to therapeutic irradiation. *Int J Radiat Oncol Biol Phys*, Vol. 21,No.1, pp. 109-122
- Ghislanzoni, M., F. Bianchi, M. Barbareschi, &E. Alessi, (2006). Cutaneous granulomatous reaction to injectable hyaluronic acid gel. *Br J Dermatol*, Vol. 154,No.4, pp. 755-758
- Gross, N.D., T.W. Ellingson, M.K. Wax, J.I. Cohen, &P.E. Andersen, (2004). Impact of retropharyngeal lymph node metastasis in head and neck squamous cell carcinoma. *Arch Otolaryngol Head Neck Surg*, Vol. 130,No.2, pp. 169-173
- Hamilton, R., J. Strobos, &N. Adkinson, (2007). Immunogenicity studies of cosmetically administered nonanimal-stabilized hyaluronic acid particles. *Dermatol Surg*, Vol. 33,No.suppl.2, pp. s176-s185
- Haque, W., C.H. Crane, S. Krishnan, M.E. Delclos, M. Javle, C.R. Garrett, R.A. Wolff, &P. Das, (2009). Reirradiation to the abdomen for gastrointestinal malignancies. *Radiat Oncol*, Vol. 455
- Hashizume, M. and M. Mihara, (2010). High molecular weight hyaluronic acid inhibits IL-6-induced MMP production from human chondrocytes by up-regulating the ERK inhibitor, MKP-1. *Biochem Biophys Res Commun*, Vol. 403,No.2, pp. 184-189
- Hayashi, S., H. Hoshi, &T. Iida, (2002). Reirradiation with local-field radiotherapy for painful bone metastases. *Radiat Med*, Vol. 20,No.5, pp. 231-236
- Iwata, S., S. Miyauchi, &M. Takehana, (1984). Biochemical studies on the use of sodium hyaluronate in the anterior eye segment. I. Variation of protein and ascorbic acid concentration in rabbit aqueous humor. *Curr Eye Res*, Vol. 3,No.4, pp. 605-610
- Joseph, K.J., Z. Al-Mandhari, N. Pervez, M. Parliament, J. Wu, S. Ghosh, P. Tai, J. Lian, &W. Levin, (2008). Reirradiation After Radical Radiation Therapy: A Survey of Patterns of Practice Among Canadian Radiation Oncologists. *Int J Radiat Oncol Biol Phys*, Vol.
- Kamiyama, R., M. Saikawa, &S. Kishimoto, (2009). Significance of retropharyngeal lymph node dissection in hypopharyngeal cancer. *Jpn J Clin Oncol*, Vol. 39,No.10, pp. 632-637
- Kirkpatrick, J.P., J.J. Meyer, &L.B. Marks, (2008). The linear-quadratic model is inappropriate to model high dose per fraction effects in radiosurgery. *Semin Radiat Oncol*, Vol. 18,No.4, pp. 240-243
- Kishi, K., H. Adati, &K. Takada, Implants for radiation therapy, in *Patent publication bulletin*, J.P. Office, Editor. 2004, Kuraray Medical: Japan.
- Kishi, K., M. Sato, S. Shirai, T. Sonomura, &R. Yamama, (2011a). Reirradiation of prostate cancer with rectum preservation: Eradicative high-dose-rate brachytherapy with natural type hyaluronate injection. *Brachytherapy*, Vol.
- Kishi, K., S. Shirai, M. Sato, &T. Sonomura, (2007a). Computer-aided preservation of risk organs in critical brachytherapy by tissue spacing with percutaneous injection of hyaluronic acid solution. *Int J Radiat Oncol Biol Phys*, Vol. 69,No.3, pp. S568-S569
- Kishi, K., S. Shirai, M. Sato, T. Sonomura, &K. Tanaka. (2007b) Preservation of risk organs in critical brachytherapy by tissue spacing with percutaneous injection. in *The 5th Japan-US Cancer Therapy Symposium & The 5th S. Takahashi Memorial Joint Symposium.*: The 5th Japan-US Cancer Therapy Symposium & The 5th S. Takahashi Memorial Joint Symposium Committee. Sendai, Japan

- Kishi, K., T. Sonomura, S. Shirai, Y. Noda, M. Sato, M. Kawai, &H. Yamaue, (2011b). Brachytherapy reirradiation with hyaluronate gel injection of paraaortic lymphnode metastasis of pancreatic cancer: paravertebral approach - A technical report with a case -. *J Radiat Res*, Vol. In press.
- Kishi, K., T. Sonomura, S. Shirai, M. Sato, &K. Tanaka, (2009). Critical organ preservation in reirradiation brachytherapy by injectable spacer. *Int J Radiat Oncol Biol Phys*, Vol. 75, No.2, pp. 587-594
- Kishi, K., K. Takifuji, S. Shirai, T. Sonomura, M. Sato, &H. Yamaue, (2006). Brachytherapy technique for abdominal wall metastases of colorectal cancer: ultrasound-guided insertion of applicator needle and a skin preservation method. *Acta Radiol*, Vol. 47, No.2, pp. 157-161
- Knelson, M., J. Haaga, H. Lazarus, C. Ghosh, F. Abdul-Karim, &K. Sorenson, (1989). Computed tomography-guided retroperitoneal biopsies. *J Clin Oncol*, Vol. 7, No.8, pp. 1169-1173
- Krasinski, R., H. Tchorzewski, &P. Lewkowicz, (2009). Antioxidant effect of hyaluronan on polymorphonuclear leukocyte-derived reactive oxygen species is dependent on its molecular weight and concentration and mainly involves the extracellular space. *Postepy Hig Med Dosw (Online)*, Vol. 63205-212
- Kusunoki, M., H. Ikeuchi, H. Yanagi, M. Noda, H. Tonouchi, Y. Mohri, K. Uchida, Y. Inoue, M. Kobayashi, C. Miki, &T. Yamamura, (2005). Bioresorbable hyaluronate-carboxymethylcellulose membrane (Septrafilm) in surgery for rectal carcinoma: a prospective randomized clinical trial. *Surg Today*, Vol. 35, No.11, pp. 940-945
- Nieder, C., A.L. Grosu, N.H. Andratschke, &M. Molls, (2005). Proposal of human spinal cord reirradiation dose based on collection of data from 40 patients. *Int J Radiat Oncol Biol Phys*, Vol. 61, No.3, pp. 851-855
- Nieder, C., A.L. Grosu, N.H. Andratschke, &M. Molls, (2006). Update of human spinal cord reirradiation tolerance based on additional data from 38 patients. *Int J Radiat Oncol Biol Phys*, Vol. 66, No.5, pp. 1446-1449
- O'Connor, A.B. and R.H. Dworkin, (2009). Treatment of neuropathic pain: an overview of recent guidelines. *Am J Med*, Vol. 122, No.10 Suppl, pp. S22-32
- Okamoto, Y., M. Murakami, E. Yoden, R. Sasaki, Y. Okuno, T. Nakajima, &Y. Kuroda, (2002). Reirradiation for locally recurrent lung cancer previously treated with radiation therapy. *Int J Radiat Oncol Biol Phys*, Vol. 52, No.2, pp. 390-396
- Oksuz, D.C., G. Meral, O. Uzel, P. Cagatay, &S. Turkan, (2004). Reirradiation for locally recurrent nasopharyngeal carcinoma: treatment results and prognostic factors. *Int J Radiat Oncol Biol Phys*, Vol. 60, No.2, pp. 388-394
- Pavlidis, T.E., E.T. Pavlidis, &A.K. Sakantamis, Current opinion on lymphadenectomy in pancreatic cancer surgery. *Hepatobiliary Pancreat Dis Int*, Vol. 10, No.1, pp. 21-25
- Popovtzer, A., I. Gluck, D.B. Chepeha, T.N. Teknos, J.S. Moyer, M.E. Prince, C.R. Bradford, &A. Eisbruch, (2009). The Pattern of Failure After Reirradiation of Recurrent Squamous Cell Head and Neck Cancer: Implications for Defining the Targets. *Int J Radiat Oncol Biol Phys*, Vol.
- Prada, P.J., J. Fernandez, A.A. Martinez, A. de la Rúa, J.M. Gonzalez, J.M. Fernandez, &G. Juan, (2007). Transperineal injection of hyaluronic acid in anterior perirectal fat to decrease rectal toxicity from radiation delivered with intensity modulated

- brachytherapy or EBRT for prostate cancer patients. *Int J Radiat Oncol Biol Phys*, Vol. 69, No. 1, pp. 95-102
- Prada, P.J., H. Gonzalez, C. Menendez, A. Llana, J. Fernandez, E. Santamarta, & P.P. Ricarte, (2009). Transperineal injection of hyaluronic acid in the anterior perirectal fat to decrease rectal toxicity from radiation delivered with low-dose-rate brachytherapy for prostate cancer patients. *Brachytherapy*, Vol. 8, No. 2, pp. 210-217
- Primavera, G., M. Carrera, E. Berardesca, P. Pinnaro, M. Messina, & G. Arcangeli, (2006). A double-blind, vehicle-controlled clinical study to evaluate the efficacy of MAS065D (XClair), a hyaluronic acid-based formulation, in the management of radiation-induced dermatitis. *Cutan Ocul Toxicol*, Vol. 25, No. 3, pp. 165-171
- Restylane®-International. Restylane. [cited 2010 1st Dec.]; Available from: <http://www.restylane.com/>.
- Salama, J.K., E.E. Vokes, S.J. Chmura, M.T. Milano, J. Kao, K.M. Stenson, M.E. Witt, & D.J. Haraf, (2006). Long-term outcome of concurrent chemotherapy and reirradiation for recurrent and second primary head-and-neck squamous cell carcinoma. *Int J Radiat Oncol Biol Phys*, Vol. 64, No. 2, pp. 382-391
- Singleton, P.A., T. Mirzapourzadeh, Y. Guo, S. Sammani, N. Mambetsariev, F.E. Lennon, L. Moreno-Vinasco, & J.G. Garcia, (2010). High-molecular-weight hyaluronan is a novel inhibitor of pulmonary vascular leakiness. *Am J Physiol Lung Cell Mol Physiol*, Vol. 299, No. 5, pp. L639-651
- Sulman, E.P., D.L. Schwartz, T.T. Le, K.K. Ang, W.H. Morrison, D.I. Rosenthal, A. Ahamad, M. Kies, B. Glisson, R. Weber, & A.S. Garden, (2008). Imrt Reirradiation of Head and Neck Cancer-Disease Control and Morbidity Outcomes. *Int J Radiat Oncol Biol Phys*, Vol. 71, No. 1, pp. 316-317
- Trotti, A., A.D. Colevas, A. Setser, V. Rusch, D. Jaques, V. Budach, C. Langer, B. Murphy, R. Cumberlin, C.N. Coleman, & P. Rubin, (2003). CTCAE v3.0: development of a comprehensive grading system for the adverse effects of cancer treatment. *Semin Radiat Oncol*, Vol. 13, No. 3, pp. 176-181
- van Vulpen, M., (2011). Prostate Cancer, In: *Re-Irradiation: New Frontiers*, C. Nieder and J.A. Langendijk (Ed.), 143-153, Springer, ISBN 978-3642124679 New York
- Vordermark, D., M. Guckenberger, K. Baier, & K. Markert, (2008). Transperineal injection of hyaluronic acid in anterior perirectal fat to decrease rectal toxicity from radiation delivered with intensity-modulated brachytherapy or EBRT for prostate cancer patients: In regard to Prada et al. . *Int J Radiat Oncol Biol Phys*, Vol. 71, No. 1, pp. 316-317
- Wiest, L.G., W. Stolz, & J.A. Schroeder, (2009). Electron microscopic documentation of late changes in permanent fillers and clinical management of granulomas in affected patients. *Dermatol Surg*, Vol. 35 Suppl 21681-1688
- Wolfram, D., A. Tzankov, & H. Piza-Katzer, (2006). Surgery for foreign body reactions due to injectable fillers. *Dermatology*, Vol. 213, No. 4, pp. 300-304
- Wolny, P.M., S. Banerji, C. Gounou, A.R. Brisson, A.J. Day, D.G. Jackson, & R.P. Richter, (2010). Analysis of CD44-hyaluronan interactions in an artificial membrane system: insights into the distinct binding properties of high and low molecular weight hyaluronan. *J Biol Chem*, Vol. 285, No. 39, pp. 30170-30180
- Wu, S.X., D.T. Chua, M.L. Deng, C. Zhao, F.Y. Li, J.S. Sham, H.Y. Wang, Y. Bao, Y.H. Gao, & Z.F. Zeng, (2007). Outcome of fractionated stereotactic radiotherapy for 90

- patients with locally persistent and recurrent nasopharyngeal carcinoma. *Int J Radiat Oncol Biol Phys*, Vol. 69, No. 3, pp. 761-769
- Wurschmidt, F., J. Dahle, C. Petersen, C. Wenzel, M. Kretschmer, & C. Bastian, (2008). Reirradiation of recurrent breast cancer with and without concurrent chemotherapy. *Radiat Oncol*, Vol. 328



## **Brachytherapy**

Edited by Dr. Kazushi Kishi

ISBN 978-953-51-0602-9

Hard cover, 128 pages

**Publisher** InTech

**Published online** 25, April, 2012

**Published in print edition** April, 2012

Importance of brachytherapy is currently increasing in cancer therapy. In brachytherapy each treatment is best fitted by physician's hand, and appropriate arrangement and selection of radiation sources facilitates the fitting. This book is full of essences to make a breakthrough in radiation oncology by brachytherapy. I hope this book will encourage all people related. Contents 1: problem of currently popular dosimetric method; 2: Monte Carlo dose simulation of ruthenium-106/rhodium-106 eyes applicators; 3. Progress in Californium-252 neutron brachytherapy; 4. Clinical aspect of endobronchial brachytherapy in central airway tumor obstruction; 5. Review from principle and techniques of Iodine-125 production at nuclear reactor plant to their clinical practice in prostate cancer treatment; 6. Stereotactic Brachytherapy for Brain Tumors using Iodine-125 seed; 7. A brachytherapy procedure with organ-sparing hyaluronate gel injection for safe and eradicated reirradiation.

### **How to reference**

In order to correctly reference this scholarly work, feel free to copy and paste the following:

Kazushi Kishi, Yasutaka Noda and Morio Sato (2012). Safe and Curative Brachytherapy Reirradiation with Organ-Sparing Hyaluronate Gel Injection, Brachytherapy, Dr. Kazushi Kishi (Ed.), ISBN: 978-953-51-0602-9, InTech, Available from: <http://www.intechopen.com/books/brachytherapy/a-new-technique-to-save-organs-at-risk-in-brachytherapy>

# **INTECH**

open science | open minds

### **InTech Europe**

University Campus STeP Ri  
Slavka Krautzeka 83/A  
51000 Rijeka, Croatia  
Phone: +385 (51) 770 447  
Fax: +385 (51) 686 166  
[www.intechopen.com](http://www.intechopen.com)

### **InTech China**

Unit 405, Office Block, Hotel Equatorial Shanghai  
No.65, Yan An Road (West), Shanghai, 200040, China  
中国上海市延安西路65号上海国际贵都大饭店办公楼405单元  
Phone: +86-21-62489820  
Fax: +86-21-62489821

© 2012 The Author(s). Licensee IntechOpen. This is an open access article distributed under the terms of the [Creative Commons Attribution 3.0 License](#), which permits unrestricted use, distribution, and reproduction in any medium, provided the original work is properly cited.