

# Reconstructive Biliary Surgery in the Treatment of Iatrogenic Bile Duct Injuries

Beata Jabłońska and Paweł Lampe  
*Medical University of Silesia in Katowice,  
Department of Digestive Tract Surgery  
Poland*

## 1. Introduction

The aim of this chapter is to present different types of biliary reconstructions used in the surgical treatment of iatrogenic bile duct injuries (IBDI).

IBDI remain an important problem in gastrointestinal surgery. The most frequently, they are caused by laparoscopic cholecystectomy which is one of the commonest surgical procedure in the world. The early and proper diagnostics of IBDI is very important for surgeons and gastroenterologists, because unrecognized IBDI lead to serious complications such as biliary cirrhosis, hepatic failure and death. Choice of the proper treatment of IBDI is very important, because it may avoid these serious complications and improve quality of life in patients. Non-invasive, percutaneous radiological and endoscopic techniques are recommended as initial treatment of IBDI. When endoscopic treatment is not effective, surgical management is considered. The goal of surgical treatment is to reconstruct the proper bile flow to the alimentary tract. In order to achieve this goal, many techniques are used. There are contradictory reports on the effectiveness of bile duct reconstruction methods in the literature.

## 2. Historical perspectives of reconstructive biliary surgery

The first descriptions of the anatomy of the liver and bile ducts originate 2000 years BC in Babylon. The presence of gallbladder stones were found in mummy priestess who lived in the eleventh century BC. Historical records derived from ancient Mesopotamia, Greece, Egypt and Rome, also demonstrate the presence of biliary tract diseases in those days. The first surgical procedures within the bile ducts were simple and uncomplicated. In 1618, Fabricus removed gallstones from the gallbladder. In 1867, Bobbs performed cholecystostomy. Cholecystostomy procedures were also performed by: Sims in 1878, Kocher in 1878 and Tait in 1879. The first planned cholecystectomy, performed on July 15, 1882, by the Berlin surgeon Langenbuch (1846-1901), was a breakthrough in the development of biliary surgery. In 1890, Couvoissier the performed the first choledochotomy. Development of operations performed on the bile ducts caused the the problem of iatrogenic bile duct injuries. In 1891, Sprengel, first described the case of bile duct injury. With the rise of this problem, the first reports of surgical reconstruction of the

injured bile ducts have appeared. In 1892, Doyen, as first, described the biliary ductal end-to-end anastomosis. The idea of biliary-alimentary anastomoses appeared as early as the nineteenth century. Cholecystoenterostomy (anastomosis between the gallbladder and colon), made by Winiwater in 1881, was the he first recorded biliary-alimentary anastomosis. In 1905, Mayo made the first biliary reconstruction as the end-to-side anastomosis between the common bile duct anastomosis (CBD) and the duodenum called choledochoduodenostomy. In 1908, Monprofit described biliary-alimentary anastomosis with a loop of small intestine Roux-Y as a way to repair the biliary tract. In 1909, Dahl reported a similar case. In 1944, Manteuffel performed hepaticojejunostomy connecting intrahepatic biliary ducts with a small intestine. In 1948, Cole attempted to produce mucosal-intestinal anastomosis by moving a segment of small intestine mucosa by incision the proximal hepatic duct. However, in this method, the mucosal fragment had not got sufficient blood supply. This technique was modified in 1969 by Smith, who described it as a mucosal graft. In 1964, Gilbert and in 1969, Grassi used in the insertion of the small intestine pedunculated on biliary vessels in the biliary reconstruction. The role of the Berlin surgeon Kehr (1862-1916), as the creator of the most widely used today T biliary drain, should be also emphasized. The French surgeons, Couinaud in 1954 and in 1956, Hepp and Couinaud, described the hepatic hilum of the liver and long extrahepatic left hepatic duct, using it to perform a wide biliary-alimentary anastomosis, after the dissection of tissue within the hilum the liver to perform, in cases of intrahepatic bile duct injuries. In 1948, Longmire and Sanford also described a technique of isolating the left hepatic duct to use it for a biliary-intestinal anastomosis, consisting of partial resection of the left lobe of the liver. In 1957, this technique has been modified and used by Soupault and Couinaud to isolate the hepatic segment of the third hepatic segment in order to perform the biliary-intestinal anastomosis in the case of atypical sectoral biliary system. In 1994, Blumgart described the technique of the hilar and intrahepatic biliary-enteric anastomosis. In 1965, Thomford and Hallenbeck described the modification of an animal model of biliary-enteric anastomosis using Roux-Y loop, consisting of the jejunostomy (intestinal loop sutured into the abdominal shell) which allowed postoperative endoscopic control and dilatation of the anastomosis. In 1984, Hutson described the application of this technique in patients with postoperative stenosis within the biliary anastomosis. This method of reconstruction has not been widely accepted and incorporated into the standard surgical treatment of iatrogenic bile duct injuries (IBDI). In Poland, the modified biliary-enteric anastomosis with using Roux-Y loop sutured into the hole in the layer of musculo-fascial, was first described in 1997 by Jędrzejczyk et al. [8]. The increase in the IBDI incidence has been reported in the early 90's, which was connected with the introduction of laparoscopic cholecystectomy. The first laparoscopic cholecystectomy was performed in 1986 by Muhe.

### 3. Pathogenesis of bile duct injuries

Iatrogenic bile duct injury account for about 95% of all benign biliary strictures (BBS). "Benign biliary strictures" is a broad concept encompassing not only strictures caused by injuries, but also as a result of other causal factors [1, 11 12]. Causes of BBS can be divided into several groups and they are summarized in table 1.

There are two basic groups of surgical procedures, which may lead to IBDI. The first group are the operations performed on the bile ducts: an open cholecystectomy (OC) and

Congenital strictures: Biliary atresia and congenital cysts Bile duct injuries: Iatrogenic: postoperative, following endoscopic and percutaneous procedures Following blunt or penetrating trauma of the abdomen Inflammatory strictures: Cholelithiasis and choledocholithiasis Mirizzi's syndrome Chronic pancreatitis Chronic ulcer or diverticulum of duodenum Abscess or inflammation of liver or subhepatic region Parasitic, viral infection Toxic drugs Recurrent pyogenic cholangitis Primary sclerosing cholangitis Radiation-induced strictures Papillary stenosis
--

Table 1. Main causes of benign biliary strictures.

laparoscopic cholecystectomy (LC), choledochotomy, and previous biliary reconstruction. The second group includes the operations performed on other abdominal organs, such as gastric resection (Bilroth II partial resection), liver resection, liver transplantation, pancreatic resection (pancreatoduodenectomy, extended distal pancreatic resection and pancreatic cyst drainage), biliary-enteric and porto-caval anastomoses, and lymphadenectomy or other procedures within the hepatoduodenal ligament. Cholecystectomy is the most common cause of IBDI. Injuries caused during cholecystectomy represent 92.5% of IBDI.

Data regarding the exact prevalence of IBDI after OC and laparoscopic LC vary depending on the literature source. However, according to most authors IBDI occur 2-4 times more likely after laparoscopic cholecystectomy than after open cholecystectomy. IBDI number has increased in recent years, twice in connection with the introduction of laparoscopic cholecystectomy. Table 2 summarizes IBDI incidence following OC and LC.

Author	IBDI incidence following OC	IBDI incidence following LC
Mc Mahon 1995	0.2%	0.81%
Strasberg 1995	0.7%	0.5%
Shea 1996	0.19-0.29%	0.36-0.47%
Targarona 1998	0.6%	0.95%
Lillemoe 2000	0.3%	0.4-0.6%
Gazzaniga 2001	0.0-0.5%	0.07-0.95%
Savar 2004	0.18%	0.21%
Moore 2004	0.2%	0.4%
Misra 2004	0.1-0.3%	0.4-0.6%
Gentileschi 2004	0.0-0.7%	0.1-1.1%
Kaman 2006	0.3%	0.6%

BDI iatrogenic bile duct injuries; OC open cholecystectomy; LC laparoscopic cholecystectomy.

Table 2. Incidence of IBDI following cholecystectomy.

There are many factors that increase the IBDI risk during surgery. Coexisting chronic or exacerbated inflammation of the operated area, obese patient, the presence of abundant adipose tissue around the hepatoduodenal ligament, not sufficiently broad insight into the operative field, and bleeding increases the difficulty of surgery and promote bile duct injuries. The conditions in which laparoscopic cholecystectomy is performed, also affect the rate of IBDI formation. Adverse factors include older age, male gender and long duration of symptoms prior to surgery. Biliary anomalies and variability of the arteries are also the factors associated with increased IBDI risk. Unusually reputed hepatic duct may be mistakenly regarded as the cystic duct and ligated or cut. Excessive, more than is necessary, dissection around the hepatoduodenal ligament during cholecystectomy may lead to damage to the axial arteries running along the CBD. Vascular damage is the cause of postoperative biliary strictures due to ischemia. According to the literature, during the distal bile duct injury the axial artery damage usually occurs (incidence 10-15% of cases), while during high biliary injuries of the proximal bile duct damage to the branches of the proper hepatic artery occurs (incidence 40-60% of cases).

#### **4. Clinical presentation of iatrogenic bile duct injuries**

The most frequently observed clinical symptoms include jaundice, fever, chills, abdominal pain, pruritus. Clinical symptoms can be divided into two main groups. The first group are patients with the bile leakage in the early postoperative period due to the bile duct injury. In the presence of a drain in the peritoneal cavity, the injury indicates the appearance of bile in the drain. In patients without a catheter in the peritoneal cavity, bile leak into the abdominal cavity, leading to biloma or bile peritonitis. In these patients, jaundice is not observed because there is no cholestasis. In the second group of patients, usually in a remote time after surgery, there are primarily clinical symptoms resulting from cholestasis due to biliary obstruction. This is most commonly jaundice,

#### **5. Diagnosis of iatrogenic bile duct injuries**

##### **5.1 Laboratory diagnosis**

Laboratory tests and imaging are used in IBDI diagnostics. In the laboratory tests, cholestasis and liver function indicators, such as bilirubin, alkaline phosphatase (FA), gamma-glutamyl-transpeptidase (GGT), alanine transaminase (ALT) and aspartate transaminase (AST), are the most useful. In patients with biliary stenosis cholestasis parameters are increased: serum bilirubin, FA, GGT and 5'-nucleotidase and leucine aminoptidase (LAP) (less marked in the laboratory), and transaminase values usually remain normal (the liver is not damaged). Elevated transaminase levels indicate damage to liver parenchyma and the development of secondary biliary cirrhosis hypoalbuminemia and prolonged prothrombin time occur due to damaged liver synthetic function.

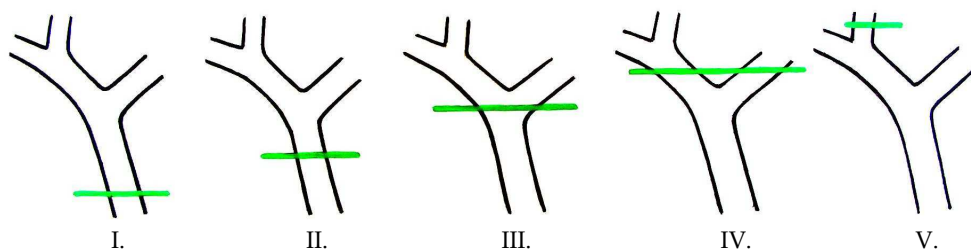
##### **5.2 Radiological diagnosis**

In IBDI diagnostics, imaging ultrasound (USG), abdominal computed tomography (CT) scan of the abdominal cavity, percutaneous cholangiography, endoscopic cholangiography and magnetic resonance imaging are performed. Abdominal ultrasound allows the visualization of intra- and extrahepatic bile ducts with the measurement of width and visibility of the

biloma within the peritoneal cavity in the case of bile leakage. In doubtful cases, you can perform abdominal CT to accurately depict the reservoir of bile. Accurate assessment of biliary tree can be made using cholangiography. Percutaneous cholangiography (percutaneous transhepatic cholangiography, PTC) is useful to evaluate the bile ducts proximal to the injury. Endoscopic cholangiography (endoscopic retrograde cholangiopancreatography, ERCP) plays a very important role in the imaging of biliary tract injuries. During ERCP it is possible to supply minor injuries through the establishment of the prosthesis into the lumen of the damaged bile ducts. The advantage of magnetic resonance cholangiography (cholangio-MR) imaging is the high accuracy of the biliary tree and it is non-invasive. This investigation is primarily used to assess the biliary tract before the reconstructive surgery.

## 6. Classification of iatrogenic bile duct injuries

Different IBDI classifications are described in the literature. In our opinion, the Bismuth classification is the most useful in a clinical practice (described in figure 1). It is based on location of the injury in the biliary tract. This classification is very helpful in prognosis after repair, but does not involve the wide spectrum of possible biliary injuries. The another classification is the Strasberg scale which, in difference from the Bismuth scale, allows to distinguish small (bile leakage from the cystic duct) and serious injuries performed during laparoscopic cholecystectomy, but it does not play an important role in choice of surgical treatment method. The Mattox classification of IBDI takes into consideration a kind of injuring factor (contusion, laceration, perforation, transection, distraction or interruption of the bile duct or the gallbladder). There are several classifications of IBDI performed during laparoscopic cholecystectomy (Steward and Way, Schmidt, Hannover) in the literature.



I. Common bile duct (CBD) and low common hepatic duct (CHD) > 2cm. from hepatic duct confluence. II. Proximal CHD < 2cm from confluence. III. Hilar injury with no residual CHD – confluence intact. IV. Destruction of confluence – right and left hepatic ducts separated. V. Involvement of aberrant right sectoral hepatic duct alone or with concomitant injury of CHD.

Fig. 1. Bismuth classification of IBDI.

## 7. Treatment of iatrogenic bile duct injuries

### 7.1 Non-invasive treatment of iatrogenic bile duct injuries

Non-invasive, percutaneous radiological endoscopic techniques are recommended as initial treatment of IBDI. When these techniques are not effective, surgical management is considered.

Type	Injury type
A	Injury of small bile ducts in communication with the main biliary system, with leakage of bile from the Luschka's or cystic ducts.
B	Injury of the sectoral bile duct, with subsequent obstruction of the main biliary system.
C	Injury of the sectoral bile duct with bile leakage of bile from bile duct, without communication with the main biliary system.
D	Side extrahepatic bile duct injury.
E1	CBD or CHD stricture at a distance > 2 cm from the hepatic duct confluence.
E2	CHD stricture at a distance < 2 cm from the hepatic duct confluence.
E3	CHD stricture within the hepatic duct confluence.
E4	Stricture involving the right and left hepatic ducts separately.
E5	Complete closure of all the bile ducts, including sectoral bile ducts.

Table 3. Strasberg classification of IBDI.

Type	Injury type
I	Contusion of the gallbladder or hepatic triad.
II	Jagged or perforation of the gallbladder.
III	The total separation of the gallbladder from the liver.
IV	CBD or CHD partial <50% CBD or CHD laceration or CSF.
V	CBD or CHD transection > 50% and injury of intrapancreatic or intraduodenal part of bile ducts.

Table 4. Mattox classification of IBDI.

Type	Injury type
I	Small incisions or incomplete intersections of CBD.
II	Stricture caused by thermal injury or clips.
III	Total transection or excision of the or CBD, CHD or the right or left hepatic ducts.
IV	Resection of the right hepatic cord erroneously recognized as the cystic duct.

Table 5. Steward i Way classification of IBDI.

Type	Injury type
A	Leak from the cystic duct (A1) or an accessory hepatic duct within gallbladder fossa (A2).
B	Clip closure of CBD or CHD incomplete (B1) or complete (B2).
C	Side injury of CBD or CHD over a distance of up to 5 mm (C1) or more than 5 mm (C2).
D	Transection of CBD or CHD without loss (D1) or loss (D2) of bile duct.
E	Stricture of CBD or CHD over a distance of up to 5 mm (E1), > 5 mm (E2) or the hepatic ducts confluence (E3) or only the right hepatic duct (E4).

Table 6. Schmidt classification of IBDI.

Type	Injury type
A	Peripheal bile leakage (in communication with main biliary system).
A1	Bile leakage from the cystic duct.
A2	Bile leakage from the gallbladder fossa.
B	CHD or CBD stricture without damage (eg caused by a clip).
B1	Incomplete.
B2	Complete.
C	Lateral CHD or CBD injury.
C1	Small spot injury (< 5 mm).
C2	Large injury (> 5 mm) below the hepatic ducts confluence.
C3	Large injury at the level of the hepatic ducts confluence.
C4	Large injury above the hepatic ducts confluence.
D	Total transection of CHD Or CBD.
D1	Without ductal loss below the hepatic ducts confluence.
D2	With ductal loss below the hepatic ducts confluence.
D3	At the level of the hepatic ducts confluence.
D4	Above the hepatic ducts confluence. (with or without ductal loss).
E	CHD or CBD stricture.
E1	Short, circular (< 5 mm) CHD or CBD stricture.
E2	Longitudinal CBD stricture (>5 mm).
E3	Stricture at the level of the hepatic ducts confluence
E4	Stricture of the right hepatic duct / sectoral hepatic duct.
E5	The complete closure of all the bile ducts, including sectoral bile ducts.

Table 7. Hannover classification of IBDI.

### 7.1.1 Percutaneous dilatation under radiological control

The effectiveness of percutaneous dilatation of biliary strictures with transhepatic insertion of the stent under radiological control is 40-85%. The main treatment-related complications associated with the liver puncture include haemorrhage, bile leakage and cholangitis. The other less common complications include pneumothorax which is the result of damage to the pleura, biliary-pleural fistula and perforation of adjacent organs, including the colon. Percutaneous technique is less effective (52%) than surgical therapy (89%). Also frequently than post-surgical complications observed (35% and 25% of complications). It is also associated with the higher number of complications (35%) than surgery (25%). The most frequently, it is recommended in very difficult cases of very high, hilar biliary strictures or in the treatment of very small bile ducts in the diameter.

### 7.1.2 Endoscopic dilatation during ERCP

Endoscopic dilatation associated with insertion of biliary prosthesis during ERCP investigation is the most frequently used non-surgical method in the treatment of IBDI. The effectiveness of endoscopic (72%) and surgical (83%) treatment is comparable. Incidence of complications in both methods of treatment is also comparable (35% vs. 26%). The common complications of endoscopic techniques regarding placement of biliary prosthesis include cholangitis, pancreatitis, prosthesis occlusion, migration, dislodgement and perforation of the bile duct.

Endoscopic treatment is recommended as initial treatment of benign biliary strictures, biliary fistula in the presence and in patients not qualified to surgical treatment.

## **7.2 Surgical treatment of iatrogenic bile duct injuries**

### **7.2.1 Immediate repair of IBDI**

In the case of intraoperative recognition of bile duct injury, it is recommended that intraoperative cholangiography or conversion from laparoscopic cholecystectomy to open, allowing a better insight into the operative field and immediate repair. The injury should be repaired by an experienced hepatobiliary surgeon. If it is impossible, a patient should be transferred to a referral hepatobiliary surgery center, after adequate drainage of a subhepatic region. If the cut bile duct is less than 2-3 mm in diameter, without communication with the main biliary system, it should be ligated in order to avoid postoperative bile leak leading to development of the biloma and abscess in the subhepatic region. Bile ducts with a diameter of 3-4 mm or more should be surgically repaired because they drain the larger area of the liver. Interruption of CHD or CBD continuity can be repaired by immediate tension-free end-to-end ductal anastomosis with or without a T tube, using absorbable sutures. Security of the immediately repaired bile duct with a T tube is controversial. If the bile duct loss is too long and immediate end-to-end biliary anastomosis is not possible without tension, hepaticojejunostomy Roux-Y is recommended.

### **7.2.2 Surgical reconstructions of iatrogenic bile duct injuries**

Over 2/3 bile duct injuries are recognized at least a few days after surgery, during which the injury occurred. The surgical treatment of elective IBDI is made using different methods of biliary reconstructions. The main aim of surgical treatment is the reconstruction of proper flow of bile to the alimentary tract. The following operations are performed in biliary injuries surgical treatment: Roux-Y hepaticojejunostomy, end-to-end ductal biliary anastomosis with T drainage or endoprosthesis conducted into the duodenum according to Górka, choledochoduodenostomy, Lahey hepaticojejunostomy, jejunal interposition hepaticoduodenostomy, Blumgart (Hepp) anastomosis, Heinecke-Mikulicz biliary plastic reconstruction and Smith mucosal graft.

#### **Conditions of proper healing of each biliary anastomosis**

- The anastomosed edges should be healthy, without inflammation, ischemia and fibrosis.
- The anastomosis should be tension-free and properly vascularized.
- It should be performed in a single layer with absorbable sutures.

#### **7.2.2.1 Types of surgical reconstructions performed in IBDI**

##### *7.2.2.1.1 End-to-end ductal anastomosis (EE)*

We recommend this method as the first, because end-to-end ductal anastomosis (EE) is the most physiological biliary reconstruction [1, 46, 48, 49]. In this type of reconstruction, extensive mobilization of the duodenum with the pancreatic head through the Kocher maneuver, excision of the bile duct stricture, and refreshment of the proximal and distal stumps should be performed. Anastomosis is performed in a single layer with interrupted absorbable PDS 4-0 or 5-0 sutures. This reconstruction is not recommended by most authors due to the higher



number of anastomosis strictures in comparison with Roux-y hepaticojejunostomy (HJ). We recommend EE first, because in some patients, extensive mobilization of the duodenum with the pancreatic head by the Kocher maneuver allows to perform the tension-free anastomosis after the extensive length-loss of the bile duct. Excision of the bile duct stricture, dissection and refreshing of the proximal and distal stumps as far as the tissues are healthy and without inflammation, and the use of non-traumatic, monofilament-interrupted sutures 5-0 allows the achievement of good long-term results. Using of an internal Y tube conducting from the right and left hepatic ducts into the duodenum through EE and the papilla of Vater also allows the proper healing of this anastomosis. This reconstruction can be performed when the bile duct loss is from 0.5 to 4 cm. It allows the achievement of very good long-term results with effectiveness comparable with HJ. It is important that establishing a physiological bile pathway allows proper digestion and absorption, which causes a higher gain weight in patients following EE, which was noted in study performed in our department. Another essential advantage of EE is possibility of of endoscopic control after surgery. The lower number of early complications is observed after EE than HJ, which is associated with opening of the alimentary tract and the higher number of performed anastomoses (biliary-enteric and entero-enteric) in patients with HJ. The disadvantage is the higher incidence of recorded postoperative stenosis at the anastomosis due to poorer blood supply of the operated area. It can't be performed in patients with bile duct loss more than 4 cm. The diameter of both anastomosed ends should be comparable. If there is a difference between a diameter of anastomosed ends, the thinner end should be incised longitudinally in the anterior surface in order to extend it before creation of anastomosis. This repair should not be carried out in bile ducts that are too thin (diameter less than 4 mm). In our opinion a patient, whom we perform first or exceptionally second bile ducts repair, is a candidate for EE. Because of a number of advantages, EE is recommended as the first method of choice for patients with IBDI.

#### 7.2.2.1.2 Roux-Y hepaticojejunostomy

Roux-Y hepaticojejunostomy (HJ) is the most frequently performed surgical reconstruction of IBDI. In this surgical technique, a proximal common hepatic duct is identified and prepared and the distal common bile duct is sutured. End-to-side or end-to-end HJ is performed in a single layer using interrupted absorbable polydioxanone (PDS 4-0 or 5-0) sutures. Most authors prefer HJ due to the lower number of postoperative anastomosis strictures. According to Terblanche et al, HJ is effective in 90% of cases [50]. However, after this reconstruction, bile flow into the alimentary tract is not physiological, because the duodenum and upper part of the jejunum are excluded from bile passage. Physiological conditions within the proximal gastrointestinal tract are changed as a result of duodenal exclusion from bile passage. An altered bile pathway is a cause of disturbances in the release of gastrointestinal hormones. There is a hypothesis that in patients with HJ, the bile bypass induces gastric hypersecretion leading to a pH change secondary to altered bile synthesis and release of gastrin. A higher number of duodenal ulcers is observed in patients with HJ, which may be associated with a loss of the neutralizing effect of the bile, including bicarbonates and the secondary gastric hypersecretion. Laboratory investigations revealed increased gastrin and glucagon-like immunoreactivity (GLI) plasma levels and decreased triglycerides, gastric inhibitory polypeptide (GIP), and insulin plasma levels in patients with HJ. An altered pathway of bile flow is also a cause of disturbance in fat metabolism in patients undergoing HJ. Moreover, the total surface of absorption in these patients is also decreased due to exclusion of the duodenum and upper jejunum from the food passage. In

our department a significantly lower weight gain in patients undergoing HJ in comparison to patients following physiological end-to-end ductal anastomosis was reported [1, 49]. The another disadvantage of HJ is a lack of capability of control endoscopic examination and endoscopic dilatation of strictured biliary anastomosis. In order to resolve this problem, a longer jejunal loop (jejunostomy) is prepared and sutured to the abdominal subcutaneous tissue in the right subcostal region. Jejunostomy can be open or closed with possibility of opening in a case of biliary anastomosis stricture, which should be endoscopically dilated. Jejunostomy is associated with bile loss of about 40 ml/day in patients.

#### *7.2.2.1.3 Choledochoduodenostomy (ChD)*

Choledochoduodenostomy (ChD) is actually rarely performed operation recommended by some authors only in cases of injury within the distal portion of the common bile duct. It guarantees physiological bile flow into duodenum and anastomosis endoscopic control, and it is easier technically. It is recommended in some cases of distal strictures, when use of the jejunal loop due to numerous adhesions is impossible. It should be performed on the large common bile duct (>15 mm diameter) because the postoperative strictures are more frequent within the narrow duct. ChD should be created between the duodenum and the distal CBD in order to decrease a risk of so-called sump syndrome noted in 0.14-3.3% of cases in the literature. In patients following ChD, recurrent ascending cholangitis due to bile reflux is noted in 0-4%. A higher rate of bile duct cancer in patients with ChD in comparison of HJ (7.6 vs. 1.9%) was reported in the literature .

#### *7.2.2.1.4 Jejunal interposition hepaticoduodenostomy (JIHD)*

Jejunal interposition hepaticoduodenostomy, using 25-35 cm of the jejunal loop, is performed in some surgical centers including our department. This reconstruction includes three (biliary-enteric, enteric-duodenal and entero-enteric) anastomoses. Biliary-enteric anastomosis is performed in a single layer with interrupted absorbable sutures 5-0 and enteric-duodenal in a single layer with interrupted or continuous absorbable sutures 4-0. In our opinion, JIHD should be used only in patients in good general condition, without active inflammation within the peritoneal cavity, with protein level more than 6 g/dl and serum bilirubin level less than 20 mg/dl. Good condition of the duodenal wall is important factor for proper healing of hepaticoduodenostomy with jejunal interposition. The advantage of this reconstruction is physiological bile flow into the duodenum, which prevents duodenal ulcer caused by changes in the neurohormonal axis within the upper alimentary tract. This method of reconstruction is recommended mainly in patients with concomitant duodenal ulcer. The disadvantage is a higher number of early complications due to presence of three anastomoses.

#### *7.2.2.1.5 Reconstructions of hilar bile duct injuries*

The repair of hilar IBDI requires special surgical techniques. In the past, so-called "mucosal graft technique" described by Smith in the 1960s was performed. This reconstruction involves creating a mucosal dome of jejunum (by removing a seromuscular patch) near the end of Roux-Y loop through which a straight rubber tube is brought via hepatic ducts and through liver parenchyma. This technique is based on the hypothesis that jejunal mucosa grafts to the biliary epithelium and mucosa-to-mucosa anastomosis is created. Short-term results were good, but in long-term results a high number of anastomosis strictures was observed. Therefore, currently, not Smith but Blumgart-Hepp technique is used in

reconstruction of hilar IBDI. In this technique, dorsal surface of the left hepatic duct parallel to the quadrate hepatic lobe. Dissection and opening of the left hepatic duct longitudinally allows to create a wide anastomosis of 1-3 cm in diameter.

Other methods of IBDI reconstruction, such as Lahey hepaticojejunostomy, jejunal Heinecke-Mikulicz biliary plastic operation Kirtley operation and others are performed sporadically.

### **7.2.2.2 Types of surgical biliary drainage used in IBDI reconstructions**

#### *7.2.2.2.1 External T-drainage*

External T-drainage - using a typical Kehr tube with insertion of its short branches into the bile duct and conducting of its long branch through the abdominal wall outside.

#### *7.2.2.2.2 External Y-drainage*

External Y-drainage - insertion of short branches of the Kehr tube into both right and left hepatic ducts, splinting of the anastomosis and conducting of its long branch through the jejunal loop and abdominal wall outside.

### **7.2.2.3 Internal Y-drainage**

Internal Y-drainage - insertion of short branches of the Kehr tube into both right and left hepatic ducts, splinting of the anastomosis and conducting of its long branch into the duodenum by the papilla of Vater.

### **7.2.2.4 Rodney-Smith drainage**

Rodney Smith drainage - using two straight rubber tubes splinting the biliary-enteric anastomosis that are brought via hepatic ducts and through liver parenchyma and conducted through the abdominal wall outside. This drainage type is used in high intrahilar biliary-enteric anastomosis. In the past, it was used in Smith "mucosal graft technique".

### **7.2.2.5 No drainage**

Drainage using is still controversial. The advantage of biliary drainage is limitation of the inflammation and fibrosis occurring after the surgical procedure. In some authors' opinion, the presence of the biliary tube prevents anastomosis stricture. The disadvantage of biliary drainage is a higher risk of postoperative complications. There are recommendations (according to Mercado et al) to use transanastomotic stents when there is a thin bile duct less than 4 mm in diameter, and when there is inflammation within the ductal anastomosed edges that makes proper healing of the anastomosis questionable.

## **8. Treatment of iatrogenic bile duct injuries – Assessment of results in the surgical treatment of iatrogenic bile duct injuries**

### **8.1 Short-term results and early complications**

The early postoperative morbidity rate is 20-30% and mortality rate 0-2%. The most frequent early complication is wound infection (8-17.7%). Other complications are the following: bile collection, intra-abdominal abscess, biliary-enteric anastomosis dehiscence, biliary fistula, cholangitis, peritonitis, eventration, pneumonia, circulatory insufficiency, intra-abdominal bleeding, sepsis, infection of the urinary tract, pneumothorax, acute pancreatitis, thrombosis and embolic complications, diarrhea, ileus and multi-organ insufficiency.

## 8.2 Long-term results and quality of life

### 8.2.1 Follow-up after surgical reconstructions

#### 8.2.1.1 Duration of follow-up

IBDI remain a serious clinical problem and a challenge for even the most experienced surgical centers of reference. According to literature, the effectiveness of surgical treatment of IBDI is 70-90%. The recurrent strictures after biliary reconstruction occur in 10-30% of cases. About 80% of postoperative recurrence of biliary strictures are observed during the first five years following reconstruction. Two-thirds (65%) of recurrent biliary strictures develop within 2-3 years after the reconstruction, 80% within 5 years, and 90% within 7 years. Recurrent strictures 10 years after the surgical procedure are also described in the literature. Therefore, the objective assessment of long-term results of surgical treatment plays an important role in the observation period (follow-up) (FU). According to most authors, patients following biliary reconstruction should be observed at least 3 years; according to some authors even 5 to 10 years. Satisfactory length of follow-up, which is necessary in order to assess the long-term results of the repair procedure, is 2 to 5 years. Some authors recommend 10 or 20 years of observation. The criteria of success of surgery include: the absence of clinical symptoms such as biliary jaundice or cholangitis and absence of recurrent stenosis after surgery requiring endoscopic or surgical correction.

The early proper biliary reconstruction is very important, because duration of biliary obstruction is the most important risk factor of biliary cirrhosis. According to literature, prolonged time from injury to repair and portal hypertension are important parameters correlating with secondary biliary cirrhosis. So, early biliary repair can prevent liver fibrosis. According to the literature, biliary cirrhosis occurs in two thirds of patients without effective biliary repair. Portal hypertension is noted in 15-25% of patients with biliary cirrhosis due to IBDI. Reoperations within inflammation, fibrosis and a higher risk of intra-operative bleeding due to portal hypertension with collateral circulation and intraperitoneal adhesions are very difficult and associated with increased mortality rate. Therefore, early and proper biliary reconstruction increases survival rate and decreases morbidity and mortality rates in patients with IBDI.

#### 8.2.1.2 Follow-up classifications

Different classifications are used for an objective assessment of the effectiveness of biliary repair. The Terblanche scale taking into account clinical parameters is the most frequently used classification [50, 72]. Other less frequently used classifications are the following: the McDonald, Brummelkamp Lygidakis, Cardenas and Munoz, and Nielubowicz scales.

<b>I</b>	<b>Excellent result.</b> No biliary symptoms with normal liver function.
<b>II</b>	<b>Good result.</b> Transitory symptoms, currently no symptoms and normal liver function.
<b>III</b>	<b>Fair result.</b> Clearly related symptoms requiring medical therapy and/or deteriorating liver function.
<b>IV</b>	<b>Poor result.</b> Recurrent stricture requiring correction or related death.

Table 8. Terblanche classification.

<b>A</b>	No clinical symptoms from the biliary tract, proper laboratory liver function parameters tests.
<b>B</b>	No clinical signs, laboratory liver function parameters tests slightly elevated liver function parameters, or periodically occurring episodes of pain or fever.
<b>C</b>	Pain, cholangitis with the presence of fever with jaundice and abnormalities in laboratory tests.
<b>D</b>	Condition requiring surgical or endoscopic correction.

Table 9. McDonald classification.

<b>I</b>	Without pain, normal liver function tests.
<b>II</b>	Minor clinical symptoms due to periodic cholangitis resolved after antibiotic therapy, occurring 2-3 times a year, not requiring hospitalization. Proper liver function tests, except of increased serum bilirubin and alkaline phosphatase, with rapid normalization after symptoms resolution.
<b>III</b>	Severe recurrent cholangitis, occurring in more 3 times a year,, lasting over a week and requiring hospitalization. Laboratory tests showing a tendency do increased ALT and AST and transit but rapid increased serum bilirubin and alkaline phosphatase.

Table 10. Lygidakis i Brummelkamp classification.

<b>I</b>	Asymptomatic course.
<b>II</b>	Minor clinical symptoms.
<b>III</b>	Recurrent cholangitis.

Table 11. Muñoz-Cardenas classification.

<b>Very good result</b>	Without clinical symptoms.
<b>Good result</b>	Cholangitis 1-2 a year without jaundice, and without debilitating normal life and work of the patient.
<b>Poor result</b>	Often repeated bouts of cholangitis with jaundice, showing recurrence of stenosis.

Table 12. Nielubowicz classification.

## 9. Conclusion

The early and proper treatment of IBDI is very important, because it can prevent serious complications and improve quality of life in patients. Non-invasive methods are used as initial treatment. When it is not effective, surgical management should be considered. Surgical treatment includes different types of reconstructions.

## 10. References

- [1] Ahrendt S.; & Pitt H. (2001). Surgical Therapy of Iatrogenic Lesions of Biliary Tract. *Word J Surg*, Vol. 25, pp. 1360-1365.
- [2] Barker E.M.; & Winkler M. (1984). Permanent-access hepaticojejunostomy. *Br J Surg*, Vol. 71, pp. 188-191.
- [3] Beal J.M. (1984). Historical perspective of gallstone disease. *Surg Gynecol Obstet*, Vol. 158, pp. 181-189.
- [4] Bektas H.; Schrem H.; Winny M.; & Klempnauer J. (2007). Surgical treatment and outcome of iatrogenic bile duct lesions after cholecystectomy and the impact of different clinical classification systems. *Br J Surg* 2007, Vol. 94, No. 9, pp. 1119-1127.
- [5] Bismuth H.; & Franco D. (1978). Long term results of Roux-en-Y hepaticojejunostomy. *Surg Gyn Obstet*, Vol. 146, No. 2, pp. 161-167.
- [6] Bismuth H.; & Majno P.E. (2001). Biliary strictures: classification based on the principles of surgical treatment. *Word J Surg*, Vol. 25, pp. 1241-1244.
- [7] Blumgart L.H. (1994). Hilar and intrahepatic biliary enteric anastomosis. *Surg Clin North Am*, Vol. 74, pp. 731-740
- [8] Bolton J.S.; Braasch J.W.; & Rossi R.L. (1980). Management of benign biliary stricture. *Surg Clin North Am*, Vol. 60, pp. 313-332.
- [9] Braasch J.W. (1994). Historical perspectives of biliary tract injuries. *Surg Clin North Am*, Vol 74, No. 4 pp. 731-740.
- [10] Buell J.F.; Cronin D.C.; Funaki B.; & al. (2002). Devastating and Fatal Complications Associated With Combined Vascular and Bile Injuries During Cholecystectomy. *Ann Surg*, Vol. 137, pp. 703-710.
- [11] Chaudhary A.; Chandra A.; Negi S.; & Sachdev A. (2002). Reoperative Surgery for Postcholecystectomy Bile Duct Injuries. *Dig Surg*, Vol. 19, pp. 22-27.
- [12] Coleman J.A.; & Yeo Ch.J. (2000). Postoperative Bile Duct Strictures: Management and Outcome In the 1990s. *Ann Surg*, Vol. 232, No. 3, pp. 430-441.
- [13] Connor S.; & Garden O.J. (2006). Bile duct injury in the era of laparoscopic cholecystectomy. *Br J Surg*, Vol. 93, pp. 158-168.
- [14] Davids P.; Tanka A.; Rauws E, Gulik T.; Leeuwen D.; Wit L.; Verbeek P.,; Huibregtse K.; Heyde N.; & Tytgat G. (1993). Benign Biliary Strictures. Surgery or Endoscopy? *Ann Surg*, Vol. 217, No. 3, pp. 237-243.
- [15] Flum D.R.; Cheadle A.; Prael C.; Dellinger E.P.; & Chan L. (2003). Bile Duct Injury During Cholecystectomy and Survival in Medicare Beneficiaries. *JAMA* 2003, Vol. 290, No. 16, pp. 2168-2173.
- [16] Gazzaniga G.M.; Filauro M.; & Mori L. (2001). Surgical treatment of Iatrogenic Lesions of the Proximal Common Bile Duct. *Word J Surg*, Vol. 25, pp. 1254-1259.
- [17] Gentileschi P.; Di Paola M.; Catarci M.; & al. (2004). Bile duct injuries during laparoscopic cholecystectomy. A 1994-2001 audit on 13,718 operations in the area of Rome. *Surg Endosc*, Vol. 18, pp. 232-236.
- [18] Górka Z.; & Rudnicki M. (1991). Zespolecie przewodowo-czeczko-dwunastnicze w operacjach odtwórczych dróg żółciowych. *Pol Przegl Chir*, Vol. 63, pp. 1003-1008.
- [19] Górka Z.; Ziąja K.; Nowak J.; Lampe P.; & Wojtyczka A. (1992). 195 operacji kalectwa żółciowego. *Pol Przegl Chir*, Vol. 64; pp. 969-976.


- [20] Górka Z.; Ziaja K.; Wojtyczka A.; Kabat J.; & Nowak J. (1992). End-to-end anastomosis as a method of choice in surgical treatment of selected cases of biliary handicap. *Pol J Surg*, Vol. 64, pp. 977-979
- [21] Gouma D.J.; & Obertop H. (2002). Management of Bile Duct Injuries: Treatment and Long-Term Results. *Dig Surg*; Vol. 19, pp. 117-122.
- [22] Hall J.G.; & Pappas TN. (2004). Current Management of Biliary Strictures. *J Gastrointest Surg*, Vol. 8, No. 8, pp. 1098-1110.
- [23] Hardy K.J. (1993). Carl Langenbuch and the lasarus Hospital: events and circumstances surrounding the first cholecystectomy *Aust N Z J Surg*, Vol. 63, No. 1, pp. 56-64.
- [24] Imamura M.; Takahashi M.; Sasaki I.; Yamauchi H.; & Sato T. (1988). Effects of the Pathway of Bile Flow on the Digestion of FAT and the Release of Gastrointestinal Hormones. *Am J Gastroenterol*, Vol. 83, pp. 386-392.
- [25] Jabłońska B.; Lampe P.; Olakowski M.; Lekstan A.; & Górka Z. (2008). Surgical treatment of iatrogenic biliary injuries - early complications. *Przegl Chir*, Vol. 80, No. 6, pp. 299-305.
- [26] Jabłońska B.; Lampe P.; Olakowski M.; Górka Z.; Lekstan A.; & Gruszka T. (2009). Hepaticojejunostomy vs. end-to-end biliary reconstructions in the treatment of iatrogenic bile duct injuries. *J Gastrointest Surg*, Vol. 13, No.6, pp. 1084-1093.
- [27] Jabłońska B.; & Lampe P. (2009). Iatrogenic bile duct injuries - etiology, diagnosis and management. *World J Gastroenterol*, Vol. 15, No. 33, pp. 4097-4104.
- [28] Jabłońska B.; Lampe P.; Olakowski M.; Lekstan A.; & Górka Z. (2010). Long-term Results in the Surgical Treatment of Iatrogenic Bile Duct Injuries. *Pol J Surg*, Vol. 82, No. 6, pp. 354-361.
- [29] Jarnagin W.R.; & Blumgart LH (1999). Operative Repair of Bile Duct Injuries Involving the Hepatic Duct Confluence. *Arch Sur*, Vol. 134, pp. 769-775.
- [30] Jarnagin W.R.; & Blumgart L.H. (2002). Benign biliary strictures. [In:] Blumgart LH, Fong Y, ed. *Surgery of the liver and biliary tract*. WB Saunders Company, Philadelphia 2002: pp. 895-929.
- [31] Jędrzejczyk W.; Jużków H.; & Jackowski M. (1997). Modyfikacja techniki operacyjnej w kalectwie dróg żółciowych - nadzieje i obawy. *Pol Przegl Chir*, Vol. 69, No. 3, pp. 297-300.
- [32] Kaman L.; Sanyal S.; Behera A.; Singh R.; & Katariya R.N. (2006). Comparison of major bile duct injuries following laparoscopic cholecystectomy and open cholecystectomy. *ANZ J Surg*, Vol. 76, pp. 788-791.
- [33] Koffron A.; Ferrario M.; Parsons W.; Nemcek A.; Saker M.; & Abecassis M. (2001). Failed primary management of iatrogenic biliary injury: Incidence and significance of concomitant hepatic arterial disruption. *Surgery*, Vol. 130, pp. 722-731.
- [34] Kosiński B.; Umiński M.; Jędrzejczyk G. (1995). Kalectwo dróg żółciowych. *Pol Przegl Chir*, Vol. 67, No. 2, pp. 141-144.
- [35] Kozicki I.; & Bielecki K. (1997). Hepaticojejunostomy in Benign Biliary Stricture - Influence of Careful Postoperative Observations on Long-Term Results. *Dig Surg*, Vol. 14, pp. 527-533.
- [36] Kozicki I.; & Bielecki K.; the late Kowalski A.; & Krolicki L. (1994). Repeated reconstruction for recurrent benign bile duct stricture. *Br J Surg*, Vol. 81, pp. 677-679.

- [37] Kozicki I.; Bielecki K.; & Lembas L. (2000). Leczenie śródwnękowych urazów dróg żółciowych po cholecystektomii laparoskopowej. *Pol Przegl Chir*, Vol. 72, No. 11, pp. 1049-1060.
- [38] Krawczyk M.; & Patkowski W. (2001). Taktyka postępowania w jatrogennym uszkodzeniu dróg żółciowych. *Pol Przegl Chir*, Vol. 73, No. 1, pp. 4-16.
- [39] Lillemoe K.D.; Melton G.B.; Cameron J.L.; Pitt H.A.; Campbell K.A.; Talamini M.A.; Sauter P.A.; Coleman J.; & Yeo C.J. (2000). Postoperative Bile Duct Strictures: Management and Outcome in the 1990s. *Ann Surg*, Vol.232, No. 3, pp. 430-441.
- [40] Lygidakis N.J.; & Brummelkamp W.H. (1986). Surgical management of proximal benign biliary strictures. *Acta Chir Scand*, Vol. 152, pp. 367-371.
- [41] Mattox K.L.; Feliciano D.V.; & Moore E.E.(1996). *Trauma*. 3rd Ed. Stamford, CT: Appleton&Lange, 1996: 515-519.
- [42] Mc Mahon A.J.; Fullarton G.; Barter J.N.; & O'Dwyer P.J. (1995). Bile duct injury and bile leakage In laparoscopic cholecystectomy. *Br J Surg*; Vol. 82, pp. 307-313.
- [43] McDonald M.L.; Farnell M.B.; Nagorney D.M.; Ilstrup D.M.; & Kutch J.M. (1995). Benign biliary strictures: repair and outcome with contemporary approach. *Surgery*, Vol. 118, pp. 582-591.
- [44] Mercado M.A.; Chan C.; Orozco H.; Cano-Gutiérrez G.; Chaparro J.M.; Galindo E.; Vilatobá M.; & Samaniego-Arvizu G. (2002) To stent or not to stent bilioenteric anastomosis after iatrogenic injury: A Dilemma not answered? *Surgery*, Vol. 137, pp. 60-63.
- [45] Mercado M.A.; Chan C.; Orozco H.; Tielve M.; & Hinojosa C.A. (2003). Acute bile duct injury. The need for a high repair. *Surg Endosc*, Vol. 17, pp. 1351-1355.
- [46] Misra S.; Melton G.B.; Geschwind J.F.; Venbrux A.C.; Cameron J.L.; & Lillemoe K.D. (2004). Percutaneous Management of Bile Duct Strictures and Injuries Associated with Laparoscopic Cholecystectomy: A Decade of Experience. *J Am Coll Surg*, Vol. 198, pp. 218-226.
- [47] Moore D.F.; Feuer I.D.; Holzman M.D.; & al. (2004). Long-term Detrimental Effect of Bile Injury on Health-Related Quality of Life. *Arch Surg*, Vol. 139, pp. 476-482.
- [48] Muñoz R.; & Cardenas S. (1990). Thirty Years' Experience with Biliary Tract Reconstruction by Hepaticoenterostomy and Transhepatic T Tube. *Am J Surg*, Vol. 159, pp. 405-410.
- [49] Murr M.M.; Gigot J.F.; Nagorney D.M.; Harmsen W.S.; Ilstrup D.M.; & Farnell M.B. (1999). Long-term Results of Biliary Reconstruction After Laparoscopic Bile Duct injuries. *Arch Surg*, Vol. 134, No. 6, pp. 604-610
- [50] Negi S.S.; Sakhuja P.; Malhotra V.; & al. (2004). Factors Predicting Advanced Hepatic Fibrosis in Patients With Postcholecystectomy Bile Duct Strictures. *Arch Surg*, Vol. 139, pp. 299-303.
- [51] Nielsen M.K.; Jensen S.L.; Malstrom J.; & Niwlsen O.V. (1980). Gastrin and gastric acid secretion in hepaticojejunostomy Roux-en-Y. *Surg Gyn Obstet*, Vol. 150, pp. 61-64.
- [52] Nielubowicz J.; Olszewski K.; & Szostek M. (1973). Operacje odtwórcze w kalctwie dróg żółciowych. *Pol Przegl Chir*, Vol. XLV, No. 12, pp. 1389-1395.
- [53] Pellegrini C.A.; Thomas M.J.; & Way L.W. (1984). Recurrent biliary stricture: patterns of recurrence and outcome of surgical therapy. *Am J Surg*, No. 147, pp. 175-180.



- [54] Perakath B.; Sitaram V.; Mathew G.; & al.(2003). Postcholecystectomy benign biliary stricture with portal hypertension: is a portosystemic shunt before hepaticojejunostomy necessary? *Ann R Coll Surg Engl*, Vol. 85, pp. 317-320.
- [55] Pitt H.A.; Kaufman H.S.; Coleman J.; White R.I.; & Cameron J.L. (1989). Benign postoperative biliary strictures. Operate or dilate? *Ann Surg*, Vol. 210, pp. 417-425.
- [56] Pitt H.A.; Miyamoto T.; Parapatis S.K.; Tompkins R.K.; & Longmire W.P. Jr. (1982). Factors influencing outcome in patients with postoperative biliary strictures. *Am J Surg*, Vol. 144, pp. 14-21.
- [57] Reynolds W. Jr. 2001 The first laparoscopic cholecystectomy. *JSLs*. Jan-Mar;5(1):89-94.
- [58] Robinson T.N.,; Stiegmann G.V.; Durham J.D.; Johnson S.I.; Wachs M.E.; Serra A.D.; & Kumpe D.A. (2001). Management of major bile duct injury associated with laparoscopic cholecystectomy. *Surg Endosc*, Vol. 15, pp. 1381-1385.
- [59] Rossi R.L.; & Tsao J.I. (1994). Biliary reconstruction. *Surg Clin North Am*, Vol. 74, No. 4, pp. 825-841.
- [60] Rudnicki M.; McFadden D.W.; Sheriff S. & Ischer J.E. (1992). Roux-en-Y jejunal Bypass abolishes postprandial neuropeptide Y release. *J Surg Res*, Vol. 53, pp. 7-11.
- [61] Savar A.; Carmody I.; Hiatt J.R.; & Busuttill R.W. (2004). Laparoscopic Bile Duct Injuries: Management at a Tertiary Liver Center. *Am Surg*, Vol. 70, pp. 906-909.
- [62] Schmidt S.C.; Langrehr J.M.; Hintze R.E.; & Neuhaus P. (2005). Long-term results and risk factors influencing outcome of major bile duct injuries following cholecystectomy. *Br J Surg*, Vol. 92, pp. 76-82.
- [63] Schmidt S.C.; Settmacher U.; Langrehr J.M.; & Neuhaus P. (2004). Management and outcome of patients with combined bile duct and hepatic arterial injuries after laparoscopic cholecystectomy. *Surgery*, No. 135, pp. 613-618.
- [64] Shamiyeh A.; & Wayand W. (2004). Laparoscopic cholecystectomy: early and late complications and their treatment. *Langenbecks Arch Surg*, No. 389, Vo.3, pp. 164-171.
- [65] Shea J.A.; Healey M.J.; Jesse A.; & al. (1996). Mortality and Complications Associated with Laparoscopic Cholecystectomy: A Meta-Analysis. *Ann Surg*, Vo. 224, No. 5, pp. 609-620.
- [66] Sicklick J.K.; Camp M.S.; Lillemoe K.D.; & al. (2005). Surgical Management of Bile Duct Injuries Sustained During Laparoscopic Cholecystectomy. Perioperative Results in 200 Patients. *Ann Surg*, Vol. 241, No. 5, pp. 786-795.
- [67] Sicklick J.K.; Camp M.S.; Lillemoe K.D.; Melton G.B.; Yeo C.J.; Campbell K.A.; Talamini M.A.; Pitt H.A.; Coleman J.; Sauter P.A.,; & Cameron J.L. (2005). Surgical Management of Bile Duct Injuries Sustained During Laparoscopic Cholecystectomy. Perioperative Results in 200 Patients. *Ann Surg*, Vol. 241, pp. 786-795.
- [68] Sikora S.S.; Pottakkat B.; Srikanth G.; Kumar A.; Saxena R.; & Kapoor V.K. (2006). Postcholecystectomy Benign Biliary Strictures - Long-Term Results. *Dig Surg*, Vol. 23, pp. 304-312.
- [69] Sikora S.S.; Srikanth G.; Agrawal V.; & al. (2008). Liver histology in benign biliary stricture: fibrosis to cirrhosis... and reversal? *J Gastroenterol Hepatol*, Vol. 23, No. 12, pp. 1879-84.
- [70] Smith R. (1964). Hepaticojejunostomy with transhepatic intubation: a technique for very high strictures of the hepatic ducts. *Br J Surg*, Vol. 51, pp. 186-194.

- [71] Steward L.; & Way L.W. (1995). Bile Duct Injuries During Laparoscopic Cholecystectomy. Factors That Influence the Results of Treatment. *Arch Surg*, Vol. 130, pp. 1123-1128.
- [72] Strasberg S.M.; Hertz M.; & Soper N.J. (1995). An analysis of the problem of biliary injury during laparoscopic cholecystectomy. *J Am Coll Surg*, Vol. 189, pp. 101-125.
- [73] Targarona E.M.; Marco C.; Balague C.; & al. (1998). How, when and why bile duct injury occurs. A comparison between open and laparoscopic cholecystectomy. *Surg Endosc*, Vol. 12, No. 4, pp. 322-326.
- [74] Terblanche J.; Worthley C.; & Krige J. (1990). High or low hepaticojejunostomy for bile duct strictures? *Surgery*, Vol. 108, pp. 828-834.
- [75] Tocchi A.; Costa G.; Lepre L.; Lotta G.; Mazzoni G.; & Sita A. (1996). The Long-Term Outcome of Hepaticojejunostomy In the Treatment of Benign Bile Duct Strictures. *Ann Surg*, Vol. 224, No. 2, pp. 162-167.
- [76] Tocchi A.; Mazzoni G.; Liotta G.; Costa G.; Lepre L.; Miccini M.; Masi E.; Lamazza M.A.; & Fiori E. (2000). Management of Benign Biliary Strictures. *Arch Surg*, Vol. 135, No. 2, pp. 153-157.
- [77] Tocchi A.; Mazzoni G.; Lotta G.; Lepre L.; Cassini D.; & Miccini M. (2001). Late Development of Bile Duct Cancer in Patients Who Had Biliary-Enteric Drainage for Benign Disease: A Follow-Up Study of More Than 1,000 Patients. *Ann Surg*, Vol. 234, No. 2, pp. 210-214 .
- [78] Tsalis K.G.; Christoforidis E.C.; Dimitriadis C.A.; Kalfadis S.C.; Botsios D.S.; & Dadoukis J.D. (2003). Management of bile duct injury during and after laparoscopic cholecystectomy. *Surg Endosc*, Vol. 17, pp. 31-37.
- [79] van Gulik T.M. (1986). Langenbuch's cholecystectomy, once a remarkably controversial operation. *Neth J Surg*, Vol. 38, No. 5, p. 138-141.
- [80] Waage A.; & Nilsson M. (2006). Iatrogenic Bile Duct Injury. A Population-Based Study of 152 776 Cholecystectomies in the Swedish Inpatient Registry. *Arch Surg*, Vol. 141, pp. 1207-1213.
- [81] Warren K.W.; & Jefferson M. (1973). Prevention and Repair of Strictures of the Extrahepatic Bile Ducts. *Surg Clin North Am*, No. 53, Vol. 5, pp. 1169-1190.
- [82] Wexler M.J.; & Smith R. (1975). Jejunal mucosal graft: a sutureless technic for repair of high bile duct strictures. *Am J Surg*, Vol. 129, pp. 204-211.
- [83] Wudel L.J.; Wright J.K.; Pinson C.W.; Herline A.; Debelak J.; Seidel S.; Revis K.; & Chapman W. (2001). Bile Duct Injury Following Laparoscopic Cholecystectomy: A Cause for Continued Concern. *The Amer Surg*, Vol. 67, No. 6, pp. 557-564.
- [84] Yeo Ch.J.; Lillemoe K.D.; Ahrendt S.; & Pitt A.P. (2002). Operative Management of Strictures and Benign Obstructive Disorders of the Bile Duct. [In:] Zuidema GD, Yeo ChJ, ed. *Shackelford's Surgery of the Alimentary Tract*. Vol III. 5th edition. WB Saunders Company, Philadelphia 2002: pp. 247-261.



## **New Advances in the Basic and Clinical Gastroenterology**

Edited by Prof. Tomasz Brzozowski

ISBN 978-953-51-0521-3

Hard cover, 546 pages

**Publisher** InTech

**Published online** 18, April, 2012

**Published in print edition** April, 2012

The purpose of this book was to present the integrative, basic and clinical approaches based on recent developments in the field of gastroenterology. The most important advances in the pathophysiology and treatment of gastrointestinal disorders are discussed including; gastroesophageal reflux disease (GERD), peptic ulcer disease, irritable bowel disease (IBD), NSAIDs-induced gastroenteropathy and pancreatitis. Special focus was addressed to microbial aspects in the gut including recent achievements in the understanding of function of probiotic bacteria, their interaction with gastrointestinal epithelium and usefulness in the treatment of human disorders. We hope that this book will provide relevant new information useful to clinicians and basic scientists as well as to medical students, all looking for new advancements in the field of gastroenterology.

### **How to reference**

In order to correctly reference this scholarly work, feel free to copy and paste the following:

Beata Jabłońska and Paweł Lampe (2012). Reconstructive Biliary Surgery in the Treatment of Iatrogenic Bile Duct Injuries, *New Advances in the Basic and Clinical Gastroenterology*, Prof. Tomasz Brzozowski (Ed.), ISBN: 978-953-51-0521-3, InTech, Available from: <http://www.intechopen.com/books/new-advances-in-the-basic-and-clinical-gastroenterology/reconstructive-biliary-surgery-in-the-treatment-of-iatrogenic-bile-duct-injuries>

# **INTECH**

open science | open minds

### **InTech Europe**

University Campus STeP Ri  
Slavka Krautzeka 83/A  
51000 Rijeka, Croatia  
Phone: +385 (51) 770 447  
Fax: +385 (51) 686 166  
[www.intechopen.com](http://www.intechopen.com)

### **InTech China**

Unit 405, Office Block, Hotel Equatorial Shanghai  
No.65, Yan An Road (West), Shanghai, 200040, China  
中国上海市延安西路65号上海国际贵都大饭店办公楼405单元  
Phone: +86-21-62489820  
Fax: +86-21-62489821

© 2012 The Author(s). Licensee IntechOpen. This is an open access article distributed under the terms of the [Creative Commons Attribution 3.0 License](#), which permits unrestricted use, distribution, and reproduction in any medium, provided the original work is properly cited.