

# Digital Templating and Correction of a Valgus Post-Traumatic Lower Limb Deformity

Francisco Lajara-Marco, Francisco J. Ricón,  
Carlos E. Morales and José E Salinas  
*Hospital Vega Baja Orihuela (Alicante)*  
*Spain*

## 1. Introduction

The management of post-traumatic deformities of the lower limb, either occurring immediately after failed primary fracture treatment leading to malunion, or developing gradually caused by an injury of the growth mechanism, is an everlasting challenge, the orthopaedic surgeon has to face.

Precise preoperative planning is a key principle of success in orthopaedic surgery. Traditionally, preoperative planning has been performed on standard radiographs with various techniques. Recently, digital templating has been proposed as a method using electronically overlay templates from a digital library on clinical radiographs for arthroplasties.

## 2. Case report

A 37-years-old man was suffering of mechanical knee pain. He previously had a non-union left diaphyseal tibial fracture and had undergone a reduction and internal fixation at least three times, an anterior cruciate ligament reconstruction with a patellar tendon autograft and a medial collateral ligament reconstruction with hamstring tendon autograft some 15 years ago. Pre-morbidity, he was HBV positive. Clinical examination revealed a combined valgus deformity by a medial collateral ligament insufficiency and a tibial shaft deformity in a multioperated lower limb with range of motion (ROM) of 0° to 140°. Radiographs revealed a malunited diaphyseal tibial fracture and degenerative changes in articular cartilage of the lateral compartment of the knee (Fig. 1). The patient, was at a relatively young age to receive a total knee arthroplasty. Additionally, he displayed good range of motion, so the patient was candidate for an osteotomy to correct the supero-lateral tilt to the joint line. (Badhe & Foster, 2002; Goradia and Van Allen, 2002; Phisitkul et al, 2006).

### 2.1 Deformity analysis

In order to analyze deformity and choose the osteotomy level we used the methods which have been described by Paley 2002. The authors have developed a universal system of geometric deformity planning based on the mechanical or anatomic axes. The place where

the axes intersect is the center of rotation angulation (CORA) of a deformity. Osteotomy level and type should be considered relative to the CORA enabling us to avoid creating secondary deformities. This type of planning is applicable to both frontal and sagittal plane deformities.

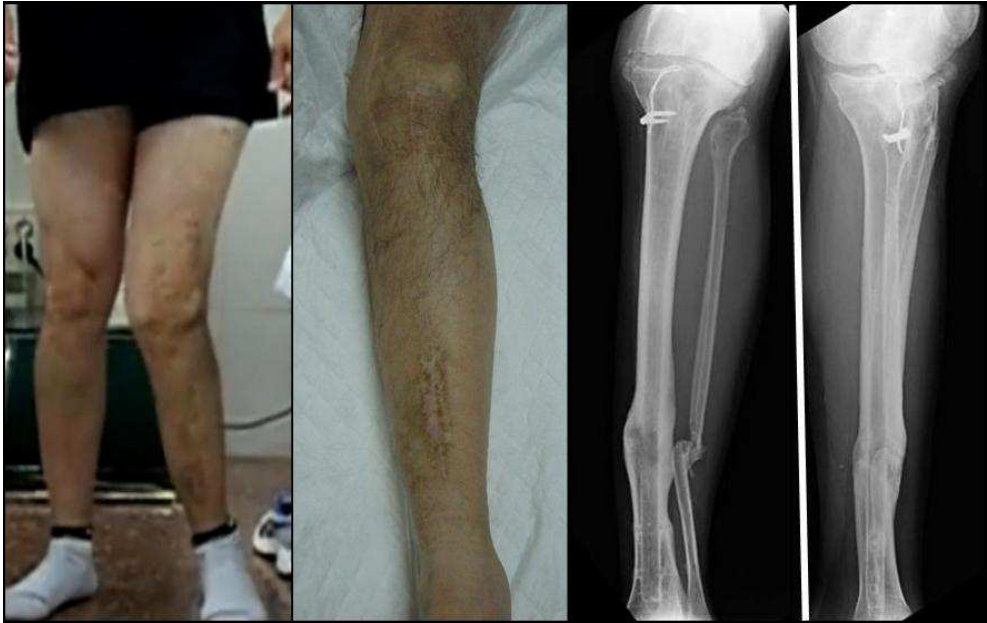

Fig. 1. Initial clinical and radiographs examination

True anteroposterior (AP) and lateral radiographs of the femur and tibia should be obtained with the knee in neutral rotation (patella forward on the AP projection). A full-length standing AP radiograph of both lower extremities including the hip, knee, and ankle on one film with the patella forward allows simultaneous assessment of alignment, length, and knee joint stability.

We have no significant deformity in the axial or sagittal plane and have a valgus knee deformity in the coronal plane that is more evident when the patient is walking because of medial collateral ligament insufficiency. So we have a static deformity due to malunited diaphyseal tibial fracture and a dynamic valgus instability caused by medial ligament injury.

When we apply the Paley's analysis we realise that we have another static component, the medial distal femoral mechanical angle (MDFMA) has  $83^\circ$  when the normal MDFMA has  $87^\circ$ . And what can we say about the tibial shaft? When we make the tibial mechanical axis planning, we come to the conclusion that this is a multiapical angulation with two CORAs, one proximal to eight centimetres of the knee joint and one distal to 13 centimetres of the ankle joint, this is the site of the old tibial shaft fracture (Fig 2).

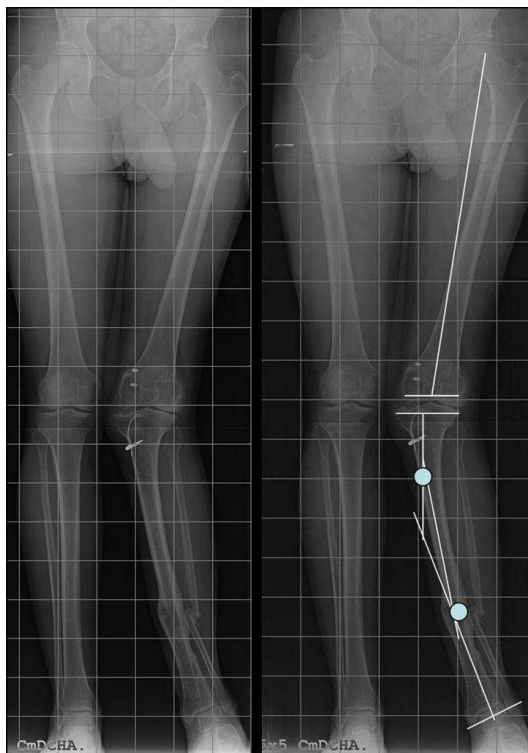


Fig. 2. Full-length standing AP radiograph of both lower extremities including the hip, knee, and ankle. Osteotomy Planning Using the Anatomic Method described by Paley

We have used **digital templating** in a clinical session, with commercially available software (Adobe Photoshop CS4; Adobe Systems Inc, San Jose, CA) (Jamali, 2009) to quickly and conveniently choose two osteotomy options. The size and shape of an opening wedge and closing wedge can be predicted and planned before surgery with the software. The virtually osteotomized tibia can then be freely transformed and rotated until the desired correction is achieved on the image. The final mechanical axis of the extremity can also be confirmed on this image to run in the desired position.

In order to prepare the two strategies we have used digital templating: (A) **Osteotomy level selection:** The level of the initial transverse osteotomy is drawn on the long, standing radiograph, then, the selection tool is used to select a rectangle around the entire tibia, ankle, and foot. (B) **Osteotomy fragment reorientation:** This image selection is copied and pasted into a new layer using the software. The virtually osteotomized tibia can then be rotated using “rotate canvas arbitrary”. This command rotates the image (clockwise or anticlockwise) by an arbitrary angle. However, we decide the value of the rotation angle in degrees, the value of the osteotomy. The final mechanical axis of the extremity can also be confirmed on this image to run in the desired position and the lateral cortical opening can be measured on the pre-operative plan. (Fig 3)

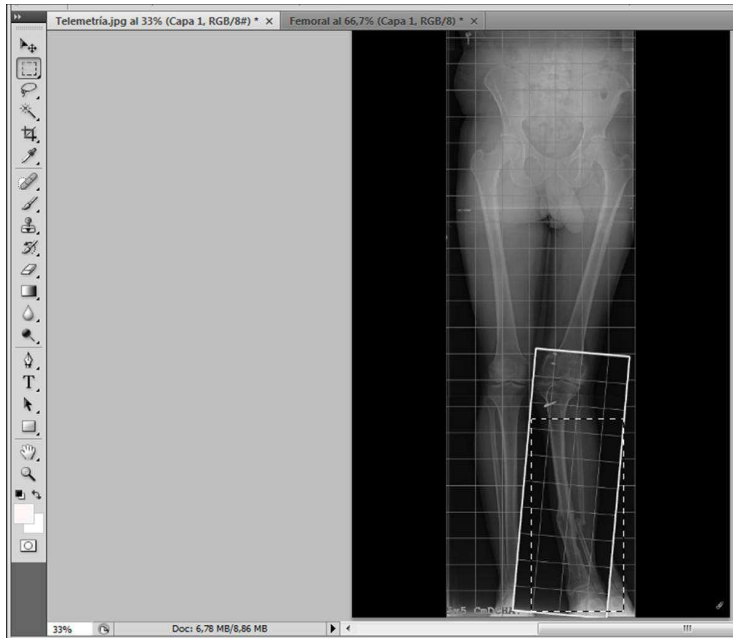

Fig. 3. Osteotomy level selection and osteotomy fragment reorientation with Adobe1 Photoshop1 CS4.

In this case, we plan two strategies. First option (no shown), one osteotomy for each problem, making of a lateral opening wedge femoral osteotomy of  $5^\circ$  and two tibial osteotomies one in each CORA, a proximal medial closing wedge tibial osteotomy of  $9^\circ$  and other distal lateral opening wedge tibial osteotomy of  $6^\circ$ . But we have to be aware that we are going to do last osteotomy on an old fracture focus. Second option (Fig 4) is making a lateral opening wedge femoral osteotomy of  $5^\circ$  and one medial closing wedge tibial osteotomy of  $16^\circ$  upper of the proximal CORA. This option has some advantages; there are places that don't have any previous surgeries, with no skin incisions and allowing fixation with two plates. However we have to accept a slight translational deformity. We opted for the second strategy.

## 2.2 Surgical technique

Distal femoral opening wedge osteotomy was performed according to Puddu (Arthrex, Naples, FL) at the distal epiphyseal region. The distal femur was approached laterally at the distal epiphyseal region. A 3-mm guide wire is drilled in the lateral condyl 1 cm above the lateral epicondyle, and directed to the origin of the medial collateral ligament (adductor tubercle) under fluoroscopic control. Over this wire a special sleeve is placed to determine the osteotomy plane. The osteotomy is made using an oscillating saw ending approximately 5 mm lateral of the medial cortex. The osteotomy plane is spread using special spreading wedges. The Puddu plate, which is designed with varying spacer blocks, is then placed over the osteotomy gap and secured proximally with traditional bicortical screws and distally with partially threaded cancellous screws. The wedge is filled with bone allografts.

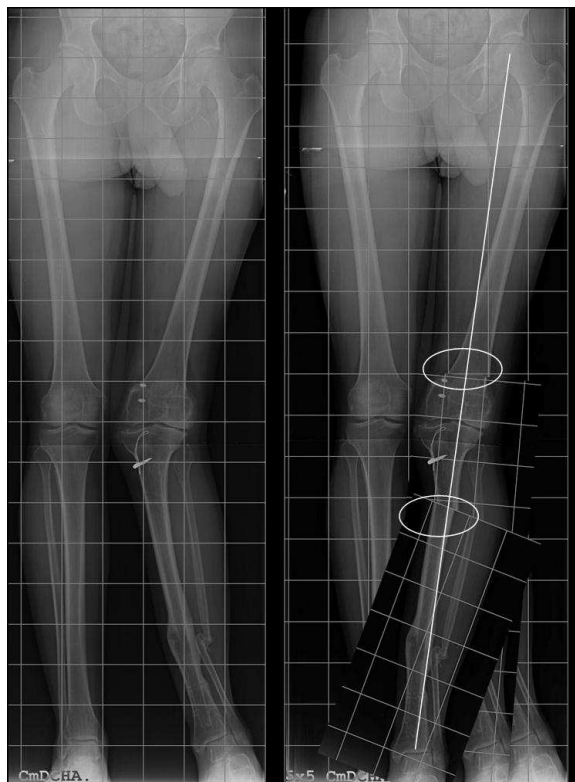

Fig. 4. Option selected: Lateral opening wedge femoral osteotomy of  $5^\circ$  and one medial closing wedge tibial osteotomy of  $16^\circ$  upper of the proximal CORA

Before medial closing wedge tibial osteotomy (TO) was made, a fibular transection was performed at the junction of the middle and distal thirds through a separate incision and the peroneal nerve was exposed and protected. A five to six centimetres long incision is made on the medial side of the tibia just at the level of the osteotomy, which is confirmed by placing a needle under fluoroscopic control, then we performed the TO using an oscillating saw, 8 cm below the medial joint line, bone wedge size was based on the preoperative calculations from the long leg standing radiograph (Fig 5). Finally, fixing it provisionally in position with a medial small locking compression plate (3,5mm LCP plate Synthes, Paoli, PA) and was ultimately fixed with a lateral 4,5mm LCP plate.

The definitive axis and the osteosynthesis are checked with the image intensifier. In order to assess mechanical axis deviation correction intraoperatively, a cautery cord is stretched from the center of the femoral head to the centre of the ankle plafond.

The last stage is to perform the posteromedial ligaments reconstruction with contralateral gracilis autograft, through a curvilinear medial-sided incision from the anteromedial proximal tibia to the medial femoral epicondyle. It is tensioned at 30 degrees and fixed with two bioabsorbable interference screws.

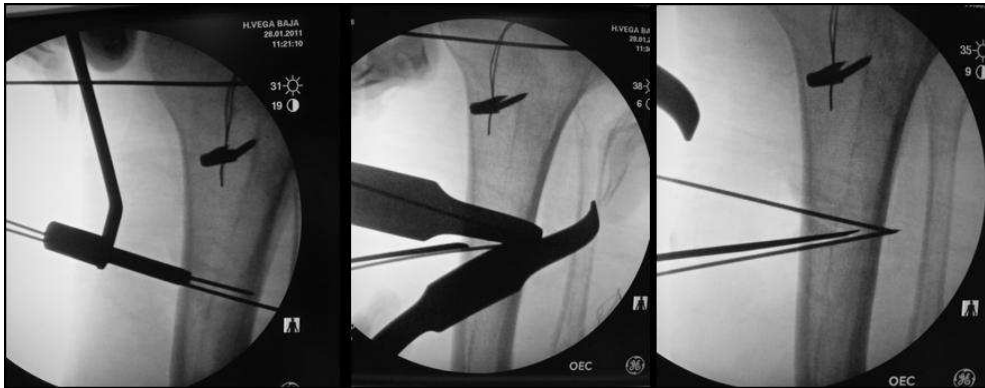

Fig. 5. Medial closing wedge TO fluoroscopic control

### 2.3 Postoperative management

Postoperatively, the leg was placed in a hinged knee brace locked 30° of flexion (Fig), due to medial ligaments reconstruction. The patient was initially non-weight bearing, with crutches. The patient was allowed to undergo protected range of motion from 0 to 90° at 4 weeks postoperatively. Full range of motion was regained after 8 weeks, because of the distal femoral osteotomy which slowed down rehabilitation. However, even with two extra articular procedures, postoperative arthrofibrosis did not occur. Partial weight bearing was allowed 12 weeks after the operation. The patient returned to full weight bearing 20 weeks after the operation.

### 2.4 Results

Patient was very satisfied with the result. He kept a full range of motion and he could walk and ride a bike without any significant pain (Fig 6) However, even if improvement in gait pattern was achieved the medial collateral ligament remained slightly lax.

His osteotomy sites appeared healed and the tibiofemoral angle was corrected, the time needed to achieve complete clinical and radiographic bone union was 12 weeks. No complications were encountered, such as delayed union, nonunion, deep infection, skin necrosis, peroneal nerve and vascular injury. There was one case of superficial infection; this was fixed by surgical debridement and antibiotic treatment.

### 3. Conclusion

Commercially available software can be used with a step-by-step technique for orthopaedic applications with lower cost and increased flexibility than commercial orthopaedic software. We have used this technique of digital templating to discuss all osteotomies options in order to quickly and conveniently choose the best option for this post-traumatic valgus deformity. The size and shape of an opening wedge and closing wedge can be predicted and planned before surgery with the software.

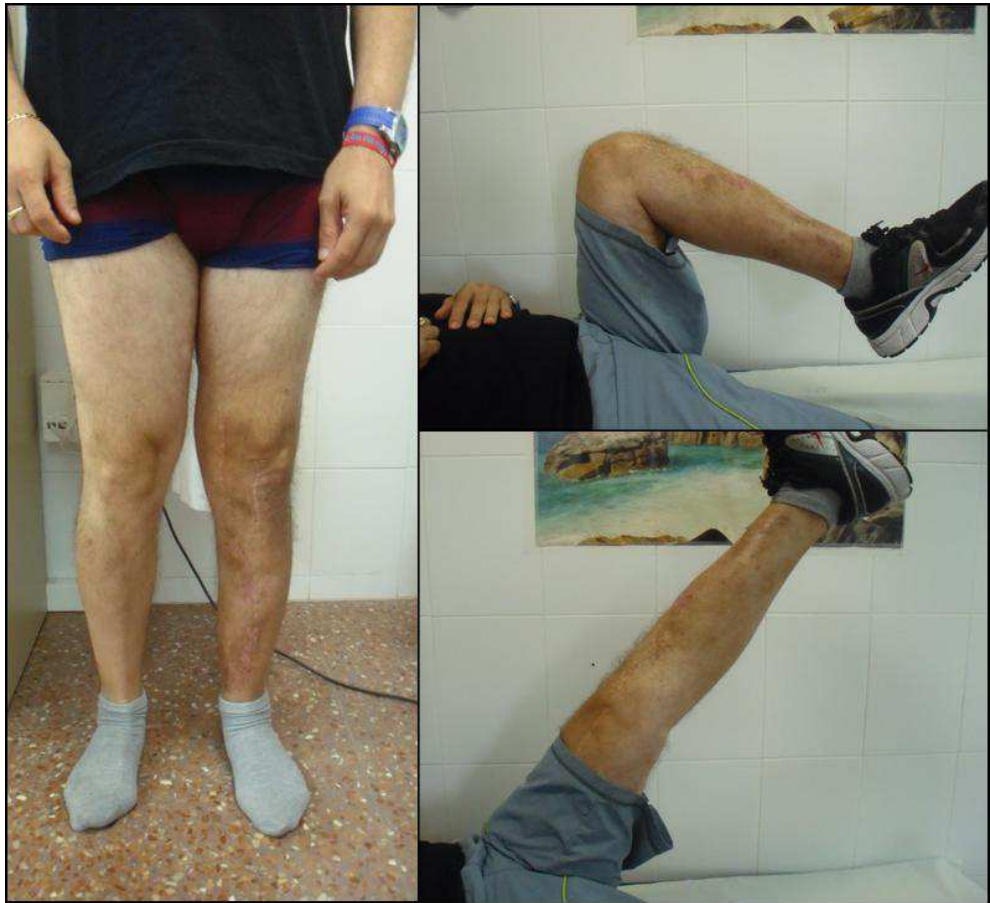

Fig. 6. Clinical view and range of motion at the last follow-up.

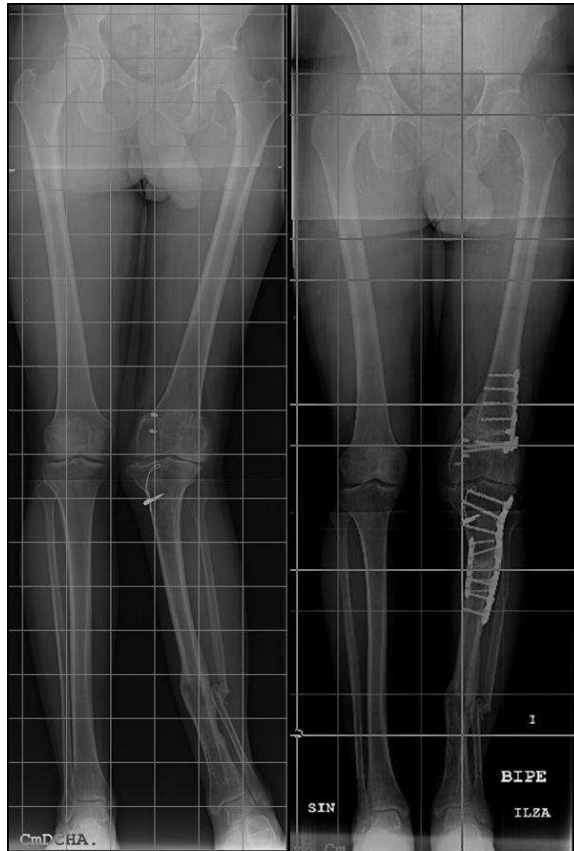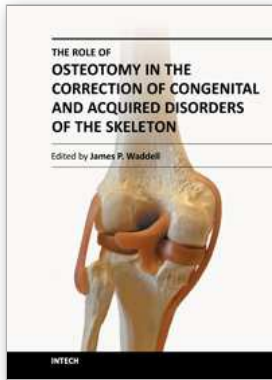


Fig. 7. Full-length standing AP radiograph of both lower extremities. Before (left side) and after (right side) osteotomies.

#### 4. References

- Badhe NP, Forster IW. (2002) High tibial osteotomy in knee instability: the rationale of treatment and early results. *Knee Surg Sports Traumatol Arthrosc.* Vol 10, No 1, (January 2001), pp 38-43, ISSN. 0942-2056
- Goradia VK, Van Allen J. (2002) Chronic lateral knee instability treated with high tibial osteotomy. *Arthroscopy* Vol 18, No7, (September 2001) pp 807-811. ISSN 0749-8063
- Jamali AA. (2009) Digital templating and preoperative deformity analysis with standard imaging software. *Clin Orthop Relat Res.* Vol 467, No 10, (May 2009), pp 2695-704. ISSN : 1528-1132
- Paley D. (2002). *Principles of Deformity Correction* (1st edition), Springer-Verlag, ISBN : 3-540-41665-X, New York, NY.
- Phisitkul P, Wolf BR, Amendola A. (2006) Role of high tibial and distal femoral osteotomies in the treatment of lateral-posterolateral and medial instabilities of the knee. *Sports Med Arthrosc.* Vol.14, No 2, (June 2005 ), pp 96-104. ISSN 1062-8592





## **The Role of Osteotomy in the Correction of Congenital and Acquired Disorders of the Skeleton**

Edited by Prof. James Waddell

ISBN 978-953-51-0495-7

Hard cover, 294 pages

**Publisher** InTech

**Published online** 11, April, 2012

**Published in print edition** April, 2012

This book demonstrates specific osteotomy techniques from the skull to the hallux. The role of osteotomy in the correction of deformity is under appreciated in part because of the ubiquitous nature of joint replacement surgery. It should be remembered, however, that osteotomy has a role to play in the correction of deformity in the growing child, the active young adult, and patients of any age with post-traumatic deformity limiting function and enjoyment of life. In this text we bring you a number of papers defining specific problems for which osteotomy is found to be an effective and lasting solution. I hope you find it useful.

### **How to reference**

In order to correctly reference this scholarly work, feel free to copy and paste the following:

Francisco Lajara-Marco, Francisco J. Ricón, Carlos E. Morales and José E Salinas (2012). Digital Templating and Correction of a Valgus Post-Traumatic Lower Limb Deformity, The Role of Osteotomy in the Correction of Congenital and Acquired Disorders of the Skeleton, Prof. James Waddell (Ed.), ISBN: 978-953-51-0495-7, InTech, Available from: <http://www.intechopen.com/books/the-role-of-osteotomy-in-the-correction-of-congenital-and-acquired-disorders-of-the-skeleton/digital-templating-and-correction-of-a-valgus-post-traumatic-lower-limb-deformity->

**INTECH**  
open science | open minds

### **InTech Europe**

University Campus STeP Ri  
Slavka Krautzeka 83/A  
51000 Rijeka, Croatia  
Phone: +385 (51) 770 447  
Fax: +385 (51) 686 166  
[www.intechopen.com](http://www.intechopen.com)

### **InTech China**

Unit 405, Office Block, Hotel Equatorial Shanghai  
No.65, Yan An Road (West), Shanghai, 200040, China  
中国上海市延安西路65号上海国际贵都大饭店办公楼405单元  
Phone: +86-21-62489820  
Fax: +86-21-62489821

© 2012 The Author(s). Licensee IntechOpen. This is an open access article distributed under the terms of the [Creative Commons Attribution 3.0 License](#), which permits unrestricted use, distribution, and reproduction in any medium, provided the original work is properly cited.