

# Myofascial Trigger Point: Symptoms, Diagnosis, Intervention

Bang Nguyen  
*Darebin Community Health  
Australia*

## 1. Introduction

It is acknowledged in medicine that being physically active has overall positive health benefits by reducing the risk of chronic health problems such as cardiovascular disease, diabetes, some forms of cancer, osteoporosis, obesity, falls and fractures, and some mental health problems (Brukner & Brown, 2005; Owen et al., 2007). However, some of us take it to the extreme in sports, whilst others need to be persuaded to be active on urgent medical advice. Even so, regardless of our level of activity or occupation, most of us would have experienced musculoskeletal (MSK) pain at one point or another. It is estimated that between 13.5 and 47% of the general population have MSK pain (Cimmino & Ferrone, 2011; Fleckenstein et al., 2010). The threat of MSK pain can prevent us from enjoying daily physical activities. With significant implications for public health and wellbeing, MSK injury prevention, diagnosis, intervention, rehabilitation occupies an important space in the general population and contemporary sports medicine.

The search for the underlying cause of MSK pain has been controversial to date. Due to its puzzling characteristics, current popular interventions for MSK disorders have focused mainly on the site and symptoms of pain, not the source of pain and have been rewarded with limited success (see table 2). Clinicians might not be aware that in the majority of MSK disorders pain is referred (Nguyen, 2010). The path to a clear, accurate pathological diagnosis and intervention has been impeded by misdiagnosis influenced by preconceived notions of the pathogenesis. Myofascial trigger point (MTrP) hypothesis offers a distinctive and direct pathway towards the aetiology, leading to an accurate diagnosis, resolution and reliable outcomes for MSK disorders. This chapter aims to present the relationship between MSK disorders and MTrP, including diagnosis, as well as ischaemic compression (IC) as an effective technique to resolve MSK disorders.

## 2. Current context

Musculoskeletal is a general term which relates to muscles and the skeleton. The MSK system involves tendon, muscle, fascia, bones, bursa, joints and associated tissues that move the body and maintain its form. The orthodox approach in research and treating MSK pain has focused on the immediate site and not the source of pain in the local area. Plantar heel pain (a type of MSK pain) has frustrated clinicians, not through a lack of effort or will, but more its stubborn resistance to interventions. Consider the pathogenesis of plantar heel pain (PHP). The

evolution of the pathogenesis of PHP began with inferior calcaneal exostoses (spurs) hypothesis but when this was not so (Shama et al., 1983), repetitive trauma to the plantar fascia causing microtears and inflammation hypothesis (fasciitis) suggested (Barrett, 1999), but when inflammation was not evident, a degenerative process (fasciosis) was proposed (Lemont et al., 2003). The current diagnosis is fasciopathy. The same parallel can be drawn for Achilles enthesopathy, Achilles tendonitis, Achilles tendinosis and Achilles tendinopathy. These terms are commonly used by clinicians to describe MSK disorders of the body.

There are at least 16 different pathomechanical hypotheses dealing with foot and ankle mechanics (see Table 1).

<b>Pathomechanical hypotheses</b>	
<ul style="list-style-type: none"> <li>▪ Traditional (Root, Orien, Weed)</li> <li>▪ Sagittal plane facilitation theory</li> <li>▪ Pressure mapping</li> <li>▪ Pathology specific prescribing</li> <li>▪ The windlass</li> <li>▪ High gear/low gear</li> <li>▪ Subtalar axis location rotation equilibrium (SALRE)</li> <li>▪ Preferred motion pathway</li> </ul>	<ul style="list-style-type: none"> <li>▪ Centre of pressure</li> <li>▪ Foot typing approaches</li> <li>▪ Neoteric biomechanics</li> <li>▪ Bottom block theory</li> <li>▪ Tissue stress</li> <li>▪ Functional foot drop</li> <li>▪ Sensory/proprioceptive models</li> <li>▪ Maximum Arch Subtalar Supination (MASS)</li> </ul>
Adapted from Payne C. 2010 (unpublished)	

Table 1. Pathomechanical hypothesis

Accordingly, there are 13 plus interventional modalities that claim to have therapeutic effects on plantar heel pain (see Table 2).

The interventional modalities used for plantar heel pain are also commonly used in other areas of the body to treat MSK pain. The interventions are diverse and range from a simple heel pad to radiotherapy (Miszczyk et al., 2007). Autologous platelet injections is a relatively recent procedure used to reverse the degenerative process of neovascularisation diagnosis of tendinosis (Peerbooms et al., 2010).

If the pathogenesis remains speculative and elusive, associated with limited clinically meaningful and reliable outcomes, future hypotheses will become more elaborate and creative.

MTrP therapy is an effective intervention because the therapy relates directly to the muscle pathology, clinical symptoms, biomechanics, context and its predictable and reliable outcomes. The concept of MTrP pain is not new. An intimate understanding of the clinical application is deficient, knowledge of the significant impact on MSK pain is unappreciated because of sporadic awareness and usage by health professionals. MTrP has been used in isolation from its clinical manifestations in the past, restraining its real potential, cumulative knowledge and adoption by clinicians.

Likely to be beneficial	Unknown effectiveness	Likely to be ineffective or harmful
<ul style="list-style-type: none"> <li>• Casted custom made insoles improved function but not pain at 3 months. There was no difference between casted and prefabricated orthoses.</li> <li>• Taping (low dye or anti pronatory taping). Limited evidence of pain relief at 1 week and no evidence beyond 1 week.</li> </ul>	<ul style="list-style-type: none"> <li>• Corticosteroid injection used in the short term alone.</li> <li>• Corticosteroid injection combined with other interventions</li> <li>• Night splints combined with NSAIDs.</li> <li>• Heel pads only or combined with other interventions.</li> <li>• Local anaesthetic injection.</li> <li>• Electrotherapy:               <ul style="list-style-type: none"> <li>- Extracorporeal shock wave therapy</li> <li>- Ultrasound</li> <li>- Lasers</li> </ul> </li> <li>• Surgery</li> <li>• Platelet rich plasma injection</li> <li>• Chiropractic manipulation</li> <li>• Stretching exercises (Achilles tendon &amp; plantar fascia stretching).</li> <li>• Magnetic insoles</li> <li>• Acupuncture</li> </ul>	<ul style="list-style-type: none"> <li>• Corticosteroid injection in the medium to long term.</li> <li>• Corticosteroid injection plus local anaesthetic injection in the medium to long term combined with NSAIDs or heel pads.</li> </ul>
<p>Adapted from Buchbinder, 2004; Landorf &amp; Menz, 2008; McPhoil et al., 2008; Roxas, 2005; Stuber &amp; Kristmanson, 2006.</p>		

Table 2. Interventions

### 3. Characteristics of myofascial trigger point

Unlike direct trauma, blunt injury, cutaneous or ischaemic pain, the characteristics of MTrP pain are not confined to a local. MTrP pain is modulated by pain-sensitive nerve endings known as nociceptors. Nociceptors are found within bones, joint capsules, cartilage, ligaments, muscles, tendons, muscle fascia and bursa (Pearce, 2004). Chemicals released by

damaged tissues or mechanical force can stimulate these nociceptors. Early signs of MSK injury are muscular deficiencies, pain, tightness and sometimes accompanied with autonomic phenomenon, sensation of vasoconstrictions or pilomotor activity (Travell & Simons, 1999). MSK pain usually occurs as a result of overuse, unconditioned, abrupt increase, tight, or sustained awkward eccentric or concentric loading of muscles.

From the author's experience, MTrP is not a common diagnosis used by health professionals. It is easy to miss if clinicians are not familiar with the diagnosis. The consequence of this experience is that one of the most common causes of musculoskeletal pain and disorders, is under-treated and the receipt of effective and timely treatment is delayed or not at all. This could place strains on the financial resources when other inappropriate investigations or treatments are used (Hey & Helewa, 1994).

MTrP is defined as a distinct, focal, hyperirritable spot in skeletal muscle that is associated with a hypersensitive spot in a taut band. Active MTrPs are painful either spontaneously, upon mechanical or chemical stimulation and may give rise to referred pain, motor dysfunction and autonomic phenomenon (Travell & Simons, 1999). Latent MTrPs are painful on stimulation but cause no spontaneous pain. This often precedes active trigger points and is seen in tight, weak muscles. In MTrP pain, the pain is not the source of pain but usually a distance from the source in the reference zone, unless it involves intrinsic muscles. From the author's experience, the focal pain at the medial tubercle of the calcaneus in plantar heel pain is a MTrP itself. Clinically, full expression of all the documented characteristics of referred pain upon stimulation of MTrP depends on the muscle and degrees of hypersensitivity but the effects all resulted in musculoskeletal pain. Plantarflexors of the ankle when mechanically stimulated do not always refer pain into the foot compared to the ankle dorsiflexors. The ankle dorsiflexors are primarily responsible for causing dorsal foot pain and is a good example of local tenderness, pain recognition and presence of a taut band (Hong & Simons, 1998). The involuntary or local twitch response often mentioned in medical literature (Hong, 1994) is often observed more in gluteal and plantar flexors of the foot muscles of hypertonic athletes, but not in the general population. Another often described feature is a palpable nodule in a taut band. A nodule is not always present at a MTrP.

Depending on the depth of the MTrP and thickness of the muscle, the tactile sensation of MTrPs has different contrasts. The tactile sensation and texture of the infraspinatus is thin, superficial, bony and tendinous. The erector spinae is superficial and a thick ropy band. The gluteal muscles, are thick, spongy and deep. The priority should always be on locating the MTrPs accurately. With more practice, familiarity and application of the technique, practitioners will gain rapid confidence in the use of MTrP therapy and learn to manage its peculiar characteristics more effectively.

Another important characteristic of MTrP is that it does not refer pain in dermatomal or myotomal patterns (Fomby & Mellion, 1997) but relates more to each individual muscle or the muscle's group action. One technique used to isolate the affected muscle or muscle group is to repeat the movements that caused pain and observe the agonist and antagonist muscle. The muscles that should be studied closely are the muscles that are being strained the most, or compensating for the opposing tight muscles. For example, lateral dorsal foot pain when the peroneal group is fatigued by tight foot plantar flexors. In addition, also observe for any abnormal eccentric or concentric contractions of muscle through prolonged abnormal angulation, rotation or position.

#### 4. Patient history

Clinical diagnosis relies on the natural history and physical examination. In order to ascertain adequate clinical information to make an informed diagnosis, these clinical considerations need to be evaluated:

1. onset of injury
2. type of pain sensation and intensity
3. type of action/activity that aggravates the pain
4. duration of pain
5. engaged in recent unaccustomed training or sports
6. any recent period of muscular inactivity
7. any abrupt increased or changes to levels of physical activity
8. any systemic medical condition or diabetic neuropathy
9. any obvious trauma/muscle tear
10. body symmetry and limb length discrepancy
11. joint subluxation
12. predisposing and perpetual factors such as Vit D , magnesium and iron deficiencies
13. peripheral vascular disease
14. morning pain, rest pain or symptoms aggravated by changes in the weather
15. autonomic phenomenon eg, skin temperature, hypersensitivity, goosebumps and colour
16. muscle fatigue
17. abnormal muscular compensation
18. muscle flexibility
19. pain with mechanical stimulation
20. muscle tenderness, deficiency, stiffness and weakness with/without atrophy
21. underlying infections, bony stress reaction or fracture
22. non specific arthritis

Age is not immuned from MSK pain, however older people are usually affected by their sedentary lifestyle and consequently their muscle conditioning. Occasionally clients forget how old they are and have not adjusted their expectations of what they can do comfortably and recovery time required. Their ambition sometimes exceeds their ability. Sever's disease (calcaneal apophysitis), is thought to be a cause of plantar heel pain in mainly boys between 6-10 years of age (Barrett, 1999). The disease is more likely to be consequences of excessive sporting commitments and inadequate stretching, and has responded well to MTrP therapy from clinical experience. There are currently no laboratory tests or medical imaging techniques capable of confirming the presence of MTrPs. Diagnosis is based on clinical investigations with no standardized reliable laboratory or diagnostic imaging studies available. This does not mean MTrP is rare, difficult to diagnose or arbitrary. The most reliable features necessary for identifying MTrPs are localised tenderness, presence of a taut band and pain recognition (Gerwin, 2010; Hong & Simons, 1998).

#### 5. Clinical examination

To identify MTrP, the exact location of the symptoms of pain must be isolated. Upon locating the pain, ask for the movements that reproduce the symptoms and passively take it through its full range of motion. Observe for the muscles that are under strained throughout

the movement. A working knowledge of biomechanics is an advantage, as it helps to identify and explain the possible pathomechanics and abnormal compensation.

Evaluate the predisposing factors guided by the clinical history to locate the most probable primary trigger points and muscles implicated. Sometimes clinical skill is important to differentiate between similar symptoms caused by different pathogenesis. For instance, a middle age client with type II diabetes for 5 years with a sedentary lifestyle was recently encouraged to increase physical activity under medical advice to reduce the risk of diabetes complications. After a few days of activity, the client returned and complained of unilateral dorsal foot pain. In this scenario, it is very tempting to assume and without further investigations of a muscular nature, dismiss it as early onset of neuropathy or peripheral vascular disease. In another situation, a patient presented with mild hallux abducto valgus (bunion) according to the (Garrow et al., 2001), no pressure-related lesions noted but hypersensitive to footwear and light touch at the joint medially and pain radiating into the proximal phalanx dorsally. The overlap in each of these scenarios may confuse the clinical picture and can undermine the confidence of an accurate diagnosis. In the diabetic patient, when the muscles of the leg were thoroughly assessed, there was ankle equinus and MTrPs detected at the origin of the ankle dorsiflexors, secondary to muscle fatigue, compensating for tight foot plantarflexors. In the patient with the bunion, MTrPs detected in the lower third of the ankle plantarflexors.

## **6. Pathophysiology of myofascial trigger points**

The pathophysiology of myofascial pain is poorly understood. The aetiology of MTrP is focused on dysfunctional motor endplates as the centrepiece of the pathology (McPartland & Simons, 2006). Local muscle contractions compress sensory nerves, blood vessels and interrupt normal physiological interactions at the neuromuscular junction. The local physiological changes initiated by local ischaemia and hypoxia result in tissue damage, which releases cellular chemicals.

Chemicals released by damaged tissues such as histamine, serotonin, bradykinin, prostaglandin, leukotrienes and substance P, initiates the pain sequence. When chemical mediated nociceptors are stimulated, the activation threshold of a neuron is reduced and consequently the nociceptors require less stimulation to fire. This leads to peripheral sensitisation and hyperalgesia.

Prolonged nociceptive signals from MTrP may eventually cause central sensitisation where the central nervous system (CNS) is recruited into the pain perpetuation cycle. The autonomic nervous system (ANS) also contributes to the overall sensitisation of the CNS, facilitated by its various spinal reflex activities. In some cases of MTrP, there is a definite perception of involuntary vascular activity, involving the ANS. Complaints of paraesthesia, vasoconstrictions and pilomotor activity are not uncommon in the reference zone. Clinically, it is often reported that there is recovery of normal sensation and perception of increased circulation once MTrPs are inactivated.

## **7. Indications for MTrP therapy by ischaemic compression**

The client medical, natural, occupational history and clinical examinations should provide adequate support to make clear clinical diagnosis of MTrP or otherwise. Indications for use

of MTrP therapy are usually when there is a high index of suspicion of non specific joint pain, with no supporting clinical or imaging evidence, muscle deficiency with or without atrophy and no obvious trauma or inflammation. An accurate diagnosis is crucial for the success of the intervention of MTrP therapy. In general, observe the area of pain and identify which muscles are implicated. Test for muscle range of motion, tightness, muscle weakness, muscle vitality and biomechanics. A MTrP would trigger a deep, dull pain and the description of pain differs from one region of the body to another depending on the profile of the muscles concerned, as discussed earlier. A MTrP is hypersensitive/exaggerated pain with initial moderate ischaemic compression (IC) pressure and pain should gradually eased off within 60 seconds. If not, reassess the diagnosis or check the technique, be vigilant to avoid pressing on bony prominences. This should be followed up by three deliberate, prolonged, elongated stretches of the affected muscles' holding for 30 seconds each time and repeating at least twice a day. The highest reported reduction of pain is usually after the first treatment. The affected limb should feel lighter, flexible and improved in strength immediately after intervention. The procedure should be followed up at the clinic several days apart or if possible repeat same at home until the MTrP area is painless on compression. Depending on the chronicity, MTrP could resolve within a few days to two weeks with daily therapy and stretching. Muscle stretching is ongoing even long after the pain is gone. The pain intensity upon compression of MTrP diminished subsequently after each treatment at the same MTrP. Do not expect the same intensity levels of pain thereafter. The concept of IC can be applied widely whenever there is MSK pain due to MTrP. For example, MSK conditions such as plantar heel pain, low back pain, patellafemoral pain syndrome, groin pain, sciatica without radiculopathy, frozen shoulders, carpal tunnel syndrome and Sever's disease have been successfully treated with MTrP therapy. Differential diagnosis should also be noted but is rare, such as rheumatoid arthritis, crystal deposition arthropathies, osteoporosis, diffuse idiopathic skeletal hyperostosis, diabetes mellitus, hypertrophic osteoarthropathy, Paget's disease, hyperlipidemia, sarcoidosis, sickle cell anemia, acromegaly, ankylosing spondylitis, psoriatic arthritis, Reiter's syndrome, Bechet's syndrome and systemic lupus erythematosus (Barrett, 1999; Lichniak, 1990).

Following the correct order for MTrP therapy is very important. Muscles affected by MTrP are tight and are resistant to stretching. IC relaxes the muscle, decreases pain and increases propensity to stretch. Stretching without IC is painful, slow resolution, impractical, safety and permanency are some concerns (Fahlstrom et al., 2003). The following sequence is suggested

1. MTrP deactivation
2. Muscle stretching
3. Proprioceptive exercises to improve neuromuscular functions
4. Strengthening exercises
5. Power and endurance

## **8. Ischaemic compression**

Immediate strengthening exercises after injury or absence from physical activity when MTrPs are present will tighten the muscle further. This will be counter productive in relieving pain and restoring function. There are many intervention options for MTrP

therapy but only several modalities have been popular amongst clinicians, such as ischaemic compression, laser, traditional Chinese acupuncture, Western dry needling, wet needling, stretch and spray. There is some confusion between dry needling, wet needling, traditional Chinese acupuncture and ischaemic compression. These four modalities will encompass the majority of manual therapist's scope of practice if they perform MTrP therapy, given the amount of literature written and will be summarised here.

Western dry needling or intramuscular stimulation is an invasive technique where thin solid wire needles puncture the skin directly at the MTrP. The technique, if used correctly, aims to elicit a local twitch response or reproduction of pain, to confirm the accurate placement of the needles (Hong, 1994). The hypothesis for the pain-relieving mechanism is when the needle is inserted into the skin, it stimulates the release of endogenous opioids. The second hypothesis is thought to be the pain gate control theory, where one noxious stimulus offsets the previous noxious stimulus. The exact mechanisms remain uncertain. (Moffet, 2006; Selvaratnam & Knight, 1995).

Wet needling uses a hollow hypodermic needle to deliver various substances such as saline solution, local anaesthetic, botox or corticosteroid at the MTrP to achieve an analgesic effect. It has been observed that the various substances do not have an effect on the success of relieving pain at the MTrP (Lewit, 1979).

In traditional Chinese acupuncture it is thought Qi- the vital life energy found in the body's meridians is disturbed, and an imbalance of relationships between Yin and Yang. The insertion of needles at acupoints mainly along the meridians would restore normal body equilibrium. This technique remains controversial as there are no anatomical or scientific evidence to validate the existence of Qi or meridians. A recent review claimed little convincing evidence traditional acupuncture is effective in relieving pain, and adverse events continue to be reported (Ernst et al., 2011). However these claims are strongly contested and the counter claims that inappropriate methodology, interpretations and conclusions were reached (Bovey et al., 2011). Acupuncture as a modality needs to be appraised, respected and require adequate proficiency gained before practice (Dommerholt et al., 2006).

Ischaemic compression is firm sustained compression at a MTrP. The hypothesis suggests compression lengthens the shortened sarcomere, the subsequent release of pressure corresponds to reactive hyperaemia which flushes away noxious substances and by-products of cellular metabolism that foster muscle contraction (Mance et al., 1986). This technique requires interaction between the client and practitioner. The client will assist the practitioner to locate the exact position of the MTrPs, if the practitioner is not accurate in locating it initially. With more practice and experience accumulated, the practitioner will have more confidence and be more efficient in locating the MTrPs with minimum assistance from the client. It is a safe technique with immediate effectiveness and treats the muscle pathology directly.

After MTrPs have been deactivated, ongoing muscle stretching and conditioning should reflect the daily or sporting demands. Muscle stretching should ongoing and prophylactic to maintain muscle flexibility and to minimise recurrence. The rationale for selecting IC as the preferred modality by the author is it avoids the medicolegal, efficacy, competency, practicality and client safety.



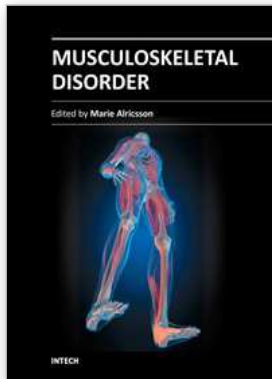
## 9. Conclusion

Myofascial trigger point as a cause of MSK disorders and dysfunction is more pervasive clinically than it has been revealed in the literature. Its significance and potential is still to be appreciated and embraced by the scientific and clinical communities. With mounting clinical evidence, clinicians should not hesitate to consider MTrP as a diagnosis for MSK disorders and apply IC as an intervention. IC is safe, affordable, non invasive, effective, rapid, and user friendly. It is a distinctive technique to resolve MSK pain and deficiencies from all other modalities currently available. IC accounts for the pathogenesis and pathophysiology involved in MSK disorders. In addition, it has huge economic implications as it reduces potential harmful interventions, shortens the course of illness and minimises unnecessary medical expenses through accurate diagnosis. Failure to recognise MTrP as a common MSK disorder is detrimental to clients and health systems with scarce resources.

## 10. References

- Barrett, SL., O'Malley, R. (1999) Plantar Fasciitis and Other Causes of Heel Pain. *Am Fam Physician*, 59(8), pp.(2200-2206)
- Bovey, M., Deadman, P. (2011) A response to "Acupuncture: Does it alleviate pain and are there serious risks? A review of reviews" by E. Ernst, Myeong Soo Lee and Tae-Young Choi, PAIN@, Volume 152, Issue 4 (April 2011). *The Journal of Chinese Medicine*. <http://www.jcm.co.uk/drum-tower-archive/mark-bovey/>
- Brukner, PD., Brown, WJ. (2005) Is exercise good for you? *MJA* , 183 (10), pp. (538-541)
- Buchbinder, R. (2004) Plantar Fasciitis. *New England Journal of Medicine*, 350(21), pp. (2159-2166)
- Cimmino MA., Ferrone C. (2011) Epidemiology of chronic musculoskeletal pain. *Best Practice & Research Clinical Rheumatology*, 25(2), pp.(173-178)
- Dommerholt, J., del Moral, OM., Grobli, C. (2006) Trigger Point Dry Needling. *J Manual & Manipulative Ther*, 14(4), pp. (E70-E87)
- Ernst, E., Lee, MS., Choi, TY. (2011). Acupuncture: does it alleviate pain and are there serious risks? A review of reviews. *Pain*, 152(4), pp.(755-64)
- Fahlstrom M, Jonsson P, Lorentzon R, Alfredson H. (2003) Chronic Achilles tendon pain treated with eccentric calf-muscle training. *Knee Surg Sports Traumatol Arthrosc* 11, pp. (327-33)
- Fleckenstein, J., Zaps, D., Ruger, LJ., Lehmeyer, L., Freiberg F., Lang, PM., Irrnich, D. (2010) Discrepancy between prevalence and perceived effectiveness of treatment methods in myofascial pain syndrome: Results of a cross-sectional, nationwide survey, *BMC Muscular Skeletal Disorders*, 11:32
- Fomby, EW., Mellion, MB. (1997) Identifying and Treating Myofascial Pain Syndrome. *The Physician and Sportsmedicine*, 28(2),pp.(67-75)
- Garrow, AP. Papageorgiou, A., Silman,AJ., Thomas, E., Jayson, MIV., Macfarlane, GJ. (2001) The Grading of Hallux Valgus Manchester Scale, *J Am Podiatr Med Assoc*, 91(2), pp. (74-78)
- Gerwin, RD. (2010) Myofascial pain syndrome, In: *Muscle pain: Diagnosis and Treatment*, S. Mense and R.D. Gerwin, pp. (15-83)
- Hey, L., Helewa, A. (1994) Myofascial pain syndrome: a critical review of the literature. *Physiother Canada*, 46(1), pp. (28-35)

- Hong, CZ. (1994) Lidocaine injection versus dry needling to myofascial trigger point. The importance of the local twitch response. *Am J Phys Med Rehabil*, 73(4), pp.(256-63)
- Hong, C., Simons, DG. (1998) Pathophysiologic and Electrophysiologic Mechanisms of Myofascial Trigger points. *Arch Phys Med Rehabil*, 79(7), pp.(863-872)
- Landorf, KB., Menz, HB. (2008) Plantar heel pain and fasciitis. *BMJ Clinical Evidence*, 02:1111
- Lemont, H., Ammirati, KM., Usen, N. (2003) Plantar Fasciitis A Degenerative Process (Fasciosis) Without Inflammation. *J Am Podiatr Med Assoc*, 93(3),pp.(234-237)
- Lewit, K. (1979) The needle effect in the relief of myofascial pain. *Pain*, 6 (1) pp. (83-90)
- Lichniak JE. (1990) The heel in systemic disease. *Clin Podiatr Med Surg*, 7(2), pp. (225-241)
- Mance, D., McConnell, B., Ryan, PA. (1986) Silverman M, Master G. Myofascial pain syndrome. *J Am Podiatr Med Assoc*, 76(6), pp. (328-31)
- McPartland JM, Simons DG. (2006) Myofascial Trigger points: Translating Molecular theory into Manual Therapy. *J Manual & Manipulative Ther*, 14(4), pp. (232-239)
- McPoil, TG., Cornwall, MW., Wukich, DK., Irrgang, JJ., Godges, JJ., Martin, RL. (2008) Heel pain - Plantar fasciitis: Clinical practice guidelines linked to the international classification of function, disability, and health from the orthopaedic section of the American Physical Therapy Association. *J Orthop Sports Phys Ther*, 38(4), pp. (A1-A18)
- Miszczyk, L., Jochymek, B., Wozniak, G. (2007) Retrospective evaluation of radiotherapy in plantar fasciitis. *The British Journal of Radiology*, 80, pp. (829-834)
- Moffet H. (2006) How might acupuncture work? Asystemic review of physiologic 454 rationales from clinical trials. *BMC Complement Altern Med*, 6:25.
- Nguyen, BM. (2010) Trigger points therapy and plantar heel pain: A case report. *The Foot*, 20, pp.(158-162)
- Owen, N., Spthonis, K., Leslie, E. (2007) Physical Activity and Health, In: *Cambridge Handbook of Psychology, Health and Medicine*. Ayers, S. Baum, A. McManus, C. et al., pp.(155-157), Cambridge University Press.
- Payne C. (2010) Biomechanics Workshop Manual. (Unpublished)
- Pearce, JM. (2004) Myofascial pain, fibromyalgia or fibrositis? *Eur Neurol*, 52(2), pp.67.
- Peerbooms, JC., van Laar, W., Faber, F., Schuller, HM., van der Hoeven, H., Gosen, T (2010) Use of platelet rich plasma to treat plantar fasciitis: design of a multi centre randomized controlled trial. *BMC Musculoskeletal Disorders*, 11:69
- Roxas, M. (2005) Plantar fasciitis: diagnosis and therapeutic considerations. *Alternative medicine review*, 10(2), pp. (83-93)
- Selvaratnam, P., Knight, K. (1995) Acupuncture, In: *Sports physiotherapy: applied science and practice*, M. Zuluaga, pp. (289-294) Churchill Livingstone, Melbourne
- Shama, SS., Kominsky, SJ., Lemont, H. (1983) Prevalence of non-painful heel spur and its relation to postural foot position. *J Am Podiatr Med Assoc*, 73, pp.(122-123)
- Simons, DG., Travell, JG., Simons, LS. (1999) *Myofascial pain and dysfunction: The trigger point manual. Volume 1: Upper half of body*. 2nd ed. MD: Williams & Wilkins, Baltimore
- Stuber, K., Kristmanson, K. 2006 Conservative therapy for plantar fasciitis: a narrative review of randomized controlled trials. *J Can Chiropr Assoc*, 50(2), pp. (118-133)



## **Musculoskeletal Disorder**

Edited by Prof. Marie Alricsson

ISBN 978-953-51-0485-8

Hard cover, 82 pages

**Publisher** InTech

**Published online** 04, April, 2012

**Published in print edition** April, 2012

Work-related musculoskeletal disorders are a significant problem throughout the world. The work environment has undergone rapid changes in recent years. With increasing number of workers being tied to man, machine systems, susceptibility to constrained postures, visual strain and mental and physical stresses have increased. This book is a collaboration among many clinicians and researchers and a small step in addressing these issues by discussing various aspects of musculoskeletal disorders from different professions, researchers and countries.

### **How to reference**

In order to correctly reference this scholarly work, feel free to copy and paste the following:

Bang Nguyen (2012). Myofascial Trigger Point: Symptoms, Diagnosis, Intervention, Musculoskeletal Disorder, Prof. Marie Alricsson (Ed.), ISBN: 978-953-51-0485-8, InTech, Available from:  
<http://www.intechopen.com/books/musculoskeletal-disorder/musculoskeletal-pain-symptoms-diagnosis-and-intervention>

**INTECH**  
open science | open minds

### **InTech Europe**

University Campus STeP Ri  
Slavka Krautzeka 83/A  
51000 Rijeka, Croatia  
Phone: +385 (51) 770 447  
Fax: +385 (51) 686 166  
[www.intechopen.com](http://www.intechopen.com)

### **InTech China**

Unit 405, Office Block, Hotel Equatorial Shanghai  
No.65, Yan An Road (West), Shanghai, 200040, China  
中国上海市延安西路65号上海国际贵都大饭店办公楼405单元  
Phone: +86-21-62489820  
Fax: +86-21-62489821

© 2012 The Author(s). Licensee IntechOpen. This is an open access article distributed under the terms of the [Creative Commons Attribution 3.0 License](#), which permits unrestricted use, distribution, and reproduction in any medium, provided the original work is properly cited.