

Suburethral Slingplasty Using a Self-Fashioned Mesh for Treating Urinary Incontinence and Anterior Vaginal Wall Prolapse

Chi-Feng Su, Soo-Cheen Ng, Horng-Jyh Tsai and Gin-Den Chen
*Kuang Tien General Hospital, Chung Shan Medical University/Hospital,
Department of Obstetrics and Gynecology
Taiwan*

1. Introduction

The pelvic floor is a highly complex structure and plays a dual role in supporting the pelvic viscera (bladder, bowel, and uterus) and maintaining the functional integrity of these organs. Pelvic organ support is maintained by complex interactions between the levator ani muscles of the pelvic floor and connective tissues along with the urethra, vaginal wall, rectum, and normal innervation (Boreham et al., 2002; Wei and DeLancey, 2004). The pelvic floor and pelvic cavity is an integral structure and can be functionally divided into three compartments. Each compartment is not discrete and is comprised of different pelvic organs. The anterior compartment contains the urethra and bladder, the middle compartment holds the vagina and uterus, and the posterior compartment consists of the anus and rectum.

Conventionally, the pathophysiology of stress urinary incontinence at the bladder neck is caused by proximal urethral hypermobility and/or intrinsic sphincter deficiency (Schick et al., 2004). The urethra and bladder lie on the supportive or suspension layers which are composed of the pubourethral ligament, endopelvic fascia, pubococcygeal muscle, and the anterior vaginal wall. The breakdown of these layers can attenuate the urethra and/or cause asymptomatic or symptomatic anterior vaginal wall prolapse.

2. Pelvic organ prolapse and stress urinary incontinence share similar risk factors

It has been noted that better pelvic-floor muscle function is associated with less severe prolapse and urinary symptoms. Poor pelvic floor muscle function is one of the inciting or contributory factors in the development of prolapse (Borello-France et al., 2007). Consistent tension from increased intra-abdominal pressure, loss of muscular support for pelvic organs, wideness of genital hiatus, and stretched or torn connective tissue might lead to prolapse (Wei and DeLancey, 2004). Furthermore, intermittent mechanical forces imposed on the prolapsed vaginal tissues or denervation of the vaginal tissues during vaginal delivery might cause decreased content of differentiated smooth muscle in the vaginal wall

of women with pelvic organ prolapse. The pathogenesis of pelvic organ prolapse is not completely understood. The development of pelvic organ prolapse may be multi-factorial. Vaginal childbirth, advancing age, and increasing body mass index are the most consistent risk factors of pelvic organ prolapse (Jelovsek et al., 2007). Other factors such as prolonged second stage of labor, constipation, chronic cough previous to pelvic surgery, and increased intra-abdominal pressure caused by heavy lifting have also been reported in association with the occurrence of stress urinary incontinence and pelvic organ prolapse (Dietz, 2008). The weakness in the supportive layer of the urethra and a lax anterior vaginal wall which results in stress urinary incontinence and/or pelvic organ prolapse seems to be caused by a "multiple-hit" mechanism.

3. Prevalence of pelvic organ prolapse associated stress urinary incontinence

The exact prevalence of pelvic organ prolapse is difficult to estimate due to patient misunderstandings and misconceptions in presenting these issues to their health care providers. Most of the estimated prevalence rates for pelvic organ prolapse are derived from the incidence of surgery for this disease or from clinic-based samples (Lawrence et al., 2008). Pelvic organ prolapse has been estimated to affect about 50% of parous women aged 50 years or over whereas stress urinary incontinence occurs in 30%. These prevalence rates increase with age (Subak et al., 2001; Abou-Elela et al., 2009; Maher et al., 2010). Pelvic organ prolapse and stress urinary incontinence coexist in 15 to 80 percent of women (Bai et al., 2002). Experts estimate that up to 50% of women with pelvic organ prolapse with the uterus in situ do not have stress urinary incontinence (Gallentine and Cespedes, 2001).

This continence mechanism in advanced pelvic organ prolapse might be caused by urethral kinking or external urethral compression, which causes obstruction that can stop the demonstration of stress urinary incontinence (Romanzi et al. 2000; Elneil, 2009). However, during surgery to reduce the prolapsed uterus or anterior vaginal wall it may be noted from the urodynamic study that 36 to 80% of the women with pelvic organ prolapse have coexisting urodynamic stress incontinence. These patients have occult stress urinary incontinence (Haessler et al., 2005; Reena et al., 2007). In addition, postoperative stress urinary incontinence (de novo stress urinary incontinence) has been noted in 10 to 30% of women following prolapse repair (Bump et al., 1996; Hung et al., 2004; Reena et al., 2007). Other reports estimate that 11 to 65% of continent patients with pelvic organ prolapse develop de novo stress urinary incontinence following pelvic reconstructive procedures performed during prophylactic anti-incontinence surgery (Borstad E and Rud T, 1989; Ellerkmann et al., 2001; Gutman et al., 2008).

4. The evolution and trends in anti-incontinence treatments

More than 100 types of anti-incontinence procedures have been invented for treating urinary incontinence in the past century. The choice of surgical method and route for treating urinary incontinence is done according to the type of incontinence, the patient's condition, the surgeon's preferences, and available materials (Wu et al., 2008). Based on the evidence of treatment outcomes, trends in anti-incontinence procedures range from the vaginal route (Kelly plication, anterior repair...), cystoscopy and needle procedures (Stamey, Pereyra,

Raz...), bladder neck suspension and/or colposuspension to the conventional pubovaginal sling. Retropubic Burch colposuspension was considered the gold standard and the most popular anti-incontinence operation by 1995 (Jarvis, 1994). In recent decades, newer tension-free, patch and prosthetic tapes with minimal invasive procedures have been used such as the tension-free vaginal tape (TVT) procedure which is based on the integral theory and was introduced by Petros and Ulmsten (1993). The treatment outcomes seem promising (Wu et al., 2008). The use of macroporous monofilament mesh has become a popular treatment in anti-incontinence surgery. However, long-term complications of these synthetic materials still need to be solved.

The goals of these procedures for achieving continence have shifted from suburethral fascia plication (Kelly procedure), lifting the urethra up to a higher retropubic position (MMK), elevating the bladder neck to enhance pressure transmission ratio (colposuspension), to stabilizing the bladder neck or proximal urethra to increase urethral closure pressure (sling operation). Now, the popular minimal invasive procedures, based on the integral theory (Petros and Ulmsten 1993), are trying to create a dynamic kinking of the mid-urethra at the level of the high pressure zone in the urethral pressure profile or in the urethral knee angle (terminology used in sonographic findings) (Wu et al., 2008; Lo et al., 2004).

5. The evolution of pelvic reconstruction surgeries

The surgical treatment for pelvic organ prolapse can be categorized into obliterative and reconstructive procedures. Reconstructive surgery for treating prolapse aims to correct the prolapsed vagina, preserve (or improve) vaginal sexual function and relieve the associated pelvic symptoms. Reconstructive surgery can be performed by either the transabdominal or vaginal route. Currently, several common approaches for correcting apex or uterovaginal prolapse include abdominal sacral colpopexy, abdominal sacral cervicopexy, McCall culdoplasty, high uterosacral ligament suspension, and vaginal sacrospinous ligament suspension. Anterior and posterior colporrhaphy in combination with central plication of the fibromuscular layer of the vaginal wall are still popular techniques for correcting anterior and posterior vaginal wall prolapse (Jelovsek et al., 2007; Gomelsky et al., 2011). Paravaginal defect repair, a side-specific repair of the vaginal wall to make a reproximation of vaginal tissue that has been torn from its lateral attachment to the arcus tendineus fascia pelvis or arcus tendineus levator ani, has also been advocated by some physicians for treating anterior vaginal wall prolapse (Mallipeddi PK et al., 2001; Young et al. 2001).

In the past two decades, the efficacy of anterior colporrhaphy, associated with central plication of the pubourethral ligament or fibromuscular layers of the vaginal wall for treating urinary incontinence or anterior vaginal wall prolapse, has been controversial. Beck et al. reported the cure rate for treating 194 patients increased from 75 to 94% when a Kelly-Kennedy technique was modified to include a vaginal retropubic urethropexy (Beck et al., 1991). Jarvis's review revealed a cure rate of around 60% using anterior colporrhaphy for stress urinary incontinence (Jarvis., 1994). It has been reported that only 30 to 46% of patients experience satisfactory or optimal anatomic results with standard anterior or ultralateral anterior colporrhaphy for the treatment of anterior vaginal wall prolapse (Weber et al., 2001). However, for this group the clinically relevant definitions of success were defined as (1) no prolapse beyond the hymen, (2) the absence of prolapse symptoms (visual

analog scale ≤ 2), and (3) the absence of re-treatment. There was a higher success rate for treating anterior vaginal wall prolapse with anterior colporrhaphy (Chmielewski et al., 2011). In the past, the discrepancy in success rates of anterior colporrhaphy for the treatment of anterior vaginal wall prolapse can be attributed to varying definitions of success. As we know, a higher success rate is associated with a higher complication rate for the treatment of pelvic organ prolapse. Physicians should base the definition of success on patient perceptions and satisfaction according to clinically relevant definitions of success rather than on physicians' perceptions of success.

The use of mesh has also become common practice in pelvic reconstructive procedures in recent decades. An increasing number of commercial kits have been designed for site-specific defect repair or total mesh-augmented vaginal repairs to reinforce the supportive function of the vagina. Recent literature demonstrates that graft-augmented repairs seem to have a high success rate and conventional standard repairs (no mesh augmentation) have relatively high recurrence rates. However, potentially high success rates resulting from use of mesh products are accompanied by a high complication rate. Complications or side-effects associated with vaginal mesh include mesh erosion or extrusion, infection, pain, and dyspareunia (Baessler et al. 2006; Maher and Baessler 2006; Natale et al., 2006; Wu MP, 2008; Jelovsek et al. 2007; Gomelsky et al., 2011). Therefore, researchers from the Third International Consultation on Incontinence concluded that because of mesh's high potential morbidity, mesh placed transvaginally should only be used in well-designed clinical trials and not in general practice until more data is available (Brubaker et al. 2005).

6. Staged or concomitant procedures for treating pelvic organ prolapse and stress urinary incontinence

Currently, choosing either a concomitant or stepwise approach to treat concurrent pelvic organ prolapse and stress urinary incontinence is still debatable. A proper balance between the risk of incomplete treatment and exposing a patient to an unnecessary operation requires consideration when explaining the treatment outcomes to the patient. Some surgeons recommend concomitant procedures to treat co-existing stress urinary incontinence and pelvic organ prolapse in order to avoid the possibility of secondary surgery. However, they may encounter some inherent risks and unexpected adverse effects such as postoperative voiding difficulty, bladder outlet obstruction, and/or de novo detrusor overactivity. Others prefer staged procedures to correct pelvic organ prolapse first, followed by re-evaluation for the presence of stress urinary incontinence after the wound has healed and stabilized (Gordon et al., 2001; Huang et al., 2005; Winters JC, 2008; Wu et al., 2010). As mentioned before, anterior colporrhaphy might also cure stress urinary incontinence and its success rate is as high as 60% (Jarvis 1994). Intuitively, staged procedures most likely prevent two-thirds of unnecessary procedures for incontinence when contrasted with concomitant operations.

7. Rationale for suburethral slingplasty

The Cochrane Database of Systematic Reviews revealed that the use of mesh or graft inlays at the time of anterior vaginal wall repair may reduce the risk of recurrent anterior vaginal

wall prolapse (Maher et al. 2010). The high failure rates of pelvic reconstructive procedures for anterior compartment prolapse might be a result of a decrease in the muscularis of the prolapsed vaginal tissues which impair vaginal tone and contractility (Boreham et al., 2002). Alterations in collagen, elastin, and proteoglycan proteins of the extracellular matrix within the pelvic-support ligaments and vaginal tissue might also contribute to or be associated with causes of pelvic organ prolapse or recurrence (Connell KA., 2011).

In order to reduce the high failure rate of anterior vaginal wall repair, we developed a tension free vaginal tape, using self-fashioned Gynemesh, for treating urodynamic stress incontinence and anterior vaginal wall prolapse, concomitantly. The rationale behind our suburethral slingplasty is using tension-free mesh for augmenting and enforcing the supporting layer of the urethra and bladder to treat stress urinary incontinence and anterior vaginal wall prolapse concomitantly. This procedure has provided a relatively high success rate in curing urinary incontinence (continence was 80%, improvement was 17%) and reduced the rate of recurrence of anterior vaginal wall prolapse (none with recurrent prolapse greater than stage II). As well, there was a more acceptable rate of mesh erosion (6%) when combined with other pelvic reconstructive procedures.

8. Surgical technique

The basis of the current procedure is to place a tension-free and customized mesh underneath the proximal urethra and bladder to act as a supporting suburethral hammock to reinforce the anterior vaginal wall while undergoing pelvic reconstructive operations. The self-fashioned mesh may augment the supporting and suspension effects against an increase in mechanical forces of daily activities and gravity. Concurrently, the mesh patch may also act as a frame for inducing fibroblasts in fibrogenesis during healing (Hung et al. 2010).

8.1 Preparation of self-fashioned mesh

The self-fashioned mesh is a polypropylene mesh from Gynemesh PS (10 cm in width and 15 cm in length; 300 USD a piece; Gynecare, Ethicon inc., Somerville, NJ, USA)(Su et al. 2009). The mesh is trimmed in the shape of a body with a pair of arms (shown in Figure 1)




Fig. 1. The mesh is trimmed in the shape of a body with a pair of arms (B) from a Gynemesh PS (A)

and the size of the mesh is tailored to fit the patient. The length of the mesh can be adjusted according to the length of the patient's anterior vaginal wall since the end of the mesh is anchored to the vaginal apex or pubocervical fascia. The bilateral ends of the mesh are sewn using an absorbable 1-0 Vicryl suture (Ethicon inc., Somerville, NJ, USA) using a Stamey needle for the following procedures (Figure 2).

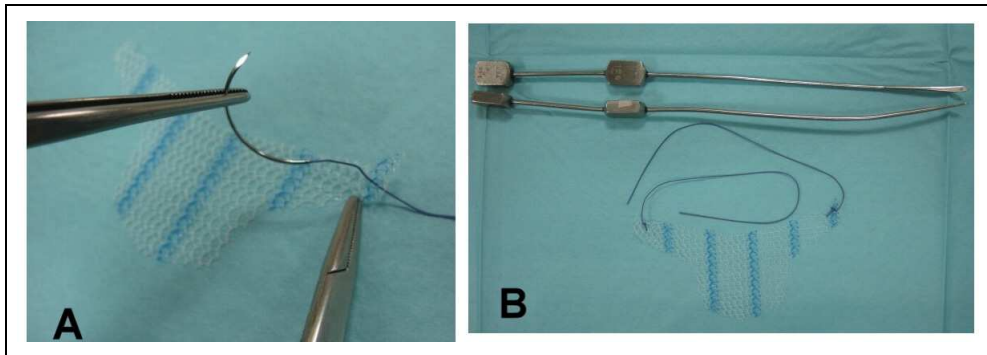


Fig. 2. The bilateral ends of the mesh are sewn using an absorbable 1-0 Vicryl suture (A). Prepared self-fashioned mesh and Stamey needles (B)

8.2 Procedures for placement of the self-fashioned mesh

The bladder neck is identified by gently pulling the Foley catheter. The anterior vaginal wall is incised in the midline from the proximal urethra to the apex of the vaginal cuff or cervix (for patients whose uterus is preserved). At the level of the proximal urethra, a tunnel underneath the pubourethral ligament is created on each side of the urethra to reach the insertion of the ligament. The vaginal mucosa layer is undermined from the fibromuscular layer of the anterior vaginal wall on each side to reach the lateral point of insertion into the paravaginal fascia. The retropubic space (Retzius space) is not entered during the dissection of the paravaginal fascia.

A Stamey needle is introduced through the suprapubic incision (less than 5 mm each side), passed blindly through the retropubic space along the posterior surface of the pubic bone (retropubis; avoiding resistance from bones and the bladder wall) (Figure 3), until the needle tip is advanced to the ventral aspect of the pubourethral ligament. The needle tip is advanced laterally along the posterior aspect of the pubis into the tip of the tunnel that was created before and passed through this fibromuscular layer (Figure 4). The 1-0 Vicryl suture is threaded through the needle hole at a certain length. The Stamey needle is withdrawn back from the suprapubic incision until the 1-0 Vicryl suture is present (Figure 5). The 1-0 Vicryl suture is pulled out through the suprapubic incision until the end of the mesh arm passes into the retropubic space (surgeon feels loss of strongest resistance while the 1-0 Vicryl suture is being pulled). The end of the mesh arm is anchored into the ventral aspect of the paravaginal fascia (paraurethral portion, near the original portion of the arcus tendineous fascia pelvis and arcus tendineous levator ani). These procedures are repeated on the other side.

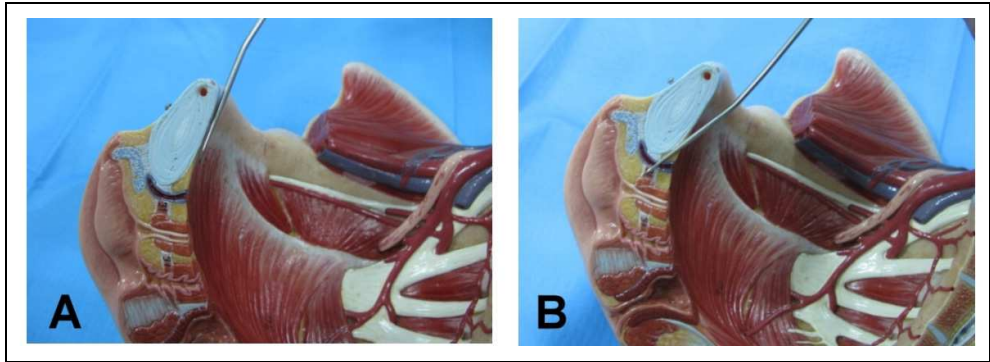


Fig. 3. Stamey needle is introduced through the suprapubic space.

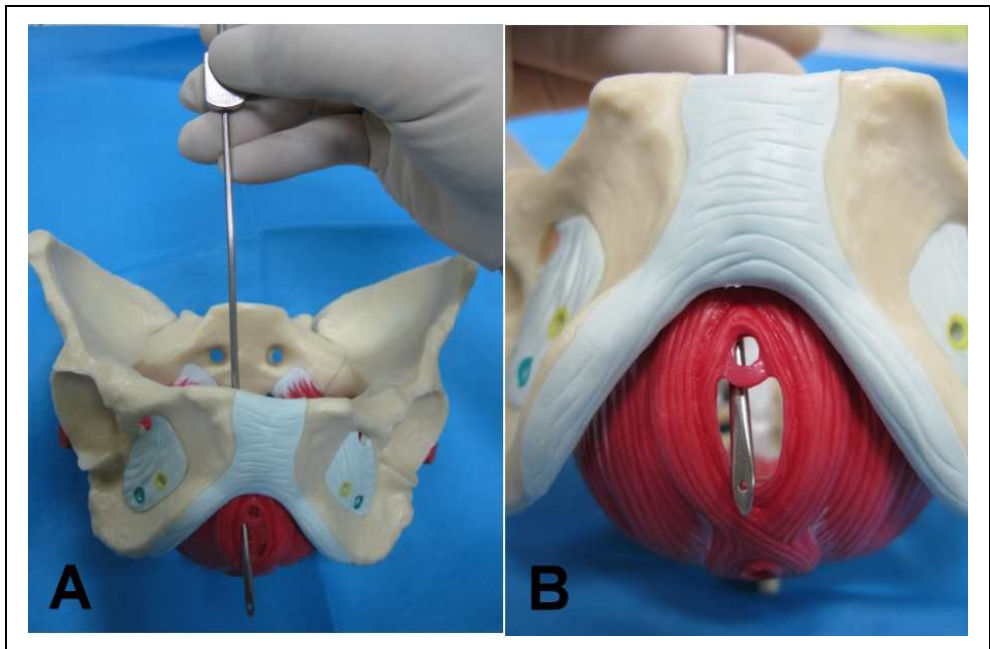


Fig. 4. The Stamey needle tip is advanced laterally into the retropubic tunnel that was created before and passed through this fibromuscular layer.

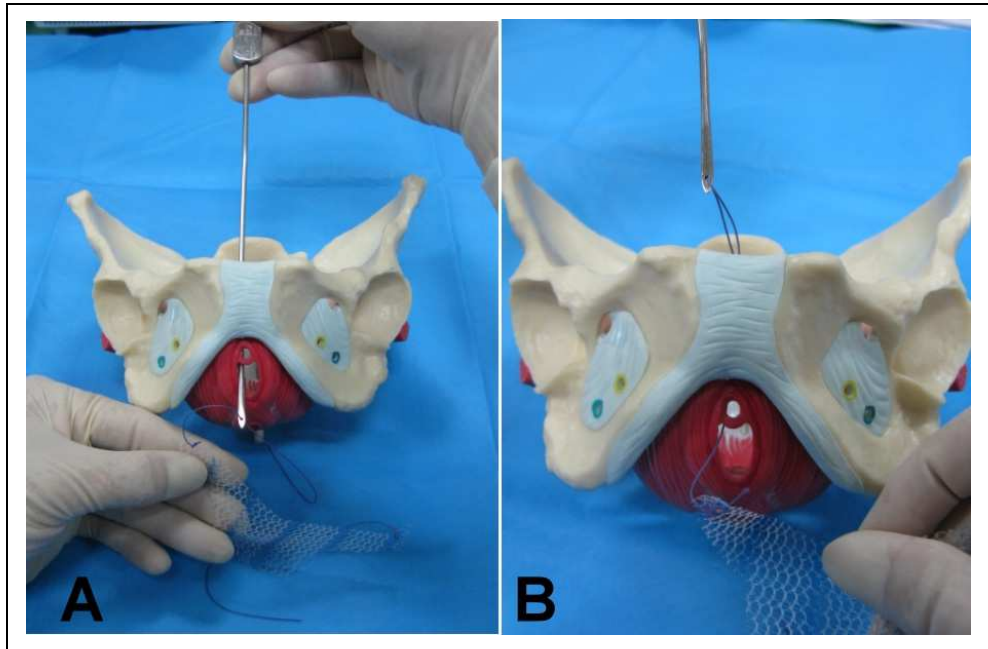


Fig. 5. The Stamey needle is withdrawn back from the suprapubic incision until the 1-0 Vicryl suture is present.

The mesh arms are adjusted by pulling the 1-0 Vicryl suture through the suprapubic incision until the mesh is placed underneath the dorsal aspect of the pubourethral ligament, proximal urethra, and bladder neck without tension and mesh unfolds. Surgeons have the option, according to their preference, of performing plication of the fibromuscular layer of the bladder before placing the mesh underneath the bladder and dorsal aspect of the paravaginal fascia. The mesh is also flattened without tension so that the bilateral edges of the mesh reach the lateral sulci of the vagina (Figure 6). The Smead-Jones suturing method is used to close the suburethral mucosa and anterior vaginal mucosa to create a mass cushion on the suburethral mucosa and anterior vaginal wall. Concomitant pelvic reconstructive procedures are performed after closing the anterior vaginal wall.

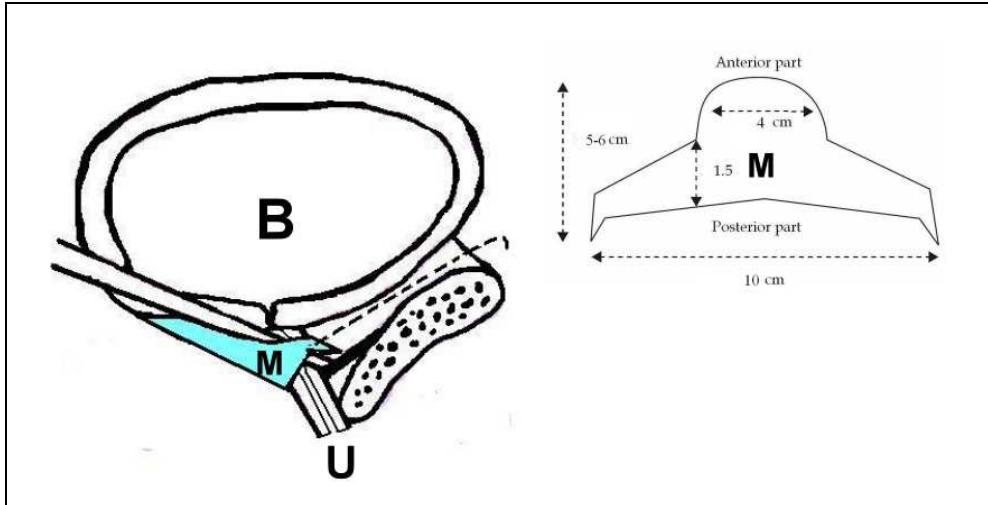


Fig. 6. The mesh is tension-free flattened under the suburethral area. B: Bladder; U: Urethra; M: self-fashioned mesh.

9. Outcomes and complications of using self-fashioned mesh

Our results for using self-fashioned mesh for the treatment of concurrent stress urinary incontinence and pelvic organ prolapse showed a relatively high success rate in curing urinary incontinence (continence was 80%, improvement was 17%) and less recurrence of anterior vaginal wall prolapse (none with recurrent prolapse greater than stage II) in a three-year follow-up. However, mesh erosion was not completely averted. Exposed vaginal mesh was removed uneventfully. None of these patients experienced recurrent urinary incontinence and prolapse.

9.1 Comparison of relevant published articles

There are three similar articles using self-fashioned mesh for treating stress urinary incontinence and anterior vaginal wall prolapse have been found in recent five years (Mustafa and Wadie, 2006; Amrute et al., 2007; Eboue et al., 2010). Character of mesh, patient number, mean follow-up period, success rates, and complications of these articles and ours are as tabled below (Table 1). Outcomes of using self-fashioned meshes are promising. Mesh erosion rates in these case series are acceptable compared to that of commercial mesh kits (Jelovsek et al. 2007; Gomelsky et al., 2011).

The rationale for using self-fashioned mesh is: (1) to support the proximal urethra, bladder neck and anterior vaginal wall so they are simultaneously free of tension; (2) to provide a frame for augmenting the vaginal wall; (3) to fashion the size of the mesh to fit the defect in the vaginal wall; (4) to avoid complications induced by mesh arms by not using additional full-length mesh arms. A mesh patch lessens the amount of synthetic materials present in the wound bed which might diminish potential complications. Technically, it would be easier to remove the mesh patch than the full-length mesh if late complications occur (Tsui et al. 2005).

First author	Methods	Cases (n)	Mean follow up(m)	objective success (%)	Outcomes
Eboue	Trapezoidal shape with four arms, microporous multifilament polypropylene, transoburator, cystocele with/without SUI, history with/ without prior hysterectomy, no additional surgery	123	34	87.7% of SUI, 97.5% of cystocele	6.5% of erosion rate, bladder injury (1), urethral injury (2), paravesical hematoma (4), de novo SUI (9/66), de novo urgency (12/83); satisfactory outcome, maybe better with use of macroporous, monofilament mesh.
Amrute	H shaped macroporous monofilament polypropylene, retopubic route, SUI with POP, additional VH or SSLF, vaginal closure as in a Mercedes Benz or tripod fashion	76	30.7	89% of SUI, 95% of cystocele	2.1% of vaginal erosion, 2.1% of de novo SUI, 15.7% of de novo urgency; High success rate with single mesh use for SUI and cystocele and prevention of postoperative SUI
Mustafa	Placard shaped polypropylene mesh, retopubic route, SUI with/without cystocele	14	11	84.5 % of SUI, not reported of cystocele	Erosion not reported; a simple, economic and cost-effective procedure by using placard mesh
Su	A macroporous monofilament polypropylene, SUI with/without POP, and with/without prior pelvic surgery, additional VH, SSLF or posterior repair, vaginal closure by Smead-Jones method	65	33	97% of SUI, 100% of cystocele	6% of mesh erosion, de novo urgency (1); a satisfactory outcomes, decrease the erosion rate by Smead-Jones suturing

Table 1. Clinical information self-customized mesh studies

9.2 Comparative cost of a self-fashioned mesh

The price of commercial mesh kits varies in the international market. In Taiwan, the National Health Insurance (NHI) covers some commercial kits for patients undergoing anti-incontinence surgery. The commercial mesh kits for pelvic organ prolapse are not covered by NHI. Patients choosing commercial mesh kits for treating their pelvic organ prolapse must pay 1,200-2,000 USD out of their own pockets for the additional surgical cost. In comparison, the cost of a self-fashioned mesh is relatively affordable for patients with stress urinary incontinence and pelvic organ prolapse, and the success rate is not compromised because of the lower expense of a self-fashioned mesh kit.

Stress urinary incontinence and pelvic organ prolapse are significant problems in relatively affluent countries. However, early childbearing and high fertility with early marriage, many vaginal deliveries, and frequent heavy lifting result in a high prevalence of stress urinary incontinence and pelvic organ prolapse. The situation in developing countries is far worse and cannot be overlooked (Wunasekera et al., 2007). Therefore, financial consideration for choosing a self-fashioned mesh or commercial mesh kits seems to be an important issue for treating this disease.

10. Conclusion

This procedure provides an easier placement technique, a relatively high success rate, and less recurrence. The complications of the self-fashioned mesh (monofilament and macroporous polypropylene) are acceptable compared to other commercial mesh kits. In addition, the cost of the self-fashioned mesh is cheaper than the commercial mesh kits. The self-fashioned mesh is an alternative option for treating stress urinary incontinence and anterior vaginal wall simultaneously.


11. References

- Amrute, KV.; Eisenberg, ER. Rastinehad, AR. Kushner, L. & Badlani, GH. (2007). Analysis of Outcomes of Single Polypropylene Mesh in Total Pelvic Floor Reconstruction *Neurourol Urodyn*, Vol. 26, No.1, pp. 53-58, ISSN 0733-2467
- Baessler, K. & Maher, CF. (2006). Mesh augmentation during pelvic floor reconstructive surgery: risks and benefits. *Curr Opin Obstet Gynecol*, Vol.18, No.5, (October 2006), pp. 195-201, ISSN 0147-1988
- Bai, SW.; Jeon, MJ. Kim, JY. Chung, KA. Kim, SK. & Park, KH.. (2002). Relationship between stress urinary incontinence and pelvic organ prolapse. *Int Urogynecol J Pelvic Floor Dysfunct*, Vol.13, No.4, pp. 256-260, ISSN 0937-3462
- Beck, RP.; McCormick, S.& Nordstrom, L.(1991). A 25-year experience with 519 anterior colporrhaphy procedures. *Obstet Gynecol*, Vol. 78, No.6, (December 1991), pp. 1011-1018, ISSN 0029-7844
- Boreham, MK.; Wai, CY. Miller, RT. Schaffer, JI. & Word, RA. (2002). Morphometric analysis of smooth muscle in the anterior vaginal wall of women with pelvic organ prolapse. *Am J Obstet Gynecol*, Vol. 187, No. 1, (July 2002), pp.56-63, ISSN 0002-9378
- Borstad, E. & Rud, T. (1989). The risk of developing urinary stress incontinence after vaginal repair in continent women. A clinical and urodynamic follow-up study. *Acta Obstet Gynecol Scand Suppl*, Vol. 68, No.6, pp. 545-549, ISSN 0001-6349

- Brubaker, L.; Bump, RC. Fynes, M. Jacquetin, B. Karram, K. Maher, C. Norton, B. & Cervigini, M. (2005). Surgery for pelvic organ prolapse. In: *Incontinence, 3rd International Consultation on Incontinence*, Abrams, P. Cardozo, L. Koury, S. & Wein, A., (Ed.), 1371-1402, Health Publication., ISBN 0-9546956-2-3, Paris, France
- Chmielewski, L.; Walters, MD. Weber, AM. & Barber, MD. (2011). Reanalysis of a randomized trial of 3 techniques of anterior colporrhaphy using clinically relevant definitions of success. *Am J Obstet Gynecol*, [Epub ahead of print], ISSN 0002-9378
- Connell, KA. (2011) Elastogenesis in the vaginal wall and pelvic-organ prolapse. *N Engl J Med*, Vol 364, No.24, (June 2011), pp. 2356-2358, ISSN 0028-4793
- Eboue, C.; Marcus-Braun, N. & von Theobald P. (2010). Cystocele repair by transobturator four arms mesh: monocentric experience of first 123 patients. *Int Urogynecol J Pelvic Floor Dysfunct*, Vol.21, No.1, (January 2010), pp. 85-93, ISSN 0937-3462
- Ellerkmann, RM.; Cundiff, GW. Melick, CF. Nihira, MA. Leffler, K. & Bent, AE. (2001). Correlation of symptoms with location and severity of pelvic organ prolapse. *Am J Obstet Gynecol*, Vol. 185, No. 6, (December 2001), pp. 1332-1338, ISSN 0002-9378
- Gomelsky, A.; Penson, DF. & Dmochowski, RR. (2011). Pelvic organ prolapse (POP) surgery: the evidence for the repairs. *BJU Int*; Vol. 107, No. 11, (June 2011), pp. 1704-1719, ISSN 1464-4096
- Gordon, D.; Gold, RS. Pauzner, D. Lessing, JB. & Groutz, A. (2001). Combined genitourinary prolapse repair and prophylactic tension-free vaginal tape in women with severe prolapse and occult stress urinary incontinence: preliminary results. *Urology*, Vol. 58, No. 4, (October 2001), pp. 547-550, ISSN 0090-4295
- Gutman, RE.; Ford, DE. Quiroz, LH. Shippey, SH. & Handa, VL. (2008) Is there a pelvic organ prolapse threshold that predicts pelvic floor symptoms? *Am J Obstet Gynecol*, Vol. 199, No. 6, (December 2008), pp. 683. e1-7, ISSN 0002-9378
- Haessler, AL.; Lin, LL. Ho, MH. Beston, LH. & Bhatia, NN. (2005). Reevaluating occult incontinence. *Curr Opin Obstet Gynecol*, Vol.17, No.5, (October 2005), pp. 535-540, ISSN 0147-1988
- Huang, KH.; Kung, FT. Liang, HM. Chen, CW. Chang, SY. & Hwang, LL. (2006). Concomitant pelvic organ prolapse surgery with TVT procedure. *Int Urogynecol J Pelvic Floor Dysfunct*, Vol. 17, No.1, (June 2006), pp. 60-65, ISSN 0937-3462
- Hung, MJ.; Liu, FS. Shen, PS. Chen, GD. Lin, LY. & Ho, ESC. (2004) Factors that affect recurrence after anterior colporrhaphy procedure reinforced with four-corner anchored polypropylene mesh. *Int Urogynecol J Pelvic Floor Dysfunct*, Vol. 15, No.6, (2004), pp. 399-406, ISSN 0937-3462
- Jarvis, GJ.;(1994). Surgery for genuine stress incontinence. *Br J Obstet Gynecol*, Vol. 101, No. 5, (May 1994), pp. 371-374, ISSN 1471-0528
- Jelovsek, JE.; Maher, C. & Barber, MD. (2007). Pelvic organ prolapse. *Lancet*; Vol. 369, No. 9566, (May 2007), pp.1027-1038, ISSN 0140-6736
- Lo, TS.; Horng, SG. Liang, CC. Lee, SJ. & Soong, YK. (2004).Ultrasound assessment of mid-urethral tape at three-year follow-up after tension-free vaginal tape procedure. *Urology*, Vol. 63, No. 4 (April 2004), pp. 671-675, ISSN 0090-4295
- Maher, C. & Baessler, K. (2006) Surgical management of anterior vaginal wall prolapse: An evidence based literature review. *Int Urogynecol J Pelvic Floor Dysfunct*, Vol.17, No.2, (February 2006), pp. 195-201, ISSN 0937-3462

- Maher, C.; Baessler, K. Glazener, CMA. Adams, EJ. & Hagen, S. (2008) Surgical management of pelvic organ prolapse in women: A short version Cochrane Review. *Neurourol Urodyn*, Vol. 27, No.1, pp. 3-12, ISSN 0733-2467
- Maher, C.; Feiner, B. Basessler, K. Adams, EJ. Hagen, S. & Glazener, CM. (2010). Surgical management of pelvic organ prolapse in women. *Cochrane Database syst Rev*, Vol.14, No.4, (April 2010), CD004014, ISSN 1469-493X
- Mallipeddi, PK.; Steele, AC. Kohli, N. & Karram, MM.(2001).Anatomic and functional outcome of vaginal paravaginal repair in the correction of anterior vaginal wall prolapse. *Int Urogynecol J Pelvic Floor Dysfunct*, Vol.12, No.2, pp. 83-88, ISSN 0937-3462
- Mustafa, M. & Wadie, BS. (2006). Placard-shaped in situ vaginal wall sling for the treatment of stress urinary incontinence. *Int J Urol*, Vol. 13, No. 2, (February 2006), pp.132-134, ISSN 0919-8172
- Natale,F.; Weir, JM. & Cervigni, M.(2006). Pelvic floor reconstructive surgery: which aspects remain controversial? *Curr Opin Urol*, Vol. 16, No.6, (November 2006), pp.407-12, ISSN 0963-0643
- Petros, PE. & Ulmsten, UI. (1993). An integral theory and its method for the diagnosis and management of female urinary incontinence. *Scand J Urol Nephrol*, Vol. 153, pp.1-93, ISSN 0036-5599
- Reena, C.; Kekre, AN. & Kekre, N. (2007) Occult stress incontinence in women with pelvic organ prolapse. *Int J Gynaecol Obstet*, Vol. 97, No.1 (April 2007), pp.31-34, ISSN 0020-7292
- Romanzi, LJ.; Chaikin, DC. & Blaivas, JG. (1999). The effect of genital prolapse on voiding. *J Urol*, Vol. 161, No. 2, (February 1999), pp. 581-586, ISSN 0022-5347
- Schick, E.; Jolivet-Tremblay, M. Tessier, J. Dupont, C. & Bertrand, PE. (2004). Observations on the function of the female urethra III: An overview with special reference to the relation between urethral hypermobility and urethral incompetence. *Neurourol Urodyn*, Vol. 23, No.1, pp. 22-26, ISSN 0733-2467
- Su, CF.; Ng, SC. Tsui, KP. Chen, GD. & Tsai, HJ. (2009). Suburethral slingplasty using a self-fashioned Gynemesh for treating urinary incontinence and anterior vaginal wall prolapse. *Taiwan J Obstet Gynecol*, Vol. 48, No. 1, (March 2009), pp.53-39, ISSN 1028-4559
- Tsui, KP.; Ng, SC. Tee, YT. Yeh, GP. Chen, GD. (2005). Complications of synthetic graft materials used in suburethral sling procedures. *Int Urogynecol J Pelvic Floor Dysfunct*, Vol. 16, No. 2, (Mar-Apr 2005), pp. 165-167, ISSN 0937-3462
- Weber, AM. Walters, MD. Piedmonte, MR. & Ballard, LA. (2001). Anterior colporrhaphy: a randomized trial of three surgical techniques. *Am J Obstet Gynecol*, Vol. 185, No. 6, (December 2001), pp. 1299-1306, ISSN 0002-9378
- Wei, J.& DeLancey, JOL. (2004). Functional anatomy of the pelvic floor and lower urinary tract. *Clin Obstet Gynecol*; Vol. 47, No. 1, (March 2004), pp. 3-17, ISSN 0009-9201
- Winters, JC.(2008). A critical appraisal of preventive slings and prolapse surgery – what’s a urologist to do? *J Urol*, Vol. 180, No. 3, (September 2008), pp. 809-810, ISSN 0022-5347
- Wu, MP. (2008). The use of prostheses in pelvic reconstructive surgery: Joy or Toy? *Taiwan J Obstet Gynecol*, Vol. 47, No. 2, (June 2008), pp.151-156, ISSN 1028-4559

- Wu, MP.& Huang, KH. (2008). Tension-free midurethral sling surgeries for stress urinary incontinence. *Incont Pelvic Floor Dysfunct*, 53-60. Vol. 2, No.2, pp.53-60, ISSN 1994-568X
- Wu, MP. Long, CY & Liang, CC.(2010). Staged or concomitant surgery for correcting pelvic organ prolapse and stress urinary incontinence. *Incont Pelvic Floor Dysfunct*, Vol. 4, No.4, pp.93-98, ISSN 1994-568X
- Wunasekera, P.; Sazaki, J. & Walker, G. (2007). Pelvic organ prolapse: don't forget developing countries. *Lancet*; Vol. 369, No. 9575, (May 2007), pp.1789-1790, ISSN 0140-6736
- Young, SB.; Daman, JJ. & Bony, LG. (2001). Vaginal paravaginal repair: one-year outcomes. *Am J Obstet Gynecol*, Vol. 185, No. 6, (December 2001), pp. 1360-1366, ISSN 0002-9378



Urinary Incontinence

Edited by Mr. Ammar Alhasso

ISBN 978-953-51-0484-1

Hard cover, 324 pages

Publisher InTech

Published online 04, April, 2012

Published in print edition April, 2012

Management strategies are framed within a multidisciplinary team structure and as such a range of specialists ranging from psychologists, specialist nurses, gynaecologists and urologists author the chapters. There are some novel methods outlined by the authors with their clinical application and utility described in detail, along with exhaustive research on epidemiology, which is particularly relevant in planning for the future.

How to reference

In order to correctly reference this scholarly work, feel free to copy and paste the following:

Chi-Feng Su, Soo-Cheen Ng, Horng-Jyh Tsai and Gin-Den Chen (2012). Suburethral Slingplasty Using a Self-Fashioned Mesh for Treating Urinary Incontinence and Anterior Vaginal Wall Prolapse, *Urinary Incontinence*, Mr. Ammar Alhasso (Ed.), ISBN: 978-953-51-0484-1, InTech, Available from:

<http://www.intechopen.com/books/urinary-incontinence/suburethral-slingplasty-using-a-self-fashioned-mesh-for-treating-urinary-incontinence-and-anterior-v>

INTECH

open science | open minds

InTech Europe

University Campus STeP Ri
Slavka Krautzeka 83/A
51000 Rijeka, Croatia
Phone: +385 (51) 770 447
Fax: +385 (51) 686 166
www.intechopen.com

InTech China

Unit 405, Office Block, Hotel Equatorial Shanghai
No.65, Yan An Road (West), Shanghai, 200040, China
中国上海市延安西路65号上海国际贵都大饭店办公楼405单元
Phone: +86-21-62489820
Fax: +86-21-62489821

© 2012 The Author(s). Licensee IntechOpen. This is an open access article distributed under the terms of the [Creative Commons Attribution 3.0 License](#), which permits unrestricted use, distribution, and reproduction in any medium, provided the original work is properly cited.