

Cryptococcal Meningitis

Claudia Fabrizio, Sergio Carbonara and Gioacchino Angarano
*Clinic of Infectious Diseases, University of Bari,
Italy*

1. Introduction

Cryptococcus neoformans is an encapsulated yeast first described in 1894, whose infection can induce a wide spectrum of clinical manifestations that range from a harmless colonization of the airways and asymptomatic infection to meningitis or disseminated disease.

Virulence probably plays a relatively small role in the outcome of this infection: the crucial factor is the immune status of the host. The most serious infections usually develop, in fact, in patients with defective cell-mediated immunity, for example those with AIDS, organ transplantation, reticuloendothelial malignancy, corticosteroid treatment and sarcoidosis, but not in subjects with neutropenia or immunoglobulin deficiency. Cryptococcosis has shown an increasing incidence over the last decades, mainly because of the AIDS pandemic, and still represents a major life-threatening fungal infection in these patients.

2. Mycology

Of the more than 50 species that comprise the genus *Cryptococcus*, human disease is primarily associated with *C. neoformans* and *C. gattii*. These two species, once considered as two varieties of *C. neoformans*, include five serotypes based on antigenic specificity of the capsular polysaccharide; serotypes A, D, and AD (*C. neoformans*), and serotypes B and C (*C. gattii*). Genome analyses demonstrate that serotypes A and D are actually distinct strains, respectively called *C. neoformans* var. *grubii* and *C. neoformans* var. *neoformans*.

C. neoformans forms round, yeast like cells, 3-6 μm in diameter, which are surrounded by a polysaccharide capsule when the yeast is present in the host and in certain culture media; colonies are smooth, convex and they grow in solid media at 20-37°C.

The characteristics that allow identification of *C. neoformans* include microscopical appearance, biochemical features (such as the use of creatinine as a nitrogen source, the production of melanine, etc.) and the ability to grow at 37°C; in fact, most of nonpathogenic *Cryptococcus* strains are not able to grow at this temperature.

3. Epidemiology

C. neoformans occurs mainly in immune-impaired subjects, can be recovered in high concentrations in pigeon faeces and bird nests, and is distributed worldwide, with different epidemiological features according to the different strains. Most cases of cryptococcosis

involve serotype A (*C. neoformans* var. *grubii*), which is reported especially in patients living in low-income countries, whereas, in Western areas, it represents a clinical problem mainly in late presentation HIV-infected patients and is a marker of poor access to health care. On the other hand, serotype D (*C. neoformans* var. *neoformans*) is predominantly found in Western Europe and its infection is uncommon in the rest of the world.

C. gattii (serotypes B and C) causes 70-80% of Cryptococcal infections among immunocompetent hosts and can be isolated from certain species of eucalyptus trees and from the air beneath them. Infection by these strains is mainly common in tropical and subtropical areas, where the clinical disease occurs sporadically. However, a recent outbreak (1999-2003), involving patients with apparently normal immune system, was reported in some areas of Canada and Northwest US.

The incidence of Cryptococcal infection does not significantly differ in relation to age, race or occupation.

Since the mid 1980s, most Cryptococcal disease has occurred in patients with AIDS. The overall incidence (5-10% of patients with AIDS in Europe and US) decreased after the availability of highly active antiretroviral therapy (HAART). However, cryptococcosis still causes death in 15-44% of all patients with AIDS in sub-Saharan Africa and remains one of the most common AIDS-defining illnesses in some other areas, such as India, Brazil and Thailand.

4. Pathophysiology

Cryptococcal infection develops both in animals and humans, but neither animal-to-animal, animal-to-human transmission nor person-to-person direct respiratory transmission has been documented. The organism is primarily transmitted via the respiratory route. Humans can get Cryptococcal infection by inhalation of airborne fungi which are spread from the sources mentioned above. Following inhalation, the yeast spores are deposited into the pulmonary alveoli, where they are phagocytized by alveolar macrophages. Encapsulated yeasts, however, are often resistant to phagocytosis, because of the antiphagocytic and immunosuppressive properties of the polysaccharidic capsule, which is able to inhibit the recognition of the yeast by phagocytes and the leukocyte migration into the area of fungal replication.

The host response to Cryptococcal infection involves both cellular and humoral components, including natural killer cells, T-lymphocytes, macrophages and anti-Cryptococcal antibodies, which enhance the cell-mediated immune response to the organism.

C. neoformans infection is usually characterized by little or absent necrosis or organ dysfunction until late in the disease; the typical lesion consists of a cystic cluster of yeasts with no well-defined inflammatory response and well-formed granulomas are generally absent.

The initial pulmonary Cryptococcal infection is usually asymptomatic; in immunocompetent hosts the infection can be cleared, contained as latent infection or cause a disease limited to the lungs, inducing development of a pneumonia with poorly defined interstitial nodules. In contrast, in immunosuppressed patients, especially those with defects in the function of T cells, the infection can progress to a meningitis and/or a disseminated disease, which usually is the result of a reactivation of a chronic latent pulmonary infection; in fact, from the lungs of these

patients, cryptococci disseminate widely and may infect any organ, most frequently the central nervous system (CNS), but also bones, prostate, eyes and skin.

5. Clinical

The CNS is the main site of Cryptococcal disease in both immunocompetent and immunocompromised hosts. The infection usually involves both the meninges and the brain, causing a diffuse, usually subacute or chronic disease.

Immunocompetent hosts may present with either meningitis or, more frequently than immunocompromised hosts, with cryptococcomas, which often manifest with focal neurologic defects.

The clinical presentation and the course of Cryptococcal meningitis vary according to the underlying medical conditions and immune status of the host: the most common symptoms are headache, altered mental status (personality changes, memory loss, reduced level of consciousness, confusion, lethargy, up to coma), nausea and vomiting (often associated with increased intracranial pressure) and cranial nerves paralysis. Other findings, less frequently observed, may include ataxia, aphasia, hearing defects and choreoathetoid movements.

Ocular symptoms such as blurred vision, photophobia or diplopia may result from arachnoiditis, papilledema, optic nerve neuritis or chorioretinitis.

Physical findings, such as fever and stiff neck, are less common because of the limited inflammatory response induced by the encapsulated yeasts. . Some HIV positive patients may have minimal or nonspecific symptoms at presentation and may often be afebrile; this lack or aspecificity of symptoms contribute to delayed diagnosis.

Dementia is a potential sequela and may indicate the presence of hydrocephalus as a late complication.

In the case of CNS disease, Cryptococcal lesions should be carefully searched in other body sites, considering that, especially in AIDS patients, virtually any organ can be involved. In particular, a pneumonia without peculiar features (interstitial patterns or basal unilateral infiltrates are frequently observed) and skin lesions mimicking molluscum contagiosum are frequently observed.

6. Diagnosis

6.1 Laboratory studies

Even with widespread disease, the routine laboratory tests (e.g. leukocyte count, haematocrit, erythrocyte sedimentation rate) may yield normal results.

Evaluation of cerebral spinal fluid (CSF) is essential in diagnosing CNS disease, usually showing depressed CSF glucose concentrations, mild elevated protein concentrations and leukocyte counts of 20/ μ L or higher, with a lymphocyte predominance. The CSF can be normal at times, such as in AIDS patients with inadequate inflammatory response or in persons with early infection.

It is also important to evaluate the CSF opening pressure, because elevated values (more than 250 mmH₂O) are found in more than half of patients and are associated with a poor

prognosis, requiring drainage of CSF to reduce the pressure to 200 mmH₂O or lower. Prior to removal of CSF, CT scanning or MRI should be performed to exclude intracranial masses that could result in cerebral herniation, especially in patients with focal neurological signs.

6.2 Microbiological investigations

Etiological diagnosis of Cryptococcal meningitis is obtained by microbiological investigations performed on the CSF.

An India ink preparation is commonly used with CSF to identify the organism by direct microscopy and to support a presumptive diagnosis; if performed correctly, 25-50% of patients with Cryptococcal meningitis show cryptococci.

In patients with a negative India ink test result, Cryptococcal meningitis can be diagnosed with the highly sensitive and specific Cryptococcal antigen testing in CSF, which it is almost invariably detected at high titre in this disease. The test is performed by an immunoenzymatic procedure. If a lumbar puncture cannot be performed, testing for serum antigen can be useful; this test may also be considered as an initial screening tool to detect Cryptococcal infection in HIV positive patients.

CSF and blood should always be cultured for fungi; CSF culture should be performed from three or more centrifuged specimens in Sabouraud dextrose agar. Blood culture results prove positive in up to 75% of HIV infected patients; this indicates an extensive infection, in which the organism may be observed within peripheral leukocytes or bone marrow macrophages.

A high Cryptococcal burden at the baseline (as detected by quantitative CSF culture or high CSF antigen titre) and an altered mental status are the most important predictors of death.

6.3 Imaging studies

Obtaining a CT or MRI of the brain prior to performing a lumbar puncture is important in patients who present with focal neurologic deficits or a history suggesting slowly progressive meningitis, in order to detect mass lesion that may increase the risk of cerebral herniation following a lumbar puncture.

CT can reveal small, ring-enhancing lesions or non-enhancing 'pseudocysts'. Both CT scanning and MRI can also reveal the presence of hydrocephalus caused by basilar meningitis.

7. Therapeutical management

Cryptococcal meningitis and disseminated disease represent severe clinical conditions which were invariably fatal prior to the use of amphoterycin B, flucytosine and azoles; in fact, without a specific antifungal treatment, mortality rates of 100% have been reported within two weeks after clinical presentation in certain HIV-infected populations. The availability of such antifungal therapy regimens has lead to a dramatic decrease in the mortality. However, the three month mortality rate during a correct management of acute Cryptococcal meningoencephalitis still approximates 20%, even in areas where HAART and advanced medical care are widely available.

Treatment regimens are based on a sequence of induction, consolidation and maintenance regimens, both in AIDS and non-AIDS patients (**Table 1**). The first and second phase of the

treatment aim to obtain a rapid clearance of cryptococcus by the CNS, whereas maintenance therapy is targeted to maintain a stable suppression (latency) of the chronic infection in the human organism.

Clinical Setting	Induction Therapy	Duration	Consolidation/Maintenance therapy	Duration
HIV-infected patients	c-AMB (0,7-1 mg/kg/ daily) + flucytosine (100 mg/kg/ daily) <i>or</i> :	≥2 weeks	Consolidation: fluconazole (400 mg/ daily) Maintenance: fluconazole (200 mg/ daily)	≥ 8 weeks
	L-AMB (3-4 mg/kg/ daily) <i>or</i> ABLC (5mg/kg/ daily) (if there are renal concerns) + flucytosine (100 mg/kg/ daily) <i>or</i> :	≥2 weeks	Consolidation and maintenance: Itraconazole (400 mg daily) ^a <i>or</i> : c-AMB (1 mg/kg per week) ^a	≥1 year ^b
	c-AMB <i>or</i> L-AMB <i>or</i> ABLC (for flucytosine-intolerant patients; doses as above)	4-6 weeks		≥1 year ^b
Organ transplant recipients	L-AMB (3-4 mg/kg daily) <i>or</i> ABLC (5 mg/kg daily) + flucytosine (100 mg/kg daily) <i>or</i> :	≥2 weeks	Consolidation: fluconazole (400-800 mg daily)	8 weeks
	c-AMB (0.7 mg/kg daily) <i>or</i> L-AMB (6 mg/kg daily) <i>or</i> ABLC (5 mg/kg daily)	≥4-6 weeks	Maintenance: fluconazole (200-400 mg daily)	6-12 months
Non-HIV, non-transplant patients	c-AMB (0.7-1 mg/kg daily) + flucytosine (100 mg/kg daily) <i>or</i> :	≥4 weeks	Consolidation: fluconazole (400-800 mg daily)	8 weeks
	L-AMB (3-4 mg/kg daily) <i>or</i> ABLC (5 mg/kg daily) + flucytosine (100 mg/kg daily) <i>or</i> :	≥4 weeks	Maintenance: fluconazole (200 mg daily)	6-12 months
	c-AMB <i>or</i> L-AMB <i>or</i> ABLC (for flucytosine-intolerant patients; doses as above)	≥6 weeks		

ABLC, amphotericin B lipid complex; c-AMB, amphotericin B deoxycholate; L-AMB, liposomal amphotericin B. a: Inferior to fluconazole. b: Consider discontinuing antifungal therapy after a minimum of one year, if following a successful HAART, CD4+ count ≥100 cells/μL and undetectable viral load are detected for ≥3 months.

Adapted from [Perfect JR, Clin Inf Dis 1010;50:291-322]

Table 1. Antifungal treatment for Cryptococcal meningoencephalitis

7.1 Management of adverse events

Antifungal drugs used for Cryptococcal meningitis may induce adverse reaction and toxicity. Therefore, patients receiving such regimens must be strictly monitored for dose-

dependent nephrotoxicity and electrolyte alterations, if treated with amphotericin B; for bone marrow suppression and gastrointestinal disturbance, if receiving flucytosine; for hepatotoxicity, if fluconazole is administered.

7.2 HIV-infected patients

Induction therapy is based on amphotericin B deoxycholate (c-AMB) plus flucytosine (see **Table 1** for dosage) for at least two weeks; flucytosine can be administered orally or intravenously in severe cases or if oral intake is not possible. This regimen should be followed by a consolidation therapy with fluconazole orally for eight weeks.

In patients with renal function impairment, lipid formulations of amphotericin B, mainly represented by amphotericin B lipid complex (ABLC) and liposomal amphotericin B (L-AMB), appear to be less nephrotoxic and can substitute c-AMB. Lipid formulations of amphotericin B can also be used as monotherapy for four to six weeks or in association with fluconazole in flucytosine-intolerant patients.

Alternative consolidation regimens include flucytosine plus fluconazole for six weeks, fluconazole alone for 10 to 12 weeks or itraconazole for 10 to 12 weeks, although the results of several trials with these therapies are variable and often disappointing.

Maintenance therapy in HIV-infected patients should be started when CSF Cryptococcal culture becomes negative and a substantial clinical improvement is observed; oral fluconazole is the most effective therapy, with a very low relapse rate, if compared with regimens based on oral itraconazole or intravenous c-AMB. It is considered reasonable to discontinue maintenance therapy, if patients have successfully completed a course of initial therapy and, following HAART, their CD4+ cell count increase to $\geq 200/\mu\text{l}$ for at least three to six months.

Primary prophylaxis for Cryptococcal disease is not routinely recommended for several reasons: its relative infrequency in areas where HAART is available, potential for drug toxicity or interactions with concurrent medications, risk of antifungal drug resistance and costs. However, according to some studies, a screening strategy (Cryptococcal antigen testing) and a prophylaxis may be useful in areas where the availability of HAART is limited and cryptococcosis incidence is high.

7.3 Organ transplant recipient

Cryptococcosis is the third most common fungal infection among solid organ transplant recipients, usually occurring more than one year post-transplant and generally representing a reactivation of latent infection; CNS involvement and/or disseminated disease are documented in most of these patients. Acquisition of the organism usually occurs via inhalation, but the risk of transmission through donor organs or other tissues has also been recently described, even if in a few cases.

Primary induction therapy is based on either L-AMB or ABLC plus flucytosine (see **Table 1** for doses) for at least two weeks, followed by fluconazole for eight weeks as consolidation regimen and for additional six to 12 months, at lower dosage, as maintenance therapy. The use of c-AMB should be avoided because of the risk of nephrotoxicity, especially with the concurrent use of calcineurine inhibitors which are often administered to these patients as immunosuppressive therapy.

If induction therapy does not include flucytosine, L-AMB should be administered for at least four to six weeks. Moreover, a positive CSF culture result after two weeks of induction treatment may indicate a poor outcome and suggests a prolonged induction period with L-AMB in these patients.

During cryptococcosis, a careful reduction of the immunosuppressant therapy (slow dose decrease over time and/or stepwise elimination of immunosuppressants) should be adopted following the initiation of antifungal therapy. Furthermore, reduction of corticosteroids should precede that of calcineurin inhibitors, since the latter drugs have a direct anti-Cryptococcal activity.

7.4 Non-HIV infected, non transplant recipients patients

This represents a heterogeneous category of patients that may include 'presumably immunocompetent hosts', but also people with different immune defects (such as malignancy, connective tissue diseases, severe liver disease and so on).

Antifungal regimens for these patients are substantially the same as the one mentioned above (see Table 1), but there are different opinions about the length of induction therapy: according to some authors, in fact, duration of induction phase should be two weeks, while others suggest to administer it for four to six weeks. The great variability of features in patients forming this category makes it necessary to adapt the therapeutical management to each case.

8. Indications for the management of complications

8.1 Persistence and relapses

Persistent infection is defined by positive results of CSF cultures after four weeks of effective antifungal therapy; relapse is defined by the recovery of cryptococci from a previously checked sterile body site and/or the recrudescence of signs/symptoms at the previous site of disease after an initial normalization. Most cases of relapse are due to an inadequate primary therapy (dose and/or duration) or to the lack of the patient adherence to the consolidation or maintenance treatment.

Restarting induction regimen for a longer course and with a higher dosage may be the first approach in these situations, using amphotericin B deoxycholate plus fluconazole in flucytosine intolerant patients and high doses of fluconazole plus flucytosine in polyene intolerant patients.

The possibility of development of antifungal drug resistance should also be checked in terms of changes in the MIC from the original isolate: a ≥ 3 -dilution difference, in fact, suggests development of direct drug resistance.

Finally, the use of Voriconazole or Posaconazole as salvage therapy should be considered in cases resistant to the first-line antifungal agents. However, the frequent interactions of these agents with several antiretroviral drugs should be carefully considered in HIV-infected patients. In this regard, the use of therapeutic drug monitoring of the plasma concentrations of these agents may represent a useful tool in clinical practice.

8.2 Elevated CSF pressure

Control of CSF pressure is one of the most important determinants in the outcome of Cryptococcal meningitis because elevated values are associated with a high burden of yeasts

in the CNS and with increased morbidity and mortality rates. This association is valid for most HIV-infected patients (there is lack of data about this complication in non-HIV patients with Cryptococcal meningitis), so it is very important to measure the initial opening pressure during the first lumbar puncture. If there is persistent pressure elevation (≥ 25 cm of CSF) and symptoms, lumbar puncture should be repeated daily, until CSF pressure and symptoms have been stabilized for ≥ 2 days, considering temporary percutaneous lumbar drains or ventriculostomy if repeated daily lumbar punctures are required.

8.3 Cryptococcoma

Large cryptococcomas should be treated with a combination of antifungal therapy and early surgical removal, as response to antifungal drugs only is poor. Multiple lesions require a prolonged induction/eradication therapy. Corticosteroids may be required if there is a substantial surrounding oedema, especially in the presence of neurological deficits. Moreover, a nonresponsive brain mass in severely immunosuppressed patients may also suggest the presence of a second pathogen or a tumour.

8.4 IRIS

Immune reconstitution inflammatory syndrome (IRIS) consists of a paradoxical worsening of the clinical manifestations or the course of the Cryptococcal disease in spite of an appropriate antifungal therapy and an apparent microbiological efficacy of the latter. IRIS is interpreted as an exuberant inflammatory reaction of the host at the sites of Cryptococcal infection, subsequent to a rapid improvement in the cellular immunity; for example, IRIS may occur in AIDS patients following introduction of HAART and the restoration of pathogen-specific CD4+ cells.

Risk factors for developing IRIS include: severe Cryptococcal disease (high fungemia), HIV infection, extremely low baseline CD4+ cell count, no previous antiretroviral therapy, lack of CSF sterilization at week two of therapy, introduction of HAART during the early part of antifungal induction therapy and rapid decrease in the HIV viral load in response to HAART.

If IRIS occurs, it is not recommended to modify antifungal therapy, neither to administrate any specific treatment for minor manifestations, whereas corticosteroids may be required for major complications, such as severe CNS inflammation. In order to reduce the risk of developing IRIS, according to the principal current guidelines, introduction of HAART should be delayed for two to 10 weeks after the starting of antifungal therapy.

9. Suggested treatment in special clinical situations

9.1 Pregnant women

If Cryptococcal meningitis occurs during pregnancy it is often severe because of the immunological alterations associated with this event. c-AMB or L-AMB should be administrated as induction therapy, while the use of flucytosine (pregnancy category C) must be considered in relationship to benefit versus risk. Fluconazole (pregnancy category C) must be preferably started after delivery and should be avoided in the first trimester. During the last two trimesters the possible benefits following fluconazole use should be carefully weighed against the risks associated to the long-lasting exposure to this drug during pregnancy.

9.2 Children

Cryptococcosis in children is less frequent than in adults and it is associated with some underlying conditions, such as primary immune defects or certain haematological malignancies, peculiar to childhood, and to common risk factors for both adults and children (e.g. AIDS, transplant recipients).

Induction and consolidation therapy for children is based on the use of c-AmB plus flucytosine for two weeks, followed by fluconazole for eight weeks (10-12 mg/kg daily); for AmB-intolerant patients it is possible to administrate either L-AmB or ABLC. Maintenance therapy is based on the use of fluconazole (6 mg/kg daily).

The optimal dosing and duration of therapy for children with cryptococcosis, however, have not been precisely determined because of the lack of literature data concerning this matter. For the non-HIV-infected, non-transplant population, treatment dose and length schedules similar to that indicated above for adults is prescribed (except for fluconazole dose, which is modified as explained above).

9.3 Resource – Limited health care environment

In many areas of the world with high incidence of cryptococcosis the most effective antifungal drugs are often not available and adjustments in the management of patients with Cryptococcal disease often become necessary. The recommendations concerning therapeutical approach in these settings include:

- When flucytosine is not available, induction therapy is represented by c-AmB with or without fluconazole for two weeks, followed by fluconazole as consolidation therapy for eight weeks and as maintenance therapy until immune reconstitution.
- When a polyene is not available, induction therapy is based on fluconazole for at least 10 weeks or until CSF culture results are negative, followed by consolidation/maintenance therapy with the same drug, at a lower dosage.
- When a polyene is not available but flucytosine is available, induction therapy is represented by fluconazole plus flucytosine for two to 10 weeks, followed by maintenance therapy with fluconazole.
- With use of primary fluconazole therapy for induction, both primary or secondary drug resistance of the isolate may be an issue, and MIC testing is advised; for azole-resistant strains, administer c-AmB until CSF, blood, and/or other sites are sterile.

9.4 *C. gattii* infection

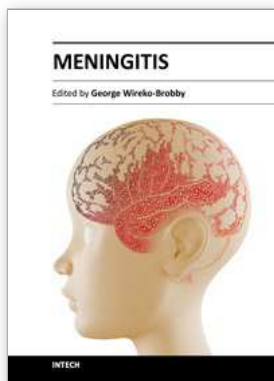
Induction, consolidation and suppressive treatment are the same as for *C. neoformans*. A delayed response to treatment frequently occurs. A radiology follow-up focused on cryptococcoma and hydrocephalus is needed as these conditions are often observed in patients with *C. gattii* infection, as described above. For very large and multiple cryptococcomas, a combination of cAmB and flucytosine therapy for four to six weeks should be considered, followed by fluconazole for six to 18 months, depending on whether surgery was performed. Neurosurgical intervention must be considered if there is compression of vital structures, failure to reduce the size of cryptococcoma after four weeks of therapy or failure to thrive.

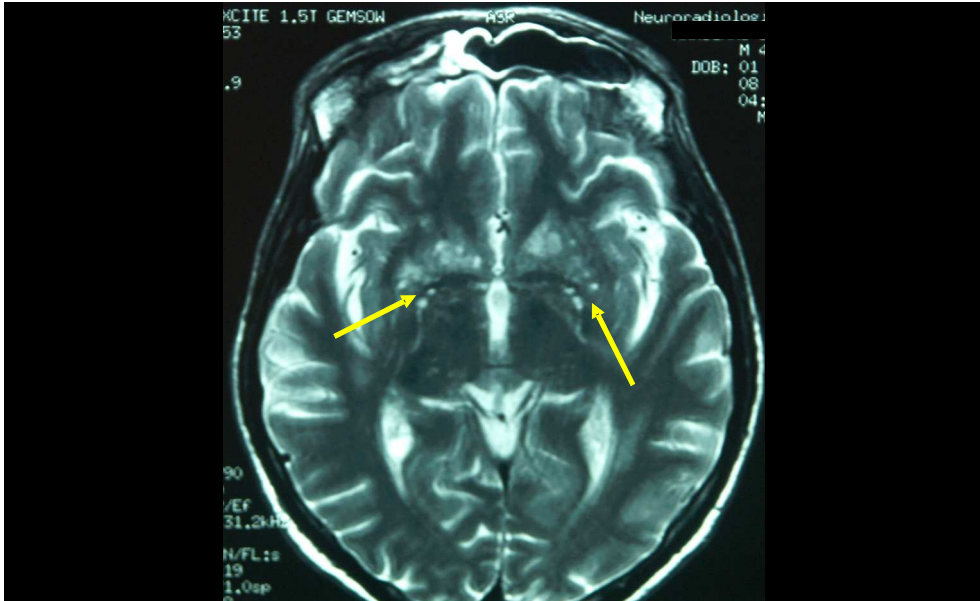

Fig. 1. Brain magnetic resonance of an AIDS patient with Cryptococcal meningitis, highlighting dilatation of the perivascular (Virchow-Robin) spaces

10. References

- Centers for Disease Control and Prevention. Guidelines for Prevention and Treatment of Opportunistic Infections in HIV-Infected Adults and Adolescents: recommendations from CDC, the National Institutes of Health, and the HIV Medicine Association/Infectious Diseases Society of America. *MMWR Morb Mortal Wkly Rep* 2009; 58:48-50.
- Jarvis JN, Harrison TS. HIV-associated cryptococcal meningitis. *AIDS* 2007; 21:2119-2129
- Perfect JR, Dismukes WE, Dromer F, et al. Clinical Practice Guidelines for the Management of Cryptococcal Disease: 2010 Update by the Infectious Diseases Society of America. *Clin Inf Dis* 2010; 50:291-322
- Carbonara S, Regazzi M, Ciraci E, et al. Long-term efficacy and safety of TDM-assisted combination of voriconazole plus efavirenz in an AIDS patient with cryptococcosis and liver cirrhosis. *Ann Pharmacother* 2009 May;43(5):978-84.
- Sorrell TC, Chen SC-A. Recent advances in management of cryptococcal meningitis: commentary. *F1000 Medicine Reports* 2010, 2:82
- Pukkila-Worley R & Mylonakis E. Epidemiology and management of cryptococcal meningitis: developments and challenges. *Expert Opin. Pharmacother* (2008) 9(4):551-560
- Baddley JW, Schaine DC et al. Transmission of *Cryptococcus neoformans* by organ transplantation. *Clin Inf Dis* 2011; 52(4): e94-e98
- King JW, DeWitt ML. Cryptococcosis. <http://emedicine.medscape.com/article/215354-overview> (updated Mar 9, 2011)



Meningitis

Edited by Prof. George Wireko-Brobby

ISBN 978-953-51-0383-7

Hard cover, 232 pages

Publisher InTech

Published online 30, March, 2012

Published in print edition March, 2012

Meningitis is a medical emergency requiring a rapid diagnosis and an immediate transfer to an institution supplied with appropriate antibiotic and supportive measures. This book aims to provide general practitioners, paediatricians, and specialist physicians with an essential text written in an accessible language, and also to highlight the differences in pathogenesis and causative agents of meningitis in the developed and the developing world.

How to reference

In order to correctly reference this scholarly work, feel free to copy and paste the following:

Claudia Fabrizio, Sergio Carbonara and Gioacchino Angarano (2012). Cryptococcal Meningitis, Meningitis, Prof. George Wireko-Brobby (Ed.), ISBN: 978-953-51-0383-7, InTech, Available from:
<http://www.intechopen.com/books/meningitis/cryptococcal-meningitis>

INTECH
open science | open minds

InTech Europe

University Campus STeP Ri
Slavka Krautzeka 83/A
51000 Rijeka, Croatia
Phone: +385 (51) 770 447
Fax: +385 (51) 686 166
www.intechopen.com

InTech China

Unit 405, Office Block, Hotel Equatorial Shanghai
No.65, Yan An Road (West), Shanghai, 200040, China
中国上海市延安西路65号上海国际贵都大饭店办公楼405单元
Phone: +86-21-62489820
Fax: +86-21-62489821

© 2012 The Author(s). Licensee IntechOpen. This is an open access article distributed under the terms of the [Creative Commons Attribution 3.0 License](#), which permits unrestricted use, distribution, and reproduction in any medium, provided the original work is properly cited.