

Intraoperative Radiotherapy for Early Breast Cancer

Masataka Sawaki
*Department of Breast Oncology,
Aichi Cancer Center Hospital,
Japan*

1. Introduction

The standard treatment for early breast cancer is breast-conserving therapy (BCT) with whole breast external irradiation therapy (WBI), and local control plays crucial role on survival (Clarke et al., 2005). It has been established that there is no significant difference in disease-free or overall survival rates between treatment by mastectomy or by lumpectomy with WBI for women with early breast cancer (Fisher et al., 2002; Veronesi et al., 2002). WBI actually provides statistically significant local control and survival data out to 15 years in favor of WBI compared to none (Clarke, et al., 2005). In actuality many women are still encouraged to proceed to mastectomy, because of the lack of access to radiotherapy centers or the long course of treatment of WBI. On the other hand, local recurrences after BCT with or without WBI arise most in the same quadrant as the primary cancer (Veronesi et al., 2001). The main objective of radiotherapy after BCT is considered to be the destruction of residual cancer cells in the operative field. Partial breast irradiation (PBI) has been tested in clinical trials for selected patients, and these studies have shown adequate local control, minimal toxicity, and good cosmetic appearance (Njeh et al., 2010). Intraoperative radiotherapy (IORT) is one of these PBI methods, which has recently been used in early stage breast cancer. Partial breast radiation therapy administered around the tumor bed has been comparable to WBI in selected patients (Antonucci et al., 2009; Benitez et al., 2007; Vicini et al., 2001; Vicini et al., 2003). Many phase II or III trials evaluating adjuvant IORT are actively accruing patients in the United States (NSABP-B39), Europe, United Kingdom, and Australia (Holmes et al., 2007). The standard treatment for early breast cancer is BCT with WBI, and outside the setting of a clinical trial, use of IORT as well as accelerated partial breast irradiation (APBI) is not yet recommended (Njeh, et al., 2010; Skandarajah et al., 2009). Then, particularly in practice setting, patients' selection is critical to the successful application of PBI (Polgár et al., 2010; Vicini et al., 2011).

This review concentrates on the eligibility, methods, outcome, and the point at issue of IORT for early breast cancer. With regard to terms, I defined IORT as the delivery of single fractional dose irradiation directly to the tumor bed during operation, and PBI as irradiation confined to the tumor bed either during operation or after surgery.

2. Eligibility for IORT – Who is suitable for IORT?

Many attempts have been made to identify subgroups of patients who might avoid radiotherapy after BCT, but these are not distinct factors. In general, the risk factors for local recurrence after BCT are larger tumor size, higher tumor grade, younger age, lymph node-positive, and close surgical margin (Clarke, et al., 2005; Fisher, 1997; Park et al., 2000). Then, we review clinical questions of which patients can be considered for IORT. Some points are discussed separately as below.

2.1 Age

Cumulative incidence of recurrence of tumor in the ipsilateral breast after WBI with a boost is different among age, younger women have higher incidence (Bartelink et al., 2007). Age \geq 50 years has been selected in most prospective trials, and studies have shown that elderly patients treated with WBI (Antonini et al., 2007; Bartelink, et al., 2007) or MammoSite® (Chao et al., 2007) were low risk. Few women younger than 50 has been treated with PBI in prospective single arm studies.

2.2 Tumor size

A maximum tumor size of 2cm has been selected in most prospective trials. T2 tumors ($>2\text{cm}$, $\leq 5\text{cm}$) or T0 (ductal carcinoma *in situ*; DCIS) tumors are cautionary recommended (Smith et al., 2009). Patients with T3 or T4 tumors should not receive PBI. An extensive intraductal component should be treated with caution. Patients with multicentric tumors; i.e. presence of foci of cancer in different quadrants, should not receive PBI because of the extent of disease. Patients of clinically unifocal or multifocal tumors with a total tumor size no greater than 2 cm could be suitable for PBI (Smith, et al., 2009).

2.3 Nodal status

Node positive is one of the risk factor for ipsilateral breast cancer (Clarke, et al., 2005). Then, majority of patients who have been treated in prospective single arm APBI trials had pathologically node negative disease. Patients who do not undergo surgical nodal assessment or who have pathologic evidence of nodal involvements should not receive PBI.

2.4 Pathology

One area of concern in the use of IORT is the management of positive surgical margins as positivity is discovered at the final histology, a few days after surgery and IORT. Attention should be paid to ensure negative margins on final pathology (Beal et al., 2007), although margin positivity does not always influence the rate of local recurrences if effective radiotherapy is delivered (Chism et al., 2006; Mariani et al., 1998; Veronesi et al., 2010). Intraoperative frozen sections may be used to reduce positive margins (Fukamachi et al., 2010). Patients with close but negative margins ($<2\text{ mm}$) may be treated with caution (Smith, et al., 2009). Tumors with higher tumor grade is not suitable for PBI, because it is one of risk factors for local recurrence and most prospective trials have not considered as eligibility criteria. As for the tumor characteristics biologically, such as HER2-type or basal-type have

been shown to involve higher risk for local recurrence than luminal A or B-types (Kyndi et al., 2008; Nguyen et al., 2008; Veronesi, et al., 2010), then tailored local-regional treatment for early-stage breast cancer has been reported to be mandatory now (Solin, 2010).

2.5 Oncology

There has been only limited study of IORT including PBI in patients receiving neoadjuvant or concurrent chemotherapy. For patients who will receive adjuvant chemotherapy, it is recommended that APBI be performed first and that there should be an interval of at least 2 to 3 weeks between completion of APBI and initiation of chemotherapy (Smith, et al., 2009). Thus, IORT including PBI allows radiotherapy to be given without delaying administration of chemotherapy or hormonal therapy. But careful observation is needed; a retrospective analysis from MammoSite registry single arm trial reported an association between initiation of adjuvant chemotherapy within 3 weeks of the last MammoSite treatment and an increased risk of both radiation recall skin retraction and suboptimal cosmetics (Haffty et al., 2008). There is no data when adjuvant endocrine therapy with APBI should be started.

We show recommendation for APBI in Table 1.

Factors	Suitable group
Age	≥60
BRCA1/2 mutation	Not present
Tumor size	≤2 cm
T stage	T1
Margins	Negative by at least 2 mm
Grade	Any
LVSI	No
ER status	Positive
Multicentricity	Unicentric only
Multifocally	Clinically unifocal with total size ≤2 cm
Histology	Invasive ductal or other favorable subtypes
Pure DCIS	Not allowed
EIC	Not allowed
Associated LCIS	Allowed
Nodal status	pN0
Nodal surgery	SN Bx or ALND
Neoadjuvant Therapy	Not allowed

Table 1. Suitable patient group recommendation selections for APBI outside of clinical trials; ASTRO Consensus Statement (Smith, et al., 2009)

3. Radiation methods

Several radiation methods are commonly in use for IORT. We show various radiation techniques for IORT in Table 2.

Author	Year (publish)	No. of cases	Median follow up (months)	Technique	Ipsilateral breast cancer recurrence (%)
Sawaki M	2011	32	26	Electrons	0
Veronesi U	2010	1,822	36.1	Electrons	1.3
Vaidya JS	2010	854	48	Photons	1.2
Lemanski C	2010	42	30	Electrons	4.8
Mussari S	2006	47	48	Electrons	0

Table 2. Clinical studies using full-dose Intraoperative radiation therapy (IORT)

3.1 Electrons Intraoperative Therapy (ELIOT)

3.1.1 As a single fractional dose

ELIOT is one of these PBI methods, which has recently been used in early stage breast cancer, mainly at the European Institute of Oncology (Italian: *Istituto Europeo di Oncologia*; IEO) in Milan since 1999 (Intra et al., 2006; Luini et al., 2005; Veronesi et al., 2005; Veronesi, et al., 2010; Veronesi et al., 2001). They have been promoted to prospective trials to investigate tolerance to increased IORT doses and ultimately to introduce the use of 21 Gy in the context of breast conserving surgery. A single dose of 21 Gy at 90% isodose has been shown to be feasible in European breast cancer patients and biologically equivalent to a full dose of conventional WBI (Intra, et al., 2006; Luini, et al., 2005; Veronesi, et al., 2005; Veronesi, et al., 2001). The main advantages are follows. 1) To be able to deliver the radiation before tumor cells have a chance to proliferate under surgical intervention have a rich vascularization, which makes them more sensitive to the action of the radiation. 2) To be able to deliver under direct visualization at the time of surgery. It has the potential for accurate dose delivery by permitting delivery of the radiation dose directly to the surgical margins. 3) IORT could minimize some potential side effects, since skin and the subcutaneous tissue can be displaced. 4) The spread of irradiation to lung and heart is reduced significantly. 5) IORT allows radiotherapy to be given without delaying administration of chemotherapy or hormonal therapy. 6) There is potential for decreasing healthcare cost, because it is one fraction as opposed to 25 fractions. For elderly patients, it is feasible and corresponded to acceptable quality index criteria (Lemanski et al., 2010). In Asian breast cancer patients 21 Gy was recommended as a result of phase I study, which had been used a scheme of dose-escalation from 19, 20, and 21 Gy. (Sawaki et al., 2009), and subsequent phase II study indicated feasibility at 21 Gy (Sawaki et al., 2011). In this technique a disk should be needed to reduce the spread of irradiation to lung and heart. The disk is located between gland and pectoralis muscle. The aluminum and lead disk has been used in Italy (Intra, et al., 2006; Mussari et al., 2006). As for another kind of disk, two layers disk; a first layer (source side) of polymethyl methacrylate (PMMA) and a second layer of copper was designed and selected from metals such as aluminum, copper and lead after testing for their shielding capabilities and the range of the backscatter (Oshima et al., 2009).

IORT extends the primary operation only for an additional 15 minutes plus approximately 30 minutes of a radiotherapy physicist's time to prepare the device (Sawaki, et al., 2009), although conventional WBI radiotherapy usually requires 5 weeks of outpatient treatment.

The largest randomized clinical trial to date is now in progress at the Milan Institute. The goal of the trial is to determine the equivalence of local recurrence rates between quadrantectomy with conventional WBI and that with IORT. To date, they remain investigational until information on its long-term efficacy and safety becomes available (Buchholz, 2009). In the trial at the Milan Institute, 21 Gy, which is recommended through more than 1000 IORT procedures (Intra, et al., 2006), was used for the IORT arm. In the most update data, local recurrence rate was 1.3% (24/1,822) (Veronesi, et al., 2010). In addition, IORT can achieve early initiation of radiotherapy (RT). Delay in the initiation of RT is associated with a decrease in local recurrence rate (Huang, 2003).

3.1.2 As a boost

With regard to another concept of full-dose intraoperative radiotherapy, an anticipated boost during operation has been studied (Reitsamer et al., 2002; Reitsamer et al., 2006). A single dose of 9 Gy was applied to the 90% reference isodose with energies ranging from 4 to 15 MeV, using round applicator tubes 4–8 cm in diameter. After wound healing, the patients received additional 51 – 56 Gy external boost radiation (EBRT) to the whole breast (Reitsamer, et al., 2002). The advantages are follows. 1) To complete skin sparing, 2) the precise application of the boost directly to the tumor bed with a homogeneous tissue radiation and 3) to reduce postoperative radiation time for 7-10 days (time of postoperative boost radiotherapy) (Reitsamer, et al., 2002; Reitsamer, et al., 2006).

3.1.3 Nipple sparing mastectomy

Nipple sparing mastectomy can be applied for treatment of breast cancer when mastectomy is indicated. To reduce the risk of retro areolar recurrence, radio-surgical treatment combining subcutaneous mastectomy with intraoperative radiotherapy (ELIOT) is proposed (Petit et al., 2009; Petit et al., 2009). The IORT with electrons of 16 Gy in one shot was delivered on the nipple areolar area. Local recurrence rate was not higher than the usual rate observed in the literature, although longer follow up is needed.

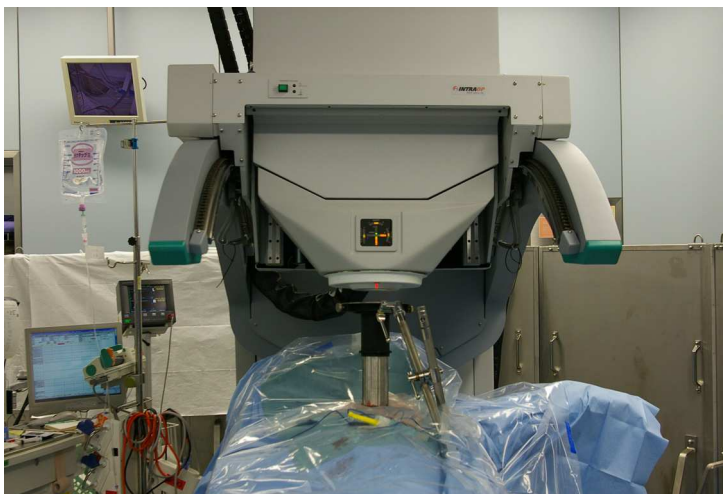




Fig. 1. Intraoperative radiotherapy (electrons)

3.2 Targeted intraoperative radiotherapy (TARGIT)

This device is inserted intraoperatively into the tumor cavity after excision of the tumor and emits X-rays from within the breast (Vaidya et al., 2010). The authors used a miniature electron-beam-driven X-ray source called Intrabeam®, which emits low energetic X-rays with 50 kV from the point source. In large randomized clinical trial, TARGIT trial for selected patients with early breast cancer, a single dose of radiotherapy delivered at the time of surgery by use of targeted intraoperative radiotherapy is considered as an alternative to external beam radiotherapy delivered over several weeks (Vaidya, et al., 2010), although it needs longer follow up to conclude the no inferiority to the WBI (Reitsamer et al., 2010).

4. Conclusion

In conclusion, IORT is an option applied for breast conserving therapy in the selected patients. TARGIT trial has been considered as an alternative to external beam radiotherapy delivered over several weeks (Vaidya, et al., 2010). And also ELIOT appears a promising feature in early breast cancer treated with breast conserving surgery, reducing the exposure of normal tissues to radiations and shortening the radiation course from 6 weeks to one single session (Veronesi, et al., 2010). These clinical studies have shown adequate local control, minimal toxicity, and good cosmetic appearance, although a longer follow up is needed for the evaluation of the late side effects. In practice setting, careful management is needed because patients' selection is critical to the successful application of IORT.

5. Conflict of Interest

The author states that I have no conflict of interest.

6. Acronyms and abbreviations

ALND; Axillary lymph node dissection
APBI; Accelerated partial breast irradiation
ASTRO; American Society for Radiation Oncology
BCT; Breast conserving therapy
DCIS; Ductal carcinoma *in situ*
EBRT; External boost radiation
EIC; Extensive intraductal component
ELIOT; Electrons intraoperative therapy
ER; Estrogen receptor
IORT; Intraoperative radiotherapy
LCIS; lobular carcinoma *in situ*
LVSI; Lymph-vascular space invasion
PBI; Partial breast irradiation
PMMA; polymethyl methacrylate
RT; Radiotherapy
SN Bx; Sentinel lymph node biopsy
TARGIT; Targeted intraoperative radiotherapy
WBI; Whole breast external irradiation therapy


7. References

- Antonini N, Jones H, Horiot JC et al (2007) Effect of age and radiation dose on local control after breast conserving treatment: EORTC trial 22881-10882. *Radiother Oncol* 82:265-271
- Antonucci JV, Wallace M, Goldstein NS et al (2009) Differences in Patterns of Failure in Patients Treated With Accelerated Partial Breast Irradiation Versus Whole-Breast Irradiation: A Matched-Pair Analysis With 10-Year Follow-Up. *International Journal of Radiation OncologyBiologyPhysics* 74:447-452
- Bartelink H, Horiot JC, Poortmans PM et al (2007) Impact of a higher radiation dose on local control and survival in breast-conserving therapy of early breast cancer: 10-year results of the randomized boost versus no boost EORTC 22881-10882 trial. *J Clin Oncol* 25:3259-3265
- Beal K, McCormick B, Zelefsky M et al (2007) Single-Fraction Intraoperative Radiotherapy for Breast Cancer: Early Cosmetic Results. *International Journal of Radiation OncologyBiologyPhysics* 69:19-24
- Benitez P, Keisch M, Vicini F et al (2007) Five-year results: the initial clinical trial of Mammosite balloon brachytherapy for partial breast irradiation in early-stage breast cancer. *The American Journal of Surgery* 194:456-462
- Buchholz TA (2009) Radiation therapy for early-stage breast cancer after breast-conserving surgery. *N Engl J Med* 360:63-70

- Chao KK, Vicini FA, Wallace M et al (2007) Analysis of treatment efficacy, cosmesis, and toxicity using the MammoSite breast brachytherapy catheter to deliver accelerated partial-breast irradiation: the william beaumont hospital experience. *Int J Radiat Oncol Biol Phys* 69:32-40
- Chism D, Freedman G, Li T et al (2006) Re-excision of margins before breast radiation—diagnostic or therapeutic? *International Journal of Radiation OncologyBiologyPhysics* 65:1416-1421
- Clarke M, Collins R, Darby S et al (2005) Effects of radiotherapy and of differences in the extent of surgery for early breast cancer on local recurrence and 15-year survival: an overview of the randomised trials. *Lancet* 366:2087-2106
- Fisher B, Anderson S, Bryant J et al (2002) Twenty-year follow-up of a randomized trial comparing total mastectomy, lumpectomy, and lumpectomy plus irradiation for the treatment of invasive breast cancer. *N Engl J Med* 347:1233-1241
- Fisher ER (1997) Lumpectomy margins and much more. *Cancer* 79:1453-1458; discussion 1459-1460
- Fukamachi K, Ishida T, Usami S et al (2010) Total-Circumference Intraoperative Frozen Section Analysis Reduces Margin-Positive Rate in Breast-Conservation Surgery. *Jpn J Clin Oncol* 40:513-520
- Haffty BG, Vicini FA, Beitsch P et al (2008) Timing of Chemotherapy after MammoSite radiation therapy system breast brachytherapy: analysis of the American Society of Breast Surgeons MammoSite breast brachytherapy registry trial. *Int J Radiat Oncol Biol Phys* 72:1441-1448
- Holmes D, Baum M, Joseph D (2007) The TARGIT trial: targeted intraoperative radiation therapy versus conventional postoperative whole-breast radiotherapy after breast-conserving surgery for the management of early-stage invasive breast cancer (a trial update). *The American Journal of Surgery* 194:507-510
- Huang J (2003) Does Delay in Starting Treatment Affect the Outcomes of Radiotherapy? A Systematic Review. *J Clin Oncol* 21:555-563
- Intra M, Luini A, Gatti G et al (2006) Surgical technique of intraoperative radiation therapy with electrons (ELIOT) in breast cancer: A lesson learned by over 1000 procedures. *Surgery* 140:467-471
- Kyndi M, Sorensen FB, Knudsen H et al (2008) Estrogen Receptor, Progesterone Receptor, HER-2, and Response to Postmastectomy Radiotherapy in High-Risk Breast Cancer: The Danish Breast Cancer Cooperative Group. *J Clin Oncol* 26:1419-1426
- Lemanski C, Azria D, Gourgon-Bourgade S et al (2010) Intraoperative radiotherapy in early-stage breast cancer: results of the montpellier phase II trial. *Int J Radiat Oncol Biol Phys* 76:698-703
- Luini A, Orecchia R, Gatti G et al (2005) The Pilot Trial on Intraoperative Radiotherapy with Electrons (ELIOT): Update on the Results. *Breast Cancer Res Treat* 93:55-59
- Mariani L, Salvadori B, Marubini E et al (1998) Ten year results of a randomised trial comparing two conservative treatment strategies for small size breast cancer. *Eur J Cancer* 34:1156-1162
- Mussari S, Sabino Della Sala W, Busana L et al (2006) Full-dose intraoperative radiotherapy with electrons in breast cancer. First report on late toxicity and cosmetic results from a single-institution experience. *Strahlentherapie und Onkologie : Organ der Deutschen Rontgengesellschaft [et al]* 182:589-595

- Nguyen PL, Taghian AG, Katz MS et al (2008) Breast Cancer Subtype Approximated by Estrogen Receptor, Progesterone Receptor, and HER-2 Is Associated With Local and Distant Recurrence After Breast-Conserving Therapy. *J Clin Oncol* 26:2373-2378
- Njeh CF, Saunders MW, Langton CM (2010) Accelerated Partial Breast Irradiation (APBI): A review of available techniques. *Radiat Oncol* 5
- Oshima T, Aoyama Y, Shimozato T et al (2009) An experimental attenuation plate to improve the dose distribution in intraoperative electron beam radiotherapy for breast cancer. *Phys Med Biol* 54:3491-3500
- Park CC, Mitsumori M, Nixon A et al (2000) Outcome at 8 years after breast-conserving surgery and radiation therapy for invasive breast cancer: influence of margin status and systemic therapy on local recurrence. *J Clin Oncol* 18:1668-1675
- Petit JY, Veronesi U, Orecchia R et al (2009) Nipple sparing mastectomy with nipple areola intraoperative radiotherapy: one thousand and one cases of a five years experience at the European institute of oncology of Milan (EIO). *Breast Cancer Res Treat* 117:333-338
- Petit JY, Veronesi U, Rey P et al (2009) Nipple-sparing mastectomy: risk of nipple-areolar recurrences in a series of 579 cases. *Breast Cancer Res Treat* 114:97-101
- Polgár C, Limbergen EV, Pötter R et al (2010) Patient selection for accelerated partial-breast irradiation (APBI) after breast-conserving surgery: Recommendations of the Groupe Européen de Curiethérapie-European Society for Therapeutic Radiology and Oncology (GEC-ESTRO) breast cancer working group based on clinical evidence (2009). *Radiother Oncol* 94:264-273
- Reitsamer R, Fastner G, Kopp M et al (2010) Intraoperative radiotherapy for early breast cancer. *Lancet* 376:1141; author reply 1143-1144
- Reitsamer R, Peintinger F, Sedlmayer F et al (2002) Intraoperative radiotherapy given as a boost after breast-conserving surgery in breast cancer patients. *Eur J Cancer* 38:1607-1610
- Reitsamer R, Sedlmayer F, Kopp M et al (2006) The Salzburg concept of intraoperative radiotherapy for breast cancer: results and considerations. *Int J Cancer* 118:2882-2887
- Sawaki M, Sato S, Kikumori T et al (2009) A phase I study of intraoperative radiotherapy for early breast cancer in Japan. *World J Surg* 33:2587-2592
- Sawaki M, Sato S, Noda S et al (2011) Phase I/II study of intraoperative radiotherapy for early breast cancer in Japan. *Breast Cancer*:2011 Jul 16. [Epub ahead of print]
- Skandarajah AR, Lynch AC, Mackay JR et al (2009) The Role of Intraoperative Radiotherapy in Solid Tumors. *Ann Surg Oncol* 16:735-744
- Smith BD, Arthur DW, Buchholz TA et al (2009) Accelerated partial breast irradiation consensus statement from the American Society for Radiation Oncology (ASTRO). *J Am Coll Surg* 209:269-277
- Solin LJ (2010) Tailored Local-Regional Treatment for Early-Stage Breast Cancer. *Clinical Breast Cancer* 10:343-344
- Vaidya JS, Joseph DJ, Tobias JS et al (2010) Targeted intraoperative radiotherapy versus whole breast radiotherapy for breast cancer (TARGIT-A trial): an international, prospective, randomised, non-inferiority phase 3 trial. *Lancet* 376:91-102
- Veronesi U, Cascinelli N, Mariani L et al (2002) Twenty-year follow-up of a randomized study comparing breast-conserving surgery with radical mastectomy for early breast cancer. *N Engl J Med* 347:1227-1232

- Veronesi U, Marubini E, Mariani L et al (2001) Radiotherapy after breast-conserving surgery in small breast carcinoma: long-term results of a randomized trial. *Ann Oncol* 12:997-1003
- Veronesi U, Orecchia R, Luini A et al (2005) Full-Dose Intraoperative Radiotherapy With Electrons During Breast-Conserving Surgery. *Ann Surg* 242:101-106
- Veronesi U, Orecchia R, Luini A et al (2010) Intraoperative radiotherapy during breast conserving surgery: a study on 1,822 cases treated with electrons. *Breast Cancer Res Treat* 124:141-151
- Veronesi U, Orecchia R, Luini A et al (2001) A preliminary report of intraoperative radiotherapy (IORT) in limited-stage breast cancers that are conservatively treated. *Eur J Cancer* 37:2178-2183
- Vicini F, Arthur D, Wazer D et al (2011) Limitations of the American Society of Therapeutic Radiology and Oncology Consensus Panel guidelines on the use of accelerated partial breast irradiation. *Int J Radiat Oncol Biol Phys* 79:977-984
- Vicini FA, Baglan KL, Kestin LL et al (2001) Accelerated treatment of breast cancer. *J Clin Oncol* 19:1993-2001
- Vicini FA, Kestin L, Chen P et al (2003) Limited-Field Radiation Therapy in the Management of Early-Stage Breast Cancer. *JNCI Journal of the National Cancer Institute* 95:1205-1210



Modern Practices in Radiation Therapy

Edited by Dr. Gopishankar Natanasabapathi

ISBN 978-953-51-0427-8

Hard cover, 370 pages

Publisher InTech

Published online 30, March, 2012

Published in print edition March, 2012

Cancer is the leading cause of death in economically developed countries and the second leading cause of death in developing countries. It is an enormous global health encumbrance, growing at an alarming pace. Global statistics show that in 2030 alone, about 21.4 million new cancer cases and 13.2 million cancer deaths are expected to occur, simply due to the growth, aging of the population, adoption of new lifestyles and behaviors. Amongst the several modes of treatment for cancer available, Radiation treatment has a major impact due to technological advancement in recent times. This book discusses the pros and cons of this treatment modality. This book "Modern Practices in Radiation Therapy" has collaged topics contributed by top notch professionals and researchers all around the world.

How to reference

In order to correctly reference this scholarly work, feel free to copy and paste the following:

Masataka Sawaki (2012). Intraoperative Radiotherapy for Early Breast Cancer, Modern Practices in Radiation Therapy, Dr. Gopishankar Natanasabapathi (Ed.), ISBN: 978-953-51-0427-8, InTech, Available from:

<http://www.intechopen.com/books/modern-practices-in-radiation-therapy/intraoperative-radiotherapy-for-early-breast-cancer>

INTECH
open science | open minds

InTech Europe

University Campus STeP Ri
Slavka Krautzeka 83/A
51000 Rijeka, Croatia
Phone: +385 (51) 770 447
Fax: +385 (51) 686 166
www.intechopen.com

InTech China

Unit 405, Office Block, Hotel Equatorial Shanghai
No.65, Yan An Road (West), Shanghai, 200040, China
中国上海市延安西路65号上海国际贵都大饭店办公楼405单元
Phone: +86-21-62489820
Fax: +86-21-62489821

© 2012 The Author(s). Licensee IntechOpen. This is an open access article distributed under the terms of the [Creative Commons Attribution 3.0 License](#), which permits unrestricted use, distribution, and reproduction in any medium, provided the original work is properly cited.