

# Gynecomastia and Liposuction

Francisco J. Agullo<sup>1,2</sup>, Sadri O. Sozer<sup>1,2</sup> and Humberto Palladino<sup>1,2</sup>

<sup>1</sup>Texas Tech University Health Sciences Center, El Paso, TX

<sup>2</sup>El Paso Cosmetic Surgery Center, El Paso, TX

USA

## 1. Introduction

Gynecomastia is derived from the Greek terms gynec (feminine) and mastos (breast). The literal translation, male breasts, relates to any condition that results in excessive development of breast tissue in males.

Galen introduced the term gynecomastia in the second century AD. He defined gynecomastia as an unnatural increase in the breast fat of males. The first recorded description of a reduction mammoplasty was by Paulus of Aegina in the seventh century AD, who referred to the condition as an "effeminacy of men."

Gynecomastia is responsible for a significant amount of emotional and psychological trauma especially in the young population. The treatment of gynecomastia has continued to evolve over the ages and today needs to be designed specifically to address the amount of skin excess, glandular breast tissue, adipose tissue, degree of breast ptosis, and the size of the nipple areolar complex (NAC). Each component should be considered separately to optimize the outcome.

## 2. Incidence

The increase in breast size due to the accumulation of fatty tissue, as seen in obese patients, is considered pseudogynecomastia. True gynecomastia may or may not be associated with pathologic conditions as this can be the result of the usual physiologic development. Prevalence of asymptomatic gynecomastia is 60%–90% in neonates, 50%–60% in adolescents, and up to 70% in men age 50–69 years. [1-3] Trimodal distribution for asymptomatic gynecomastia is noted (neonatal, pubertal, and in elderly males). Prevalence of symptomatic gynecomastia is markedly lower.

Physiologic gynecomastia is common in adolescents at the time of puberty with published incidence rates of 25 to 65% by the ages of 14. [4] By the time pubertal changes are completed and hormonal levels stabilized the persistence of gynecomastia is uncommon. Different series report between 30% and 50% incidence although in adolescent populations the incidence of bilateral gynecomastia could be even higher.[5]

Previous studies have reported that in an average out-patient clinic you may see 10 to 20 new cases of gynecomastia per year, accounting for up to 80% of all male breast referrals. [2,

3, 6, 7] In a recent study the referrals for specialist evaluation for gynecomastia have increased 500% since 1990's making this pathology more prevalent.[8]

### 3. Pathophysiology

The hormonal role of estrogen/testosterone ratio has been identified as a cause of gynecomastia although many other reasons were identified as possible causes of gynecomastia (Table 1). Is important to rule out any other pathologic process related to gynecomastia, in particular testicular sources. A thorough interrogation should be performed including family history as well as relevant medications, recreational drugs, etc.

<b>Physiologic</b>	<b>Androgen deficiency</b>	<b>Drugs</b>
Neonatal	Hypogonadism	Alcohol
Puberty	Primary	Amphetamines
Advance age	Klinefelter's syndrome	Chemotherapeutic agents
Familial	Kallman's syndrome	Cimetidine
	Congenital anorchia	Digitalis
	ACTH deficiency	Haldol
	Defects in androgen synthesis	Hydroxyzine
	Secondary	Isoniazid
	Trauma	Methyldopa
	Orchitis	Marijuana
	Cryptorchidism	Opiates
	Irradiation	Phenothiazines
	Hydrocele	Progestins
	Spermatocele	Reserpine
	Varicocele	Spirololactone
	Renal failure	Tricyclic antidepressants
	Exogenous Androgens	
	Estrogen excess	
	Testicular sources	
	Germ cell tumors	
	Choriocarcinoma	
	Seminoma	
	Teratoma	
	Non-germ cell tumors	
	Leydig cell tumor	
	Granulosa-theca tumor	
	Sertoli cell tumor	
	True Hermaphroditism	
	Liver disease	
	Exogenous estrogen	
	Malnutrition	
<b>Systemic Conditions / idiopathic</b>		
Obesity		
Hyperthyroidism		
Hypothyroidism		
Chronic illness		
AIDS		
<b>Neoplastic</b>		
Breast carcinoma		
Liver carcinoma		
Lung carcinoma		
Adrenal tumors		
<b>Infectious</b>		
Sparganum or plerocercoid larva of the tapeworm		

Table 1. Causes of Gynecomastia

Symmetrical and bilateral breast enlargement is usually the result of both glandular and adipose tissue enlargement. In those cases where a unilateral or asymmetrical involvement is noted a thorough diagnostic investigation should be done to rule out breast carcinoma, where a breast biopsy is indicated.

#### **4. Indications and contraindications**

Considering that gynecomastia is a cause of emotional and psychological distress is important to clearly identify the main concern for the patient in the context of development. Many times is just a matter of aesthetic concern but other circumstances such as pain, tenderness, and even the possibility of cancer should be considered. Reassurance and guidance play an important role in the adolescent population during puberty. Watchful waiting during these years is an accepted practice.

All patients undergoing gynecomastia should be optimized to avoid complications. NSAID's should be stopped one week prior to the procedures and resumed one week after the procedure if necessary. No patients on therapeutic anticoagulation should be treated for this condition. Smoking is relative contraindications but is our practice to require smoking cessation for at least two weeks prior to the procedure and four weeks after the procedure. Contraindications for gynecomastia include patients with:

- cardiopulmonary disease
- renal failure
- therapeutic anticoagulation
- wound-healing problems
- immunodeficiency
- active smokers
- morbid obesity

#### **5. Patient evaluation and selection**

A complete evaluation is necessary to identify the cause of the pathology, optimize the timing for surgery, rule out neoplastic origin, and avoid unnecessary interventions.

Physical examination should include bilateral breast exams as well as neck and axillary bimanual palpation to rule out any masses or adenopathies. A bilateral testicular examination should be included.

Any palpable mass, especially in asymmetric enlargement should undergo biopsy to rule out malignancy.

Laboratory evaluation should follow physical findings and patients should be appropriately referred to an endocrinologist as needed.

#### **6. Medical management**

Neonatal and puberal gynecomastia are usually self limiting and often do not require any type of treatment. Less than 10% of adolescent will experience persistent breast enlargement that will require some kind of intervention. On the other hand, gynecomastia of advanced

age does not resolve spontaneously and often requires treatment. Several drugs have been used in the treatment of gynecomastia for different reasons. Clomiphene, an antiestrogen has been utilized and reported since 1970's by multiple authors [9-11]. The androgen Danazole has also been used with success [12-14]. Testosterone supplementation for cases of testosterone deficiency has been used. Most recently Tamoxifen has been used with some success[15-17]. Even radiation has been reported in the past.

Medical treatment of gynecomastia is usually applied during the first stages of the disease as a palliative method to control symptoms such as pain and tenderness while surgical management is usually the method of choice to address the aesthetic concern.

## 7. Surgical management

The surgical management of gynecomastia has evolved considerably over the last 60 years. Since the first descriptions by Webster in 1946 [18], the subsequent classifications by Simon in 1973[19], and the introduction of liposuctions for gynecomastia in 1983 [20] a broad spectrum of alternatives developed to address the multiple degrees of this condition. The subsequent advances in technologies and minimally invasive techniques allowed for a more refined approach to the condition. Based on this Dr. Rohrich expanded the classification and management alternatives in 2003. [21]

### 7.1 Considerations

There are certain characteristics that need to be addressed when planning a surgical approach to gynecomastia. These characteristics are:

- Amount of skin excess and skin quality
- Adipose component
- Glandular component
- Size of nipple areolar complex

#### *Amount of skin excess and skin quality*

The skin envelope plays a significant role in determining which will be the preferred approach. As outlined in Table-2 and Table-3, Dr. Rohrich modification of the original Simon classification serves as a guide for treatment. In cases with minimal skin excess and good skin quality a minimally invasive approach should suffice. This includes liposuction and perhaps limited skin incisions such as periareolar, intra-areolar, transaxillary, and endoscopic for excision of breast tissue. When the skin envelope is enlarged and/or stretched such as in postbariatric population, or in moderate to severe cases of gynecomastia, a larger excision should be planned.

The position of the nipple areolar complex (NAC) is also an important factor and will determine if a minimally invasive approach will be sufficient, or a mastopexy, and even a free nipple graft, will be required.

The different methods to address a significant skin excess and ptosis include crescentic excision, periareolar mastopexy, vertical mastopexy, Wise pattern mastopexy and inframammary fold scar. Crescentic mastopexy will allow for minimal mobilization up to 1 cm of the NAC in a cephalad direction. At the same time allows for access for direct excision of the breast tissue. This method is reserved for cases with mild to moderate ptosis and good

skin quality. Periareolar mastopexy can be utilized also when a mild amount of excess skin is to be excised allowing for better access to excision of breast tissue. Vertical mastopexy can address cases of moderate ptosis allowing a comfortable access for removal of breast tissue. This method could be used for moderate to severe cases where skin excision and NAC repositioning form 1 to 5 cm is required. Wise pattern mastopexy is usually reserved for cases where a significant amount of excess tissue is to be removed. This approach also allows for an open access for removal of breast tissue and at the same time allows for easy repositioning of the NAC. The scars resulting from this procedure are usually the limiting factor as patients prefer a less invasive approach. The inframammary fold scar allows a large resection of excess tissue with a transverse scar along the inframammary fold but often requires free nipple graft for transposition of the NAC.

#### *Adipose component*

The amount of adipose tissue plays an important role on the method required to address the gynecomastia. The main line of treatment for adipose tissue is suction assisted liposuction (SAL). Some patients may present with dense fibrous septi within the adipose tissue. In these cases ultrasound assisted liposuction (UAL) or power assisted liposuction (PAL) in combination with SAL delivers the best result. If the adipose component is the main cause of gynecomastia, liposuction alone or combined with a minimal access excision should be the preferred option.

#### *Glandular component*

If the glandular component of the breast is prevalent the fibrous architecture becomes the main concern. Liposuction techniques alone are often insufficient to completely address the issue and a direct excision of some kind is required. While SAL still play a significant role in addressing the adipose tissue and sculpting of the periphery, the central glandular component should be excised. Some authors advocate a minimally invasive approach either by performing minimal access incisions in the periphery of the NAC or using arthroscopic shavers as a mean to break down the fibrous capsule of the glandular component and retrieve it with conventional liposuction methods.[22] If skin excess is also a significant concern, direct excision becomes the method of choice as the access is granted by the larger skin incisions.

#### *Size of the nipple areolar complex*

In some cases the diameter of the NAC is too large and other times there is a significant asymmetry between the sizes of the NACs. In either of these circumstances a reduction of the NAC is required. A periareolar incision is performed and the excess tissue is removed reducing the diameter of the NAC. This procedure can also be performed in combinations with either of the mastopexy techniques described above.

Classification	Clinical Features	Treatment Options
Grade I	Breast fullness without ptosis	Excision plus liposuction
Grade II	Breast fullness with the nipple at the IMF	Excision, liposuction and nipple transposition
Grade III	Significant hypertrophy with the nipple below the IMF	Breast reduction with nipple transposition

Table 2. Classification of Gynecomastia

Classification	Clinical Features	Treatment Options
Grade I: Minimal hypertrophy, less than 250 g.	IA: Primarily fatty breast tissue IB: Primarily fibrous breast tissue	Suction assisted lipectomy (SAL) is highly successful Additional excision is often required
Grade II: Moderate hypertrophy, 250 to 500 g.	IIA: Primarily fatty breast tissue IIB: Primarily fibrous breast tissue with peripheral fat	SAL is highly effective Usually requires central excision with peripheral suction
Grade III: Severe hypertrophy, more than 500 g.	Severe hypertrophy with grade I ptosis	Requires resection with suction
Grade IV: Severe Hypertrophy with grade II or III ptosis	Severe hypertrophy with grade II or III ptosis	Requires resection with suction and possible nipple transposition.

Table 3. Rohrich Classification of Gynecomastia

## 7.2 Operative technique

Markings are made to outline the boundaries of treatment. The inframammary fold is also marked preoperatively with the patient standing. Further markings for NAC repositioning are performed with the patient in the upright position. All patients undergo general anesthesia and are positioned supine with the arms abducted. The entire chest wall and upper abdomen are included in the operative field. Appropriate antibiotic and deep venous thrombosis prophylaxis are used.

### *Liposuction*

Suction assisted liposuction alone or in combination with UAL and PAL play an essential role in the treatment of pseudogynecomastia or those cases where mild gynecomastia is present with a predominant adipose component. Our preferred technique includes infiltration of the surgical area with superwet solution (1:1 ratio) with a solution containing 50 ml of 1% lidocaine, and one ampule of 1:1000 epinephrine in 1 liter of lactated Ringer's solution. A remote access at the anterior axillary line is used for a 3-4 mm liposuction canula.

Following the initial conventional SAL the UAL is used to address the areas of dense tissues. Ultrasound-assisted liposuction is first performed using the LySonix 3000 Ultrasonic Surgical Aspirator System (Byron Medical, Tucson, Ariz.). It is set on the pulse mode at amplitude of 90 percent. A plastic port is placed into the incision through which the ultrasound probe is passed. The endpoint for ultrasound application is loss of tissue resistance throughout the marked area (approximately 4 to 10 minutes per side). We do not perform PAL although it is a viable alternative. The skin flaps are thinned to a thickness of approximately 1.5 cm. Extra SAL is utilized if further refinements are necessary after UAL. Sequential pressure with a rolled gauze-sponge is applied at the end of the procedure to evacuate the excess of fluid through the access ports. The ports are sutured and a compression garment is applied.

### *Liposuction and endoscopic excision of breast tissue*

Liposuction is usually performed as previously explained. The transaxillary approach is used for the excision of the breast tissue. Similarly to the approach for transaxillary breast

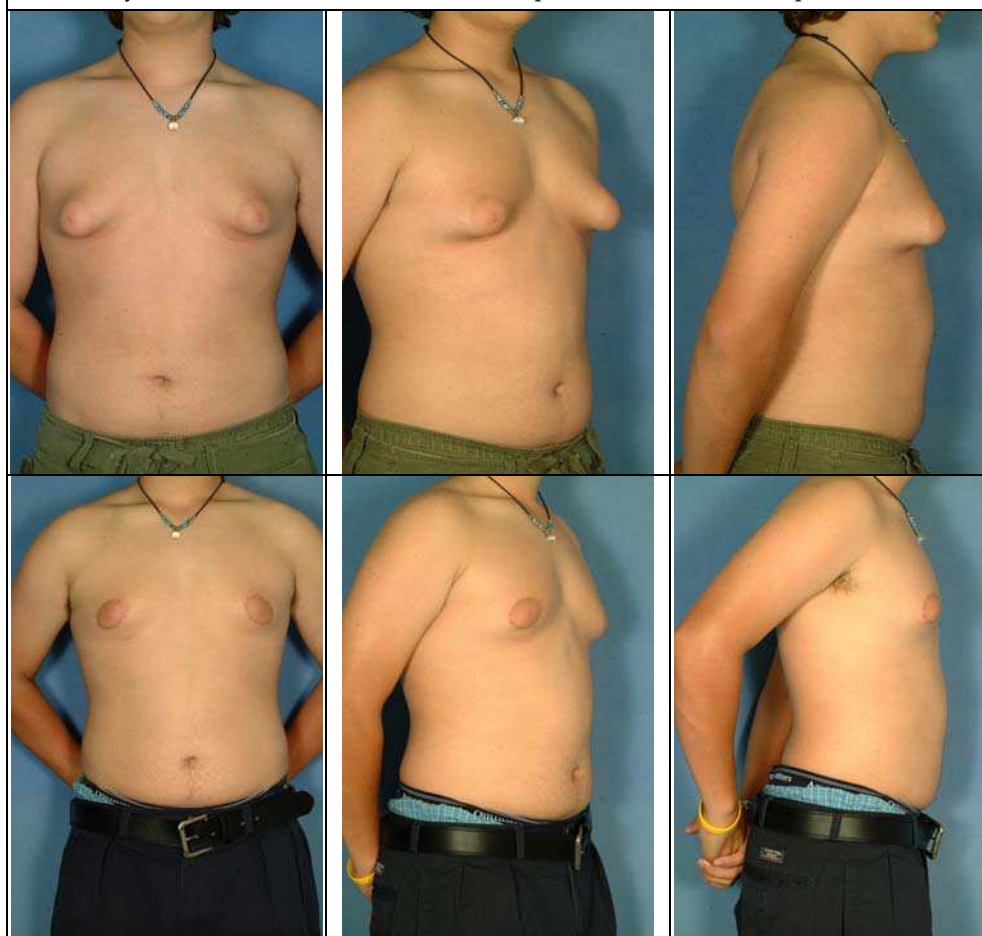
augmentation, a tunnel is developed and the breast tissue including adipose and glandular tissue are excised under direct visualization using and endoscopic guidance. This technique is reserved for conditions where there is no need for repositioning of the NAC and good skin quality.

*Liposuction with direct excision and repositioning of the nipple areola complex*

Liposuction is performed as explained above and once completed the direct excision and NAC repositioning are undertaken following the preoperative markings. If no NAC repositioning is required a minimal access direct excision is performed through an inferior periareolar incision. The authors find that the morbidity of this approach is minimal and, at the same time, more efficient and cost effective than other minimally invasive techniques described. Case 1

**Case 1**

Grade II gynecomastia treated with periareolar approach with liposuction (SAL and UAL) followed by direct excision of breast tissue - Preop and 6 months follow up.

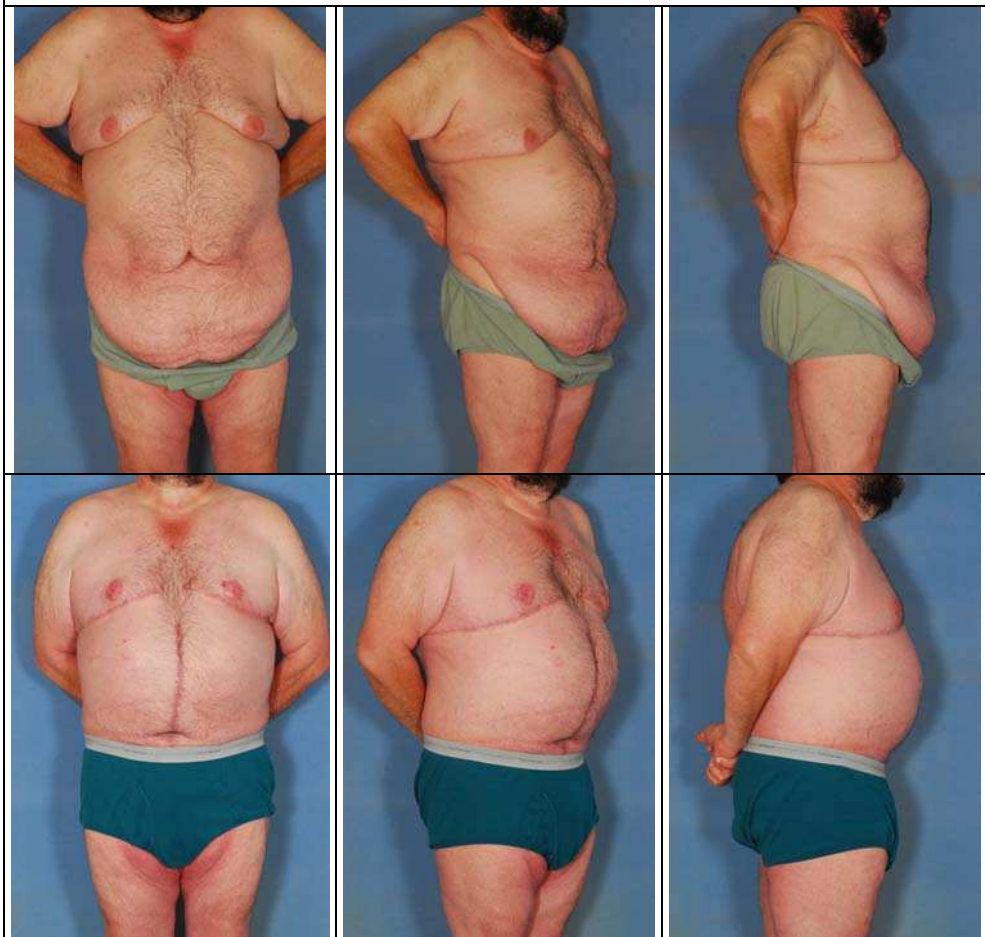

*Wise pattern and inframammary approach with or without free nipple graft*

This is the treatment of choice for the severe ptosis and the massive weight loss patient. In some cases a radical resection with free nipple grafting is necessary and delivers the best results to those patients with Grade III or severe gynecomastia. In these cases we favour an inframammary approach with resection of excess skin, subcutaneous and glandular tissue and repositioning of the NAC as a free NAC graft. The position of the new NAC is determined once the excision has been undertaken and the flaps approximated with staples. The new NAC position is deepithelialized and the free nipple graft sawn into position with a bolster dressing. Case 2

**Case 2**

Grade III gynecomastia on a massive weight loss patient. Treatment included inframammary fold approach with direct excision of excess skin and breast tissue followed by free nipple graft. Preop and one month follow up.





The algorithm on Figure 1 demonstrates our propose treatment plan for the different degrees of gynecomastia

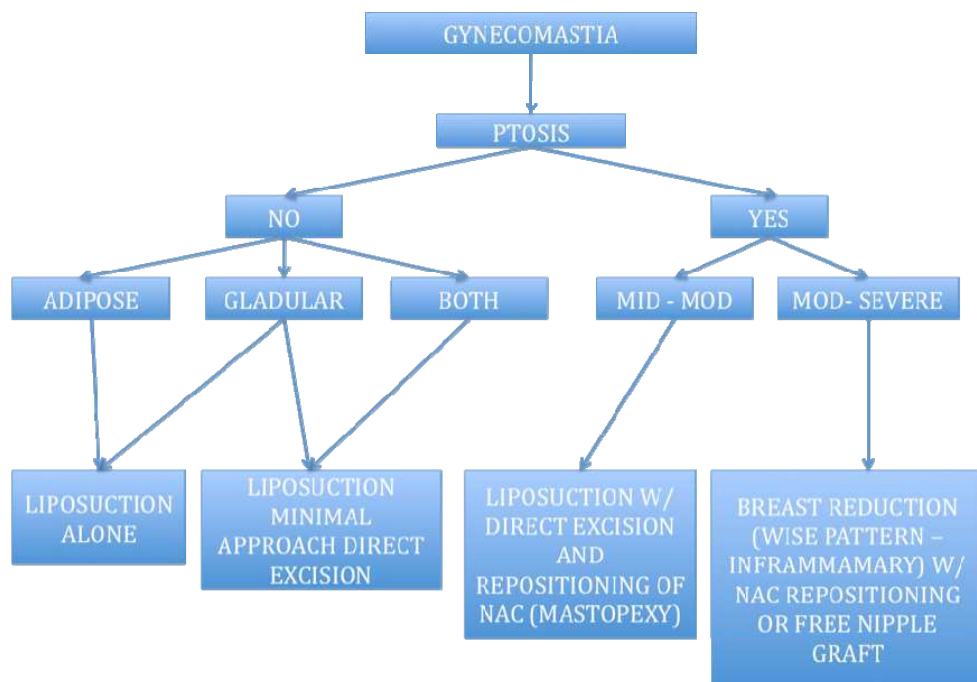


Fig. 1.

### 7.3 New developments

#### *Laser assisted liposuction*

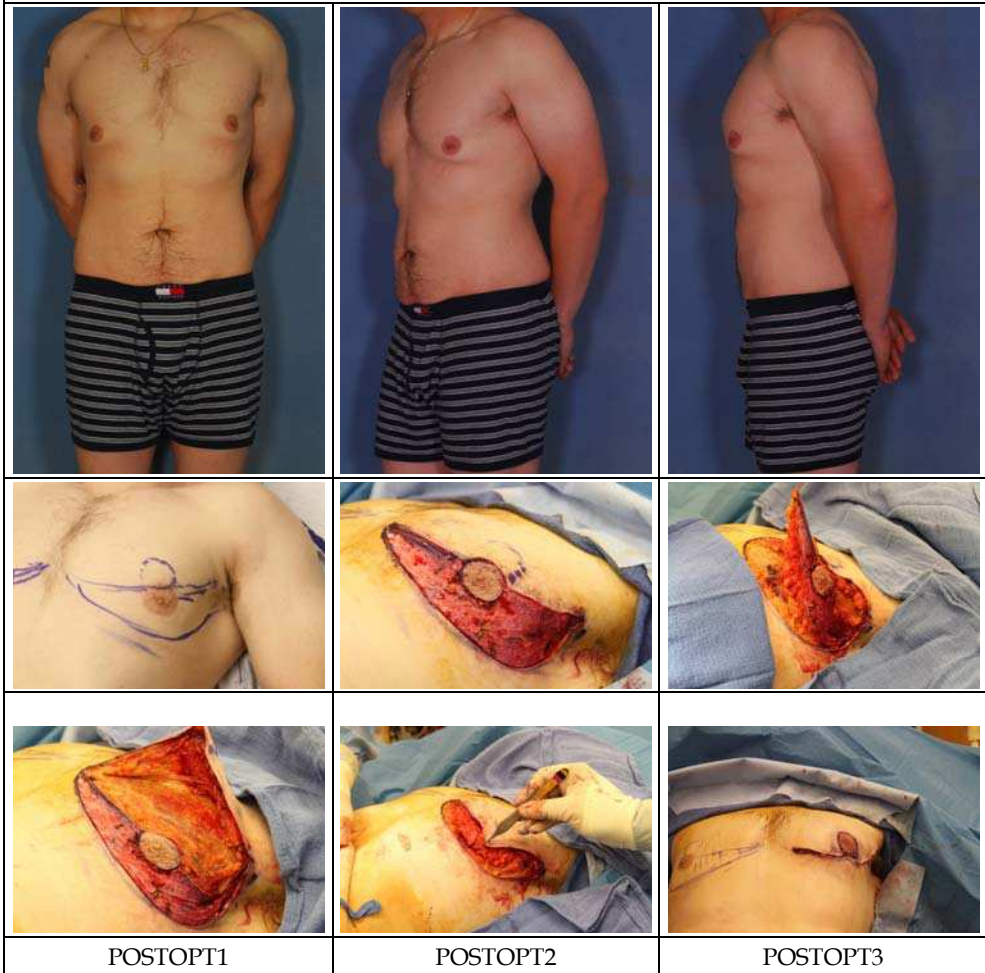
Laser assisted liposuction has been described. The adjunct of laser therapy facilitates the lipolysis process without undue risk. [23, 24]

#### *Dermoglandular repositioning for re-contouring of the masculine chest*

Resection of breast an adipose tissue is not always the answer to gynecomastia. With the new developments and techniques in body contouring a new path for the treatment of gynecomastia has emerged. Some cases of gynecomastia require a reshaping procedure more than an ablative one. Although not yet published, we would like to present a case that illustrates this concept. Case 3. On a weight loss patient with gynecomastia a dermoglandular flap containing the NAC was fashioned and repositioned. The resulting shape of the chest contour shows restoration of the masculine contour of the anterior chest wall, where an ablative procedure would have resulted in a flat appearance.

## Case 3

Grade I gynecomastia with caudal displacement of the NAC following weight loss. Treatment included dissection and repositioning of the NAC based on a dermoglandular flap. Preop intraop and post operative pictures are shown.



### 8. Postoperative care

All patients received compression garment treatment for six weeks to minimize the formation of seromas and avoid dead space. Those patients that undergo a large excision with wide undermining get drained for approximately 10 to 14 days. Patients are advised to refrain from strenuous activity for a period of 4 weeks with a recovery time of 7 to 10 days before returning to regular activities. We strongly believe a compliant postoperative course has a significant impact in speed of recovery and avoidance of complications.

## 9. Complications

The development of seromas is the number one complication. Often times and despite the rigorous measures to avoid seromas the dead space created by liposuction is prone to subsequent accumulation of fluid that needs to be drained during the follow up period. Hematomas are much less frequent with an incidence under 1%. Infection is uncommon but wound healing complications can be a problem, especially in those cases with a large resection and free nipple grafting. The avoidance of undue tension and the use of drain and/or quilting sutures may help to decrease the common misadventures of the postoperative period. Skin necrosis and skin damage from aggressive liposuction, ultrasound liposuction, or arthroscopic shaver use have been reported. These complications are due to technical errors and should be avoided by the use of a consistent and careful technique.

## 10. Conclusion

Gynecomastia is a condition with increase prevalence and the advent of new developments and techniques require a dynamic update to deliver the best possible outcome. Several options are available today to address the different degrees of gynecomastia. The careful analysis of individual patients will permit the selection of the appropriate treatment method to deliver the best result. Psychological guidance plays an important role in the treatment of the condition.

## 11. References

- [1] Georgiadis E, Papandreou L, Evangelopoulou C, Aliferis C, Lymberis C, Panitsa C, Batrinos M: Incidence of gynaecomastia in 954 young males and its relationship to somatometric parameters. *Ann Hum Biol* 1994, 21(6):579-587.
- [2] Niewoehner CB, Nuttal FQ: Gynecomastia in a hospitalized male population. *Am J Med* 1984, 77(4):633-638.
- [3] Nordt CA, DiVasta AD: Gynecomastia in adolescents. *Curr Opin Pediatr* 2008, 20(4):375-382.
- [4] Nydick M, Bustos J, Dale JH, Jr., Rawson RW: Gynecomastia in adolescent boys. *JAMA* 1961, 178:449-454.
- [5] Carlson HE: Gynecomastia. *N Engl J Med* 1980, 303(14):795-799.
- [6] Hands LJ, Greenall MJ: Gynaecomastia. *Br J Surg* 1991, 78(8):907-911.
- [7] Hanavadi S, Banerjee D, Monypenny IJ, Mansel RE: The role of tamoxifen in the management of gynaecomastia. *Breast* 2006, 15(2):276-280.
- [8] Al-Allak A, Govindarajulu S, Shere M, Ibrahim N, Sahu AK, Cawthorn SJ: Gynaecomastia: A decade of experience. *Surgeon* 2011, 9(5):255-258.
- [9] Laron Z, Dickerman Z: Clomiphene in pubertal-adolescent gynecomastia. *J Pediatr* 1978, 92(1):169.
- [10] LeRoith D, Sobel R, Glick SM: The effect of clomiphene citrate on pubertal gynaecomastia. *Acta Endocrinol (Copenh)* 1980, 95(2):177-180.
- [11] Stepanas AV, Burnet RB, Harding PE, Wise PH: Clomiphene in the treatment of pubertal-adolescent gynecomastia: a preliminary report. *J Pediatr* 1977, 90(4):651-653.

- [12] Beck W, Stubbe P: [Excessive gynecomastia in boys. Effective medical treatment using danazol (Winobanin)]. *Monatsschr Kinderheilkd* 1984, 132(1):32-37.
- [13] Beck W, Stubbe P: Endocrinological studies of the hypothalamo-pituitary gonadal axis during danazol treatment in pubertal boys with marked gynecomastia. *Horm Metab Res* 1982, 14(12):653-657.
- [14] Swoboda W, Bohrn E: [Steroid treatment of adolescent gynecomastia with danazol (author's transl)]. *Wien Med Wochenschr* 1981, 131(5):127-132.
- [15] Ting AC, Chow LW, Leung YF: Comparison of tamoxifen with danazol in the management of idiopathic gynecomastia. *Am Surg* 2000, 66(1):38-40.
- [16] Derman O, Kanbur N, Kilic I, Kutluk T: Long-term follow-up of tamoxifen treatment in adolescents with gynecomastia. *J Pediatr Endocrinol Metab* 2008, 21(5):449-454.
- [17] Devoto CE, Madariaga AM, Lioi CX, Mardones N: [Influence of size and duration of gynecomastia on its response to treatment with tamoxifen]. *Rev Med Chil* 2007, 135(12):1558-1565.
- [18] Webster JP: Mastectomy for Gynecomastia Through a Semicircular Intra-areolar Incision. *Ann Surg* 1946, 124(3):557-575.
- [19] Simon BE, Hoffman S, Kahn S: Classification and surgical correction of gynecomastia. *Plast Reconstr Surg* 1973, 51(1):48-52.
- [20] Teimourian B, Perlman R: Surgery for gynecomastia. *Aesthetic Plast Surg* 1983, 7(3):155-157.
- [21] Rohrich RJ, Ha RY, Kenkel JM, Adams WP, Jr.: Classification and management of gynecomastia: defining the role of ultrasound-assisted liposuction. *Plast Reconstr Surg* 2003, 111(2):909-923; discussion 924-905.
- [22] Petty PM, Solomon M, Buchel EW, Tran NV: Gynecomastia: evolving paradigm of management and comparison of techniques. *Plast Reconstr Surg* 2010, 125(5):1301-1308.
- [23] Wollina U, Goldman A: Minimally invasive esthetic procedures of the male breast. *J Cosmet Dermatol* 2011, 10(2):150-155.
- [24] Rho YK, Kim BJ, Kim MN, Kang KS, Han HJ: Laser lipolysis with pulsed 1064 nm Nd:YAG laser for the treatment of gynecomastia. *Int J Dermatol* 2009, 48(12):1353-1359.



## **Current Concepts in Plastic Surgery**

Edited by Dr. Frank Agullo

ISBN 978-953-51-0398-1

Hard cover, 264 pages

**Publisher** InTech

**Published online** 23, March, 2012

**Published in print edition** March, 2012

Plastic surgery continues to be a rapidly growing field in medicine. There have been multiple recent advancements in the field. Specifically, there has been a continuously growing interest in fat grafting, body contouring, minimally invasive surgery, and plastic surgery education. At the same time, there have been continued advances and modifications in surgical techniques, which translate into better and improved results for our patients while increasing safety and efficacy. The title of the book is Current Concepts in Plastic Surgery and, as such, it highlights some of the "hot topics" in recent years. We have invited renowned specialists from around the world to share their valued expertise and experience. Most of the chapters will expose the reader to multiple techniques for achieving desired results, with emphasis on the author's preferred methodology.

### **How to reference**

In order to correctly reference this scholarly work, feel free to copy and paste the following:

Francisco J. Agullo, Sadri O. Sozer and Humberto Palladino (2012). Gynecomastia and Liposuction, Current Concepts in Plastic Surgery, Dr. Frank Agullo (Ed.), ISBN: 978-953-51-0398-1, InTech, Available from: <http://www.intechopen.com/books/current-concepts-in-plastic-surgery/gynecomastia-and-liposuction>

**INTECH**  
open science | open minds

### **InTech Europe**

University Campus STeP Ri  
Slavka Krautzeka 83/A  
51000 Rijeka, Croatia  
Phone: +385 (51) 770 447  
Fax: +385 (51) 686 166  
[www.intechopen.com](http://www.intechopen.com)

### **InTech China**

Unit 405, Office Block, Hotel Equatorial Shanghai  
No.65, Yan An Road (West), Shanghai, 200040, China  
中国上海市延安西路65号上海国际贵都大饭店办公楼405单元  
Phone: +86-21-62489820  
Fax: +86-21-62489821

© 2012 The Author(s). Licensee IntechOpen. This is an open access article distributed under the terms of the [Creative Commons Attribution 3.0 License](#), which permits unrestricted use, distribution, and reproduction in any medium, provided the original work is properly cited.