

From Mouse to Man: Translational Value of Animal Models of Allergic Rhinitis

James G. Wagner and Jack R. Harkema
Michigan State University
USA

1. Introduction

Allergic rhinitis (AR) is the most prevalent atopic disease in the world, affecting 10-20% of the population or up to 600 million people (Asher et al. 2006; Meltzer and Bukstein 2011). Data from multi-year international studies show that the incidence of upper airway allergy is greater than that for asthma, and since 1994 the prevalence of AR has increased more rapidly than allergic asthma (Asher et al. 2006; Weinmayr et al. 2008). The common clinical definition of AR is nasal obstruction, sneezing, rhinorrhea, and pruritus associated with known or suspected allergens. Comorbidity with asthma is common, with 50% to 100% of allergic asthma patients in the United States and Europe reporting AR symptoms (Gaugris et al. 2006). Furthermore, as much as 30% of individuals with AR have lower airway symptoms, such as bronchial hyperreactivity, and AR has emerged as a risk factor for eventually developing asthma (Ciprandi and Cirillo 2006; Ponikau et al. 2003). Because of the frequency of AR coexisting with allergic asthma, a role for common pathophysiologic linkages between asthma and AR has been a focus of discussion among clinical scientists. Comparison of the nasal and bronchial mucosa from allergic airways reveal similar inflammatory and epithelial cell alterations in both tissues, suggesting that common mechanisms of pathogenesis may contribute to each condition (Chanez et al. 1999). Given the clinical and pathologic commonalities of AR and asthma, recent efforts of physicians worldwide has led to Allergic Rhinitis and its Impact on Asthma (ARIA), a collaborative development of diagnostic and therapeutic strategies to treat AR as an asthma risk (Bousquet et al. 2001). A central tenet of ARIA is that AR and asthma represent a “united airway disease” and should be viewed as an interrelated disease with common etiology, features and treatments (Compalati et al. 2010; Marple 2010).

However the inherent differences in the anatomic, morphologic, and functional aspects of nasal versus pulmonary airways result in unique inflammatory and allergic responses in each site. For example, airway obstruction in upper and lower airways occurs by very different mechanisms. Smooth muscle contraction narrows conducting airways in lung, whereas acute vasodilation of vascular tissue limits airflow through nasal airways. Mucus overproduction and hypersecretion may also contribute to airway occlusion and obstruction in both nasal and bronchial airways. Excess mucus such as during rhinorrhea might be more easily cleared from the nose, but mucus plugging in pulmonary airways is a prominent feature associated with mortality in *status asthmaticus*. While the “one-airway” concept may be an attractive paradigm to describe relationships in allergic airways in support of the ARIA framework, differences in clinical opinions for treatment remain (Chipps et al. 2010).

Basic research directed at the study of each condition separately, as well as in tandem, is needed to fully understand the pathophysiology of allergic airways disease. AR is a unique pathophysiological entity that is part of a spectrum of atopic disease including eczema and asthma. The use of relevant animal models of allergic airways disease is necessary to provide the supportive data that defines the extent and nature of AR:asthma relationships. In the last decade, research efforts that focused on animal models of AR have begun to provide a scientific framework with which to understand the role of upper airways in allergic airways disease.

2. Insights from animal models of allergic asthma

Extensive work in susceptible rodent strains using ovalbumin as the test allergen, or environmentally-relevant allergens (e.g., house dust mite, cockroach), has helped describe both the acute and chronic immune and inflammatory responses in pulmonary airways.

The strengths and limitations of laboratory animal models has been debated (Shapiro 2006; Wenzel and Holgate 2006). Studies using mice, especially transgenics and knockout strains, have been important for understanding of the role of cytokines, adhesion molecules, and cell receptors in allergic inflammatory responses. Asthma is a chronic disease of inflammation that is marked by extensive airway remodeling. By comparison, most rodent models of asthma are relatively acute, with regular exposure to allergen challenges over a few days or weeks. As such, the reproduction of the human asthma pathophysiology is not perfect. While airway hyperreactivity, eosinophilic and lymphocytic infiltration, and mucus overproduction can be induced in experimental asthma, other features such as smooth muscle cell proliferation, myofibroblast activation, subepithelial fibrosis, and epithelial proliferation and shedding are often absent in allergic rodent models.

Given the limitations of acute rodent models, efforts to develop chronic asthma models that use frequent exposures to lower allergen concentrations can better portray exposure histories of allergic subjects to seasonal and episodic exacerbations. Specifically, airway remodeling in these mice include key features of human asthma, such as intraepithelial eosinophils, collagen deposition, epithelial hyperplasia and metaplasia, smooth muscle hyperplasia and hypertrophy, and increases in myofibroblasts (Lloyd and Robinson 2007; Nials and Uddin 2008; Yu et al. 2006).

Regardless of the rodent model (mouse, rat or guinea pig), the method to induce allergic responses in lower airways is similar across species and allergens. Primary sensitization to the allergen is accomplished by using either systemic (e.g., intraperitoneal, subcutaneous or dermal) or airway (aerosol inhalation, or instillation in the nose, pharynx, or trachea) routes of exposure, and given as a single or multiple administrations. An adjuvant, usually alum (potassium aluminium sulfate), may also be used. Sensitized animals are then challenged with a secondary exposure by either dermal, inhalation, or airway instillation, and with varying volumes and allergen concentrations or several days or weeks. Several groups have conducted comparisons of the different protocols and determined strengths and limitations of several approaches. (Farraj et al. 2006; Pauluhn and Mohr 2005; Samarasinghe et al. 2011; Southam et al. 2002; Ulrich et al. 2008).

3. Animal models of allergic rhinitis

Preclinical research on allergic airways disease has focused predominately on the lower airways and asthma. By comparison, animal models of AR are relatively underdeveloped and understudied. Until recently, AR models have relied on short-term protocols and

therefore present the same weaknesses of focusing on acute inflammation and less attention on airway remodeling as acute asthma models discussed above. However more effort is being put into developing chronic models to address nasal obstruction, rhinorrhea, and remodeling that define human AR.

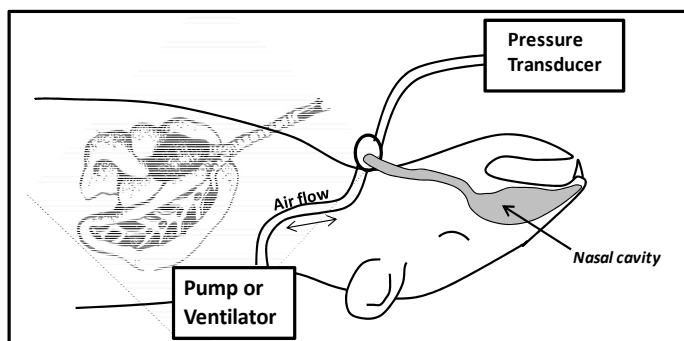
The standard laboratory guinea pig and, to a lesser extent, the Brown Norway rat and BALB/c mouse, have been the primary laboratory animals used to describe nasal responses to allergic stimuli. Occlusion of nasal passages, and the necessity for oral breathing, is the most common complaint from patients with AR. Nasal obstruction in response to an allergic stimulus is characterized by early and late phases of inflammation (Patou et al. 2006; Widdicombe 1990). An immediate and transient episode of itching and sneezing begins within seconds of exposure and lasts for 5 to 30 minutes. A secondary (late) phase is characterized by rhinorrhea and airway obstruction that can last for hours. The initial irritation and sneeze reflex is promoted by preformed mediators released from mast cells and basophils—specifically histamines, tryptase, cysteinyl leukotrienes (cysLTs), and platelet activating factor (PAF). Mucus hypersecretion with airway obstruction during the secondary phase is accompanied by a progression in mucosal swelling, tissue infiltration of eosinophils and neutrophils, and the synthesis and release of prostaglandins, interleukins, and reactive oxygen species (ROS).

In the allergic guinea pig, enumerating the frequency of nasal rubbing and sneezes is a subjective but useful measure, especially for testing the early phase mechanisms and therapies involving histamine- and leukotriene-dependent pathways (Al Suleimani et al. 2006; Szelenyi et al. 2000). For example observers will count between 3-6 sneezes and 6-10 rubbings per minute after acute exposure to allergen (Al Suleimani et al. 2008; Tsunematsu et al. 2007). However, the histopathology associated with nasal obstruction in both early and late phase responses in AR has not been extensively studied. This is in contrast to the detailed descriptions of airway remodeling and pathology that drive analogous responses in lower airways, i.e., early and late bronchoconstriction, which are well-studied in mice. Vasodilation-induced swelling of mucosa, remodeling of mucus-secreting apparatus, fibrosis and inflammatory cell infiltration are potential changes that can be detected in experimental AR. Nasal remodeling that occurs after chronic, multiple challenges to allergen may alter the early responses described above, and provide a more relevant approach to understand the complex pathophysiologic mechanisms in human AR.

3.1 Nasal obstruction in experimental AR

Approaches in humans to assess nasal airflow and acoustic rhinometry are not easily adapted to rodents (Kaise et al. 1999). However, direct and indirect methods have been developed and refined in recent years, which appear to provide a reproducible physiologic approach to determine nasal obstruction. Like direct measures of pulmonary function, invasive approaches are required to obtain direct measures of nasal flows and pressures in laboratory rodents. By retrograde cannulation of the trachea (directed toward the nasopharynx), ventilation patterns used to determine pulmonary function can be applied to the nasal cavity (Figure 1). For example, using the Flexivent system (Scireq, Montreal), direct nasal cavity pressure and flow measurements can be collected in mice during forced oscillation maneuvers using a small animal ventilator (Miyahara et al. 2005). More recently this approach was simplified to use a syringe pump to create flow through the nasal cavity while changes in nasal pressure were detected with a pressure transducer (Xie et al. 2009). Both studies found increased nasal resistance in allergic BALB/c mice without inducing

changes in lower airways. However these are the only two examples of direct resistance measures in experimental AR, and pathological changes were not fully investigated.



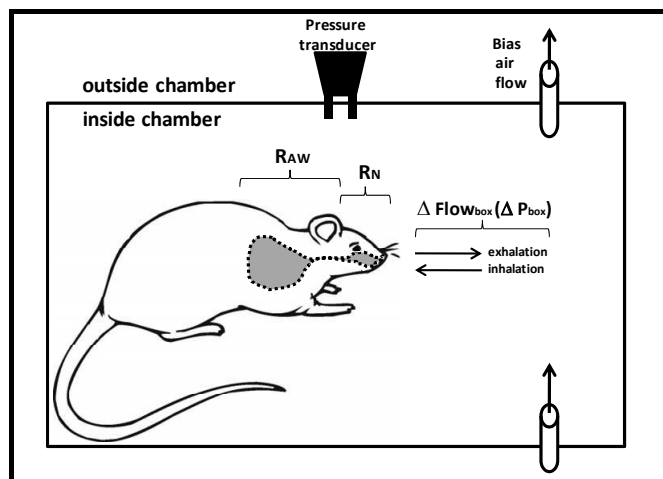
After retrograde cannulation of the trachea and ventilation of the nasal cavity, direct assessment of nasal resistance can be determined in anesthetized laboratory rodents. The lower airways can also be ventilated to determine pulmonary mechanics in the same animal.

Fig. 1. Direct measurement of nasal airway mechanics.

A second method employs a novel use of whole-body plethysmography (WBP) which, in nose-only breathing in rodents, would also detect contributions of flow and pressure changes from the upper airway (Figure 2). WBP has been used extensively to measure lower airway function in allergic rodents, and relies on a unit-less parameter called enhanced pause (Penh), the physiologic meaning has been debated over the last ten years (Bates et al. 2004; Frazer et al. 2011; Lomask 2006; Lundblad et al. 2007). Briefly, part of the derivation of the Penh parameter utilizes the change in the expiratory flow pattern, which some interpret as bronchoconstriction. It has been used to estimate lower airway reactivity in allergic rodents, and therefore a central criticism is that any upper airway obstruction (i.e., nasal) is ignored in the most data interpretations.

Some studies have taken advantage of WBP in rhinitis models where intranasal challenge protocols are designed for allergen delivery to be limited to the nose, and not to reach the deep lung. For example, Nakaya and coworkers measured increases in Penh after intranasal histamine or allergen challenge in allergic BALB/c mice (Nakaya et al. 2006). Although modest pulmonary inflammation was detected, there were no allergen-induced changes in lower airway resistance when analyzed by separate, invasive techniques that bypassed the nose. As such, it was concluded that changes in Penh were due solely to nasal obstruction.

It should be noted that this approach does not address another central criticism of Penh, that it simply represents ventilator timing, rather than airway obstruction. However a separate parameter that is reliably measured by WBP is respiratory frequency. In a series of studies by Miyahara and coworkers, decreased breathing rate in mice has been used as a reliable marker of increased nasal resistance (Miyahara et al. 2008; Miyahara et al. 2006; Miyahara et al. 2005). Respiratory frequency has also been used as an indicator of nasal obstruction in guinea pig models of AR, where it correlated well with histamine-induced airway reactivity (Zhao et al. 2005). Together these findings suggest that respiratory frequency, (i.e., ventilatory timing), is a reasonable indicator of nasal obstruction. An assumption of this model is that the contribution from lower airways or from neurogenic control of breathing is negligible in these rhinitis protocols that exploit WBP.



Total box pressure (P_{box}) fluctuates with the changes in box flow (Flow_{box}) caused by the animal's breathing. Changes in duration of inhalation and expiration are used to calculate enhanced pause (P_{enh}), which has been used as a surrogate for airway resistance (R). Alternatively, respiration rate can be directly measured. Rodents are obligate nose breathers. AR models and their dosing regimens assume that nasal resistance (R_N) is greater than lower airway resistance (R_{AW}). If $R_N \gg R_{AW}$, then changes in P_{enh} or respiration rate are interpreted as an indicator of R_N and of nasal obstruction.

Fig. 2. Whole body plethysmography to estimate nasal obstruction in rodents.

The relevance of AR models, especially using WBP to estimate nasal resistance, is to avoid the involvement of lower airways. Many AR models therefore target the upper airways by minimizing the instilled volume or by conducting intranasal challenges in conscious animals. Kinetic studies show that with instilled volumes of 10 μL or less, 70% of the instillate is retained in the nasal cavity of anesthetized mice, while 15% to 20% reaches the lung (Southam et al. 2002). In conscious mice, nasal retention of instillate can be achieved with volumes as large as 25 μL , where only 5% or less makes it to the lung. Although delivery to the nose is optimized with these approaches, subtle effects in the lung, either direct or indirect, cannot be completely discounted.

As discussed in the introduction to this chapter, the "united airway" hypothesis linking AR to asthma suggests that immunogenic responses in upper and lower airways are connected (Marple 2010; Pawankar 2006). While asthma:rhinitis relationships are clearly evident in clinical and epidemiological studies, reports from animals models are limited and without a consensus mechanism. For example allergen delivery to either upper or lower airways induced localized inflammation in either upper or lower airways, but not both (Li et al. 2005). However, serum eotaxin, interleukin (IL)-5, and eosinophils were equally elevated in all protocols, regardless of preferential inflammation in either nose or lung. In separate studies using mice, lower airway inflammation was dependent on circulating T-helper-2 lymphocytes and adhesion molecule expression (KleinJan et al. 2009). Thus, even with site-specific delivery of airway allergen, circulating cellular and inflammatory mediators associated with AR could affect pulmonary airway reactivity. Circulating cytokines and activated inflammatory cells during both AR and non-allergic are hypothesized to mediate lower airway pathologies, include hyperreactivity (Braunstaal 2009; Hellings and

Prokopakis 2010). As such, the only certain physiologic measure of nasal obstruction in allergic rodents, is to isolate the nasal cavity from the lower airway and perform modified pulmonary function techniques. Though presently in limited use, retrograde ventilation holds the most promise to understand mechanics of upper airway obstruction in rodents. Other techniques that measure only the nasal pressure changes to estimate resistance (Δ pressure/ Δ flow), have also been correlated with allergen-induced AR indicators such as nasal rubbing, sneezes and secretions in guinea pigs (Al Suleimani et al. 2006; Fukuda et al. 2003). While these methods may provide a direct measure of nasal cavity physiology not available by WBP, one limitation is the need for euthanasia after measurements are taken. In addition, some physiological responses in experimental AR may not be relevant for humans. For example, in guinea pigs, allergen-induced nasal resistance was reversed by antihistamines, but not by an adrenergic agonist (McLeod et al. 2002). These results disagree with the ameliorative effects of commonly used vasoconstrictors in humans. In separate studies using allergic mice, nasal resistance was dependent on immunoglobulin (Ig) E-mediated pathways but not on eosinophil accumulation (Miyahara et al. 2005). This result runs counter to the putative, causative role for eosinophils in the late response of airway obstruction (Ciprandi et al. 2004a). Taken together, the current approaches to measuring nasal obstruction show some limitations of acute AR models, and illustrate the need to develop chronic protocols that may better represent human AR.

3.2 Remodeling in experimental AR

In general, animal models of AR are less reported and lack the diversity of experimental animal models of asthma. Most experimental AR protocols range from hours to days of allergen challenge, with at most 12 exposures to allergen before measuring endpoints. These brief treatment regimens are most often designed to test the efficacy of pharmaceutical agents against acute exacerbations, leaving relatively few animal studies that model chronic AR of humans. Although these models have provided important insight into the early and late inflammatory and obstructive responses, accompanying histopathologic descriptions have been either vague or inaccurate.

Like asthma, AR is a chronic disease marked by episodic rounds of inflammation, yet few rodent AR models have been designed to examine long-term alterations and potential airway remodeling of the nasal mucosa. This limitation might easily have been filled, in part, by examining the nose from mice used in a number of well-designed, chronic experimental asthma models (Hirota et al. 2009; Ikeda et al. 2003; McMillan and Lloyd 2004; Yu et al. 2006). Repeated challenge with allergen for weeks or months produces many features of human asthma, including subepithelial fibrosis, smooth muscle and mucus cell hyperplasia, and epithelial exfoliation. In the few chronic experimental AR where histopathological changes are reported, some epithelial and inflammatory responses are consistent with human AR.

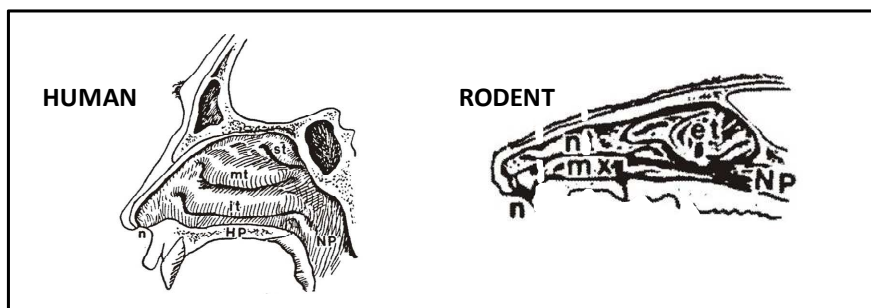
Multiple intranasal ovalbumin challenges in BALB/c mice over 3 months caused time- and challenge-dependent development of subepithelial fibrosis and goblet cell hyperplasia in the proximal aspects of nasoturbinates (Lim et al. 2007). Immunohistochemical detection of matrix metalloproteinase and tissue inhibitors of metalloproteinase was localized to the fibrotic lesions. Transient tissue infiltration of eosinophils occurred at early (1 week), but not later timepoints (1-3 months). Similar associations of decreasing inflammatory cell recruitment with repeated allergen provocation was found in C57BL/6 mice, where airway mucosal remodeling was evident only after 4-8 weeks of challenges, and eosinophil influx

peaked after 2 weeks (Wang et al. 2008). In allergic BALB/c mice that were challenged 3 times a week, goblet cell hyperplasia in lateral walls occurred after 5, but not 2 weeks, and persists through 4 months; by 10 weeks of multiple challenges collagen deposition was evident (Nakaya et al. 2007). Despite the brevity in reports on experimental chronic AR, these studies nonetheless suggest that chronic remodeling of nasal mucosa after repeated exposures is preceded by a transient inflammatory response.

4. Translation to human AR

Translation of experimental results from animal studies to human AR is challenging. The distinct gross structural differences and distribution of epithelium of the rodent and human are important considerations. From a review of the literature, further examples of the limitations of histopathologic comparisons across and within human and experimental AR in animals include 1) inconsistencies in site-specific selection for evaluation, 2) misidentification of nasal anatomy in mice, and 3) the use of subjective quantitative and qualitative analyses (e.g., number of goblet cells versus amounts of stored mucosubstances). Interspecies variability in nasal gross anatomy has been emphasized in previous reviews (Harkema 1991; Harkema et al. 2006). Marked differences in airflow patterns among mammalian species are primarily due to variation in the shape of nasal turbinates. The human nose has three turbinates: the superior (st), middle (mt), and inferior (it) as depicted below in Figure 3.

These structures are relatively simple in shape compared to turbinates in most laboratory animals that have complex folding and branching patterns (Fig. 3). In mice, rats and guinea pigs, evolutionary pressures concerned chiefly with olfactory function and dentition have defined the shape of the turbinates and the type and distribution of the cells lining them. In the proximal nasal airway, the complex nasoturbinates (nt) and maxilloturbinates (mx) of small laboratory rodents probably provide better protection of the lower respiratory tract than the simple middle and inferior turbinates of the human nose. The posterior nasal cavity consists of ethmoturbinates (et) which are lined olfactory epithelium and comprised up to half of the rodent nasal cavity.

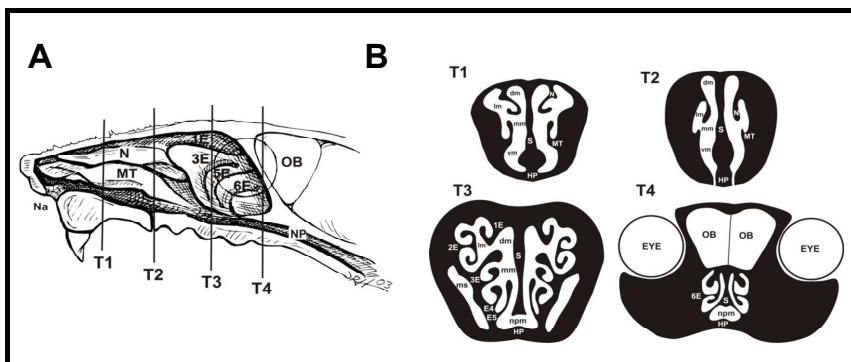


Diagrammatic representation of the exposed mucosal surface of the lateral wall and turbinates in the nasal airways of human and rat. The nasal septum has been removed to expose the nasal passage; illustration are not to scale. et – ethmoturbinates; HP – hard palate; it – inferior turbinate; mt – middle turbinate; mx – maxilloturbinate; n – naris; NP – nasopharynx; nt – nasoturbinate; st – superior turbinate.

Fig. 3. Comparative Nasal Anatomy.

Mucosal swelling in turbinates, especially where they are in close opposition to the septum and lateral wall, can impede both airflow and mucus drainage through the nasal cavity. Another major difference is the distribution of epithelial types in rodents and humans. Approximately 50% of the nasal cavity surface area in rats is lined by sensory neuroepithelium (Gross et al. 1982). By comparison, olfactory epithelium in humans is limited to an area of about 500 mm², which is only 3% of the total surface area of the nasal cavity. The majority of the nonolfactory nasal epithelium of laboratory animals and humans is ciliated respiratory epithelium. Although this pseudostratified nasal epithelium is similar to ciliated epithelium lining other proximal airways (i.e., trachea and bronchi), it also has unique features. Nasal respiratory epithelium in the rat is composed of six morphologically distinct cell types: mucous, ciliated, nonciliated columnar, cuboidal, brush, and basal. We have identified the nasal transitional epithelium, which consists of simple cuboidal cells and lines the proximal airways and maxilloturbinates of rodents, as a sensitive epithelium to undergo metaplastic responses to allergens (Wagner et al. 2002). It is unknown if similar metaplastic changes occur during human AR.

Most of the histopathologic analyses in both humans and rodents have been in regions populated with respiratory epithelium, where the character of the mucus-secreting apparatus and underlying mucosa are evaluated. The anterior portion of the middle and inferior turbinates are common sampling sites for biopsies in humans, partly because of their accessibility (Fig. 3). In rodents, by comparison, analyses are usually in the nasal septum and lateral wall (Figure 4; T1), as well as sites that unfortunately are not clearly identified in the methodological descriptions. The septal mucosa overlies cartilage, whereas the mucosa of turbinates overlies bone. Thus, when responses in respiratory epithelium of laboratory rodents and humans are compared, the surface epithelium may be similar, but the cellularity and vascularization of the underlying mucosa may be quite different and belie inaccurate conclusions with regard to structure/function relationships and its impact on the pathophysiology.



A) Diagrammatic representation of the right nasal passage of the laboratory mouse with the septum removed exposing the nasoturbinat (N), maxilloturbinat (MT), ethmoturbinates (1E-6E), and the nasal pharynx (NP). Lines T1-T4 represent the location of the transverse sections taken for light microscopic examination. B) Anterior face of transverse sections T1-T4. Na, nares; N, nasoturbinat; MT, maxilloturbinat; 1E-6E, six ethmoid turbinates projecting from the lateral wall. HP, hard palate; OB, olfactory bulb of the brain; NP, nasopharynx; DM, dorsal medial meatus (airway); L, lateral meatus; MM, middle meatus; V, ventral meatus; S, septum; MS, maxillary sinus; NPM, nasopharyngeal meatus.

Fig. 4. Anatomic features the rodent nose.

There is no common approach for histologic evaluation by clinicians or by researchers in AR models, and thus comparisons are relatively limited. Veterinary pathologists have proposed a sampling regimen that captures the key anatomical features and epithelial populations in the rodent nose that respond to inhaled materials such as allergens (Young 1981). As depicted in Figure 4, four sampling sites (T1-4), from proximal to distal include respiratory epithelium (mucus-secreting cells) on the septum, nasoturbinates -and maxilloturbinates (T1 and T2 sections), olfactory epithelium in ethmoturbinates (T3), and respiratory epithelium of the nasopharynx (T3-4). Similar sampling strategies for humans have not been proposed, and biopsy are limited to disease and lesion status.

Early analyses of human responses focused on goblet cell enumeration, where modest increases during seasonal AR were not statistically significant (Berger et al. 1997b). Similar modest changes in the epithelial hyperplasia lining the nasal septum after acute allergen challenge has been reported in BALB/c mice (Miyahara et al. 2006) and Brown Norway rats (Wagner et al. 2002). However in the rat model there was a profound increase in the amount of intraepithelial mucosubstances (Wagner et al. 2002), suggesting that hypertrophy and hyperproduction of mucosubstances within individual cells, rather than an increase in mucous cells (hyperplasia), may underlie the hypersecretory mucosa associated with human AR. Supporting this notion are reports of secreted mucosubstances within the nasal lumen of allergic rats (Wagner et al. 2002; Wagner et al. 2008), which parallels the findings of Berger et al. (Berger et al. 1999) who found more actively secreting goblet cells in AR patients than in healthy controls. These features are likely overlooked with routine examination of hemotoxylin and eosin-stained tissue, and can be underestimated if mucus detection relies on only a single stain, rather than both periodic acid-Schiff (PAS) and alcian blue, which stain for neutral and acidic mucosubstances, respectively.

Mucosal and airway recruitment of eosinophils, neutrophils, and mast cells are commonly reported in both experimental and clinical AR (Miyahara et al. 2006; Nakaya et al. 2006; Wagner et al. 2002; Wagner et al. 2008). Furthermore, eosinophils in nasal biopsies or in nasal lavage fluid are highly correlated with most symptoms in AR patients (Ciprandi et al. 2004a; 2004b). Eosinophil products such as nitric oxide, cysteinyl leukotrienes, and interleukins are potential mediators of nasal obstruction (mucosal swelling) and goblet cell secretory responses during AR. However, at least two animal studies have found no causative role for eosinophils in AR responses. Blockade of IL-5 in guinea pigs inhibits eosinophil accumulation in nasal mucosa, but mucus secretion and nasal airway obstruction are unaffected after chronic allergen exposure (Yamasaki et al. 2002). Furthermore, in IgE-receptor-deficient mice, nasal obstruction is independent of eosinophil recruitment into nasal tissues (Miyahara et al. 2005). By comparison, eosinophils are strongly suggested, but not clinically proven to mediate late responses that lead to obstruction in human AR (Ciprandi et al. 2004a; 2004b). Furthermore eosinophil-independent pathways of airway hyperreactivity and mucus cell metaplasia have also been demonstrated in murine asthma models (Humbles et al. 2004; Singer et al. 2002). More studies with chronic models of AR are needed to clarify the role of eosinophils in both allergic asthma and AR.

Histamine-dependent pathophysiological responses initiated by activated mast cells are well defined in AR. Increases in degranulated mast cells are detected and identified in turbinate biopsies from patients with AR (Amin et al. 2001; Berger et al. 1997a). In kinetic studies of the response to allergen provocation in human AR, investigators have reported mast cell migration from the lamina propria into nasal epithelium where degranulation occurs (Fokkens et al. 1992). In allergic guinea pigs by comparison, mast cell migration, but not

increased numbers or degranulation, was detected in the subepithelial mucosa (Kawaguchi et al. 1994). Beyond this example, comparative descriptions of nasal mast cell histopathology are rarely reported in experimental AR models. In a more recent report in a chronic mouse model of fungal AR, descriptions of mast cell kinetics into the epithelium and mucosa are very similar to that found in human AR (Lindsay et al. 2006). Despite the subjective evaluation and misidentification of nasal anatomy, this model reproduces many key features of human AR besides mast cell pathology. Specifically, the lesions include epithelial injury, shedding, invaginations, hyperplasia, and secretions, as well as thickening of lamina propria and progressive infiltration of eosinophils.

5. Paranasal airways

We have recently reported the involvement of paranasal airways in allergic Brown Norway rats that was enhanced by ozone inhalation (Wagner et al. 2009). Eosinophilic infiltrates and mucous cell metaplasia were detected in both the maxillary sinus and nasolacrimal duct, which is the first report of these responses in paranasal structures in experimental AR. Other reports of murine sinusitis models have appeared over the last decade. However most of these studies have been based on inappropriate application of mouse anatomy to human disease. Specifically, the airspaces between the ethmoid turbinates of mice (Figure 3B), have been misinterpreted to be analogous to human ethmoid sinuses (Bomer et al. 1998; Jacob and Chole 2006; Lindsay et al. 2006; Phillips et al. 2009). Ethmoid turbinates in mice do not enclose sinus airways, are lined predominantly by olfactory neuroepithelium, and receive significant airflow (Harkema et al. 2006; Kimbell et al. 1997). By comparison, the ethmoid sinuses of the human nasal cavity are true sinuses lined with respiratory epithelium and receive relatively less airflow. Inflammatory and immune processes in the mucosa underlying these distinct epithelial populations are likely to have different responses. As such caution is advised in the interpretation and design of rhinosinusitis studies, as the translational value of many existing reports from these mouse models is questionable. The rodent possesses a true maxillary sinus analogous to the sinus airways in human, consisting of respiratory epithelium and submucosal secretory glands, and as such is a more suitable structure to assess experimental sinusitis in mice.

6. Conclusions

Observations in human AR provide suggestive evidence that airway remodeling similar to allergic lower airways are also present in the nose, e.g., epithelial damage, basement membrane thickening, mesenchymal changes, eosinophilic infiltrates, mast cell migration, and alteration in the mucus-secreting apparatus (Ponikau et al. 2003; Salib and Howarth 2003). However these findings are inconsistent in rodent models of acute AR. Without a common methodological approach for the collection and analysis of both rodent and human tissues, relevant comparisons and meaningful conclusions will be difficult.

A critical knowledge gap concerns the histopathological changes in the rodent nose that occurs with chronic allergen challenge. Acute protocols have served well to describe inflammatory cell infiltration and reorganization of the mucus-secreting apparatus. It is not clear if the nasal structures in rodent AR exhibit notable tissue remodeling, such as neovascularization in mucosa, collagen deposition, or submucosal gland development. Subepithelial fibrosis can be induced in mouse nasal turbinates after 3 months (Lim et al.

2007), but additional reports in the literature are lacking. In order to provide a more clinically relevant model, more studies are needed that use repeated challenge regimens and extended low-dose exposures, similar to those used in mouse models of chronic asthma.

More systematic approaches need to be applied to the evaluation of nasal pathology in rodents. Strategies for histopathologic analyses should begin by consulting nasal diagrams generated by Mery et al. (Mery et al. 1994), or using the approach proposed by Young (Young 1981). We have recently identified sensitive sites to evaluate respiratory epithelial populations in nasal septum, lateral wall, turbinates, and nasopharynx (Farraj et al. 2003; Wagner et al. 2008). Analysis of the nasolacrimal duct as a sensitive site for allergic rhinoconjunctivitis is virtually absent in rodent models. Similarly, little attention is given to rodent sinus airways during experimental AR, though both structures are easily identified in rodent nasal maps. Many recent sinusitis models are limited by misidentification of nasal structures and irrelevance to human rhinosinusitis. A more thorough approach that combines descriptive and morphometric approaches would strengthen the translational value of animal models of AR. A integrated approach that unifies histopathologic and physiologic data from human and animal AR is needed to understand mechanisms of chronic responses in the allergic nose. Extension and incorporation of existing research on rodent asthma would greatly benefit the design and analysis of rodent models of AR.

7. References

- Al Suleimani M, Ying D, Walker MJ. (2006). A comprehensive model of allergic rhinitis in guinea pigs. *J Pharmacol Toxicol Methods* 55(2):127-134.
- Al Suleimani YM, Dong Y, Walker MJ. (2008). Differential responses to various classes of drugs in a model of allergic rhinitis in guinea pigs. *Pulm Pharmacol Ther* 21(2):340-348.
- Amin K, Rinne J, Haahtela T, Simola M, Peterson CG, Roomans GM, Malmberg H, Venge P, Seveus L. (2001). Inflammatory cell and epithelial characteristics of perennial allergic and nonallergic rhinitis with a symptom history of 1 to 3 years' duration. *J Allergy Clin Immunol* 107(2):249-257.
- Asher MI, Montefort S, Bjorksten B, Lai CK, Strachan DP, Weiland SK, Williams H. (2006). Worldwide time trends in the prevalence of symptoms of asthma, allergic rhinoconjunctivitis, and eczema in childhood: ISAAC Phases One and Three repeat multicountry cross-sectional surveys. *Lancet* 368(9537):733-743.
- Bates J, Irvin C, Brusasco V, Drazen J, Fredberg J, Loring S, Eidelman D, Ludwig M, Macklem P, Martin J, Milic-Emili J, Hantos Z, Hyatt R, Lai-Fook S, Leff A, Solway J, Lutchen K, Suki B, Mitzner W, Pare P, Pride N, Sly P. (2004). The use and misuse of Penh in animal models of lung disease. *Am J Respir Cell Mol Biol* 31(3):373-374.
- Berger G, Goldberg A, Ophir D. (1997a). The inferior turbinate mast cell population of patients with perennial allergic and nonallergic rhinitis. *Am J Rhinol* 11(1):63-66.
- Berger G, Marom Z, Ophir D. (1997b). Goblet cell density of the inferior turbinates in patients with perennial allergic and nonallergic rhinitis. *Am J Rhinol* 11(3):233-236.
- Berger G, Moroz A, Marom Z, Ophir D. (1999). Inferior turbinate goblet cell secretion in patients with perennial allergic and nonallergic rhinitis. *Am J Rhinol* 13(6):473-477.
- Bomer K, Brichta A, Baroody F, Boonlayangoor S, Li X, Naclerio RM. (1998). A mouse model of acute bacterial rhinosinusitis. *Arch Otolaryngol Head Neck Surg* 124(11):1227-1232.


- Bousquet J, Van Cauwenberge P, Khaltaev N. (2001). Allergic rhinitis and its impact on asthma. *J Allergy Clin Immunol* 108(5 Suppl):S147-334.
- Braunstahl GJ. (2009). United airways concept: what does it teach us about systemic inflammation in airways disease? *Proc Am Thorac Soc* 6(8):652-654.
- Chanez P, Vignola AM, Vic P, Guddo F, Bonsignore G, Godard P, Bousquet J. (1999). Comparison between nasal and bronchial inflammation in asthmatic and control subjects. *Am J Respir Crit Care Med* 159(2):588-595.
- Chippis B, Spector S, Farrar J, Carr W, Meltzer E, Storms W, Kaliner M, Luskin A, Bukstein D, Oppenheimer J, Smart B, Derebery J, Harder J, Dykewicz M, Benninger M. (2010). Differences in recommendations between the Allergic Rhinitis and its Impact on Asthma Update 2010 and US Rhinitis Practice Parameters. *Journal of Allergy and Clinical Immunology* 127(6):1640-1641.
- Ciprandi G, Cirillo I, Vizzaccaro A, Milanese M, Tosca MA. (2004a). Airway function and nasal inflammation in seasonal allergic rhinitis and asthma. *Clin Exp Allergy* 34(6):891-896.
- Ciprandi G, Cirillo I, Vizzaccaro A, Milanese M, Tosca MA. (2004b). Correlation of nasal inflammation and nasal airflow with forced expiratory volume in 1 second in patients with perennial allergic rhinitis and asthma. *Ann Allergy Asthma Immunol* 93(6):575-580.
- Ciprandi G, Cirillo I. (2006). The lower airway pathology of rhinitis. *J Allergy Clin Immunol* 118(5):1105-1109.
- Compalati E, Ridolo E, Passalacqua G, Braido F, Villa E, Canonica GW. (2010). The link between allergic rhinitis and asthma: the united airways disease. *Expert Rev Clin Immunol* 6(3):413-423.
- Farraj AK, Harkema JR, Jan TR, Kaminski NE. (2003). Immune responses in the lung and local lymph node of A/J mice to intranasal sensitization and challenge with adjuvant-free ovalbumin. *Toxicol Pathol* 31(4):432-447.
- Farraj AK, Harkema JR, Kaminski NE. (2006). Topical application versus intranasal instillation: a qualitative comparison of the effect of the route of sensitization on trimellitic anhydride-induced allergic rhinitis in A/J mice. *Toxicol Sci* 92(1):321-328.
- Fokkens WJ, Godthelp T, Holm AF, Blom H, Mulder PG, Vroom TM, Rijntjes E. (1992). Dynamics of mast cells in the nasal mucosa of patients with allergic rhinitis and non-allergic controls: a biopsy study. *Clin Exp Allergy* 22(7):701-710.
- Frazer DG, Reynolds JS, Jackson MC. (2011). Determining when enhanced pause (Penh) is sensitive to changes in specific airway resistance. *J Toxicol Environ Health A* 74(5):287-295.
- Fukuda S, Midoro K, Gyoten M, Kawano Y, Ashida Y, Nabe T, Kohno S, Nagaya H. (2003). Effects of TAK-427 on acute nasal symptoms and nasal obstruction in guinea pig model of experimental allergic rhinitis. *Eur J Pharmacol* 476(3):239-247.
- Gaugris S, Sazonov-Kocevar V, Thomas M. (2006). Burden of concomitant allergic rhinitis in adults with asthma. *J Asthma* 43(1):1-7.
- Gross EA, Swenberg JA, Fields S, Popp JA. (1982). Comparative morphometry of the nasal cavity in rats and mice. *J Anat* 135(Pt 1):83-88.
- Harkema JR, Carey SA, Wagner JG. (2006). The nose revisited: a brief review of the comparative structure, function, and toxicologic pathology of the nasal epithelium. *Toxicol Pathol* 34(3):252-269.

- Harkema JR. (1991). Comparative aspects of nasal airway anatomy: relevance to inhalation toxicology. *Toxicol Pathol* 19(4 Pt 1):321-336.
- Hellings PW, Prokopakis EP. (2010). Global airway disease beyond allergy. *Curr Allergy Asthma Rep* 10(2):143-149.
- Hirota JA, Ask K, Fritz D, Ellis R, Wattie J, Richards CD, Labiris R, Kolb M, Inman MD. (2009). Role of STAT6 and SMAD2 in a model of chronic allergen exposure: a mouse strain comparison study. *Clin Exp Allergy* 39(1):147-158.
- Humbles AA, Lloyd CM, McMillan SJ, Friend DS, Xanthou G, McKenna EE, Ghiran S, Gerard NP, Yu C, Orkin SH, Gerard C. (2004). A critical role for eosinophils in allergic airways remodeling. *Science* 305(5691):1776-1779.
- Ikeda RK, Miller M, Nayar J, Walker L, Cho JY, McElwain K, McElwain S, Raz E, Broide DH. (2003). Accumulation of peribronchial mast cells in a mouse model of ovalbumin allergen induced chronic airway inflammation: modulation by immunostimulatory DNA sequences. *J Immunol* 171(9):4860-4867.
- Jacob A, Chole RA. (2006). Survey anatomy of the paranasal sinuses in the normal mouse. *Laryngoscope* 116(4):558-563.
- Kaise T, Ukai K, Pedersen OF, Sakakura Y. (1999). Accuracy of measurement of acoustic rhinometry applied to small experimental animals. *Am J Rhinol* 13(2):125-129.
- Kawaguchi S, Majima Y, Sakakura Y. (1994). Nasal mast cells in experimentally induced allergic rhinitis in guinea-pigs. *Clin Exp Allergy* 24(3):238-244.
- Kimbell JS, Godo MN, Gross EA, Joyner DR, Richardson RB, Morgan KT. (1997). Computer simulation of inspiratory airflow in all regions of the F344 rat nasal passages. *Toxicol Appl Pharmacol* 145(2):388-398.
- KleinJan A, Willart M, van Nimwegen M, Leman K, Hoogsteden HC, Hendriks RW, Lambrecht BN. (2009). United airways: circulating Th2 effector cells in an allergic rhinitis model are responsible for promoting lower airways inflammation. *Clin Exp Allergy* 40(3):494-504.
- Li J, Saito H, Crawford L, Inman MD, Cyr MM, Denburg JA. (2005). Haemopoietic mechanisms in murine allergic upper and lower airway inflammation. *Immunology* 114(3):386-396.
- Lim YS, Won TB, Shim WS, Kim YM, Kim JW, Lee CH, Min YG, Rhee CS. (2007). Induction of airway remodeling of nasal mucosa by repetitive allergen challenge in a murine model of allergic rhinitis. *Ann Allergy Asthma Immunol* 98(1):22-31.
- Lindsay R, Slaughter T, Britton-Webb J, Mog SR, Conran R, Tadros M, Earl N, Fox D, Roberts J, Bolger WE. (2006). Development of a murine model of chronic rhinosinusitis. *Otolaryngol Head Neck Surg* 134(5):724-730; discussion 731-722.
- Lloyd CM, Robinson DS. (2007). Allergen-induced airway remodelling. *Eur Respir J* 29(5):1020-1032.
- Lomask M. (2006). Further exploration of the Penh parameter. *Exp Toxicol Pathol* 57 Suppl 2:13-20.
- Lundblad LK, Irvin CG, Hantos Z, Sly P, Mitzner W, Bates JH. (2007). Penh is not a measure of airway resistance! *Eur Respir J* 30(4):805.
- Marple BF. (2010). Allergic rhinitis and inflammatory airway disease: interactions within the unified airspace. *Am J Rhinol Allergy* 24(4):249-254.

- McLeod RL, Young SS, Erickson CH, Parra LE, Hey JA. (2002). Characterization of nasal obstruction in the allergic guinea pig using the forced oscillation method. *J Pharmacol Toxicol Methods* 48(3):153-159.
- McMillan SJ, Lloyd CM. (2004). Prolonged allergen challenge in mice leads to persistent airway remodelling. *Clin Exp Allergy* 34(3):497-507.
- Meltzer EO, Bukstein DA. (2011). The economic impact of allergic rhinitis and current guidelines for treatment. *Ann Allergy Asthma Immunol* 106(2 Suppl):S12-16.
- Mery S, Gross EA, Joyner DR, Godo M, Morgan KT. (1994). Nasal diagrams: a tool for recording the distribution of nasal lesions in rats and mice. *Toxicol Pathol* 22(4):353-372.
- Miyahara S, Miyahara N, Lucas JJ, Joetham A, Matsubara S, Ohnishi H, Dakhama A, Gelfand EW. (2008). Contribution of allergen-specific and nonspecific nasal responses to early-phase and late-phase nasal responses. *J Allergy Clin Immunol* 121(3):718-724.
- Miyahara S, Miyahara N, Matsubara S, Takeda K, Koya T, Gelfand EW. (2006). IL-13 is essential to the late-phase response in allergic rhinitis. *J Allergy Clin Immunol* 118(5):1110-1116.
- Miyahara S, Miyahara N, Takeda K, Joetham A, Gelfand EW. (2005). Physiologic assessment of allergic rhinitis in mice: role of the high-affinity IgE receptor (FcεRI). *J Allergy Clin Immunol* 116(5):1020-1027.
- Nakaya M, Dohi M, Okunishi K, Nakagome K, Tanaka R, Imamura M, Baba S, Takeuchi N, Yamamoto K, Kaga K. (2006). Noninvasive system for evaluating allergen-induced nasal hypersensitivity in murine allergic rhinitis. *Lab Invest* 86(9):917-926.
- Nakaya M, Dohi M, Okunishi K, Nakagome K, Tanaka R, Imamura M, Yamamoto K, Kaga K. (2007). Prolonged allergen challenge in murine nasal allergic rhinitis: nasal airway remodeling and adaptation of nasal airway responsiveness. *Laryngoscope* 117(5):881-885.
- Nials AT, Uddin S. (2008). Mouse models of allergic asthma: acute and chronic allergen challenge. *Dis Model Mech* 1(4-5):213-220.
- Patou J, De Smedt H, van Cauwenberge P, Bachert C. (2006). Pathophysiology of nasal obstruction and meta-analysis of early and late effects of levocetirizine. *Clin Exp Allergy* 36(8):972-981.
- Pauluhn J, Mohr U. (2005). Experimental approaches to evaluate respiratory allergy in animal models. *Exp Toxicol Pathol* 56(4-5):203-234.
- Pawankar R. (2006). Allergic rhinitis and asthma: are they manifestations of one syndrome? *Clin Exp Allergy* 36(1):1-4.
- Phillips JE, Ji L, Rivelli MA, Chapman RW, Corboz MR. (2009). Three-dimensional analysis of rodent paranasal sinus cavities from X-ray computed tomography (CT) scans. *Can J Vet Res* 73(3):205-211.
- Ponikau JU, Sherris DA, Kephart GM, Kern EB, Gaffey TA, Tarara JE, Kita H. (2003). Features of airway remodeling and eosinophilic inflammation in chronic rhinosinusitis: is the histopathology similar to asthma? *J Allergy Clin Immunol* 112(5):877-882.
- Salib RJ, Howarth PH. (2003). Remodelling of the upper airways in allergic rhinitis: is it a feature of the disease? *Clin Exp Allergy* 33(12):1629-1633.

- Samarasinghe AE, Hoselton SA, Schuh JM. (2011). A comparison between intratracheal and inhalation delivery of *Aspergillus fumigatus* conidia in the development of fungal allergic asthma in C57BL/6 mice. *Fungal Biol* 115(1):21-29.
- Shapiro SD. (2006). Animal models of asthma: Pro: Allergic avoidance of animal (model[s]) is not an option. *Am J Respir Crit Care Med* 174(11):1171-1173.
- Singer M, Lefort J, Vargaftig BB. (2002). Granulocyte depletion and dexamethasone differentially modulate airways hyperreactivity, inflammation, mucus accumulation, and secretion induced by rmIL-13 or antigen. *Am J Respir Cell Mol Biol* 26(1):74-84.
- Southam DS, Dolovich M, O'Byrne PM, Inman MD. (2002). Distribution of intranasal instillations in mice: effects of volume, time, body position, and anesthesia. *Am J Physiol Lung Cell Mol Physiol* 282(4):L833-839.
- Szelenyi I, Marx D, Jahn W. (2000). Animal models of allergic rhinitis. *Arzneimittelforschung* 50(11):1037-1042.
- Tsunematsu M, Yamaji T, Kozutsumi D, Murakami R, Kimura S, Kino K. (2007). Establishment of an allergic rhinitis model in mice for the evaluation of nasal symptoms. *Life Sci* 80(15):1388-1394.
- Ulrich K, Hincks JS, Walsh R, Wetterstrand EM, Fidock MD, Sreckovic S, Lamb DJ, Douglas GJ, Yeaton M, Perros-Huguet C, Evans SM. (2008). Anti-inflammatory modulation of chronic airway inflammation in the murine house dust mite model. *Pulm Pharmacol Ther* 21(4):637-647.
- Wagner JG, Harkema JR, Jiang Q, Illek B, Ames BN, Peden DB. (2009). Gamma-tocopherol attenuates ozone-induced exacerbation of allergic rhinosinusitis in rats. *Toxicol Pathol* 37(4):481-491.
- Wagner JG, Hotchkiss JA, Harkema JR. (2002). Enhancement of nasal inflammatory and epithelial responses after ozone and allergen coexposure in Brown Norway rats. *Toxicol Sci* 67(2):284-294.
- Wagner JG, Jiang Q, Harkema JR, Ames BN, Illek B, Roubey RA, Peden DB. (2008). gamma-Tocopherol prevents airway eosinophilia and mucous cell hyperplasia in experimentally induced allergic rhinitis and asthma. *Clin Exp Allergy* 38(3):501-511.
- Wang H, Lu X, Cao PP, Chu Y, Long XB, Zhang XH, You XJ, Cui YH, Liu Z. (2008). Histological and immunological observations of bacterial and allergic chronic rhinosinusitis in the mouse. *Am J Rhinol* 22(4):343-348.
- Weinmayr G, Forastiere F, Weiland SK, Rzehak P, Abramidze T, Annesi-Maesano I, Bjorksten B, Brunekreef B, Buchele G, Cookson WO, von Mutius E, Pistelli R, Strachan DP. (2008). International variation in prevalence of rhinitis and its relationship with sensitisation to perennial and seasonal allergens. *Eur Respir J* 32(5):1250-1261.
- Wenzel S, Holgate ST. (2006). The mouse trap: It still yields few answers in asthma. *Am J Respir Crit Care Med* 174(11):1173-1176; discussion 1176-1178.
- Widdicombe JG. (1990). Nasal pathophysiology. *Respir Med* 84 Suppl A:3-9; discussion 9-10.
- Xie J, Zhang Q, Lai K, Zhong N. (2009). Measurement of Nasal Airway Resistance and Response in Mice. *Int Arch Allergy Immunol* 151:262-264.

- Yamasaki M, Mizutani N, Sasaki K, Nabe T, Kohno S. (2002). No involvement of interleukin-5 or eosinophils in experimental allergic rhinitis in guinea pigs. *Eur J Pharmacol* 439(1-3):159-169.
- Young JT. (1981). Histopathologic examination of the rat nasal cavity. *Fundam Appl Toxicol* 1(4):309-312.
- Yu M, Tsai M, Tam SY, Jones C, Zehnder J, Galli SJ. (2006). Mast cells can promote the development of multiple features of chronic asthma in mice. *J Clin Invest* 116(6):1633-1641.
- Zhao Y, Woo JK, Leung PC, Chen GG, Wong YO, Liu SX, van Hasselt CA. (2005). Symptomatic and pathophysiological observations in a modified animal model of allergic rhinitis. *Rhinology* 43(1):47-54.



Allergic Rhinitis

Edited by Prof. Marek Kowalski

ISBN 978-953-51-0288-5

Hard cover, 214 pages

Publisher InTech

Published online 21, March, 2012

Published in print edition March, 2012

Allergic rhinitis, while troublesome for a patient, may be also a challenge for the physician. That is why physicians must still learn more on the pathophysiology, clinical spectrum and novel diagnostic and therapeutic approaches to the disease. The chapters of this volume address a variety of important topics related to allergic rhinitis. They begin with a description of innovative translational approaches allowing for unification of animal and human models. Contributing authors provide up-to-date reviews of clinical aspects of allergic rhinitis in children, its association with bronchial asthma and other co-morbid conditions. They also discuss the impact of allergic rhinitis on sleep and sports. Together with articles on diagnostic approaches as well as novel treatments, the book offers a comprehensive and stimulating review of the topic. May this book find a wide readership among allergists and other physicians interested in allergic disease, and also among pediatricians, general practitioners and other specialists who increasingly have to deal with this seemingly benign, but sometimes extremely troublesome, disease.

How to reference

In order to correctly reference this scholarly work, feel free to copy and paste the following:

James G. Wagner and Jack R. Harkema (2012). From Mouse to Man: Translational Value of Animal Models of Allergic Rhinitis, *Allergic Rhinitis*, Prof. Marek Kowalski (Ed.), ISBN: 978-953-51-0288-5, InTech, Available from: <http://www.intechopen.com/books/allergic-rhinitis/from-mouse-to-man-translational-value-of-animal-models-of-allergic-rhinitis>

INTECH
open science | open minds

InTech Europe

University Campus STeP Ri
Slavka Krautzeka 83/A
51000 Rijeka, Croatia
Phone: +385 (51) 770 447
Fax: +385 (51) 686 166
www.intechopen.com

InTech China

Unit 405, Office Block, Hotel Equatorial Shanghai
No.65, Yan An Road (West), Shanghai, 200040, China
中国上海市延安西路65号上海国际贵都大饭店办公楼405单元
Phone: +86-21-62489820
Fax: +86-21-62489821

© 2012 The Author(s). Licensee IntechOpen. This is an open access article distributed under the terms of the [Creative Commons Attribution 3.0 License](#), which permits unrestricted use, distribution, and reproduction in any medium, provided the original work is properly cited.