

Non-Thrombotic Pulmonary Embolism

Vijay Balasubramanian, Malaygiri Aparnath and Jagrati Mathur
University of California, San Francisco, Fresno (UCSF Fresno)
USA

1. Introduction

Pulmonary thrombo-embolism (PTE) remains a common cause of morbidity and mortality worldwide. Annually, as many as 300,000 people in the United States die from acute pulmonary embolism and the diagnosis is often not made until autopsy (Tapson, 2008). Obstruction of the pulmonary artery or one of its branches by material other than thrombi is commonly referred to as Non-thrombotic Pulmonary Embolism (NTPE). The lungs are a prominent target for the embolization of any material larger than approximately 10 microns that gains access to the venous circulation. This includes thrombi, air, amniotic fluid, fat, injected foreign material, and tumor (Fig 1). In comparison with pulmonary thrombo-embolism, NTPE is a less common condition (M. B. King & Harmon, 1994). Its complex and diverse etiologies renders it more difficult to accurate diagnosis and characterization. Therefore, there is a gross scarcity of epidemiologic data pertaining to this group. We speculate that it is often underestimated (both due to under-recognition and under-diagnosis). In contrast to pulmonary thrombo-embolism, the complex and diverse pathogenesis of different subtypes of emboli is subject to continuing speculation and extends beyond “simple” mechanical obstruction of pulmonary vasculature. Non-thrombotic emboli may also be associated with a severe inflammatory response both in the systemic and pulmonary circulation, unlike pulmonary thrombo-emboli.

The diagnosis of NTPE is even more challenging given lack of specific clinical features, heterogeneity of radiographic findings as well as lack of specific laboratory blood tests. Nonetheless, NTPE can be associated with some specific radiographic findings and familiarity with these features should aid in prompt diagnosis (Han et al.,2003). High index of clinical suspicion in the appropriate clinical setting often paves the way to prompt diagnosis. It is important that the correct type of pulmonary emboli be identified, since treatment and prognosis vary considerably. In this chapter, we have summarized the current concepts of various types of NTPE.

2. Fat embolism

Fat Embolism (FE) is by far the most frequent NTPE observed outside the clinical setting of Obstetrics-Gynecology. The term FE refers to the presence of fat globules within the

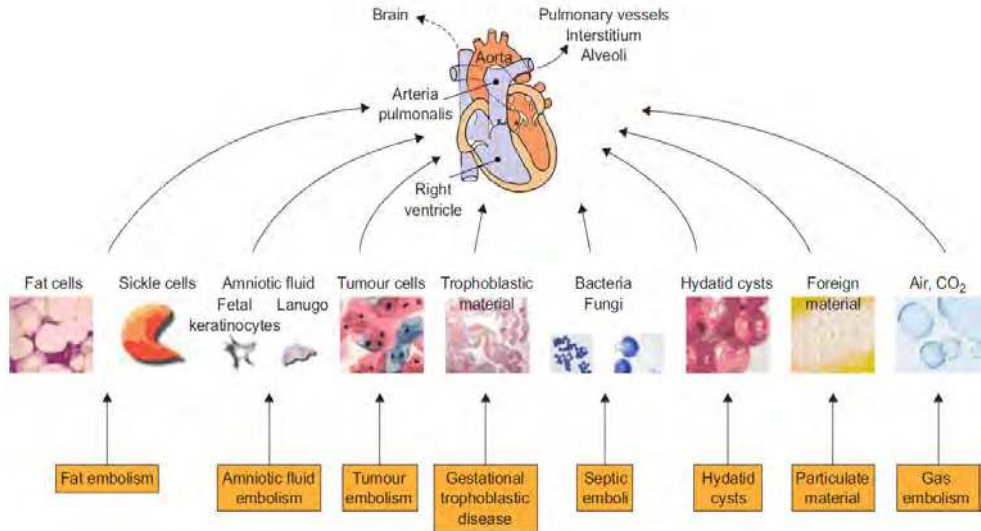


Fig. 1. Different sub-types of NTPE (Reproduced with permission – Jorens et al, ERJ 2009)

peripheral and pulmonary circulation. It can range from being asymptomatic to life threatening respiratory failure with or without neurological and other systemic manifestations often described as Fat Embolism Syndrome (FES).

3. Epidemiology

The reported incidence of FE & FES varies widely in literature. FE occurs in great majority of patients who sustain pelvic or long-bone fractures, endo-medullary nailing of long-bone fractures or placement of knee and hip prosthesis. Embolic showers of circulating fat globules have been demonstrated in up to 41% of patients following surgical nailing of long bone fractures (Talbot & Schemitsch, 2006). However, only a small percentage of these patients develop FES (406th Medical General Laboratory, Professional Section, 1951; Deland, 1956; Gossling & Pellegrini, 1982; Gurd & Wilson, 1974; Koessler et al., 2001; Levy, 1990; Lozman et al., 1986; Palmovic & McCarroll, 1965; Peltier, 1969; Shier & Wilson, 1980; Talbot & Schemitsch, 2006). The incidence of posttraumatic FES can range from 0.25% (Peltier, 1969) to 35% (Gurd & Wilson, 1974; Lindeque et al., 1987; Riska & Myllynen, 1982). The timing of the fracture fixation also appears to impact the incidence of FES. Delayed surgery predisposes to a higher incidence. Non-traumatic FE or FES is rare.

4. Risk factors

Trauma, orthopedic procedures and soft tissue injuries including severe burns are by far the most common causes of FE and FES. FES is more likely to develop after pelvic or lower extremity fractures; it is seldom observed in patients with isolated upper extremity fractures.

Characteristics	Comments
Age: 10-40 years - peak incidence Sex : M > F	<ul style="list-style-type: none"> • Physically most active age group - higher risk of trauma • Children <10 yrs old: lower fat and olein content of the bone marrow (hence, less likely to develop FES) • Elderly : low impact fractures, mostly single fracture, mainly involving the neck of the femur thus less intramedullary pressure and less marrow is available for embolization.
Location of fracture(s) in order of incidence: <ul style="list-style-type: none"> • Lower extremity and/or pelvic • Upper extremity • Rib & vertebrae 	Femur (excluding neck) is the single most common site
Number of fracture(s) Multiple > single	More marrow is available for embolization
Type of fracture Closed > open	Higher pressure is more likely to develop in closed than open (Dedhia & Mushambi, 2007; ten Duis et al., 1988; Thomas & Ayyar, 1972).

Table 1. Traumatic Fat Embolism - Factors predisposing to FES among Trauma patients

5. Non-traumatic fat embolism

Non traumatic Fat embolism or FES is rare and overall incidence is extremely low (Stein et al., 2008). It can be divided into three categories.

- Procedures related (Table-2)
- Diseases related (Table-3)
- Drugs related (Table-4)

6. Non orthopedic procedures associated with fat embolization. (Table-2)

Soft tissue filling	(Coronado-Malagon et al., 2010)
Bone marrow transplantation	(Bulger et al., 1997; Hasan et al., 2001; Jenkins et al., 2002; Lipton et al., 1987; Robert et al., 1993)
Renal transplantation	(Jones et al., 1965; Lipton et al., 1987)
Lipectomy	(Laub & Laub, 1990)
Autologous fat harvesting	(Currie et al., 1997)
Periurethral injection	(Currie et al., 1997)
Lymphangiography	(Francis et al., 1983)
Mineral oil enemas	(Rabah et al., 1987)
Injection of rice bran oil into breasts	(Kiyokawa et al., 1995)
Cardiopulmonary resuscitation	(Buchanan & Mason, 1982; Bulger et al., 1997; Jackson & Greendyke, 1965; Jenkins et al., 2002; Robert et al., 1993)
Liposuction	Bulger et al., 1997; Guardia et al., 1989; Jenkins et al., 2002; M. B. King & Harmon, 1994; Laub & Laub, 1990; Platt et al., 2002; Richards, 1997; Robert et al., 1993; R. M. Ross & Johnson, 1988)
Intraosseous fluid and drug administration	(Hasan et al., 2001; Vichinsky et al., 2000)
Extracorporeal circulation such as extracorporeal membrane oxygenation or cardiopulmonary bypass	(Akhtar, 2009; Bulger et al., 1997; Gravante et al., 2008; Jenkins et al., 2002; M. B. King & Harmon, 1994; Richards, 1997; Robert et al., 1993; ten Duis, 1997)

Table 2. Procedures related

7. Conditions associated with fat embolization (Table-3)

Pancreatitis	(Bulger et al., 1997; Godeau et al., 1996; Goldhaber, 2004; Guardia et al., 1989; Jenkins et al., 2002; M. B. King & Harmon, 1994; Lynch, 1954; Richards, 1997; Robert et al., 1993)
Panniculitis	(Goldhaber, 2004)
Osteomyelitis	(Broder & Ruzumna, 1967; Goldhaber, 2004; M. B. King & Harmon, 1994; Richards, 1997; Wagner, 1865)
Sickle cell crisis	(Bulger et al., 1997; Goldhaber, 2004; Hutchinson et al., 1973; Jenkins et al., 2002; M. B. King & Harmon, 1994; Richards, 1997; Robert et al., 1993)
Alcoholic fatty liver	(Goldhaber, 2004)
Liquefying subcutaneous hematoma	(Jorens et al., 2009)
Viral hepatitis in pre-existing fatty liver	(Schulz et al., 1996)
Bone tumor lysis	(Weinhouse, January 2011)
Burns	(Bulger et al., 1997; Jenkins et al., 2002; M. B. King & Harmon, 1994; Levy, 1990; Patil & Wakankar, 2008; Richards, 1997; Robert et al., 1993; Weisz, 1974)
Decompression sickness	(Bulger et al., 1997; Haymaker & Davison, 1950; Jenkins et al., 2002; M. B. King & Harmon, 1994; Ober et al., 1959; Richards, 1997; Robert et al., 1993)
Diabetes mellitus	(Cuppige, 1963; M. B. King & Harmon, 1994; Richards, 1997; Weinhouse, January 2011)

Table 3. Diseases related

8. Drugs associated with fat embolization (Table-4)

Cyclosporine A solvent	(Weinhouse, January 2011)
Carbon tetrachloride poisoning	(Macmahon & Weiss, 1929; Taviloglu & Yanar, 2007)
Infusion of lipids at a rate greater than normal clearing capacity, i.e. 3.8 gm/kg/day,	(Bulger et al., 1997; Haber et al., 1988; Jenkins et al., 2002; Kitchell & Balogh, 1986; Rayburg et al., 2010; Ritter et al., 1997; Robert et al., 1993)
Intraosseous fluid and drug administration	(Hasan et al., 2001; Vichinsky et al., 2000)
Corticosteroids	(Bulger et al., 1997; Jenkins et al., 2002; Robert et al., 1993; Weinhouse, January 2011)

Table 4. Drugs related

In view of the large number of patients who are treated with liposome-embedded drugs, reports of fatal FE caused by intravenous liposome drug delivery or intra-venous hyperalimentation are debatable (Kitchell & Balogh, 1986; Tolentino et al., 2004).

Pathophysiology of FES remains unknown. Two main theories, namely mechanical and biochemical, dominate the literature and have gained acceptance (Bulger et al., 1997; Choi et al., 2002; Mellor & Soni, 2001; Parisi et al., 2002).

9. Mechanical hypothesis

Gauss first proposed the mechanical theory of fat embolization which requires that large fat cells in the bone marrow rupture into the venous circulation through torn venules at the fracture site in the setting of a favorable pressure gradient (increased intra-medullary pressure). These fat globules subsequently embolize to the lungs and obstruct the pulmonary capillaries (Gauss, 1924). Systemic embolization takes place via intra-cardiac shunts or PFO. Small fat droplets (7-10 micrometers) can pass through pulmonary capillaries (Parisi et al., 2002) causing systemic embolization in the absence of anatomic shunt. The clinical picture is dictated by the extent of the organ(s) involved. However, mechanical theory does not explain the following observations:

- Not all patients who have fat emboli develop FES (Aoki et al., 1998)
- "Latent period": from the time of onset of injury to the onset of symptoms and signs of FES
- Non-Traumatic causes of FES

Therefore factors other than mechanical obstruction must be playing a role which led to the biochemical hypothesis.

10. Biochemical hypothesis

In 1927, Lehman and Moore first postulated that a substance exists that causes destabilization of the emulsion of chylomicrons in the bloodstream with coalescence of fat

stores in response to stress and catecholamine release (Lehman & Moore, 1927). Currently the most widely held view is that there is physiochemical alteration leading to degradation of embolized fat and production of toxic intermediates—mainly Free Fatty Acids (FFAs). Circulating FFAs originating from triglycerides at the fracture site may become concentrated as a result of systemic lipolysis induced by catecholamines. Alternatively, fat emboli trapped in pulmonary vessels may be metabolized to FFAs and glycerol by lipase secreted by lung parenchymal cells (P. L. Baker et al., 1971). However the exact source of FFAs remains unknown. Regardless of the source of the FFAs, circulating FFAs level is elevated in patients with fractures and in animal models of nontraumatic fat embolism. It has been postulated that decreased hepatic clearance as in shock, sepsis, or decreased plasma concentration of albumin also increase the risk of FES (Mays, 1970; Moylan et al., 1976). FFAs have been shown in both animal and human studies to have the following systemic effects

- Toxicity to lung parenchyma:
 - capillary leak
 - curtailed surfactant production
 - interstitial hemorrhage and pulmonary edema (Herndon, 1975; Parker et al., 1974; Szabo et al., 1977)
- Cerebral cortical cell damage (Parisi et al., 2002)
- Cardiac contractile dysfunction (Dedhia & Mushambi, 2007; Hulman, 1988b)
- C-reactive protein which is elevated in these patients appears to interact with circulating chylomicrons to form fat globules **de novo**, which can explain non traumatic fat embolism (Hulman, 1988a).

Coagulation cascade activation, disseminated intravascular coagulation (DIC), and antifibrinolytic pathways may further contribute to lung injury (E. G. King et al., 1971; Saldeen, 1970). The biochemical theory, could explain “latent period” and nontraumatic forms of FES (Schnaid et al., 1987). It must be emphasized that evidence is largely circumstantial and the exact pathophysiological mechanism responsible for FES remains unknown.

11. Clinical features

FES usually presents as multisystem disorder in the setting of long bone fracture(s) or major trauma. The most commonly affected organs are brain and lung. The presentation is heterogeneous given diverse causes as well as multi-organ involvement. Latent period is typically 12 to 72 hours although rarely it can be as short as few hours in the setting of major trauma or as long as 2 weeks (Gary, 2004; Johnson & Lucas, 1996; M. B. King & Harmon, 1994; Mellor & Soni, 2001; Moreau, 1974; Parisi et al., 2002; Peltier, 1984; Schonfeld et al., 1983; Shier & Wilson, 1980). 85% of patients will develop signs and symptoms within 48 hours of injury (Sevitt, 1962). The classic triad of hypoxemia, neurological dysfunction and petechial rash is seen in only about 50% of the patients.

12. Pulmonary

It is uncommon to develop FES in the absence of respiratory manifestations. A great majority of patients present with varying degrees of respiratory insufficiency that can range from nearly asymptomatic hypoxemia to severe hypoxemia and ARDS requiring mechanical

ventilation (Bernard et al., 1994). The most “fulminant” form of FES presents as “acute cor pulmonale” with respiratory failure causing death within a matter of few hours, usually after a major trauma (Mellor & Soni, 2001; Parisi et al., 2002; Peltier, 1984; Schonfeld et al., 1983). Although frequently clinically inapparent, hypoxemia is nearly universal (Peltier et al., 1974; A. P. Ross, 1970).

13. Central nervous system

Neurological findings are nonspecific and usually completely reversible. They can range from anxiety and restlessness to comatose state requiring mechanical ventilation. The early signs and symptoms are delirium, restlessness, confusion or anxiety. Diffuse encephalopathy and coma can ensue (Jacobson et al., 1986). Focal neurological deficits are common. These findings are frequently not responsive to correction of hypoxemia (Metting et al., 2009) and have infrequently been observed in absence of pulmonary involvement.

14. Skin

The characteristic petechial rash has been reported to be present in about 50% to 60% of patients with FES. Upper anterior torso, axillae, neck, upper arm, conjunctivae and oral mucosa are usual sites. The rash is NOT due to thrombocytopenia but from fat emboli obstructing capillaries and causing capillary damage and subsequent hemorrhages. The petechial rash may be the only physical sign.

15. Eye

Retinopathy has been reported in up to 50% of patients (Adams, 1971). Fundoscopic findings (Kearns, 1956) include macular edema, cotton-wool spots, retinal hemorrhages and occasional fat droplets. The findings are attributed to microvascular injury in the form of microinfarcts of retina which usually disappear with possible residual scotomas.

16. Cardiovascular

Tachycardia is invariably present. Hemodynamic changes include: (Aebli et al., 2005; Krebs et al., 2007; Murphy et al., 1997)

- Increase in pulmonary arterial pressure due to not only mechanical obstruction from fat embolism but also from pulmonary vasoconstriction.
- Reduction in systemic arterial pressure
- Reduction in cardiac output
- Arrhythmias

Cardiovascular deterioration is often transient but can be fulminant resulting in severe cardiac failure, cardiac arrest and even death.

Other findings: Rarely severe hypocalcemia leading to tetany has been reported (Gurd & Wilson, 1974). Jaundice/icterus can be present. Hematological findings include anemia, thrombocytopenia and DIC (Dines et al., 1972; Herndon, 1975; Hulman, 1988b; McCarthy et

al., 1973; Peltier, 1984; Peltier, 1988). Elevation of ESR & CRP, presence of fat globules in the urine, sputum or blood, elevation of serum lipase and phospholipase A2 have been described.

17. Role of Bronchial Alveolar Lavage (BAL)

Presence of lipid inclusions in alveolar macrophages in the BAL has been associated with various traumatic and nontraumatic conditions, especially aspiration pneumonia and lipid infusion. Quantification of cells containing fat droplets in bronchial alveolar lavage (BAL) fluid within the first 24 hours after trauma have also been shown to correlate with clinical fat embolism in some studies) (Al-Khuwaitir et al., 2002; Chastre et al., 1990; Mellor & Soni, 2001; Mimoz et al., 1995). In the absence of an exogenous source of fat, BAL fluid that contains more than 30% macrophages laden with lipid inclusions is highly suggestive of FES.

18. Imaging

The findings are nonspecific and appear after a variable lag period as related to clinical symptoms. Chest roentgenogram may reveal diffuse evenly distributed alveolar and interstitial densities suggestive of pulmonary edema or acute lung injury. Computed tomography (CT) of the chest may rarely show fat in the pulmonary artery. Multiple sub-centimeter, ill-defined centrilobular and subpleural nodules can be seen in the acute phase of FES. Diffuse lung calcifications located in the branches of the pulmonary arteries have been described in the late course of FES (Hamrick-Turner et al., 1994). Ventilation perfusion scan (V/Q scan) may reveal subsegmental perfusion defects (H. M. Park et al., 1986).

Computed tomography (CT) of the brain may show nonspecific signs of cerebral edema and hemorrhagic infarcts in multiple areas (Meeke et al., 1987). Magnetic resonance imaging (MRI) of the brain and MR spectroscopy seem to be the most sensitive method in detection of cerebral emboli, but nonspecific (J. J. Chen et al., 2008; Eguia et al., 2007; Guillevin et al., 2005; Sasano et al., 2004; Satoh et al., 1997; Stoeger et al., 1998). Diffusion-weighted imaging may reveal bright spots on a dark background, a finding known as the "Starfield pattern" (Parizel et al., 2001). Cerebral micro-emboli can be detected in vivo after long bone fracture by transcranial Doppler (Barak et al., 2008; Forteza et al., 1999).

Transesophageal Echo (TEE) is most useful for diagnosing intra-operative FES. TEE has sensitivity of 80% and specificity of 100% in patients with fat embolism large enough to cause hemodynamic instability (Pruszczyk et al., 1997). TEE cannot reliably distinguish fat emboli from tumor emboli.

19. Diagnosis

Given the extremely heterogeneous pattern of presentation, precise diagnosis of FES remains elusive. Various diagnostic criteria have been proposed. However given the lack of gold standard diagnostic tests and lack of pathognomic signs, it is difficult to determine validity of these criteria. Therefore the diagnosis of FES is based on a constellation of clinical and laboratory findings and exclusion of other potential diagnoses (Taviloglu & Yanar, 2007).

The following diagnostic criteria are widely used.

Major	Minor
<ul style="list-style-type: none"> • Respiratory insufficiency • Cerebral involvement • Petechial rash 	<ul style="list-style-type: none"> • Pyrexia • Tachycardia • Retinal changes • Jaundice • Renal changes (anuria or oliguria) • Thrombocytopenia (a drop of >50% of the admission platelet count) • High erythrocyte sedimentation rate • Fat macroglobulinemia

Table 5. Gurd and Wilson: FES = 1 major + 4 minor + Fat microglobulinemia

Criterion	Points
Diffuse petechiae	5
Alveolar infiltrates	4
Hypoxemia <70 mm Hg	3
Confusion	1
Fever 38 C	1
Heart rate >120/min	1
Respiratory rate >30/min	1

Table 6. Schonfeld's criteria - FES = 5 or more points

20. Management

There is no definitive therapy for FES. The treatment is mainly supportive. Maintenance of adequate oxygenation, ensuring hemodynamic stability, prophylaxis of venous thrombosis and stress related gastrointestinal bleeding and nutrition are key aspects. Therefore clinical management strategies should be geared towards prophylactic measures in trauma victims. Early stabilization of the fractures as well as early operative intervention reduces the incidence and severity of FES (Al-Khuwaitir et al., 2002; A. B. Baker, 1976; Bone et al., 1989; Jenkins et al., 2002; Johnson & Lucas, 1996; Parisi et al., 2002; Riska et al., 1976; Riska & Myllynen, 1982; Svenningsen et al., 1987; Tachakra et al., 1990; Talucci et al., 1983). Early (< 24 hours) fixation of the fracture of the femur was associated with an improved outcome even in patients with concomitant head and chest trauma (Brundage et al., 2002). When fracture stabilization was delayed in patients with multiple injuries, the incidence of ARDS, FE and pneumonia, the costs of hospital care and the number of days in the intensive care unit (ICU) were increased (Behrman et al., 1990; Bone et al., 1989). Intraosseous pressure limitation during orthopedic procedures reduces the intravasation of intramedullary fat and other debris and therefore may reduce the incidence and severity of FES (Y. H. Kim et al., 2002; Kropfl et al., 1999; Pitto et al., 1999; Pitto et al., 2002; Pitto, Schramm et al., 1999). Incidence and severity of FES are decreased when corticosteroids are given prophylactically, although no mortality benefit has been demonstrated (Alho et al., 1978; Bederman et al.,

2009; Kallenbach et al., 1987; Lindeque et al., 1987; Schonfeld et al., 1983). Nonetheless, prophylactic use of corticosteroids remains controversial mainly because of lack of large scale studies. The results of treatment with drugs, including clofibrate, dextran-40, ethyl alcohol, heparin, and aspirin are inconclusive (K. M. Chan et al., 1984; Gossling & Pellegrini, 1982; Peltier, 1984; Shier et al., 1977; Stoltenberg & Gustilo, 1979).

21. Prognosis

With timely supportive care and hemodynamic support, most patients with FES recover completely. Mortality rate has been variably reported to be 10 to 20% (Fabian et al., 1990; Moreau, 1974; Peltier, 1965; Peltier et al., 1974).

22. Septic pulmonary embolism

Septic pulmonary embolism (SPE) is an uncommon but serious disorder that is often difficult to diagnose. SPE are thrombi containing microorganisms in a fibrin matrix that are mobilized via the bloodstream from an infectious nidus to get implanted into the vascular system of the lungs. The organisms can be bacteria, fungi or parasites.

23. Epidemiology

In 1978, MacMillan et al. (MacMillan et al., 1978) studied 60 patients with SPE over a 5-year period and reported that most of SPE cases occurred in drug users. Intravenous drug abuse (IVDA-78%) and tricuspid endocarditis were identified as the embolic source in 53% of these IVDA cases (fig 2b) (MacMillan et al., 1978). However, the epidemiology and outcome of patients with SPE have changed over the past 30 years with the increased use of long term indwelling catheters and devices (pacemakers, prosthetic vascular devices) and also increase in the number of immune-compromised patients. The predominant cause of SPE in the current era is infections related to intravascular devices/catheters or soft-tissue infections. Its incidence is declining among IVDA presumably due to greater needle hygiene (Fig 2a) (Cook et al., 2005). Intravascular devices are a common cause of local site infection and cause up to 50% of the nosocomial bacteremias. Central venous catheters account for 80-90% of these infections.

In a large series of postmortem examinations in Japan, a total of 11,367 PE cases were identified from 396,982 postmortem examinations. In this study, the incidence of septic PE was found to be 2.2% (Sakuma et al., 2007).

24. Risk factors

A prerequisite for the development of SPE appears to be a heavily infected source such as long-term indwelling vascular devices, bacterial endocarditis of the right heart valves or peripheral thrombophlebitis (head and neck or pelvic infections) leading to showers of septic emboli to the lung. In the above-mentioned recent Japanese study with 247 SPE patients, fungal emboli were more common than bacterial emboli. Among the fungi, *Aspergillus* was the most common pathogen (20.8%) encountered preceding *Mucor* or *Candida*. Cancer was the most common predisposing factor associated with fungal SPE (63%) - Leukemia (43.2%), followed by adenocarcinoma and lymphoma. The top three infectious sources showering septic emboli were pneumonia, sepsis and infective endocarditis.

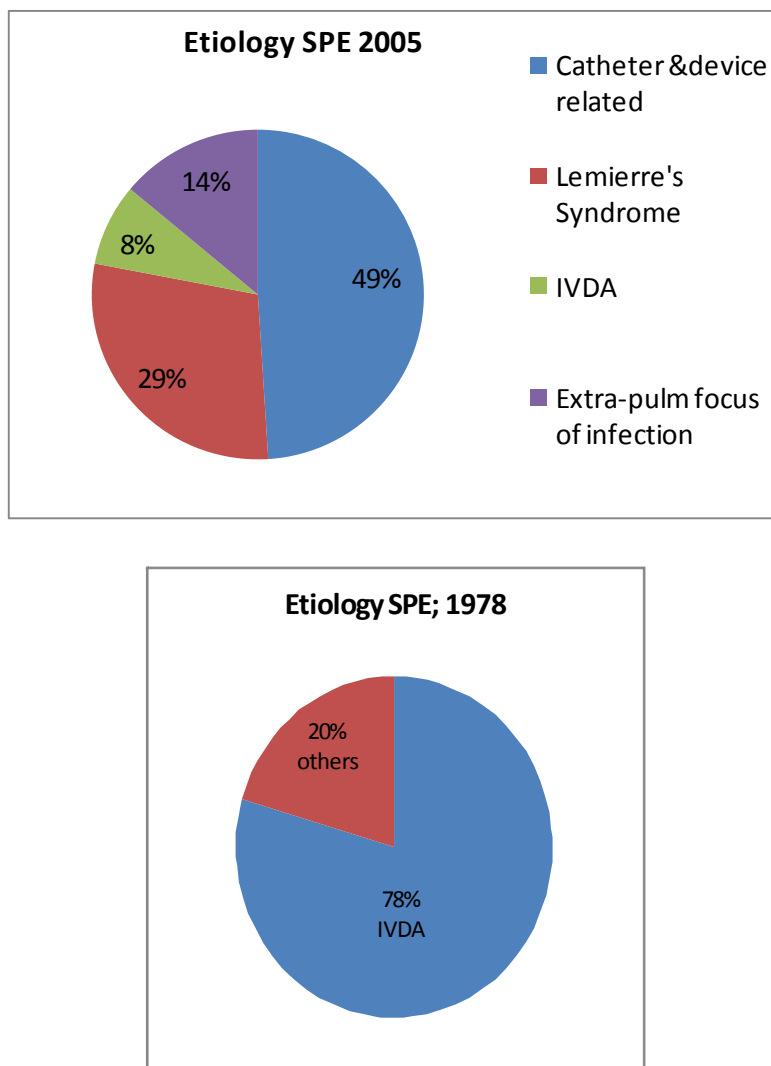


Fig. 2. (a & b): Causes of Septic Pulmonary Embolism (Cook et al., 2005; MacMillan et al., 1978)

25. Pathophysiology

Septic emboli are transported to the lung via the hematogenous route from various sources of infection. These emboli cause occlusion of the small, peripheral pulmonary arteries leading to pulmonary infarction which could further complicate to microabscesses. Extravasation from the bronchial arteries - "pulmonary hemorrhages", may cause peripheral consolidation. (Fig 3- Flow chart).

A peculiar subtype is Lemierre's syndrome (postanginal sepsis), a severe illness caused by the anaerobic bacterium, *Fusobacterium necrophorum* which typically occurs in healthy teenagers and young adults. The infection originates in the throat as tonsillo-pharyngitis, odontogenic infection, mastoiditis or sinusitis and spreads via a septic thrombophlebitis of the tonsillar vein and internal jugular vein. The ensuing bacteremia is complicated by septic emboli to a range of sites such as lung, joints, and bones. Pulmonary involvement in Lemierre's syndrome has been reported in up to 97% with SPE, lung abscesses and empyema (Golpe et al., 1999; Riordan & Wilson, 2004; Sinave et al., 1989). The causative organisms of Lemierre's syndrome include the anaerobic gram-negative *Fusobacterium* species, and also *Eikenella*, *Porphyromonas*, *Streptococci* and *Bacteroides*. Recently, methicillin-resistant *Staphylococcus aureus* has been identified as a new causative agent (Riordan & Wilson, 2004).

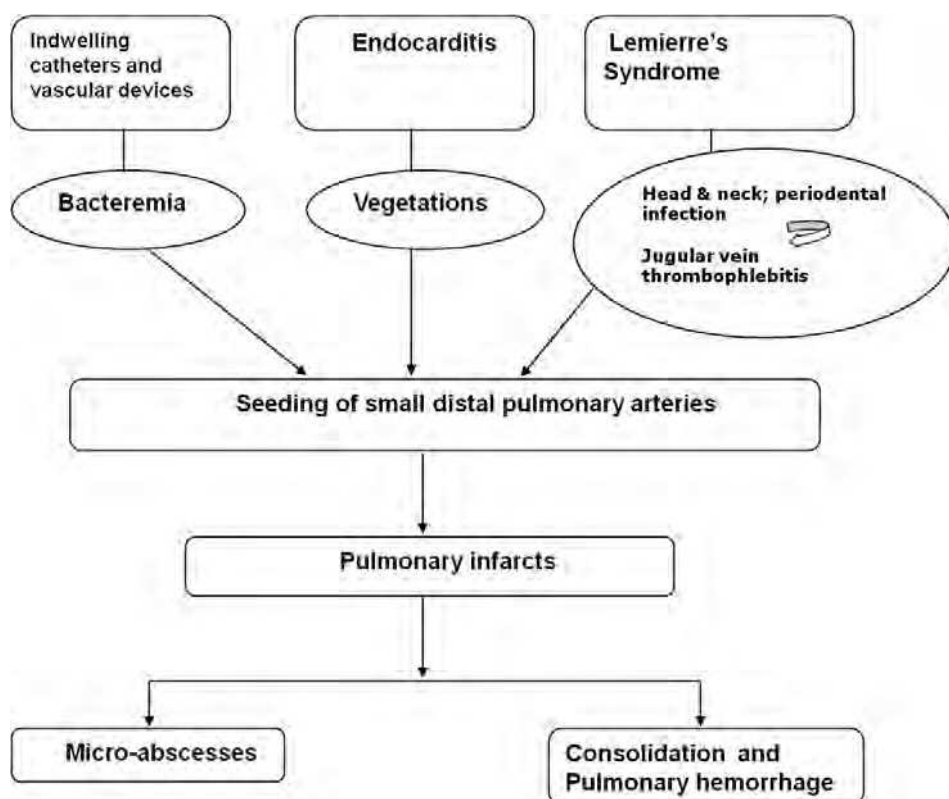


Fig. 3.

26. Clinical features

The clinical features of SPE are non-specific and patients generally present with a febrile illness, cough, hemoptysis, dyspnea and pleuritic chest pain. Diffuse cavitory lung nodules and infiltrates associated with an active focus of extra-pulmonary infection should clue the

clinician into thinking about a diagnosis of SPE. Other pulmonary complications of SPE include pleural effusion, empyema, and rupture of subpleural lesions leading to spontaneous pneumothorax.

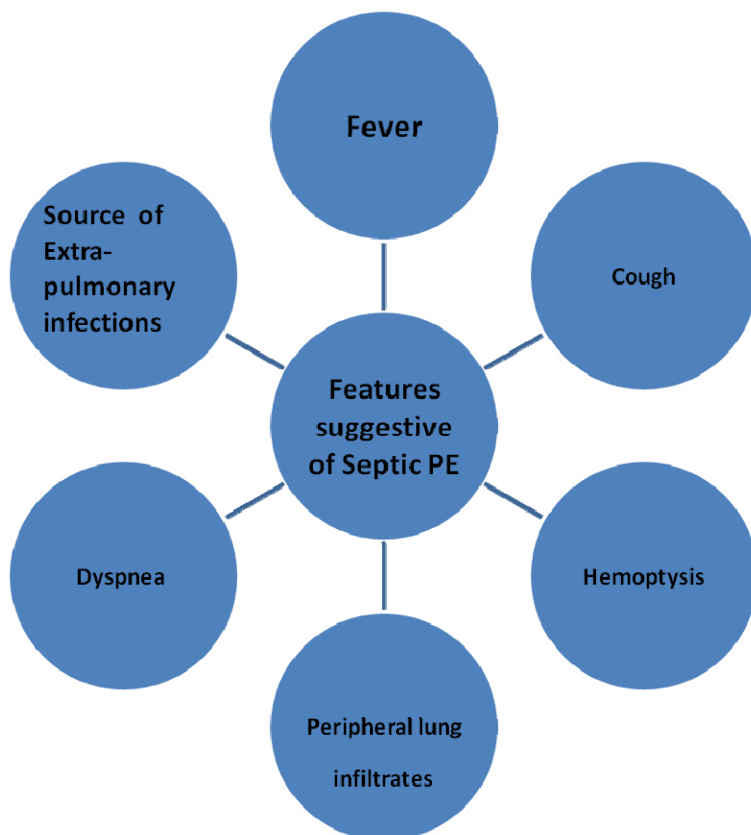


Fig. 4. Clinical manifestations of SPE

Lemierre's syndrome usually occurs in previously healthy adolescent or young adults, generally presenting with high grade fever (39-41°C) and rigors. History is usually significant for sore throat, tooth ache, odynophagia, dysphagia and chest pain in the week preceding the presentation. On examination the patient appears ill, may have signs of periodontal disease, the tonsils are usually inflamed with exudates and peritonsillar abscesses releasing foul-smelling pus. "The diagnosis of this infection may be suggested by the peculiar odour—like Limburger or overripe Camembert cheese—of pus produced by it." (Alston, 1955). Signs of internal jugular vein thrombosis may be present in 26-45% of cases. Features suggestive of the development of internal jugular vein thrombophlebitis include neck pain and stiffness, cervical lymphadenopathy often in the anterior triangle and more characteristically a tender (normally unilateral) swelling at the angle of the jaw— anterior to, and parallel with, the sternomastoid muscle (Riordan & Wilson, 2004).

27. Diagnosis

Clinical and radiological features at presentation are usually nonspecific and the diagnosis is frequently delayed (Huang et al., 1989). Radiographic findings, predisposing background or illness, and clinical evidence of infection usually are clues to the diagnosis. Blood cultures, chest CT and echocardiography are valuable when evaluating a patient with suspected SPE. Basic laboratory testing provides some clues to diagnosis. Patients typically have a neutrophil predominant leucocytosis. Liver function tests are abnormal in approximately 50% of patients. C-reactive protein is invariably raised.

Microbiology: The diagnosis of bacteremia or fungemia is confirmed by recovery of the same species of micro-organisms from the peripheral blood cultures and from quantitative cultures obtained from the source of SPE. Pus drained from any site should be sent for culture, including catheter tip, localized abscesses in the neck, empyema, septic arthritis, bone, and soft tissue abscesses.

Chest radiograph findings are usually nonspecific with a spectrum of radiological abnormalities. The usual findings include patchy air space opacities simulating nonspecific broncho-pneumonia, multiple ill-defined nodules (usually 1-3 cm) in various stages of cavitation with irregular thick walls or wedge-shaped densities of varying sizes located peripherally abutting the pleura. Other x-ray features also include blunting of the costophrenic angle, indicating small pleural effusions or empyema.

Computed tomography (CT) of the chest: Common findings are patchy consolidation with air bronchograms, nodules in various stages of cavitation (predominant in the lower lobes), wedge-shaped peripheral lesions abutting the pleura with or without extension into the pleural space - pleural effusion/empyema, and hilar or mediastinal lymphadenopathy. The "*feeding vessel sign*" has been considered highly suggestive (although not pathognomonic) of septic PE and consists of a distinct vessel leading directly into the center of a nodule (Fig 5). This sign may represent hematogenous spread to the lungs and may also be seen in metastasis. The prevalence of this sign varies from 67-100% in various series and the heterogeneous sub pleural wedge-shaped opacities are seen in 70-75% of patients (Kwon et al., 2007). Multi-detector CT is faster and superior to the classical CT technology for detection of this sign (Dodd et al., 2006).

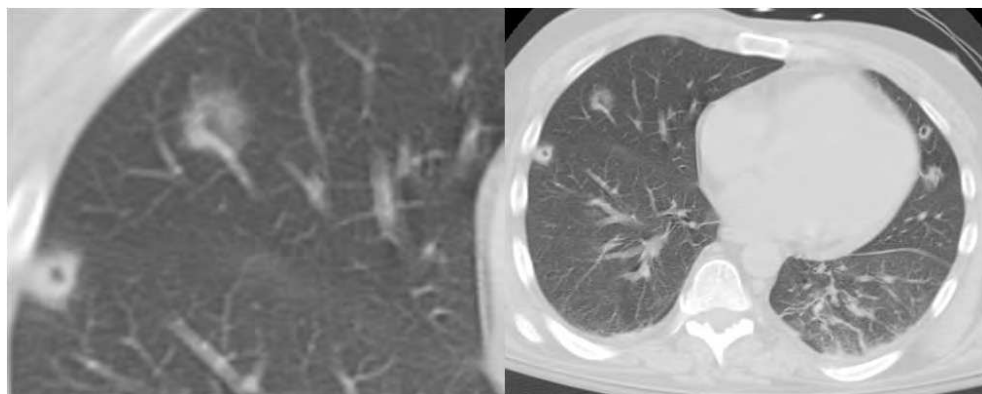


Fig. 5. The "Feeding vessel" sign and multiple peripheral cavitating lesions suggestive of SPE

Features	Gram Positive SPE	Gram negative SPE
1) Size of emboli	Larger	Smaller
2) Radiographic Characteristics	1) Cavitation 2) Air bronchograms in nodules 3) Peripheral wedge shaped opacities	1) 'Halo sign': Central area of soft tissue attenuation surrounded by a halo of ground-glass attenuation. 2) Hemorrhagic nodules and infarcts 3) "Feeding vessel" sign

Table 7. Characteristics of SPE

Echocardiography is an important tool in evaluating patients for endocarditis. Transesophageal echocardiography (TEE) increases the sensitivity of detecting vegetations from 75 to 95 percent while maintaining the specificity of 85 to 98 percent and is thus, superior to the transthoracic technique (TTE) in delineating vegetations, abscesses and leaflet perforations in the heart (Dodd et al., 2006).

28. Treatment

Recent studies demonstrate improved outcomes for patients with SPE with virtually all patients recovering from their illness. This may be attributable to earlier diagnosis, prompt administration of broad-spectrum antibiotics and improvements in surgical and supportive care. Discontinuation of vascular catheters/devices is recommended. In Lemierre's syndrome, vigorous antibiotic treatment for 4-6 weeks, targeting the organism and drainage of accessible abscesses are indicated. Internal jugular vein ligation/excision is rarely indicated as is the use of anticoagulation (Armstrong et al., 2000; Lustig et al., 1995). Consensus recommendation (American Heart Association (AHA), British Society for Antimicrobial Chemotherapy (BSAC), and the European Society for Cardiology (ESC)) is that, prompt use of antibiotics in treatment of endocarditis may result in reduction of incidence of SPE (Baddour et al., 2005; Elliott et al., 2004). The recommended duration of antibiotics is 4 to 6 weeks. The 2008 American College of Chest Physicians (ACCP) guidelines recommend against the use of routine antithrombotic therapy unless a separate indication exists.

29. Amniotic fluid embolism

AFE is an exceedingly rare and one of the most catastrophic complications of pregnancy. It remains an enigma to this date, more than half a century after the first published autopsy series. AFE is responsible for significant proportion of maternal mortality (Lang & King, 2008; Lewis, 2007). The presence of fetal debris in the pulmonary circulation of a mother who died suddenly during labor was first reported by Meyer in 1926 (Meyer, 1926) and

subsequently by Steiner and Lushbaugh in 1941 as an autopsy series (Steiner & Lushbaugh, 1941).

30. Epidemiology & risk factors

The true incidence of AFE remains unknown and is variably reported in literature. The incidence of AFE has been estimated to be in 1 in 8000 to 80000 deliveries with reported mortality rates in older reports as high as 60%. However, more recent data suggest lower mortality rates ranging between 27-37% (Clark et al., 1995; Morgan, 1979; Tuffnell, 2005). For unknown reasons, the incidence of AFE is much higher in North America, around 1 in 15000 deliveries, Australia -1 in 30000 deliveries (C. L. Roberts et al., 2010), United Kingdom - 1 in 50000 (Abenhaim et al., 2008; Knight et al., 2010; Kramer et al., 2006).

AFE usually occurs during immediate postpartum period. Data from a national registry revealed that AFE occurred during labor but before delivery in 70% of cases and during caesarean section in 19% (Clark et al., 1995). Although, reported as early as second trimester, the diagnosis in cases occurring as late as 36 h postpartum has been described (Devriendt et al., 1995). AFE following trans-abdominal amniocentesis is very rare (Hasaart & Essed, 1983). It has been estimated that AFE accounted for 12% of all maternal deaths related to legally induced abortion since 1972 (Grimes & Schulz, 1985; Guidotti et al., 1981). It is seldom associated with (surgical) manipulation during caesarean section (Laforga, 1997), curettage (Grimes & Cates, 1977), cervical suture removal (Margan et al., 1984) or repair of an incompetent cervix (Margan et al., 1984), or after car or motor vehicle accidents (Olcott et al., 1973). Large fetal size, use of oxytocics and vaginal prostaglandins, advanced gestational age, amnio-infusion or complicated labor have all been implicated (Maher et al., 1994; Morgan, 1979). In reality, specific risk factors have not been conclusively identified. Logistic regression identified advanced maternal age, placental pathologies and caesarean deliveries in a large population-based cohort study (Abenhaim et al., 2008). Maternal age below 20 years and dystocia has been associated with lower incidence of AFE.

Pathophysiology: The pathogenesis of AFE remains poorly understood. The detection of fetal tissue in maternal pulmonary artery is not pathognomonic. In fact, there is no clear temporal relationship between entry of amniotic fluid in to maternal circulation and symptom onset. The "antigenic" nature of AF along with pulmonary eosinophilic infiltrates, elevated antitrypsin activity suggestive of mast cell degranulation has resulted in some authors to propose "Anaphylactoid syndrome of Pregnancy" as an alternative name to AFE. Autopsy findings frequently reveal disseminated intravascular coagulation (DIC). Isolated DIC may herald AFE. Amniotic fluid accelerates clot initiation and propagation.

Hemodynamic Effects: A biphasic pattern of hemodynamic changes have been favored in most recent descriptions. The "acute phase" comprising of acute elevation of pulmonary arterial pressure ("acute Cor Pulmonale"), followed by left ventricular dysfunction/failure.

31. Clinical features

AFE is a diagnosis of exclusion. It typically occurs during labor and delivery or in the immediate postpartum period, although it can occur as late as 48 hours postpartum. About 70% of cases occur before delivery (range, 63–76%). The symptoms are often sudden and protean. AFE is typified by maternal collapse associated with breathlessness, cyanosis, cardiac dysrhythmia, hypotension and then haemorrhage associated with DIC. Clark et al,

Adjusted odds ratio (95% confidence interval)		
Characteristics	Kramer et al (Canadian Cohort) (Kramer et al., 2006)	Abenheim et al (American Cohort) (Abenheim et al., 2008)
Maternal age 35 years	1.9 (1. -2.7)	2.2 (1.5-2.)
Cesarean delivery	12.5 (7.9 -19.9) - cephalic presentation 8.6 (4.3-17.4) - non-cephalic presentation	5.7 (3.7-8.7)
Forcep delivery	5.9 (3.4-10.3)	4.3 (1.9-6.6)
Vacuum delivery	2.9 (1.6-5.3)	1.9 (1 -3.7)
Abr ptio placenta	---	8.0 (4.0-15.9)
Placenta previa	----	30.4 (15.4-60.1)
Abruptio placenta or placenta previa	3.5 (2.3-5.5)	
Eclampsia	11.5 (2.8-46.9)	29.1 (7.1-119.3)
Fetal distress	1.7 (1.2-2.5)	1.5 (1.0-2.2)

Table 8. Risk factors associated with an increased risk of AFE in two large registries.

found the most common presenting signs and symptoms were hypotension and signs of non-reassuring fetal status (100%), pulmonary edema or respiratory symptoms (93%), cardiac arrest (87%), cyanosis (83%), and coagulopathy (83%). A majority develop seizures, encephalopathy and permanent neurological sequelae [85], due to cerebral ischemia and anoxia. The clinical course seems to have phases that are likely temporally related to pathophysiologic changes (Clark, 1990).

Induced abortion	(Grimes & Schulz, 1985; Guidotti et al., 1981; Lawson et al., 1990)
foeticide	(Edwards & Davies, 2000; Shojai et al., 2003)
Intrapartum amnioinfusion	(Dorairajan & Soundararaghavan, 2005; Maher et al., 1994)
Transabdominal amniocentesis	(Hasaart & Essed, 1983; Paterson et al., 1977)
Blunt abdominal trauma	(Judich et al., 1998; Olcott et al., 1973)
Surgical trauma	(Pluymakers et al., 2007)
Removal of cervical sutures	(Haines & Wilkes, 2003; Margan et al., 1984)
Manual removal of placenta	(Manchanda & Sriemevan, 2005)

Table 9. Procedures associated with AFE.

32. Diagnosis

The diagnosis of AFE is “clinical” and one of exclusion. AFE should be suspected if a woman experiences one or more of the following during late pregnancy or within 48 hours of delivery: acute or sudden onset of hypotension and/or cardiac arrest, hypoxemia,

seizures or coma, DIC and in absence of potential alternative explanation for these manifestations (Table 2). Demonstration of fetal squamous cells in pulmonary arterial circulation is not pathognomonic. Presence of AF cells in BAL may be supportive. There are no specific laboratory tests for diagnosing AFE. Diagnostic markers for AFE have been developed which rely on detection of fetal or amniotic fluid constituents in maternal circulation, such as Serum Sialyl Tn Antigen, (Benson et al., 2001; Kobayashi et al., 1993; Oi et al., 1998) and plasma zinc coproporphyrin (a component of meconium) (Kanayama et al., 1992). Serum Tryptase, a marker of mast cell degranulation may be elevated but unreliable (Dorne et al., 2002; Farrar & Gherman, 2001; Marcus et al., 2005; Nishio et al., 2002).

33. Management

There is no specific treatment for AFE. The condition can be neither predicted nor prevented. The principles of management of AFE are mainly supportive, ie, to restore and maintain hemodynamic stability, to correct hypoxia and maintain adequate oxygenation, correction of coagulopathy with blood products as necessary and to deliver the fetus promptly at the earliest sign of maternal or fetal distress. Given sudden or hyperacute manner of presentation, prompt and aggressive response from the treating clinician is a must. As the diagnosis is not always clear from the onset of collapse, the role of diagnostic tests is to exclude conditions that can be treated specifically such as, Thrombotic PE which is more common compared to AFE. Hypoxia must be corrected promptly as significant proportions of survivors have residual neurological impairment due to cerebral anoxia (Moore & Baldisseri, 2005). Hypotension and shock should be aggressively treated with intravenous fluids, vasopressors and ionotropes as necessary. Since clinical manifestations are biphasic and complex, invasive hemodynamic monitoring is essential. Additional data from trans-thoracic or trans-esophageal echocardiography may be useful (James et al., 2004; Koegler et al., 1994; Stanten et al., 2003; van Haeften et al., 1989; Verroust et al., 2007). Administration of blood component is considered the first line treatment for coagulopathy associated with AFE. DIC is frequently associated with severe hemorrhage, so transfusion of packed red blood cells is a priority to maintain adequate tissue oxygenation. Uterine atony with DIC is a dangerous complication that might require immediate surgical intervention such as, hysterectomy.

As AFE occurred during labor in a predominant number of cases, immediate delivery of fetus by means of caesarian section is mandatory to prevent fetal hypoxic damage and to facilitate resuscitation (Davies & Harrison, 1992; Prasad & Howell, September 2001). Advanced cardiac life support (ACLS) protocol should be followed in case of cardiac arrest. The goal of drug therapy is to restore normal maternal hemodynamics in conjunction with the delivery of the fetus as soon as possible after the onset of asystole or malignant arrhythmia. During resuscitation, the uterus should be displaced to the left to avoid compression of the large vessels and improve venous return.

34. Prognosis

AFE accounts for approximately 10% of all maternal death within the USA (Atrash et al., 1990). Case fatality rate has declined significantly in recent years due to the prompt and aggressive resuscitation measures. (Abenheim et al., 2008; Benson, 1993; Clark et al., 1995; Morgan, 1979). There is higher likelihood of survival if the women survive long enough to

be transferred to intensive care unit. AFE still carries significant morbidity which includes neurological deficit in significant proportions of mothers as well as newborn. Neonatal survival is reported to be at 70%.

Either In the absence of any other clear cause

Acute maternal collapse with one or more of the following features:

- Acute fetal compromise
- Cardiac arrhythmias or arrest
- Coagulopathy
- Convulsion
- Hypotension
- Maternal haemorrhage
- Premonitory symptoms, e.g. restlessness, numbness, agitation, tingling
- Shortness of breath

Excluding women with maternal haemorrhage as the first presenting feature in whom there was no evidence of early coagulopathy or cardiorespiratory compromise

Or Women in whom the diagnosis was made at post-mortem examination by finding fetal squames or hair in the lungs

Table 10. UK Obstetric Surveillance System (UKOSS) criteria for defining cases of AFE

35. Tumor embolism

Pulmonary tumor emboli are defined as clumps of malignant cells within the lumina of pulmonary arteries and arterioles (Kane et al., 1975). Microscopic pulmonary tumor emboli involve the small pulmonary arteries, arterioles and alveolar septal capillaries which are occluded by aggregates of tumor cells accompanied by platelet-fibrin thrombosis.

Types:

1. "Acute" tumor emboli - "massive" tumor emboli that can result in symptoms over "days"
2. "Sub-acute" tumor emboli - multiple small emboli resulting in "symptoms" over weeks to months

36. History & epidemiology

In 1897, Schmidt (M. B. Schmidt, 1903) first described pulmonary tumor embolization in a patient with gastric carcinoma. Autopsy showed the pulmonary bed was massively occluded by tumor emboli and pathology was similar to gastric tumor cells. It was not until 1937 that Brill and Robertson (Brill & Robertson, 1937) described the clinical syndrome of sub acute cor-pulmonale due to multiple tumor emboli to the pulmonary microvasculature. This syndrome is rare and exceedingly difficult to recognize before death. Since then pulmonary tumor embolism has been described in a variety of malignancies.

The estimated incidence of pulmonary tumor embolism is 3-26% among patients with solid tumors as reported by autopsy series (Bast et al., 2000; Kane et al., 1975; Shields & Edwards,

1992). Despite the relative prevalence at autopsy, the diagnosis is infrequently made ante mortem and thus the incidence of clinically significant tumor embolism is unclear (C. K. Chan et al., 1987). Retrospective chart reviews demonstrate that only 8% of patients with pathological evidence of tumor emboli have documented morbidity and mortality (Kane et al., 1975; Shields & Edwards, 1992).

37. Etiology

The risk appears to be greatest with mucin secreting adenocarcinomas of the breast, lung, stomach and colon. However, PTE has also been reported in hepatocellular, prostate, renal cell and choriocarcinomas. Other rare associations are listed below (K. E. Roberts et al., 2003).

- Breast
- Stomach
- Lung
- Liver
- Prostate
- Pancreas
- Bone
- Undifferentiated carcinoma
- Ovary
- Bladder
- Cervix
- Colorectal
- Kidney
- Mesothelioma
- Wilms' tumor
- Esophageal
- Parotid
- Melanoma
- Myxoma
- Thyroid
- Trophoblastic
- Vulva
- Neurogenic sarcoma

38. Pathology

Histological studies of tumor emboli in humans and animals have provided some insights into the fate of pulmonary tumor emboli. Schimdt noted that tumor emboli are usually associated with intravascular platelet-fibrin rich thrombi. As a result, cancer cells become fewer and degenerative in appearance during the organization of these thrombi. The tumor emboli have no tendency to invade the arterial wall (Winterbauer et al., 1968). Necropsy studies and animal model studies suggest that tumor emboli are destroyed or remain latent and are not truly metastases. Soares et al (Soares et al., 1993) studied 222 consecutive autopsies of cancer cases and detected pulmonary hypertensive arteriopathy

with proliferative endarteritis. Thus, PTE may be pathologically indistinguishable from other forms of pulmonary arterial hypertension, except for the notable absence of plexiform lesions. Some investigators describe tumor emboli as possessing an unusual level of resistance to recannulation (as compared to thromboembolism) and therefore likely lead to progressive and irreversible obstruction of the pulmonary vascular bed (Winterbauer et al., 1968).

Pathophysiology: Pulmonary vasculature provides the first capillary bed to the circulating tumor cells. The process of pulmonary metastasis consists of sequential steps that includes intravascular and/or lymphatic invasion of the lung by the neoplastic cells. Large scale autopsy studies suggest that tumor cells spread to the pulmonary vasculature in basically 4 ways (Kane et al., 1975; Winterbauer et al., 1968):

1. Large tumor emboli to the main pulmonary artery or large lobar branches producing the syndrome of acute pulmonary hypertension.
2. Microscopic tumor embolization involving small arteries and arterioles accounting for progressive dyspnea and subacute pulmonary hypertension.
3. Generalized lymphatic dissemination leading to pulmonary microvascular involvement (lymphatic carcinomatosis) causing diffuse interstitial infiltrates.
4. A combination of the above three mechanisms.

Clinical features: In most patients, primary malignancy was established when tumor emboli were noted. The signs and symptoms are non-specific. Patients with large proximal emboli have rapid onset of symptoms due to acute right heart failure indistinguishable from the presentation of a massive thromboembolism. Lymphangitic carcinomatosis and microvascular disease involving small pulmonary arteries, follow a more deliberate and progressive course resulting in subacute cor pulmonale.

Physical examination shows evidence of pulmonary hypertension and signs of right heart dysfunction. Common findings included: tachypnea, tachycardia, cyanosis, hypotension, elevated Jugular venous distension (JVD), audible pulmonic sound (P2), ascites and peripheral edema. Although considered "classic", signs of right heart failure are only reported in 15% to 20% of patients with this syndrome (Veinot et al., 1992).

Diagnosis: Ante-mortem diagnosis of pulmonary tumor embolism can be very difficult due to lack of distinctive features compared to thrombo-embolism which is more common. Diagnosis often made via tissue specimens from open lung biopsy or autopsy. Pulmonary arterial sampling (in a wedge position) has resulted in diagnosis in a few cases (Masson & Ruggieri, 1985; K. E. Roberts et al., 2003).

39. Management

Treatment of the pulmonary tumor embolism is directed at the primary tumor. Complete surgical resection of the primary tumor results in gradual resolution of the tumor emboli and reversal of the respiratory symptoms in patients with renal cell carcinoma, atrial myxoma and choriocarcinoma (C. K. Chan et al., 1987). The curative surgical resection in these cases may be due to early recognition or related to the less aggressive nature of the underlying malignancies. Embolectomy and IVC filter placement have been employed in the rare patients suffering from large, central pulmonary tumor emboli arising from infra-diaphragmatic tumors. Chemotherapy generally does not affect the prognosis unless the primary tumor is very chemo-sensitive i.e. Wilm's tumor or trophoblastic tumors.

40. Pulmonary cement embolism

Pulmonary Cement Embolism (PCE) is a complication of Percutaneous Vertebroplasty (PVP) and Balloon Kyphoplasty which are minimally invasive procedures used to treat osteoporotic and other vertebral fractures (Galibert et al., 1987; Garfin et al., 2001; Gigante & Pierangeli, 2008; McDonald et al., 2008; Oner et al., 2006; Stoffel et al., 2007; Wu & Fournay, 2005). Polymethylmethacrylate (PMMA, "cement") leakage is a frequent occurrence during these procedures and the source of PCE (Gangi et al., 1999; Garfin et al., 2001; Hauck et al., 2005; Hodler et al., 2003; R. Schmidt et al., 2005; Vasconcelos et al., 2002; Yeom et al., 2003). The risk of pulmonary cement embolism (PCE) ranges from 3.5% to 23% for osteoporotic fractures (Anselmetti et al., 2005; Choe et al., 2004; Duran et al., 2007; Y. J. Kim et al., 2009). A recent report suggested a prevalence of 8.8% (Gill et al., 2010). Exact incidence is difficult to estimate as many are asymptomatic and escape detection. Patients with malignant lesions of the vertebrae might be at a higher risk of developing PCE due to damaged cortical substance and increased vascularity, while technical factors such as inappropriate viscosity of the cement at the time of injection, lack of visual guidance and higher cement volume injected during the procedure increase the risk of PCE (Baroud et al., 2006; Bohner et al., 2003; Choe et al., 2004; Deramond et al., 1998). The clinical spectrum following PMMA leakage is broad: asymptomatic extravasation into surrounding tissues, features of nerve root compression (Kelekis et al., 2003; Laredo & Hamze, 2005; Ratliff et al., 2001), asymptomatic and symptomatic pulmonary cement embolism (Anselmetti et al., 2005; Choe et al., 2004; Duran et al., 2007; Y. J. Kim et al., 2009), even cardiac perforation (S. Y. Kim et al., 2005; Lim et al., 2008; Schoenes et al., 2008; Son et al., 2008) and death (H. L. Chen et al., 2002; Monticelli et al., 2005; Stricker et al., 2004; Yoo et al., 2004) have been reported. Fat embolism occurring simultaneously with cement embolism may also contribute to the clinical picture (Aebli et al., 2002; Rauschmann et al., 2004). Clinically PCE cannot be distinguished from thrombotic pulmonary embolism (Bernhard et al., 2003; Jang et al., 2002; Padovani et al., 1999; Tozzi et al., 2002). Diagnosis is based on history and imaging which shows presence of radio-opaque densities (Figs 6 a&b). There is not enough evidence to underlay treatment guidelines. Since cement is regarded as "thrombogenic", (Francois et al., 2003; Perrin et al., 1999; Righini et al., 2006; Tozzi et al., 2002) anticoagulation for 6 months is recommended for symptomatic patients or patients with central PCE. Asymptomatic patients with peripheral PCE should have close clinical follow up with no anticoagulation. Surgical embolectomy may be considered for exceptional cases of central embolism. Routine chest roentgenogram should be obtained after PVP and BKP regardless of the symptoms as many patients are asymptomatic.

41. Gas embolism

Gas embolism (GE) is mainly ambient "air" embolism (AE) but also includes other gases such as carbon dioxide, nitrous oxide, nitrogen and helium. It is a rare and potentially fatal condition. There are 2 main types of GE, i.e. venous and arterial. They are distinguished by the mechanism of entry. Venous GE (VGE) occurs usually as a complication of iatrogenic procedures such as vascular catheter placement, mechanical ventilation and rarely surgical procedures (pulmonary lung biopsy, open heart surgeries, craniotomy). Arterial GE causes ischemia. As little as 0.5ml of air can result in coronary ischemia, cardiac arrhythmias, serious brain damage and even death.

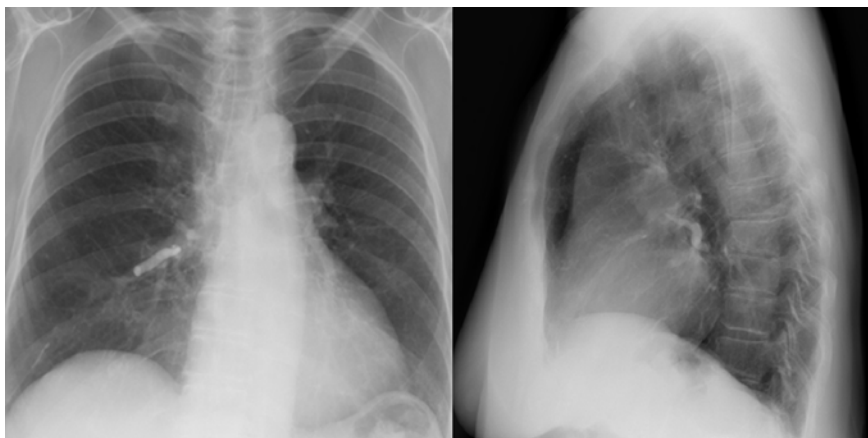

Fig. 6. a: Chest radiograph showing radio-opaque density in right main pulmonary artery

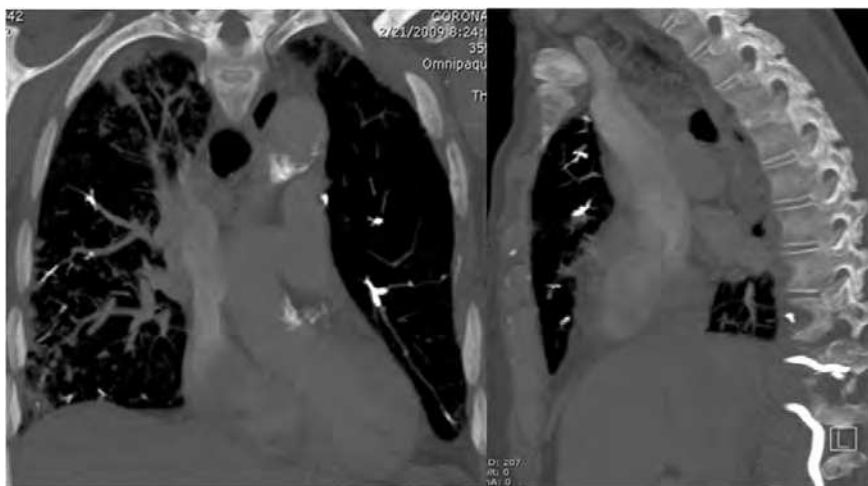


Fig. 6. b: CT Chest revealing bright intravascular densities in segmental and subsegmental pulmonary arteries

In venous GE, manifestations include cough, dyspnea, tachypnea and a hypoxemic “gasp” reflex when 10% or more of the pulmonary vessels are occluded (Souders, 2000; Sviri et al., 2004). Arterial embolization into the coronary arteries induces a specific drum-like or “mill-wheel” murmur along with electrocardiographic changes of ischemia (Rossi et al., 2000).

The key to controlling air embolism lies in prevention. First line of treatment includes administration of 100% oxygen, placing the patient in left lateral decubitus position to prevent right ventricular outflow obstruction by airlock. Hyperbaric Oxygen (HBO) may be used. 100% oxygen decreases the size of the gas bubbles by increasing the ambient pressure and by establishing a diffusion gradient that favors the elimination of gas from the bubbles and by increasing the gradient for the egress of nitrogen from

the bubbles (Muth & Shank, 2000; Van Liew et al., 1993). Adjunctive treatment, includes fluid administration and prophylaxis against venous thromboembolism in paralyzed patients. Treatment is effective in most cases, although residual deficits can remain in serious cases.

42. Foreign body embolism

42.1 Silicone embolism

Silicone is thought to be an immunological inert substance and a component of many implantable medical devices. Silicone emboli (SIE) were first reported in trans-sexual males in 1970's and then later in young healthy women seeking low cost enhancements. Silicone implants are approved and widely used for breast augmentation, however liquid silicone used for aesthetic purposes cause significant morbidity when injected in the hips and buttocks, face, breasts, and vagina and is illegal in the US (Bartsich & Wu, 2010). Clinical features are similar to fat embolism with majority of patients meeting Schonfeld criteria (Schmid et al., 2005). The most common presentation is hypoxemia (92%) (Bartsich & Wu, 2010). Silicone embolic syndrome (SES) is a constellation of mainly pulmonary symptoms including dyspnea, fever, cough, hemoptysis, chest pain, hypoxia, alveolar hemorrhage, and altered consciousness presenting in patients shortly after silicone injection (within the first few hours) (Schmid et al., 2005). Later sequelae may occur within a few days and the possibility of delayed-onset pneumonitis or local inflammation at injection sites can occur up to years after administration (Chastre et al., 1987). Several factors have been implicated in leading to silicone emboli, including large volume injections, high-pressure infiltration, particle migration, and intravascular injection (Villa & Sparacio, 2000). It is thought that alveolar macrophages ingest silicone and fat to provoke an inflammatory response by increasing vascular permeability, activating endothelial cells, inducing the accumulation of activated neutrophils and modulating immunoregulatory responses in the lung. Imaging is usually suggestive of an embolic, congestive, pneumonitis or diffuse alveolar damage pattern. Treatment is supportive, consisting mainly of supplemental oxygen and steroid therapy.

43. Hyaluronic acid embolism

Hyaluronic acid (HA) is an approved dermal filler used for correction of facial wrinkles and folds (H. J. Park et al., 2010). All other uses are considered off label and illegal. HA associated pulmonary emboli (HAAPE) have been described in few case reports (Famularo et al., 2001; H.J. Park et al., 2010). Typical presentation of HAAPE is acute respiratory failure within hours after the HA injection in the anterior wall of the vagina, G-Spot amplification or for lip amplification by an unlicensed medical practitioner. Due to the extensive venous plexus, procedures involving injections in and around the injection site can cause NTPE. Although HA is thought to be non-immunogenic, it can cause localized granulomatous foreign body reactions with multinucleated giant cells around amorphous basophilic materials in the pulmonary vessels and lung parenchyma, as seen on video-assisted lung biopsy (Fernandez-Acenero et al., 2003; Honig et al., 2003; Raulin et al., 2000). Treatment is mainly supportive.

44. Others

Any material that is injected intravenously can potentially enter the pulmonary circulation leading to pulmonary embolism. Foreign materials such as talc, starch, cotton, and cellulose

used as insoluble binding agents in oral tablets, are first pulverized, then dissolved in water and injected by intravenous drug users, and may be carried by the bloodstream until they lodge in the pulmonary capillary bed to cause NTPE (Farber et al., 1989; Ferrer et al., 2002; Low & Nicol, 2006; Pare et al., 1989).

The advent of modern percutaneous interventional procedures has led to a rise in catheter or fragment related pulmonary embolism. Catheter embolism usually takes place when the catheter is withdrawn from the introducing needle causing the distal portion of the catheter to be sheared off (Propp et al., 1988). Spontaneous catheter breakage accounts for 25% of the catheter emboli. Retained catheter fragments have high rate of complications such as arrhythmias, perforations and thrombus formation (Fisher & Ferreyro, 1978; Richardson et al., 1974).

Prostate brachytherapy can also lead to embolization of radioactive seeds. On imaging the radioactive seeds appear as small (Iodine-125 measures 4.8 mm in length and 0.8 mm in diameter) metallic densities, usually detected incidentally. Clinical implications of these embolized radioactive seed implants remain unclear. Patients with arteriovenous malformations undergo therapeutic cerebral embolization with different materials such as cyano-acrylate agents, polyvinyl alcohol foam particles, micro-coils, silk or dacron thread and balloons. Cyano-acrylate has been reported to cause symptomatic pulmonary embolism (Kjellin et al., 2000; Pelz et al., 1995). Intravenous injection of elemental mercury is rare and has typically been reported in relation to psychiatric or suicidal incidents (Givica-Perez et al., 2001). Systemic embolization of mercury has been reported as well (Shareeff et al., 2000; Vas et al., 1980). On imaging, multiple metallic densities are seen. Mercury may remain in the body for a long time and metallic densities may remain visible for years after the injection (Ambre et al., 1977).

45. Conclusion

NTPE continues to pose a diagnostic challenge in clinical medicine despite much advancement in laboratory testing and imaging. Improved awareness along with techniques to allow for more accurate ante-mortem diagnosis may facilitate early and prompt recognition of these syndromes which may in turn pave the way for better treatment modalities.

46. Acknowledgement

We wish thank Ms. Judy Kammerer (Librarian, UCSF Fresno) for her invaluable contribution in preparation of this chapter.

47. References

- 406th Medical General Laboratory, Professional Section. (1951). *Fat embolism: Annual publication, historical report*, Tokyo
- Abenhaim, H. A., Azoulay, L., Kramer, M. S. & Leduc, L. (2008). Incidence and risk factors of amniotic fluid embolisms: A population-based study on 3 million births in the united states. *American Journal of Obstetrics and Gynecology*, Vol.199, No.1, pp. 49.e1-49.e8, 1097-6868; 0002-9378
- Adams, C. B. (1971). The retinal manifestations of fat embolism. *Injury*, Vol.2, No.3, pp. 221-224, 0020-1383

- Aebli, N., Krebs, J., Davis, G., Walton, M., Williams, M. J. & Theis, J. C. (2002). Fat embolism and acute hypotension during vertebroplasty: An experimental study in sheep. *Spine*, Vol.27, No.5, pp. 460-466, 1528-1159; 0362-2436
- Aebli, N., Schwenke, D., Davis, G., Hii, T., Theis, J. C. & Krebs, J. (2005). Polymethylmethacrylate causes prolonged pulmonary hypertension during fat embolism: A study in sheep. *Acta Orthopaedica*, Vol.76, No.6, pp. 904-911, 1745-3674
- Akhtar, S. (2009). Fat embolism. *Anesthesiology Clinics*, Vol.27, No.3, pp. 533-50, table of contents, 1932-2275
- Alho, A., Saikku, K., Eerola, P., Koskinen, M. & Hamalainen, M. (1978). Corticosteroids in patients with a high risk of fat embolism syndrome. *Surgery, Gynecology & Obstetrics*, Vol.147, No.3, pp. 358-362, 0039-6087
- Al-Khuwaitir, T. S., Al-Moghairi, A. M., Sherbeen, S. M. & Subh, H. M. (2002). Traumatic fat embolism syndrome. *Saudi Medical Journal*, Vol.23, No.12, pp. 1532-1536, 0379-5284
- Alston, J. M. (1955). Necrobacillosis in great britain. *British Medical Journal*, Vol.2, No.4955, pp. 1524-1528, 0007-1447
- Ambre, J. J., Welsh, M. J. & Svare, C. W. (1977). Intravenous elemental mercury injection: Blood levels and excretion of mercury. *Annals of Internal Medicine*, Vol.87, No.4, pp. 451-453, 0003-4819
- Anselmetti, G. C., Corgnier, A., Debernardi, F. & Regge, D. (2005). Treatment of painful compression vertebral fractures with vertebroplasty: Results and complications. *La Radiologia Medica*, Vol.110, No.3, pp. 262-272, 0033-8362
- Aoki, N., Soma, K., Shindo, M., Kurosawa, T. & Ohwada, T. (1998). Evaluation of potential fat emboli during placement of intramedullary nails after orthopedic fractures. *Chest*, Vol.113, No.1, pp. 178-181, 0012-3692
- Armstrong, A. W., Spooner, K. & Sanders, J. W. (2000). Lemierre's syndrome. *Current Infectious Disease Reports*, Vol.2, No.2, pp. 168-173, 1534-3146; 1523-3847
- Atrash, H. K., Koonin, L. M., Lawson, H. W., Franks, A. L. & Smith, J. C. (1990). Maternal mortality in the united states, 1979-1986. *Obstetrics and Gynecology*, Vol.76, No.6, pp. 1055-1060, 0029-7844
- Baddour, L. M., Wilson, W. R., Bayer, A. S., Fowler, V. G., Jr, Bolger, A. F., Levison, M. E., . . . Infectious Diseases Society of America. (2005). Infective endocarditis: Diagnosis, antimicrobial therapy, and management of complications: A statement for healthcare professionals from the committee on rheumatic fever, endocarditis, and kawasaki disease, council on cardiovascular disease in the young, and the councils on clinical cardiology, stroke, and cardiovascular surgery and anesthesia, american heart association: Endorsed by the infectious diseases society of america. *Circulation*, Vol.111, No.23, pp. e394-434, 1524-4539; 0009-7322
- Baker, A. B. (1976). The fat embolism syndrome, results of a therapeutic regime. *Anaesthesia and Intensive Care*, Vol.4, No.1, pp. 53-55, 0310-057X
- Baker, P. L., Pazell, J. A. & Peltier, L. F. (1971). Free fatty acids, catecholamines, and arterial hypoxia in patients with fat embolism. *The Journal of Trauma*, Vol.11, No.12, pp. 1026-1030, 0022-5282
- Barak, M., Kabha, M., Norman, D., Soudry, M., Kats, Y. & Milo, S. (2008). Cerebral microemboli during hip fracture fixation: A prospective study. *Anesthesia and Analgesia*, Vol.107, No.1, pp. 221-225, 1526-7598; 0003-2999

- Baroud, G., Crookshank, M. & Bohner, M. (2006). High-viscosity cement significantly enhances uniformity of cement filling in vertebroplasty: An experimental model and study on cement leakage. *Spine*, Vol.31, No.22, pp. 2562-2568, 1528-1159; 0362-2436
- Bartsich, S. & Wu, J. K. (2010). Silicon emboli syndrome: A sequela of clandestine liquid silicone injections. A case report and review of the literature. *Journal of Plastic, Reconstructive & Aesthetic Surgery : JPRAS*, Vol.63, No.1, pp. e1-3, 1878-0539; 1748-6815
- Bast, R. C., Kufe, D. W., Pollock, R. E. & Weichselbaum, R. R. (2000). *Cancer medicine* (5th ed.), B.C. Decker, 9781550091137, Ontario
- Bederman, S. S., Bhandari, M., McKee, M. D. & Schemitsch, E. H. (2009). Do corticosteroids reduce the risk of fat embolism syndrome in patients with long-bone fractures? A meta-analysis. *Canadian Journal of Surgery. Journal Canadien De Chirurgie*, Vol.52, No.5, pp. 386-393, 1488-2310; 0008-428X
- Behrman, S. W., Fabian, T. C., Kudsk, K. A. & Taylor, J. C. (1990). Improved outcome with femur fractures: Early vs. delayed fixation. *The Journal of Trauma*, Vol.30, No.7, pp. 792-7; discussion 797-8, 0022-5282
- Benson, M. D. (1993). Nonfatal amniotic fluid embolism. three possible cases and a new clinical definition. *Archives of Family Medicine*, Vol.2, No.9, pp. 989-994, 1063-3987
- Benson, M. D., Kobayashi, H., Silver, R. K., Oi, H., Greenberger, P. A. & Terao, T. (2001). Immunologic studies in presumed amniotic fluid embolism. *Obstetrics and Gynecology*, Vol.97, No.4, pp. 510-514, 0029-7844
- Bernard, G. R., Artigas, A., Brigham, K. L., Carlet, J., Falke, K., Hudson, L., Spragg, R. (1994). The american-european consensus conference on ARDS. definitions, mechanisms, relevant outcomes, and clinical trial coordination. *American Journal of Respiratory and Critical Care Medicine*, Vol.149, No.3 Pt 1, pp. 818-824, 1073-449X
- Bernhard, J., Heini, P. F. & Villiger, P. M. (2003). Asymptomatic diffuse pulmonary embolism caused by acrylic cement: An unusual complication of percutaneous vertebroplasty. *Annals of the Rheumatic Diseases*, Vol.62, No.1, pp. 85-86, 0003-4967
- Bohner, M., Gasser, B., Baroud, G. & Heini, P. (2003). Theoretical and experimental model to describe the injection of a polymethylmethacrylate cement into a porous structure. *Biomaterials*, Vol.24, No.16, pp. 2721-2730, 0142-9612
- Bone, L. B., Johnson, K. D., Weigelt, J. & Scheinberg, R. (1989). Early versus delayed stabilization of femoral fractures. A prospective randomized study. *The Journal of Bone and Joint Surgery. American Volume*, Vol.71, No.3, pp. 336-340, 0021-9355
- Brill, I. C. & Robertson, T. D. (1937). Subacute cor pulmonale. *Archives of Internal Medicine*, Vol.60, pp. 1043-1057, 0003-9926
- Broder, G. & Ruzumna, L. (1967). Systemic fat embolism following acute primary osteomyelitis. *JAMA : The Journal of the American Medical Association*, Vol.199, No.13, pp. 150-152, 0098-7484
- Brundage, S. I., McGhan, R., Jurkovich, G. J., Mack, C. D. & Maier, R. V. (2002). Timing of femur fracture fixation: Effect on outcome in patients with thoracic and head injuries. *The Journal of Trauma*, Vol.52, No.2, pp. 299-307, 0022-5282
- Buchanan, D. & Mason, J. K. (1982). Occurrence of pulmonary fat and bone marrow embolism. *The American Journal of Forensic Medicine and Pathology*, Vol.3, No.1, pp. 73-78, 0195-7910

- Bulger, E. M., Smith, D. G., Maier, R. V. & Jurkovich, G. J. (1997). Fat embolism syndrome. A 10-year review. *Archives of Surgery (Chicago, Ill.: 1960)*, Vol.132, No.4, pp. 435-439, 0004-0010
- Chan, C. K., Hutcheon, M. A., Hyland, R. H., Smith, G. J., Patterson, B. J. & Matthay, R. A. (1987). Pulmonary tumor embolism: A critical review of clinical, imaging, and hemodynamic features. *Journal of Thoracic Imaging*, Vol.2, No.4, pp. 4-14, 0883-5993
- Chan, K. M., Tham, K. T., Chiu, H. S., Chow, Y. N. & Leung, P. C. (1984). Post-traumatic fat embolism--its clinical and subclinical presentations. *The Journal of Trauma*, Vol.24, No.1, pp. 45-49, 0022-5282
- Chastre, J., Brun, P., Soler, P., Basset, F., Trouillet, J. L., Fagon, J. Y., . . . Hance, A. J. (1987). Acute and latent pneumonitis after subcutaneous injections of silicone in transsexual men. *The American Review of Respiratory Disease*, Vol.135, No.1, pp. 236-240, 0003-0805
- Chastre, J., Fagon, J. Y., Soler, P., Fichelle, A., Dombret, M. C., Hutten, D., . . . Gibert, C. (1990). Bronchoalveolar lavage for rapid diagnosis of the fat embolism syndrome in trauma patients. *Annals of Internal Medicine*, Vol.113, No.8, pp. 583-588, 0003-4819
- Chen, H. L., Wong, C. S., Ho, S. T., Chang, F. L., Hsu, C. H. & Wu, C. T. (2002). A lethal pulmonary embolism during percutaneous vertebroplasty. *Anesthesia and Analgesia*, Vol.95, No.4, pp. 1060-2, table of contents, 0003-2999
- Chen, J. J., Ha, J. C. & Mirvis, S. E. (2008). MR imaging of the brain in fat embolism syndrome. *Emergency Radiology*, Vol.15, No.3, pp. 187-192, 1070-3004
- Choe, D. H., Marom, E. M., Ahrar, K., Truong, M. T. & Madewell, J. E. (2004). Pulmonary embolism of polymethyl methacrylate during percutaneous vertebroplasty and kyphoplasty. *AJR.American Journal of Roentgenology*, Vol.183, No.4, pp. 1097-1102, 0361-803X
- Choi, J. A., Oh, Y. W., Kim, H. K., Kang, K. H., Choi, Y. H. & Kang, E. Y. (2002). Nontraumatic pulmonary fat embolism syndrome: Radiologic and pathologic correlations. *Journal of Thoracic Imaging*, Vol.17, No.2, pp. 167-169, 0883-5993
- Clark, S. L. (1990). New concepts of amniotic fluid embolism: A review. *Obstetrical & Gynecological Survey*, Vol.45, No.6, pp. 360-368, 0029-7828
- Clark, S. L., Hankins, G. D., Dudley, D. A., Dildy, G. A. & Porter, T. F. (1995). Amniotic fluid embolism: Analysis of the national registry. *American Journal of Obstetrics and Gynecology*, Vol.172, No.4 Pt 1, pp. 1158-67; discussion 1167-9, 0002-9378
- Cook, R. J., Ashton, R. W., Aughenbaugh, G. L. & Ryu, J. H. (2005). Septic pulmonary embolism: Presenting features and clinical course of 14 patients. *Chest*, Vol.128, No.1, pp. 162-166, 0012-3692
- Coronado-Malagon, M., Visoso-Palacios, P. & Arce-Salinas, C. A. (2010). Fat embolism syndrome secondary to injection of large amounts of soft tissue filler in the gluteal area. *Aesthetic Surgery Journal / the American Society for Aesthetic Plastic Surgery*, Vol.30, No.3, pp. 448-450, 1527-330X; 1090-820X
- Cuppige, F. E. (1963). Fat embolism in diabetes mellitus. *American Journal of Clinical Pathology*, Vol.40, pp. 270-275, 0002-9173
- Currie, I., Drutz, H. P., Deck, J. & Oxorn, D. (1997). Adipose tissue and lipid droplet embolism following periurethral injection of autologous fat: Case report and review of the literature. *International Urogynecology Journal and Pelvic Floor Dysfunction*, Vol.8, No.6, pp. 377-380,

- Davies, M. G. & Harrison, J. C. (1992). Amniotic fluid embolism: Maternal mortality revisited. *British Journal of Hospital Medicine*, Vol.47, No.10, pp. 775-776, 0007-1064
- de Falco, R., Scarano, E., Di Celmo, D., Grasso, U. & Guarnieri, L. (2005). Balloon kyphoplasty in traumatic fractures of the thoracolumbar junction. preliminary experience in 12 cases. *Journal of Neurosurgical Sciences*, Vol.49, No.4, pp. 147-153, 0390-5616
- Dedhia, J. D. & Mushambi, M. C. (2007). Amniotic fluid embolism. *Continuing Education in Anaesthesia, Critical Care & Pain*, Vol.7, No.5, pp. 152-156, 1743-1816; 1743-1824
- Deland, F. H. (1956). *Bone marrow embolism and associated fat embolism to the lungs*. Thesis, Graduate School, University of Minnesota).
- Deramond, H., Depriester, C., Galibert, P. & Le Gars, D. (1998). Percutaneous vertebroplasty with polymethylmethacrylate. technique, indications, and results. *Radiologic Clinics of North America*, Vol.36, No.3, pp. 533-546, 0033-8389
- Devriendt, J., Machayekhi, S. & Staroukine, M. (1995). Amniotic fluid embolism: Another case with non-cardiogenic pulmonary edema. *Intensive Care Medicine*, Vol.21, No.8, pp. 698-699, 0342-4642
- Dines, D. E., Linscheid, R. L. & Didier, E. P. (1972). Fat embolism syndrome. *Mayo Clinic Proceedings*. *Mayo Clinic*, Vol.47, No.4, pp. 237-240, 0025-6196
- Dodd, J. D., Souza, C. A. & Muller, N. L. (2006). High-resolution MDCT of pulmonary septic embolism: Evaluation of the feeding vessel sign. *AJR.American Journal of Roentgenology*, Vol.187, No.3, pp. 623-629, 1546-3141; 0361-803X
- Dorairajan, G. & Soundararaghavan, S. (2005). Maternal death after intrapartum saline amnioinfusion--report of two cases. *BJOG : An International Journal of Obstetrics and Gynaecology*, Vol.112, No.9, pp. 1331-1333, 1470-0328
- Dorne, R., Pommier, C., Emery, J. C., Dieudonne, F. & Bongiovanni, J. P. (2002). Amniotic fluid embolism: Successful evolution course after uterine arteries embolization. [Embolie de liquide amniotique: evolution favorable apres embolisation therapeutique des arteres uterines] *Annales Francaises d'Anesthesie Et De Reanimation*, Vol.21, No.5, pp. 431-435, 0750-7658
- Duran, C., Sirvanci, M., Aydogan, M., Ozturk, E., Ozturk, C. & Akman, C. (2007). Pulmonary cement embolism: A complication of percutaneous vertebroplasty. *Acta Radiologica (Stockholm, Sweden : 1987)*, Vol.48, No.8, pp. 854-859, 1600-0455; 0284-1851
- Edwards, G. J. & Davies, N. J. (2000). Amniotic fluid embolus following feticide - a cautionary tale. *Journal of Obstetrics and Gynaecology : The Journal of the Institute of Obstetrics and Gynaecology*, Vol.20, No.2, pp. 191, 0144-3615
- Eguia, P., Medina, A., Garcia-Monco, J. C., Martin, V. & Monton, F. I. (2007). The value of diffusion-weighted MRI in the diagnosis of cerebral fat embolism. *Journal of Neuroimaging : Official Journal of the American Society of Neuroimaging*, Vol.17, No.1, pp. 78-80, 1051-2284
- Elliott, T. S., Foweraker, J., Gould, F. K., Perry, J. D., Sandoe, J. A. & Working Party of the British Society for Antimicrobial Chemotherapy. (2004). Guidelines for the antibiotic treatment of endocarditis in adults: Report of the working party of the british society for antimicrobial chemotherapy. *The Journal of Antimicrobial Chemotherapy*, Vol.54, No.6, pp. 971-981, 0305-7453

- Fabian, T. C., Hoots, A. V., Stanford, D. S., Patterson, C. R. & Mangiante, E. C. (1990). Fat embolism syndrome: Prospective evaluation in 92 fracture patients. *Critical Care Medicine*, Vol.18, No.1, pp. 42-46, 0090-3493
- Famularo, G., Liberati, C., Sebastiani, G. D. & Polchi, S. (2001). Pulmonary embolism after intra-articular injection of methylprednisolone and hyaluronate. *Clinical and Experimental Rheumatology*, Vol.19, No.3, pp. 355, 0392-856X
- Farber, H. W., Fairman, R. P., Millan, J. E., Rounds, S. & Glauser, F. L. (1989). Pulmonary response to foreign body microemboli in dogs: Release of neutrophil chemoattractant activity by vascular endothelial cells. *American Journal of Respiratory Cell and Molecular Biology*, Vol.1, No.1, pp. 27-35, 1044-1549
- Farrar, S. C. & Gherman, R. B. (2001). Serum tryptase analysis in a woman with amniotic fluid embolism. A case report. *The Journal of Reproductive Medicine*, Vol.46, No.10, pp. 926-928, 0024-7758
- Fernandez-Acenero, M. J., Zamora, E. & Borbujo, J. (2003). Granulomatous foreign body reaction against hyaluronic acid: Report of a case after lip augmentation. *Dermatologic Surgery : Official Publication for American Society for Dermatologic Surgery [Et Al.]*, Vol.29, No.12, pp. 1225-1226, 1076-0512
- Ferrer, J., Montes, J. F., Villarino, M. A., Light, R. W. & Garcia-Valero, J. (2002). Influence of particle size on extrapleural talc dissemination after talc slurry pleurodesis. *Chest*, Vol.122, No.3, pp. 1018-1027, 0012-3692
- Fisher, R. G. & Ferreyro, R. (1978). Evaluation of current techniques for nonsurgical removal of intravascular iatrogenic foreign bodies. *AJR.American Journal of Roentgenology*, Vol.130, No.3, pp. 541-548, 0361-803X
- Forteza, A. M., Koch, S., Romano, J. G., Zych, G., Bustillo, I. C., Duncan, R. C. & Babikian, V. L. (1999). Transcranial doppler detection of fat emboli. *Stroke; a Journal of Cerebral Circulation*, Vol.30, No.12, pp. 2687-2691, 0039-2499
- Francis, R. A., Barnes, P. A. & Libshitz, H. I. (1983). Pulmonary oil embolism after lymphangiography. *Journal of Computer Assisted Tomography*, Vol.7, No.1, pp. 170-171, 0363-8715
- Francois, K., Taeymans, Y., Poffyn, B. & Van Nooten, G. (2003). Successful management of a large pulmonary cement embolus after percutaneous vertebroplasty: A case report. *Spine*, Vol.28, No.20, pp. E424-5, 1528-1159; 0362-2436
- Galibert, P., Deramond, H., Rosat, P. & Le Gars, D. (1987). Preliminary note on the treatment of vertebral angioma by percutaneous acrylic vertebroplasty. [Note preliminaire sur le traitement des angiomes vertebraux par vertebroplastie acrylique percutanee] *Neuro-Chirurgie*, Vol.33, No.2, pp. 166-168, 0028-3770
- Gangi, A., Dietemann, J. L., Guth, S., Steib, J. P. & Roy, C. (1999). Computed tomography (CT) and fluoroscopy-guided vertebroplasty: Results and complications in 187 patients. *Seminars in Interventional Radiology*, Vol.16, No.2, pp. 137-142, 0739-9529
- Garfin, S. R., Yuan, H. A. & Reiley, M. A. (2001). New technologies in spine: Kyphoplasty and vertebroplasty for the treatment of painful osteoporotic compression fractures. *Spine*, Vol.26, No.14, pp. 1511-1515, 0362-2436
- Gary, A. D. (2004). Amniotic fluid embolism. In L. C. Steven, A. B. Michael, G. R. Saabe & et al. (Eds.), *Text book of critical care obstetrics* (pp. 463-471) Blackwell.
- Gauss, H. (1924). The pathology of fat embolism. *Archives of Surgery*, Vol.9, pp. 593-603, 0004-0010

- Gigante, N. & Pierangeli, E. (2008). Minimally invasive anterior approach for kyphoplasty of the first thoracic vertebra in a patient with multiple myeloma. *Minimally Invasive Neurosurgery : MIN*, Vol.51, No.1, pp. 26-29, 0946-7211
- Gill, N. S., Hamidjaja, L., Kandaswamy, C., Venugopal, C., Lesperance, R., & Balasubramanian, V. (2010). Incidence of cement pulmonary embolism after percutaneous vertebroplasty procedure [Abstract]. *American Journal of Respiratory Critical Care Medicine*, 181 A1901.
- Givica-Perez, A., Santana-Montesdeoca, J. M., Diaz-Sanchez, M., Martinez-Lagares, F. J. & Castaneda, W. R. (2001). Deliberate, repeated self-administration of metallic mercury injection: Case report and review of the literature. *European Radiology*, Vol.11, No.8, pp. 1351-1354, 0938-7994
- Godeau, B., Schaeffer, A., Bachir, D., Fleury-Feith, J., Galacteros, F., Verra, F., Lebagry, F. (1996). Bronchoalveolar lavage in adult sickle cell patients with acute chest syndrome: Value for diagnostic assessment of fat embolism. *American Journal of Respiratory and Critical Care Medicine*, Vol.153, No.5, pp. 1691-1696, 1073-449X
- Goldhaber, S. Z. (2004). Pulmonary embolism. *Lancet*, Vol.363, No.9417, pp. 1295-1305, 1474-547X; 0140-6736
- Golpe, R., Marin, B. & Alonso, M. (1999). Lemierre's syndrome (necrobacillosis). *Postgraduate Medical Journal*, Vol.75, No.881, pp. 141-144, 0032-5473
- Gossling, H. R. & Pellegrini, V. D., Jr. (1982). Fat embolism syndrome: A review of the pathophysiology and physiological basis of treatment. *Clinical Orthopaedics and Related Research*, Vol.(165), No.165, pp. 68-82, 0009-921X
- Gravante, G., Araco, A., Sorge, R., Araco, F., Nicoli, F., Caruso, R., . . . Cervelli, V. (2008). Pulmonary embolism after combined abdominoplasty and flank liposuction: A correlation with the amount of fat removed. *Annals of Plastic Surgery*, Vol.60, No.6, pp. 604-608, 1536-3708; 0148-7043
- Grimes, D. A. & Cates, W., Jr. (1977). Fatal amniotic fluid embolism during induced abortion, 1972-1975. *Southern Medical Journal*, Vol.70, No.11, pp. 1325-1326, 0038-4348
- Grimes, D. A. & Schulz, K. F. (1985). Morbidity and mortality from second-trimester abortions. *The Journal of Reproductive Medicine*, Vol.30, No.7, pp. 505-514, 0024-7758
- Guardia, S. N., Bilbao, J. M., Murray, D., Warren, R. E. & Sweet, J. (1989). Fat embolism in acute pancreatitis. *Archives of Pathology & Laboratory Medicine*, Vol.113, No.5, pp. 503-506, 0003-9985
- Guidotti, R. J., Grimes, D. A. & Cates, W., Jr. (1981). Fatal amniotic fluid embolism during legally induced abortion, united states, 1972 to 1978. *American Journal of Obstetrics and Gynecology*, Vol.141, No.3, pp. 257-261, 0002-9378
- Guillevin, R., Vallee, J. N., Demeret, S., Sonnevill, R., Bolgert, F., Mont'alverne, F., . . . Chiras, J. (2005). Cerebral fat embolism: Usefulness of magnetic resonance spectroscopy. *Annals of Neurology*, Vol.57, No.3, pp. 434-439, 0364-5134
- Gurd, A. R. & Wilson, R. I. (1974). The fat embolism syndrome. *The Journal of Bone and Joint Surgery, British Volume*, Vol.56B, No.3, pp. 408-416, 0301-620X
- Haber, L. M., Hawkins, E. P., Seilheimer, D. K. & Saleem, A. (1988). Fat overload syndrome. an autopsy study with evaluation of the coagulopathy. *American Journal of Clinical Pathology*, Vol.90, No.2, pp. 223-227, 0002-9173

- Haines, J. & Wilkes, R. G. (2003). Non-fatal amniotic fluid embolism after cervical suture removal. *British Journal of Anaesthesia*, Vol.90, No.2, pp. 244-247, 0007-0912
- Hamrick-Turner, J., Abbitt, P. L., Harrison, R. B. & Cranston, P. E. (1994). Diffuse lung calcifications following fat emboli and adult respiratory distress syndromes: CT findings. *Journal of Thoracic Imaging*, Vol.9, No.1, pp. 47-50, 0883-5993
- Han, D., Lee, K. S., Franquet, T., Muller, N. L., Kim, T. S., Kim, H., . . . Byun, H. S. (2003). Thrombotic and nonthrombotic pulmonary arterial embolism: Spectrum of imaging findings. *Radiographics : A Review Publication of the Radiological Society of North America, Inc*, Vol.23, No.6, pp. 1521-1539, 1527-1323; 0271-5333
- Hasaart, T. H. & Essed, G. G. (1983). Amniotic fluid embolism after transabdominal amniocentesis. *European Journal of Obstetrics, Gynecology, and Reproductive Biology*, Vol.16, No.1, pp. 25-30, 0301-2115
- Hasan, M. Y., Kisson, N., Khan, T. M., Saldajeno, V., Goldstein, J. & Murphy, S. P. (2001). Intraosseous infusion and pulmonary fat embolism. *Pediatric Critical Care Medicine : A Journal of the Society of Critical Care Medicine and the World Federation of Pediatric Intensive and Critical Care Societies*, Vol.2, No.2, pp. 133-138, 1529-7535
- Hauck, S., Beisse, R. & Bu hren, V. (2005). Vertebroplasty and kyphoplasty in spinal trauma. *European Journal of Trauma*, Vol.31, pp. 453-463, 1439-0590; 1615-3146
- Haymaker, W. & Davison, C. (1950). Fatalities resulting from exposure to simulated high altitudes in decompression chambers; a clinicopathologic study of five cases. *Journal of Neuropathology and Experimental Neurology*, Vol.9, No.1, pp. 29-59, illust, 0022-3069
- Herndon, J. H. (1975). The syndrome of fat embolism. *Southern Medical Journal*, Vol.68, No.12, pp. 1577-1584, 0038-4348
- Hodler, J., Peck, D. & Gilula, L. A. (2003). Midterm outcome after vertebroplasty: Predictive value of technical and patient-related factors. *Radiology*, Vol.227, No.3, pp. 662-668, 0033-8419
- Honig, J. F., Brink, U. & Korabiowska, M. (2003). Severe granulomatous allergic tissue reaction after hyaluronic acid injection in the treatment of facial lines and its surgical correction. *The Journal of Craniofacial Surgery*, Vol.14, No.2, pp. 197-200, 1049-2275
- Huang, R. M., Naidich, D. P., Lubat, E., Schinella, R., Garay, S. M. & McCauley, D. I. (1989). Septic pulmonary emboli: CT-radiographic correlation. *AJR.American Journal of Roentgenology*, Vol.153, No.1, pp. 41-45, 0361-803X
- Hulman, G. (1988a). Fat macroglobule formation from chylomicrons and non-traumatic fat embolism. *Clinica Chimica Acta; International Journal of Clinical Chemistry*, Vol.177, No.2, pp. 173-178, 0009-8981
- Hulman, G. (1988b). Pathogenesis of non-traumatic fat embolism. *Lancet*, Vol.1, No.8599, pp. 1366-1367, 0140-6736
- Hutchinson, R. M., Merrick, M. V. & White, J. M. (1973). Fat embolism in sickle cell disease. *Journal of Clinical Pathology*, Vol.26, No.8, pp. 620-622, 0021-9746
- Jackson, C. T. & Greendyke, R. M. (1965). Pulmonary and cerebral fat embolism after closed-chest cardiac massage. *Surgery, Gynecology & Obstetrics*, Vol.120, pp. 25-27, 0039-6087
- Jacobson, D. M., Terrence, C. F. & Reinmuth, O. M. (1986). The neurologic manifestations of fat embolism. *Neurology*, Vol.36, No.6, pp. 847-851, 0028-3878

- James, C. F., Feinglass, N. G., Menke, D. M., Grinton, S. F. & Papadimos, T. J. (2004). Massive amniotic fluid embolism: Diagnosis aided by emergency transesophageal echocardiography. *International Journal of Obstetric Anesthesia*, Vol.13, No.4, pp. 279-283, 0959-289X
- Jang, J. S., Lee, S. H. & Jung, S. K. (2002). Pulmonary embolism of polymethylmethacrylate after percutaneous vertebroplasty: A report of three cases. *Spine*, Vol.27, No.19, pp. E416-8, 1528-1159; 0362-2436
- Jenkins, K., Chung, F., Wennberg, R., Etchells, E. E. & Davey, R. (2002). Fat embolism syndrome and elective knee arthroplasty. *Canadian Journal of Anaesthesia = Journal Canadien d'Anesthésie*, Vol.49, No.1, pp. 19-24, 0832-610X
- Johnson, M. J. & Lucas, G. L. (1996). Fat embolism syndrome. *Orthopedics*, Vol.19, No.1, pp. 41-8; discussion 48-9, 0147-7447
- Jones, J. P., Jr, Engleman, E. P. & Najarian, J. S. (1965). Systemic fat embolism after renal homotransplantation and treatment with corticosteroids. *The New England Journal of Medicine*, Vol.273, No.27, pp. 1453-1458, 0028-4793
- Jorens, P. G., Van Marck, E., Snoeckx, A. & Parizel, P. M. (2009). Nonthrombotic pulmonary embolism. *The European Respiratory Journal : Official Journal of the European Society for Clinical Respiratory Physiology*, Vol.34, No.2, pp. 452-474, 1399-3003; 0903-1936
- Judich, A., Kuriansky, J., Engelberg, I., Haik, J., Shabtai, M. & Czerniak, A. (1998). Amniotic fluid embolism following blunt abdominal trauma in pregnancy. *Injury*, Vol.29, No.6, pp. 475-477, 0020-1383
- Kallenbach, J., Lewis, M., Zaltzman, M., Feldman, C., Orford, A. & Zwi, S. (1987). 'Low-dose' corticosteroid prophylaxis against fat embolism. *The Journal of Trauma*, Vol.27, No.10, pp. 1173-1176, 0022-5282
- Kanayama, N., Yamazaki, T., Naruse, H., Sumimoto, K., Horiuchi, K. & Terao, T. (1992). Determining zinc coproporphyrin in maternal plasma--a new method for diagnosing amniotic fluid embolism. *Clinical Chemistry*, Vol.38, No.4, pp. 526-529, 0009-9147
- Kane, R. D., Hawkins, H. K., Miller, J. A. & Noce, P. S. (1975). Microscopic pulmonary tumor emboli associated with dyspnea. *Cancer*, Vol.36, No.4, pp. 1473-1482, 0008-543X
- Kearns, T. P. (1956). Fat embolism of the retina demonstrated by a flat retinal preparation. *American Journal of Ophthalmology*, Vol.41, No.1, pp. 1-2, 0002-9394
- Kelekis, A. D., Martin, J. B., Somon, T., Wetzel, S. G., Dietrich, P. Y. & Rufenacht, D. A. (2003). Radicular pain after vertebroplasty: Compression or irritation of the nerve root? initial experience with the "cooling system". *Spine*, Vol.28, No.14, pp. E265-9, 1528-1159; 0362-2436
- Kim, S. Y., Seo, J. B., Do, K. H., Lee, J. S., Song, K. S. & Lim, T. H. (2005). Cardiac perforation caused by acrylic cement: A rare complication of percutaneous vertebroplasty. *AJR.American Journal of Roentgenology*, Vol.185, No.5, pp. 1245-1247, 0361-803X
- Kim, Y. H., Oh, S. W. & Kim, J. S. (2002). Prevalence of fat embolism following bilateral simultaneous and unilateral total hip arthroplasty performed with or without cement : A prospective, randomized clinical study. *The Journal of Bone and Joint Surgery.American Volume*, Vol.84-A, No.8, pp. 1372-1379, 0021-9355
- Kim, Y. J., Lee, J. W., Park, K. W., Yeom, J. S., Jeong, H. S., Park, J. M. & Kang, H. S. (2009). Pulmonary cement embolism after percutaneous vertebroplasty in osteoporotic

- vertebral compression fractures: Incidence, characteristics, and risk factors. *Radiology*, Vol.251, No.1, pp. 250-259, 1527-1315; 0033-8419
- King, E. G., Weily, H. S., Genton, E. & Ashbaugh, D. G. (1971). Consumption coagulopathy in the canine oleic acid model of fat embolism. *Surgery*, Vol.69, No.4, pp. 533-541, 0039-6060
- King, M. B. & Harmon, K. R. (1994). Unusual forms of pulmonary embolism. *Clinics in Chest Medicine*, Vol.15, No.3, pp. 561-580, 0272-5231
- Kitchell, C. C. & Balogh, K. (1986). Pulmonary lipid emboli in association with long-term hyperalimentation. *Human Pathology*, Vol.17, No.1, pp. 83-85, 0046-8177
- Kiyokawa, H., Utsumi, K., Minemura, K., Kasuga, I., Torii, Y., Yonemaru, M., . . . Toyama, K. (1995). Fat embolism syndrome caused by vegetable oil injection. *Internal Medicine (Tokyo, Japan)*, Vol.34, No.5, pp. 380-383, 0918-2918
- Kjellin, I. B., Boechat, M. I., Vinuela, F., Westra, S. J. & Duckwiler, G. R. (2000). Pulmonary emboli following therapeutic embolization of cerebral arteriovenous malformations in children. *Pediatric Radiology*, Vol.30, No.4, pp. 279-283, 0301-0449
- Knight, M., Tuffnell, D., Brocklehurst, P., Spark, P., Kurinczuk, J. J. & UK Obstetric Surveillance System. (2010). Incidence and risk factors for amniotic-fluid embolism. *Obstetrics and Gynecology*, Vol.115, No.5, pp. 910-917, 1873-233X; 0029-7844
- Kobayashi, H., Ohi, H. & Terao, T. (1993). A simple, noninvasive, sensitive method for diagnosis of amniotic fluid embolism by monoclonal antibody TKH-2 that recognizes NeuAc alpha 2-6GalNAc. *American Journal of Obstetrics and Gynecology*, Vol.168, No.3 Pt 1, pp. 848-853, 0002-9378
- Koehler, A., Sauder, P., Marolf, A. & Jaeger, A. (1994). Amniotic fluid embolism: A case with non-cardiogenic pulmonary edema. *Intensive Care Medicine*, Vol.20, No.1, pp. 45-46, 0342-4642
- Koessler, M. J., Fabiani, R., Hamer, H. & Pitto, R. P. (2001). The clinical relevance of embolic events detected by transesophageal echocardiography during cemented total hip arthroplasty: A randomized clinical trial. *Anesthesia and Analgesia*, Vol.92, No.1, pp. 49-55, 0003-2999
- Kramer, M. S., Rouleau, J., Baskett, T. F., Joseph, K. S. & Maternal Health Study Group of the Canadian Perinatal Surveillance System. (2006). Amniotic-fluid embolism and medical induction of labour: A retrospective, population-based cohort study. *Lancet*, Vol.368, No.9545, pp. 1444-1448, 1474-547X; 0140-6736
- Krebs, J., Ferguson, S. J., Nuss, K., Leskosek, B., Hoerstrup, S. P., Goss, B. G., . . . Aebli, N. (2007). Plasma levels of endothelin-1 after a pulmonary embolism of bone marrow fat. *Acta Anaesthesiologica Scandinavica*, Vol.51, No.8, pp. 1107-1114, 0001-5172
- Kropfl, A., Davies, J., Berger, U., Hertz, H. & Schlag, G. (1999). Intramedullary pressure and bone marrow fat extravasation in reamed and unreamed femoral nailing. *Journal of Orthopaedic Research : Official Publication of the Orthopaedic Research Society*, Vol.17, No.2, pp. 261-268, 0736-0266
- Kwon, W. J., Jeong, Y. J., Kim, K. I., Lee, I. S., Jeon, U. B., Lee, S. H. & Kim, Y. D. (2007). Computed tomographic features of pulmonary septic emboli: Comparison of causative microorganisms. *Journal of Computer Assisted Tomography*, Vol.31, No.3, pp. 390-394, 0363-8715

- Laforga, J. B. (1997). Amniotic fluid embolism. report of two cases with coagulation disorder. *Acta Obstetrica Et Gynecologica Scandinavica*, Vol.76, No.8, pp. 805-806, 0001-6349
- Lang, C. T. & King, J. C. (2008). Maternal mortality in the united states. *Best Practice & Research.Clinical Obstetrics & Gynaecology*, Vol.22, No.3, pp. 517-531, 1521-6934
- Laredo, J. D. & Hamze, B. (2005). Complications of percutaneous vertebroplasty and their prevention. *Seminars in Ultrasound, CT, and MR*, Vol.26, No.2, pp. 65-80, 0887-2171
- Laub, D. R., Jr & Laub, D. R. (1990). Fat embolism syndrome after liposuction: A case report and review of the literature. *Annals of Plastic Surgery*, Vol.25, No.1, pp. 48-52, 0148-7043
- Lawson, H. W., Atrash, H. K. & Franks, A. L. (1990). Fatal pulmonary embolism during legal induced abortion in the united states from 1972 to 1985. *American Journal of Obstetrics and Gynecology*, Vol.162, No.4, pp. 986-990, 0002-9378
- Lehman, E. P. & Moore, R. M. (1927). Fat embolism, including experimental production without trauma. *Archives of Surgery*, Vol.14, pp. 621, 0004-0010
- Levy, D. (1990). The fat embolism syndrome. A review. *Clinical Orthopaedics and Related Research*, Vol.(261), No.261, pp. 281-286, 0009-921X
- Lewis, G. (Ed.). (2007). *The confidential enquiry into maternal and child health (CEMACH). saving mothers' lives: Reviewing maternal deaths to make motherhood safer - 2003-2005. the seventh resport on confidential enquiries into maternal deaths in the united kingdom CEMACH*, London
- Lim, S. H., Kim, H., Kim, H. K. & Baek, M. J. (2008). Multiple cardiac perforations and pulmonary embolism caused by cement leakage after percutaneous vertebroplasty. *European Journal of Cardio-Thoracic Surgery : Official Journal of the European Association for Cardio-Thoracic Surgery*, Vol.33, No.3, pp. 510-512, 1010-7940
- Lindeque, B. G., Schoeman, H. S., Dommissie, G. F., Boeyens, M. C. & Vlok, A. L. (1987). Fat embolism and the fat embolism syndrome. A double-blind therapeutic study. *The Journal of Bone and Joint Surgery.British Volume*, Vol.69, No.1, pp. 128-131, 0301-620X
- Lipton, J. H., Russell, J. A., Burgess, K. R. & Hwang, W. S. (1987). Fat embolization and pulmonary infiltrates after bone marrow transplantation. *Medical and Pediatric Oncology*, Vol.15, No.1, pp. 24-27, 0098-1532
- Low, S. E. & Nicol, A. (2006). Talc induced pulmonary granulomatosis. *Journal of Clinical Pathology*, Vol.59, No.2, pp. 223, 0021-9746
- Lozman, J., Deno, D. C., Feustel, P. J., Newell, J. C., Stratton, H. H., Sedransk, N., . . . Shah, D. M. (1986). Pulmonary and cardiovascular consequences of immediate fixation or conservative management of long-bone fractures. *Archives of Surgery (Chicago, Ill.: 1960)*, Vol.121, No.9, pp. 992-999, 0004-0010
- Lustig, L. R., Cusick, B. C., Cheung, S. W. & Lee, K. C. (1995). Lemierre's syndrome: Two cases of postanginal sepsis. *Otolaryngology--Head and Neck Surgery : Official Journal of American Academy of Otolaryngology-Head and Neck Surgery*, Vol.112, No.6, pp. 767-772, 0194-5998
- Lynch, M. J. (1954). Nephrosis and fat embolism in acute hemorrhagic pancreatitis. *A.M.A.Archives of Internal Medicine*, Vol.94, No.5, pp. 709-717, 0888-2479
- Macmahon, H. E. & Weiss, S. (1929). Carbon tetrachloride poisoning with macroscopic fat in the pulmonary artery. *The American Journal of Pathology*, Vol.5, No.6, pp. 623-630.3, 0002-9440

- MacMillan, J. C., Milstein, S. H. & Samson, P. C. (1978). Clinical spectrum of septic pulmonary embolism and infarction. *The Journal of Thoracic and Cardiovascular Surgery*, Vol.75, No.5, pp. 670-679, 0022-5223
- Maher, J. E., Wenstrom, K. D., Hauth, J. C. & Meis, P. J. (1994). Amniotic fluid embolism after saline amnioinfusion: Two cases and review of the literature. *Obstetrics and Gynecology*, Vol.83, No.5 Pt 2, pp. 851-854, 0029-7844
- Manchanda, R. & Sriemevan, A. (2005). Anaphylactoid syndrome caused by amniotic fluid embolism following manual removal of placenta. *Journal of Obstetrics and Gynaecology : The Journal of the Institute of Obstetrics and Gynaecology*, Vol.25, No.2, pp. 201-202, 0144-3615
- Marcus, B. J., Collins, K. A. & Harley, R. A. (2005). Ancillary studies in amniotic fluid embolism: A case report and review of the literature. *The American Journal of Forensic Medicine and Pathology*, Vol.26, No.1, pp. 92-95, 0195-7910
- Margan, I., Urbancic, S., Voncina, D., Janezic, P., Mocivnik, M., Srebotnjak-Lipovec, D. & Stricevic, Z. (1984). Amniotic fluid embolism in multiple pregnancy in the second trimester of gestation. [Embolija amnijskom tekucinom kod viseplodne trudnoce u drugom tromjesecu gestacije] *Jugoslavenska Ginekologija i Opstetricija*, Vol.24, No.1-2, pp. 29-32, 0017-002X
- Masson, R. G. & Ruggieri, J. (1985). Pulmonary microvascular cytology. A new diagnostic application of the pulmonary artery catheter. *Chest*, Vol.88, No.6, pp. 908-914, 0012-3692
- Mays, E. T. (1970). The effect of surgical stress on plasma free fatty acids. *The Journal of Surgical Research*, Vol.10, No.7, pp. 315-319, 0022-4804
- McCarthy, B., Mammen, E., Leblanc, L. P. & Wilson, R. F. (1973). Subclinical fat embolism: A prospective study of 50 patients with extremity fractures. *The Journal of Trauma*, Vol.13, No.1, pp. 9-16, 0022-5282
- McDonald, R. J., Trout, A. T., Gray, L. A., Dispenzieri, A., Thielen, K. R. & Kallmes, D. F. (2008). Vertebroplasty in multiple myeloma: Outcomes in a large patient series. *AJNR.American Journal of Neuroradiology*, Vol.29, No.4, pp. 642-648, 1936-959X; 0195-6108
- Meeke, R. I., Fitzpatrick, G. J. & Phelan, D. M. (1987). Cerebral oedema and the fat embolism syndrome. *Intensive Care Medicine*, Vol.13, No.4, pp. 291-292, 0342-4642
- Mellor, A. & Soni, N. (2001). Fat embolism. *Anaesthesia*, Vol.56, No.2, pp. 145-154, 0003-2409
- Metting, Z., Rodiger, L. A., Regtien, J. G. & van der Naalt, J. (2009). Delayed coma in head injury: Consider cerebral fat embolism. *Clinical Neurology and Neurosurgery*, Vol.111, No.7, pp. 597-600, 1872-6968; 0303-8467
- Meyer, J. R. (1926). Embolia pulmonar amnio caseosa. *Brasil-Medico*, Vol.2, pp. 301-303, 0006-9205
- Mimoz, O., Edouard, A., Beydon, L., Quillard, J., Verra, F., Fleury, J., . . . Samii, K. (1995). Contribution of bronchoalveolar lavage to the diagnosis of posttraumatic pulmonary fat embolism. *Intensive Care Medicine*, Vol.21, No.12, pp. 973-980, 0342-4642
- Monticelli, F., Meyer, H. J. & Tutsch-Bauer, E. (2005). Fatal pulmonary cement embolism following percutaneous vertebroplasty (PVP). *Forensic Science International*, Vol.149, No.1, pp. 35-38, 0379-0738

- Moore, J. & Baldisseri, M. R. (2005). Amniotic fluid embolism. *Critical Care Medicine*, Vol.33, No.10 Suppl, pp. S279-85, 0090-3493
- Moreau, J. P. (1974). Fat embolism: A review and report of 100 cases. *Canadian Journal of Surgery, Journal Canadien De Chirurgie*, Vol.17, No.4, pp. 196-199, 0008-428X
- Morgan, M. (1979). Amniotic fluid embolism. *Anaesthesia*, Vol.34, No.1, pp. 20-32, 0003-2409
- Moylan, J. A., Birnbaum, M., Katz, A. & Everson, M. A. (1976). Fat emboli syndrome. *The Journal of Trauma*, Vol.16, No.5, pp. 341-347, 0022-5282
- Murphy, P., Edelist, G., Byrick, R. J., Kay, J. C. & Mullen, J. B. (1997). Relationship of fat embolism to haemodynamic and echocardiographic changes during cemented arthroplasty. *Canadian Journal of Anaesthesia = Journal Canadien d'Anesthesie*, Vol.44, No.12, pp. 1293-1300, 0832-610X
- Muth, C. M. & Shank, E. S. (2000). Gas embolism. *The New England Journal of Medicine*, Vol.342, No.7, pp. 476-482, 0028-4793
- Nishio, H., Matsui, K., Miyazaki, T., Tamura, A., Iwata, M. & Suzuki, K. (2002). A fatal case of amniotic fluid embolism with elevation of serum mast cell tryptase. *Forensic Science International*, Vol.126, No.1, pp. 53-56, 0379-0738
- Ober, W. B., Bruno, M. S., Simon, R. M. & Weiner, L. (1959). Hemoglobin S-C disease with fat embolism: Report of a patient dying in crisis: Autopsy findings. *The American Journal of Medicine*, Vol.27, pp. 647-658, 0002-9343
- Oi, H., Kobayashi, H., Hirashima, Y., Yamazaki, T., Kobayashi, T. & Terao, T. (1998). Serological and immunohistochemical diagnosis of amniotic fluid embolism. *Seminars in Thrombosis and Hemostasis*, Vol.24, No.5, pp. 479-484, 0094-6176
- Olcott, C., Ath, Robinson, A. J., Maxwell, T. M. & Griffin, H. A. (1973). Amniotic fluid embolism and disseminated intravascular coagulation after blunt abdominal trauma. *The Journal of Trauma*, Vol.13, No.8, pp. 737-740, 0022-5282
- Oner, F. C., Verlaan, J. J., Verbout, A. J. & Dhert, W. J. (2006). Cement augmentation techniques in traumatic thoracolumbar spine fractures. *Spine*, Vol.31, No.11 Suppl, pp. S89-95; discussion S104, 1528-1159; 0362-2436
- Padovani, B., Kasriel, O., Brunner, P. & Peretti-Viton, P. (1999). Pulmonary embolism caused by acrylic cement: A rare complication of percutaneous vertebroplasty. *AJNR. American Journal of Neuroradiology*, Vol.20, No.3, pp. 375-377, 0195-6108
- Palmovic, V. & McCarroll, J. R. (1965). Fat embolism in trauma. *Archives of Pathology*, Vol.80, No.6, pp. 630-635, 0363-0153
- Parisi, D. M., Koval, K. & Egol, K. (2002). Fat embolism syndrome. *American Journal of Orthopedics (Belle Mead, N.J.)*, Vol.31, No.9, pp. 507-512, 1078-4519
- Parizel, P. M., Demey, H. E., Veeckmans, G., Verstreken, F., Cras, P., Jorens, P. G. & De Schepper, A. M. (2001). Early diagnosis of cerebral fat embolism syndrome by diffusion-weighted MRI (starfield pattern). *Stroke; a Journal of Cerebral Circulation*, Vol.32, No.12, pp. 2942-2944, 1524-4628; 0039-2499
- Pare, J. P., Cote, G. & Fraser, R. S. (1989). Long-term follow-up of drug abusers with intravenous talcosis. *The American Review of Respiratory Disease*, Vol.139, No.1, pp. 233-241, 0003-0805
- Park, H. J., Jung, K. H., Kim, S. Y., Lee, J. H., Jeong, J. Y. & Kim, J. H. (2010). Hyaluronic acid pulmonary embolism: A critical consequence of an illegal cosmetic vaginal procedure. *Thorax*, Vol.65, No.4, pp. 360-361, 1468-3296; 0040-6376

- Park, H. M., Ducret, R. P. & Brindley, D. C. (1986). Pulmonary imaging in fat embolism syndrome. *Clinical Nuclear Medicine*, Vol.11, No.7, pp. 521-522, 0363-9762
- Parker, F. B., Jr, Wax, S. D., Kusajima, K. & Webb, W. R. (1974). Hemodynamic and pathological findings in experimental fat embolism. *Archives of Surgery (Chicago, Ill.: 1960)*, Vol.108, No.1, pp. 70-74, 0004-0010
- Paterson, W. G., Grant, K. A., Grant, J. M. & McLean, N. (1977). The pathogenesis of amniotic fluid embolism with particular reference to transabdominal amniocentesis. *European Journal of Obstetrics, Gynecology, and Reproductive Biology*, Vol.7, No.5, pp. 319-324, 0301-2115
- Patil, N. & Wakankar, H. (2008). Morbidity and mortality of simultaneous bilateral total knee arthroplasty. *Orthopedics*, Vol.31, No.8, pp. 780-9; quiz 790-1, 0147-7447
- Peltier, L. F. (1965). The diagnosis of fat embolism. *Surgery, Gynecology & Obstetrics*, Vol.121, pp. 371-379, 0039-6087
- Peltier, L. F. (1969). Fat embolism. A current concept. *Clinical Orthopaedics and Related Research*, Vol.66, pp. 241-253, 0009-921X
- Peltier, L. F. (1984). Fat embolism. an appraisal of the problem. *Clinical Orthopaedics and Related Research*, Vol.(187), No.187, pp. 3-17, 0009-921X
- Peltier, L. F. (1988). Fat embolism. A perspective. *Clinical Orthopaedics and Related Research*, Vol.(232), No.232, pp. 263-270, 0009-921X
- Peltier, L. F., Collins, J. A., Evarts, C. M. & Sevitt, S. (1974). A panel by correspondence. fat embolism. *Archives of Surgery (Chicago, Ill.: 1960)*, Vol.109, No.1, pp. 12-16, 0004-0010
- Pelz, D. M., Lownie, S. P., Fox, A. J. & Hutton, L. C. (1995). Symptomatic pulmonary complications from liquid acrylate embolization of brain arteriovenous malformations. *AJNR.American Journal of Neuroradiology*, Vol.16, No.1, pp. 19-26, 0195-6108
- Perrin, C., Jullien, V., Padovani, B. & Blaive, B. (1999). Percutaneous vertebroplasty complicated by pulmonary embolus of acrylic cement. [Une vertebroplastie percutanee compliquee d'une embolie pulmonaire de ciment acrylique] *Revue Des Maladies Respiratoires*, Vol.16, No.2, pp. 215-217, 0761-8425
- Pitto, R. P., Hamer, H., Fabiani, R., Radespiel-Troeger, M. & Koessler, M. (2002). Prophylaxis against fat and bone-marrow embolism during total hip arthroplasty reduces the incidence of postoperative deep-vein thrombosis: A controlled, randomized clinical trial. *The Journal of Bone and Joint Surgery.American Volume*, Vol.84-A, No.1, pp. 39-48, 0021-9355
- Pitto, R. P., Koessler, M. & Kuehle, J. W. (1999). Comparison of fixation of the femoral component without cement and fixation with use of a bone-vacuum cementing technique for the prevention of fat embolism during total hip arthroplasty. A prospective, randomized clinical trial. *The Journal of Bone and Joint Surgery.American Volume*, Vol.81, No.6, pp. 831-843, 0021-9355
- Pitto, R. P., Schramm, M., Hohmann, D. & Kossler, M. (1999). Relevance of the drainage along the linea aspera for the reduction of fat embolism during cemented total hip arthroplasty. A prospective, randomized clinical trial. *Archives of Orthopaedic and Trauma Surgery*, Vol.119, No.3-4, pp. 146-150, 0936-8051

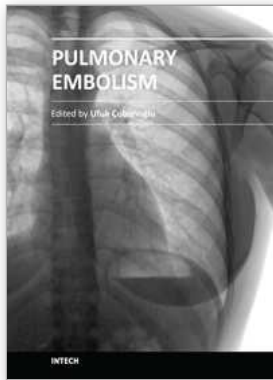
- Platt, M. S., Kohler, L. J., Ruiz, R., Cohle, S. D. & Ravichandran, P. (2002). Deaths associated with liposuction: Case reports and review of the literature. *Journal of Forensic Sciences*, Vol.47, No.1, pp. 205-207, 0022-1198
- Pluymakers, C., De Weerd, A., Jacquemyn, Y., Colpaert, C., Van de Poel, E. & Jorens, P. G. (2007). Amniotic fluid embolism after surgical trauma: Two case reports and review of the literature. *Resuscitation*, Vol.72, No.2, pp. 324-332, 0300-9572
- Prasad, B. G. R. & Howell, C. (September 2001). Cardiac arrest and cardiopulmonary resuscitation in pregnancy. In *MOET provider manual* (pp. 14:2-6)
- Propp, D. A., Cline, D. & Hennenfent, B. R. (1988). Catheter embolism. *The Journal of Emergency Medicine*, Vol.6, No.1, pp. 17-21, 0736-4679
- Pruszczuk, P., Torbicki, A., Pachon, R., Chlebus, M., Kuch-Wocial, A., Pruszyński, B. & Gurba, H. (1997). Noninvasive diagnosis of suspected severe pulmonary embolism: Transesophageal echocardiography vs spiral CT. *Chest*, Vol.112, No.3, pp. 722-728, 0012-3692
- Rabah, R., Evans, R. W. & Yunis, E. J. (1987). Mineral oil embolization and lipid pneumonia in an infant treated for hirschsprung's disease. *Pediatric Pathology / Affiliated with the International Paediatric Pathology Association*, Vol.7, No.4, pp. 447-455, 0277-0938
- Ratliff, J., Nguyen, T. & Heiss, J. (2001). Root and spinal cord compression from methylmethacrylate vertebroplasty. *Spine*, Vol.26, No.13, pp. E300-2, 0362-2436
- Raulin, C., Greve, B., Hartschuh, W. & Soegding, K. (2000). Exudative granulomatous reaction to hyaluronic acid (hylaform). *Contact Dermatitis*, Vol.43, No.3, pp. 178-179, 0105-1873
- Rauschmann, M. A., von Stechow, D., Thomann, K. D. & Scale, D. (2004). Complications of vertebroplasty. [Komplikationen in der Vertebroplastie] *Der Orthopade*, Vol.33, No.1, pp. 40-47, 0085-4530
- Rayburg, M., Kalinyak, K. A., Towbin, A. J., Baker, P. B. & Joiner, C. H. (2010). Fatal bone marrow embolism in a child with hemoglobin SE disease. *American Journal of Hematology*, Vol.85, No.3, pp. 182-184, 1096-8652; 0361-8609
- Richards, R. R. (1997). Fat embolism syndrome. *Canadian Journal of Surgery. Journal Canadien De Chirurgie*, Vol.40, No.5, pp. 334-339, 0008-428X
- Richardson, J. D., Grover, F. L. & Trinkle, J. K. (1974). Intravenous catheter emboli. experience with twenty cases and collective review. *American Journal of Surgery*, Vol.128, No.6, pp. 722-727, 0002-9610
- Righini, M., Sekoranta, L., Le Gal, G., Favre, I., Bounameaux, H. & Janssens, J. P. (2006). Pulmonary cement embolism after vertebroplasty. *Thrombosis and Haemostasis*, Vol.95, No.2, pp. 388-389, 0340-6245
- Riordan, T. & Wilson, M. (2004). Lemierre's syndrome: More than a historical curiosa. *Postgraduate Medical Journal*, Vol.80, No.944, pp. 328-334, 0032-5473
- Riska, E. B. & Myllynen, P. (1982). Fat embolism in patients with multiple injuries. *The Journal of Trauma*, Vol.22, No.11, pp. 891-894, 0022-5282
- Riska, E. B., von Bonsdorff, H., Hakkinen, S., Jaroma, H., Kiviluoto, O. & Paavilainen, T. (1976). Prevention of fat embolism by early internal fixation of fractures in patients with multiple injuries. *Injury*, Vol.8, No.2, pp. 110-116, 0020-1383
- Ritter, M., Mamlin, L. A., Melfi, C. A., Katz, B. P., Freund, D. A. & Arthur, D. S. (1997). Outcome implications for the timing of bilateral total knee arthroplasties. *Clinical*

- Orthopaedics and Related Research*, Vol.(345), No.345, pp. 99-105, 0009-921X
- Robert, J. H., Hoffmeyer, P., Broquet, P. E., Cerutti, P. & Vasey, H. (1993). Fat embolism syndrome. *Orthopaedic Review*, Vol.22, No.5, pp. 567-571, 0094-6591
- Roberts, C. L., Algert, C. S., Knight, M. & Morris, J. M. (2010). Amniotic fluid embolism in an australian population-based cohort. *BJOG : An International Journal of Obstetrics and Gynaecology*, Vol.117, No.11, pp. 1417-1421, 1471-0528; 1470-0328
- Roberts, K. E., Hamele-Bena, D., Saqi, A., Stein, C. A. & Cole, R. P. (2003). Pulmonary tumor embolism: A review of the literature. *The American Journal of Medicine*, Vol.115, No.3, pp. 228-232, 0002-9343
- Ross, A. P. (1970). The fat embolism syndrome: With special reference to the importance of hypoxia in the syndrome. *Annals of the Royal College of Surgeons of England*, Vol.46, No.3, pp. 159-171, 0035-8843
- Ross, R. M. & Johnson, G. W. (1988). Fat embolism after liposuction. *Chest*, Vol.93, No.6, pp. 1294-1295, 0012-3692; 0012-3692
- Rossi, S. E., Goodman, P. C. & Franquet, T. (2000). Nonthrombotic pulmonary emboli. *AJR.American Journal of Roentgenology*, Vol.174, No.6, pp. 1499-1508, 0361-803X
- Sakuma, M., Sugimura, K., Nakamura, M., Takahashi, T., Kitamukai, O., Yazu, T., . . . Shirato, K. (2007). Unusual pulmonary embolism: Septic pulmonary embolism and amniotic fluid embolism. *Circulation Journal : Official Journal of the Japanese Circulation Society*, Vol.71, No.5, pp. 772-775, 1346-9843
- Saldeen, T. (1970). Fat embolism and signs of intravascular coagulation in a posttraumatic autopsy material. *The Journal of Trauma*, Vol.10, No.4, pp. 273-286, 0022-5282
- Sasano, N., Ishida, S., Tetsu, S., Takasu, H., Ishikawa, K., Sasano, H. & Katsuya, H. (2004). Cerebral fat embolism diagnosed by magnetic resonance imaging at one, eight, and 50 days after hip arthroplasty: A case report. *Canadian Journal of Anaesthesia = Journal Canadien d'Anesthesie*, Vol.51, No.9, pp. 875-879, 0832-610X
- Satoh, H., Kurisu, K., Ohtani, M., Arita, K., Okabayashi, S., Nakahara, T., . . . Ohbayashi, N. (1997). Cerebral fat embolism studied by magnetic resonance imaging, transcranial doppler sonography, and single photon emission computed tomography: Case report. *The Journal of Trauma*, Vol.43, No.2, pp. 345-348, 0022-5282
- Schmid, A., Tzur, A., Leshko, L. & Krieger, B. P. (2005). Silicone embolism syndrome: A case report, review of the literature, and comparison with fat embolism syndrome. *Chest*, Vol.127, No.6, pp. 2276-2281, 0012-3692
- Schmidt, M. B. (1903). *Die verbreitungswege der karzinome und die beziehung generalisierter sarcome zu den leukaemischen neubildungen* G. Fischer, Vienna
- Schmidt, R., Cakir, B., Mattes, T., Wegener, M., Puhl, W. & Richter, M. (2005). Cement leakage during vertebroplasty: An underestimated problem? *European Spine Journal : Official Publication of the European Spine Society, the European Spinal Deformity Society, and the European Section of the Cervical Spine Research Society*, Vol.14, No.5, pp. 466-473, 0940-6719
- Schnaid, E., Lamprey, J. M., Viljoen, M. J., Joffe, B. I. & Seftel, H. C. (1987). The early biochemical and hormonal profile of patients with long bone fractures at risk of fat embolism syndrome. *The Journal of Trauma*, Vol.27, No.3, pp. 309-311, 0022-5282

- Schoenes, B., Bremerich, D. H., Risteski, P. S., Thalhammer, A. & Meiningner, D. (2008). Cardiac perforation after vertebroplasty. [Palacos im Herzen] *Der Anaesthetist*, Vol.57, No.2, pp. 147-150, 0003-2417
- Schonfeld, S. A., Ploysongsang, Y., DiLisio, R., Crissman, J. D., Miller, E., Hammerschmidt, D. E. & Jacob, H. S. (1983). Fat embolism prophylaxis with corticosteroids. A prospective study in high-risk patients. *Annals of Internal Medicine*, Vol.99, No.4, pp. 438-443, 0003-4819
- Schulz, F., Trubner, K. & Hildebrand, E. (1996). Fatal fat embolism in acute hepatic necrosis with associated fatty liver. *The American Journal of Forensic Medicine and Pathology*, Vol.17, No.3, pp. 264-268, 0195-7910
- Sevitt, S. (1962). Pathophysiology of systemic embolism-- the brain. In S. Sevitt (Ed.), *Fat embolism* (pp. 143). London, UK: Butterworth.
- Shareeff, M., Bhat, Y. M., Adabala, R. & Raoof, S. (2000). Shortness of breath after suicide attempt. *Chest*, Vol.118, No.3, pp. 837-838, 0012-3692
- Shields, D. J. & Edwards, W. D. (1992). Pulmonary hypertension attributable to neoplastic emboli: An autopsy study of 20 cases and a review of the literature. *Cardiovascular Pathology*, Vol.1, pp. 279-287, 1054-8807
- Shier, M. R. & Wilson, R. F. (1980). Fat embolism syndrome: Traumatic coagulopathy with respiratory distress. *Surgery Annual*, Vol.12, pp. 139-168, 0081-9638
- Shier, M. R., Wilson, R. F., James, R. E., Riddle, J., Mammen, E. F. & Pedersen, H. E. (1977). Fat embolism prophylaxis: A study of four treatment modalities. *The Journal of Trauma*, Vol.17, No.8, pp. 621-629, 0022-5282
- Shojai, R., Chau, C., Boubli, L. & D'Ercole, C. (2003). Amniotic fluid embolism during late term termination of pregnancy. *Prenatal Diagnosis*, Vol.23, No.11, pp. 950-951, 0197-3851
- Sinave, C. P., Hardy, G. J. & Fardy, P. W. (1989). The lemiere syndrome: Suppurative thrombophlebitis of the internal jugular vein secondary to oropharyngeal infection. *Medicine*, Vol.68, No.2, pp. 85-94, 0025-7974
- Soares, F. A., Pinto, A. P., Landell, G. A. & de Oliveira, J. A. (1993). Pulmonary tumor embolism to arterial vessels and carcinomatous lymphangitis. A comparative clinicopathological study. *Archives of Pathology & Laboratory Medicine*, Vol.117, No.8, pp. 827-831, 0003-9985
- Son, K. H., Chung, J. H., Sun, K. & Son, H. S. (2008). Cardiac perforation and tricuspid regurgitation as a complication of percutaneous vertebroplasty. *European Journal of Cardio-Thoracic Surgery : Official Journal of the European Association for Cardio-Thoracic Surgery*, Vol.33, No.3, pp. 508-509, 1010-7940
- Souders, J. E. (2000). Pulmonary air embolism. *Journal of Clinical Monitoring and Computing*, Vol.16, No.5-6, pp. 375-383, 1387-1307
- Stanten, R. D., Iverson, L. I., Daugharty, T. M., Lovett, S. M., Terry, C. & Blumenstock, E. (2003). Amniotic fluid embolism causing catastrophic pulmonary vasoconstriction: Diagnosis by transesophageal echocardiogram and treatment by cardiopulmonary bypass. *Obstetrics and Gynecology*, Vol.102, No.3, pp. 496-498, 0029-7844
- Stein, P. D., Yaekoub, A. Y., Matta, F. & Kleerekoper, M. (2008). Fat embolism syndrome. *The American Journal of the Medical Sciences*, Vol.336, No.6, pp. 472-477, 0002-9629

- Steiner, P. E. & Lushbaugh, C. C. (1941). Maternal pulmonary embolism by amniotic fluid as a cause of obstetric shock and unexpected deaths in obstetrics. *Journal of the American Medical Association*, Vol.117, pp. 1245-1254, 1341-1345, 0002-9955
- Stoeger, A., Daniaux, M., Felber, S., Stockhammer, G., Aichner, F. & zur Nedden, D. (1998). MRI findings in cerebral fat embolism. *European Radiology*, Vol.8, No.9, pp. 1590-1593, 0938-7994
- Stoffel, M., Wolf, I., Ringel, F., Stuer, C., Urbach, H. & Meyer, B. (2007). Treatment of painful osteoporotic compression and burst fractures using kyphoplasty: A prospective observational design. *Journal of Neurosurgery.Spine*, Vol.6, No.4, pp. 313-319, 1547-5654; 1547-5646
- Stoltenberg, J. J. & Gustilo, R. B. (1979). The use of methylprednisolone and hypertonic glucose in the prophylaxis of fat embolism syndrome. *Clinical Orthopaedics and Related Research*, Vol.(143), No.143, pp. 211-221, 0009-921X
- Stricker, K., Orler, R., Yen, K., Takala, J. & Luginbuhl, M. (2004). Severe hypercapnia due to pulmonary embolism of polymethylmethacrylate during vertebroplasty. *Anesthesia and Analgesia*, Vol.98, No.4, pp. 1184-6, table of contents, 0003-2999
- Svenningsen, S., Nesse, O., Finsen, V., Hole, A. & Benum, P. (1987). Prevention of fat embolism syndrome in patients with femoral fractures--immediate or delayed operative fixation? *Annales Chirurgiae Et Gynaecologiae*, Vol.76, No.3, pp. 163-166, 0355-9521
- Sviri, S., Woods, W. P. & van Heerden, P. V. (2004). Air embolism--a case series and review. *Critical Care and Resuscitation : Journal of the Australasian Academy of Critical Care Medicine*, Vol.6, No.4, pp. 271-276, 1441-2772
- Szabo, G., Magyar, Z. & Reffy, A. (1977). The role of free fatty acids in pulmonary fat embolism. *Injury*, Vol.8, No.4, pp. 278-283, 0020-1383
- Tachakra, S. C., Potts, D. & Idowu, A. (1990). Early operative fracture management of patients with multiple injuries. *The British Journal of Surgery*, Vol.77, No.10, pp. 1194, 0007-1323
- Talbot, M. & Schemitsch, E. H. (2006). Fat embolism syndrome: History, definition, epidemiology. *Injury*, Vol.37 Suppl 4, pp. S3-7, 0020-1383
- Talucci, R. C., Manning, J., Lampard, S., Bach, A. & Carrico, C. J. (1983). Early intramedullary nailing of femoral shaft fractures: A cause of fat embolism syndrome. *American Journal of Surgery*, Vol.146, No.1, pp. 107-111, 0002-9610
- Tapson, V. F. (2008). Acute pulmonary embolism. *The New England Journal of Medicine*, Vol.358, No.10, pp. 1037-1052, 1533-4406; 0028-4793
- Taviloglu, K. & Yanar, H. (2007). Fat embolism syndrome. *Surgery Today*, Vol.37, No.1, pp. 5-8, 0941-1291
- ten Duis, H. J. (1997). The fat embolism syndrome. *Injury*, Vol.28, No.2, pp. 77-85, 0020-1383
- ten Duis, H. J., Nijsten, M. W., Klasen, H. J. & Binnendijk, B. (1988). Fat embolism in patients with an isolated fracture of the femoral shaft. *The Journal of Trauma*, Vol.28, No.3, pp. 383-390, 0022-5282
- Thomas, J. E. & Ayyar, D. R. (1972). Systemic fat embolism. A diagnostic profile in 24 patients. *Archives of Neurology*, Vol.26, No.6, pp. 517-523, 0003-9942
- Tolentino, L. F., Tsai, S. F., Witt, M. D. & French, S. W. (2004). Fatal fat embolism following amphotericin B lipid complex injection. *Experimental and Molecular Pathology*, Vol.77, No.3, pp. 246-248, 0014-4800

- Tozzi, P., Abdelmoumene, Y., Corno, A. F., Gersbach, P. A., Hoogewoud, H. M. & von Segesser, L. K. (2002). Management of pulmonary embolism during acrylic vertebroplasty. *The Annals of Thoracic Surgery*, Vol.74, No.5, pp. 1706-1708, 0003-4975
- Tuffnell, D. J. (2005). United kingdom amniotic fluid embolism register. *BJOG : An International Journal of Obstetrics and Gynaecology*, Vol.112, No.12, pp. 1625-1629, 1470-0328
- van Haeften, T. W., Strack van Schijndel, R. J. & Thijs, L. G. (1989). Severe lung damage after amniotic fluid embolism; a case with haemodynamic measurements. *The Netherlands Journal of Medicine*, Vol.35, No.5-6, pp. 317-320, 0300-2977
- Van Liew, H. D., Conkin, J. & Burkard, M. E. (1993). The oxygen window and decompression bubbles: Estimates and significance. *Aviation, Space, and Environmental Medicine*, Vol.64, No.9 Pt 1, pp. 859-865, 0095-6562
- Vas, W., Tuttle, R. J. & Zylak, C. J. (1980). Intravenous self-administration of metallic mercury. *Radiology*, Vol.137, No.2, pp. 313-315, 0033-8419
- Vasconcelos, C., Gailloud, P., Beauchamp, N. J., Heck, D. V. & Murphy, K. J. (2002). Is percutaneous vertebroplasty without pretreatment venography safe? evaluation of 205 consecutive procedures. *AJNR. American Journal of Neuroradiology*, Vol.23, No.6, pp. 913-917, 0195-6108
- Veinot, J. P., Ford, S. E. & Price, R. G. (1992). Subacute cor pulmonale due to tumor embolization. *Archives of Pathology & Laboratory Medicine*, Vol.116, No.2, pp. 131-134, 0003-9985
- Verroust, N., Zegdi, R., Ciobotaru, V., Tsatsaris, V., Goffinet, F., Fabiani, J. N. & Mignon, A. (2007). Ventricular fibrillation during termination of pregnancy. *Lancet*, Vol.369, No.9576, pp. 1900, 1474-547X; 0140-6736
- Vichinsky, E. P., Neumayr, L. D., Earles, A. N., Williams, R., Lennette, E. T., Dean, D., . . . Mancini, E. A. (2000). Causes and outcomes of the acute chest syndrome in sickle cell disease. national acute chest syndrome study group. *The New England Journal of Medicine*, Vol.342, No.25, pp. 1855-1865, 0028-4793
- Villa, A. & Sparacio, F. (2000). Severe pulmonary complications after silicone fluid injection. *The American Journal of Emergency Medicine*, Vol.18, No.3, pp. 336-337, 0735-6757
- Wagner, E. (1865). Die fettembolie der lungen capillaren. *Arch Heilkunde*, Vol.6, pp. 146-147, 369-381, 481-491,
- Weinhouse, G. L. (January 2011). Fat embolism syndrome. *UpToDate*,
- Weisz, G. M. (1974). Fat embolism. *Current Problems in Surgery*, pp. 1-54, 0011-3840
- Winterbauer, R. H., Elfenbein, I. B. & Ball, W. C., Jr. (1968). Incidence and clinical significance of tumor embolization to the lungs. *The American Journal of Medicine*, Vol.45, No.2, pp. 271-290, 0002-9343
- Wu, A. S. & Fournery, D. R. (2005). Supportive care aspects of vertebroplasty in patients with cancer. *Supportive Cancer Therapy*, Vol.2, No.2, pp. 98-104, 1543-2912
- Yeom, J. S., Kim, W. J., Choy, W. S., Lee, C. K., Chang, B. S. & Kang, J. W. (2003). Leakage of cement in percutaneous transpedicular vertebroplasty for painful osteoporotic compression fractures. *The Journal of Bone and Joint Surgery. British Volume*, Vol.85, No.1, pp. 83-89, 0301-620X
- Yoo, K. Y., Jeong, S. W., Yoon, W. & Lee, J. (2004). Acute respiratory distress syndrome associated with pulmonary cement embolism following percutaneous vertebroplasty with polymethylmethacrylate. *Spine*, Vol.29, No.14, pp. E294-7, 1528-1159; 0362-2436



Pulmonary Embolism

Edited by Dr. Ufuk Çobanoğlu

ISBN 978-953-51-0233-5

Hard cover, 236 pages

Publisher InTech

Published online 14, March, 2012

Published in print edition March, 2012

Pulmonary embolism is a serious, potentially life-threatening cardiopulmonary disease that occurs due to partial or total obstruction of the pulmonary arterial bed. Recently, new improvement occurred in the diagnosis and treatment of the disease. The aim of this disease is to re-review pulmonary embolism in the light of new developments. In this book, in addition to risk factors causing pulmonary embolus, a guide for systematic approaches to lead the risk stratification for decision making is also presented. In order to provide a maximum length of active life and continuation of functional abilities as the aim of new interventional gerontology, the risk factors causing pulmonary embolus in elderly individuals are evaluated, and the approach to prevention and treatment are defined. The risk of the development of deep vein thrombosis and pulmonary embolism, combined with obesity due to immobility, the disease of this era, irregular and excessive eating, and treatment management are highlighted. Non-thrombotic pulmonary emboli are also covered and an attempt is made to constitute an awareness of this picture that can change the treatment and prognosis of the disease to a considerable extent. In addition to the pathophysiological definition of pulmonary embolus, the priority goal of quick and definitive diagnosis is emphasized, and diagnostic strategies are discussed in the book. A numerical analysis of the vena cava filters, which is a current approach to prevent pulmonary emboli recurrences, is presented in the last chapter.

How to reference

In order to correctly reference this scholarly work, feel free to copy and paste the following:

Vijay Balasubramanian, Malaygiri Aparnath and Jagrati Mathur (2012). Non-Thrombotic Pulmonary Embolism, Pulmonary Embolism, Dr. Ufuk Çobanoğlu (Ed.), ISBN: 978-953-51-0233-5, InTech, Available from: <http://www.intechopen.com/books/pulmonary-embolism/non-thrombotic-pulmonary-embolism>

INTECH

open science | open minds

InTech Europe

University Campus STeP Ri
Slavka Krautzeka 83/A
51000 Rijeka, Croatia
Phone: +385 (51) 770 447
Fax: +385 (51) 686 166
www.intechopen.com

InTech China

Unit 405, Office Block, Hotel Equatorial Shanghai
No.65, Yan An Road (West), Shanghai, 200040, China
中国上海市延安西路65号上海国际贵都大饭店办公楼405单元
Phone: +86-21-62489820
Fax: +86-21-62489821

© 2012 The Author(s). Licensee IntechOpen. This is an open access article distributed under the terms of the [Creative Commons Attribution 3.0 License](#), which permits unrestricted use, distribution, and reproduction in any medium, provided the original work is properly cited.