

White-Spot Lesions in Orthodontics: Incidence and Prevention

Airton O. Arruda, Scott M. Behnan and Amy Richter
*University of Michigan,
USA*

1. Introduction

The most common negative effect of orthodontic treatment with fixed appliances is the development of incipient carious lesions around brackets. The objectives of this chapter are to present some of the results of two studies aiming: 1) to evaluate patients treated with comprehensive orthodontics to determine the incidence of new carious lesions during treatment; and 2) to investigate the potential of ACP-containing resin cement and other treatments (fluoride varnish, resin sealer, MI Paste) to prevent incipient carious lesions on bracketed teeth. In the first study, 350 orthodontic patients were selected randomly. The pre- and post-treatment photographs of the patients were examined to determine lesion development. The labial surface of each tooth was scored with a standardized system based on the *International Caries Determination and Assessment System II*. The independent variables were collected by chart abstraction. In the second study, 100 extracted human premolars were allocated randomly to five groups (N = 20). Brackets were bonded with ACP-cement (Aegis-Ortho), Transbond

XT (Control), Transbond XT followed by application of fluoride varnish (Vanish), resin sealer (Pro-seal) and CPP-ACP paste (MI Paste). All teeth were pH cycled for 15 days in demineralization solution and artificial saliva. The extent of demineralization in each group was assessed using Quantified Light-induced Fluorescence (QLF) and Confocal Laser Scanning Microscopy (CLSM). The incidence of patients who developed at least one new white-spot lesion during treatment was 73%. Treatment length was associated significantly with new white-spot lesion development. The independent variables of gender, age and extraction/non-extraction were not associated with lesion development. Fluorescence loss and lesion depth measurements demonstrated that the Pro-seal and Vanish groups had the least amount of demineralization. The control group showed the most demineralization. Although the MI Paste and Aegis-Ortho groups experienced less demineralization than controls, neither was significant statistically. Only the Pro-seal and Vanish groups had significantly smaller lesions than the control group for both QLF and CLSM. Thus, the development of new lesions appeared to be related to treatment duration and, to a lesser degree, to initial oral hygiene score. Light-cured filled sealer (Pro-seal) and the fluoride varnish (Vanish) have the potential to prevent enamel demineralization adjacent to orthodontic brackets exposed to cariogenic conditions.

2. White-spot lesions

One of the most common negative side effects of orthodontic treatment with fixed appliances is the development of incipient caries lesions around brackets and bands, particularly in cases with poor oral hygiene (Fig. 1). Caries lesions typically form around the bracket interface, usually near the gingival margin (Gorelick *et al.*, 1982). Certain bacterial groups such as mutans streptococci and lactobacilli ferment sugars to create an acidic environment that over time might lead to the development of dental caries. Since orthodontic appliances make plaque removal more difficult, patients are more susceptible to carious lesions. The irregular surfaces of brackets, bands, wires, and other attachments also limit naturally occurring self-cleaning mechanisms, such as movement of the oral musculature and saliva (Rosenbloom and Tinanoff, 1991).

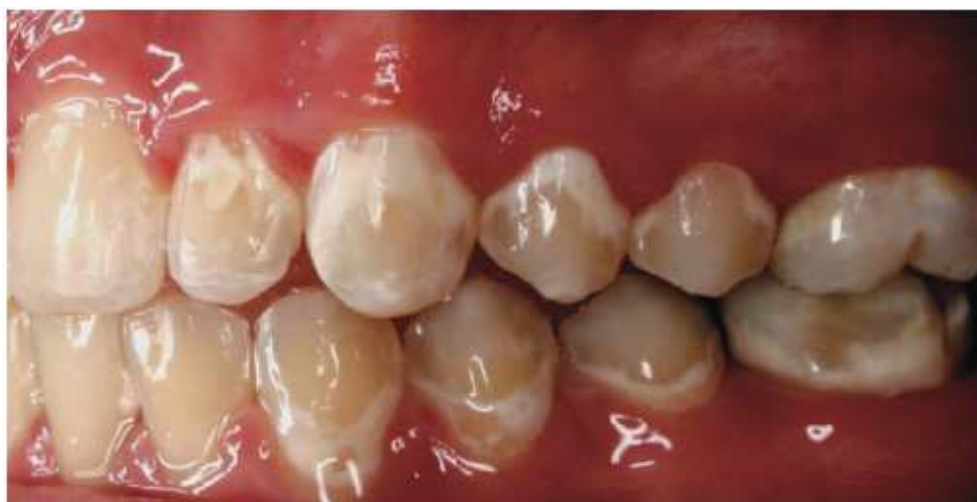

Fig. 1. Incipient caries lesions (white spots) develop around brackets and bands due to poor oral hygiene

Incipient lesions are characterized by their opacity, mineral loss, and decrease of fluorescence radiance when compared to healthy enamel surfaces. Many incipient enamel lesions have a white appearance due to an optical phenomenon caused by mineral loss in the surface and sub-surface that alters the refractive index and increases the scattering of light in the affected area, all resulting in greater visual enamel opacity.

Studies have shown that white spot lesions can take only one month to develop (Øgaard *et al.*, 1988; O'Reilly and Featherstone, 1987; Gorton and Featherstone, 2003). A clinical study reported the prevalence at 50% (Gorelick *et al.*, 1982), while recent investigations put the incidence of white spot lesions in the orthodontic populations studied at 73-95% (Richter *et al.*, 2009; Lovrov *et al.*, 2007). Orthodontists and patients will notice these lesions after removal of the fixed appliances, especially since the white spots tend to form in the maxillary esthetic zone (Gorelick *et al.*, 1982; Banks and Richmond, 1994). While some studies have reported a decrease in the display of white spot lesions over time post-

orthodontic treatment, these unesthetic spots tend to remain unless they are resolved with more aggressive treatment, such as minimally invasive or even full restorative dentistry (Øgaard, 1989; Årtun and Thylstrup, 1989).

3. Measures to counteract this problem

3.1 Oral hygiene

The first line of defense against the development of incipient caries lesions has traditionally been patient education, with a special emphasis on optimal oral hygiene. The advocacy organization for orthodontists in the United States known as the American Association of Orthodontists (AAO) has developed patient manuals and a website to provide recommendations for patients undergoing orthodontic treatment (AAO, 2009). Specifically, the website suggests extra time for toothbrushing, specialized tips to get in between the braces, floss threaders, oral irrigators, and over-the-counter mouthrinses. Additionally, the AAO sponsored informed consent form emphasizes the need for excellent oral hygiene and routine visits to the general dentist (AAO, 2005). It also warns that inadequate oral hygiene could result in caries, discolored teeth, and periodontal disease. Finally, the form explains that the aforementioned problems may be aggravated if the patient has not had the benefit of fluoridated water. In many cases, patient education will also include an emphasis on proper diet with reduced intake of sugars. Despite these efforts by the orthodontist and staff members, many patients will still be non-compliant with oral hygiene instructions. Unfortunately, most orthodontists have a limited background in the behavioral basis of compliance (Mehra *et al.*, 1998). Thus, patient non-compliance presents a unique challenge to orthodontic practices.

3.2 Fluoride during orthodontic treatment (rinses, etc)

In addition to reinforced oral hygiene instructions, orthodontists have turned to various products and preventive measures to reduce this problem. Dental professionals have employed fluoride for years to prevent caries and remineralize enamel in patients. A systematic review found a reduced level of caries and adolescents who have regular supervised rinsing with a fluoride mouthwash (Marinho, 2004). Daily fluoride rinses have shown promising results, and a significant reduction in enamel lesions can be achieved during orthodontic therapy through the daily use of a 10 mL neutral 0.05% sodium fluoride rinse. However, typical patient compliance rates with this protocol have been relatively low (Geiger *et al.*, 1992).

3.3 Fluoride varnish

Preventive measures that do not require patient compliance would seem to make more sense for the typical orthodontic patient population of adolescents. For some patients, professional fluoride varnish application by orthodontic auxiliaries at routine appointments can in part address this compliance issue (Vivaldi-Rodrigues *et al.*, 2006). On the other hand, each application requires over five minutes of chair-time, and whether or not today's high efficiency/high volume orthodontic practice will devote the time and resources to apply this protocol is debatable. Generally however, fluoride varnishes have a proven track record in caries reduction when applied properly. Vanish (3M/Omni) is a very popular 5% NaF white

varnish used for prevention of dental caries. The manufacturer advertises the ease of use, lack of an unesthetic yellow color found in other varnishes, enhanced flow characteristics, and its fluoride delivery of 22,600 ppm. Its name comes from an alleged ability to disappear after application. Data gathered by the manufacturer declare greater fluoride release over a 48-hour period in comparison to other fluoride products. To date, Vanish in particular has not been tested in any of the *in-vitro* or *in-vivo* trials in the literature.

3.4 Resin sealer

Just as sealants have been shown to prevent caries in molars with deep fissures, resin-based sealers have been applied on facial surfaces of bracketed teeth to prevent enamel caries. In addition to the increased chair-time for this procedure, earlier generations of resin sealers have been found to have very low wear resistance. Previous studies have proven that most of the chemically cured sealants (Zachrisson *et al.*, 1979) do not effectively seal smooth enamel surfaces, because of oxygen inhibition of polymerization when the sealant is in contact with the air in a thin layer. Instead, only "islands" of cured sealant remain where resin pooling occurs. Even light-cured sealants (Banks and Richmond, 1994) that were unfilled or lightly filled could not provide any more protection than the chemically cured sealants. A more recent developed product Pro-seal (Reliance, Itasca, IL) has been marketed as a sealer that is more resistant to toothbrush abrasion than earlier generations, since it is a highly filled resin. In patients with poor oral hygiene, Pro-seal can be added before bracket bonding or after bonding. Additionally, the manufacturer claims that Pro-seal releases fluoride, which further enhances its anticariogenic properties.

3.5 ACP/ CPP-ACP

Recently, there has been increased interest and development in calcium phosphate-based remineralization technology (Reynolds and del Rio, 1984; Rosen *et al.*, 1984). One of the newest modalities in preventive dentistry is the introduction of amorphous calcium phosphate (ACP) into methacrylate composites, gum, pastes, and other dental products. Casein is the predominant phosphoprotein in bovine milk and accounts for almost 80 percent of its total protein, primarily as calcium phosphate stabilized micellular complexes (Aimutis, 2004). Several laboratory and animal experiments have investigated the low cariogenic potential and the possible cario-static activity of dairy products (milk, casein, caseinates and cheeses). The use of casein as an anticariogenic additive to food, toothpaste or drinking water has not been implemented because of its adverse organoleptic properties and the large amount required for efficacy (Reynolds, 1998).

Casein phosphopeptide (CPP) contains the cluster sequence of -Ser (P)-Ser (P)-Ser (P)-Glu-Glu from casein (Iijima *et al.*, 2004). CPP does not have the limitations of casein, has the potential for specific anticariogenic activity, and is at least 10 times greater on a weight basis than it is for casein (so not as much is needed for it to be effective). CPP can remarkably stabilize calcium phosphate (which usually is highly insoluble) in a state-forming CPP-amorphous calcium phosphate (ACP) complex. There is no conclusive evidence that ACP is an integral mineral component in hard tissues. Its advocates theorize that it likely plays a special role as a precursor to bioapatite and as a transient phase in biomineralization. In solutions, ACP is converted readily to stable crystalline phases such as octacalcium phosphate or apatitic products (Mathew and Takagi, 2001). Reynolds and colleagues have

proposed that under acidic conditions, localized CPP-ACP buffers the free calcium and phosphate ions, substantially increasing the level of calcium phosphate in plaque and, therefore, maintaining a state of supersaturation that inhibits enamel demineralization and enhances remineralization (Reynolds *et al.*, 1999). Rose conducted a laboratory experiment in which he showed that CPP-ACP binds well to dental plaque, providing a large calcium reservoir that may inhibit demineralization and assist in subsequent remineralization (Rose, 2000).

This technology has entered the orthodontic marketplace in two different forms: resin bracket bonding cement containing ACP and topical paste containing the CPP-ACP complex. Aegis-Ortho, an ACP-including resin bonding cement, has been marketed by Bosworth (Skokie, IL) as a substitute for ordinary bracket bonding cement, with the added benefit of caries prevention. The manufacturer claims that the acidic challenge (pH at or below 5.8) to the surrounding bracket area will trigger the release of calcium and phosphate from the cement, and a supersaturated calcium phosphate matrix will not only inhibit demineralization, but also remineralize the enamel. ACP-filled composite resins have been shown to recover 71% of the lost mineral content of demineralized teeth (Skrtic *et al.*, 1996).

A similar chemical process is manifested with MI paste (GC America, Alsip, IL). Instead of residing in the resin cement, the casein phosphopeptide-amorphous calcium phosphate (CPP-ACP) is applied topically in the mouth to affected areas. The manufacturer implicates this product not only lesion prevention (applied twice daily after brushing throughout orthodontic treatment), but also claims the patient can expect the complete reversal of such lesions after three months use post-debonding. Additionally, the manufacturer has recommended MI paste for dental patients with xerostomia, dental sensitivity, gastric reflux, fluorosis, exposed root surfaces, and as an adjunct to tooth bleaching.

4. Current level of evidence

4.1 Fluoride varnish

A myriad of *in-vivo* and *in-vitro* studies have been carried out to study the efficacy of preventive measures against white spot lesion formation during orthodontic treatment. Fluoride varnish has by far the strongest evidence base. The potential of fluoride varnish has been evaluated *in-vitro* (Adriens *et al.*, 1990; van der Linden and Dermaut, 1998; Todd *et al.*, 1999; Demito *et al.*, 2004) as well as *in-vivo* (Vivaldi-Rodrigues *et al.*, 2006; Øgaard *et al.*, 2001). Generally, investigations carried out *in-vitro* indicate a moderate to strong beneficial effect of the tested varnishes on enamel demineralization. Two *in-vivo* studies have emerged. In a split-mouth prospective study, there was 44.3% less demineralization noted for teeth that had been treated every 12 weeks with fluoride varnish during orthodontic treatment (Vivaldi-Rodrigues *et al.*, 2006). In a double-blinded randomized placebo-controlled trial, Stecksén-Blicks *et al.* reported that although fluoride varnish did not totally prevent white spot lesion formation, the incidence was significantly reduced in the fluoride varnish group. In addition to differences in study design, the frequency of fluoride application also varied among the studies. Stecksén *et al.* applied the fluoride varnish at six week intervals, the typical appointment interval for most orthodontic patients.

4.2 Resin sealer

After less successful earlier sealers, findings about the application of a filled-resin sealer (Pro-seal) have been published in the literature. One *in-vitro* study using an acid challenge found that demineralization was significantly less with Pro-seal treatment, compared to an untreated enamel surface (Hu and Featherstone, 2005). In fact, the demineralization levels established by microhardness profiles showed that the Pro-seal group had 98% less demineralization than the control group. This study also featured a group of teeth treated with fluoride varnish. While both the Pro-seal and fluoride varnish had significantly less demineralization than the control group, the sealer had significantly less demineralization than the varnish. Furthermore, the study also found that Pro-seal can stand up to acid challenge and toothbrush abrasion in a laboratory environment. These outcomes were corroborated by another *in-vitro* study, that also found that the filled-resin sealer (Pro-seal) provided significantly more protection than either fluoride varnish or an unfilled resin sealer, with a 92% reduction in lesion depth compared with the controls using polarized light microscopy (Buren *et al.*, 2008). In looking at its supposed fluoride release, one study found that Pro-seal released fluoride ions in a sustained way - with significantly decreasing amounts over a 17-week period, though this release was measured to be sub-ppm (Soliman *et al.*, 2006). Despite some favorable results with *in-vitro* models, no *in-vivo* trials with Pro-seal have been published in the literature.

4.3 Amorphous calcium phosphate (ACP)

4.3.1 CPP-ACP paste

Due to the early stages of this technology, published independent research on the ACP products like MI Paste is limited. Generally, the studies on caries prevention with CPP-ACP consist of *in-situ* caries models with gums, mouthrinses, or lozenges (Iijima *et al.*, 2004; Reynolds *et al.*, 2003). In addition, the vast majority of these studies were carried out by the same group that first isolated CPP-ACP at the University of Melbourne, Australia. For example, using topical applications of CPP-ACP via sugar-free chewing gum and mouthrinse, Reynolds *et al.* showed that CPP-ACP incorporated into dental plaque can significantly increase the levels of plaque calcium and phosphate ions (Reynolds *et al.*, 2003). Conversely, an *in-vitro* study carried out by an American group found that while fluoride 5000 ppm paste had a statistically significant protective effect against demineralization on enamel sections, MI Paste had no effect (Pulido *et al.*, 2008). There are two published studies that examine the role of CPP-ACP paste in orthodontics. In an *in-vitro* study that assessed the demineralization around bonded molar tubes on extracted third molars, a mild decrease in demineralization was found with the application of CPP-ACP (Sudjalim *et al.*, 2007). On the other hand, the authors of this very article recommended combining CPP-ACP with a fluoride gel to enhance the treatment effect. For the most part, clinicians loyal to the CPP-ACP protocol apply it without a fluoride gel, and the brochures by the manufacturer make no mention of additional rinses or gels. Andersson *et al.* conducted an *in-vivo* post-orthodontic treatment study, in which they compared the remineralization capabilities of 0.05% Sodium Fluoride mouthwash and the application of Topacal (CPP-ACP topical cream) on patients with white spot lesions. The study found significant remineralization with both protocols, and found no significant differences between the groups over time.

Still, the authors pointed out that the remineralization that occurred with CPP-ACP treatment was generally more esthetic than with the fluoride rinse.

4.3.2 ACP-containing bonding cement

As for ACP bonding cement products like Aegis-Ortho, there are currently no published comparative studies on its ability to prevent white spot lesions in the peer-reviewed literature. Two reports detail the questionable bond strength of ACP-containing cement. In spite of its potential benefits, frequent bond failures with ACP-cement have been reported. An *in-vitro* study with an earlier generation of Aegis-Ortho showed that orthodontic brackets bonded to teeth with an ACP-containing composite material failed at significantly lower forces than brackets bonded to teeth with a conventional resin-based composite orthodontic cement (Dunn, 2007). Another *in-vitro* study found that brackets bonded with the conventional Transbond XT had more than two times the shear bond strength in comparison to brackets bonded with Aegis-Ortho cement (Foster *et al.*, 2008). In evaluating the current evidence base for ACP and its various products, the number of published *in-vitro* and *in-vivo* trials is clearly underwhelming. In a 2008 systematic literature review published in the Journal of the American Dental Association (JADA), the authors concluded that there is insufficient clinical trial evidence to make a recommendation regarding the long-term effectiveness of casein derivatives, specifically CPP-ACP, in preventing caries *in-vivo* (Azarpazhooh and Limeback, 2008).

5. Summary of evidence

Of all the treatments for incipient caries lesions during orthodontic treatment, agents with fluoride including varnish have the highest level of evidence. Multiple laboratory and clinical studies have demonstrated its efficacy. Highly-filled resin sealers like Pro-seal are relatively new, although the results from a few *in vitro* studies have demonstrated impressive results. On the other hand, a clinical study on its demineralization prevention has not yet surfaced. At this juncture, the evidence level for ACP products like CPP-ACP paste or ACP resin bonding cement is low. There is a clear need for more independent research of casein derivatives like CPP-ACP to make conclusions about its efficacy in caries prevention.

6. Clinical status quo

In terms of the clinical status quo for prevention of incipient caries lesions during orthodontic treatment, one has to first reference the AAO sponsored informed consent form, in which there is an emphasis on excellent oral hygiene, regular visits to the general dentist, and access to fluoridated water (AAO, 2009). In looking at practice trends, a recent survey by the Journal of Clinical Orthodontics does provide some information about the usage of some of the preventive measures previously outlined (Keim *et al.*, 2008). Despite its proven efficacy, only 9.3% of orthodontists deliver fluoride varnish to their patients. The article also mentions that only 7.4% of orthodontists employ the fluoride-releasing glass ionomer adhesive for bracket bonding, which is understandable given its questionable physical properties. There were no data in the article detailing the usage of ACP products or resin sealers. In any event, the fact that more than half of orthodontic patients develop incipient

caries lesions (Gorelick *et al.*, 1982; Richter *et al.*, 2009) and that only 9.3% of orthodontists give their patients fluoride varnish (Keim *et al.*, 2008), raises questions about emphasis of preventive care in today's orthodontic practice.

7. Need for investigation

Due to high caries incidence, low patient compliance, and low usage of fluoride varnish by orthodontists, there appears to be a need for a better treatment modality for patients undergoing orthodontic treatment. Regardless of the exact prevalence rate for white spot lesion development, most dental professionals would agree that it is currently far too high. While adjuncts to treatment such as fluoride rinse can potentially reduce the incidence of white spot lesions, the required compliance of high caries-risk patients is dubious. Equally troublesome, available non-compliant and proven treatments like professionally applied fluoride varnish have failed to catch the attention of practicing orthodontists. The resin sealer (Pro-seal) seems to address the patient compliance issue, but if orthodontists have neither the time nor the interest to deliver fluoride varnish, their likelihood of investing the resources and chair time to etch and light cure Pro-seal on twenty teeth is probably low. Aegis-Ortho bracket cement containing ACP seems to address all these issues. It does not require patient compliance, and it does not require any additional chair time in the office, since time allotted for orthodontic bracket bonding is already a part of the treatment plan. In spite of some reports, which document a low bond strength of its earlier generations, if ameliorated, this product holds immense potential for preventive care during orthodontic treatment. First however, there is a need to test and document the preventive properties of ACP-containing bracket cement with *in-vitro* studies.

8. Methods to assess demineralization

With a heightened interest in evidenced-based dentistry, the dental research community has over the years employed various modes of technology to quantify extent of enamel demineralization. The ideal method of assessment should be simple, noninvasive, reproducible, and precise. The following is brief description of four commonly employed techniques (TMR, PLM, QLF, and CLSM).

8.1 Microradiography

Transverse Microradiography (TMR) or contact-microradiography is one of the most widely accepted methods used to assess demineralization and remineralization in dental hard tissues in *in-situ* and *in-vitro* studies. It is a highly sensitive method to measure the morphology of and the change in mineral content of enamel and dentin samples (Arends and Ten Bosch, 1992). In TMR the tooth sample to be investigated is cut into thin slices (about 80 μm and 200 μm for dentine samples). A microradiographic image is made on high resolution film by X-ray exposure of the sections together with a calibration stepwedge. The microradiogram is digitized by a video camera or photomultiplier. The mineral can be automatically calculated from the gray levels of the images of section and stepwedge using a custom-made software. In examining the reliability of TMR, Exterkate *et al.* found that repeated microradiographs of the same thin enamel sections resulted in a negligible spread in mineral loss among them (Exterkate *et al.*, 1993). Such reliability and the more recent

application of computer imaging make microradiography a standard method used in caries research for the assessment of lesion profiles.

8.2 Polarized light microscopy

Polarized light evaluations of enamel sections have been useful in describing the early caries lesion and alterations in structure upon further demineralization or remineralization. Generally, it provides information on absorption color and boundaries between minerals of differing refraction indices. Materials such as enamel act as beam splitters and divide light rays into two parts. Polarized Light microscopy (PLM) in turn exploits the interference of split light rays, as they are reunited along the same optical path to extract information about materials. Essentially, polarized light microscopy allows the visualization of areas with different porosities. The histologic features seen under a polarized light microscope allow the examiner to distinguish carious and non-carious enamel by their respective distribution of pores (Gwinnett, 1966). Polarized light examination of enamel specimens is a well-established procedure in which it is customary to view quinoline-imbibed sections orientated so that normal enamel is blue/green in color (Gilmour and Edmunds, 1998).

8.3. Quantitative light-induced fluorescence

Quantitative Light-induced Fluorescence (QLF) is one method of assessing levels of enamel demineralization. With QLF, real-time fluorescent images are captured into a computer and stored in an image database. Optional quantitative analysis tools enable the user to quantify parameters like mineral loss, lesion depth, lesion size, stain size and severity with high precision and repeatability. The QLF method is based on the auto-fluorescence of teeth. When teeth are illuminated with high intensity blue light they will start to emit light in the green part of the spectrum. When enamel demineralization takes place, minerals are replaced mainly by water from saliva, causing a decrease in the light path in the tooth substance. This results in less light absorption by enamel. Because fluorescence is a result of light absorption, the intensity of fluorescence decreases in demineralized regions of the enamel, which appear darker than sound tooth structures (de Josselin *et al.*, 1995; al-Khateeb *et al.*, 1998; Rousseau *et al.*, 2002). Thus, the fluorescence of the dental tissue has a direct relation with the mineral content of the enamel. The effectiveness of QLF for measurement of enamel demineralization has been demonstrated in several studies. The use of QLF allows for quantitative analysis has been reported to be well correlated (0.73-0.83) with the degree of mineral loss from early enamel lesions *in-vitro* when measured by longitudinal microradiography. (Hafstrom-Bjorkman *et al.*, 1992; Emami *et al.*, 1996; Lagerweij *et al.*, 1996). The use of QLF as a method of following caries development during orthodontic treatment has been suggested and encouraged by the results of several *in-vitro* studies. (Benson *et al.*, 2003 and Pretty *et al.*, 2003). Recent studies also indicate that QLF is suitable for *in-vivo* monitoring of mineral changes in incipient enamel lesions (Van der Veen *et al.*, 2000 and Al Khateeb *et al.*, 2002).

8.4 Confocal laser scanning ,icroscopy

Confocal Laser Scanning Microscopy (CLSM) is yet another method of assessing enamel demineralization. This technique accelerates and simplifies the measuring of mineral loss. The enamel specimens are sectioned in half, stained with fluorescent dye, and analyzed

using a CLSM system (Fontana *et al.*, 1996). The major advantage of this method is that it enables quantitative analysis of thick samples without the problems of thin section preparation required for microradiography or polarized light microscopy. Essentially, CLSM allows a subsurface examination since the scattered, reflected, and fluorescent light from planes out of focus is eliminated – providing a subsurface image only from a thin layer upon which it is focused. This processed digital image can be used to determine surface features, area and volume analysis of given structures, and views of the total structure from any angle in three dimensions. In terms of efficacy, a statistically significant high correlation was found between mineral changes measured using microradiography and the changes in lesion parameters analyzed by confocal microscopy (González-Cabezas *et al.*, 1998)

With all the treatment modalities flooding the marketplace, the orthodontist might find it difficult to sort out what works best and why when oral hygiene deteriorates. The objectives of this chapter are to highlight the results of two recent studies that investigated:

1. The incidence of new WSLs before and after orthodontic treatment using photographic records; and
2. The potential of ACP-containing resin cement and other treatments (fluoride varnish, resin sealer, MI Paste) to prevent incipient caries lesions next to bracketed teeth.

9. Methods and materials: Part I

9.1 Selection of subjects

From a population of 2,296 patients treated in the graduate orthodontic clinic at the University of Michigan School of Dentistry (UMSD) between 1997 and 2004, 350 patient records were selected randomly using a random number sequence. Inclusion criteria for record selection consisted of patients who:

1. Underwent comprehensive orthodontic treatment utilizing full fixed appliances on labial tooth surfaces;
2. Had complete initial and final series of intraoral photographs; and
3. Had complete treatment log information within their chart.

9.2 Chart abstraction

Data collection from de-identified patient charts included gender and age at initiation of orthodontic treatment, and treatment variables such as extraction therapy and comprehensive treatment time. Comprehensive treatment time was defined as the period between initiation of full fixed appliance therapy and removal of all active fixed appliances. Initial oral hygiene score, frequency of oral hygiene discussion, oral hygiene instruction and fluoride application and/or rinse were recorded from progress notes in the chart.

9.3 Photography

Intraoral pre-treatment (initial) and post-treatment (final) photographs of each patient were taken as part of standard orthodontic recordkeeping procedures. All photographs, stored as 35 mm slides, were taken in the Clinical Photography Department at the UMSD by two professional photographers utilizing a standardized intraoral photography procedure.

Individual slides were scanned into digital format using a Nikon Slide Feeder SF-200 (S) and Super Coolscan 4000 ED scanner. Scanned images were enlarged 325% and imported into an individual Microsoft PowerPoint presentation for each patient.

9.4 Dental caries determination

Images were evaluated by trained investigators using a scoring system specifically adapted for use with photographed images (*International Caries Detection and Assessment System II*; Ismail, 2005). Visible labial surfaces examined included maxillary and mandibular central and lateral incisors, canines, first and second premolars, and first molars. The evaluators scored each visible labial tooth surface before and after orthodontic treatment. The scores were combined to determine the labial caries incidence for each patient. Teeth were examined and scored from first molar to first molar, maxilla and mandible (Fig. 2).

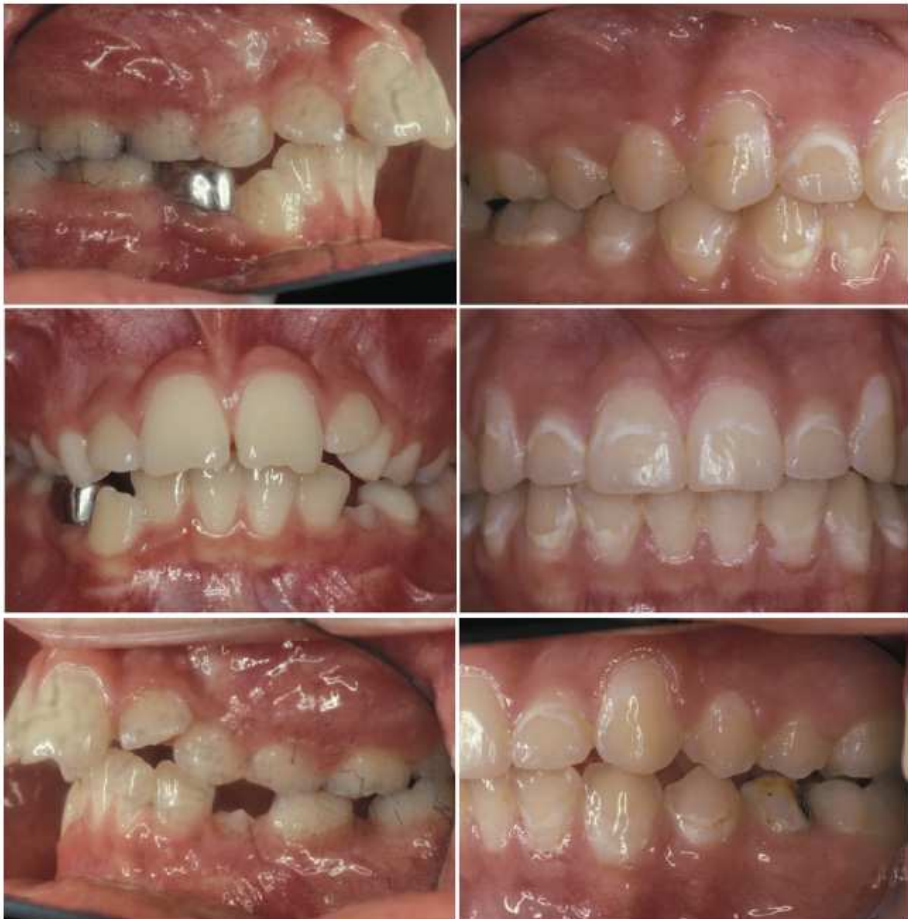

Fig. 2. Tooth labial surfaces were examined and scored from left first molar to right first molar, maxilla and mandible, before and after orthodontic treatment.

10. Results: Part I

The overall incidence of patients who developed at least one WSL during orthodontic treatment was 72.9% (N = 255; Table 1 and Fig. 3), while for newly developed cavitated lesions that were unrestored on the final record was 2.3%. Of the eight patients that developed cavitated lesions during orthodontic treatment, four (1.1%) developed one new cavitated lesion, three (0.9%) developed two new cavitated lesions and one (0.3%) developed four new cavitated lesions. Of the maximum 24 surfaces investigated per patient, on average 4.2 surfaces in each patient showed new WSL. The average of surfaces with new cavitations was only 0.04 and 0.05 with restorations. Even though infrequently, some early WSL regressed to sound (0.07 per patient). Demographic variables of gender and age at initiation of treatment were not related significantly to development of new decalcified or cavitated lesions. There was a significant relationship between increased treatment length and number of newly developed lesions ($P = 0.03$; Table 2). The mean number of labial surfaces per patient that developed new WSL was 3.01 for patients with a treatment length of less than 22 months. This increased to 5.28 teeth for patients with therapy longer than 33 months. The number of new cavitations, however, showed only a nonsignificant trend ($P = 0.08$) with increased treatment time. In addition, the number of newly developed lesions (both WSL and cavitations) showed no significant association with extraction or non-extraction treatment protocols (Table 3). Although no relationship was demonstrated between pretreatment oral hygiene scores and lesion development, the recorded number of oral hygiene discussions between provider and patient were associated significantly with development of both white-spot ($P < 0.0001$) and cavitated ($P = 0.0006$) lesions. The mean number of new lesions for patients with whom oral hygiene discussions had never been noted in the chart was 3.08, while the mean number of decalcified lesions for patients who were given oral hygiene instruction on three or more occasions increased to 7.78. A similar increase was exhibited for the mean number of cavitated lesions for patients given three or more oral hygiene discussions (mean = 0.20) *vs.* those with whom oral hygiene was not discussed after initial instruction (mean = 0.01). Age group ($P = 0.03$), treatment length ($P = 0.01$) and number of oral hygiene discussions ($P < 0.0001$) were associated with development of WSL. There was a decrease in WSLs associated with increasing age group (regression coefficient = -0.59). An increase in WSLs was associated with both increased treatment time (regression coefficient = 0.07) and increased number of oral hygiene discussions (regression coefficient = 1.88).

11. Methods and materials: Part II

11.1 Sample preparation

One hundred human premolar teeth were collected from various oral surgery practices located in southeast Michigan. Only premolars presenting a healthy facial enamel surface were included. All teeth were assigned randomly to five equal groups of 20 teeth. One of the groups had brackets bonded with Aegis-Ortho resin cement while the remaining groups were bonded with Transbond XT. Of the four Transbond XT groups, one served as a control, another received Vanish (3M, Espe, MN) fluoride varnish, another received MI Paste and the final received a coat of Pro-seal as adjunctive treatments.

11.2 Demineralization protocol

Teeth were exposed to a pH cycling system to develop caries-like lesions. Each day teeth were incubated in demineralization solution (lactic acid and Carbopol [pH = 5.0], 50% saturated with hydroxyapatite) for eight hours, rinsed with de-ionized water and placed in artificial saliva for 30 minutes, followed by two seconds of brushing with a powerbrush (Sonicare, Philips) and fluoridated dentifrice (NaF, 1,100 ppm F), rinsed again and placed back in artificial saliva until next demineralization period (next day).

Number of teeth with newly developed WSL	Frequency of patients (N)	Percent of total patients	Cumulative frequency	Cumulative percent
0	95	27.1	95	27.1
1	57	16.3	152	43.4
2	48	13.7	200	57.1
3	18	5.1	218	62.2
4	21	6.0	239	68.3
5	18	5.1	257	73.4
6	21	2.3	265	75.7
7	11	3.1	276	78.9
8	10	2.8	286	81.7
9	9	2.6	295	84.3
10	6	1.7	301	86.0
11	5	1.4	306	87.4
12	8	2.3	314	89.7
13	6	1.7	320	91.4
14	5	1.4	325	92.9
15	7	2.0	332	94.9
16	5	1.4	337	96.3
17	4	1.1	341	97.4
18	4	1.1	345	98.6
19	1	0.3	346	98.9
20	2	0.6	348	99.4
21	1	0.3	349	99.7
22	1	0.3	350	100.0

Table 1. Incidence of white-spot lesions (WSLs)

Solutions were refreshed daily during the experimental period of 15 days. On day 15, all teeth were removed from the saliva solution, rinsed under tap water and stored in 100% humidity. To assess demineralization, Quantitative Light-induced Fluorescence (QLF) and Confocal Laser Scanning Microscopy (CLSM) were used. Both procedures were carried out at the Oral Health Research Institute (IU) in Indianapolis, IN.

Variable	Parameter estimate	Standard error	t-value	P-value
Sex	-0.73	0.55	-1.33	0.19
Age group	-0.59	0.28	-2.12	0.03*
Treatment length	0.07	0.02	2.76	0.01*
Initial oral hygiene score	-0.08	0.56	-0.14	0.89
Number of oral hygiene discussions	1.88	0.39	4.86	<0.00*

*= P- value significant at $P < 0.005$.

Table 2. Multivariable regression model.

Age	Trend, fewer new lesions as age increases
Treatment length	Trend, 0.08 new lesions per month of treatment
Oral hygiene	Counter-intuitive trend, number increases as number of discussions increased

Table 3. Inferential statistics. Adjusted R-square = 0.11. This model accounts for 11% of the variation in WSL development.

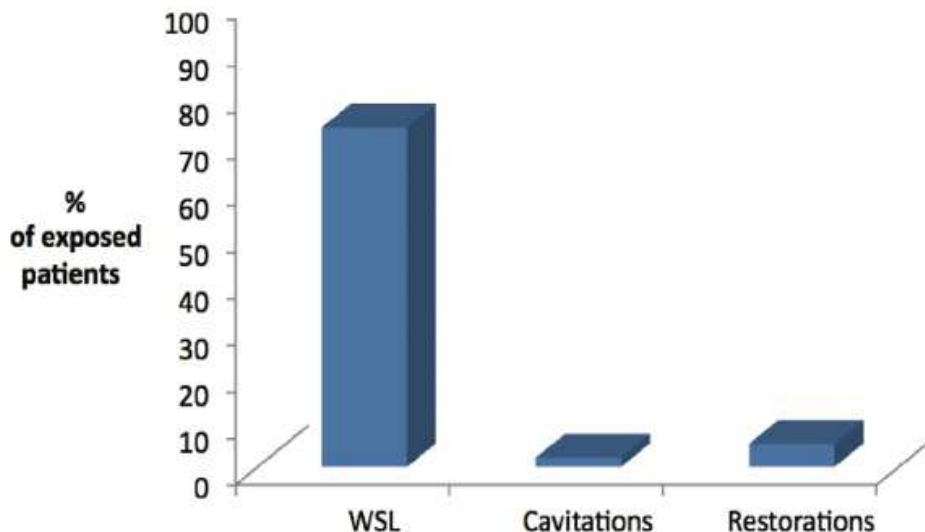


Fig. 3. Distribution of patients with at least one new lesion.

12. Results: Part II

Demineralization assessed by QLF is shown in Table 4. The Proseal group had the least amount of fluorescence loss followed by the Vanish group. Aegis-Ortho group, MI Paste group and the control group (Transbond) had the most fluorescence loss and were not different significantly. Demineralization assessed by CLSM is shown in Table 5. No detectable lesion depth was seen in any of the specimens of Pro-seal and Vanish groups. The greatest lesion depth was found in the control group (Transbond), but it was not different significantly from Aegis-Ortho and MI Paste.

<i>Treatment Group</i>	<i>Mean ΔF</i>	<i>SD</i>
TbXT + Pro-seal	-7.0	4.4
TbXT + Vanish	-19.7	3.5
* Aegis-Ortho	-22.9	3.7
* TbXt + MI Paste	-25.0	6.2
* Transbond XT (TbXT) – Control	-29.6	8.2

*Groups not different significantly ($P>0.05$). ΔF =fluoresce loss.

Table 4. Loss of fluorescence per group(N=20).

<i>Treatment Group</i>	<i>Mean ΔF</i>	<i>SD</i>
TbXT + Pro-seal	0.0	0.0
TbXT + Vanish	0.0	0.0
* Aegis-Ortho	15.9	7.4
* TbXt + MI Paste	16.4	15.8
* Transbond XT (TbXT) – Control	32.9	19.3

*Groups not different significantly ($P>0.05$). ΔF =lesion depth.

Table 5. Lesion depth for each group (N=20).

13. Discussion

The use of intraoral photographs for caries determination in orthodontic patients is a well-accepted method. Standardized photographs taken before and after appliance placement are available readily as a standard procedure in orthodontic care. Color photography as a means of recording prevalence of enamel opacity is a powerful method (Ellwood, 1993). Studies have shown that assessment of enamel demineralization from color images appears to be more reproducible than direct clinical observation utilizing only the naked eye (Benson *et al.*, 1998). Moreover, photographic records provide an efficient means to capture the appearance of enamel and provide a permanent record at a given time point. It allows an examiner, therefore, to assess the caries experience of a patient blindly and randomly. Based on pre- and post-

orthodontic treatment photographic patient records, this study showed a high incidence of new WSLs (72.9%) in patients treated with comprehensive orthodontics, while the incidence of new cavitated lesions in this population was 2.3%. Gender, age and oral hygiene at start of treatment were not associated with lesion development, while a significant association was evidenced with treatment duration. Patients in treatment for less than 22 months developed on average three WSLs, while patients in treatment for 33 months or longer developed on average more than five lesions. Linear regression analysis suggested that as the duration of fixed appliances increased one month, 0.08 new WSLs were developed. The *in vitro* study sought to test four different treatments, which comprise much of the currently available therapies to prevent WSLs. The four experimental groups differed in their application, chemistry and physical properties. The Aegis-Ortho cement serves as a replacement for a typical bracket bonding cement. This ACP-containing material supposedly reduces the incidence of enamel demineralization with the release of calcium and phosphate ions – not only to reduce demineralization, but also to promote the remineralization of enamel. The fluoride varnish group received the same bonding cement as the control plus an application of Vanish, a popular fluoride varnish used for caries prevention. Unlike fluoride rinses that require patient compliance, the delivery of Vanish takes place in the dental chair and could be applied at the monthly orthodontic appointment. The CPP-ACP group teeth received an adjunctive daily application of MI Paste, whose chemical mechanism of action resembles that of the ACP cement. Instead of having ACP just residing in the bracket cement, the preventive protocol for MI Paste demands a daily application and, thus, a certain degree of patient compliance. MI Paste is claimed to have the ability to prevent WSLs during orthodontic treatment. Teeth in the final group received a light cured filled sealant as adjunctive treatment. Though it claims to offer some fluoride release, Pro-seal at its core functions as a protective physical barrier against the acid attacks.

Compared with the control group, the Pro-seal group had a statistically significant difference in regard to both outcome measures (*i.e.*, lesion depth and fluorescence loss). The CLSM results indicated that there was no demineralization on any of the specimens in this group. Similarly, the QLF test demonstrated that teeth treated with Pro-seal had the least amount of fluorescence loss by far. The findings of this study confirmed that the Pro-seal functions as a protective barrier that is impermeable to the daily acid challenge. This impressive display of demineralization prevention under *in vitro* cariogenic conditions also has been observed in other studies (Hu and Featherstone, 2005; Buren *et al.*, 2008).

When interpreting the results of the current study, it is important to examine the experimental methods used. Obviously, the oral cavity of the typical teenager presents a much more dynamic and abrasive environment than those used in this *in vitro* study. However, it has been shown that Pro-seal sealant also displays physical properties when subjected to abrasion (Hu and Featherstone, 2005). Pro-seal prevented enamel demineralization convincingly and, thus, seems to be a reasonable treatment option that requires zero patient compliance.

The results from this study also indicated that teeth treated with the fluoride varnish had less enamel demineralization than the control and the ACP groups. Although it had a statistically significant difference in both lesion depth and fluorescence loss when compared to the control group, the difference was not nearly as dramatic in the QLF test. Currently, there are no other *in vitro* studies in the literature that examine fluoride varnish around orthodontic brackets with both CLSM and QLF.

In that there was zero demineralization measured with the CLSM but some degree of fluorescence loss found with the QLF raises questions. In spite having the specimens brushed daily, for the most part the fluoride varnish remained unexpectedly on the tooth surface throughout the experiment and had to be removed with a plastic scaler at the end of the experiment. Therefore, its mechanism of action must be considered. In addition to the anti-cariogenic properties of fluoride as rationale for use, the fluoride may not have been the only mechanism of action in this *in vitro* experiment in that the varnish formed a physical barrier to the acid challenge.

In this study, the Aegis-Ortho group and the MI Paste group showed less demineralization numerically than the control group for both the CLSM and QLF test, though neither had statistical significance. Thus, both Aegis-Ortho and MI Paste were not different from the control group. The similar numerical levels of effectiveness for Aegis-Ortho and MI Paste are not surprising, given their similar mode of action. In analyzing these two treatments, the obvious disadvantage for the MI Paste group is that it requires daily application, whereas the ACP in Aegis-Ortho simply resides in the bracket bonding cement.

While the results of this study help us better understand the prevention potential of these products, *in vitro* experimental conditions cannot encapsulate all the complexities of a living oral cariogenic environment.

The ultimate answer on efficacy of these products has to come from well-designed controlled clinical trials. An *in vivo* randomized controlled trial study that employs proven methods for clinical evaluation of incipient lesions around brackets and also includes the patient compliance factor would provide the highest level of evidence with respect to the preventive treatment modalities discussed.

14. Conclusions

The incidence of WSLs in patients treated with comprehensive orthodontics was very high, suggesting that any preventive therapy provided appeared to be ineffective. This widespread problem poses an alarming concern and warrants significant attention from both patients and providers that should result in greatly increased emphasis on effective caries prevention. Results from this study suggest that both the lightcured filled sealer (Pro-seal) and the fluoride varnish (Vanish) have the potential to prevent enamel demineralization next to orthodontic brackets exposed to cariogenic conditions.

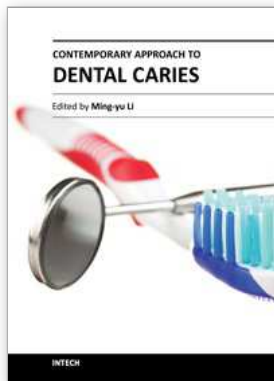
15. References

- Adriens ML, Dermaut LR, Verbeeck RM: The use of Fluor Protector, a fluoride varnish as a prevention method under orthodontic bands. *Eur J Orthod* 1990;12:316-9.
- Aimutis WR. Bioactive properties of milk proteins with particular focus on anticariogenesis. *J Nutr* 2004;134:989-95.
- Al-Khateeb S, Forsberg CM, de Josselin de Jong E, Angmar-Mansson B. A longitudinal laser fluorescence study of white spot lesions in orthodontic patients. *Am J Orthod Dentofacial Orthop* 1998;113:595-602.
- Al-Khateeb S, Exterkate RA, de Josselin de Jong E, Angmar-Månsson B, ten Cate JM Light-induced fluorescence studies on dehydration of incipient enamel lesions. *Caries Res.* 2002 ;36:25-30.

- American Association of Orthodontists [Internet] Missouri; AAO; [cited 2009 Jan 5]. Available from <http://www.braces.org/knowmore/care/>.
- Andersson A, Sköld-Larsson K, Hallgren A, Petersson LG, Twetman S. Effect of a dental cream containing amorphous cream phosphate complexes on white spot lesion regression assessed by laser fluorescence. *Oral Health Prev Dent*. 2007;5:229-33.
- Arends J, Ten Bosch JJ. Demineralization and remineralization evaluation techniques. *J Dent Res* 1992;71:924-8.
- Årtun J, Thylstrup A. A 3-year clinical and SEM study of surface changes of carious enamel lesions after inactivation. *Am J Orthod Dentofacial Orthop* 1989;95:327-33.
- Azarpazhooh A, Limeback H. Clinical efficacy of casein derivatives: A systematic review of the literature. *J Am Dent Assoc* 2008;139:915-924.
- Banks PA, Richmond S. Enamel sealants: a clinical evaluation of their value
- Benson PE, Pender N, Higham SM. Quantifying enamel demineralization from teeth with orthodontic brackets - a comparison of two methods. Part 1: repeatability and agreement. *Eur J Orthod* 2003;25:149-58.
- Benson PE, Pender N, Higham SM. Quantifying enamel demineralization from teeth with orthodontic brackets - a comparison of two methods. Part 2: validity. *Eur J Orthod* 2003;25:159-65.
- Buren JL, Staley RN, Wefel J, Qian F. Inhibition of enamel demineralization by an enamel sealant, Pro-seal: An *in vitro* study. *Am J Orthod Dentofacial Orthop* 2008;133:S88-S94.
- de Josselin de Jong E, Sundstrom F, Westerling H, Tranaeus S, ten Bosch JJ, Angmar-Mansson B. A new method for *in-vivo* quantification of changes in initial enamel caries with laser fluorescence. *Caries Res* 1995;29:2-7.
- Demito CF, Vivaldi-Rodrigues G, Ramos AL, Bowman SJ. The efficacy of a fluoride varnish in reducing enamel demineralization adjacent to orthodontic brackets: an *in-vitro* study. *Orthod Craniofacial Res* 2004;7:205-10.
- Dunn W. Shear bond strength of an amorphous calcium phosphate - containing orthodontic resin cement. *Am J Orthod Dentofacial Orthop* 2007;131:243-7.
- Emami Z, al-Khateeb S, de Josselin de Jong E, Sundstrom F, Trollsas K, Angmar-Mansson B. Mineral loss in incipient caries lesions quantified with laser fluorescence and longitudinal microradiography. A methodologic study. *Acta Odontol Scand* 1996;54:8-13.
- Exterkate RAM, Damen JJM, ten Cate JM (1993). A single section model for enamel de- and remineralization studies. I. The effects of different Ca/P ratios in remineralization solutions. *J Dent Res*. 1993;72:1599-1603.
- Fontana M, Dunipace AJ, Gregory RL, Noblitt TW, Li Y, Park KK, Stookey GK. An *in-vitro* microbial model for studying secondary caries formation. *Caries Res* 1996a;30:112-8.
- Fontana M, Dunipace AJ, Noblitt TW, Fischer GM, Katz BP, Stookey GK. Measurement of enamel demineralization using microradiography and confocal microscopy. *Caries Res* 1996b;30:317-25.
- Foster JA, Berzins DW, Bradley TG. Bond strength of an amorphous calcium phosphate-containing orthodontic adhesive. *Angle Orthod*. 2008;78:339-44.
- Geiger AM, Gorelick L, Gwinnett AJ, Benson BJ. Reducing white spot lesions in orthodontic populations with fluoride rinsing. *Am J Orthod Dentofacial Orthop* 1992;101:403-7.
- Gilmour AS, Edmunds DH. The polarized light microscopic appearance of caries-like lesions adjacent to restored cavities in the crowns and roots of extracted human teeth. *J Oral Rehabil*. 1998;25:929-39.

- González-Cabezas C, Fontana M, Dunipace AJ, Li Y, Fischer GM, Proskin HM, Stookey GK. Measurement of enamel remineralization using microradiography and confocal microscopy. *Caries Res* 1998;32:385-92.
- Gorelick L, Geiger AM, Gwinnett AJ. Incidence of white spot formation after bonding and banding. *Am J Orthod Dentofacial Orthop* 1982; 81:93-98.
- Gorton J, Featherstone JDB. *In vivo* inhibition of demineralization around orthodontic brackets. *Am J Orthod Dentofacial Orthop* 2003; 123:10-14.
- Gwinnett J. Normal Enamel II: Qualitative polarized light study. *J. Dent. Res.* 1966 45: 261-5.
- Hafstrom-Bjorkman U, Sundstrom F, de Josselin de Jong E, Oliveby A, Angmar-Mansson B. Comparison of laser fluorescence and longitudinal microradiography for quantitative assessment of *in-vitro* enamel caries. *Caries Res* 1992;26:241-7.
- Hu W, Featherstone JDB. Prevention of enamel demineralization: An *in vitro* study using light-cured filled sealant. *Am J Orthod Dentofacial Orthop* 2005;128:592-600.
- Iijima Y, Cai F, Shen P, Walker G, Reynolds C, Reynolds EC. Acid resistance of enamel subsurface lesions remineralized by a sugar-free chewing gum containing casein phosphopeptide-amorphous calcium phosphate. *Caries Res* 2004;38:551-6.
- Informed consent for the orthodontic patient: risks and limitations of orthodontic treatment. American Association of Orthodontists (2005).
- Ismail A. Rationale and evidence for the International Caries Detection and Assessment System (ICDAS II). In: Stookey G, ed. *Clinical Models Workshop: Remin-demin, Precavitation, Caries: Proceedings of the 7th Indiana Conference*. Indianapolis: Indiana University School of Dentistry 2005:161-222.
- Keim RG, Gottlieb EL, Nelson AH, Vogels DS 3rd. 2008 JCO study of orthodontic diagnosis and treatment procedures, Part 1: Results and trends. *J Clin Orthod.* 2008;42:625-40.
- Lagerweij M, van der Veen M, Ando M, Lukantsova L, Stookey G. The validity and repeatability of three light-induced fluorescence systems: an *in-vitro* study. *Caries Res* 1999;33:220-6.
- Lovrov S, Hertrich K, Hirschfelder U. Enamel Demineralization during Fixed Orthodontic Treatment - Incidence and Correlation to Various Oral-hygiene Parameters. *J Orofac Orthop.* 2007;68:353-63.
- Marinho VCC, Higgins JPT, Logan S, Sheiham A. Fluoride mouthrinses for preventing dental caries in children and adolescents (Cochrane Review). In: The Cochrane Library, Issue 1, 2004. Chichester, UK: John Wiley & Sons.
- Mathew M, Takagi S. Structures of biological minerals in dental research. *J Res Natl Inst Stand Technol* 2001;106:1035-44.
- Mehra T, Nanda RS, Sinha PK. Orthodontists' assessment and management of patient compliance. *Angle Orthod.* 1998; 68:115-22.
- Øgaard B, Rolla G, Arends J. Orthodontic appliances and enamel demineralization. Part 1. Lesion development. *Am J Orthod Dentofacial Orthop* 1988;94:68-73.
- Øgaard B. Prevalence of white spot lesions in 19-year-olds: a study on untreated and orthodontically treated persons 5 years after treatment. *Am J Orthod Dentofacial Orthod* 1989;96:423-7.
- Øgaard B, Larsson E, Henriksson T, Birkhed D, Bishara SE: Effects of a combined application of antimicrobial and fluoride varnishes in orthodontic patients. *Am J Orthod Dentofacial Orthop* 2001;120:28-35.
- O'Reilly MM, Featherstone JDB. Demineralization and remineralization around orthodontic appliances: An *in vivo* study. *Am J Orthod Dentofacial Orthop* 1987;92:33-40.
- Pretty IA, Pender N, Edgar WM, Higham SM. The *in-vitro* detection of early enamel de- and re-mineralization adjacent to bonded orthodontic cleats using quantitative light-induced fluorescence. *Eur J Orthod* 2003;25:217-23.

- Pulido MT, Wefel JS, Hernandez MM, Denehy GE, Guzman-Armstrong S, Chalmers JM, Qian F. The inhibitory effect of MI paste, fluoride and a combination of both on the progression of artificial caries-like lesions in enamel. *Oper Dent*. 2008;33:550-5.
- Reynolds EC, del Rio A. Effect of Casein and whey-protein solutions on caries experience and feeding patterns of the rat. *Arch Oral Biol* 1984;29:927-33.
- Reynolds EC. Anticariogenic complexes of amorphous calcium phosphate stabilized by casein phosphopeptides: a review. *Spec Care Dentist* 1998;18:8-16
- Reynolds EC, Black CL, Cai F, et al. Advances in enamel remineralization: anticariogenic casein phosphopeptide-amorphous calcium phosphate. *J Clin Dent* 1999;10:86-8
- Reynolds EC, Cai F, Shen P, Walker GD. Retention in plaque and remineralization of enamel lesions by various forms of calcium in a mouthrinse or sugar-free chewing gum. *J Dent Res* 2003;82:206-11.
- Richter AE, Arruda AO, Peters MC and Sohn W. Incidence of caries lesions for patients treated with comprehensive orthodontics. *J Dent Res* 88(Spec Iss A): Abstract Miami meeting, 2009.
- Rose RK. Binding characteristics of *Streptococcus mutans* for calcium and casein phosphopeptide. *Caries Res* 2000;34:427-31.
- Rosen S, Min DB, Harper DS, Harper WJ, Beck EX, Beck FM. Effect of cheese, with and without sucrose, on dental caries and recovery of *Streptococcus mutans* in rats. *J Dent Res* 1984;63:894-6.
- Rosenbloom RG, Tinanoff N. Salivary *Streptococcus mutans* levels in patients before, during and after orthodontic treatment. *Am J Orthod Dentofacial Orthop* 1991;100:35-7.
- Rousseau C, Vaidya S, Creanor SL, Hall AF, Girkin JM, Whitters CJ, et al. The effect of dentine on fluorescence measurements of enamel lesions *in-vitro*. *Caries Res* 2002;36:381-5.
- Skrtic D, Hailer AW, Antonucci JM, Takagi S, Eanes ED. Quantitative assessment of the efficacy of amorphous calcium phosphate/methacrylate composites in remineralizing caries-like lesions artificially produced in bovine enamel. *J Dent Res*. 1996;75:1679-86.
- Soliman MM, Bishara SE, Wefel J, Heilman J, Warren JJ. Fluoride release rate from an orthodontic sealant and its clinical implications. *Angle Orthod*. 2006;76:282-8
- Stecksén-Blicks C, Renfors G, Oscarson ND, Bergstrand F, Twetman S. Caries-preventive effectiveness of a fluoride varnish: A randomized controlled trial in adolescents with fixed orthodontic appliances. *Caries Res* 2007;41:455-459.
- Sudjalim TR, Woods MG, Manton DJ, Reynolds EC. Prevention of demineralization around orthodontic brackets *in-vitro*. *Am J Orthod Dentofacial Orthop* 2007;131:705.
- Todd MA, Stanley RN, Kanellis MJ, Donly KJ, Wefel JS: Effect of a fluoride varnish on demineralization adjacent to orthodontic brackets. *Am J Orthod Dentofacial Orthop* 1999;116:159-67.
- van der Linden RP, Dermaut LR: White spot formation under orthodontic bands cemented with glass ionomer with or without Fluor Protector. *Eur J Orthod* 1998;20: 219-24.
- van der Veen MH, de Josselin de Jong E Application of quantitative light-induced fluorescence for assessing early caries lesions. *Monogr Oral Sci*. 2000;17:144-62.
- Vivaldi-Rodrigues G, Demito CF, Bowman SJ, Ramos AL. The effectiveness of a fluoride varnish in preventing the development of white spot lesions. *World J Orthod* 2006;7:138-144.
- Zachrisson BU, Heimgard E, Ruyter IE, Mjor IA. Problems with sealants for bracket bonding. *Am J Orthod* 1979;75:641-9.



Contemporary Approach to Dental Caries

Edited by Dr. Ming-Yu Li

ISBN 978-953-51-0305-9

Hard cover, 488 pages

Publisher InTech

Published online 14, March, 2012

Published in print edition March, 2012

With an update of the recent progress in etiology, pathogenesis, diagnosis, and treatment of caries, it may be said that the final defeat of dental caries is becoming possible soon. Based on the research in this area in recent decades, "Contemporary Approach to Dental Caries" contained the caries in general, the diagnosis of caries, caries control and prevention, the medical treatment of caries, dental caries in children and others such as secondary caries. This book provides the reader with a guide of progress on the study of dental caries. The book will appeal to dental students, educators, hygienists, therapists and dentists who wish to update their knowledge. It will make you feel reading is profitable and useful for your practice.

How to reference

In order to correctly reference this scholarly work, feel free to copy and paste the following:

Airton O. Arruda, Scott M. Behnan and Amy Richter (2012). White-Spot Lesions in Orthodontics: Incidence and Prevention, Contemporary Approach to Dental Caries, Dr. Ming-Yu Li (Ed.), ISBN: 978-953-51-0305-9, InTech, Available from: <http://www.intechopen.com/books/contemporary-approach-to-dental-caries/incipient-caries-lesions-in-orthodontics>

INTECH

open science | open minds

InTech Europe

University Campus STeP Ri
Slavka Krautzeka 83/A
51000 Rijeka, Croatia
Phone: +385 (51) 770 447
Fax: +385 (51) 686 166
www.intechopen.com

InTech China

Unit 405, Office Block, Hotel Equatorial Shanghai
No.65, Yan An Road (West), Shanghai, 200040, China
中国上海市延安西路65号上海国际贵都大饭店办公楼405单元
Phone: +86-21-62489820
Fax: +86-21-62489821

© 2012 The Author(s). Licensee IntechOpen. This is an open access article distributed under the terms of the [Creative Commons Attribution 3.0 License](#), which permits unrestricted use, distribution, and reproduction in any medium, provided the original work is properly cited.