

Limited Hand Surgery in Epidermolysis Bullosa

Bartłomiej Noszczyk and Joanna Jutkiewicz-Sypniewska
*Medical Center for Postgraduate Education
Poland*

1. Introduction

Epidermolysis bullosa (EB) is the name given to a group of rare congenital diseases with similar clinical symptoms. Their common feature is the susceptibility of the epithelia and skin to injury. Even minor shear forces from the sideways stretching of the skin contribute to epidermal tearing with blister formation. These blisters turn into wounds. In the most severe forms of the disease, wounds dominate on the skin and mucosa, leading to early death or deformations from scars and contractures.

1.1 Types of EB

Four main types of EB are distinguished based on the level of the ultrastructural defect in the area of the basement membrane zone (BMZ) (Fine, 2010). In epidermolysis bullosa simplex (EBS), the epithelium separates at the level of the basal cells, most commonly as a result of damage to keratin 5 and 14. In junctional epidermolysis bullosa (JEB), the level of the epithelial separation is in the lamina lucida and results from laminin -332, collagen XVII or integrin $\alpha 6\beta 4$ defects. In dystrophic epidermolysis bullosa (DEB), the epithelium is damaged below the lamina densa as a result of an incorrectly structured collagen VII building the anchoring fibrils. In Kindler syndrome, protein damage may affect several layers simultaneously. Apart from the epidermis, any basement membrane epithelia may become damaged. Most typically affected are the oral cavity and the esophageal and upper respiratory tract mucosa. The disease may also affect the tissues not covered with epithelium, such as tooth enamel, which is damaged in all the JEB forms.

The extent of symptoms involving the skin is varied and not completely characteristic. In the localized EBS form (EBS - loc) they manifest mainly as blisters on the hands and feet. In both generalized forms of EBS the blisters are located throughout the whole body. The risk of pseudosyndactyly in Dowling - Meara (EBS-DM) is estimated at 3% at or after the age of 3 (Fine et al., 2005). In the, non-Dowling-Meara (EBS-nDM), the blisters, although generalized, tend to spare the hands and feet (Fine, 2010).

Among the several different subtypes of junctional epidermolysis bullosa (JEB), two are generalized. The highest risk of death accompanies the Herlitz (JEB-H) form. In these patients, death stems from severe infectious complications or multi-organ failure. The predominating symptoms in this type are non-healing wounds covered with granulation tissue. It appears in the first months of life and can involve the upper respiratory tract. In the

more common non-Herlitz (JEB-nH) form, the blisters are generalized and occur on the hands as well, often accompanied by atrophic scars and atrophic nails. The risk of pseudosyndactyly increases with advanced age.

The dystrophic type of epidermolysis bullosa (DEB) is divided into two main subtypes, depending on the mode of inheritance. In both, the generalized blisters lead to the formation of wounds, which typically heal and scar. The autosomal dominant form (generalized dominant dystrophic - DDEB) is characterized by symptoms of a slightly lower intensity. The risk of pseudosyndactyly is just 3% by the age of 40 (Fine et al., 2005). The forms with autosomal recessive inheritance have a more severe course. The most severe one, described as generalized recessive dystrophic epidermolysis bullosa (RDEB), occurs in 2 out of one million births (Pfundner et al., 2001). The disease activity in RDEB is extremely high in nearly every anatomic site (Devries et al., 2004).

1.2 Hand deformations in RDEB

The characteristic features of generalized RDEB are intensifying contractures and pseudosyndactyly affecting the hands and feet. Their risk by the age of 20 is estimated at 98% (Fine et al., 2005). In time, they lead the hands to contract into a cocoon. If such a severe disability appears in early childhood, it may hinder or preclude normal development. The mechanism of pseudosyndactyly, finger contractures and the development of the characteristic mitten deformities is not completely clear. The gradual web creep in children not undergoing surgery is probably facilitated by fine blisters and recurrent epidermal injuries. In the early postoperative period in operated patients, this complication typically stems from the adhesion of contacting wound surfaces. However, in all patients, this process also develops on the hands and feet under the influence of unknown causes. Observations suggest that the epithelium has a natural tendency towards migration "with shortcuts". It gradually retreats from the indented web spaces, leaving non-separated surfaces of the dermis. As a result, this retreat leads the dermal layers to stick under the surface of the forming cocoon. The contacting layers usually do not fully adhere. Hence, the pseudosyndactyly results. Initially, despite the adhesions, the fingers remain extended. During this period, the epithelium forming the cocoon continues to overgrow, forming a thick stratum corneum. Its structure at this time resembles paper, and it quickly becomes too rigid to allow movement. This rigidity leads to habitual finger bending and further cocoon overgrowth, which soon involves the entire hand.

1.3 Other complications of RDEB

Effective intervention for RDEB patients requires multidisciplinary treatment. Apart from dermatological care, the majority of patients require pediatric care due to multifactorial anemia and malnutrition. In some patients, kidney failure and cardiomyopathy develop, both of which may increase the risk of death. Among the other symptoms of note are corneal injuries requiring ophthalmologic treatment and esophageal stenosis, which can develop in early childhood. Sometimes, these are accompanied by microstomy and ankyloglossia. Difficulties with swallowing quickly contribute to malnutrition and growth retardation. The treatment requires esophageal dilation or gastrostomy. Some RDEB patients are diagnosed with squamous cell carcinoma by the age of 20. This cancer is a common cause of death in adults. The risk of this neoplasm is estimated at 7.5% by the age of 20 and 67.8% after the age of 35 (Fine & Mellerio, 2009a).

1.4 Repeated hand surgery – The problem in RDEB

Despite many attempts to use modern technology or to change surgical techniques, the recurrence of deformation is unavoidable and commonplace. Because every epidermal cell in the body has the same genetic defect, local therapy may result in only temporary improvement. Hand procedures may become necessary in 61% of RDEB patients. In this group, 5 or more operations are presumed to be the norm (Fine et al., 2005). It is estimated that recurrences appear, on average, every 2.4 years (1 to 5 years) (Terrill et al., 1992). In the experience of many surgeons, this time interval is even shorter. Furthermore, the time required for full wound healing after surgery for advanced deformations may reach 6 to 8 weeks (Fivenson et al., 2003). It is frequently observed, therefore, that patients spend a considerable period of potentially good hand efficiency in the hospital receiving dressing replacements. Most of these procedures require general anesthesia.

In order to support patients' independence and psychomotoric development, operations could be recommended early, when deformations may no longer be prevented by physiotherapy and splinting. In practice, however, patients typically present to the hospital when they or their parents are aware that surgery may no longer be postponed. If the deformations are advanced, the extent of the needed surgery influences the postoperative course. Patients then become discouraged by repeated hospitalizations and less likely to cooperate in the future.

1.5 Common methods in RDEB surgery

Removal of the thick epidermis that creates the cocoon is ineffective. In the beginning of the operation however, the hand may be "de-cocooned" using epidermal degloving technique. It outlines the area where direct force may be applied and saves intact epidermis beyond surgical manipulation (Ladd et al., 1996). This maneuver helps to apply manual traction to the tips of the affected fingers, which may be extended after a sharp release on the palmar side of the contracted joints. Other authors prefer to dispense with degloving, emphasizing however the need to apply some force in order to extend the contracted digits (Ciccarelli et al., 1995). Although such forceful manipulation destroys epidermis, the same principle applies to the first web space, where pseudosyndactyly often involves the adductor fascia and the first dorsal interosseous muscles (Ladd et al. 1996). The abduction and extension of the fingers is then maintained by Kirshner wires. Others have suggested the continuous use of acrylic gloves for three months following surgery (Terrill et al., 1992). Today modern splints from thermoplastic materials are recommended, that may be easily remodeled or discarded after they become polluted.

The most thorough review and practical evaluation of surgical methods in RDEB was presented recently (Bernardis & Box, 2010). Currently, most authors prefer to avoid using force during joint extension to prevent neurovascular bundle injury and subluxation. It has also been suggested that the full release of contractures may be not useful or necessary. This procedure creates extensive defects, leaving a bare dermal surface and uncovered neurovascular bundles, which require grafting. Full thickness skin grafts (FTSGs) are often used in deeper defects. The amount of full-thickness dermis suitable for harvesting is limited, however. Therefore, other solutions have been proposed for the remaining surface of superficial defects. Various opinions exist over the use of split skin grafts (SSGs). The

harvesting of SSGs is associated with the creation of dermal defects in the donor area that often become difficult-to-heal wounds. In addition, the use of dermatome can deepithelize the skin adjacent to the planned donor site and can destroy the graft epidermis, usually rendering it useless (Bernardis & Box, 2010). In such cases, leaving the wounds on the lateral surfaces of the fingers and on the palmar surface of the hand without any biological dressings may be an equally good solution. Some authors claim that this technique does not prolong the healing time similarly compared with any other methods (Ciccarelli et al., 1995).

Attempts to use allogeneic dermal substitutes have not produced clear results. Allogeneic culture skin substitutes (Eisenberg & Llewelyn, 1998) and Apligraf (Fivenson et al., 2003) have been used. Although the time to recurrence was increased in allogeneic skin patients, the results for Apligraf were unclear. Some modern dressings were also used, but these did not reduce the duration of healing or the number of weekly dressing changes performed under general anesthesia (Jutkiewicz et al., 2010). All these methods, however, enabled the avoidance of dermatome use on the fragile epidermal surface.

2. Limited hand surgery in RDEB

2.1 Preparation for surgery

2.1.1 Basic recommendations

In the modern treatment of EB, a great degree of significance is placed on the establishment of centers that enable contact with a team of specialists experienced in managing this rare disease (Pohla-Gubo & Hintner, 2010). Pediatric surgeons unfamiliar with EB may make errors stemming from a lack of knowledge of basic care principles. The following recommendations are designed to help practitioners avoid iatrogenic skin injuries:

- Children should not be lifted up independently. In particular, grabbing by the armpits easily causes wounds. Patient transfers should be assisted by the parents. Heavier children should be transferred on a blanket.
- In the case of disposable cloths, any elastics or belts should be removed from. Also, buttons or zippers in the bedclothes may cause blisters, particularly in anesthetized patients. Disposable clothes or wristbands should not adhere to skin when moist.
- Do not pull by the naked skin. In particular, do not restrain a child who has broken free. Grabbing by the wrists or by the fingers when attempting to stretch them causes epidermal tearing. When swabbing the skin before an injection, do not rub it with the swab.
- Band-aids should not be applied to the skin. Wounds may be caused by a band-aid used for fixing the vein needle or the intubation tube. Remember not to affix disposable electrodes to the skin during the preparation for surgery, particularly ECG and diathermy or self-adhesive draping in the operating field.
- Ensure that information on the proper procedure is provided at level of the department and the operating suite.

2.1.2 Metabolic disorders

Metabolic disorders in RDEB may require treatment in the preparation for surgery. These stem from increased energy expenditure, impaired absorption due to defects of the small

intestinal epithelium, and insufficient food supply caused by blisters in the mouth and esophageal stenosis. The progressing stenosis hinders the intake of liquids and the swallowing of saliva. Attempts to insert gastric tubes are often associated with skin and mucosal injuries. Confirmed stenosis should rather be an indication for esophageal dilation. The recommended method is contrast X-ray or fluoroscopic guidance balloon dilation. In the population of patients with RDEB, approximately one-third require at least one such procedure. In many patients, the stenosis recurs. The mean time between subsequent dilations is estimated at 1 to 2 years (Fine & Mellerio, 2009b).

In greater deficiencies or independently of esophageal dilation, gastrostomy should be considered. In particular, during the preoperative period, it enables easy supplementation of food taken orally. It should be emphasized that attempts to insert percutaneous endoscopic gastrostomy (PEG) tubes. These expose the patient to unnecessary risk. In the authors' center, laparotomy is performed under general anesthesia, without intubation. Such a choice also rules out laparoscopic gastrostomy.

Apart from food deficiencies, anemia also requires management. Many patients with RDEB are hospitalized with very low hemoglobin values. This is, to a large extent, caused by iron deficiency, associated with both insufficient supply in food and poor absorption in the intestine. Anemia in these patients also results from chronic inflammation associated with healing (Fine & Mellerio, 2009a). In a large portion of patients, despite the treatment with oral preparations, the hemoglobin level remains below 8 g/dl. With these levels, modern intravenous preparations are believed to be more effective. In the authors' center, Venofer is administered. This substitute has, thus far, prevented the need for treatment with blood, even at hemoglobin values below 6 g/dl. However, it should be emphasized that such a low hemoglobin is recognized as an indication for transfusion. Recently, erythropoietin has also been used, although there have yet been no studies indicating its clear advantage.

2.1.3 Skin infections

In preparation for surgery, local infections accompanying the non-healing wounds should also be considered for treatment. The patients admitted for hand surgery often have old wounds in other body regions. It is emphasized that the distinction between the colonization of such wounds and infection should be made based on the clinical picture and not the culture results. Systemic treatment is rarely required. However, the presence of group A streptococcus may constitute an indication for antibiotic use (Brandling-Bennett & Morel, 2010). The growth of beta - hemolytic streptococcus is also a contraindication for hand surgery (Bernardis & Box, 2010). The majority of the other microorganisms present in non-healing wounds do not affect the planning of surgery. Fungal infections in the mouth do not constitute a contraindication either. *Candida albicans* and *Candida parapsilosis* are both common florae of non-healing wounds in patients with EB (Brandling-Bennett & Morel, 2010).

2.2 Preparation for anesthesia

Before elective surgery, it is important to assess comorbid conditions. In over 75% of patients with RDEB, gastroesophageal reflux disease (GERD) is observed (Fine & Mellerio, 2009b). This condition increases the risk of choking during intubation. In the majority of

children, continued treatment with proton pump inhibitors should be considered. Of note, the risk of cardiomyopathy may also constitute a relative contraindication for surgery. In patients with RDEB, this risk stands at 4.5% by the age of 20 (Fine & Mellerio, 2009a). To rule out the disease, echocardiography is required. The integrity of the respiratory tract should also be assessed. In view of the possibility of microstomy, ankyloglossia, and fixation of the epiglottis, intubation may prove difficult.

During the immediate preparation, the operating room should be supplied with appropriate dressings, and the operating table should be adapted. Adhesives should be removed from all needles and electrodes affixed to the skin. A good alternative for band-aids are silicone tapes with limited adhesiveness that are recommended for patients with EB (e.g. Mepitac). Fixing the intubation tube requires the use of a bandage or silicone tape. For the closing of the eyelids, moisturizing gels with methylcellulose are used. Petroleum-based products are difficult to rinse off post surgery and cause instinctive rubbing of the eyes (Goldschneider et al., 2010).

Two techniques for the safe use of anesthesiological masks are recommended. The first consists of the intensive moisturizing of the skin and mask edge with a moisturizing agent. The second uses silicone tapes such as Mepitac. After either product is affixed, it protects the facial skin while at the same time maintaining air-tightness with the mask (Goldschneider et al., 2010). In patients with RDEB, anesthesia may be considered without intubation, using a mask alone. The common finding of ankyloglossia hinders the tongue from falling back, protecting against the closure of the airway. In the authors' center, anesthesia without intubation is primarily used. The mask is secured with a common cotton swab or a hydrogel wound dressing. However, the depth of such anesthesia is harder to control. Therefore, the method requires an experienced team and good communication between the surgeon and anesthesiologist.

2.3 Indications for surgery

The long-term skin symptoms of RDEB in the hands, including pseudosyndactyly and scars, lead to the establishment of contractures in the joints. Some authors introduce precise angle measurements, describing the extension and flexion deficits in the metacarpophalangeal (MCP) and interphalangeal (IP) joints (Terrill et al., 1992). Based on similar criteria, precise indications for surgery have been proposed (Cicarelli et al., 1995). These were the following: (1) palmar contracture, (2) contracture of the proximal interphalangeal (PIP) joint greater than 30 degrees, (3) significant involvement of the small finger, (4) pseudosyndactyly extending to the PIP joint, or (5) impairment of activities of daily living.

Many authors emphasize, however, that irrespectively of deformity grade lesions should be treated early enough to prevent irreversible consequences (Azizkhan et al., 2007). Surgery is typically thought to be indicated when the loss of function compromises the patient's independence and impairs his/her appearance (Bernardis & Box, 2010). Because thumb mobility contributes to 50% of hand functionality, the release of the first web space alone results in a significant improvement. Therefore the aim of surgery is to provide simple pinch grip and grasp, by releasing the first web space and flexion contractures; independent finger movement, by releasing pseudosyndactyly; and improved appearance of the hand (Bernardis & Box, 2010).

The treatment of early lesions is also beneficial in view of the higher probability of maintaining long-term hand function. Postponing the decision about the next surgery and delaying the treatment reduces the total duration of functionality. In the authors' center, the following assumptions have recently been made: (1) the treatment of early lesions permits the reduction of the scope of the surgery, (2) the reduction of the scope of the surgery lowers the number of dressing changes, and (3) giving up the aim of full finger extension may have little effect on the time to recurrence. These assumptions have enabled the formulation of the surgery objectives as pinch grip and grasp and independent finger movement. Therefore, indications for surgery may be defined as follows:

- Pseudosyndactyly of the first web space reaching the IP joint,
- Pseudosyndactyly of fingers II-V

Assuming that the patients present for regular visits, it is possible to adequately notice the progression of lesions early and make a timely decision with regards to surgery. With less frequent visits, the patients often present with palmar finger contractures secondary to pseudosyndactyly (Fig. 1a, 1b). Indications for surgery had occurred in those patients prior to presentation. Isolated flexion contractures without advanced pseudosyndactyly are less common. These are only a relative indication for treatment because they may be extended and maintained in such a state only for short periods.

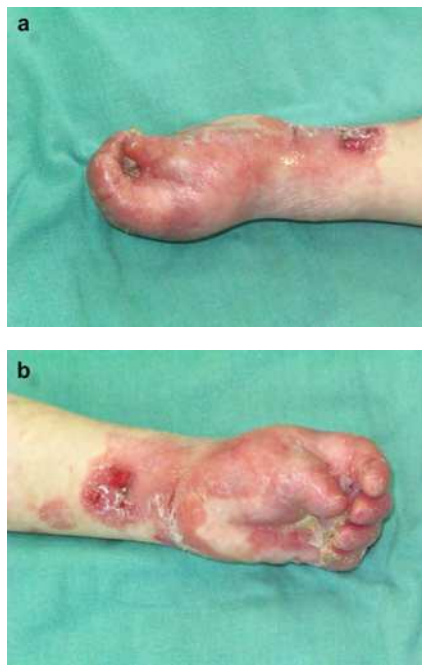

Fig. 1. (a) Pseudosyndactyly of the first web space. (b) Palmar contracture and pseudosyndactyly of fingers II-V. Explanation in the text. Patient AA.

Sometimes, discouraged by previous experiences with protracted healing, patients do not return for years. This avoidance leads to total deformations of the mitten type (Fig. 2a). This

situation is still an indication for surgery, although the patients have to be aware of the poor prognosis concerning mobility in the IP joints. Such advanced lesions prolong healing and reduce the efficacy of subsequent rehabilitation.

2.4 Surgical treatment

2.4.1 Features of a limited approach

An important principle and advantage of the presented treatment is the possibility of avoiding direct contact with the patient's skin. This protection minimizes the extent of iatrogenic epidermal injury and, consequently, facilitates healing. The disadvantage of this treatment is that it eliminates the possibility of full forced extension of the fingers during surgery. Both factors differentiate the suggested approach from other methods.

2.4.2 Hand preparation in the operating room

Only one hand is operated on during each hospital admission. This does not hinder the patient's functioning and reduces the associated stress and discomfort of healing. Half an hour before the patient is brought into the operating suite, the hand may be soaked in a bowl with Betadine solution. Washing at the suite, immediately before the surgery, is limited to patting with a web swab. Energetic rubbing would lead to epidermal injuries.

The authors do not use a tourniquet. We believe that it is not necessary in the described technique. However, the majority of surgeons feel comfortable operating without a blood supply. If a tourniquet is used, it should be placed on an arm wrapped with a thick layer of cotton wool. Prior to pumping, the limb is raised for 2 minutes. It must not be wrapped with an elastic bandage or a rubber band to remove the blood. Prior to placing the limb on the table, a thick pad of sterile cotton wool should be placed under the elbow.

Before starting the dissection, thick sutures, e.g. Vicryl 3.0 or 4.0, are placed on the fingertips. Their ends are left long and are tightened with an instrument. They are then used to pull away the fingers during the contracture release. The assistant holds the sutures during the surgery, which avoids the direct handling of the patient skin. The surgeon holds in his/her left hand only the suture of the finger that is currently extended. As a result, the right hand is free.

2.4.3 Separation of pseudosyndactyly and contractures

In cases where the hand is curled in a complete cocoon (Fig. 2a), the fingertips are difficult to release without an initial dissection. A small, circular incision around the fingertips enables them to be detached and lever with blunt scissors. Only then can the suture be placed. In such advanced deformities, the epidermis is retained only on the dorsal surfaces of the fingers. Therefore, the surgery is continued by cutting the epidermis on the dorsal side. During cutting, it is clear that the dermal layers between the fingers remain "glued" rather than grown together into one whole (Fig. 2b). It is easy to find the web space by parting it with scissors. Separation of the fingers may be made easier by pulling them slightly sideways. On the dorsal side, the epidermis is cut to the MP joints level. On the palmar side, the fingers are separated to only half the length of the proximal phalanges. However, to reach this level, the fingers must be simultaneously released from contractures (Fig. 2c). This release usually requires sharp dissection. Particularly on the palmar side of the PIP joints,

the use of scissors or a scalpel is necessary. Attention should be paid to the neurovascular bundles. If possible, they should not be exposed, and flexor sheaths should not be reached.

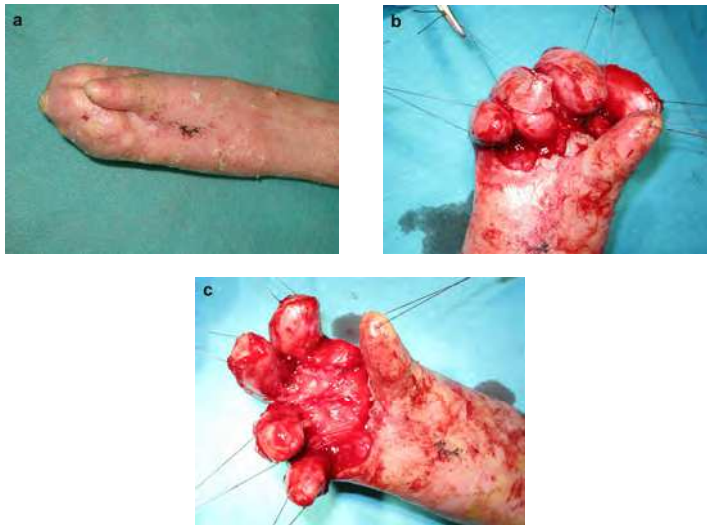

Fig. 2. (a) Mitten hand deformation, (b) Separated pseudosyndactyly. (c) Released contracture. Explanation in the text. Patient BB.

In most cases, the extension in the PIP joints does not have to exceed a right angle (Fig. 3a). Further extension would require the grabbing of the finger by the surgeon's hand and its forced pulling. Such a maneuver is used in more invasive surgical techniques; however, it leads to extensive epidermal injuries and complete exposure of the flexor sheaths.

The thumb is separated in a similar manner. The epidermis is cut on the dorsal side (Fig. 3a). Next, the surgeon moves to the palmar side, dissecting to the depth of the muscle fibers. Both the dermal contractures and some of the adductor pollicis fibers may require sharp separation. However, if possible, it is better to stretch the muscle and joints, gently pulling the suture on the thumb tip (Fig. 3b). This facilitates the protection of the neurovascular bundles near the flexor muscle sheath.

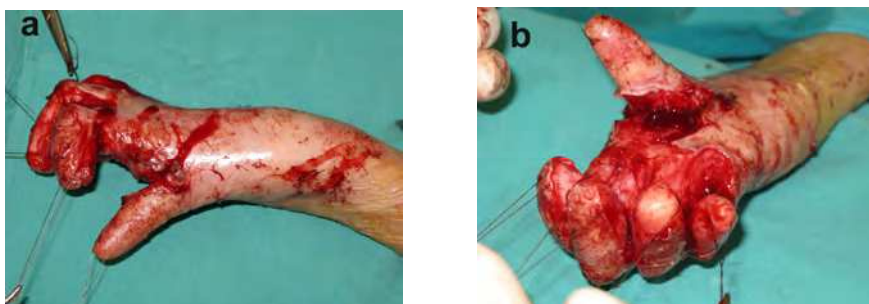


Fig. 3. (a) Joints extended to the right angle, (b) Separated thumb pseudosyndactyly. Explanation in the text. Patient BB.

In less advanced contractures (Fig. 1a, 1b), the described method allows for the nearly complete preservation of the thumb (Fig. 4a) and palmar epidermis (Fig. 4b). It also facilitates healing and limits the dressing changes to one or two subsequent hospitalizations.

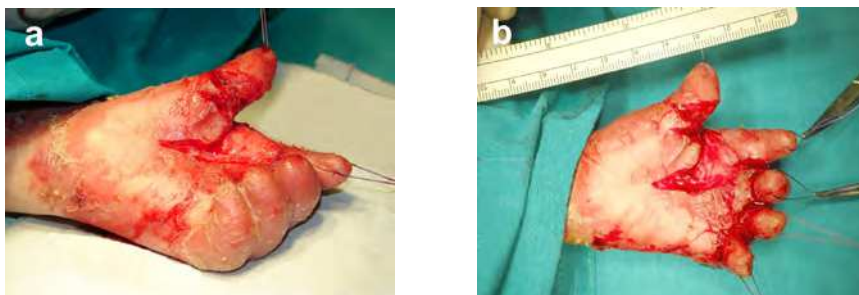


Fig. 4. (a) Minor palmar wound, (b) Epidermis on the fingers is preserved. Explanation in the text. Patient AA.

In some patients, the need for the release of contractures of fingers II-V should be carefully considered. This question concerns especially those whose multiple prior operations deterred from surgery (Fig 5a). The reduction of the extent of subsequent surgeries for the separation of the first web space (Fig. 5b) may sufficiently improve hand functionality.

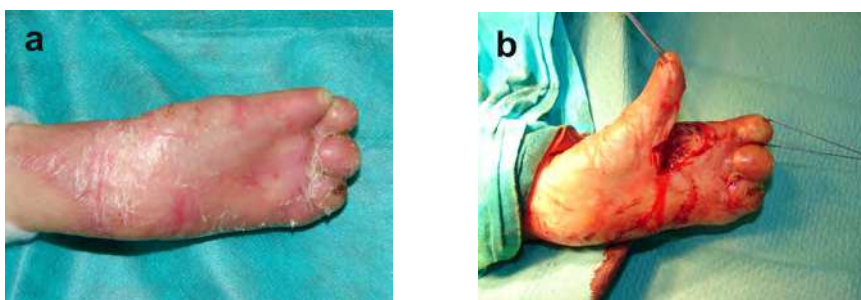

Fig. 5. (a) Recurrent mitten deformation, (b) Isolated thumb release. Explanation in the text. Patient CC.

2.4.4 Skin grafts

At sites where flexor muscle sheaths or neurovascular bundles are exposed covering with FTSGs may be required. These grafts usually undergo epidermal separation during manipulation associated with the defatting of the undersurface and placing. Despite the above, they usually heal well. On the other hand, it is not known whether FTSGs tendency to resist contracture delays the recurrence in patients with EB.

Due to the limited supply of FTSGs and the instability of SSGs, an intermediate solution was suggested over 30 years ago (Cuono & Finsteth, 1978). Since this technique facilitates healing, it is particularly suitable for surgeries of limited scope. It involves the acquisition of isolated epidermis in a technique called the "split-off". The graft is acquired from the thighs

or from another surface on which blisters are not found. It should be collected with excess to ensure the thorough covering of all wounds. Bleeding from the collection site is minimal. Thus, the area does not require prompt compression dressing. If necessary the next graft can be harvested in immediate vicinity.

The graft margins should be marked with a felt-tip pen and cut superficially with a lancet (Fig.6a). Next, using the elevator, the epidermal edge is slipped off. Gently, it may be separated from the skin without any damage (Fig.6b). After complete layer separation, the outer surface of the graft is covered with a greased tulle, which facilitates the transfer of the epidermal layer (Fig.6c) and its splitting into appropriate fragments (Fig.6d). At the donor site, a typical tulle dressing is applied.

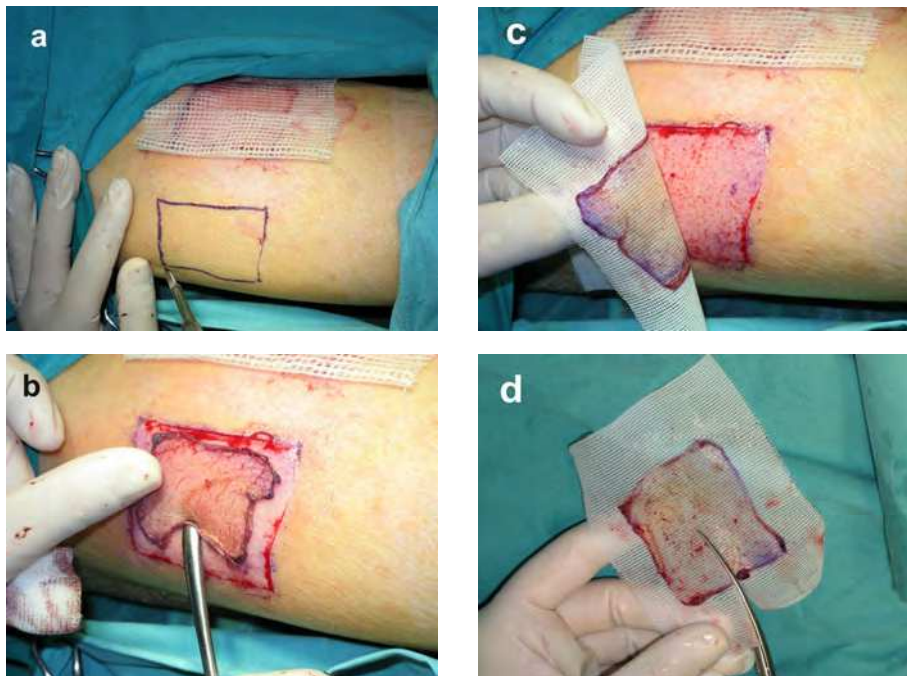


Fig. 6. (a) Markings on the thigh. (b) Harvesting the split-off graft. (c) Graft transfer. (d) Graft splitting. Explanation in the text.

The grafts, transferred to the recipient site may be implanted and fixed with sutures or applied to the wound with the transportation tulle, which then constitutes a part of the dressing (Fig.7a). The “split-off” epidermis may be combined, if necessary, with full-thickness grafts (Fig.7b).

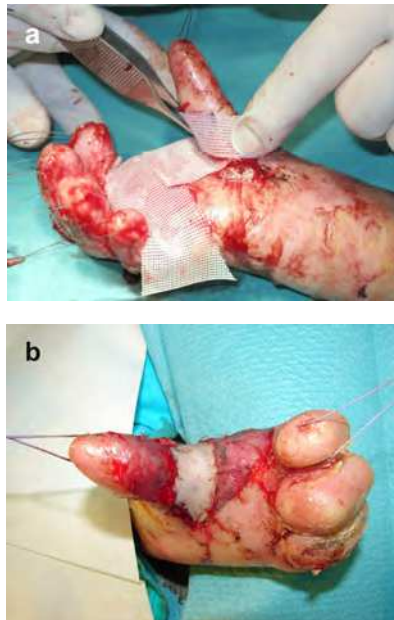


Fig. 7. (a) Grafts left with tulle. (b) Grafts sutured to their beds. Explanation in the text. Patients BB and CC respectively.

Prior to the application of further dressings, a polyurethane sponge is wrapped around the wrist (Fig. 8a). The subsequent dressings inserted into the web spaces are sutured to it (Fig.8b). The hand and fingers may be immobilized with an additional layer of thermoplastic splint applied on the palmar side.

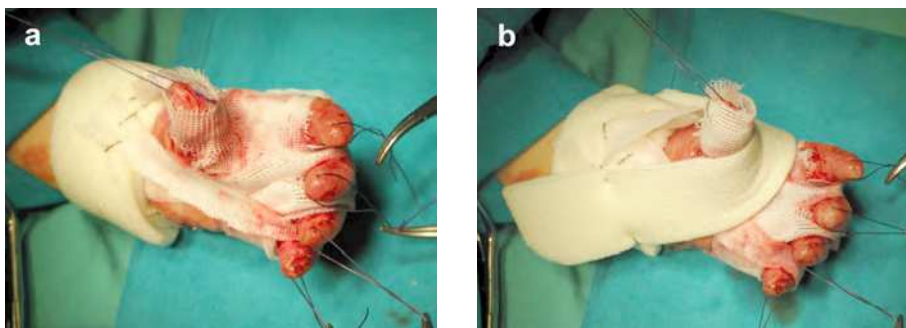


Fig. 8. (a) A sponge band wrapped around a wrist. (b) Dressings fixed to wrist band. Explanation in the text. Patient AA.

2.4.5 Postoperative dressings

The first dressing change after a week, requires the reservation of the operating room and general anesthesia. Before the removal of each dressing layer, it should be thoroughly

soaked in Betadine solution. The non-healed, and in some areas, macerated epidermis separates easily from its base (Fig. 9a). Only after it dries up does it adhere fully to the wound (Fig. 9b). The spot bleeding appearing locally may be blocked by touching with a moist swab with 40% solution of silver nitrate (Fig. 9c). The donor area of the collected "split-off" graft does not heal during this time (Fig. 9d).

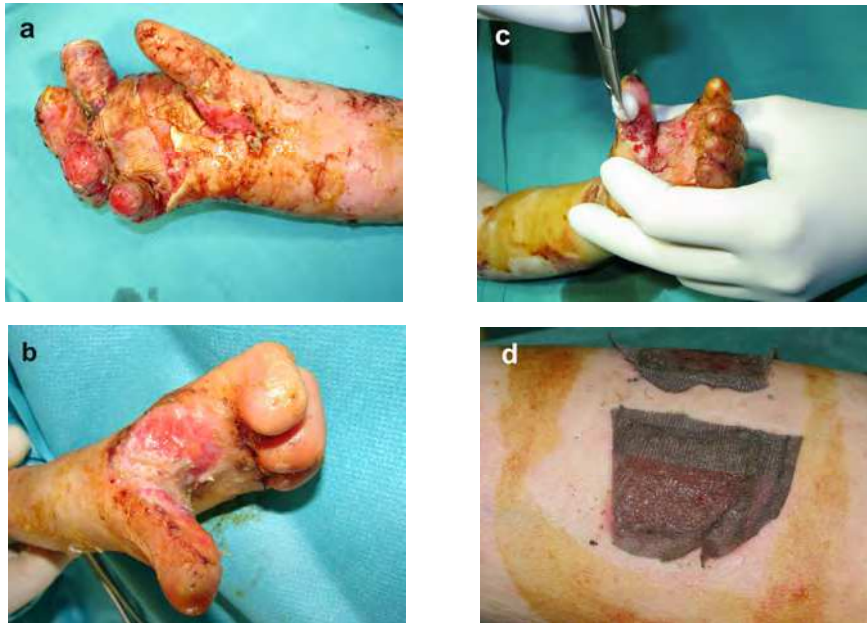


Fig. 9. One week after the operation. (a) Macerated epidermis, (b) Healing epidermis, (c) Minor bleeding, (d) Healing donor area. Explanation in the text. Patients BB, CC and AA respectively.

Both the donor area and the hand require new dressings that are made as described previously, using the greased (Fig. 10a) or silver impregnated tulle (Fig. 10b).

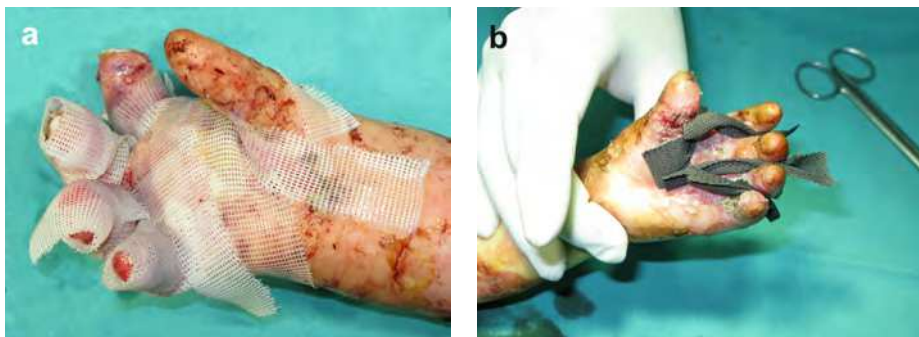


Fig. 10. One week after the operation. (a) Tulle dressing. (b) Silver tulle. Explanation in the text. Patients BB and AA respectively.

The dressing procedures at two weeks also require anesthesia in the operating room. The grafts, despite local maceration, are already clearly healed (Fig.11a). The dried up and macerated epidermis is not removed to avoid bleeding (Fig. 11b). Upon the application of new dressings, the hand is immobilized on the palmar side, with the use of a splint with thumb support (Fig. 11c). A properly adjusted thermoplastic splint further supports the extension of the fingers, even if they were left partly flexed during the operation (Fig. 11b). The “split-off” graft donor area is, by this time, already healed and does not require any dressing (Fig. 11d).

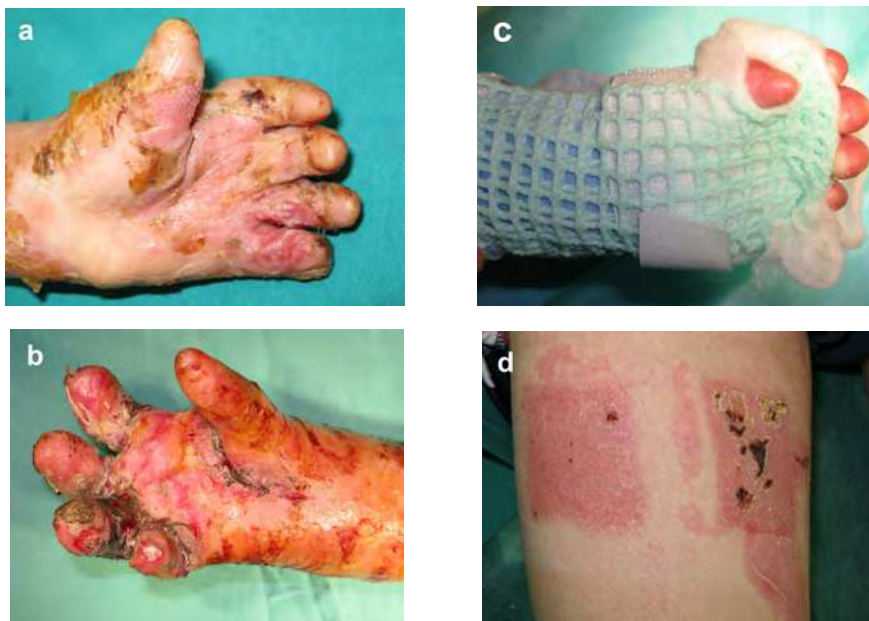


Fig. 11. Dressings at two weeks. (a) Local maceration. (b) Minor wounds. (c) Splint. (d) Healed donor area. Explanation in the text. Patients AA, BB and AA respectively.

After three weeks, most of the dressings may be changed in the dressing room without anesthesia. Minor wounds are present at that time only in patients in whom a decision was made to undertake a more extensive approach. These wounds are often associated with secondary injuries occurring during the removal of old dressings (Fig. 12a). The removal of subsequent dressing layers should therefore be preceded by the soaking of the hand in Betadine solution. From the third week post surgery, despite the presence of minor wounds (Fig. 12b - 12d), daily hygiene procedures should be performed in a home setting. Parents should continuously collaborate with the rehabilitation specialist. The dorsal thermoplastic hand splints with bands on the fingers are used from the third week until the end of the third month during the day and night. The daily application of the thermoplastic splint after dressing replacement may require an ongoing adjustment of its setting. Without parental cooperation, this adjustment would be impossible.

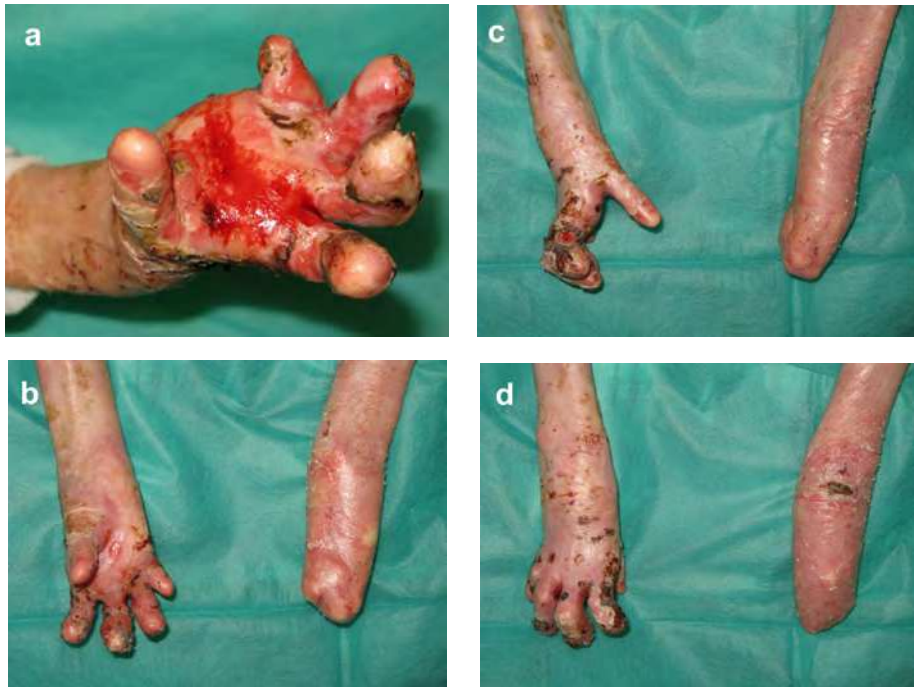

Fig. 12. Twenty one and twenty four days after the operation. (a) Accidental trauma. (b - d) Wounds healed. Explanation in the text. Patients BB.

In the authors' center, the results of 10 hands operated with the described limited approach currently exceed one year (Fig. 13a-13b). No early recurrence was noted within this time.

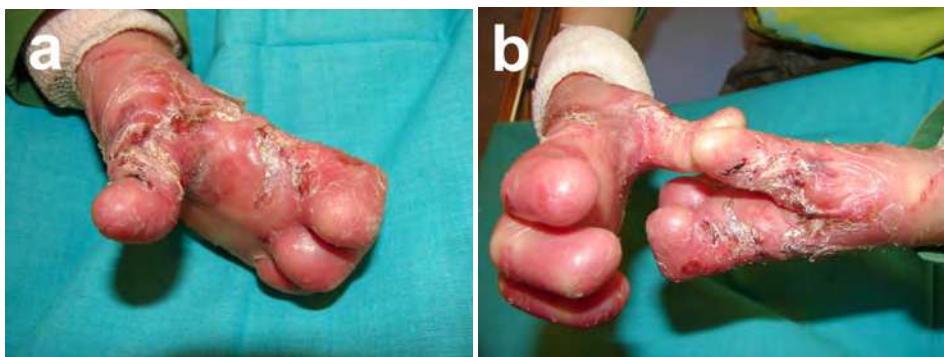

Fig. 13. (a) Left thumb six month after the operation. (b) Right thumb one year after the operation. Patient CC.

The observations indicate that, in comparison with other methods used in parallel, they do not differ significantly. However, this lack of a difference may be associated with the presented indications for surgery, which currently apply to all of the RDEB patients treated in the center. It appears that the treatment of early lesions enhances patient health, irrespective of the selected surgical method. Results of more extensive techniques may be good, even after many years (Fig. 14 a-b). Comparable early results of the limited approach may be similar (Fig.14 c-d). This benefit occurs with both lower financial outlays and decreased psychophysical burden.

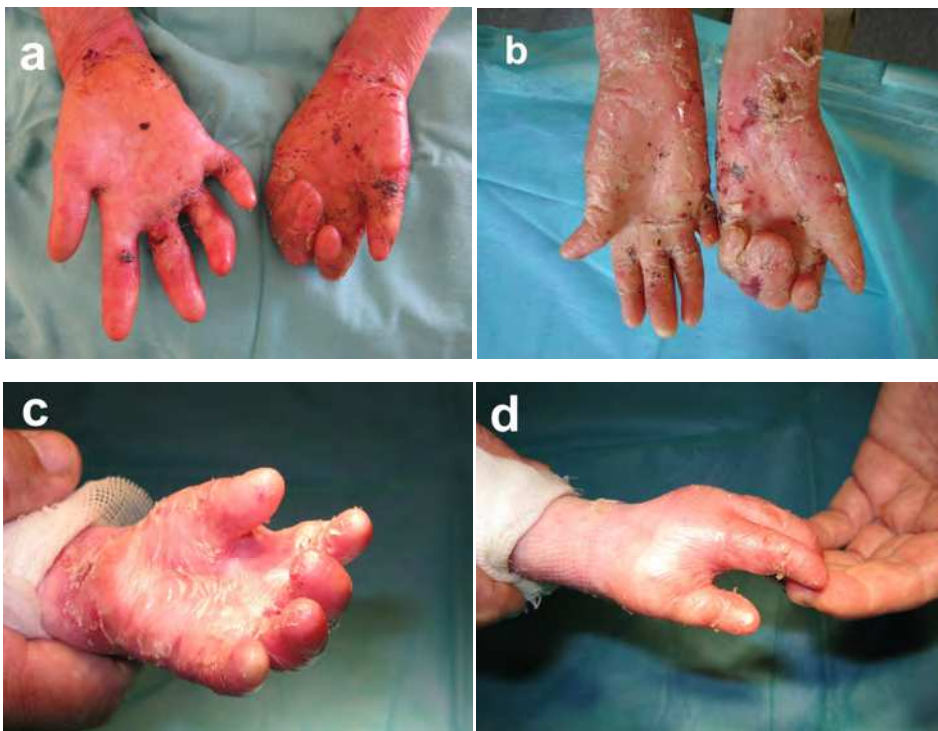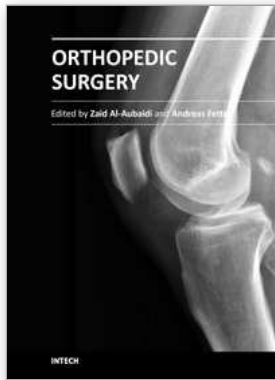


Fig. 14. (a-b) Right hand of the patient eight months and four years after the operation. (c-d) Patient after the limited surgery (patient AA), at eight months.

3. References

- Azizkhan RG, Denyer JE, Mellerio JE, González R, Bacigalupo M, Kantor A, Passalacqua G, Palisson F, Lucky AW. Surgical management of epidermolysis bullosa: Proceedings of the IInd International Symposium on Epidermolysis Bullosa, Santiago, Chile, 2005. *Int J Dermatol.* 2007;46(8):801-8.
- Bernardis C, Box R. Surgery of the hand in recessive dystrophic epidermolysis bullosa. *Dermatol Clin.* 2010;28(2):335-41, xi.
- Brandling-Bennett HA, Morel KD. Common wound colonizers in patients with epidermolysis bullosa. *Pediatr Dermatol.* 2010;27(1):25-8.
- Ciccarelli AO, Rothaus KO, Carter DM, Lin AN. Plastic and reconstructive surgery in epidermolysis bullosa: clinical experience with 110 procedures in 25 patients. *Ann Plast Surg.* 1995;35(3):254-61.
- Cuono C, Finseth F. Epidermolysis bullosa: current concepts and management of the advanced hand deformity. *Plast Reconstr Surg.* 1978;62(2):280-5.
- Devries DT, Johnson LB, Weiner M, Fine JD. Relative extent of skin involvement in inherited epidermolysis bullosa (EB): composite regional anatomic diagrams based on the findings of the National EB Registry, 1986 to 2002. *J Am Acad Dermatol.* 2004;50(4):572-81.
- Eisenberg M, Llewelyn D. Surgical management of hands in children with recessive dystrophic epidermolysis bullosa: use of allogeneic composite cultured skin grafts. *Br J Plast Surg.* 1998;51(8):608-13.
- Fine JD, Johnson LB, Weiner M, Stein A, Cash S, Deleoz J, Devries DT, Suchindran C. Pseudosyndactyly and musculoskeletal contractures in inherited epidermolysis bullosa: experience of the National Epidermolysis Bullosa Registry, 1986-2002. *J Hand Surg Br.* 2005;30(1):14-22.
- Fine JD, Mellerio JE. Extracutaneous manifestations and complications of inherited epidermolysis bullosa: part II. Other organs. *J Am Acad Dermatol.* 2009;61(3):387-402
- Fine JD, Mellerio JE. Extracutaneous manifestations and complications of inherited epidermolysis bullosa: part I. Epithelial associated tissues. *J Am Acad Dermatol.* 2009;61(3):367-84
- Fine JD. Inherited epidermolysis bullosa. *Orphanet J Rare Dis.* 2010;5:12.
- Fivenson DP, Scherschun L, Cohen LV. Apligraf in the treatment of severe mitten deformity associated with recessive dystrophic epidermolysis bullosa. *Plast Reconstr Surg.* 2003;112(2):584-8.
- Goldschneider K, Lucky AW, Mellerio JE, Palisson F, del Carmen Viñuela Miranda M, Azizkhan RG. Perioperative care of patients with epidermolysis bullosa: proceedings of the 5th international symposium on epidermolysis bullosa, Santiago Chile, December 4-6, 2008. *Paediatr Anaesth.* 2010;20(9):797-804.
- Jutkiewicz J, Noszczyk BH, Wrobel M. The use of Biobrane for hand surgery in Epidermolysis bullosa. *J Plast Reconstr Aesthet Surg.* 2010;63(8):1305-11.
- Ladd AL, Kibele A, Gibbons S. Surgical treatment and postoperative splinting of recessive dystrophic epidermolysis bullosa. *J Hand Surg Am.* 1996;21(5):888-97.

- Mellerio JE. Epidermolysis bullosa care in the United Kingdom. *Dermatol Clin.* 2010 Apr;28(2):395-6, xiv.
- Pfendner E, Uitto J, Fine JD. Epidermolysis bullosa carrier frequencies in the US population. *J Invest Dermatol.* 2001;116(3):483-4.
- Pohla-Gubo G, Hintner H. Epidermolysis bullosa care in Austria and the Epidermolysis Bullosa House Austria. *Dermatol Clin.* 2010;28(2):415-20, xv.
- Terrill PJ, Mayou BJ, Pemberton J. Experience in the surgical management of the hand in dystrophic epidermolysis bullosa. *Br J Plast Surg.* 1992;45(6):435-42.



Orthopedic Surgery

Edited by Dr Zaid Al-Aubaidi

ISBN 978-953-51-0231-1

Hard cover, 220 pages

Publisher InTech

Published online 09, March, 2012

Published in print edition March, 2012

Orthopaedic surgery is the widest and the strongest growing surgical specialty. It is clear, that the process of improving treatments and patients care, requires knowledge, and this requires access to studies, expert opinion and books. Unfortunately, the access to this knowledge is being materialized. As we believe that access to the medical knowledge should be reachable to everyone free of charge, this book was generated to cover the orthopaedic aspect. It will provide the reader with a mix of basic, but as well highly specialized knowledge. In the process of editing this book, my wife Jurgita has been, as usual, the most supportive person. I would like to thank her for being in my life. I would like to thank Mr. Greblo, the Publishing Process Manager, for all his help and last but not least thanks to our readers, as without them this book would have no meaning.

How to reference

In order to correctly reference this scholarly work, feel free to copy and paste the following:

Bartłomiej Noszczyk and Joanna Jutkiewicz-Sypniewska (2012). Limited Hand Surgery in Epidermolysis Bullosa, Orthopedic Surgery, Dr Zaid Al-Aubaidi (Ed.), ISBN: 978-953-51-0231-1, InTech, Available from: <http://www.intechopen.com/books/orthopedic-surgery/limited-hand-surgery-in-epidermolysis-bullosa>

INTECH
open science | open minds

InTech Europe

University Campus STeP Ri
Slavka Krautzeka 83/A
51000 Rijeka, Croatia
Phone: +385 (51) 770 447
Fax: +385 (51) 686 166
www.intechopen.com

InTech China

Unit 405, Office Block, Hotel Equatorial Shanghai
No.65, Yan An Road (West), Shanghai, 200040, China
中国上海市延安西路65号上海国际贵都大饭店办公楼405单元
Phone: +86-21-62489820
Fax: +86-21-62489821

© 2012 The Author(s). Licensee IntechOpen. This is an open access article distributed under the terms of the [Creative Commons Attribution 3.0 License](#), which permits unrestricted use, distribution, and reproduction in any medium, provided the original work is properly cited.