

# Paroxysmal Nocturnal Hemoglobinuria

Antonio M. Risitano

*Head of Bone Marrow Transplant Clinical Unit  
Department of Biochemistry and Medical Biotechnologies  
Federico II University of Naples, Naples  
Italy*

## 1. Introduction

Paroxysmal nocturnal hemoglobinuria (PNH) is a complex hematological disorder resulting in a quite unique clinical syndrome. In fact, the typical clinical presentation encompasses three distinct hematological manifestations, i.e., hemolytic anemia, bone marrow failure and thrombophilia (Dunn et al 2000; Parker & Ware 2003; Notaro & Luzzatto 2003). Thus, the term PNH covers only one feature of the disease – the one that is the most evident to patients, even if it does not reveal the actual clinical and pathophysiological complexity of the disease. The first extensive description of PNH was made by Dr. Strübing in 1882, although some cases could be identified even in older reports (maybe the first one dates back to 1678 by Dr. Schmidt from Gdanks). Remarkably, Dr. Strübing recognized the uniqueness of the clinical syndrome (hemolytic anemia with possible thrombosis), anticipating some of the pathophysiological implications that were unraveled decades later. In fact, he hypothesized that hemoglobinuria was due to “red blood cells which dissolve into the vessels” (corresponding to intravascular hemolysis in current terminology), possibly secondary to a “disordered blood production” of erythrocytes which are “abnormally sensitive” to acidification (namely, the production of blood cells with the aberrant PNH phenotype, that makes them susceptible to complement-mediated lysis) (Crosby 1951). However, it was with Marchiafava and Nazari (Marchiafava & Nazari 1911) in 1911 that the disease was recognized as a distinct medical entity, characterized by “chronic hemolytic anemia with perpetual hemosiderinuria”, subsequently known as the *Marchiafava-Micheli syndrome* (Micheli 1928); the current name “*paroxysmal nocturnal hemoglobinuria*” was eventually coined by Dr. Enneking in 1928 (Enneking 1928). In the last century, a number of reports on PNH were subsequently published because the puzzling nature of the disease has intrigued generations of investigators; however, PNH remained a mystery until the 1980s, when most of its pathophysiology was progressively elucidated, first with the description of the molecular defect of PNH cells, and then with the identification of the underlying genetic defect. By that time it was already known that PNH erythrocytes are exquisitely sensitive to lysis upon complement activation, both *in vivo* and *in vitro*. Thus, the observation that PNH cells lack from their surface some complement regulators, all included in a specific class of membrane-bound proteins (the so-called glycosyl phosphatidyl-inositol (GPI)-anchored proteins [GPI-APs]), clearly explained the reason for such sensitivity. Thereafter, the

biochemical pathway accounting for GPI-AP surface expression was described, as well as its impairment in PNH cells. Finally, the genetic lesion leading to the aberrant phenotype was identified in distinct mutations in the *phosphatidylinositol glycan class A (PIG-A)* gene. This formally demonstrated that PNH is a clonal hematological disorder characterized by the expansion of abnormal (GPI-AP deficient, *PIG-A* mutated) hematopoietic stem cells (HSCs) carrying an intrinsic defect, that accounts for the clinical phenotype of the disease. Nowadays most pathophysiological events occurring in PNH patients have been extensively described, even if definitive explanations for some disease manifestations (i.e., thromboembolic events) are still elusive. In the last few years, insights into the field pertain to the new treatment strategies that have drastically changed the management and clinical outcome of PNH patients. In fact, the availability of an inhibitor of the complement cascade – the actual effector mechanism of hemolysis in PNH – has led to the first etiological treatment for PNH, which seems to have a superb impact on the natural history of the disease.

## 2. Epidemiology

PNH is a rare acquired disease, with a worldwide prevalence estimated in the range of 1-5 cases per million (Rosse 1996; Orphanet 2004) regardless of the ethnicity; however, given the rarity of the disease and possible reporting biases, its incidence and prevalence remain largely unknown. Indeed, most reports deal with retrospective data, but formal epidemiological studies are lacking. A recent analysis from a well-defined geographical area (Hill et al 2006c) suggests that the actual incidence could be higher than previously reported, in the range of about 1.3/1,000,000/year, leading to a prevalence of about 15 cases per million in a 15 year observation period; however, these data may suffer from biases due to referral center, as well as to inclusion criteria (Parker et al 2005; De Latour et al 2008). In fact, a higher incidence might reflect the inclusion of patients with subclinical PNH, who have not been included in previous studies. In addition, geographical variations in PNH incidence should be considered; for instance, an increased prevalence is reported in some regions which also harbor higher incidence of aplastic anemia (e.g., Thailand and some other Asian countries) (Pramoonjago et al 1999). A multi-national prospective PNH registry is currently ongoing, and possibly will provide more definitive data on the actual incidence and prevalence of PNH in different geographical areas (Muus et al 2010). The incidence of PNH is similar in both genders, and most patients are diagnosed in their middle age (third or fourth decades), although cases have been reported in adolescents, children and even the elderly (De Latour et al 2008; Ware et al 1991).

## 3. Genetic basis

### 3.1 The GPI anchor and the *PIG-A* gene

The hallmark of PNH is hemolytic anemia secondary to the intrinsic susceptibility of affected red cells to complement activation (Ham & Dingle 1939; Rosse & Dacie 1966); thus, the presence of intrinsically abnormal blood cells is the cause of the disease phenotype. However, in PNH patients not all blood cells are affected, as they in fact present a mosaicism of normal and abnormal blood cells; therefore, a putative genetic cause was unlikely to be inherited or transmitted to the progeny. The clonal origin of PNH hematopoiesis was first demonstrated in 1970 by Dr. Luzzatto's group, who showed that, in

patients heterozygous for the glucose-6-phosphate-dehydrogenase (G6PD), affected red blood cells (RBCs) all share the same G6PD allele (which, on the other hand, is not involved in pathophysiology of the disease *per se*) (Oni et al 1970). Subsequently, the biochemical defect of PNH cells was identified in a specific molecular abnormality, consisting in the bizarre lack of several proteins from the cell surface. This peculiar defect was first described in the 1980s (Kunstling & Rosse 1969; Nicholson-Weller et al 1983; Selvaraj et al 1988), and rapidly became the hallmark of PNH, although its relationship with the pathophysiology of the disease remained obscure at that time. Notably, this abnormal phenotype pertained not only to erythrocytes, rather it included myeloid and megakaryocytic lineages too, suggesting that it derived from either multi-potent hematopoietic progenitors or even hematopoietic stem cells (Kinoshita et al 1985). Focusing on the underlying intrinsic abnormality rather than on the consequences of individual protein deficiency (which accounts for the susceptibility to hemolysis, as discussed later on), it became clear that all the proteins missing from the PNH cell surface shared a common mechanism responsible for their attachment to the cell membrane (Medof et al 1987). This is a specific glycolipid structure named glycosyl-phosphatidyl inositol (GPI) anchor (Mahoney et al 1992). The functional implications of the GPI-anchoring of proteins are not completely understood; they include ease of assemblage and shedding, lateral mobility, capping, involvement in endo-, exo-, and potocytosis (a clathrin-independent form of endocytosis and recycling). The strongest evidence that this type of membrane anchoring is important in cell biology is its high conservation among eukaryotic cells; indeed, it is found even in yeast and trypanosome. In 1993, using complementation of GPI-anchored protein deficient cell lines and expression cloning, Kinoshita and colleagues first isolated the cDNA of the *PIG-A* gene (Takeda et al 1993; Miyata et al 1993). *PIG-A* is a housekeeping gene located on the short arm of the X chromosome (Xp22.1); the organization of the genomic gene was described in 1994 (Bessler et al 1994). The *PIG-A* gene, in combination with at least two other proteins, encodes an enzyme essential to transfer N-acetyl glucosamine to phosphatidyl inositol; this is the very first step of the GPI-anchor biosynthesis (Armstrong et al 1992; Hirose et al 1992; Takahashi et al 1993). GPI-deficient cell lines showing defects in any of the various metabolic steps have been produced by experimental mutagenesis (Kinoshita et al 1995); however, the study of PNH has shown, at the very beginning surprisingly, that the same early step is impaired in all patients, and all patients have a mutation in the *PIG-A* gene (Takeda et al 1993, Luzzatto et al 1997, Nafa et al 1995). The present explanation for this finding is that among the various genes involved in the GPI-anchor synthesis, *PIG-A* may be the only one that is X-linked (Almeida et al 2009). As a consequence, a single mutation in that gene will produce an abnormal cell in either sex: males have only one allele and females have only one functional allele (as result of X-chromosome inactivation). Although females have two *PIG-A* alleles, only half of the mutation will occur in the functional X; thus, the risk of having the disease is the same in both genders. Since a defect causing a metabolic block is generally recessive, it is very unlikely (although not impossible) that a double mutation targeting both alleles of an autosomal gene in the same cell may occur *in vivo*. In keeping with this assumption, quite recently two kindreds harboring a mutation in the *PIG-M* gene were described (hence, with the genetic lesion inherited, not acquired). Indeed, all affected members did not develop PNH, but presented a quite distinct clinical syndrome characterized by a partial GPI deficiency associated with a propensity to thrombosis and seizures, in the absence of significant hemolysis (Almeida et al 2006).

### 3.2 *PIG-A* mutations in PNH

Direct sequencing of the *PIG-A* gene has demonstrated distinct mutations in all PNH patients (Luzzatto et al 2000; Nishimura et al 1999); in most cases, each patient has a single mutation (even if distinct *PIG-A* mutated clones may co-exist in some patients) and mutations are unique to each patient (private mutations). These mutations can be found in all blood lineages, consistent with a genetic lesion occurring in hematopoietic stem cell(s) (Takeda et al 1993; Endo et al 1995). All types of mutations have been observed (Nafa et al 1995; Nafa et al 1998): small deletions or insertions producing frameshift (the most frequent), nucleotide substitutions resulting in stop codon, large deletions, missense mutations causing amino acids substitutions or new sites for alternative splicing. No particular clustering of mutations has emerged, even if most of the mutations occur in exon 2, probably because it is the largest. If we compare the type of mutations found in PNH with those found in G6PD deficiency -- another (this time inherited) X-linked disorder of a housekeeping gene -- a clear discrepancy is evident. In PNH, a vast majority of mutations have extremely severe functional consequences, (i.e., production of truncated proteins, leading to a complete GPI deficiency -- the PNH type III phenotype), whereas missense mutations are rare (usually resulting in the PNH type II phenotype); in G6PD deficiency almost all mutations are missense, leading to single amino acid substitutions with conserved (although possibly altered) function. Two considerations may be relevant to this discrepancy: i. in inherited disorders, mutations in a housekeeping gene may be lethal, and thus have been selected to allow residual functional activity; by contrast, null mutations can be seen if they are somatically acquired, because they do not affect organ development and pertains only to a small fraction of somatic cells, which may survive albeit with some functional abnormality; ii. if missense mutations in PNH are rare, it means that the gene must be seriously damaged for leading to a clonal expansion. Indeed, the rare missense mutations found in PNH patients are associated with a marked reduction of GPI-linked proteins, indicating that they usually have affected either mRNA stability or protein function, or both. Remarkably, different types of mutations may account for different cell phenotypes in PNH patients, especially when the erythrocytes are considered. In fact, RBCs harboring a mutation leading to the complete inactivation of the *PIG-A* gene product will unequivocally show a complete deficiency of all GPI-APs from their surface (the so-called PNH type III phenotype). In contrast, mutations leading to partial inactivation of the *PIG-A* gene (for instance missense mutations) may lead to a partial deficiency of GPI-APs, known as the PNH type II phenotype. Of note, this biochemical finding has direct functional consequences; in fact, as discussed later on, type II and type III erythrocytes have a quite distinct susceptibility to complement-mediated lysis (Rosse & Dacie 1966). Quite surprisingly, some PNH patients may harbor at the same time type II and type III cells, suggesting that distinct *PIG-A* mutated HSCs may expand concomitantly (Endo et al 1995; Nafa et al 1998). Indeed, even phenotypically identical PNH cells may carry distinct *PIG-A* genotypes (Endo et al 1995; Nishimura et al 1997), suggesting that the functional phenotype rather than the specific genetic defect may play a major role in the development of the disease (Luzzatto et al 1997), as discussed below.

## 4. Pathophysiology

### 4.1 The dual pathophysiology theory

PNH develops through a somatic mutation in the *PIG-A* gene occurring in HSC(s), which originate progeny mature blood cells uniquely lacking of all GPI-APs from their surface.

PNH is therefore an acquired genetic blood disorder, that cannot be transmitted to the progeny; however, the *PIG-A* mutation is likely insufficient to cause the disease and additional events are thought to be involved (Rotoli & Luzzatto 1989).

#### 4.1.1 The *PIG-A* mutation is not sufficient for the development of clinical PNH

A number of observations support the idea that the *PIG-A* mutation itself is necessary, but not sufficient to cause PNH. In fact, the expansion of PNH cells over normal hematopoiesis remains a key step to develop the disease phenotype. These observations include both findings from tentative animal models of PNH, as well as findings from human individuals, with or without PNH.

*Murine models of PNH.* In order to explore experimentally the causal relationship between the *PIG-A* mutation and the development of PNH, murine models have been generated in the last few years to recapitulate human PNH (Rosti 2002). Initially, a complete knockout animal has been attempted, but it could not be produced due to fetal loss, demonstrating that *pig-a* is necessary for embryogenesis (Kawagoe et al 1996). Thus, a different strategy was devised, aiming to inactivate the mouse *pig-a* gene directly in embryonic stem (ES) cells, using the conventional knock-out gene targeting technique. Preliminary *in vitro* studies demonstrated that *pig-a* deficient ES cells were able to differentiate into mature cells of various hematopoietic lineages, thus showing that *pig-a* is not necessary for the differentiation and maturation of hematopoietic progenitors (Rosti et al 1997). However, when this approach was challenged *in vivo*, using chimeras obtained by inserting *pig-a* knocked out ES cells in early embryonic development, only a few chimeras survived (pointing out, once again, the pivotal role of the GPI-anchor for embryonic development), showing a low proportion of GPI-deficient blood cells at birth, which subsequently decreased with aging (Tremml et al 1999). These data support the theory that there was no absolute growth advantage for *pig-a* mutated cells as compared to normal cells coexisting in the same organism. Notably, the generation of a mouse model showing *in vivo* expansion of *pig-a* mutated hematopoiesis, thus better mimicking the human PNH disease, required a more sophisticated experimental approach (Keller et al 2001; Jasinski et al 2001). This included a conditional inactivation of the murine *pig-a* gene implemented using Cre recombinase and its specific recombination sites loxP; when the Cre/loxP system was targeted to the hematopoietic stem cells or the erythroid/megakaryocytic lineage using tissue-specific c-FES and GATA-1 regulatory sequences, respectively, the generation of mice having almost 100% of red cells with the PNH phenotype was obtained. However, even these mice do not really mimic the disease phenotype seen in humans, because PNH hematopoiesis tends to decrease over time (Jasinski et al 2001). Indeed, the conclusion from murine models is that the *pig-a* mutation is not sufficient itself to sustain the expansion of PNH-like hematopoiesis over time, suggesting the presence of additional causal factors.

*PIG-A mutations in human individuals.* *PIG-A* mutation may be identified in affected cells from all PNH patients, demonstrating a clear etiological role in the development of PNH. However, it is not true that all individuals who undergo inactivating mutations in the *PIG-A* gene develop clinical PNH. In fact, it has been shown that a few blood cells harboring the PNH phenotype (namely, a complete or partial deficiency in all GPI-APs) may be detected even in normal individuals, at a frequency of 10 to 50 cells per million (Araten et al 1999). This was possible thanks to an ultra-sensitive flow cytometry analysis (see above, diagnosis of PNH) of large numbers of circulating granulocytes or erythrocytes obtained from healthy

subjects. When these phenotypically abnormal cells were selected and studied at the genetic level, they revealed themselves to be clonal, and to carry specific *PIG-A* mutations (as demonstrated by a nested PCR technique) undistinguishable from those identified in PNH patients (Araten et al 1999). This clearly demonstrated that, *in vivo*, a *PIG-A* mutation was not sufficient to cause the disease, for at least two different reasons. First, to sustain clonal expansion, such mutations have to occur in multipotent HSC, while in most cases they statistically could pertain to cells without self-renewal capability, such as differentiated blood cells or committed hematopoietic progenitors. Second, a *PIG-A* mutation, even when occurring in a HSC, could simply confer a biological phenotype (the GPI deficiency) that requires additional, *PIG-A*-independent, conditions for further clonal expansion leading to the disease. The latter view is also supported by the observation that, at least in some patients, PNH hematopoiesis may include more than one abnormal clone. This was initially postulated based on the differential susceptibility of erythrocyte population to complement lysis (Rosse & Dacie 1966; Rotoli et al 1984), as subsequently demonstrated by flow cytometry (van der Schoot et al 1990), and finally confirmed by *PIG-A* sequencing (Endo et al 1996; Nishimura et al 1997)). In keeping, the expansion of distinct clones carrying the same, albeit molecularly heterogeneous, functional defect seems to suggest an expansion based on non-stochastic processes, such as selection, rather than a random process. This is also supported by the observation that relapse of PNH may be sustained by clones harboring *PIG-A* mutations different from those identified at diagnosis (Nafa et al 1998).

#### 4.1.2 Clonal expansion of the *PIG-A* mutated clone(s) and development of clinical PNH

This background raised the hypothesis of a dual pathophysiology for PNH: the *PIG-A* mutation is not sufficient to cause the disease, and requires a second, independent event (Rotoli & Luzzatto 1989). This theory is also known as the “relative advantage” (Luzzatto et al 1997) or “escape” theory (Young & Maciejewski 2000). According to this view, a mutation in the *PIG-A* gene might be a fairly common phenomenon, with no major biological consequences, because in physiological conditions the mutated cell has no reason for expanding in the presence of a vast majority of normal cells. In fact, no intrinsic proliferative advantage has been demonstrated in PNH hematopoietic progenitors in comparison to normal ones (Araten et al 2002). However, additional factors may alter this equilibrium, creating the conditions for the expansion of PNH clone(s), and possibly leading to the occurrence of a single *PIG-A* mutated stem cell sustaining hematopoiesis even for the rest of the patient’s life (Nishimura et al 2002; Nishimura et al 2004). The nature of such second event(s) can be of various origin, and distinct pathways -- not necessarily mutually exclusive -- have been postulated.

*An immune-mediated damage of hematopoiesis sparing PNH cells.* The well-accepted theory of PNH pathophysiology claims that such second event is a change in the microenvironment of hematopoiesis, leading to the selective expansion of the *PIG-A* mutated cells. It is quite accepted that such external factor, which does not affect the intrinsic features of the *PIG-A* mutated cells, is an (auto)-immune attack against hematopoiesis. Several clinical and experimental observations support the presence of such auto-immune attack in PNH; they include the well-known clinical overlap between PNH and aplastic anemia (AA, which is in most cases immune-mediated) (Lewis & Dacie 1967), as well as the direct demonstration of immune abnormalities in PNH patients. All these observations are discussed later on in this chapter. Indeed, normal and PNH cells are not different in terms of growth or survival, but PNH cells could be spared by immune-mediated damage, finally resulting in a progressive

consumption of normal hematopoiesis, with relative expansion of PNH hematopoiesis (Rotoli & Luzzatto 1989; Luzzatto et al 1997; Young & Maciejewski 2000). This was confirmed by gene expression profiling performed in normal and PNH HSCs: when CD34+ cells from PNH patients were separated according to the presence or absence of GPI-APs on their surface, distinct patterns of gene expression were identified. In fact, phenotypically normal (GPI-AP positive) CD34+ cells harbored diffuse abnormalities of their transcriptome, with over-expression of genes involved in apoptosis and immune activity, paralleling the findings seen in CD34+ cells of AA patients. By contrast, phenotypically abnormal PNH CD34+ (GPI-AP negative) showed a gene expression profiling closer to that obtained in CD34+ cells from healthy individuals (Chen et al 2005). Notably, normal and PNH CD34+ cells did not show any difference in the genes involved in growth or proliferation, rather suggesting the presence of sublethal extrinsic damage in phenotypically normal HSCs but not in their *PIG-A* mutated counterpart. Indeed, PNH cells ultimately expand as a result of a selective pressure that acts negatively on normal hematopoiesis; however, the molecular reasons underlying the “escape” still remain elusive. Contradictory data have been produced on a putative differential sensitivity to inhibitory stimuli between normal and PNH cells; susceptibility to apoptosis has been reported to be increased, normal or decreased in different models. It has been shown that human cell lines carrying the *PIG-A* mutation are less susceptible to NK-mediated killing compared to their normal counterpart (Nagakura et al 2002). In a more sophisticated model, GPI-deficient cells were not able to induce primary and secondary stimulation of both antigen-specific and alloreactive T cells, providing experimental support to the hypothesis that the PNH clone could inefficiently interact with the immune system (Murakami et al 2002). Indeed, the actual mechanisms causing the escape may include the absence of specific GPI-APs directly targeted by effector immune cells, or a protection due to the absence of important molecules involved in cell-cell interaction (e.g., accessory molecules). Alternatively, a broader impaired sensitivity to common effector mechanisms may be hypothesized, possibly due to the lack of GPI-APs or to non specific structural changes of the raft structure in the outer surface. Remarkably, the observation that patients with a B-cell lymphoproliferative disorder treated by alemtuzumab may develop expansion of GPI-deficient (PNH-like) T cells indirectly confirms the escape theory. Alemtuzumab is a monoclonal antibody that kills lymphocytes targeting the GPI-linked protein CD52; after treatment, CD52-negative lymphocytes may be found, which also lack all other GPI-APs. Once such lymphocytes are cloned, mutations in the *PIG-A* gene can be demonstrated; interestingly, the same mutation can be found also in a few cells from pre-treatment blood samples. In most cases these expansions are self-limiting and transient, and GPI-deficient T-cells gradually disappear after alemtuzumab discontinuation. Thus, this model elucidates most features of the PNH pathogenesis: the pre-existence of *PIG-A* mutated cells, their expansion only in the presence of a selective pressure negatively acting on normal cells (mutated cells are intrinsically resistant to alemtuzumab due to the absence of CD52), and the gradual disappearance of the mutated clone once the selective mechanism has been removed (Hertstein et al 2005). It has to be remarked that none of these alemtuzumab-treated patients developed PNH, because the expansion of GPI-AP deficient clones includes only mature lymphocytes and not multipotent HSCs (alemtuzumab does not kill HSC or hematopoietic progenitors, because CD52 expression is restricted to the lymphoid cells).

*Additional mutations conferring growing advantage.* The selective advantage of the *PIG-A* mutated clone could also be explained by a second (or a pre-existing) mutation of the

aberrant clone, which confers an absolute growth advantage. The most striking evidence supporting this theory is the observation that a few PNH patients may harbor, in the *PIG-A* mutated clone, an additional concomitant genetic lesion in the chromosome 12. This lesion was identified in a mutation in the 3' of the *HMGA2* gene, which leads to *HMGA2* over-expression and subsequent proliferative advantage (Inoue et al 2006). However, this mutation has not been found in larger series of PNH patients, making the pathogenic role of this lesion questionable. Clonal dominance of the PNH clone may also be due to other, still unknown, additional mutation(s) of the *PIG-A* mutated cells, possibly secondary to an intrinsic genetic instability of the abnormal clone. However, recent data exclude that *PIG-A* mutated cells have any increase in genetic instability. In fact, using the *PIG-A* itself as sentinel gene, the intrinsic rate of somatic mutation in PNH cells did not differ from that of normal cells, and it was remarkable less than that of cells with known genetic instability (i.e., Fanconi Anemia cells) (Araten et al 2007). Thus, these data argue against the possibility that PNH can be due to either a pre-existing genetic instability favoring the *PIG-A* mutation, or to a genetic instability secondary to the *PIG-A* mutation itself, which could predispose to additional genetic events necessary for PNH development. This is also supported, *in vivo*, by the clinical observation that malignant evolution in PNH patients is extremely rare, even if possible (Krause 1983; Devine et al 1987a); karyotypic abnormalities can be found in a few PNH patients, but in most cases they are transient and do not lead to leukemic transformation (Araten et al 2001). Remarkably, both MDS and truly leukemic cells not necessarily come from the *PIG-A* mutated clone; in fact, even more frequently they arise from the non-PNH, normal, residual hematopoiesis (van Kamp et al 1994; Araten et al 2001). Thus, the malignant evolution seems not related to any intrinsic feature secondary to the *PIG-A* mutation, but rather to the underlying bone marrow disorder, possibly including even clonal dominance itself.

*The neutral evolution theory.* More recently, a third possibility has been postulated, that even the expansion of the *PIG-A* mutated HSC could be a simple stochastic phenomenon, not requiring any additional event; this theory has been described as the “neutral evolution” hypothesis. According to the mathematic model provided by Dingli (Dingli et al 2008), given the stochastic nature of hematopoiesis (Notaro & Luzzatto et al 2010), a *PIG-A* mutation may randomly occur within the active HSCs pool, which in adults comprises about 400 cells, each replicating, on average, once per year. Subsequently, the expansion of the mutant clone may simply reflect the stochastic dominance of a few HSC, regardless of any functional feature (either absolute or conditional growth advantage), which may lead to a PNH clone size large enough to cause the disease. According to the authors, this model would fit the actual (expected) incidence of PNH (Hill et al 2006c). The chances that a single clone (even carrying a neutral mutation like the *PIG-A*) overcomes residual hematopoiesis increases with oligoclonal hematopoiesis, reconciling the model with the observation that clinical PNH mostly develop in patients with an underlying bone marrow failure.

## 4.2 Hematopoiesis in PNH patients

### 4.2.1 Marrow failure and PNH

As discussed later on, anemia is a typical presentation of PNH; however, cytopenias involving other blood lineages are also common in PNH patients. Cytopenia in these patients is mainly due to impaired production by the bone marrow, as confirmed by the



reduction in hematopoietic progenitors assessed by culture assays. In fact, it has been demonstrated that bone marrow from PNH patients show a significant reduction in all lineage-committed progenitors (CFU-E, BFU-E, CFU-GM, CFU-GEMM) (Rotoli et al 1984; Maciejewski et al 1997), as well as in stem cells/multi-potent progenitors (LTC-IC) (Maciejewski et al 1997). This was demonstrated in all PNH patients, regardless of their clinical presentation (see disease classification) (Parker et al 2005); namely, a subclinical marrow failure can be detected even in patients with hypercellular bone marrow. The functional impairment of the bone marrow may become clinically evident in a fraction of patients (at least one third), leading to mild cytopenia up to clinically significant bone marrow failure, seen as aplastic anemia (AA) (Lewis & Dacie 1967). In fact, many PNH patients may sooner or later develop frank aplastic anemia during the course of their disease (Hillmen et al 1995; Sociè et al 1996; De Latour et al 2008); conversely, AA patients may also develop PNH. Indeed, a substantial fraction of AA patients (up to 40%) may have detectable PNH clone (Nissen et al 1999; Mukhina et al 2001; Sugimori et al 2006; Scheinberg et al 2010), in most cases not large enough to cause evident hemolysis; however, the size of the PNH clone may vary over time, possibly leading to clinical PNH. Thus, PNH and AA are closely embedded (Dameshek 1967), and should be considered as different presentations of the same disorder rather than independent conditions. Furthermore, regardless of its clinical presentation, PNH must be considered by definition a bone marrow disorder because of its impairment of hematopoiesis, which is both quantitative (clinical or subclinical) and qualitative (the aberrant phenotype stems from the *PIG-A* mutated HSC). To some extent, PNH could be considered an attempt of the body to prevent the development of AA by rescuing hematopoiesis with PNH cells (Rotoli & Luzzatto 1989); in fact, the PNH clone ensures some mature blood cells, even if it leads to specific consequences secondary to the abnormality of the PNH cells (i.e., hemolysis and thrombophilia).

#### 4.2.2 Immune derangement in PNH patients

Given the clinical overlap between PNH and AA, it is reasonable to hypothesize that pathogenic mechanisms involved in AA may also play a pivotal role in PNH, representing the additional factor required for developing clinical PNH once a *PIG-A* mutation has occurred (without any specific chronologic order). The immunological mechanisms in idiopathic AA play a pivotal role in damaging the hematopoietic compartment, leading to HSC pool consumption or to functional impairment and subsequent pancytopenia (Young & Maciejewski 2000; Young et al 2006). A number of experimental observations supports the presence of an anti-hematopoiesis immune attack, although the target antigens are still undefined, as are the mechanisms leading to the breach in immune tolerance. Unknown triggers of autoimmunity induce a cellular immune response resulting in a preferential expansion of specific T cell clones that may damage the hematopoietic progenitors, directly or through indirect mechanisms, such as the production of inhibitory cytokines. Stem cell damage can be mediated by cytokine-transduced inhibition (mostly type I cytokines, such as interferon- $\gamma$  and tumor necrosis factor- $\alpha$ ), or by direct cell-mediated killing due to cytotoxic lymphocytes (CTLs) (reviewed in Young et al 2006). Such mechanisms, which may attack innocent bystander cells in addition to the primary target cells, ultimately result in apoptosis, the main key mechanism of HSC damage. Circulating and marrow CTLs have been demonstrated in vivo in AA patients, and their inhibitory effect on hematopoiesis has been documented in vitro (reviewed in Young et al 2006); this cellular immune response has

been dissected at the molecular level through the identification of *in vivo*-dominant T cell clonotypes, which are evidence of a pathogenic antigen-driven immune response (Risitano et al 2004). Since in PNH a similar antigen-driven immune response targeting marrow tissue may be postulated, investigators have evaluated the same pathways of the immune system for possible abnormalities. As for AA, evidence of immune derangement in PNH has been produced, mostly pointing out the pivotal role of cell-mediated immunity. In fact, oligoclonality of the T cell pool has been reported (Karadimitris et al 2000), and immunodominant pathogenic CTL clones may be detected in most PNH patients (Risitano et al 2004; Plasilova et al 2004). Notably, immunodominant T-cell clones identified in PNH patients may share highly homologous T-cell receptor beta (TCR-beta) sequences, and additional closely related sub-dominant T-cell clones may be identified, consistent with an antigen-driven public immune response (Gargiulo et al 2007). The observation that recurrent or highly homologous TCR-beta sequences may be identified regardless of the individual patient's HLA background (in contrast with what is seen in AA) (Risitano et al 2004), may also suggest that a non-peptidic triggering antigen may be involved, possibly related to the GPI-anchor itself (Gargiulo et al 2007). Functionally, these pathogenic T cells harbor an effector, cytotoxic phenotype, characterized by expression of CD8 and CD57. These effector lymphocytes also show an imbalance in the expression of the activating and inhibitory surface receptors; in fact, they tend to over-express the activating isoforms of inhibiting superfamily receptors, which elicit a powerful cytolytic activity (Poggi et al 2005). Notably, in some PNH patients these CTL clonal populations may expand to represent a subclinical (Risitano et al 2005) or even clinically meaningful LGL proliferations (Karadimitris et al 2001).

### **4.3 Hemolysis in PNH patients**

#### **4.3.1 The complement system**

The complement system is a key component of innate immunity, that has evolved to recognize both exogenous pathogenic microorganisms as well as injured self tissues, and to amplify adaptive immunity (Müller-Eberhard 1988; Holers 2008). The complement system encompasses distinct functional pathways with unique mechanisms of activation, which then all merge into a common final effector mechanism -- the cytolytic membrane attack complex (MAC). Thus, initiation of complement activation may occur along three different pathways - classical, alternative or lectin - which independently lead to activation of C3 and C5 convertases. While the classical and the lectin pathways require specific triggers to be activated, usually infectious agents, it has been known for decades that the complement alternative pathway (CAP) exhibits low-grade continuous activation due to spontaneous hydrolysis of C3 (the so-called tick-over phenomenon) (Pangburn et al 1981; Pangburn & Müller-Eberhard 1983). In addition, some components of the CAP constitute an amplification mechanism (the so called CAP amplification loop), which amplifies complement activation regardless of the specific pathway that initially generates the first C3b molecule. Fine mechanisms have evolved to control the complement system, including membrane-bound proteins (complement receptor 1 [CR1], membrane cofactor protein [MCP], and the membrane proteins CD55 and CD59) as well as fluid-phase components, including complement factor I (FI) and factor H (FH). Among these, CD55 and CD59 are of pivotal importance in PNH, given that they are normally expressed on blood cells through the GPI-anchor (Medof et al 1986).

### 4.3.2 Complement regulatory proteins and PNH erythrocytes

CD55, also known as Decay Accelerating Factor (DAF), is a 70-kd protein first isolated in 1969 (Hoffman 1969) and subsequently purified in 1982 (Nicholson-Weller et al 1982) which inhibits the formation and the stability of C3 convertase (both C3bBb and C4b2a) (Nicholson-Weller 1992). Historically, CD55 was the first complement regulator reported to be absent on PNH erythrocytes (Pangburn et al 1983(a); Pangburn et al 1983(b); Nicholson-Weller et al 1983) possibly accounting for the increased susceptibility of PNH erythrocytes to complement mediated lysis. However, further studies suggested that factors other than CD55 should also be involved, possibly acting downstream on the complement cascade (Medof et al 1987; Shin et al 1986). Subsequently, CD59 (also known as Membrane Inhibitor of Reactive Lysis, MIRL) was identified as an additional complement inhibitor expressed on normal erythrocytes, while PNH erythrocytes were demonstrated deficient in CD59 (Holguin et al 1989(a)). CD59 interferes with the terminal effector complement, blocking the incorporation of C9 onto the C5b-C8 complex, forming the membrane attack complex (MAC) (Meri et al 1990). Thus, independently from CD55 the lack of CD59 may explain complement-mediated hemolysis of PNH erythrocytes (Holguin et al 1989(b)). The hierarchical contribution of CD55 and CD59 to hemolysis suggests that CD59 is the key molecule which, if absent, leads to lysis (Wilcox et al 1991); in contrast, redundant mechanisms (including CD59 itself) usually overcome the isolated deficiency of CD55 (Holguin et al 1992). This is also confirmed by clinical observations: in fact, patients carrying the so-called Inab phenotype (an isolated CD55 deficiency, with normal CD59 expression) do not suffer from hemolysis (Telen & Green 1989; Merry et al 1992) whereas anecdotic cases of CD59 deficiency lead to a clinical phenotype undistinguishable from PNH (Yamashina et al 1990; Motoyama et al 1992).

### 4.3.3 Increased susceptibility of PNH erythrocytes to complement-mediated lysis in vitro and in vivo

It is intelligible that the deficiency of the complement regulatory proteins CD55 and CD59 renders PNH erythrocytes susceptible to uncontrolled complement activation and subsequent lysis.

*In vitro.* The very initial studies on PNH performed by Dr. Ham associated the hemolysis observed in PNH patients with an intrinsic susceptibility of red cells to complement activation *in vitro* (Ham 1937; Ham & Dingle 1939). In fact, the acidified serum assay (also known as the Ham test) - where the acidification activates the complement through the alternative pathway - became the standard technique for the diagnosis of PNH. The abnormality resulted intrinsic to patient erythrocytes, given that hemolysis occurs regardless of the origin of serum, while sera from patients do not result into the lysis of erythrocytes from normal individuals. This assumption was also confirmed in cross-transfusion studies (Rosse 1971). Since these initial studies it was evident that not all the erythrocytes drawn from a patient had the same susceptibility to complement-mediated lysis, making the point that all patients presented a mosaicism of normal and affected erythrocytes. Rosse and Dacie clearly elucidated that in erythrocytes obtained from PNH patients three different phenotypes could be identified, differing in their sensitivity to complement-mediated lysis *in vitro* (Rosse & Dacie 1966; Rosse 1973). The first phenotype had a normal (equal to that of erythrocytes from healthy individuals) sensitivity to complement, while abnormal cells could have a dramatic hypersensitivity to complement-

mediated lysis (15-25 times the normal one), or just a moderate hypersensitivity (3-5 times normal). These phenotypes are referred as PNH type I, type III and type II, respectively (Rosse & Dacie 1966; Rosse 1973); now we know that they correspond to a normal expression of GPI-APs (type I), or to a complete (type III) or partial (type II) deficiency of GPI-APs, as documented by flow cytometry (van der Schoot et al 1990). Notably, PNH patients may have either PNH type II or type III only, or may harbor a combination of both phenotypes. As anticipated, the proportion of the specific phenotype shapes the clinical manifestations of an individual patients (especially the extent of hemolysis), and may vary greatly not only among patients, but even in the same patient during the course of the disease.

*In vivo.* The *in vivo* consequence of the hypersensitivity of PNH erythrocyte to complement activation accounts for the most obvious manifestation of PNH, namely intravascular hemolysis and subsequent hemoglobinuria. Indeed, it is well known that PNH erythrocytes chronically undergo intravascular hemolysis in PNH patients *in vivo*, with a lifespan reduced to 10% compared to normal RBCs. This chronic hemolysis likely results from steady-state complement activation, due to the low-grade spontaneous C3 tick-over leads to chronic CAP activation on the PNH erythrocyte surface (Pangburn et al 1981; Pangburh & Müller-Eberhard 1983). It should be reiterated that both the initial complement activation and the down-stream effector mechanisms are uncontrolled on PNH erythrocytes. Specifically, the lack of CD55 impairs the regulation of C3 convertases (regardless the triggering pathway - classical or alternative) (Mold et al 1990), leading to increased C3 activation and further progression along the subsequent steps of the complement cascade. Thus on PNH erythrocytes -- due to the lack of CD55 -- the complement cascade activated by the CAP continues through to MAC assembly, finally coming to lysis for the lack of CD59. In this view, PNH can be considered mostly a CAP-mediated disease (Holers 2008); in real life, this physiological low-level complement activation is greatly amplified during inflammatory or infectious diseases. Indeed, overt hemolysis and paroxysms of PNH patients likely results from a specific triggering action on the complement cascade, which may occur along each of the three distinct complement pathways. There are no data demonstrating which is the complement pathway activated in specific conditions *in vivo* (i.e. infections); however one may speculate that all the three pathways may co-operate, with a possible hierarchical dominance of the CAP, given its capability to amplify any complement activation regardless the initial triggering pathway.

#### 4.4 Thrombophilia and PNH

In addition to hemolytic anemia and bone marrow failure, thrombophilia is the third typical manifestation of PNH; however, in contrast to the other two, much less is known about its pathophysiology. A number of possible mechanisms have been hypothesized, and some pieces of evidence have been provided, although the final mechanism remains speculative, possibly because it can be multifactorial. The clinical observation that thrombotic complications are more common in patients with larger PNH clones (Hall et al 2003; Grünewald et al 2003; Moyo et al 2004) and greater hemolysis may suggest that the pathogenic mechanism could be in some way embedded with complement activation (Markiewski et al 2007) and hemolysis itself. At least four distinct (but not mutually exclusive) mechanisms can be hypothesized. First, uncontrolled complement regulation on

platelet surface might lead to platelet activation and aggregation, enhancing clot formation (Gralnick et al 1995; Louwes et al 2001). Second, thrombophilia may directly result from hemolysis, due to the build-up of cell-free plasma hemoglobin released by the erythrocytes. This may occur through the ability of free hemoglobin to scavenge nitric oxide from plasma, blocking its inhibitory action on platelet aggregation and adhesion to endothelium, as well as its regulatory effect on vessel wall tone (Schafer et al 2004; Rother et al 2005). An other mechanism by which hemolysis might lead to thrombophilia includes the generation of procoagulant particles. In fact, microvesicles are known to be released in PNH patients upon hemolysis and complement activation from RBCs (Hugel et al 1999), WBCs (monocytes) and platelets, (Wiedmer et al 1993; Simak et al 2004) and even from the endothelium. However, even if their procoagulant action is commonly accepted (van Beers et al 2009), their specific role in the pathophysiology of thromboembolisms in PNH is not yet proven. The fourth possible mechanism of thrombophilia in PNH might be an impairment of the fibrinolytic system, due to the lack of membrane-bound urokinase-type plasminogen activator receptor (uPAR) -- which is GPI-linked, and to the excess of its soluble form (Ninomiya et al 1997; Sloand et al 2006).

## 5. Clinical features

PNH is characterized by a unique triad of clinical features: intravascular hemolysis, thromboembolic events and cytopenia (Dunn et al 2000; Parker & Ware 2003; Notaro & Luzzatto 2003). However, not all three manifestations are present in all the patients, and the individual presentation of each patient may greatly vary according to the most dominant signs and symptoms. Thus, many investigators have tried to classify PNH according to the most typical clinical presentations; however, distinct categories are hard to define for a disease with such an unpredictable presentation and evolution.

### 5.1 Classification

The most adopted classification of PNH was proposed by the International PNH Interest Group in 2005 (Parker et al 2005), whereby PNH patients are grouped according to the presence of hemolysis and of an underlying bone marrow disorder. Accordingly, three distinct subtypes are identified: i. classic PNH, characterized by hemolysis without other marrow disorder (i.e., hemolytic PNH patients without relevant cytopenia); ii. PNH in the setting of another bone marrow disorder, characterized by hemolysis associated with an underlying marrow disorder, usually AA or MDS (i.e., hemolytic PNH patients with cytopenia; AA or MDS may be concomitant or have preceded PNH); iii. subclinical PNH, characterized by the presence of PNH cells in the absence of any clinical or laboratory sign of hemolysis, in the setting of other hematological disorders (i.e., AA or MDS patients with GPI-AP deficient cells, but not clinical PNH). This classification does not completely take into account that, by definition, PNH carries an underlying bone marrow disorder, and as a result most PNH patients have cytopenia or some signs of marrow failure. In fact, a recent registry study (de Latour et al 2008) made the point that many PNH patients do not fit either one of the two major categories, and a fourth subgroup has been included (intermediate PNH, characterized by hemolysis and mild cytopenia not qualifying for the diagnosis of AA). However, even this classification seems to fail the goal of identifying patient subgroups with distinct clinical outcome (de Latour et al 2008). Some other groups have

used in the past a different classification (Notaro & Luzzatto 2003), where the category of AA/PNH patients is restricted to those with concomitant severe AA and clinically meaningful hemolysis, who require more intensive care and are supposed to have a worse prognosis. According to this classification, classic PNH patients are further grouped into hyperplastic and hypoplastic (based on peripheral counts and bone marrow analysis), AA/PNH patients are only those with severe marrow failure and concomitant clinically relevant hemolysis, whereas subclinical PNH patients are characterized by small PNH clone(s) (even with minimal signs of hemolysis) associated with either AA or thromboembolic disease (the latter are very rare cases with a clinical PNH that does not include relevant hemolysis).

## 5.2 Hemolysis

Hemolysis is the most typical manifestation of PNH, which by definition affects all patients with clinical PNH. However, the extent of hemolysis varies among patients, according to size of the PNH clone(s), type of PNH erythrocytes (type II versus type III), and possibly the level of complement activation (which may vary according to specific medical conditions or patient-specific features). Typically, hemolysis is chronic (secondary to the low-level spontaneous complement activation), with possible exacerbations (the paroxysms) consequent to a massive complement activation, often in association with infections or other triggering events. Hemolysis of PNH erythrocytes occurs in the vessels (intravascular hemolysis), and leads to a number of clinical consequences. The most evident sign to the patient is the hemoglobinuria, with the emission of dark urine, whose aspect is commonly defined as "*marsala wine*" or coke-like, according to the Country of origin of the observer and/or the time of the report (Parker 2002). The color of urine is not constant over time, with the most typical dark urine often seen in the morning (hence the name "*paroxysmal nocturnal hemoglobinuria*"); however, the patient's urine mostly range from dark yellow to orange and dark red, with very rapid variations during the day. Even if nocturnal CO<sub>2</sub> retention has been hypothesized as possible cause of plasma pH fall and subsequent complement activation (Ham 1937), the reasons underlying nocturnal exacerbation of hemolysis are not yet fully understood (unless first-morning hyperconcentrated urine is not by itself an explanation for evident hemoglobinuria). The typical biochemical marker of hemolysis is the increase in lactate dehydrogenase (LDH), which may be as high as tenfold the upper normal value; additional intra-erythrocytary components may also increase, such as aminotransferases (especially the alanine one). As in other hemolytic disorders, unconjugated bilirubin levels may increase, even up to frank jaundice; compensatory erythropoiesis is usually demonstrated by very high reticulocyte counts, even if the latter value greatly depends upon the underlying marrow function (patients with hyperproliferative PNH may show even 300000-400000 cell  $\times 10^9/L$ , while those with AA/PNH usually have less than 60000 cell  $\times 10^9/L$ ). Secondary iron deficiency may appear as a consequence of perpetual iron loss through urine. Clinically, the main consequence of continuous hemolysis is the development of anemia, and possibly other related symptoms such as asthenia and weakness. The extent of anemia is very heterogeneous among patients, also depending on other factors such as compensatory erythropoiesis (which may be impaired in patients with more severe marrow failure) or even iron/vitamin deficiency. As a result, anemia may be severe in some patients and requiring frequent transfusions, or

well-compensated in other cases, even with normal-like hemoglobin levels. Furthermore, anemia may greatly vary even in the clinical course of an individual patients, with sudden worsening or unexpected improvements in the absence of any known reason; anecdotic cases showing spontaneous remission of the disease have also been reported (Hillmen et al 1995; Sociè et al 1996; de Latour et al 2008). In addition to anemia, it is now accepted that hemolysis may induce by itself specific disabling symptoms. This is usually seen in concomitance with the typical “paroxysms” of PNH, which are massive hemolytic crises often triggered by specific conditions (e.g., infections, surgery). These disabling symptoms include malaise and fatigue, with possible painful crises; the latter are quite typical, and mostly involve the abdomen, mimicking an acute abdomen. Some patients also report lumbar or sub-sternal pain, headache, dysphagia (both painful and difficult swallowing) and erectile dysfunction (Rother et al 2005). PNH paroxysms are irregular and unpredictable in individual patients, although most show a quite regular recurrence in the long run period. However, some of these hemolysis-related symptoms (especially malaise and fatigue exceeding those expected based on the low hemoglobin level) can be also seen as a consequence of chronic hemolysis. All these symptoms, which significantly impact patient well-being, are thought to be due to smooth muscle dystonia secondary to local nitric oxide (NO) consumption by plasma free-hemoglobin (Rosse 2000, Moyo et al 2004, Rother et al 2005).

### 5.3 Bone marrow failure

The second key clinical feature of PNH is cytopenia; in contrast to erythrocytes, PNH granulocytes and platelets have anormal lifespan *in vivo* (Brubaker et al 1977; Devine et al 1987b); as discussed above, an underlying marrow disorder is embedded in the dual pathophysiology of the disease and with PNH clone expansion (Rotoli & Luzzatto 1989). Thus, some degree of marrow failure is common or even expected in PNH patients, ranging from mild cytopenias to severe aplastic anemia (Dunn et al 2000; Parker & Ware 2003; Notaro and Luzzatto 2003), and it may qualify for distinct disease categories (Parker et al 2005). Remarkably, the specific picture of each individual patient may change during the course of the disease, with patients initially presenting with normal marrow function and subsequently developing more severe marrow failure, as well as patients initially diagnosed with aplastic anemia subsequently developing frank hemolytic PNH (Tichelli et al 1992; Scheinberg et al 2010). Bone marrow failure usually becomes evident because of neutropenia and thrombocytopenia; however, it has to be remarked that marrow failure may also contribute to anemia in PNH patients. In fact, many PNH patients have a reticulocyte count that is inadequate to the hemoglobin level (iron deficiency may also contribute to that). The proportion of PNH patients with marrow failure ranges from 30 to 70% in different series, possibly because of heterogeneous definitions of bone marrow failure itself. The most homogeneous data from the French registry indicate that over 430 PNH patients 26% presented with normal counts (neutrophils  $> 1.5 \times 10^9/L$ , platelets  $> 120 \times 10^9/L$ ) at diagnosis, 52% were classified as AA/PNH (with at least two of the following: Hb  $< 10\text{gr/dL}$ , neutrophils  $< 1.0 \times 10^9/L$ , platelets  $> 80 \times 10^9/L$ ) and the remaining 22% as intermediate PNH (de Latour et al 2008).

### 5.4 Thrombophilia

The third typical manifestation of PNH is thrombophilia, with thrombosis developing in about 40% of all patients; accordingly, PNH is the medical condition with the higher risk of

thrombosis. Unfortunately, as the underlying pathogenic mechanisms are not fully understood, thromboses are largely unpredictable in PNH patients, even if according to most series they generally develop in patients with large clones and massive hemolysis (Hall et al 2003; Moyo et al 2004). The thrombotic risk is peculiar to each patient, possibly as a result of additional independent (environmental or genetic) risk factors that may shape the individual predisposition to thrombosis. For instance, inherited polymorphisms such as Factor V Leiden mutation and the 677 C>T methylenetetrahydrofolate reductase gene variant (as well as other polymorphisms leading to hyperhomocysteinemia) may have a relevant role, although this has not been proven so far (Nafa et al 1996). However, this concept has in some way been confirmed by the observation that the thrombotic risk is different in PNH patients with specific ethnicity; in fact, Asian patients have a lower incidence of thrombosis (Nishimura et al 2004), while Afro-Americans and Latin-Americans seem to have an increased incidence (Araten et al 2005). Thrombosis of PNH is quite unique, because it mostly occurs at venous sites which are unusual for other non-PNH-related thrombosis. Intra-abdominal veins are the most frequent sites, followed by cerebral and limb veins; other possible sites include dermal veins, the lungs - with pulmonary embolus - and the arteries - leading to arterial thrombosis. Thrombotic disease may be life-threatening and is the main cause of death for PNH patients (Hillmen et al 1995; Socie et al 1996; de Latour et al 2008). Typical severe presentations of thrombotic PNH include hepatic venous (Budd-Chiari syndrome) (Hoekstra et al 2009), portal, mesenteric, and renal vein thrombosis. Usually patients are asymptomatic, until clinical manifestations appear, especially pain; other signs and symptoms are specific according to the vessel involved (e.g., ascites, varices and splenomegaly in hepatic/portal thrombosis, or stroke in cerebral vein thrombosis). Unfortunately, pain is not a useful symptom by itself, because it may also be due to vessel wall dystonia or to a transient ischemic attack (especially of the intestine) rather than to true thrombosis. However, a thrombotic episode has to be suspected in all PNH patients with obscure pain, even when it may mimic acute abdomen; ultra sound scan and magnetic resonance imaging (especially angiography) are useful to rule out these dangerous complications. Recurrence after the first episode and/or development of chronic thrombotic disease is typical of PNH (Hillmen et al 1995; Socie et al 1996; de Latour et al 2008; Audebert et al 2005; Moyo et al 2004); this is especially common in the setting of the Budd-Chiari syndrome, when the thrombotic process initially affects small veins, and then progressively involves large hepatic veins, with the development of life-threatening manifestations like variceal bleeding, jaundice, ascitis and liver failure. At this stage, liver regenerative nodules may also appear, which may erroneously suggest the presence of hepatocellular carcinoma. Thrombosis of other splanchnic vein may usually lead to secondary ischemia and infarction, possibly leading to gangrene of the peripheral organ. Even if thromboses in PNH are unpredictable, recent data suggest that some biochemical parameters may work as surrogate markers of overt thrombophilia in PNH. They include D-dimers and other plasma markers of coagulation pathway activation, reactive fibrinolysis and endothelial cell activation (Helley et al 2010). However, their use has not been validated yet.

### 5.5 Other clinical manifestations

*Renal failure.* Both acute and chronic renal failure have been described in PNH patients (Nair et al 2008). Acute renal insufficiency is usually seen in concomitance with hemolytic crisis, as a result of massive hemoglobinuria. This condition is usually self-limiting and tends to



recover spontaneously in a few days after the resolution of the crisis, although specific interventions (even dialysis) may be needed in the acute phase. Chronic kidney disease (CKD) has also been reported; in a recent paper the incidence of clinically relevant CKD was estimated in the range of 20% (Hillmen et al 2010), but these data have not been confirmed by other groups (nor in previous large retrospective studies) (Hillmen et al 1995; Socie et al 1996; de Latour et al 2008). Pathophysiologically, CKD might be related to microthrombi of the renal vessels, as well as to renal cortex siderosis, which can be easily demonstrated in PNH patients by magnetic resonance imaging.

*Infections.* Infectious complications are common in PNH patients; they mostly pertain to cases with concomitant marrow failure, as a direct consequence of neutropenia. However, they could also be related to some functional impairment of PNH neutrophils and monocytes, and especially of their oxidative response - which is necessary for microorganism destruction - as documented by some *in vitro* data (Cacciapuoti et al 2007).

*Pulmonary hypertension.* Pulmonary hypertension (PH) has also been reported as possible complication of PNH by a single group (Hill et al 2006b); however, the clinical relevance of this observation remains to be confirmed in larger studies.

## 5.6 Pregnancy

Pregnancy is a specific issue which deserves an appropriate discussion in the setting of PNH. In fact, pregnancy in PNH certainly carries a high risk of complications for both mother and fetus. The main cause of complications is thrombophilia, which obviously worsens during pregnancy, and may lead to any of the thrombotic presentations described above. Additional risks may be related to suboptimal hemoglobin levels that hamper normal fetal development, as well as to cytopenia secondary to marrow failure, which may lead to infectious and hemorrhagic complications. It has to be remarked that, as for AA, pregnancy rarely causes worsening or recurrence of underlying bone marrow failure. A recent review (Fieni et al 2006) collecting 43 patients reported between 1965 and 2005 estimated the range of maternal and fetal mortality to 11.6% and 7.2%, respectively, which is quite lower than what previously thought. All the deaths were due to thrombotic complications, including fetal loss secondary to placental vein thrombosis; no case of fetal malformation was reported. Other major maternal complications included hemorrhage and infections; the most common fetal complication was pre-term delivery due to maternal complications (including placental vein thrombosis). On the other hand, pregnancies with successful outcome in the absence of any complication have also been described. Thus, caution should be advised in counseling PNH women about a possible pregnancy, for both maternal and fetal risk. Regardless of the absolute contraindication to pregnancy (which could be re-discussed in the era of new treatment strategies), pregnancy in PNH remains a high-risk medical condition which requires an experienced caring team.

## 6. Natural history

The natural history of PNH is quite unpredictable, given the very heterogeneous disease presentation and evolution. In fact, some patients may live with the disease for decades, without major complications, whereas some others present with life-threatening medical complications, which in any case may develop at any moment during the course of the disease. Thus, the evolution and outcome of an individual patient is largely unpredictable.

Despite the rarity of the disease, some information from large series is available, although it might suffer from possible selection biases (e.g., exclusion of patients with early death due to dramatic presentation, such as lethal thrombosis) (Hillmen et al 1995; Sociè et al 1996; de Latour et al 2008). Median survival was estimated above 10 years in the past decade in two independent series, with one fourth of patients surviving longer than 25 years (Hillmen et al 1995; Sociè et al 1996); more recently, the update of the French registry has revealed a median survival of about 22 years from diagnosis (de Latour et al 2008). Notably, these changes in median survival refer to the years before the introduction of the anti-complement therapy, and survival improvement was time-dependent (10-year survival was 63%, 76% and 92% according to diagnosis before 1995, 1995-2005 and after 2005, respectively), suggesting a relevant improvement in supportive care. Survival does not differ according to disease category: in fact, 10-year overall survival was 75%, 82% and 74% in classic PNH, intermediate PNH and AA/PNH, respectively. The main causes of death were thrombosis (cerebral thrombosis 25%, Budd-Chiari 23% - expressed as percentage of all deaths) and infectious complications (25%); they were both major causes of morbidity too. Even if PNH is not a malignant disease, progression to myelodysplastic syndrome and acute leukemia was observed with a 10-year cumulative incidence of 3.8%, which is similar to previous series (Hillmen et al 1995; Sociè et al 1996; Fujioka & Asai 1989) and to that reported for AA patients. Thrombosis developed in about 50% of classic PNH and 30% of intermediate PNH or AA/PNH patients; marrow failure developed in about 25% of classic and intermediate PNH patients. In the whole series, thrombosis was the main negative prognostic factor, followed by development of by- or pan-cytopenia, lower hemoglobin levels and previous diagnosis. Thrombosis affected long-term survival in all disease categories, including AA/PNH; risk factors for the development of thrombosis included thrombosis at diagnosis, old age, transfusion and lack of immunosuppressive treatment, and PNH clone size. Recurrent infections affected up to 40% of patients, representing the second main clinical complications of PNH; hemorrhage was an other relevant complication, especially in thrombocytopenic patients. Thus, even if most PNH patients may have a quite long life expectancy, the course of their disease may be stormy, with frequent hospitalizations, possible comorbidities and subsequent impaired quality of life. On the other hand, some patients may experience an indolent course, without major complications; a few PNH patients may also undergo spontaneous clinical remission of their disease, which can be estimated in about 5% (de Latour et al 2008) (even if an older study reported up to 15%, possibly due to definition bias) (Hillmen et al 1995). It has to be underlined that these data on the natural history of the disease might significantly change in the current era of effective anti-PNH treatment, mainly eculizumab or even bone marrow transplantation.

## 7. Diagnosis

PNH has to be suspected in patients showing mild to severe anemia with moderate reticulocytosis, elevated serum LDH and possibly mild jaundice, with negative Coombs test; all these clues suggest a non-immune hemolytic anemia. The occurrence of dark urine and urinary hemosiderin, both evidence of intravascular hemolysis, strongly support the suspect of PNH; haptoglobin is usually very low or undetectable. Additional signs to be considered are the presence of mild to severe leuko-thrombocytopenia and/or a history of thromboembolic events of unknown origin, including cerebrovascular accidents. In specific conditions, PNH may be considered even in the absence of clinically evident hemolytic

anemia, such as in patients with AA or those showing recurrent thromboembolic events in the absence of documented risk factors; all these patients may deserve a careful screening for PNH. Diagnostic tests for PNH have much changed in the past three decades: the Ham test, which was the diagnostic test until the 1980s, has been completely replaced by flow cytometry.

### **The Ham test**

Historically, the Ham test, also known as acidified serum assay, was since its identification in the 1930s the best test to diagnose PNH. Indeed, even the pathophysiological definition of PNH is based on the increased susceptibility of affected erythrocytes to complement mediated lysis (Rosse & Dacie 1966; Rosse 1991). The Ham test is an *in vitro* assay which employs this unique feature of PNH erythrocytes, testing the lysis in sera where the complement cascade (and specifically the complement alternative pathway) has been activated by pH lowering (by the addition of HCl). In these conditions, erythrocytes from PNH patients show a substantial lysis, which may vary according to the proportion of affected (*PIG-A* mutated) cells and to the type of mutation (type I versus type II PNH). Hemolysis occurs in both autologous and ABO-matched sera; as a control, lysis does not occur if the serum has been inactivated at 56° C (which inactivates some complement components), or when erythrocytes from healthy individuals are tested. In experienced hands, the test is relatively simple, and quite specific; however, its sensitivity is limited, with a threshold of about 5-10% PNH erythrocytes required for a definitive diagnosis. Other lysis assays exist, such as the sucrose lysis (or sugar water test); they exploit reduced ionic strength rather than acidification-based complement activation. However, their sensitivity and specificity for PNH are worse than those of the Ham test, and false positive may be common in other inherited hemolytic conditions. Obviously, all these lysis assays may only detect the presence of PNH erythrocytes, but cannot be utilized to detect cells with a PNH phenotype within any other blood lineage.

### **Flow cytometry**

At present the diagnosis of PNH is based on flow cytometry analysis of blood cells (Parker et al 2005; Richards et al 2002); the high sensitivity and specificity of this analysis has made the Ham and similar tests obsolete. In fact, fluorochrome-conjugated monoclonal antibodies specific to several GPI-APs expressed on the various blood cell lineages are available for routine testing; thus, simultaneous multi-parameter analysis allows accurate detection of GPI-AP deficient cell populations, measuring their extent within each blood lineage (erythrocytes, granulocytes, monocytes and lymphocytes). By this technique, one or two erythrocyte populations with abnormal expression of GPI-APs may be found in PNH patients: one completely lacking GPI-AP expression (type III PNH cells), and another characterized by GPI-AP faint (dim) expression (type II PNH cells). These findings match the observation initially made by Dr. Rosse, demonstrating the presence of distinct subpopulations of erythrocytes with different sensitivity to complement-mediated lysis (Rosse & Dacie 1966); as discussed above, this may also imply that different populations may be genetically different. The demonstration of GPI-AP deficient populations is easy for all cell lineage, even if discrimination between type II and type III PNH cells is more difficult for white blood cells; antibodies specific for GPI-APs selectively expressed by specific cell lineage may render the test more sensitive and specific. Different panels of monoclonal antibodies have been proposed by different groups (Richards et al 2000;

Borowitz et al 2010); they usually include CD55 and CD59 for erythrocytes, CD66b, CD66c and CD24 for granulocytes, CD14 or CD48 for monocytes, CD48 or CD59 for lymphocytes. A counter-staining for gating strategies on specific blood cell populations may be included; in fact, a complete testing for PNH includes the analysis of erythrocytes, granulocytes, monocytes, and possibly lymphocytes (even if they are usually minimally affected, because most of them are long-living cells sustained by peripheral homeostasis). Platelets are usually not tested for PNH phenotype, due to the difficulty to separate normal platelets from PNHs (Maciejewski et al 1996; Vu et al 1996). The simultaneous absence of different GPI-linked proteins on the same cells validates the specificity of the test; as far as the sensitivity is concerned, flow cytometry analysis in experienced hands may detect even very small PNH clones (below 1% in routine testing, (Borowitz et al 2010) up to 0.01% in ultra-sensitive analysis for research purpose) (Araten et al 1999; Sugimori et al 2006). More recently, the novel fluorescent reagent aerolysin (FLAER), which specifically binds to the GPI anchor, showed even greater sensitivity for the detection of small PNH cell population, up to 0.01% as a single marker (Brodsky et al 2000; Sutherland et al 2007). FLAER can be easily combined with other monoclonal antibodies for a comprehensive and simultaneous study of all blood leukocytes. However, given that FLAER requires to be processed by proteolytic enzymes expressed on leucocyte surface, it cannot be utilized to detect PNH erythrocytes or platelets.

### **Molecular studies**

Molecular studies on DNA or mRNA, aimed to identify the specific causative mutation within the *PIG-A* gene, are usually considered superfluous rather than confirmatory. In fact, they do not add any clinically informative data and can even be somewhat misleading. Indeed, a false negative result may occur, especially when mononuclear cells are used as nucleic acid source (proportion of PNH lymphocytes are minimal in the majority of patients), or in case of some intronic mutations; on the other hand, false positive results may also occur due to the intrinsic sensitivity of the technique. Notably, molecular studies do not deliver the most relevant information as flow cytometry-based assay, which is the exact proportion of affected GPI-deficient (thus *PIG-A* mutated) cells. Thus, molecular testing is not recommended for the diagnosis of PNH.

### **Blood**

The blood film is usually not very informative in PNH patients. Red blood cells are usually macrocytic due to reticulocytosis (which can be demonstrated by vital dyes), but cell size may greatly vary. Polychromatophilic or even nucleated erythrocytes may be present as a result of compensatory erythropoiesis. Microcytic hypochromic erythrocytes may also be present, because of the secondary iron deficiency; red cell fragments may be observed, especially in concomitance with thrombotic complications. Leukocytes do not show any abnormality, even if neutropenia is commonly seen in patients with AA/PNH; thrombocytopenia is also quite frequent.

### **Coombs test**

The differential diagnosis of PNH includes all other hemolytic conditions; thus, the Coombs test should be performed as initial assay. By definition, the Coombs test is negative in PNH, as it is a non-immune hemolytic anemia. However, it has to be remarked that a positive Coombs test may result from allo-immunization secondary to transfusion. More recently, it has been shown that a C3-only positive Coombs test may develop in most PNH patients on

eculizumab treatment (Risitano et al 2009a); this finding is not due to any antibody, but rather it derives from mechanistic reasons that will be discussed later on.

### **Bone marrow**

The bone marrow pattern may be significantly different according to the presentation of the disease. In fact, patients with classic PNH may present with hyperproliferative bone marrow, and markedly increased erythropoiesis; however, due to the underlying bone marrow disorder, they may also present normal or even reduced marrow cellularity. The latter pattern is typical in AA/PNH patients, where cellularity is below 30%, as assessed by trephine biopsy. Commonly, morphological abnormalities may be observed, sometimes leading to the misdiagnosis of MDS; it has to be underlined that in most cases such abnormalities are not specific and simply reflect the stressed erythropoiesis. Additional tests can be performed on bone marrow specimens. Cytogenetic studies may occasionally reveal karyotypic abnormalities, which may occur in either PNH or normal cells; however, they do not necessarily carry a bad prognosis as for MDS (Araten et al 2001). Flow cytometry may be used to rule out leukemic transformation; given that surface expression of most GPI-APs undergoes changes during differentiation and maturation, bone marrow flow cytometry is not recommended for the diagnosis of PNH.

### **Urine**

Even a macroscopic observation of urine may be a useful tool for the diagnosis of PNH; in fact, eye-evident hemoglobinuria may be one of the clinical presentations. Plasma free hemoglobin secondary to intravascular hemolysis depletes haptoglobin; as a result, free hemoglobin is continuously present in the glomerular filtrate. The excess hemoglobin is partially reabsorbed in the proximal tubule, and the iron stored as intracellular ferritin granules easily detected in the urine cast by appropriate iron (Perl's) staining - as hemosiderin granules. Hemosiderinuria is constantly present in all hemolytic PNH patients (even in the absence of hemoglobinuria, which fluctuates according to the concomitant hemolysis), thus it still represents an easy test to support the initial suspect of PNH.

### **Other instrumental studies**

The management of PNH patients may require many other laboratory and instrumental studies useful to investigate the evolution of the disease and its possible complications. They especially include all the techniques useful to assess the presence of possible thrombosis; according to the specific sites, the most useful are computed tomography or magnetic resonance based, (for the cerebral and sometimes the hepatic districts), or ultra-sound based (for the abdomen and limbs). Specific angiographic studies are always helpful, especially once a thrombotic episode has been demonstrated (and always for the assessment of the cerebral district), to better assess the extent of the clot and its evolution. All these studies should be performed without delay, at diagnosis and/or in the presence of specific symptoms.

## **8. Treatment**

The treatment of PNH is driven by the specific disease presentations (Brodsky 2009; Luzzatto et al 2011); however, in most cases treatment is essentially supportive, aiming at living with the disease with the least clinical burden. Thus, the main goals of PNH treatment

includes the control of anemia and possibly of hemolysis; in patients with either marrow failure or thrombosis additional specific treatments are needed. Given the chronic course of PNH, an other major goal is the prevention of possible complications, mainly thrombosis and infections, to ensure long-term survival. More recently, etiological treatments for PNH have become available with the introduction of the first anti-complement agent, the anti-complement component 5 (C5) eculizumab. Finally, the only curative option for PNH is allogeneic stem cell transplantation.

### **8.1 Supportive therapies**

The supportive treatment of PNH aims to control the main clinical manifestations of the disease; thus, it can be split according to specific manifestation – hemolysis and subsequent anemia, bone marrow failure and thrombocytopenia.

#### **8.1.1 Management of hemolysis and anemia**

Hemolysis and subsequent anemia are the hallmarks of PNH, affect most PNH patients and often require specific treatment. Unfortunately, until the new millennium there was no specific option for controlling hemolysis. Steroids were broadly used as chronic administration or for acute hemolytic crises, without any proof of efficacy. Indeed, some investigators claimed that steroids are useful in controlling chronic complement-mediated hemolysis (Issaragrisil et al 1987; Bourantas 1994) and, even more, paroxysmal crises likely interfering with complement activation and/or the underlying conditions (i.e., inflammation) triggering the complement cascade; however, so far no mechanism of action has been provided. It has been suggested that steroids might ameliorate patient well-being even in the absence of any direct control of hemolysis (Parker et al 2005); in particular, they may be effective in improving the symptoms associated with paroxysmal crises, such as dysphagia and abdominal pain, although this effect in most cases may result from the self-limiting behavior of the paroxysms. However, a continuous use of steroids is discouraged in PNH patients, given the long-term toxicity of chronic steroidal therapy; a short-term use in presence of the paroxysms is not harmful but likely useless. Androgens have been utilized as well, with limited benefit (Harrington et al 1997); however, given their potential utility in stimulating erythropoiesis and especially megakaryocytopoiesis (Katayama et al 2001), they are primarily indicated in the presence of marrow impairment rather than to control hemolysis (see below). Once again, a risk-to-benefit evaluation should be specifically made for all individual cases, given that liver toxicity, virilizing action and other side effects have to be considered; in addition, some concerns about a potential increase in the Budd-Chiari syndrome have been raised by some physicians (Parker et al 2005). Regardless of the possibility to block hemolysis, in many patients anemia leads to clinically relevant symptoms requiring specific interventions. As remarked in the pathophysiology section, anemia of PNH patients is somehow multi-factorial; thus, if the main contributor (hemolysis) cannot be affected, one may try to interfere with the additional mechanisms to improve hemoglobin levels. Besides hemolysis, the main factor affecting hemoglobin level is the bone marrow function, especially its capability to adequately compensate the ongoing hemolysis. By definition, erythropoiesis is usually impaired in patients with AA/PNH syndrome, who may require specific treatments (see below); however, ineffective erythropoiesis is commonly seen even in classic PNH patients. Given the perpetual hemosiderinuria, iron deficiency is common in PNH patients (Luzzatto et al 2011), and

simple iron supplementation may increase hemoglobin levels in many patients. Similarly, vitamin B12 and folate supplementation are usually indicated to sustain the compensatory erythropoiesis secondary to hemolysis (Luzzatto et al 2011). Erythroid stimulating agents, essentially recombinant erythropoietin, may also help enhance erythropoiesis (Stebler et al 1990; Bourantas et 1994), especially in cases showing inadequate production of endogenous erythropoietin (McMullin et al 1996). Paradoxically, all these strategies may be of limited clinical benefit, because of the increased hemolysis (and hemolysis-related symptoms) resulting from the production of PNH erythrocytes susceptible to complement-mediated lysis. Notwithstanding these interventions, moderate to severe anemia may develop in a substantial proportion of PNH patients, for whom transfusions are the main strategy to control anemia. RBC transfusions are given to PNH patients according to their hemoglobin level; as for other chronic anemic patients, transfusions should be administered to maintain hemoglobin levels above 8 gr/dL. Transfusions transiently improve anemia-related symptoms, as well as hemolysis-related symptoms (the production of PNH erythrocytes temporarily decreases by effect of the higher hemoglobin levels). Remarkably, in contrast to other transfusion-dependent patients, iron overload is usually not a transfusion-related complication in PNH, given the massive iron loss through urine; this may change in PNH patients receiving transfusions during eculizumab treatment (Risitano et al, 2009b). However, as in other transfusion-dependent patients, refractoriness to transfusion may develop, mostly due to allo-sensitization. Refractoriness to transfusions was considered a severe complication requiring alternative treatment – even stem cell transplantation; however, nowadays it is not necessarily a severe complication, given the availability of the anti-complement treatment by eculizumab. Eculizumab has also dramatically changed the management of hemolysis for all PNH patients with meaningful hemolysis, as discussed later on.

### 8.1.2 Management of marrow failure

The management of marrow failure in PNH patients is the same as for AA patients, and represents the main challenge for physicians dealing with the treatment of this condition (Risitano 2011). Indeed, in addition to supportive strategies such as anti-infectious, anti-thrombotic and anti-hemorrhagic prophylaxis and/or treatment, etiologic therapies can also be attempted. According to the pathogenic mechanisms and the dual hypothesis described above, an immune-mediated inhibition of hematopoiesis is postulated in PNH, similar to that demonstrated in AA. Thus, immunosuppressive strategies have been reasonably utilized in PNH patients, even if large prospective studies are lacking. Cyclosporine A has led some improvement in a few series (Schubert et al 1997; Stoppa et al 1996; van Kamp et al 1995). More intensive regimens (as those recommended in severe AA) using the anti-thymocyte globulin associated with high dose prednisone and cyclosporin A have also been exploited; however, the available results are quite heterogeneous (Tichelli et al 1992; Sanchez-Valle et al 1993). Alternative immunosuppressive agents such as cyclophosphamide (Brodsky et al 2010) or the anti-CD52 monoclonal antibody alemtuzumab (Risitano et al 2010a) may be an alternative option (as salvage treatment); in the setting of alemtuzumab-based treatment, there is no concern over the potential selection risk for PNH hematopoiesis, given that the GPI-linked CD52 is not expressed on HSCs. Regardless of the specific immunosuppressive regimen, when this etiological treatment leads to an improvement of the underlying bone marrow impairment, usually normal (non-

PNH) hematopoiesis may be restored, possibly resulting in a progressive dilution (or even extinction) of the PNH clone. However, some patients may continue to have remarkable hemolysis due to the persistence of the PNH clone(s). In addition to the immunosuppressive therapy, it has to be pointed out that marrow failure represents the main indication to allogeneic stem cell transplantation for PNH patients; in fact, all young PNH patients with bone marrow failure should be considered for transplantation if they have a HLA-matched donor (Luzzatto et al 2011), or even if they have an unrelated donor (later in their disease course). Indeed, marrow failure of PNH patients has to be treated as aplastic anemia by either immunosuppression or allogeneic stem cell transplantation, regardless of the presence of the PNH clone(s) (Risitano 2011).

### 8.1.3 Management of thrombophilia

The management of the propensity to develop thrombosis is the hottest issue in PNH, since this complication represents the first cause of death. Unfortunately, there are no controlled prospective clinical trials concerning either primary and secondary thrombosis prophylaxis, or acute treatment of the event. The issue of primary prophylaxis is controversial, and no consensus exists; some physicians advocate the use of warfarin for all newly diagnosed PNH patients, while others do not use any prophylaxis. Both approaches are reasonable, given the unpredictability of thromboembolic events and the lack of evidence supporting any of these strategies; possible benefits are counterbalanced by the risk of hemorrhage from warfarin therapy, which may be considerable in PNH patients with low platelet count. Given that up to two thirds of PNH patients may never develop any thrombosis during the course of their disease, some physicians consider unacceptable to risk hemorrhagic complications (especially in those who are thrombocytopenic); this perception is strengthened by the fact that current primary prophylaxis is not necessarily protective in all patients (de Latour et al 2008; Luzzatto et al 2011). A reasonable compromise may be the adoption of primary prophylaxis for patients at higher risk of thrombosis, which can be identified by the presence of additional inherited (e.g., ethnicity, factor V Leiden) or acquired (e.g., lupus anti-coagulant, pregnancy) risk factors for thrombosis. A single group reported that prophylaxis by warfarin in patients with WBC PNH clones larger than 50% resulted in a very low incidence of thromboembolic events compared to historical controls (Hall et al 2003); however, hemorrhagic complications (even fatal) were also observed, and these data need to be confirmed in larger, possibly prospective studies. To date, there is no experience with newer and possibly more manageable agents, such as thrombin inhibitors, which might play a major role in the future. In contrast, as far as secondary prophylaxis is concerned, there is general agreement that all PNH patients experiencing any thromboembolic event should remain life-long on anticoagulants; however, even in this setting, no consensus exists about the best strategy. Low-molecular-weight heparin, as well as warfarin at different therapeutic ranges, are both utilized, with some physicians even considering the addition of anti-platelet agents; most physicians start with heparin, and subsequently shift to warfarin. However, despite the extended prophylaxis, recurrence of thrombosis (either as new events or progression of the existing ones) is frequent and affects the survival of PNH patients (Audebert et al 2005; de Latour et al 2008). Moreover, life-threatening hemorrhagic events are quite frequent in this cohort of patients, mostly when concomitant thrombocytopenia is present (Hall et al 2003, Moyo et al 2004). Finally, the management of an acute thromboembolic disease may require an intensive therapy similar



to that for myocardial infarct; in addition to anti-coagulants at therapeutical doses, fibrinolytic therapies using tissue plasminogen activator have been exploited, showing efficient clearance of the thrombus in individual cases (McCullin et al 1994; Hauser et al 2003; Sholar & Bell 1985; Araten et al 2010). As for hemolytic anemia, the management of thrombophilia has substantially changed with the introduction of eculizumab.

## 8.2 Anti-complement treatment

### 8.2.1 Eculizumab: A humanized anti-complement component 5 monoclonal antibody

Eculizumab (h5G1.1-mAb, Soliris®, Alexion Pharmaceuticals) is a humanized monoclonal antibody (mAb) (Rother et al 2007) derived from the murine anti-human C5 mAb; it specifically binds the terminal complement component 5, thereby inhibiting its cleavage to C5a and C5b (Matis & Rollins 1995). Thus, eculizumab blocks the formation of MAC, the terminal effector mechanism leading to intravascular hemolysis of PNH erythrocytes. The blockade of the complement cascade at the level of C5 does not affect early complement components, preserving pivotal functions such as clearance of immune complexes and microorganisms (Matis and Rollins 1995). Eculizumab was initially investigated in patients suffering from other complement-mediated disorders; however, PNH appeared the best candidate disease to benefit from eculizumab treatment. In fact, eculizumab may compensate for the absence of CD59 on PNH erythrocytes, preventing their lysis upon complement activation (which is also uncontrolled given the absence of CD55). Eculizumab is administered intravenously, thus its bioavailability is 100%; its estimated half-life is 271 hours. Eculizumab therapy was designed to rapidly reach pharmacodynamic levels using an induction regimen, followed by a maintenance dosage schedule aiming to avoid concentration drops below the plasma level of 35 µg/mL (Hillmen et al 2006), which is the threshold level for pharmacodynamic effectiveness (based on *in vitro* data). In all PNH studies eculizumab has been administered intravenously as 4 weekly doses of 600 mg (induction regimen), followed by 900 mg doses every other week (maintenance regimen), starting 1 week after induction (week 5); this is the standard schedule, approved by the FDA for the treatment of hemolysis in PNH patients.

### 8.2.2 Safety and efficacy of eculizumab

*Eculizumab and intravascular hemolysis: efficacy from the registration studies.* The management of hemolysis of PNH, which was palliative until 2000, has dramatically changed with the availability of eculizumab (Brodsky 2009; Luzzatto et al 2011). In the last few years eculizumab has been extensively investigated for the treatment of hemolysis in patients with transfusion-dependent PNH. Safety and efficacy of eculizumab were initially established in a phase II pilot study (Hillmen et al 2004) as well as in two phase III clinical studies (TRIUMPH and SHEPHERD) (Hillmen et al 2006; Brodsky et al 2008), and subsequently were confirmed in a common open-label Extension study (Hillmen et al 2007). All patients receiving eculizumab were vaccinated against *Neisseria Meningitidis* at least two weeks before starting treatment. After the initial pilot study, which provided the proof-of-principle of effective blockade of intravascular hemolysis in eleven heavily transfused PNH patients (Hillmen et al 2004), eculizumab was tested in a double-blind, placebo-controlled, multinational randomized trial which enrolled 86 patients (Hillmen et al 2006). The eligibility criteria included at least 4 red cell transfusions in the previous 12 months, a PNH

type III erythrocyte population  $\geq 10\%$ , platelets  $\geq 100 \times 10^9/L$ , and lactate dehydrogenase (LDH)  $\geq 1.5$  times the upper limit of normal (Hillmen et al 2006). Treatment with eculizumab resulted in a dramatic reduction of intravascular hemolysis, as measured by LDH, leading to hemoglobin stabilization and transfusion independence in about half the patients. Control of intravascular hemolysis was achieved in all patients, and even cases who still required transfusions showed a reduction of their transfusional needs. The effects of eculizumab on hemolysis were evident after the first administration, and lasted for the whole study period. Compared to placebo, eculizumab significantly improved fatigue and quality of life, as measured by validated questionnaires (Hillmen et al 2006). These data were confirmed in the open-label phase III study SHEPHERD, which included a broader PNH population (minimum pretreatment transfusion requirement was one, and minimum platelet count requirement was  $30 \times 10^9/L$ ) (Brodsky et al 2008). In the 96 patients enrolled in the study, treatment with eculizumab resulted in an almost complete control of intravascular hemolysis, regardless of the pretreatment transfusion requirement, with transfusion independence achieved in half the patients, and significant improvement in fatigue and quality of life (Brodsky et al 2008). The subsequent open-label Extension study enrolled a total of 187 patients who had previously completed one of the parent clinical trials (Hillmen et al 2007). The Extension study confirmed the efficacy and safety of eculizumab with a longer follow up, confirming that the effects of eculizumab treatment on intravascular hemolysis were retained over time (Hillmen et al 2007).

*Eculizumab and thrombophilia.* The Extension study included as a secondary endpoint the assessment of thrombotic risk in PNH patients chronically receiving eculizumab treatment, by looking to the incidence of thromboembolic events in the pretreatment and treatment periods in the same patients (Hillmen et al 2007). The rate of thromboembolism decreased from 7.37 to 1.07 events/100 patient-years after eculizumab treatment, with a 85% relative reduction. This reduction was preserved even in patients on anticoagulants, suggesting that eculizumab may be the most effective agent to prevent thromboembolisms in PNH patients (Hillmen et al 2007). Whether eculizumab exerts its effect on thrombophilia of PNH directly, or through the blockade of intravascular hemolysis (e.g., by reduction of NO consumption or reduced release of procoagulant microvesicles), it is still unknown. Recently, it has been reported that eculizumab treatment results in a significant decrease in the plasma markers of coagulation pathway activation, reactive fibrinolysis and endothelial cell activation (Helley et al 2010). This finding suggests that the pathophysiology of thrombosis in PNH may involve multiple pathways, and that the triggering events possibly affected by eculizumab have not been yet identified. However, if the protective effect of eculizumab on the thromboembolic risk are confirmed in a long-term period, it is reasonable to anticipate that eculizumab may result in an improvement of survival of PNH patients. Such effect on survival has been recently shown in a limited cohort of patients (Kelly et al 2011).

*Eculizumab and PNH: any additional benefit?* More recently, it has been reported that eculizumab may lead to additional beneficial effects for PNH patients. As stated before, by inhibiting intravascular hemolysis eculizumab controls all hemolysis-related symptoms, including painful crisis, dysphagia and erectile dysfunction (Hill et al 2005). In addition, by counteracting NO consumption, eculizumab might reduce the risk of pulmonary hypertension (PH) (Hill et al 2010b). This conclusion was mainly derived from the 50% reduction of N-terminal pro-brain natriuretic peptide (NT-proBNP), which was elevated at

baseline in about 50% of PNH patients. Unfortunately this study does not include a direct estimation of pulmonary artery pressure by doppler echocardiography, making it uncertain as to whether these PNH patients exhibited clinically relevant PH. However, even if NT-proBNP can be considered a non-invasive marker for PH, possibly reflecting increased pulmonary vascular resistance and right ventricular dysfunction, it is usually utilized as prognostic marker in patients with proven diagnosis of PH. In another study, eculizumab appeared to improve renal function of PNH patients, as measured by estimated glomerular filtration rate (eGFR), preventing possible CKD (Hillmen et al 2010). The authors report that before treatment a fraction of PNH patients may have decreased eGFR, qualifying for stage 3-5 CKD (about 20%); eculizumab treatment resulted in an improvement of eGFR, and reduced the risk of major clinical kidney events. Nevertheless, PH and CKD are not commonly described in PNH patients (de Latour et al 2008); therefore, the real clinical impact of these findings has to be assessed in appropriate studies.

*Eculizumab and pregnancy.* Most hematologists try to dissuade PNH women from pursuing pregnancy, due to both maternal and fetal risk of complications, mainly secondary to thrombosis. Since eculizumab has become available, three pregnancies have been reported in women on this agent all through the gestation period; all of them had healthy newborns, without any maternal complication (Kelly et al 2010; Marasca et al 2010). Thus, even if eculizumab is formally not indicated in PNH pregnant women, and indeed the label for eculizumab classifies it as a pregnancy class C drug, common sense suggests that eculizumab be not automatically withdrawn in the case of pregnancy, giving careful consideration to the need to control the major causes of both maternal and fetal morbidity (intravascular hemolysis and subsequent anemia, and thrombophilia). It is still a matter of debate whether these data are sufficient to change our current counseling, allowing highly motivated PNH women to start pregnancy during eculizumab treatment.

*Safety and tolerability of eculizumab treatment.* The safety profile of eculizumab was assessed in the six studies involving PNH patients (Hillmen et al 2006; Brodsky et al 2008; Hillmen et al 2007), as well as on eleven studies utilizing eculizumab for different indications; the cumulative exposure was 147.44 and 492.20 patient-years in the two populations, respectively. Three deaths were reported in the PNH studies, all related to the underlying disease in two cases (one cerebral vascular accident and one progression to chronic myelomonocytic leukemia) and to an unrelated accident in the third (cerebral herniation). The main concern was a putative increased risk of infections, mostly by encapsulated bacteria, namely *Neisseria Spp*. Given the occurrence of a single case of meningitis by *Neisseria meningitidis* in the initial non-PNH cohort, all patients exposed to eculizumab were vaccinated against *Neisseria meningitidis* using a polyvalent vaccine. In addition, all patients received a warning on meningitis and infectious symptoms, as well as a rescue antibiotic prescription. No case of meningitis has been documented among the 195 PNH patients receiving eculizumab in the clinical trials; however, three patients developed a *Neisseria meningitidis* infection (possibly from *N. meningitidis* groups not covered by the prescribed vaccine), with sepsis in two cases. None of these patients developed meningitis or other complications, and all recovered promptly as a result of early diagnosis and treatment. The incidence of serious adverse events was similar in eculizumab-treated patients and in those receiving the placebo within the TRIUMPH trial; furthermore, none of the serious adverse events was considered as possibly, probably or definitely related to eculizumab. The overall rate of infectious events did not increase compared to the placebo group; however, herpes

simplex and some other site-specific infections (nasopharyngitis, upper respiratory tract infection, urinary tract infection and sinusitis) appeared to be more frequent within the eculizumab-treated population. However, in all cases the intensity was mild and the clinical resolution prompt. The occurrence of immunogenicity was assessed, and was demonstrated to be very infrequent, if at all present, and without consequence on drug efficacy. In summary, the treatment with eculizumab is safe and well-tolerated for the treatment of PNH, with negligible side effects (Hillmen et al 2006). Long-term treatment has not shown any deviation from this safety profile, as confirmed by post-marketing experience; however, anti-meningococcal vaccination and warning for symptoms of meningitis remains mandatory.

### 8.2.3 Emerging observations during treatment with eculizumab

*C3-mediated extravascular hemolysis during eculizumab treatment.* Since the introduction of eculizumab in 2005, growing evidence suggests that its effect on MAC inhibition may unmask a biologically relevant and potentially pathogenic role for the early phases of the complement cascade. We have recently documented that a novel, clinically significant finding may appear in PNH patients receiving eculizumab, accounting for some portion of residual anemia and heterogeneous hematological benefit from treatment (Risitano et al 2009a). In fact, while basically all patients achieve normal or almost normal LDH levels (pointing out an adequate control of intravascular hemolysis), only about a third reach a hemoglobin value above 11 gr/dL). In contrast, the remaining patients on eculizumab continue to exhibit moderate to severe (transfusion-dependent) anemia, in about equal proportions. In our initial series of 56 PNH patients, we have demonstrated by flow cytometry that all the 41 PNH patients on eculizumab harbored C3 fragments bound to a substantial portion of their PNH erythrocytes (while none of the untreated patients did) (Risitano et al 2009a). Our data were confirmed in an independent series by an other group that exploited a direct antiglobulin test using C3d-specific anti-sera (Hill et al 2010a). We concluded that membrane-bound C3 fragments work as opsonins on PNH erythrocytes, resulting in their entrapment by reticuloendothelial cells through specific C3 receptors and subsequent extravascular hemolysis (Risitano et al 2009a; Luzzatto et al 2010). This mechanism is supported by persistent reticulocytosis, hyperbilirubinemia and anemia in patients on eculizumab, and was also confirmed by an *in vivo* erythrocyte survival study by <sup>51</sup>Cr labeling (which showed reduced survival and hepatosplenic <sup>51</sup>Cr uptake) (Risitano et al 2009a).

*The complement cascade regulation during eculizumab treatment.* Pathophysiologically, it is clear that such a mechanism becomes evident only when eculizumab prevents MAC-mediated hemolysis, allowing longer survival of PNH erythrocytes, which continue to suffer from uncontrolled C3 convertase activation and C3 fragment deposition due to CD55 deficiency (Luzzatto et al 2010; Risitano et al 2011). Indeed, CAP is physiologically in a state of continuous activation because spontaneous (low-grade) hydrolysis of an internal thioester bond of C3 generates a C3b-like molecule, C3(H<sub>2</sub>O); nascent C3(H<sub>2</sub>O) is able to recruit factor B in forming (in the fluid phase) an unstable pro-C3 convertase. Once cleaved by factor D (generating C3(H<sub>2</sub>O)Bb), this complex will in turn cleave additional C3 molecules to generate C3b, which binds predominantly to glycophorin A and activate (now in a membrane-bound phase) the CAP amplification loop (Parker et al 1982; Pangburn et al 1983c; Müller-Eberhard 1988; Risitano et al 2011). On PNH erythrocytes, the lack of CD55

will allow this process (which is self-limiting on normal cells) to continue, leading to progressive CAP-mediated amplification, even in the presence of eculizumab (which acts downstream). The reasons why only a fraction of PNH erythrocytes has membrane-bound C3, and why the proportion varies among patients, are not fully understood. Nevertheless, *in vitro* data support the concept that PNH erythrocytes are all susceptible to C3 deposition once exposed to conditions causing complement activation (Sica et al 2010). We have hypothesized that inter-individual differences in other physiological inhibitors (such as CR1, complement FH and complement FI) may modulate the complement activation in a patient-specific fashion, leading to distinct patterns of C3 deposition. In addition, even more complex factors may drive the subsequent fate of C3-bound PNH erythrocytes; in fact, some patients may harbor large proportion of C3-bound PNH erythrocytes, without showing a clinically relevant extravascular hemolysis (Risitano et al 2010b). At the moment, there is yet no ability to predict before starting eculizumab which patients will develop C3-mediated extravascular hemolysis.

*Current strategies to overcome C3-mediated extravascular hemolysis.* C3 opsonization of PNH erythrocytes is a common phenomenon for PNH patients treated with eculizumab, even if the subsequent extravascular hemolysis may remain limited or well-compensated in most cases (Luzzatto et al 2010). However, additional therapeutic strategies are needed for patients developing a clinically relevant C3-mediated extravascular hemolysis, because they may continue to require frequent red cell transfusions, possibly developing subsequent iron overload (Risitano et al 2009a). We reported a patient managed by splenectomy (Risitano et al 2008), who achieved a substantial improvement of hemoglobin level without any medical complication; however, many physicians raise the concern that this approach may carry an increased life-long risk of infections (Brodsky 2009). In addition, the risk of intra- or peri-operative complications (especially thrombosis, or hemorrhage in thrombocytopenic patients) might also argue against this therapeutic option. Very recently a group reported a single case where steroids were beneficial in controlling C3-mediated extravascular hemolysis (Berzuini et al 2010). To best of our knowledge, this observation has not been confirmed in a larger series, and the well known side effects of long-term steroid use should advise against the use of steroids in PNH patients on eculizumab (Risitano et al 2010b). In some patients, the use of recombinant erythropoietin has proven beneficial by increasing compensatory erythropoiesis (Hill et al 2007).

*A look into the future of complement inhibition.* The emergence of experimental and clinical evidence for CAP-initiated and C3 fragment-mediated extravascular hemolysis suggests that new treatment strategies appropriately targeting the early phases of the complement cascade should be assessed. The ideal agent should prevent the early phase of complement activation on PNH cells and defuse the amplification mechanisms (e.g., the CAP amplification loop). A systemic blockade of C3 activation through all pathways by monoclonal antibodies (similar to the anti-C5 eculizumab) could be considered (e.g., by anti-C3 monoclonal antibodies) (Lindorfer et al 2010); however this approach may carry the risk of infectious and autoimmune complications secondary to a complete switching off of the complement system at this point. A novel candidate agent has been designed by creating a recombinant fusion protein between two endogenous complement-related proteins, complement factor H (FH) and complement receptor 2 (CR2). FH is a physiological complement inhibitor that modulates the initial CAP activation in the fluid phase by preventing C3 convertase activity and by promoting C3b inactivation into iC3b (Whaley et

al 1976). Indeed, FH defuses the CAP amplification loop, and it has been demonstrated protective from lysis for PNH erythrocytes *in vitro* (Ferreira & Pangburn 2007). In the aim to deliver FH activity locally at the site of complement activation, FH was fused with the iC3b/C3d-binding domain of CR2. The resulting CR2-FH fusion protein has shown a dramatic inhibition of hemolysis of PNH erythrocytes *in vitro* (Risitano et al 2009c), and further investigations are currently under way. A phase I clinical trial has just started to enroll PNH patients (Alexion Pharmaceuticals, personal communication). Once these or other next generation complement inhibitors proceed to clinical development, then we can determine whether such targeted inhibition should be additional or alternative to eculizumab. Indeed, the adequate control of C3, or both C3 and C5 activation on PNH red cells might make the downstream blockade by eculizumab redundant.

### 8.3 Hematopoietic stem cell transplantation

Cell therapy (insertion of molecules on the outer surface of blood cells) (Hill et al 2006a) and gene therapy (insertion of a functional *PIG-A* gene in early hematopoietic progenitors) have been hypothesized in the past as a curative approach for PNH. However, they seem unfeasible or even inappropriate; in fact, if the escape theory is correct, the gene therapy approach may not result in clinical benefit in PNH, since a repair of the damaged cell should result in cell destruction, as is believed to occur for normal hematopoiesis in PNH patients. The only curative strategy for PNH is allogeneic hematopoietic stem cell transplantation (SCT); SCT has been exploited since the late '80, and has proven effective in eradicating the abnormal PNH clone possibly leading to definitive cure of PNH, even if morbidity and mortality remain a major limitation. Most reports in the literature refer to single cases or small series from single-institutions (Bemba et al 1999, Raiola et al 2000; Saso et al 1999), while large prospective studies are lacking. In an overview, Parker et al (Parker et al 2005) collected data from 67 patients transplanted from different types of donors (syngeneic, sibling or HLA-identical unrelated) and using different types of conditioning (myeloablative or reduced-intensity). The results from the entire group showed a 75% long-term survival, which is quite higher than that reported in individual series (55-100%), likely as a result of a reporting bias. Data from two large registry studies are also available. The International Bone Marrow Transplant Registry reported 57 consecutive SCT performed for PNH (16 AA/PNH) between 1978 and 1995 (Matos-Fernandez et al 2009), showing a 2-year survival of 56% in 48 HLA-identical sibling transplants (the median follow-up was 44 months). The incidence of grade II or more severe acute GvHD was 34%, and that of chronic GvHD of 33%; graft failure (n=7) and infections (n=3) were the most common causes of treatment failure. An other retrospective study from the Italian Transplant Group (GITMO) on 26 PNH patients (4 AA/PNH) transplanted between 1998 and 2006 showed a 57% survival rate at 10 years. Acute and chronic GvHD were 42% (grade III-IV 12%) and 50% (extensive 16%), respectively (Santarone et al 2010). Given these results, guidelines for SCT in PNH are hard to define; the most difficult task today is to identify PNH patients who could benefit from HSCT (Brodsly 2010). At the moment, the main indication for SCT in PNH patients is an underlying bone marrow failure; as for AA patients, SCT may be performed as first-line therapy in the presence of an HLA-identical sibling donor, or in case of treatment failure in patients with an HLA-matched unrelated donor (Risitano 2011). The patient's age largely drives the choice of treatment, given that transplant-related mortality and morbidity increase with age. Refractoriness to transfusions and life-threatening thrombosis were also

indications to SCT in the past, but nowadays they rather represent indications to anti-complement treatment, with the exception of Countries where eculizumab is not available (yet). However, SCT remains a worthy second-line therapy for the few patients not achieving a good response to eculizumab. As for AA, SCT (regardless of the type of donor, sibling or unrelated donor) is the treatment of choice for PNH patients developing a clonal evolution to MDS or even AML. The Working Party for Severe Aplastic Anemia of the European Bone Marrow Transplantation Group, together with the French PNH Registry, are currently running a retrospective studies comparing the outcome of all BMT performed in Europe with the natural history of PNH (in the pre-eculizumab era). Likely the results from this study will guide future treatment strategies for PNH patients, according to specific disease presentation and complications. A number of questions remain open in the setting of SCT for PNH, to improve the clinical outcome: the most relevant is the choice of the conditioning regimen. Based on available data, AA/PNH patients should be treated as non-PNH AA patients; thus, the conditioning should be cyclophosphamide/ATG for sibling transplants, and fludarabine-based RIC for unrelated transplants (to be performed as in case of failure of IST) (Bacigalupo et al 2010). In contrast, classic, non-hypoplastic, PNH patients receiving SCT should benefit from myeloablative conditioning (e.g., busulphan-based) (Raiola et al 2000); however, RIC regimens (fludarabine-based) (Takahashi et al 2004) may be appropriate for patients who are older or who present with relevant comorbidities.

## 9. Conclusion

PNH has attracted the efforts of several generations of investigators in the last three decades for its biological and clinical uniqueness. While the '80s unraveled the GPI-anchor and the functional defect of the PNH clone, and the '90s revealed the *PIG-A* gene and its role in the pathophysiology of the disease, this new century brought forth innovative therapeutic approaches. Thanks to current treatment options, we are finally able to change the natural history of PNH, possibly giving back to PNH patients a normal-like life expectancy, in addition to a significant reduction of disease manifestations and improvement in their quality of life. As often occurs in medicine, thanks to these novel treatments we are also improving our biological knowledge of the disease and of current treatments. Thus, the scientific community has already accepted the next challenge: utilize these recent insights to develop novel targeted treatment strategies, for further improvement of current management of PNH patients.

## 10. Acknowledgments

I am grateful to Professor Bruno Rotoli who handed down to myself his devotion to PNH patients and PNH science; this chapter mostly stems from his long-lasting thoughtful teachings. I also thank Dr. Rosario Notaro, Professor Lucio Luzzatto, Dr. Jaroslaw Maciejewski and Dr. Neal Young for their contribution to my knowledge of PNH.

## 11. References

- [1] Almeida AM, Murakami Y, Layton DM, et al. Hypomorphic promoter mutation in *PIGM* causes inherited glycosylphosphatidylinositol deficiency. *Nat Med.* 2006; 12:846-51.

- [2] Almeida A, Layton M & Karadimitris A. Inherited glycosylphosphatidyl inositol deficiency: a treatable CDG. *Biochim Biophys Acta*. 2009; 1792:874-80.
- [3] Araten DJ, Nafa K, Pakdeesuwan K, et al. Clonal populations of hematopoietic cells with paroxysmal nocturnal hemoglobinuria genotype and phenotype are present in normal individuals. *Proc Natl Acad Sci U S A*. 1999; 96:5209-5214.
- [4] Araten DJ, Swirsky D, Karadimitris A, et al. Cytogenetic and morphological abnormalities in paroxysmal nocturnal haemoglobinuria. *Br J Haematol*. 2001; 115:360-8.
- [5] Araten DJ, Bessler M, McKenzie S, et al. Dynamics of hematopoiesis in paroxysmal nocturnal hemoglobinuria (PNH): no evidence for intrinsic growth advantage of PNH clones. *Leukemia*. 2002; 16:2243-8.
- [6] Araten DJ, Thaler HT & Luzzatto L. High incidence of thrombosis in African-American and Latin-American patients with Paroxysmal Nocturnal Haemoglobinuria. *Thromb Haemost*. 2005; 93:88-91.
- [7] Araten DJ & Luzzatto L. The mutation rate in PIG-A is normal in patients with paroxysmal nocturnal hemoglobinuria (PNH). *Blood*. 2006; 108:734-6.
- [8] Araten DJ, Notaro R, Thaler H, et al. Thrombolytic therapy for reversal of thrombosis in paroxysmal nocturnal hemoglobinuria. *Blood*. 2010; 116:1721(a).
- [9] Armstrong C, Schubert J, Ueda E, et al. Affected paroxysmal nocturnal hemoglobinuria T lymphocytes harbor a common defect in assembly of N-acetyl-D-glucosamine inositol phospholipid corresponding to that in class A Thy-1- murine lymphoma mutants. *J Biol Chem*. 1999; 267:25347-51.
- [10] Audebert HJ, Planck J, Eisenburg M, et al. Cerebral ischemic infarction in paroxysmal nocturnal hemoglobinuria report of 2 cases and updated review of 7 previously published patients. *J Neurol*. 2005; 252:1379-86.
- [11] Bacigalupo A, Socie' G, Lanino E, et al; Severe Aplastic Anemia Working Party of the European Group for Blood and Marrow Transplantation. Fludarabine, cyclophosphamide, antithymocyte globulin, with or without low dose total body irradiation, for alternative donor transplants, in acquired severe aplastic anemia: a retrospective study from the EBMT-SAA working party. *Haematologica*. 2010; 95: 976-82.
- [12] Bemba M, Guardiola P, Gardret L et al. Bone marrow transplantation for paroxysmal nocturnal haemoglobinuria. *Br J Haematol*. 1999; 105 :366-368.
- [13] Berzuini A, Montanelli F & Prati D. Hemolytic anemia after eculizumab in paroxysmal nocturnal hemoglobinuria. *N Engl J Med*. 2010; 363:993-4.
- [14] Bessler M, Hillmen P, Longo L, et al. Genomic organization of the X-linked gene (PIG-A) that is mutated in paroxysmal nocturnal haemoglobinuria and of a related autosomal pseudogene mapped to 12q21. *Hum Mol Genet*. 1994; 3:751-7.
- [15] Borowitz MJ, Craig FE, Digiuseppe JA, et al; Clinical Cytometry Society. Guidelines for the diagnosis and monitoring of paroxysmal nocturnal hemoglobinuria and related disorders by flow cytometry. *Cytometry B Clin Cytom*. 2010; 78:211-30.
- [16] Bourantas K. High-dose recombinant erythropoietin and low-dose corticosteroids for treatment of anemia in paroxysmal nocturnal hemoglobinuria. *Acta Haematol*. 1994; 91:62-5.
- [17] Brodsky RA, Mukhina GL, Li S, et al. Improved detection and characterization of paroxysmal nocturnal hemoglobinuria using fluorescent aerolysin. *Am J Clin Pathol*. 2000; 114:459-66.



- [18] Brodsky RA, Young NS, Antonioli E, et al. Multicenter phase III study of the complement inhibitor eculizumab for the treatment of patients with paroxysmal nocturnal hemoglobinuria. *Blood*. 2008; 114:1840-47.
- [19] Brodsky RA. How I treat paroxysmal nocturnal hemoglobinuria. *Blood*. 2009; 113:6522-7.
- [20] Brodsky RA, Chen AR, Dorr D, et al. High-dose cyclophosphamide for severe aplastic anemia: long-term follow-up. *Blood*. 2010; 115:2136-41.
- [21] Brodsky RA. Stem cell transplantation for paroxysmal nocturnal hemoglobinuria. *Haematologica*. 2010; 95:855-6.
- [22] Brubaker LH, Essig LJ & Mengel CE. Neutrophil life span in paroxysmal nocturnal hemoglobinuria. *Blood*. 1977; 50:657-62.
- [23] Cacciapuoti C, Terrazzano G, Barone L, et al. Glycosyl-phosphatidyl-inositol-defective granulocytes from paroxysmal nocturnal haemoglobinuria patients show increased bacterial ingestion but reduced respiratory burst induction. *Am J Hematol*. 2007; 82:98-107.
- [24] Chen G, Zeng W, Maciejewski JP, et al. Differential gene expression in hematopoietic progenitors from paroxysmal nocturnal hemoglobinuria patients reveals an apoptosis/immune response in 'normal' phenotype cells. *Leukemia*. 2005; 19:862-8.
- [25] Crosby WH. Paroxysmal nocturnal hemoglobinuria; a classic description by Paul Strübling in 1882, and a bibliography of the disease. *Blood*. 1951; 63:270-84.
- [26] Dameshek W. Riddle: what do aplastic anemia, paroxysmal nocturnal hemoglobinuria (PNH) and "hypoplastic" leukemia have in common? *Blood*. 1967; 30:251-254.
- [27] de Latour RP, Mary JY, Salanoubat C, et al; French Association of Young Hematologists. Paroxysmal nocturnal hemoglobinuria: natural history of disease subcategories. *Blood*. 2008; 112:3099-106.
- [28] Devine DV, Siegel RS & Rosse WF. Interactions of the platelets in paroxysmal nocturnal hemoglobinuria with complement. Relationship to defects in the regulation of complement and to platelet survival in vivo. *J Clin Invest*. 1987a; 79:131-7.
- [29] Devine DV, Gluck WL, Rosse WF, et al. Acute myeloblastic leukemia in paroxysmal nocturnal hemoglobinuria. Evidence of evolution from the abnormal paroxysmal nocturnal hemoglobinuria clone. *J Clin Invest*. 1987b; 79:314-7.
- [30] Dingli D, Luzzatto L & Pacheco JM. Neutral evolution in paroxysmal nocturnal hemoglobinuria. *Proc Natl Acad Sci U S A*. 2008; 105:18496-500.
- [31] Dunn DE, Liu JM & Young NS. 2000. Paroxysmal nocturnal hemoglobinuria. In: Young NS (ed). *Bone Marrow Failure Syndromes*. Philadelphia: W.B. Saunders Company. p 99-121.
- [32] Endo M, Ware RE, Vreeke TM, et al. Molecular basis of the heterogeneity of expression of glycosyl phosphatidylinositol anchored proteins in paroxysmal nocturnal hemoglobinuria. *Blood*. 1996; 87:2546-57.
- [33] Enneking J. Eine neue form intermittierender Haemoglobinurie (Haemoglobinuria paroxysmalis nocturna). *Klin. Wehnschr*. 1928. 7: 2045.
- [34] Ferreira VP & Pangburn MK. Factor H mediated cell surface protection from complement is critical for the survival of PNH erythrocytes. *Blood*. 2007; 15:110:1290-2.
- [35] Fieni S, Bonfanti L, Gramellini D, et al. Clinical management of paroxysmal nocturnal hemoglobinuria in pregnancy: a case report and updated review. *Obstet Gynecol Surv*. 2006; 61:593-601.

- [36] Fujioka S & Asai T. Prognostic features of paroxysmal nocturnal hemoglobinuria in Japan. *Nihon Ketsueki Gakkai Zasshi*. 1989; 52:1386-94.
- [37] Gargiulo L, Lastraioli S, Cerruti G, et al. Highly homologous T-cell receptor beta sequences support a common target for autoreactive T cells in most patients with paroxysmal nocturnal hemoglobinuria. *Blood*. 2007; 109:5036-42.
- [38] Galnack HR, Vail M, McKeown LP, et al. Activated platelets in paroxysmal nocturnal haemoglobinuria. *Br J Haematol*. 1995; 91:697-702.
- [39] Grünewald M, Siegemund A, Grünewald A, et al. Plasmatic coagulation and fibrinolytic system alterations in PNH: relation to clone size. *Blood Coagul Fibrinolysis*. 2003; 14:685-95.
- [40] Ham TH. Chronic hemolytic anemia with paroxysmal nocturnal hemoglobinuria. A study of mechanism of hemolysis to acid-base equilibrium. *N Engl J Med*. 1937; 217:915-917.
- [41] Ham TH & Dingle JH. Studies on the destruction of red blood cells. II. Chronic hemolytic anemia with paroxysmal nocturnal hemoglobinuria: certain immunological aspects of the hemolytic mechanism with special reference to serum complement. *J Clin Invest*. 1939; 18:657-672.
- [42] Hall C, Richards S & Hillmen P. Primary prophylaxis with warfarin prevents thrombosis in paroxysmal nocturnal hemoglobinuria (PNH). *Blood*. 2003; 102:3587-91.
- [43] Harrington WJ Sr, Kolodny R, Horstmann LL et al. Danazol for paroxysmal nocturnal hemoglobinuria. *Am J Hematol*. 1997; 54:149-54.
- [44] Hauser AC, Brichta A, Pabinger-Fasching I, et al. Fibrinolytic therapy with rt-PA in a patient with paroxysmal nocturnal hemoglobinuria and Budd-Chiari syndrome. *Ann Hematol*. 2003; 82:299-302.
- [45] Helley D, de Latour RP, Porcher R, et al; French Society of Hematology. Evaluation of hemostasis and endothelial function in patients with paroxysmal nocturnal hemoglobinuria receiving eculizumab. *Haematologica*. 2010; 95:574-81.
- [46] Hertenstein B, Wagner B, Bunjes D, et al. Emergence of CD52-, phosphatidylinositolglycan-anchor-deficient T lymphocytes after in vivo application of Campath-1H for refractory B-cell non-Hodgkin lymphoma. *Blood*. 1995; 86:1487-1492.
- [47] Hill A, Rother RP & Hillmen P. Improvement in the symptoms of smooth muscle dystonia during eculizumab therapy in paroxysmal nocturnal hemoglobinuria. *Haematologica*. 2005; 90:ECR40.
- [48] Hill A, Ridley SH, Esser D, et al. Protection of erythrocytes from human complement-mediated lysis by membrane-targeted recombinant soluble CD59: a new approach to PNH therapy. *Blood*. 2006a; 107:2131-7.
- [49] Hill A, Wang X, Sapsford RJ, et al. Nitric oxide consumption and pulmonary hypertension in patients with paroxysmal nocturnal hemoglobinuria. *Blood*. 2006b; 108:305a.
- [50] Hill A et al. The incidence and prevalence of Paroxysmal Nocturnal Hemoglobinuria (PNH) and survival of patients in Yorkshire. *Blood* 2006c; 108:985a.
- [51] Hill A, Richards SJ, Rother RP, et al. Erythropoietin treatment during complement inhibition with eculizumab in a patient with paroxysmal nocturnal hemoglobinuria. *Haematologica*. 2007; 92:ECR14.

- [52] Hill A, Rother RP, Arnold L, et al. Eculizumab prevents intravascular hemolysis in patients with paroxysmal nocturnal hemoglobinuria and unmasks low-level extravascular hemolysis occurring through C3 opsonization. *Haematologica*. 2010a; 95:567-573.
- [53] Hill A, Rother RP, Wang X, et al. Effect of eculizumab on haemolysis-associated nitric oxide depletion, dyspnoea, and measures of pulmonary hypertension in patients with paroxysmal nocturnal haemoglobinuria. *Br J Haematol*. 2010b; 149:414-25.
- [54] Hillmen P, Lewis SM, Bessler M, et al. Natural history of paroxysmal nocturnal hemoglobinuria. *N Engl J Med*. 1995; 333:1253-1258.
- [55] Hillmen P, Hall C, Marsh JC, et al. Effect of eculizumab on hemolysis and transfusion requirements in patients with paroxysmal nocturnal hemoglobinuria. *N Engl J Med*. 2004; 350:552-559.
- [56] Hillmen P, Young NS, Schubert J, et al. The complement inhibitor eculizumab in paroxysmal nocturnal hemoglobinuria. *N Engl J Med*. 2006; 355:1233-43.
- [57] Hillmen P, Muus P, Duhrsen U, et al. Effect of the complement inhibitor eculizumab on thromboembolism in patients with paroxysmal nocturnal hemoglobinuria. *Blood*. 2007; 110:4123-8.
- [58] Hillmen P, Elebute M, Kelly R, et al. Long-term effect of the complement inhibitor eculizumab on kidney function in patients with paroxysmal nocturnal hemoglobinuria. *Am J Hematol*. 2010; 85:553-9.
- [59] Hirose S, Ravi L, Prince GM, et al. Synthesis of mannosylglucosaminylinositol phospholipids in normal but not paroxysmal nocturnal hemoglobinuria cells. *Proc Natl Acad Sci U S A*. 1992; 89:6025-9.
- [60] Hoekstra J, Leebeek FW, Plessier A, et al. Paroxysmal nocturnal hemoglobinuria in Budd-Chiari Syndrome: findings from a cohort study. *Journal of hepatology*. 2009; 51:696-706.
- [61] Hoffman EM. Inhibition of complement by a substance isolated from human erythrocytes. I. Extraction from human erythrocyte stromata. *Immunochemistry*. 1969; 6:391-403.
- [62] Holers VM. The spectrum of complement alternative pathway-mediated diseases. *Immunol Rev*. 2008; 223:300-16.
- [63] Holguin MH, Fredrick LR, Bernshaw NJ, et al. Isolation and characterization of a membrane protein from normal human erythrocytes that inhibits reactive lysis of the erythrocytes of paroxysmal nocturnal hemoglobinuria. *J Clin Invest*. 1989; 84:7-17.
- [64] Holguin MH, Wilcox LA, Bernshaw NJ, et al. Relationship between the membrane inhibitor of reactive lysis and the erythrocyte phenotypes of paroxysmal nocturnal hemoglobinuria. *J Clin Invest*. 1989; 84:1387-94.
- [65] Holguin MH, Wilcox LA, Bernshaw NJ, et al. Erythrocyte membrane inhibitor of reactive lysis: effects of phosphatidylinositol-specific phospholipase C on the isolated and cell-associated protein. *Blood*. 1990; 75:284-9.
- [66] Holguin MH, Martin CB, Bernshaw NJ, et al. Analysis of the effects of activation of the alternative pathway of complement on erythrocytes with an isolated deficiency of decay accelerating factor. *J Immunol*. 1992; 148:498-502.
- [67] Hugel B, Socié G, Vu T, et al. Elevated levels of circulating procoagulant microparticles in patients with paroxysmal nocturnal hemoglobinuria and aplastic anemia. *Blood*. 1999; 93:3451-6.

- [68] Inoue N, Izui-Sarumaru T, Murakami Y, et al. Molecular basis of clonal expansion of hematopoiesis in 2 patients with paroxysmal nocturnal hemoglobinuria (PNH). *Blood*. 2006; 108:4232-6.
- [69] Issaragrisil S, Piankijagum A & Tang.Naitrisorana Y. Corticosteroid therapy in paroxysmal nocturnal hemoglobinuria. *Am J Hemato*. 1987; 25:77-83.
- [70] Jasinski M, Keller P, Fujiwara Y, et al. GATA1-Cre mediates Piga gene inactivation in the erythroid/megakaryocytic lineage and leads to circulating red cells with a partial deficiency in glycosyl phosphatidylinositol-linked proteins (paroxysmal nocturnal hemoglobinuria type II cells). *Blood*. 2001 ; 98:2248-2255.
- [71] Karadimitris A, Manavalan JS, Thaler HT, et al. Abnormal T-cell repertoire is consistent with immune process underlying the pathogenesis of paroxysmal nocturnal hemoglobinuria. *Blood*. 2001; 96:2613-262.
- [72] Karadimitris A, Li K, Notaro R, et al. Association of clonal T-cell large granular lymphocyte disease and paroxysmal nocturnal haemoglobinuria (PNH): further evidence for a pathogenetic link between T cells, aplastic anaemia and PNH. *Br J Haematol*. 2001; 115:1010-4.
- [73] Katayama Y, Hiramatsu Y & Kohriyama H. Monitoring of Cd59 expression in paroxysmal nocturnal hemoglobinuria treated with danazol. *Am J Hematol*. 2001; 68:280-3.
- [74] Kawagoe K, Kitamura D, Okabe M, et al. Glycosylphosphatidylinositol-anchor-deficient mice: implications for clonal dominance of mutant cells in paroxysmal nocturnal hemoglobinuria. *Blood*. 1996; 87:3600-6.
- [75] Keller P, Payne JL, Tremml G, et al. FES-Cre targets phosphatidylinositol glycan class A (PIGA) inactivation to hematopoietic stem cells in the bone marrow. *J Exp Med*. 2001; 194:581-589.
- [76] Kelly RJ, Hill A, Arnold LM, et al. Long-term treatment with eculizumab in paroxysmal nocturnal hemoglobinuria: sustained efficacy and improved survival. *Blood*. 2011;117:6786-92.
- [77] Kelly R, Arnold L, Richards S, et al. The management of pregnancy in paroxysmal nocturnal haemoglobinuria on long term eculizumab. *Br J Haematol*. 2010; 149:446-450.
- [78] Krause JR. Paroxysmal nocturnal hemoglobinuria and acute non-lymphocytic leukemia. A report of three cases exhibiting different cytologic types. *Cancer*. 1983; 51:2078-82.
- [79] Kinoshita T, Medof ME, Silber R, et al. Distribution of decay-accelerating factor in the peripheral blood of normal individuals and patients with paroxysmal nocturnal hemoglobinuria. *J Exp Med*. 1985; 162:75-92.
- [80] Kunstling TR & Rosse WF. Erythrocyte acetylcholinesterase deficiency in paroxysmal nocturnal hemoglobinuria (PNH). A comparison of the complement-sensitive and insensitive populations. *Blood*. 1969; 33:607-16.
- [81] Lewis SM & Dacie JV. The aplastic anaemia--paroxysmal nocturnal haemoglobinuria syndrome. *Br J Haematol*. 1967; 13:236-51.
- [82] Lindorfer MA, Pawluczkwowycz AW, Peek EM, et al. A novel approach to preventing the hemolysis of paroxysmal nocturnal hemoglobinuria: both complement-mediated cytolysis and C3 deposition are blocked by a monoclonal antibody specific for the alternative pathway of complement. *Blood*. 2010; 115:2283-91.

- [83] Louwes H, Vellenga E & de Wolf JT. Abnormal platelet adhesion on abdominal vessels in asymptomatic patients with paroxysmal nocturnal hemoglobinuria. *Ann Hematol.* 2001; 80:573-6.
- [84] Luzzatto L, Bessler M & Rotoli B. Somatic mutations in paroxysmal nocturnal hemoglobinuria: a blessing in disguise? *Cell.* 1997; 88:1-4.
- [85] Luzzatto L & Nafa G. Genetics of PNH. 2000. In: Young NS, Moss J (ed). *Paroxysmal nocturnal hemoglobinuria and the glycosylphosphatidylinositol-linked proteins.* Sa Diego: Academic Press. p 21-47.
- [86] Luzzatto L & Notaro R. 2003. Paroxysmal nocturnal hemoglobinuria. In Handin RI, Lux SE, Stossel TP (eds): *Blood, principles and practice of hematology* (2nd ed.). Philadelphia, PA (USA), Lippincot Williams & Wilkins; p 319-34.
- [87] Luzzatto L, Risitano AM & Notaro R. Paroxysmal nocturnal hemoglobinuria and eculizumab. *Haematologica.* 2010; 95:523-6.
- [88] Luzzatto L, Gianfaldoni G & Notaro R. Management of paroxysmal nocturnal haemoglobinuria: a personal view. *Br J Haematol.* 2011; 153:709-20.
- [89] Luzzatto L & Notaro R. Biological basis of paroxysmal nocturnal hemoglobinuria. *Hematology education: the educational program for the annual congress of European Hematology Association.* 2010;222-227.
- [90] Maciejewski JP, Sloand EM, Sato T, et al. Impaired hematopoiesis in paroxysmal nocturnal hemoglobinuria/aplastic anemia is not associated with a selective proliferative defect in the glycosylphosphatidylinositol-anchored protein-deficient clone. *Blood.* 1997; 89:1173-81.
- [91] Maciejewski JP, Young NS, Yu M, et al. Analysis of the expression of glycosylphosphatidylinositol anchored proteins on platelets from patients with paroxysmal nocturnal hemoglobinuria. *Thromb Res.* 1996; 83:433-47.
- [92] Mahoney JF, Urakaze M, Hall S, et al. Defective glycosylphosphatidylinositol anchor synthesis in paroxysmal nocturnal hemoglobinuria granulocytes. *Blood.* 1992; 79:1400-3.
- [93] Marasca R, Coluccio V, Santachiara R, et al. Pregnancy in PNH: another eculizumab baby. *Br J Haematol.* 2010; 150:707-708.
- [94] Marchiafava E & Nazari A. Nuovo contributo allo studio degli itteri emolitici cronici. *Policlinico, (sez. med.).* 1911. 18: 241.
- [95] Markiewski MM, Nilsson B, Ekdahl KN, et al. Complement and coagulation: strangers or partners in crime? *Trends in immunology.* 2007; 28:184-92.
- [96] Matis LA & Rollins SA. Complement-specific antibodies: designing novel anti-inflammatories. *Nat Med.* 1995; 1:839-42.
- [97] Matos-Fernandez NA, Abou Mourad YR, Caceres W, et al. Current status of allogeneic hematopoietic stem cell transplantation for paroxysmal nocturnal hemoglobinuria. *Biol Blood Marrow Transplant.* 2009; 15:656-61.
- [98] McMullin MF, Hillmen P, Elder GE, et al. Serum erythropoietin level in paroxysmal nocturnal hemoglobinuria: implications for therapy. *Br J Haematol.* 1996; 92:815-7.
- [99] McMullin MF, Hillmen P, Jackson J, et al. Tissue plasminogen activator for hepatic vein thrombosis in paroxysmal nocturnal haemoglobinuria. *J Intern Med.* 1994; 235:85-9.
- [100] Medof ME, Walter EI, Roberts WL, et al. Decay accelerating factor of complement is anchored to cells by a C-terminal glycolipid. *Biochemistry.* 1986; 25:6740-7.
- [101] Medof ME, Gottlieb A, Kinoshita T, et al. Relationship between decay accelerating factor deficiency, diminished acetylcholinesterase activity, and defective terminal

- complement pathway restriction in paroxysmal nocturnal hemoglobinuria erythrocytes. *J Clin Invest.* 1987; 80:165-74.
- [102] Meri S, Morgan BP, Davies A, et al. Human protectin (CD59), an 18,000-20,000 MW complement lysis restricting factor, inhibits C5b-8 catalysed insertion of C9 into lipid bilayers. *Immunology.* 1990; 71:1-9.
- [103] Merry AH, Rawlinson VI, Uchikawa M, et al. Studies on the sensitivity to complement-mediated lysis of erythrocytes (Inab phenotype) with a deficiency of DAF (decay accelerating factor). *Br J Haematol.* 1989; 73:248-53.
- [104] Micheli N. Anemia emolitica cronica con emosiderinuria perpetua. *Policlinico, (sez. prat.).* 1928; 35:2574.
- [105] Miyata T, Takeda J, Iida Y, et al. The cloning of PIG-A, a component in the early step of GPI-anchor biosynthesis. *Science.* 1993; 259:1318-1320.
- [106] Motoyama N, Okada N, Yamashina M, et al. Paroxysmal nocturnal hemoglobinuria due to hereditary nucleotide deletion in the HRF20 (CD59) gene. *Eur J Immunol.* 1992; 22:2669-73.
- [107] Mold C, Walter EI, Medof ME. The influence of membrane components on regulation of alternative pathway activation by decay-accelerating factor. *J Immunol.* 1990; 145:3836-41.
- [108] Moyo VM, Mukhina GL, Garrett ES, et al. Natural history of paroxysmal nocturnal haemoglobinuria using modern diagnostic assays. *Br J Haematol.* 2004; 126:133-8.
- [109] Mukhina GL, Buckley JT, Barber JP, et al. Multilineage glycosylphosphatidylinositol anchor-deficient haematopoiesis in untreated aplastic anaemia. *Br J Haematol.* 2001; 115:476-82.
- [110] Müller-Eberhard HJ. Molecular organization and function of the complement system. *Annu Rev Biochem.* 1988; 57:321-47.
- [111] Murakami Y, Kosaka H, Maeda Y, et al. Inefficient response of T lymphocytes to glycosylphosphatidylinositol anchor-negative cells: implications for paroxysmal nocturnal hemoglobinuria. *Blood.* 2002; 100:4116-4122.
- [112] Muus P, Szer J, Schrezenmeier H, et al. Evaluation of Paroxysmal Nocturnal Hemoglobinuria Disease Burden: The Patient's Perspective. A Report From the International PNH Registry. *Blood.* 2010; 116:1525a.
- [113] Nagakura S, Ishihara S, Dunn DE, et al. Decreased susceptibility of leukemic cells with PIG-A mutation to natural killer cells in vitro. *Blood.* 2002; 100:1031-1037.
- [114] Nafa K, Mason PJ, Hillmen P, et al. Mutations in the PIG-A gene causing paroxysmal nocturnal hemoglobinuria are mainly of the frameshift type. *Blood.* 1995; 86:4650-5.
- [115] Nafa K, Bessler M, Castro-Malaspina H, et al. The spectrum of somatic mutations in the PIG-A gene in paroxysmal nocturnal hemoglobinuria includes large deletions and small duplications. *Blood Cells Mol Dis.* 1998a; 24:370-84.
- [116] Nafa K, Bessler M, Deeg HJ, et al. New somatic mutation in the PIG-A gene emerges at relapse of paroxysmal nocturnal hemoglobinuria. *Blood.* 1998b; 92:3422-7.
- [117] Nafa K, Bessler M, Mason P, et al. Factor V Leiden mutation investigated by amplification created restriction enzyme site (ACRES) in PNH patients with and without thrombosis. *Haematologica.* 1996; 81:540-2.
- [118] Nakakuma H, Nagakura S, Iwamoto N, et al. Paroxysmal nocturnal hemoglobinuria clone in bone marrow of patients with pancytopenia. *Blood.* 1995; 85:1371-6.

- [119] Nair RK, Khaira A, Sharma A, et al. Spectrum of renal involvement in paroxysmal nocturnal hemoglobinuria: report of three cases and a brief review of the literature. *Int Urol Nephrol*. 2008; 40:471-5.
- [120] Nicholson-Weller A, Burge J, Fearon DT, et al. Isolation of a human erythrocyte membrane glycoprotein with decay-accelerating activity for C3 convertases of the complement system. *J Immunol*. 1982; 129:184-9.
- [121] Nicholson-Weller A, March JP, Rosenfeld SI, et al. Affected erythrocytes of patients with paroxysmal nocturnal hemoglobinuria are deficient in the complement regulatory protein, decay accelerating factor. *Proc Natl Acad Sci U S A*. 1983; 80:5066-70.
- [122] Nicholson-Weller A. Decay accelerating factor (CD55). *Curr Top Microbiol Immunol*. 1992; 178:7-30.
- [123] Ninomiya H, Hasegawa Y, Nagasawa T, et al. Excess soluble urokinase-type plasminogen activator receptor in the plasma of patients with paroxysmal nocturnal hemoglobinuria inhibits cell-associated fibrinolytic activity. *Int J Hematol*. 1997; 65:285-91.
- [124] Nishimura J, Inoue N, Wada H, et al. A patient with paroxysmal nocturnal hemoglobinuria bearing four independent PIG-A mutant clones. *Blood*. 1997; 89:3470-6.
- [125] Nishimura J, Murakami Y, Kinoshita T. Paroxysmal nocturnal hemoglobinuria: An acquired genetic disease. *Am J Hematol*. 1999; 62:175-82.
- [126] Nishimura Ji J, Hirota T, Kanakura Y, et al. Long-term support of hematopoiesis by a single stem cell clone in patients with paroxysmal nocturnal hemoglobinuria. *Blood*. 2002; 99:2748-2751.
- [127] Nishimura J, Kanakura Y, Ware RE, et al. Clinical course and flow cytometric analysis of paroxysmal nocturnal hemoglobinuria in the United States and Japan. *Medicine (Baltimore)*. 2004; 83:193-207.
- [128] Nissen C, Tichelli A, Gratwohl A, et al. High incidence of transiently appearing complement-sensitive bone marrow precursor cells in patients with severe aplastic anemia--A possible role of high endogenous IL-2 in their suppression. *Acta Haematol*. 1999; 101:165-72.
- [129] Oni BS, Osunkoya BO & Luzzatto L. Paroxysmal nocturnal hemoglobinuria: evidence for monoclonal origin of abnormal red cells. *Blood*. 1970; 36:145-152.
- [130] Orphanet. Paroxysmal Nocturnal Hemoglobinuria. 1-12-2004. Ref Type: Internet Communication
- [131] Pangburn MK, Schreiber RD & Müller-Eberhard HJ. Formation of the initial C3 convertase of the alternative complement pathway. Acquisition of C3b-like activities by spontaneous hydrolysis of the putative thioester in native C3. *J Exp Med*. 1981; 154:856-67.
- [132] Pangburn MK, Schreiber RD, Trombold JS, et al. Paroxysmal nocturnal hemoglobinuria: deficiency in factor H-like functions of the abnormal erythrocytes. *J Exp Med*. 1983a; 157:1971-80.
- [133] Pangburn MK & Müller-Eberhard HJ. Initiation of the alternative complement pathway due to spontaneous hydrolysis of the thioester of C3. *Ann N Y Acad Sci*. 1983; 421:291-8.

- [134] Pangburn MK, Schreiber RD & Müller-Eberhard HJ. Deficiency of an erythrocyte membrane protein with complement regulatory activity in paroxysmal nocturnal hemoglobinuria. *Proc Natl Acad Sci U S A*. 1983b; 80:5430-4.
- [135] Pangburn MK, Schreiber RD & Müller-Eberhard HJ. C3b deposition during activation of the alternative complement pathway and the effect of deposition on the activating surface. *J Immunol*. 1983c; 131:1930-5.
- [136] Parker CJ, Baker PJ & Rosse WF. Increased enzymatic activity of the alternative pathway convertase when bound to the erythrocytes of paroxysmal nocturnal hemoglobinuria. *J Clin Invest*. 1982; 69:337-46.
- [137] Parker CJ. Historical aspects of paroxysmal nocturnal hemoglobinuria; "defining the disease". *Br J Haematol*. 2002; 117:3-22.
- [138] Parker CJ & Ware RE. 2003. Paroxysmal nocturnal hemoglobinuria. In: Greer J et al (ed). *Wintrobe's clinical hematology - 11<sup>th</sup> ed*. Philadelphia: Lippincott Williams & Wilkins. p 1203-1221.
- [139] Parker C, Omine M, Richards S, et al; International PNH Interest Group. Diagnosis and management of paroxysmal nocturnal hemoglobinuria. *Blood*. 2005; 106:3699-709.
- [140] Parker C. Eculizumab for paroxysmal nocturnal haemoglobinuria. *Lancet*. 2009; 373:759-67.
- [141] Plasilova M, Risitano AM, O'Keefe CL, et al. Shared and individual specificities of immunodominant cytotoxic T cell clones in Paroxysmal Nocturnal Hemoglobinuria as determined by molecular analysis. *Exp Hematol*. 2004; 32:261-269.
- [142] Poggi A, Negrini S, Zocchi MR, et al. Patients with paroxysmal nocturnal hemoglobinuria have a high frequency of peripheral-blood T cells expressing activating isoforms of inhibiting superfamily receptors. *Blood*. 2005; 106:2399-408.
- [143] Pramoonjago P, Pakdeesawan K, Siripanyaphinyo U, et al. Genotypic, immunophenotypic and clinical features of Thai patients with paroxysmal nocturnal haemoglobinuria. *Br J Haematol*. 1999; 105:497-504.
- [144] Raiola AM, Van Lint MT, Lamparelli T, et al. Bone marrow transplantation for paroxysmal nocturnal hemoglobinuria. *Haematologica*. 2000; 85:59-62.
- [145] Richards SJ, Rawstron AC, Hillmen P. Application of flow cytometry to the diagnosis of paroxysmal nocturnal hemoglobinuria. *Cytometry*. 2000; 42:223-33.
- [146] Risitano AM, Maciejewski JP, Green S, et al. In vivo dominant immune responses in aplastic anemia patients: molecular tracking of putatively pathogenic T cells by TCR $\beta$ -CDR3 sequencing. *Lancet*. 2004 ; 364:353-363.
- [147] Risitano AM, Maciejewski JP, Muranski P, et al. Large granular lymphocyte (LGL)-like clonal expansions in paroxysmal nocturnal hemoglobinuria (PNH) patients. *Leukemia*. 2005; 19:217-22.
- [148] Risitano AM, Marando L, Seneca E, et al. Hemoglobin normalization after splenectomy in a paroxysmal nocturnal hemoglobinuria patient treated by eculizumab. *Blood*. 2008; 112:449-51.
- [149] Risitano AM, Notaro R, Marando L, et al. Complement fraction 3 binding on erythrocytes as additional mechanism of disease in paroxysmal nocturnal hemoglobinuria patients treated by eculizumab. *Blood*. 2009a; 113:4094-100.
- [150] Risitano AM, Seneca E, Marando L, et al. From Renal Siderosis Due to Perpetual Hemosiderinuria to Possible Liver Overload Due to Extravascular Hemolysis: Changes in Iron Metabolism in Paroxysmal Nocturnal Hemoglobinuria (PNH) Patients on Eculizumab. *Blood*. 2009b; 114:4031a.

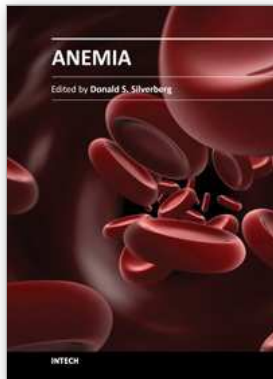


- [151] Risitano AM, Holers VM & Rotoli B. TT30, a Novel Regulator of the Complement Alternative Pathway (CAP), Inhibits Hemolysis of Paroxysmal Nocturnal Hemoglobinuria (PNH) Erythrocytes and Prevents Upstream C3 Binding On Their Surface in An in Vitro Model. *Blood*. 2009c; 114:158a.
- [152] Risitano AM, Selleri C, Serio B, et al; Working Party Severe Aplastic Anaemia (WPSAA) of the European Group for Blood and Marrow Transplantation (EBMT). Alemtuzumab is safe and effective as immunosuppressive treatment for aplastic anaemia and single-lineage marrow failure: a pilot study and a survey from the EBMT WPSAA. *British Journal of Haematology*. 2010a; 148, 791-6.
- [153] Risitano AM, Notaro R, Luzzatto L, et al. Paroxysmal Nocturnal Hemoglobinuria: Hemolysis Before and After Eculizumab. *New Engl J Med*. 2010b; 363:2270-2.
- [154] Risitano AM. Immunosuppressive therapies in the management of immune-mediated marrow failures in adults: where we stand and where we are going. *Br J Haematol*. 2011; 152:127-40.
- [155] Risitano AM, Perna F & Selleri C. Achievements and limitations of complement inhibition by eculizumab in paroxysmal nocturnal hemoglobinuria: the role of complement component 3. *Mini Rev Med Chem*. 2011; 11:528-35.
- [156] Rosse WF & Dacie JV. Immune lysis of normal human and paroxysmal nocturnal hemoglobinuria (PNH) red blood cells. I. The sensitivity of PNH red cells to lysis by complement and specific antibody. *J Clin Invest*. 1966; 45:736-748.
- [157] Rosse WF. The life-span of complement-sensitive and -insensitive red cells in paroxysmal nocturnal hemoglobinuria. *Blood*. 1971; 37:556-562.
- [158] Rosse WF. Variations in the red cells in paroxysmal nocturnal haemoglobinuria. *Br J Haematol*. 1973; 24:327-342.
- [159] Rosse WF. Dr Ham's test revisited. *Blood*. 1991; 78:547-550.
- [160] Rosse WF. Epidemiology of PNH. *Lancet* 1996; 348:560.
- [161] Rosti V, Tremml G, Soares V, et al. Murine embryonic stem cells without pig-a gene activity are competent for hematopoiesis with the PNH phenotype but not for clonal expansion. *J Clin Invest*. 1997; 100:1028-1036.
- [162] Rosti V. Murine models of paroxysmal nocturnal hemoglobinuria. *Ann N Y Acad Sci*. 2002; 963:290-6.
- [163] Rother RP, Bell L, Hillmen P, et al. The clinical sequelae of intravascular hemolysis and extracellular plasma hemoglobin: a novel mechanism of human disease. *JAMA*. 2005; 293:1653-62.
- [164] Rother RP, Rollins SA, Mojcik CF, et al. Discovery and development of the complement inhibitor eculizumab for the treatment of paroxysmal nocturnal hemoglobinuria. *Nat Biotechnol*. 2007; 25:1256-64.
- [165] Rotoli B, Robledo R & Luzzatto L. Decreased number of circulating BFU-Es in paroxysmal nocturnal hemoglobinuria. *Blood*. 1982; 60:157-9.
- [166] Rotoli B, Robledo R, Scarpato N, et al. Two populations of erythroid cell progenitors in paroxysmal nocturnal hemoglobinuria. *Blood*. 1984; 64:847-851.
- [167] Rotoli B & Luzzatto L. Paroxysmal nocturnal haemoglobinuria. *Baillieres Clin Haematol* 1989; 2:113-138.
- [168] Sanchez-Valle E, Morales-Polanco MR, Gomez-Morales E, et al. Treatment of paroxysmal nocturnal hemoglobinuria with antilymphocyte globulin. *Rev Invest Clin*. 1993; 45:457-461.

- [169] Santarone S, Bacigalupo A, Risitano AM, et al. Hematopoietic stem cell transplantation for paroxysmal nocturnal hemoglobinuria: long-term results of a retrospective study on behalf of the Gruppo Italiano Trapianto Midollo Osseo (GITMO). *Haematologica*. 2010; 95:983-8.
- [170] Saso R, Marsh J, Cevreska L, et al. Bone marrow transplants for paroxysmal nocturnal haemoglobinuria. *Br J Haematol*. 1999; 104:392-396.
- [171] Schafer A, Wiesmann F, Neubauer S, et al. Rapid regulation of platelet activation in vivo by nitric oxide. *Circulation*. 2004; 109:1819-22.
- [172] Scheinberg P, Marte M, Nunez O, et al. Paroxysmal nocturnal hemoglobinuria clones in severe aplastic anemia patients treated with horse anti-thymocyte globulin plus cyclosporine. *Haematologica*. 2010; 95:1075-80.
- [173] Schubert J, Scholz C, Geissler RG, et al. G-CSF and cyclosporin induce an increase of normal cells in hypoplastic paroxysmal nocturnal hemoglobinuria. *Ann Hematol*. 1997; 74:225-30.
- [174] Selvaraj P, Rosse WF, Silber R, et al. The major Fc receptor in blood has a phosphatidylinositol anchor and is deficient in paroxysmal nocturnal haemoglobinuria. *Nature*. 1988; 333:565-7.
- [175] Shin ML, Hansch G, Hu VW, et al. Membrane factors responsible for homologous species restriction of complement-mediated lysis: evidence for a factor other than DAF operating at the stage of C8 and C9. *J Immunol*. 1986; 136:1777-82.
- [176] Sholar PW & Bell WR. Thrombolytic therapy for inferior vena cava thrombosis in paroxysmal nocturnal hemoglobinuria. *Ann Intern Med*. 1985; 103:539-41.
- [177] Sica M, Pascariello C, Rondelli T, et al. In vitro complement protein 5 (C5) blockade recapitulates the Complement protein 3 (C3) binding to GPI-negative erythrocytes observed in Paroxysmal Nocturnal Hemoglobinuria (PNH) patients on eculizumab. *Haematologica*. 2010; 95(s2):196(a).
- [178] Simak J, Holada K, Risitano AM, et al. Elevated counts of circulating endothelial membrane microparticles in paroxysmal nocturnal hemoglobinuria indicate inflammatory status and ongoing stimulation of vascular endothelium. *Br J Hematol*. 2004; 125:804-813.
- [179] Sloan EM, Pfannes L, Scheinberg P, et al. Increased soluble urokinase plasminogen activator receptor (suPAR) is associated with thrombosis and inhibition of plasmin generation in paroxysmal nocturnal hemoglobinuria (PNH) patients. *Exp Hematol*. 2008; 36:1616-24.
- [180] Socie G, Mary JY, de Gramont A, et al. Paroxysmal nocturnal haemoglobinuria: long-term follow-up and prognostic factors. French Society of Haematology. *Lancet*. 1996; 348:573-7.
- [181] Stebler C, Tichelli A, Dazzi H, et al. High-dose recombinant human erythropoietin for treatment of anemia in myelodysplastic syndromes and paroxysmal nocturnal hemoglobinuria: a pilot study. *Exp Hematol*. 1990; 18:1204-8.
- [182] Stoppa AM, Vey N, Sainty D, et al. Correction of aplastic anaemia complicating paroxysmal nocturnal haemoglobinuria: absence of eradication of the PNH clone and dependence of response on cyclosporin A administration. *Br J Haematol*. 1996; 93:42-4.
- [183] Sugimori C, Chuhjo T, Feng X, et al. Minor population of CD55-CD59- blood cells predicts response to immunosuppressive therapy and prognosis in patients with aplastic anemia. *Blood*. 2006; 107:1308-14.

- [184] Sutherland DR, Kuek N, Davidson J, et al. Diagnosing PNH with FLAER and multiparameter flow cytometry. *Cytometry B Clin Cytom.* 2007; 72:167-77.
- [185] Takahashi M, Takeda J, Hirose S, et al. Deficient biosynthesis of N-acetylglucosaminylphosphatidylinositol, the first intermediate of glycosyl phosphatidylinositol anchor biosynthesis, in cell lines established from patients with paroxysmal nocturnal hemoglobinuria. *J Exp Med.* 1993; 177:517-21.
- [186] Takahashi Y, McCoy JP Jr., Carvallo C, et al. In vitro and in vivo evidence of PNH cell sensitivity to immune attack after nonmyeloablative allogeneic hematopoietic cell transplantation. *Blood.* 2004; 103:1383-1390.
- [187] Takeda J, Miyata T, Kawagoe K, et al. Deficiency of the GPI anchor caused by a somatic mutation of the PIG-A gene in paroxysmal nocturnal hemoglobinuria. *Cell.* 1993; 73:703-11.
- [188] Takeda J & Kinoshita T. GPI-anchor biosynthesis. *Trends Biochem Sci.* 1995; 20:367-71.
- [189] Telen MJ & Green AM. The Inab phenotype: characterization of the membrane protein and complement regulatory defect. *Blood.* 1989; 74:437-41.
- [190] Tichelli A, Gratwohl A, Nissen C, et al. Morphology in patients with severe aplastic anemia treated with antilymphocyte globulin. *Blood.* 1992; 80:337-45.
- [191] Tremml G, Dominguez C, Rosti V, et al. Increased sensitivity to complement and a decreased red blood cell life span in mice mosaic for a nonfunctional Piga gene. *Blood.* 1999; 94:2945-54.
- [192] van Beers EJ, Schaap MC, Berckmans RJ, et al; CURAMA study group. Circulating erythrocyte-derived microparticles are associated with coagulation activation in sickle cell disease. *Haematologica.* 2009; 94:1513-9.
- [193] van der Schoot CE, Huizinga TW, van 't Veer-Korthof ET, et al. Deficiency of glycosylphosphatidylinositol-linked membrane glycoproteins of leukocytes in paroxysmal nocturnal hemoglobinuria, description of a new diagnostic cytofluorometric assay. *Blood.* 1990; 76:1853-1859.
- [194] van Kamp H, Smit JW, van den Berg E, et al. Myelodysplasia following paroxysmal nocturnal haemoglobinuria: evidence for the emergence of a separate clone. *Br J Haematol.* 1994; 87:399-400.
- [195] van Kamp H, van Imhoff GW, de Wolf JT, et al. The effect of cyclosporine on haematological parameters in patients with paroxysmal nocturnal haemoglobinuria. *Br J Haematol.* 1995; 89:79-82.
- [196] Vu T, Griscelli-Bennaceur A, Gluckman E, et al. Aplastic anaemia and paroxysmal nocturnal haemoglobinuria: a study of the GPI-anchored proteins on human platelets. *Br J Haematol.* 1996; 93:586-9.
- [197] Ware RE, Hall SE & Rosse WF. Paroxysmal nocturnal hemoglobinuria with onset in childhood and adolescence. *N Engl J Med.* 1991; 325:991-996.
- [198] Whaley K & Ruddy S. Modulation of the alternative complement pathway by  $\beta$ 1H globulin. *J Exp Med.* 1976; 144:1147-63
- [199] Wiedmer T, Hall SE, Ortel TL, et al. Complement-induced vesiculation and exposure of membrane prothrombinase sites in platelets of paroxysmal nocturnal hemoglobinuria. *Blood.* 1993; 82:1192-6.
- [200] Wilcox LA, Ezzell JL, Bernshaw NJ, et al. Molecular basis of the enhanced susceptibility of the erythrocytes of paroxysmal nocturnal hemoglobinuria to hemolysis in acidified serum. *Blood.* 1991; 78:820-9.

- 
- [201] Yamashina M, Ueda E, Kinoshita T, et al. Inherited complete deficiency of 20-kilodalton homologous restriction factor (CD59) as a cause of paroxysmal nocturnal hemoglobinuria. *N Engl J Med.* 1990; 323:1184-9.
- [202] Young NS & Maciejewski JP. Genetic and environmental effects in paroxysmal nocturnal hemoglobinuria: this little PIG-A goes "Why? Why? Why?". *J Clin Invest.* 2000; 106:637-641.
- [203] Young NS, Calado RT & Scheinberg P. Current concepts in the pathophysiology and treatment of aplastic anemia. *Blood.* 2006; 108, 2509-19.



## **Anemia**

Edited by Dr. Donald Silverberg

ISBN 978-953-51-0138-3

Hard cover, 440 pages

**Publisher** InTech

**Published online** 29, February, 2012

**Published in print edition** February, 2012

This book provides an up-to-date summary of many advances in our understanding of anemia, including its causes and pathogenesis, methods of diagnosis, and the morbidity and mortality associated with it. Special attention is paid to the anemia of chronic disease. Nutritional causes of anemia, especially in developing countries, are discussed. Also presented are anemias related to pregnancy, the fetus and the newborn infant. Two common infections that cause anemia in developing countries, malaria and trypanosomiasis are discussed. The genetic diseases sickle cell disease and thalassemia are reviewed as are Paroxysmal Nocturnal Hemoglobinuria, Fanconi anemia and some anemias caused by toxins. Thus this book provides a wide coverage of anemia which should be useful to those involved in many fields of anemia from basic researchers to epidemiologists to clinical practitioners.

### **How to reference**

In order to correctly reference this scholarly work, feel free to copy and paste the following:

Antonio M. Risitano (2012). Paroxysmal Nocturnal Hemoglobinuria, Anemia, Dr. Donald Silverberg (Ed.), ISBN: 978-953-51-0138-3, InTech, Available from: <http://www.intechopen.com/books/anemia/paroxysmal-nocturnal-hemoglobinuria>

**INTECH**  
open science | open minds

### **InTech Europe**

University Campus STeP Ri  
Slavka Krautzeka 83/A  
51000 Rijeka, Croatia  
Phone: +385 (51) 770 447  
Fax: +385 (51) 686 166  
[www.intechopen.com](http://www.intechopen.com)

### **InTech China**

Unit 405, Office Block, Hotel Equatorial Shanghai  
No.65, Yan An Road (West), Shanghai, 200040, China  
中国上海市延安西路65号上海国际贵都大饭店办公楼405单元  
Phone: +86-21-62489820  
Fax: +86-21-62489821

© 2012 The Author(s). Licensee IntechOpen. This is an open access article distributed under the terms of the [Creative Commons Attribution 3.0 License](#), which permits unrestricted use, distribution, and reproduction in any medium, provided the original work is properly cited.