

Diagnostic Evaluation of Anaemia

Vikrant Kale and Abdur Rahmaan Aftab
Gastroenterology Department,
St.Luke's Hospital, Kilkenny
Ireland

1. Introduction

Anaemia is one of the major signs of disease. It is never normal and its cause(s) should always be sought.

The history, physical examination, and simple laboratory testing are all useful in evaluating the anaemic patient.

The workup should be directed towards answering the following questions concerning whether one or more of the major processes leading to anaemia may be operative:

- Is the patient bleeding (now or in the past)?
- Is there evidence for increased RBC destruction (haemolysis)?
- Is the bone marrow suppressed?
- Is the patient iron deficient? If so, why?
- Is the patient deficient in folic acid or vitamin B12? If so, why?

Depending on the provisional diagnosis, you may need special investigations like *radiologic tests, bone marrow aspiration, gastrointestinal endoscopies, molecular studies etc.* to arrive at a definite diagnosis.

2. History taking

2.1 Onset, duration and progress

Insidious onset, long duration and gradual progress of symptoms in a patient with anaemia suggests nutritional anaemia, chronic haemolytic anaemia (congenital or acquired), anaemia of chronic disease and anaemia due to chronic blood loss. Rapid onset, short duration and rapid progress of symptoms indicate acute leukaemia, acute haemolytic anaemia, hemolytic/aplastic crisis in chronic haemolytic anaemia, anaemia secondary to acute blood loss and infiltrative disorders of the bone marrow.

Presence of symptoms other than those due to anaemia is a pointer to underlying disease causing anaemia and provides clues for further work up of the patient. Inquiry should be made to uncover conditions that may cause gastro-intestinal, genito-urinary or any other blood loss.

An anaemic patient who complains of angina or symptoms of cerebral hypoxia urgently needs the oxygen carrying capacity raised by red cell transfusions and inspired oxygen, whatever may be the cause of anaemia. Passage of dark red or brown urine indicates

haemoglobinuria and suggests haemolysis. History of episodes of bone pain, backache, abdominal pain in past suggests the diagnosis of Sickle Cell Disease.

2.2 Age & sex

Anaemia is more common in pregnant women, females in reproductive age and children during the phase of rapid growth. A predominantly cereal based diet which is poor in green leafy vegetables and vitamin C containing foods is a common cause of iron deficiency.

In a female patient, a detailed menstrual history and history of reproductive performance (number of deliveries and interval between deliveries), provide information about stress on iron balance and raises the possibility of iron deficiency anaemia.

Self imposed or improperly advised dietary restrictions can contribute to nutritional anaemia.

2.3 Drug ingestion

Drug ingestion can cause anaemia in several ways. Long term ingestion of aspirin (in patients of coronary artery disease) can lead to chronic blood loss and iron deficiency anaemia. Certain drugs can cause haemolysis in individuals with G-6-PD deficiency. Rifampicin and alpha methyl dopa can cause autoimmune haemolytic anaemia. Chemotherapeutic drugs can cause marrow depression and pancytopenia.

A past history of cardiac valve surgery can indicate the possibility of haemolysis.

3. Physical examination

Clinical examination can provide a wealth of diagnostic information. Although signs are not always present, they can be helpful in making a clinical diagnosis.

A smooth(bald) tongue and nail changes of koilonychia (brittle, flat or concave nails, more common in toe nails than in finger nails), and bilateral, painless parotid enlargement in a patient with anaemia suggests the diagnosis of *iron deficiency anaemia*. Skin pigmentation in the peri-oral region and over the knuckles is suggestive of *megaloblastic anaemia*. The presence of mild jaundice would suggest possibility of *haemolytic anaemia*. A generalized greyish discoloration of skin indicates *iron overload* in anaemic patients who have been given blood transfusions over several years. Skin pigmentation and various skeletal abnormalities may be present in some cases of *constitutional hypoplastic anaemia*. The presence of petechial haemorrhages would indicate a marrow infiltrative disease (leukaemia, lymphoma, myeloma, metastases, etc.), they may also be seen in megaloblastic anaemia.

Fronto-temporal bossing, malar prominence, upper jaw and teeth projecting beyond the lower jaw, flat bridge of the nose - all giving rise to typical facial appearance are characteristic of *Thalassemia syndromes*. Puffiness of lower eye lids, loss of eye brow hair and thick voice would suggest *myxedema* as the cause of anaemia; this can be confirmed by delayed relaxation of muscle after eliciting deep reflexes.

The presence of hypertension should alert the clinician to the possibility of *anaemia secondary to chronic renal failure*.

Tenderness of calf muscles suggests megaloblastic anaemia but could be present even in iron deficiency anaemia. Signs of sub-acute combined degeneration indicate *pernicious anaemia*. Lymphadenopathy suggests the possibility of *leukaemia or lymphoma*.

4. Laboratory evaluation

Lab tests in the diagnosis of Anaemia:

<p>1. Complete Blood Count(CBC)</p> <p>A. Red blood cell count</p> <ul style="list-style-type: none"> - Haemoglobin - Hematocrit(HCT) - Reticulocyte count <p>B. Red blood cell indices</p> <ul style="list-style-type: none"> - Mean cell volume(MCV) - Mean cell haemoglobin(MCH) - Mean cell haemoglobin Concentration(MCHC) - Red cell distribution width (RDW) <p>C. White blood cell count</p> <ul style="list-style-type: none"> - Cell differential - Nuclear segmentation of Neutrophils <p>D. Platelet count</p> <p>E. Cell morphology</p> <ul style="list-style-type: none"> - Cell size - Haemoglobin content - Anisocytosis - Poikilocytosis - Polychromasia 	<p>2. Iron supply studies</p> <p>A. Serum Iron</p> <p>B. Total iron binding capacity</p> <p>C. Serum ferritin</p> <p>D. Marrow iron stain</p> <p>3. Marrow examination</p> <p>A. Aspirate</p> <ul style="list-style-type: none"> - M/E ratio* - Cell morphology - Iron stain <p>B. Biopsy</p> <ul style="list-style-type: none"> - Cellularity - Morphology
---	--

M/E ratio – ratio of myeloid to erythroid precursors.

Source – Harrison's Principles of Internal Medicine, 16th edition.

4.1 Mean corpuscular volume

The normal range for MCV is from 80 to 100 femtoliters (fL). Values in excess of 115 fL are almost exclusively seen in vitamin B12 or folic acid deficiency. Even higher values can occur as an artefact when cold agglutinins are present, which causes RBCs to go through the counting aperture in doublets or triplets. Low values usually indicate a microcytic anaemia.

4.2 Mean corpuscular haemoglobin

The normal MCH ranges from 27.5 to 33.2 picograms of haemoglobin per RBC. Low values are seen in iron deficiency and thalassemia, while increased values occur in macrocytosis of any cause.

4.3 Mean corpuscular haemoglobin concentration

The mean normal value for the MCHC is 34 grams of haemoglobin per dL of RBCs. Low values occur in the same conditions that generate low values for MCV and MCH, while increased values occur almost exclusively in the presence of congenital or acquired spherocytosis or in other congenital haemolytic anaemia in which red cells are abnormally desiccated (eg, sickle cell anaemia, haemoglobin C disease, xerocytosis).

4.4 Reticulocyte count

The reticulocyte count, either as a percentage of all RBCs, the absolute reticulocyte count, the corrected absolute reticulocyte count, or as the reticulocyte production index, helps to distinguish among the different types of anaemia:

- Anaemia with a high reticulocyte count reflects an increased erythropoietic response to continued haemolysis or blood loss.
- A stable anaemia with a low reticulocyte count is strong evidence for deficient production of RBCs (ie, a reduced marrow response to the anaemia).
- Haemolysis or blood loss can be associated with a low reticulocyte count if there is a concurrent disorder that impairs RBC production (eg, infection, prior chemotherapy).
- A low reticulocyte percentage accompanied by pancytopenia is suggestive of aplastic anaemia, while a reticulocyte percentage of zero with normal white blood cell and platelet counts suggests a diagnosis of pure red cell aplasia.

4.5 White blood cell count and differential

A low total white blood cell (WBC) count (leukopenia) in a patient with anaemia should lead to consideration of bone marrow suppression or replacement, hypersplenism, or deficiencies of cobalamin(B12) or folate. In comparison, a high total WBC count (leukocytosis) may reflect the presence of infection, inflammation, or a hematologic malignancy.

Clues to the specific abnormality present may be obtained from the WBC differential, which, in conjunction with the total WBC may show increased or decreased absolute numbers of the various cell types in the circulation. Examples include:

- An increased absolute neutrophil count in infection or steroid therapy
- An increased absolute monocyte count in myelodysplasia
- An increased absolute eosinophil count in certain infections
- A decreased absolute neutrophil count following chemotherapy
- A decreased absolute lymphocyte count in HIV infection or following treatment with corticosteroids.

4.6 Neutrophil hypersegmentation

Neutrophil hypersegmentation (NH) is defined as the presence of >5 percent of neutrophils with five or more lobes and/or the presence of one or more neutrophils with six or more lobes. This peripheral smear finding, along with macro-ovalocytic red cells, is classically associated with impaired DNA synthesis, as seen in disorders of vitamins B12 and folic acid.

4.7 Circulating nucleated red blood cells

Nucleated RBCs (NRBCs) are not normally found in the circulation. They may be present in patients with known hematologic disease (eg, sickle cell disease, thalassemia major, various

haemolytic anaemia after splenectomy), or as a part of the leukoerythroblastic pattern seen in patients with bone marrow replacement.

In patients without known hematologic disease, NRBCs may reflect the presence of a life-threatening disease, such as sepsis or severe heart failure.

4.8 Platelet count

Abnormalities in the platelet count often provide important diagnostic information. Thrombocytopenia occurs in a variety of disorders associated with anaemia, including hypersplenism, marrow involvement with malignancy, autoimmune platelet destruction (either idiopathic or drug-related), sepsis, or folate or cobalamin deficiency.

High platelet counts, in comparison, may reflect myeloproliferative disease, chronic iron deficiency, and inflammatory, infectious, or neoplastic disorders. Changes in platelet morphology (giant platelets, degranulated platelets) also may be important, suggesting myeloproliferative or myelodysplastic disease.

4.9 Pancytopenia

The combination of anaemia, thrombocytopenia, and neutropenia is termed pancytopenia. The presence of severe pancytopenia narrows the differential diagnosis to disorders such as aplastic anaemia, folate or cobalamin deficiency, or hematologic malignancy (eg, acute myeloid leukaemia). Mild degrees of pancytopenia may be seen in patients with splenomegaly and splenic trapping of circulating cellular elements (hypersplenism).

4.10 Blood smear

Many clinicians rely on the above RBC parameters and the RDW in evaluating a patient with anaemia. However, the RDW is of limited utility, and examination of the peripheral blood smear provides information not otherwise available.

As examples, the automated counter may miss the red cell fragmentation ("helmet cells", schistocytes) of microangiopathic haemolysis, microspherocytes in autoimmune haemolytic anaemia, teardrop RBCs in myeloid metaplasia, a leukoerythroblastic pattern with bone marrow replacement, the "bite cells" in oxidative haemolysis, or RBC parasites such as malaria or babesiosis.

4.11 Serial evaluation of haemoglobin and hematocrit

Measuring the rate of fall of the patient's Hb or HCT often provides helpful diagnostic information. Suppose the Hb concentration has fallen from 15 to 10 g/dL in one week. If this were due to total cessation of RBC production (ie, a reticulocyte count of zero) and if the rate of RBC destruction were normal (1 percent/day), the Hb concentration would have fallen by 7 percent over seven days, resulting a decline of 1.05 g/dL (0.07×15). The greater fall in Hb in this patient (5 g/dL) indicates that marrow suppression cannot be the sole cause of the anaemia and that blood loss and/or increased RBC destruction must be present.

4.12 Evaluation for iron deficiency

More complete evaluation for iron deficiency is indicated when the history (menometrorrhagia, symptoms of peptic ulcer disease) and preliminary laboratory data (low MCV, low MCH, high RDW, increased platelet count) support this diagnosis. In this setting, the plasma levels of iron, iron binding capacity (transferrin), transferrin saturation, and ferritin should be measured. This is discussed in detail below.

4.13 Evaluation for haemolysis

Haemolysis should be considered if the patient has a rapid fall in haemoglobin concentration, reticulocytosis, and/or abnormally shaped RBCs (especially spherocytes or fragmented RBCs) on the peripheral smear. The usual ancillary findings of haemolysis are an increase in the serum lactate dehydrogenase (LDH) and indirect bilirubin concentrations and a reduction in the serum haptoglobin concentration.

The combination of an increased LDH and reduced haptoglobin is 90 percent specific for diagnosing haemolysis, while the combination of a normal LDH and a serum haptoglobin greater than 25 mg/dL is 92 percent sensitive for ruling out haemolysis.

4.14 Intravascular haemolysis

Serum or plasma haemoglobin and urinary hemosiderin should be measured if intravascular haemolysis is a consideration, as with paroxysmal nocturnal haemoglobinuria.

4.15 Bone marrow examination

Examination of the bone marrow generally offers little additional diagnostic information in the more common forms of anaemia. If erythropoiesis is increased in response to the anaemia, the bone marrow will show erythroid hyperplasia, a nonspecific finding. Similarly, although the absence of stainable iron in the bone marrow had previously been considered the "gold standard" for the diagnosis of iron deficiency, this diagnosis is usually established by laboratory tests alone.

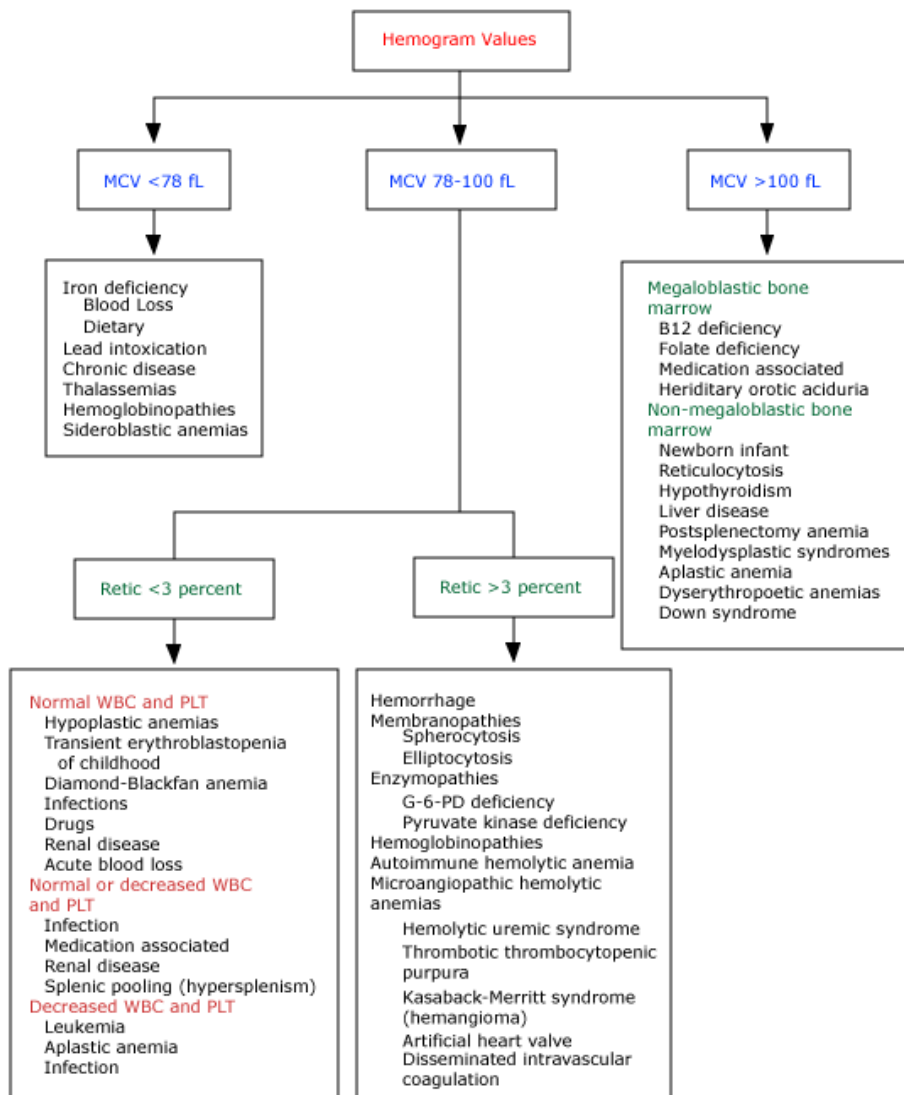
Indications for examination of the bone marrow in anaemic patients include pancytopenia or the presence of abnormal cells in the circulation, such as blast forms. Such patients may have aplastic anaemia, myelodysplasia, marrow replacement with malignancy, or a myeloproliferative disease. Other findings that may be seen in the marrow in anaemic patients include megaloblastic erythropoiesis (folate or cobalamin deficiency), absence of recognizable RBC precursors (pure RBC aplasia), vacuolization of RBC precursors (alcohol or drug-induced anaemia), and increased iron-laden RBC precursors (the sideroblastic anaemia).

4.16 Multiple causes of anaemia

Multiple causes are frequently present in adults, particularly the elderly. Common examples are:

- A patient with gastrointestinal bleeding secondary to colon cancer may also have the anaemia of chronic disease, leading to a blunted reticulocyte response.
- A patient with a chronic hemolytic anaemia (eg, sickle cell anaemia, hereditary spherocytosis) may develop worsening anaemia following acute infection, particularly with parvovirus B19, which may blunt or temporarily ablate erythropoiesis and the reticulocyte response.
- A patient with autoimmune hemolytic anaemia may develop worsening anaemia from gastrointestinal blood loss following treatment with corticosteroids.
- Anaemia, renal failure, and congestive failure are often found together, a condition that has been termed "cardio-renal anaemia syndrome." Treatment of the anaemia may improve both the renal failure and heart failure.

Algorithm for diagnosing cause of anaemia



Source : Nathan, DG, Oski, FA. *Hematology of Infancy and Childhood*, 4th ed, WB Saunders, Philadelphia, PA 1993. p. 352.

5. Anaemia due to decreased red cell production

A variety of disorders are associated with anaemia due to decreased red cell production (ie, hypoproliferative anaemia). This situation is simplistically identified by the finding of a low corrected absolute reticulocyte count (reticulocytopenia).

The differential diagnosis of a hypoproliferative anaemia can often be narrowed by identification of one of the six specific presenting patterns outlined below.

5.1 Normocytic anaemia without leukopenia or thrombocytopenia

The peripheral smear in this setting demonstrates normal red blood cell (RBC) morphology. The red cell indices are normal or slightly hypochromic or microcytic. The white blood cell (WBC) count is usually normal although there may be a neutrophilic leukocytosis. The WBC are not dysplastic and blasts are not seen. The platelet count is usually normal or elevated. The platelets are not dysplastic.

The bone marrow is usually not examined in these cases. If studied, it would show normal cellularity, normal maturation of the several cell lines, and normal iron stores.

This pattern can be induced by a number of disorders-

5.1.1 Anaemia of (chronic) inflammation

This condition is most often associated with infection, inflammation, or malignancy. Initial evaluation with ESR or CRP and then focussed investigations to find a cause should be done.

5.1.2 Mild to moderate iron deficiency

Mild to moderate iron deficiency can be associated with anaemia without the classic findings of hypochromia or microcytosis.

5.1.3 Renal failure

The anaemia associated with renal failure is usually due to a marked reduction in erythropoietin (EPO) production relative to the degree of anaemia. The EPO level usually does not fall until the creatinine clearance drops below 30 mL/minute. Urinalysis for Albumin to Creatinine ratio(ACR) is helpful in detecting renal disease, especially in patients with Diabetes mellitus.

5.1.4 Endocrine disorders

A mild hypoproliferative anaemia can be seen in a number of endocrine disorders, including hypothyroidism, hyperthyroidism, panhypopituitarism, and primary or secondary hyperparathyroidism. How the anaemia occurs in these disorders is not well understood but correction of the endocrine disturbance usually corrects the anaemia.

5.2 Normocytic anaemia with low to absent reticulocytes

The presentation in this setting is similar to variant 1 with one important exception: the RBC morphology is normal but the reticulocyte count is very low, usually <10,000/microL, frequently as low as 2,000/microL, and occasionally zero.

This pattern is highly suggestive of pure red cell aplasia. The bone marrow will show normal overall cellularity and morphology except for the virtual absence of all identifiable erythroid precursors. Giant proerythroblasts may be seen in those patients with pure red cell aplasia secondary to infection with parvovirus.

There are many causes of acquired pure red cell aplasia in adults, the most common being idiopathic, drug-induced, myelodysplastic syndrome, T-cell large granular lymphocytic leukaemia, and thymoma. Regardless of the etiology, the final common pathway seems to be an immunologic attack, usually mediated by T cells, on erythroid progenitors at a maturity level between CFU-E (colony-forming units-erythroid) and proerythroblasts.

5.3 Normocytic anaemia with pancytopenia

The peripheral smear in these patients usually reveals normal RBC morphology but macrocytosis is occasionally seen. The WBC count is low with prominent neutropenia (absolute neutrophil count below 1000/microL) and, in some cases, lymphopenia (<1000/microL) as well. WBC morphology is normal. The platelet count is reduced; the platelet morphology is generally normal with occasional large platelets.

Bone marrow examination is almost always performed in patients with pancytopenia, usually in conjunction with cytogenetic studies. The marrow in most cases of hypoproliferative anaemia with pancytopenia is either profoundly hypocellular with relatively normal morphology of the remaining elements or hypocellular with dysplasia of red cell, neutrophil, and platelet precursors. In some patients, however, the marrow is totally replaced with malignant cells or fibrosis.

Pancytopenia without prominent morphologic abnormalities has a very different set of clinical implications from isolated anaemia. The major causes of this problem include:

- Aplastic anaemia
- Bone marrow suppression following chemotherapy and/or radiation therapy
- Hypoplastic myelodysplastic syndrome
- Marrow replaced by leukaemia, lymphoma, cancer, or rarely, fibrosis

Although splenomegaly can also cause pancytopenia (ie, hypersplenism), the increased peripheral destruction seen in hypersplenism is associated with enhanced erythropoiesis and a high reticulocyte count, and the bone marrow is normocellular to hypercellular, rather than aplastic or hypocellular.

5.4 Macrocytic non-megaloblastic anaemia

The peripheral smear in this disorder shows RBCs that are distinctly macrocytic with very few macroovalocytes. The mean cell volume (MCV) is generally greater than 100 fL. The WBC may be slightly low but there is no dysplasia or blasts. Few, if any, five to six lobed neutrophils are present. The platelet count may be normal or as low as 50,000/microL.

The bone marrow is usually not examined in this setting but, if performed, cellularity and maturation are normal. *Megaloblastosis*, characteristic of cobalamin or folate deficiency, is not seen.

Several disorders can produce a hypoproliferative, macrocytic anaemia without megaloblastosis-

- Alcohol abuse
- Therapy with zidovudine(AZT), other anti-viral agents, hydroxyurea, methotrexate, phenytoin
- Myelodysplastic syndrome, early in its course
- Early in the course of cobalamin or folate deficiency.

5.5 Macrocytic megaloblastic anaemia

The peripheral smear in this setting reveals macrocytic RBCs with macroovalocytes. The WBC count is normal or low, but the neutrophils show hypersegmentation with at least 5 percent of the cells having five or more lobes. The platelet count is normal or low.

These findings are highly suggestive of folate or cobalamin (vitamin B12) deficiency. Bone marrow examination is usually not necessary.

5.6 Leucoerythroblastic anaemia

The peripheral smear in a patient with a leucoerythroblastic anaemia shows abnormal RBC morphology with tear-drop forms, elliptocytes, macrocytes, and circulating nucleated RBC. The WBC count may be high, low, or normal, but there is myeloid immaturity extending back to the myeloblast stage. The platelet count is usually low with abnormal morphology, including giant platelets and even megakaryocyte fragments.

A leucoerythroblastic picture reflects replacement of the bone marrow by granulomas, cancer, fibrosis, or primary myelofibrosis (PMF). The remaining pluripotent stem cells move to the liver and spleen as they did in fetal life, resulting in extramedullary hematopoiesis. The stromal support system in the liver and spleen is not optimal, as it is in the marrow. As a result, hematopoietic cells are released prematurely or abnormally into the circulation. The reticulocyte count is of limited value in this setting because extramedullary hematopoiesis is associated with both disordered release of reticulocytes into the peripheral blood and disordered maturation of nucleated RBC to reticulocytes in the peripheral circulation.

Having recognized the virtually pathognomonic peripheral smear findings, the differential diagnosis focuses on what is replacing the marrow. Therefore, a bone marrow biopsy (aspiration may result in a dry tap) with appropriate staining (for reticulin and collagen) is necessary. There are two major causes:

-Metastatic cancer.

-Myelofibrosis, as seen in the myeloproliferative syndromes such as PMF or myelofibrosis associated with acute myeloid leukaemia, other cancer, or radiation.

The differential diagnosis of a *hypoproliferative anaemia with microcytosis*, which is most often due to iron deficiency, is discussed below.

6. Anaemia due to iron deficiency

The development of iron deficiency, and the rapidity with which it progresses, is dependent upon the individual's initial iron stores which are, in turn, dependent upon age, sex, rate of growth and the balance between iron absorption and loss.

Causes of iron deficiency are discussed below.

6.1 Blood loss

The major cause of iron deficiency in affluent countries is blood loss, either overt or occult. Overt blood loss is, by definition, obvious and not difficult for the clinician to recognize, often by history alone. Examples include severe traumatic haemorrhage, haematemesis, melena, haemoptysis, severe menorrhagia and gross haematuria.

Occult bleeding, on the other hand, may be difficult to track down. This usually occurs via the gastrointestinal tract in men. Other causes are repeated voluntary blood donations, the post-operative setting in which blood loss greatly exceeds the amount of blood transfused, or iatrogenic anaemia due to repeated and massive blood drawing in the course of workup of a complicated medical condition. Additional factors are often responsible in women, including underestimating the degree of menorrhagia, blood loss during delivery, and direct iron loss to the fetus during pregnancy and to the neonate during lactation.

Although reduced gastrointestinal absorption of iron and a diet deficient in iron can also cause iron deficiency, it is most reasonable to believe, as a first assumption, that *iron deficiency reflects blood loss*, in order to avoid missing an occult malignancy or other bleeding intestinal lesion.

6.2 Decreased iron absorption

Gastrointestinal malabsorption of iron is a relatively uncommon cause of iron deficiency, although it may be observed in certain diseases associated with generalized malabsorption or achlorhydria [5]. However, the use of proton pump inhibitors, which reduce gastric acid secretion, has not been associated with clinical iron deficiency.

6.3 Foods and medications

There are a number of foods and medications that impair absorption of iron.

Absorption of haem iron is affected by:
Amount of haem iron, especially in meat
Content of calcium in the meal (calcium impairs iron absorption)
Absorption of nonhaem iron is affected by:
Iron status
Amount of potentially available nonhaem iron
Balance between positive and negative factors
Positive factors
Ascorbic acid
Meat or fish (haem iron enhances absorption of nonhaem iron)
Negative factors
Phytate (in bran, oats, rye fibre)
Polyphenols (in tea, some vegetables and cereals)
Dietary calcium
Soy protein

6.4 Coeliac disease

Iron deficiency anaemia, refractory to oral iron treatment can be seen in patients with coeliac disease, autoimmune atrophic gastritis or *Helicobacter pylori* infection. It is unclear whether there is a component of blood loss contributing to iron deficiency in this condition, although a component of the anaemia of chronic disease (inflammation) is seen in some individuals.

6.5 Other causes

There are several other uncommon causes of iron deficiency:

6.5.1 Intravascular haemolysis

Intravascular haemolysis, with its accompanying haemoglobinuria and hemosiderinuria can lead to significant urinary iron losses in patients with paroxysmal nocturnal haemoglobinuria and in cardiac patients with intravascular destruction of red cells secondary to malfunctioning valvular prostheses, patches, or intracardiac myxomas.

6.5.2 Pulmonary hemosiderosis

Pulmonary hemosiderosis (eg, chronic pulmonary haemorrhage in anti-glomerular basement membrane antibody disease) can appear as functional iron deficiency.

6.5.3 Response to erythropoietin

A response to treatment with erythropoietin (EPO) for the anaemia of chronic renal failure often leads to iron deficiency, since the iron requirements generated by this response can usually not be met by mobilization of the patient's iron stores alone.

6.5.4 Gastric bypass for morbid obesity

This form of surgery bypasses the duodenum, the major site of intestinal iron absorption. As a result, iron deficiency can occur following gastric bypass surgery, not only through the bypassing of the site of major iron absorption, but also as the result of decreased gastric acid availability.

6.5.5 Congenital iron deficiency

Rare families with iron deficiency anaemia unresponsive to oral iron therapy, but partially responsive to parenteral iron, have been reported.

6.6 Estimation of iron stores

The patient's history, complete blood count, red blood cell indices, and examination of the peripheral blood smear usually allow the clinician to make a presumptive diagnosis of iron deficiency anaemia. This can be followed by a therapeutic trial of iron administration to provide both confirmation of the diagnosis and therapy.

6.6.1 Therapeutic trial of iron

A presumptive diagnosis of iron deficiency anaemia is made if there is a positive response to a trial of oral iron therapy, characterized by a modest reticulocytosis beginning in about five to seven days, followed by an increase in haemoglobin at a rate of about 2 to 4 g/dL every three weeks until the haemoglobin concentration returns to normal.

The limitation of this approach occurs if there is no response, or the response is modest or incomplete. In this setting, the clinician cannot differentiate among poor patient compliance, inability to absorb the iron preparation, an incorrect diagnosis, continued bleeding, or a coexisting condition such as the anaemia of chronic disease or renal failure that blocks the full reticulocyte response.

For these reasons, laboratory tests (eg, iron studies, iron panel) are often ordered to confirm the diagnosis prior to initiation of therapy.

6.6.2 Serum or plasma ferritin

The serum or plasma ferritin concentration is an *excellent indicator of iron stores* in otherwise healthy adults and has replaced assessment of bone marrow iron stores as the gold standard

for the diagnosis of iron deficiency in most patients. There is no clinical situation other than iron deficiency in which extremely low values of serum ferritin are seen.

6.6.3 Pregnancy

Serum ferritin is useful in diagnosing iron deficiency in pregnant women, who often have an elevated serum transferrin in the absence of iron deficiency.

6.6.4 Inflammatory states

Ferritin is an acute phase reactant, with plasma levels increasing in liver disease, infection, inflammation, and malignancy.

6.6.5 Serum iron and transferrin (TIBC)

In iron deficiency anaemia, the serum iron concentration (SI) is reduced, and the level of transferrin - also measured as total iron binding capacity (TIBC) is elevated; the latter finding reflects the reciprocal relationship between serum iron and transferrin gene expression in most nonerythroid cells.

The accuracy of measurement of transferrin/TIBC for predicting the presence of iron deficiency is second only to the serum or plasma ferritin concentration. Confounding factors are pregnancy and oral contraceptives, which increase the plasma transferrin concentration.

6.6.6 Bone marrow iron

Iron in bone marrow macrophages and erythroid precursors (sideroblasts) can be detected with the Prussian Blue stain on marrow spicules. Lack of stainable iron in erythroid precursors as well as marrow macrophages is considered by most clinicians to be the "gold standard" for the diagnosis of iron deficiency. In contrast, in uncomplicated anaemia of chronic disease, iron is present in marrow macrophages but absent or reduced in erythroid precursors.

However, bone marrow sampling and testing for stainable iron is expensive, invasive, and usually unnecessary. It has been replaced in practice by measurement of serum ferritin.

6.6.7 Assessment of iron sufficiency

Serum ferritin is often ordered to assess whether the patient is iron sufficient, rather than deficient. Similarly, defining iron sufficiency for the purpose of predicting a response in anaemic patients with chronic renal insufficiency to treatment with erythropoietin requires a relatively high amount of available iron, usually stated as a serum ferritin ≥ 100 ng/mL and a transferrin saturation ≥ 20 percent.

6.6.8 Red cell morphology and indices

Despite the classic description of iron deficiency as leading to a hypochromic, microcytic anaemia, many iron deficient patients in western countries will have normal red cell morphology. Further, the finding of a hypochromic microcytic anaemia is not pathognomonic of iron deficiency, with thalassemia and, less commonly, the anaemia of chronic inflammation being the other common conditions encountered in daily practice. It is important to rule out these disorders before beginning a trial of iron therapy, since many patients with thalassemia or chronic inflammation are already iron overloaded.

7. Evaluation of anaemia due to blood loss

7.1 Upper and lower GI evaluation

Upper and lower GI investigations should be considered in all postmenopausal female and all male patients where Iron Deficiency anaemia (IDA) has been confirmed unless there is a history of significant overt non-GI blood loss.

In the absence of suggestive symptoms (which are unreliable), the order of investigations is determined by local availability, although all patients should be screened for coeliac disease with serology. Small-bowel biopsy samples should be taken at OGD if coeliac serology was positive or not performed.

If oesophago-gastro-duodenoscopy (OGD) is performed as the initial GI investigation, only the presence of gastric cancer or coeliac disease, as explained below, should deter lower GI investigation. In particular, the presence of oesophagitis, erosions and peptic ulcer disease should not be accepted as the cause of IDA until lower GI investigations have been carried out.

Colonoscopy has the following advantages over radiology: it allows biopsy of lesions, treatment of adenomas, and identification of superficial pathology such as angiodysplasia and NSAID damage. Performing gastroscopy and colonoscopy at the same session speeds investigation and saves time for both the hospital and the patient, because only one attendance for endoscopy is required.

Radiographic imaging is a sufficient alternative where colonoscopy is contraindicated. The sensitivity of CT colonography for lesions >10 mm in size is over 90%. Barium enema is less reliable, but is still useful if colonoscopy or CT colonography are not readily available.

7.2 Screening for and further investigation of coeliac disease

Ideally coeliac serology – tissue transglutaminase (tTG) antibody or endomysial antibody, if tTG antibody testing is not available – should be undertaken at presentation. But if this has not been carried out or if the result is not available, duodenal biopsy specimens should be taken. If coeliac serology is negative, small-bowel biopsies need not be performed at OGD unless there are other features, such as diarrhoea, which make coeliac disease more likely. If the tTG antibody test is negative, the post-test probability of coeliac disease is 0.3%, which is less than in the general population. If coeliac serology is positive, coeliac disease is likely and should be confirmed by small-bowel biopsy.

7.3 Further evaluation

Further imaging of the small bowel is probably not necessary unless there is an inadequate response to iron therapy, especially if transfusion dependent. In those with an inadequate response, *video capsule endoscopy* or *enteroscopy* may be helpful to detect angiodysplasia, Crohn's disease and small-bowel neoplasia.

Video capsule endoscopy has a diagnostic yield of 40-55% in this setting. However, it seldom results in a beneficial subsequent intervention. Many lesions detected by both enteroscopy and video capsule endoscopy are within the reach of a gastroscop, and repeat OGD should be considered before these procedures. Bleeding lesions identified by video capsule endoscopy may be amenable to treatment by push or double-balloon enteroscopy. However, the benefits of these procedures after a normal video capsule endoscopy in the context of IDA are unproven.

Small-bowel imaging (*MRI enteroclysis, CT enterography or barium studies*) should also be considered in patients with symptoms suggestive of small-bowel disease, transfusion-dependent IDA, and rapid recurrence of anaemia after normalisation of Hb concentrations. However, many small intestinal lesions that cause asymptomatic anaemia are mucosal and flat or nearly so and most small intestinal imaging modalities apart from video capsule endoscopy are only efficient at identifying mass lesions. CT has the additional advantage of being able to identify extraintestinal pathology such as renal tumours and lymphomas.

Helicobacter pylori colonisation may impair iron uptake and increase iron loss, potentially leading to iron deficiency and IDA. Eradication of *H pylori* appears to reverse anaemia in anecdotal reports and small studies. *H pylori* should be sought by non-invasive testing, if IDA persists or recurs after a normal OGD and colonoscopy, and eradicated if present. *H pylori* urease (CLO) testing of biopsy specimens taken at the initial gastroscopy is an alternative approach.

Autoimmune gastritis has been identified as a potential cause of IDA in up to a quarter of cases, but, although of interest, its diagnosis is currently of little practical value.

Giardia lamblia has occasionally been found during the investigation of IDA. If there is associated diarrhoea, then small-bowel biopsy samples will be taken anyway and may detect this. Where giardiasis is suspected, stool should be sent for ELISA, even if histology of duodenal biopsy samples is negative.

Radiological imaging of the mesenteric vessels is of limited use but may be of value in transfusion-dependent IDA for demonstrating vascular malformations or other occult lesions. There is no evidence to recommend labelled red cell imaging or Meckel's scans in patients with IDA. Faecal occult blood testing is of no benefit in the investigation of IDA, being insensitive and non-specific.

8. Evaluation of anaemia due to increased destruction

Hemolytic anaemia is defined as anaemia due to a shortened survival of circulating red blood cells (RBCs). Although the time of RBC senescent death in adults is 110 to 120 days, it is convenient to define haemolysis as a shortening of RBC survival to a value of less than 100 days.

While there are no symptoms specific for the diagnosis of hemolytic anaemia, recognizing haemolysis is not difficult in the classic patient, who may have many of the following:

- Rapid onset of pallor and anaemia
- Jaundice with increased indirect bilirubin concentration
- History of pigmented (bilirubin) gallstones
- Splenomegaly
- Presence of circulating spherocytic red cells (eg, autoimmune hemolytic anaemia, congenital spherocytosis)
- Other informative red cell shape changes (see below)
- Increased serum lactate dehydrogenase (LDH) concentration
- Reduced or absent level of serum haptoglobin
- A positive direct antiglobulin test (Coombs test)
- Increased reticulocyte percentage or absolute reticulocyte number, indicating the bone marrow's response to the anaemia

Laboratory findings, including an examination of the peripheral smear, are used to confirm the presence of haemolysis, and, if possible, the underlying cause.

Extravascular destruction of red blood cells
Intrinsic red blood cell defects
Enzyme deficiencies (eg, G6PD or pyruvate kinase deficiencies)
Haemoglobinopathies (eg, sickle cell disease, thalassemias, unstable haemoglobins)
Membrane defects (eg, hereditary spherocytosis, elliptocytosis)
Extrinsic red blood cell defects
Liver disease
Hypersplenism
Infections (eg, bartonella, babesia, malaria)
Oxidant agents (eg, dapsone, nitrites, aniline dyes)
Other agents (eg, lead, snake and spider bites)
Large granular lymphocytic leukaemia
Autoimmune hemolytic anaemia (warm- or cold-reacting, drugs)
Intravenous immune globulin infusion
Intravascular destruction of red blood cells
Microangiopathy (eg, aortic stenosis, prosthetic valve)
Transfusion reactions (eg, ABO incompatibility)
Infection (eg, clostridial sepsis, severe malaria)
Paroxysmal cold haemoglobinuria; cold agglutinin disease (on occasion)
Paroxysmal nocturnal haemoglobinuria
Following intravenous infusion of Rho(D) immune globulin
Following intravenous infusion with hypotonic solutions
Snake bites



Official reprint from UpToDate® www.uptodate.com

©2011 UpToDate®

Print | Back

Common causes of hemolytic anaemia in the adult

Hematologic consultation should be obtained in virtually all patients with a new onset of haemolysis, since sudden and life-threatening worsening of anaemia may occur, requiring urgent coordination between clinicians, clinical pathologists, and blood bank personnel for appropriate management.

Haemolysis may also be the first sign of an underlying systemic disorder (eg, thrombotic thrombocytopenic purpura, lupus erythematosus, chronic lymphocytic leukaemia) and may require urgent intervention to prevent death or disease-related complications.

8.1 Peripheral smear

Abnormalities suspicious for the presence of haemolysis include the following:

- Spherocytes, microspherocytes, and elliptocytes.
- Fragmented RBC (schistocytes, helmet cells) indicating the presence of microangiopathic hemolytic anaemia.
- Acanthocytes (spur cells) in patients with liver disease.
- Blister or "bite" cells due to the presence of oxidant-induced damage to the red cell and its membrane.
- RBCs with inclusions, as in Malaria, Babesiosis, and Bartonella infections.
- Teardrop RBCs with circulating nucleated RBC and early white blood cell forms, indicating the presence of marrow involvement, as in primary myelofibrosis or tumor infiltration.
- Red cell "ghosts" indicating the presence of intravascular haemolysis, most often associated with overwhelming bacterial infection (eg, Clostridium perfringens).

8.2 Serum LDH and haptoglobin

Two major tests used to diagnose the presence of haemolysis are lactate dehydrogenase (LDH), released from hemolyzed RBCs, and haptoglobin, which binds to haemoglobin released during intravascular or extravascular haemolysis or ineffective erythropoiesis with release of haemoglobin from late erythroid precursors in the bone marrow. Higher haptoglobin values in the presence of haemolysis can reflect either a lesser degree of haemolysis or concurrent inflammation, since haptoglobin is an acute phase reactant.

The combination of an increased serum LDH and a reduced haptoglobin is 90 percent specific for diagnosing haemolysis, while the combination of a normal serum LDH and a serum haptoglobin >25 mg/dL is 92 percent sensitive for ruling out haemolysis.

8.3 Reticulocyte count

The normal reticulocyte percentage is 0.5 to 1.5 percent. In patients with an otherwise intact bone marrow, the increase in erythropoietin production induced in a patient with hemolytic anaemia should raise the reticulocyte percentage above 4 to 5 percent. However, when the bone marrow is compromised (eg, following chemotherapy, infection, underlying marrow disease, cobalamin, folate, or iron deficiency), the reticulocyte response may be blunted or ablated.

8.4 Other tests

Other tests helpful in determining the presence or absence of haemolysis include:

Increased serum concentrations of indirect bilirubin from the catabolism of haemoglobin haem.

Increased mean corpuscular haemoglobin concentration (MCHC), indicating the presence of spherocytes.

Positive direct antiglobulin (Coombs') test in autoimmune hemolytic anaemia.

Tests for cold agglutinins or the Donath-Landsteiner antibody if symptoms are related to exposure to cold.

Testing for the presence of insoluble globin particles within the red blood cell (ie, Heinz bodies).

Increased blood concentration of carboxyhaemoglobin due to haemoglobin haem catabolism.

8.5 Testing for intravascular haemolysis

If intravascular haemolysis is suspected, the following additional tests are of value:

- Measurement of the PLASMA haemoglobin concentration (ie, testing for haemoglobinemia)
- Measurement of free haemoglobin in the urine supernatant (ie, testing for haemoglobinuria)
- Testing for hemosiderin in the urine sediment ≥ 7 days after the incident, allowing time for hemosiderin-containing tubular cells to be shed into the urine

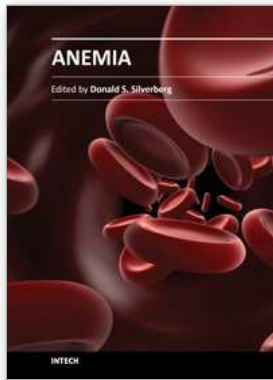
9. Conclusion

Anaemia is a frequent clinical finding, often leading to significant ill health and always requires prompt investigation and selective treatment.

By following a simple escalation pathway from history, examination and targeted investigations, a diagnosis can usually be made and effective treatment applied.

10. References

- Droogendijk J, et al, *Scand J Gastroenterol*. 2011 Jul 4.
- Gehrs BC, Friedberg RC., *Am J Hematol*. 2002 Apr;69(4):258-71.
- Goddard AF, James MW, McIntyre AS, Scott BB; on behalf of the British Society of Gastroenterology. *Gut*. 2011 Jun 6.
- Harrison's Principles of Internal Medicine*, 16th Edition.
- Mehta BC. Approach to a patient with anaemia. *Indian J Med Sci* 2004;58:26-9
- Nathan, DG, Oski, FA. *Hematology of Infancy and Childhood*, 4th ed, WB Saunders, Philadelphia, PA 1993.
- Pierce A, Nester T; for the Education Committee of the Academy of Clinical Laboratory Physicians and Scientists. *Am J Clin Pathol*. 2011 Jul;136(1):7-12.
- Powell N, McNair A. *Eur J Gastroenterol Hepatol*. 2008 Nov;20(11):1094-100.
- Stanley L Schrier, MD, *Uptodate.com*, Approach to the adult patient with anaemia,
- Stevens LA, Li S, Kurella Tamura M, et al, *Am J Kidney Dis*. 2011 Mar;57(3 Suppl 2):S9-16.
- Trifan A, Singeap AM, et al., *J Gastrointestin Liver Dis*. 2010 Mar;19(1):21-5.
- Vitale G, Fatti LM, et al. *J Am Geriatr Soc*. 2010 Sep;58(9):1825-7.



Anemia

Edited by Dr. Donald Silverberg

ISBN 978-953-51-0138-3

Hard cover, 440 pages

Publisher InTech

Published online 29, February, 2012

Published in print edition February, 2012

This book provides an up- to- date summary of many advances in our understanding of anemia, including its causes and pathogenesis, methods of diagnosis, and the morbidity and mortality associated with it. Special attention is paid to the anemia of chronic disease. Nutritional causes of anemia, especially in developing countries, are discussed. Also presented are anemias related to pregnancy, the fetus and the newborn infant. Two common infections that cause anemia in developing countries, malaria and trypanosomiasis are discussed. The genetic diseases sickle cell disease and thalassemia are reviewed as are Paroxysmal Nocturnal Hemoglobinuria, Fanconi anemia and some anemias caused by toxins. Thus this book provides a wide coverage of anemia which should be useful to those involved in many fields of anemia from basic researchers to epidemiologists to clinical practitioners.

How to reference

In order to correctly reference this scholarly work, feel free to copy and paste the following:

Vikrant Kale and Abdur Rahman Aftab (2012). Diagnostic Evaluation of Anaemia, Anemia, Dr. Donald Silverberg (Ed.), ISBN: 978-953-51-0138-3, InTech, Available from:
<http://www.intechopen.com/books/anemia/diagnostic-evaluation-of-anaemia>

INTECH
open science | open minds

InTech Europe

University Campus STeP Ri
Slavka Krautzeka 83/A
51000 Rijeka, Croatia
Phone: +385 (51) 770 447
Fax: +385 (51) 686 166
www.intechopen.com

InTech China

Unit 405, Office Block, Hotel Equatorial Shanghai
No.65, Yan An Road (West), Shanghai, 200040, China
中国上海市延安西路65号上海国际贵都大饭店办公楼405单元
Phone: +86-21-62489820
Fax: +86-21-62489821

© 2012 The Author(s). Licensee IntechOpen. This is an open access article distributed under the terms of the [Creative Commons Attribution 3.0 License](#), which permits unrestricted use, distribution, and reproduction in any medium, provided the original work is properly cited.