

Therapy of Hepatocellular Carcinoma with Iodine-131-Lipiodol

Hojjat Ahmadzadehfar^{1,*}, Amir Sabet¹,
Hans Jürgen Biersack¹ and Jörn Risse²

¹*Department of Nuclear Medicine, University Hospital Bonn*

²*Radiology and Nuclear Medicine Institute, Bad Honnef
Germany*

1. Introduction

Therapy in nuclear medicine practice has a long distinguished history. Nuclear medicine therapy is required to be highly specific and targeted, since it always involves administration of unsealed sources of radioactivity. Most therapy agents utilize β -particle emissions for their ability to penetrate tissues. This deposition of energy in tissue by β emitters results in cellular damage. Among the β emitters there are several choices with respect to energy of the β emission. Lower energy β particles can travel a few cell diameters, or at most in the sub-millimeter range. Higher energy β particles such as those emitted by Y-90 have an excellent tissue penetration with a range beyond the source of several millimeters. The physical half-life of the therapeutic radionuclide is an important consideration and underlying principle for therapy planning. Rarely, except in thyroid treatment, is the simple salt form of the radionuclide used. It is most likely attached to a drug or particle that controls its biodistribution. The ideal therapeutic radiopharmaceutical is one that remains attached to the parent drug or its metabolites, and is excreted rapidly through a known simple route¹.

For selected patients with HCC, confined to the liver but not amenable to resection or transplantation, both systemic and locoregional therapies can be considered. These include

1. Percutaneous interventions (ethanol injection, radiofrequency thermal ablation),
2. Transarterial interventions
 - a. Embolization (TAE), chemoperfusion (TAC), or chemoembolization (TACE),
 - b. Radioembolization (RE) or radioactive agent perfusion such as ¹³¹Iodine-Lipiodol or ¹⁸⁸RE-Lipiodol
3. External radiation therapy and
4. Chemotherapy, including gene and immune therapy.

In this chapter we focus only on the therapeutic indications, usefulness and methods of treatment with ¹³¹Iodine Lipiodol (¹³¹I-Lipiodol). Its rationale comes from the anatomical

* Corresponding Author

and physiological aspects of HCC being exploited for the delivery of the therapeutic agent. The liver has a dual blood supply: the hepatic artery and the portal vein. Observations on vascular supply to hepatic malignancies have demonstrated that metastatic hepatic tumours >3 mm derive in contrast to healthy hepatic cells 80-100% of their blood supply from the arterial rather than the portal hepatic circulation².

2. Basic characteristics of ¹³¹I-Lipiodol

¹³¹I is a beta emitting radionuclide with a physical half life of 8.04 days. The maximum and mean beta particle energies are 0.61MeV and 0.192MeV respectively. Additionally, ¹³¹I emits a principal gamma photon of 364 keV (81% abundance). The Beta radiation of ¹³¹I is responsible for its therapeutic effects while gamma radiation makes the distribution of the radiopharmaceutical visible.

Lipiodol is a mixture of iodized esters of poppy seed oil fatty acids used as a contrast medium for the detection of HCC which remains in these tumours for a longer period compared to normal liver or in other tissues. Isotopic exchange is used to label iodine-rich Lipiodol with ¹³¹I (Lipiodol[®], CIS Bio International/ member of IBA group). Lipiodol[®] is licensed in France for the treatment of patients with HCC and portal vein thrombosis (PVT)³. It was developed in the 1990s and was the first radiolabeled vector to be used in this setting. According to biodistribution data, more than 75% of the ¹³¹I-Lipiodol stays following the arterial administration in the liver and the remainder reaches the lungs⁴. Other tissues, including the thyroid gland, receive very little radiation.

An *in vitro* assessment ⁵ showed an unspecific uptake of Lipiodol in non-malignant endothelial cells apart from its concentration in cancer cell lines. Lipiodol alone does not appear to have any cytotoxic effect against any of the studied cell lines. However, ¹³¹I-Lipiodol is highly and only selectively cytotoxic for the cancer cell lines. Inability of tumorous cells unlike non-malignant ones to expel Lipiodol, revealed by quantification methods using computer-assisted image analysis, may further enhance the cytotoxic effect of ¹³¹I-Lipiodol in cancer cells. There is no separation of the ¹³¹I from Lipiodol during the uptake process by the cancer cells, as Lipiodol is a naturally iodinated oil compound with an iodine content of 38-40%. ¹³¹I-Lipiodol shows cytotoxic effects against the cancer cell lines even in doses as small as a quarter of the radioactivity of the ¹³¹I alone⁵.

The tumour/ non tumour uptake ratio is about 15-20:1 and increases with time, while the effective half life within the HCC tissue is also longer than that in healthy tissues (almost 6 days versus 4 days). Generally, more than 10 % of the injected Lipiodol remains within the tumour ⁶. The retention of ¹³¹I-Lipiodol in HCC tumours after intra-arterial infusion is related not only to embolization in the micro vessels of the tumour, but also to the entry into the interstitium and the tumour cells themselves. This retention can be assessed by tomodensitometric examination and inversely relates to the tumour size. Indeed, 88% of the HCCs smaller than 5 cm exhibit a high retention (of type 3 or 4 according to the criteria of Maki et al.) whereas 74% of the HCCs larger than 10 cm exhibit only a weak retention of less than 50% (of type 1 or 2 according to the criteria of Maki) ^{8,9}. Moreover, the clearance of Lipiodol from the tumour lasts longer than from the normal liver or from the lungs, possibly because of a lack of macrophagic cells in the tumour ³. ¹³¹I-Lipiodol is eliminated mainly

through the urinary tract, reaching 30–50% of the injected activity at day 8, but also to a small extent by way of the faeces (<3% at day 5) ⁴.

The required therapy activity for the intended tumour dose can be calculated for a given tumour mass according to its size. For instance producing 120 Gy in a tumour with a diameter of 1 cm requires less than 3 MBq I-131 while the same dose in a tumour with a fivefold larger diameter requires hundredfold more activity ¹⁰.

The radionuclide is supplied in 2 ml solution for injection and stored in a 4 ml cone shaped glass vial. The specific activity at calibration date is 1.1 GBq/ml and its shelf life from this time is 3 days ^{11,12}.

The conjunction of lipiodol with TACE, also called TOCA (transarterial oily chemoembolization), has also been used allowing the delivery of locally concentrated therapy due to the selective retention of the agent in the tumours for an extended period ¹³.

3. Basics of interventional nuclear medicine therapies of HCC with I131-Lipiodol

Radiation is tumoricidal if sufficient doses can be delivered selectively to the tumour without damaging adjacent normal tissue ¹⁴. Normal hepatocytes have a lower tolerance to the effects of radiation than neoplastic tissue. The dose required to destroy solid tumors, estimated at ≥ 70 Gy, is far greater than the liver tolerance dose of 35 Gy when delivered to the whole liver in 1.8 Gy/d fractions ¹⁵. If the whole liver is exposed to external-beam radiation at a mean radiation dose of 43 Gy, more than 50% of patients develop liver dysfunction ¹⁶. Conformal and stereotactic radiation therapy techniques can be used to deliver much higher radiation doses in cases with focal involvement ¹⁷; however, since primary neoplasms are often multifocal and irregular in shape and potentially replace large parts of the liver volume, only a small minority of patients are optimal candidates for such therapies ¹⁸. Internal radiation aims at improving the selectivity of the radiation by targeting the radioisotopes to the tumour cells. To achieve this targeting, the therapeutic radiopharmaceuticals such as ⁹⁰Y microspheres or ¹³¹I-Lipiodol may be administered via the hepatic artery ¹⁹.

Based on studies considering biodistribution of intraarterial ¹³¹I-Lipiodol in humans ^{4, 20, 21}, radiation doses for every mCi (37 MBq) of administered activity were estimated to be 31 cGy for the normal liver, 22 cGy for the lungs, and 239 cGy for a tumor with a greatest diameter of 4 cm using the formula:

$$\text{Dose (cGy)} = 73.8 \times E \times T_e \times \frac{A_0}{M} + 0.0346 \times \Gamma \times g \times \frac{A_0}{M}$$

where E is the average beta energy (MeV), T_e is the effective half-life (days), Γ is the specific gamma ray constant (cGy cm²/mCi hr), A_0 is the initial activity (μ Ci), M is the mass(g), and g is the geometric factor (cm).

4. Contraindications

Absolute contraindications

1. Pregnancy and breastfeeding, 2. life expectancy less than 1 month, 3. hepatic encephalopathy, 4. tumour Stage OKUDA III^{11,12}.

Relative contraindications

1. High extrahepatic tumor burden, 2. acute or severe chronic pulmonary disease, 3. The presence of contraindications for hepatic artery catheterisation ^{11,12}.

5. Therapeutic indications for 131I-Lipiodol

5.1 Palliative treatment of inoperable hepatocellular carcinoma

An improved survival rate is readily documented for those treated with 131I-Lipiodol, comparing to those receiving only medical support ²². The treatment is more effective for small, solitary and well encapsulated tumors and the response rate decreases with increasing tumor size. Its main limitation is its ineffectiveness in large (>5 cm) tumours. However, transarterial therapy with 131I-Lipiodol is superior to systemic therapy in tumours up to 5 cm in diameter²³.

The data on therapy efficacy have remained non-uniform. A decrease in tumour size has been reported in about 50 % to 60 % of patients; two early studies with seven and nine patients showed response in all tumours ^{24, 25}. In larger studies classifying therapy success according to the WHO criteria, the response rate decreases to about 30 % ²⁶. This is in agreement with our own data ²⁷. Reported response rates in different studies are summarised in table 1; only reports with more than ten patients, data on changes in tumour size and follow-up studies of at least one month, are considered.

First author, year, reference	Number of evaluable patients	CR	PR	MR	SD	PD	AFP decrease
Yoo 1991 ²⁹	24	0	3	5	8	8	13/16
Raoul 1992 ³⁰	30	0	18	4	6	2	22/29
Leung 1994 ³¹	22	1	3	-	12	6	13/25
Bhattacharya 1995 ³²	22	0	7	-	8	7	2/22
Raoul 1997 ²⁸	25	1	15	4	3	2	20/40
De Baere 1999 ²⁶	23	0	3	-	12	8	-
Risse 2000 ²⁷	13	0	2	3	4	4	-
Rindani 2002 ³³	12	0	6	-	5	1	5/7
Borbath 2005 ³⁴	19	1	0	-	7	11	2/24
Risse 2006 ³⁵	17	0	4	1	7	5	-
Boucher 2007 ³⁶	40	1	18	-	19	2	

CR: complete response, PR: partial response (tumour reduction > 50 %), MR: minimal response (tumor reduction between 25 and 50 %), AFP alpha-fetoprotein, SD: stable disease (tumour size change between -25 % - +25 %), PD: progressive disease (tumour increase > 25 %)

Table 1. Efficacy of 131I-Lipiodol therapy in patients with unresectable HCC

131I-Lipiodol is also comparatively favourable to other regional therapy procedures for palliative treatment of HCC. A multicentre randomised trial by Raoul et al²⁸ showed that 131I-Lipiodol therapy ($n=73$) was associated with a better patient tolerance and fewer vascular complications than TACE ($n=69$), although no survival advantage was demonstrated²⁸.

In a published study from our group 38 courses of intra-arterial 131I-Lipiodol therapy with a total activity up to 6.7 GBq were performed in 18 patients with HCC (6 with PVT)³⁵. Tumour volume decreased in 20/32 index nodules (63%) after the first course. Repeated therapy frequently resulted in further tumour reduction. Partial response was seen in 11 nodules while 4 nodules showed a minor response. Stable disease was found in 12 patients and progressive disease in 5. Significant response was associated with pre-therapeutic nodule volume up to 150 ml (diameter of 6.6 cm). Survival rate after 3, 6, 9, 12, 24 and 36 months was 78, 61, 50, 39, 17, and 6% respectively. Matched-pairs analysis of survival revealed 131I-Lipiodol to be superior to medical treatment. The most important side effect was a pancreatitis-like syndrome while overall tolerance was very acceptable.

The median survival in patients with unresectable HCC undergoing 131I-Lipiodol therapy has been reported between 7 and 27 months^{34, 36-38}. Chua et al reported the factors associated with survival in a newly published study including the AJCC stage (1-2 vs 3-4), Barcelona Clinic Liver Cancer stage (A-B vs C), Cancer of the Liver Italian Program score (< 2 vs >2), maximum tumor size (<4 vs >4 cm), extrahepatic disease, previous surgery and response to treatment (favorable vs unfavourable).³⁸ Considering response rate, AJCC stage 1-2 and Cancer of the Liver Italian Program score < 2 were found to be independent predictors for a favorable response in this study³⁸.

5.1.1 Palliative treatment of HCC with Portal vein thrombosis (PVT)

Although the PVT prohibits any attempt of TACE, 131I-Lipiodol has proved to be an effective therapy option in patients with HCC and PVT³⁹. Raoul et al. compared 131I-Lipiodol therapy and best supportive care in patients with HCC and PVT. The survival rates at 3, 6 and 9 mo was 71%, 48% and 7% for the treated group; and 10%, 0% and 0% for the group receiving only supportive care. The authors concluded that 131I-Lipiodol is a safe and effective palliative treatment of HCC in the presence of portal vein thrombosis²². However it should be noted that radioembolization (RE) with 90Y-Microspheres has proved to be a feasible alternative treatment for HCC patients with PVT as discussed in following section.

5.1.2 131I-Lipiodol versus radioembolisation with 90Y-Microspheres

90Y radioembolization (RE), or selective internal radiation therapy (SIRT), is a promising catheter-based liver-directed modality approved by the Food and Drug Administration for patients with primary and metastatic liver cancer⁴⁰. In a meta-analysis of 14 published articles Venti et al showed almost 80% any response ($AR = [CR + PR + SD]$) for a total of 325 patients with HCC. According to this meta-analysis, treatment with resin microspheres was associated with a significantly higher proportion of AR than with glass microsphere (0.89 vs 0.78 [$P < 0.02$])⁴¹.

Although RE is currently the preferred method for treating HCC compared to 131I-Lipiodol, its embolic nature makes severe liver dysfunction a theoretic contraindication for this

technique, as in TACE. In addition, techniques using ^{90}Y -labeled products tend to cost up to 10 times more than therapy with ^{131}I -Lipiodol ⁴², affecting the therapeutic approach especially in the countries with a poor insurance system.

PVT is not an absolute contraindication for RE any more. Although resin microspheres could pose the patient at risk for significant liver dysfunction based on the embolic treatment effect, therasphere has been shown to be safe even when the portal vein has been invaded by tumor¹⁴. However, recent studies describe safe performance of RE with resin microspheres even in PVT. There is no prospective study which compares these two methods (RE vs ^{131}I -Lipiodol) in patients with PVT in HCC considering response rate, time-to-progression, and survival.

5.1.3 ^{131}I -Lipiodol-therapy versus TAE and TACE

^{131}I -Lipiodol therapy in patients with cirrhosis and HCC has an efficacy similar to that of TACE/TAE therapy ^{28, 32, 42}. However ^{131}I -Lipiodol appears to be of more benefit in patients with advanced disease, for example, in those with Okuda stage III disease or BCLC stage D as well as in patients with PVT ⁴². PVT patients receiving ^{131}I -Lipiodol lived on average almost a year longer than those treated with TACE or TAE. Moreover, ^{131}I -Lipiodol is much better tolerated than chemoembolization, both in terms of clinically expressed side effects and arteriographic findings ²⁸.

5.2 Performing ^{131}I -Lipiodol as an adjuvant or neo-adjuvant therapy

Early intrahepatic recurrence is common after curative resection of hepatocellular carcinoma, frequently due to microscopic metastatic disease or less commonly, metachronous multicentric carcinoma within the liver remnant not detected before or during resection by conventional imaging ⁴³ and has led to attempts at adjuvant or neoadjuvant therapies.

5.2.1 ^{131}I -Lipiodol as an adjuvant therapy

It has been thought that when the postsurgical liver starts to regenerate, small microscopic daughter tumours can be stimulated to grow. If these were pre-cleared the chances of a recurrence would be lowered. Thus, ^{131}I -Lipiodol has been used in an adjuvant setting after curative surgical resection ⁴⁴. A single dose of 1.85 GBq ^{131}I -Lipiodol administered 6 weeks after curative resection of hepatocellular carcinoma could significantly decrease the rate of recurrence and increased disease-free and overall survival in a study by Lau et al. ⁴³. In their recent published paper the same authors confirmed their results after a longer follow up ⁴⁵. These findings were also confirmed by Boucher et al. administering 2.4 GBq ^{131}I -Lipiodol 8-12 weeks after surgery ⁴⁶. NG et. al.⁴⁷ also reported a good overall survival with 1.7 GBq ^{131}I -Lipiodol 1-8 months after surgery. It seems that there is no clinically significant adverse effect of adjuvant therapy by intra-arterial ^{131}I -Lipiodol after curative liver resection for HCC ⁴⁸. These results were also confirmed in a recent published study from Chua et. al. ⁴⁹. It is necessary to perform more randomized controlled trials with more patients to confirm the role of ^{131}I -Lipiodol as an adjuvant treatment especially considering the timing and the administered dose.

5.2.2 Neo-adjuvant 131I-Lipiodol administration before liver transplantation/resection

In a study by Raoul et. al⁵⁰ curative resection of hepatocellular carcinoma or liver transplantation was preceded by 2 injections of 2.4 GBq 131I-Lipiodol (5 weeks preoperative) to reduce intrahepatic recurrence. The procedure was well tolerated and associated with an objective tumour response in 56 % and a complete histological response in 24 % of 34 treated patients. An objective tumour response or necrosis of more than 90 % of the tumour mass was observed in three-quarters of these patients. Brans et. al. treated 10 HCC patients with almost 1.8 GBq 131I-Lipiodol in a pilot study followed by liver transplantation within 1-9 months⁵¹. The evidence of an anti-tumoural effect of 131I-Lipiodol was observed in 50% of patients. However, performing randomized comparisons between surgery alone *versus* surgery after intra-arterial injection of 131I-labelled Lipiodol in patients with large but technically resectable tumours is needed.

6. Imaging before performing the therapy

The work-up includes a three-phase contrast computed tomography (CT) and gadolinium-enhanced magnetic resonance imaging (MRI) of the liver for the assessment of tumour and non-tumour volume, portal vein patency, and the extent of extra-hepatic disease. Although FDG-PET is suitable for tumours showing high glucose metabolism such as colorectal carcinoma, melanoma, head and neck, and breast cancers, malignancies such as HCC or neuroendocrine tumours, except for their aggressive types show no or a very low-grade FDG uptake⁴⁰.

The suboptimal sensitivity of FDG-PET for the detection of HCC, ranging between 50% and 70% makes it an unsatisfactory imaging choice for the pre- and post-treatment evaluation in this group of patients; however, it adds valuable prognostic information (metabolic grading) as patients with a negative FDG-PET show a better prognosis than those with high FDG uptake. Choline PET/CT may also play a role in imaging of specific types of HCC in the near future^{40, 52-54}.

7. Intervention technique

Treatment with 131I-Lipiodol serves as an example for multidisciplinary management including the patient selection and care, the detailed anatomical study and dose calculation, the post-interventional treatment including timing and selection of systemic treatment, adequate follow-up of the patient as well as the management of possible complications. Prior to the therapy, patients should receive both written and verbal information about the procedure and the palliative nature of the treatment¹². The renal functional status should be adequate for the use of contrast agents during the pre-therapeutic angiogram. Haemodialysis patients may be treated with 131I-Lipiodol, however, dialysis has to be planned and timed before and after the intervention. Patients should be given a peri-interventional drug regimen with slow intravenous infusion of 24 mg dexamethasone and 8 mg ondansetron during the whole procedure and intraarterial injection of 50 mg pethidine immediately before application of the radiopharmaceutical. After blocking the thyroid with perchlorate, diagnostic angiography of the liver vessels should be performed with special attention to collateral arteries to other organs. Occasionally, computed tomography with arteriography (CT-AP) via the catheter could be added, partly with the injection of

small amounts of “cold” Lipiodol (Guerbet®). In patients with “normal” hepatic arterial anatomy the catheter can be positioned in the main hepatic artery for nonselective injection of ¹³¹I-Lipiodol. In cases with multiple nodules or variable arterial blood supply, the liver lobe containing the largest tumour mass is treated in the first session and the remaining masses in the following ones.

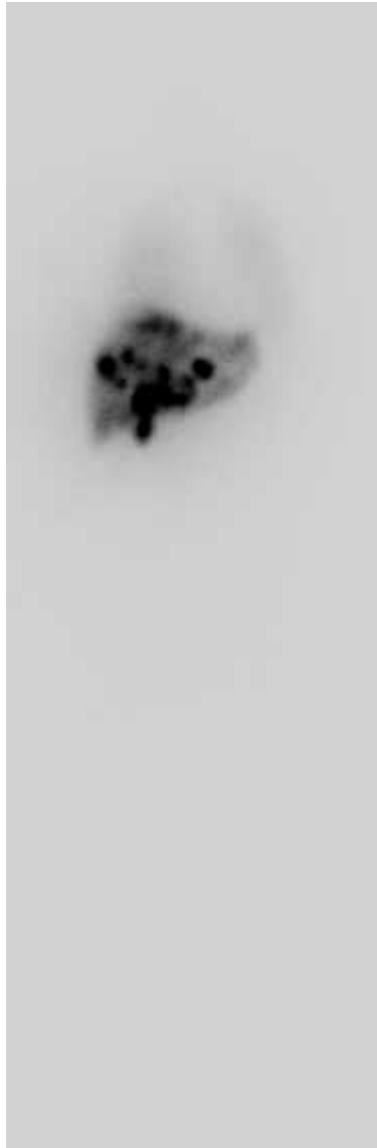

Fig. 1. Quantitative whole body scintigraphy obtained 7 days post therapeutic in a 52-year-old man showing significant activity in the HCCs and only a faint lung uptake.

¹³¹I-Lipiodol (2.22 GBq in 2 ml / ampulla) should be prepared in an appropriately ventilated cabinet in the department of Nuclear Medicine to avoid radioiodine aerosol inhalation. Injection should take at least some minutes to ensure good tolerance by the patient. The procedure and special radiation protection measures have been readily published in detail ⁵⁵. The applied activity should be determined as the difference between activity in the last receptacle before injection and the remaining activity of last receptacle and the catheter-system after flushing with saline. After the procedure the patients are transferred to the station and isolated until radiation exposure to their environment becomes low enough to be discharged (e.g in Germany < 1mSv/year) ³⁵.

Dexamethasone and tamoxifen could increase the tumoral uptake of Lipiodol and could be combined with ¹³¹I-Lipiodol to improve the therapy effectiveness ⁵⁶.

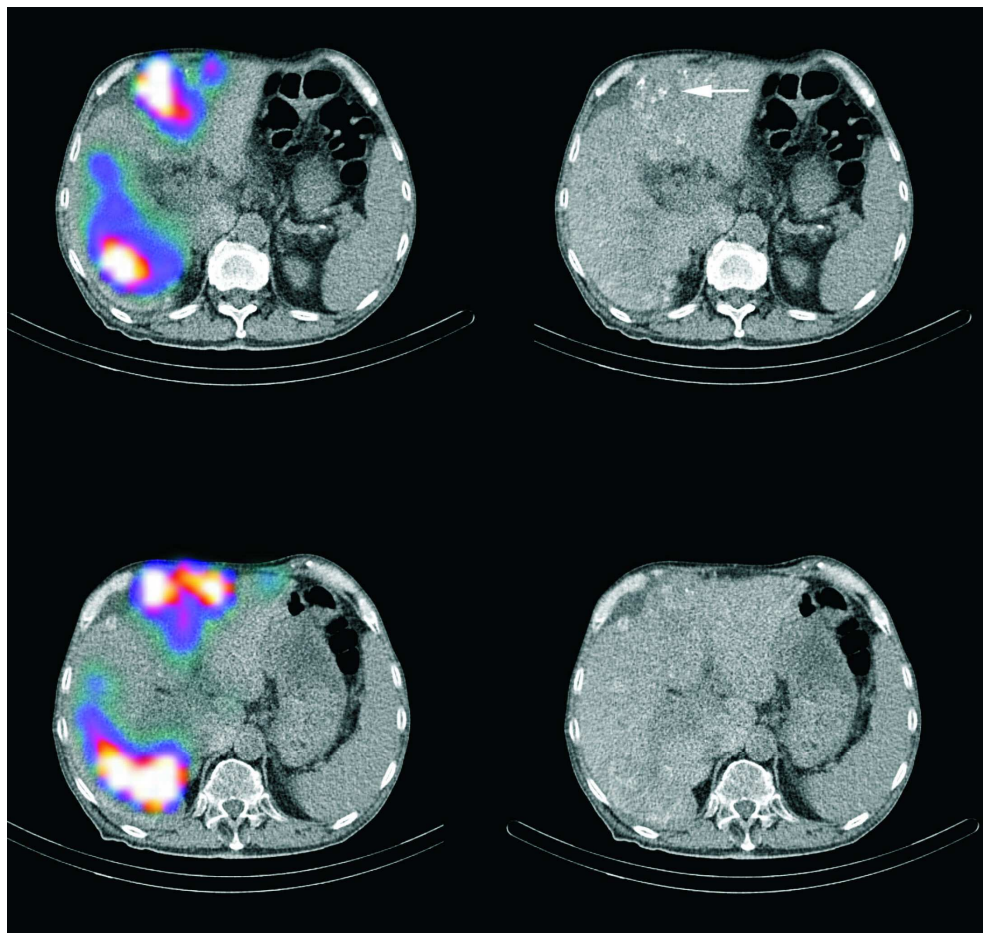


Fig. 2. SPECT/CT of the liver could be used for a better quantification of the radioactive distribution as well as dosimetry simultaneously. Note the distribution of ¹³¹I-Lipiodol in the HCCs showed with arrow.

For certain patients, in particular those presenting with a relatively large tumour several injections in 2-3 months interval may be necessary to obtain an effective response.

As Garin et. al. stated, nuclear medicine specialist receives an average dose between 140 and 443 μSv at the level of the fingers (according to the fingers) and about 17 μSv at the thorax. For the radiologists, the average doses received are 215 μSv and 15 μSv at the level of the fingers and at the thorax respectively. The authors showed that the administration of high therapeutic activities of ^{131}I -Lipiodol can be carried out with a dose much lower than the European regulatory limit of 500 mSv at the level of the fingers for the exposed personnel ⁵⁷.

8. Follow-up

Definitions of the appropriate length of the follow-up and the time points required for technical success are not well established and post treatment follow-up schedules vary depending on the treatment plan of each patient. For the evaluation of response, abdominal imaging should be performed 4 weeks and 2-3 months after each therapy ¹². Follow-up should be performed with the same modality used pre-therapeutic such as MRI, 3 phase CT, ^{18}F -FDG, ^{11}C -/ ^{18}F -Cholin or ^{11}C -/ ^{18}F -Acetate PET/CT. AFP should be tested for patients with initially increased AFP.

9. Dosimetry

Becker et al. performed a dosimetric evaluation using SPECT/CT ⁵⁸, applied to a series of 41 patients who received one or more injections of ^{131}I -Lipiodol for treatment of HCC using a standard activity of 2220 MBq. They found a mean tumoural absorbed dose of 248 ± 176 Gy for the first treatment, compared with 152 ± 122 Gy for the second treatment, and pointed out a correlation between the tumoural absorbed dose, calculated in tomographic mode, and morphological response to first treatment alone. These results pleaded in favour of increasing the administered activity at the first treatment. A tumoral absorbed dose of 280 Gy was found to represent an effective threshold absorbed dose. While 84% of the patients above this value were responders, no one appeared to respond at lower absorbed doses ⁵⁸. Tumour response adversely correlates with tumour size. High response rates have been found in tumour nodes with diameters below 6 cm in which an absorbed dose of up to 288 Gy has been calculated ^{25, 30, 59}. However, it must be considered that a reduction in tumour mass does not necessarily correlate with improved survival⁶.

10. Safety of ^{131}I -Lipiodol therapy

A phase I study ²⁴ and a multi centric phase II trial ³⁰ could not demonstrate any specific toxic effects of ^{131}I -Lipiodol. The main limiting factor was the long patient isolation required for the purpose of radioprotection. Consequently, a fixed injected activity of 2.2 GBq is proposed as a good compromise to achieve the desired efficacy while reducing the hospital stay to 1 week. Serious adverse effects are very rare. Undesirable effects observed fairly frequently consist of moderate and temporary fever (29%), moderate and temporary disturbances of the biological liver test (20%) and hepatic pain on injection (12.5%).

Moderate and reversible leukopenia (7%) and serious interstitial pneumopathies (2%) are observed more rarely ^{11, 12, 60}. Interstitial pneumonia has been reported in an estimated

prevalence of 15.5 cases per 1000 treated patients with a median respiratory symptoms delay of 30 days⁶¹.

Some authors have expressed their concern about hypothyroidism despite the very low thyroid uptake ⁶². Using potassium iodide premedication can significantly decrease thyroid iodide uptake and consequently probability of hypothyroidism ⁶³.

11. Conclusion

The effectiveness of 131I-Lipiodol treatment is proven both in the treatment of HCC with portal thrombosis and as an adjuvant to surgery after the resection of HCCs. It is at least as effective as chemoembolization and is tolerated much better. Severe liver dysfunction represents theoretic contraindication for radioembolization as well as for TACE. In such cases 131I-Lipiodol is an alternative therapy option especially in tumors smaller than 6 cm.


12. References

- [1] Eary J. Principles of Therapy with Unsealed Sources. In: Eary J, Brenner W, eds. *NUCLEAR MEDICINE THERAPY* 2007.
- [2] Lien WM, Ackerman NB. The blood supply of experimental liver metastases. II. A microcirculatory study of the normal and tumor vessels of the liver with the use of perfused silicone rubber. *Surgery*. Aug 1970;68(2):334-340.
- [3] Raoul JL, Boucher E, Rolland Y, Garin E. Treatment of hepatocellular carcinoma with intra-arterial injection of radionuclides. *Nat Rev Gastroenterol Hepatol*. Jan 2010;7(1):41-49.
- [4] Raoul JL, Bourguet P, Bretagne JF, et al. Hepatic artery injection of I-131-labeled lipiodol. Part I. Biodistribution study results in patients with hepatocellular carcinoma and liver metastases. *Radiology*. Aug 1988;168(2):541-545.
- [5] Al-Mufti RA, Pedley RB, Marshall D, et al. In vitro assessment of Lipiodol-targeted radiotherapy for liver and colorectal cancer cell lines. *Br J Cancer*. Apr 1999;79(11-12):1665-1671.
- [6] Risse JH, Menzel C, Grunwald F, Strunk H, Biersack HJ, Palmedo H. Therapy of hepatocellular cancer with iodine-131-Lipiodol. *Rom J Gastroenterol*. Jun 2004;13(2):119-124.
- [7] Maki S, Konno T, Maeda H. Image enhancement in computerized tomography for sensitive diagnosis of liver cancer and semiquantitation of tumor selective drug targeting with oily contrast medium. *Cancer*. Aug 15 1985;56(4):751-757.
- [8] Brans B, Bacher K, Vandevyver V, et al. Intra-arterial radionuclide therapy for liver tumours: effect of selectivity of catheterization and 131I-Lipiodol delivery on tumour uptake and response. *Nucl Med Commun*. Apr 2003;24(4):391-396.
- [9] Garin E, Bourguet P. Intra-arterial Therapy of Liver Tumours. In: Biersack HJ, Freeman LM, eds. *Clinical Nuclear Medicine*: Springer-Verlag Berlin Heidelberg; 2007:491-508.
- [10] Yoo HS, Park CH, Suh JH, et al. Radioiodinated fatty acid esters in the management of hepatocellular carcinoma: preliminary findings. *Cancer Chemother Pharmacol*. 1989;23 Suppl:S54-58.
- [11] Guidelines for 131I-ethiodised oil (Lipiodol) therapy. *Eur J Nucl Med Mol Imaging*. Mar 2003;30(3):BP20-22.

- [12] Giammarile F. EANM procedure guideline for the treatment of liver cancer and metastases with intra-arterial radioactive ligands. *23rd ANNUAL CONGRESS OF THE EUROPEAN ASSOCIATION OF NUCLEAR MEDICINE*. Vol Vienna2010:40-41.
- [13] Thomas MB, Jaffe D, Choti MM, et al. Hepatocellular carcinoma: consensus recommendations of the National Cancer Institute Clinical Trials Planning Meeting. *J Clin Oncol*. Sep 1 2010;28(25):3994-4005.
- [14] Salem R, Lewandowski R, Roberts C, et al. Use of Yttrium-90 glass microspheres (TheraSphere) for the treatment of unresectable hepatocellular carcinoma in patients with portal vein thrombosis. *J Vasc Interv Radiol*. Apr 2004;15(4):335-345.
- [15] Kennedy A, Nag S, Salem R, et al. Recommendations for radioembolization of hepatic malignancies using yttrium-90 microsphere brachytherapy: a consensus panel report from the radioembolization brachytherapy oncology consortium. *Int J Radiat Oncol Biol Phys*. May 1 2007;68(1):13-23.
- [16] Dawson LA, Normolle D, Balter JM, McGinn CJ, Lawrence TS, Ten Haken RK. Analysis of radiation-induced liver disease using the Lyman NTCP model. *Int J Radiat Oncol Biol Phys*. Jul 15 2002;53(4):810-821.
- [17] Greco C, Catalano G, Di Grazia A, Orecchia R. Radiotherapy of liver malignancies. From whole liver irradiation to stereotactic hypofractionated radiotherapy. *Tumori*. Jan-Feb 2004;90(1):73-79.
- [18] Murthy R, Nunez R, Szklaruk J, et al. Yttrium-90 microsphere therapy for hepatic malignancy: devices, indications, technical considerations, and potential complications. *Radiographics*. Oct 2005;25 Suppl 1:S41-55.
- [19] Ho S, Lau WY, Leung TW, Johnson PJ. Internal radiation therapy for patients with primary or metastatic hepatic cancer: a review. *Cancer*. Nov 1 1998;83(9):1894-1907.
- [20] Nakajo M, Kobayashi H, Shimabukuro K, et al. Biodistribution and in vivo kinetics of iodine-131 lipiodol infused via the hepatic artery of patients with hepatic cancer. *J Nucl Med*. Jun 1988;29(6):1066-1077.
- [21] Madsen MT, Park CH, Thakur ML. Dosimetry of iodine-131 ethiodol in the treatment of hepatoma. *J Nucl Med*. Jun 1988;29(6):1038-1044.
- [22] Raoul JL, Guyader D, Bretagne JF, et al. Randomized controlled trial for hepatocellular carcinoma with portal vein thrombosis: intra-arterial iodine-131-iodized oil versus medical support. *J Nucl Med*. Nov 1994;35(11):1782-1787.
- [23] Lau WY, Lai EC. Hepatocellular carcinoma: current management and recent advances. *Hepatobiliary Pancreat Dis Int*. Jun 2008;7(3):237-257.
- [24] Bretagne JF, Raoul JL, Bourguet P, et al. Hepatic artery injection of I-131-labeled lipiodol. Part II. Preliminary results of therapeutic use in patients with hepatocellular carcinoma and liver metastases. *Radiology*. Aug 1988;168(2):547-550.
- [25] Kobayashi H, Hidaka H, Kajiya Y, et al. Treatment of hepatocellular carcinoma by transarterial injection of anticancer agents in iodized oil suspension or of radioactive iodized oil solution. *Acta Radiol Diagn (Stockh)*. Mar-Apr 1986;27(2):139-147.
- [26] de Baere T, Taourel P, Tubiana JM, et al. Hepatic intraarterial I-131 iodized oil for treatment of hepatocellular carcinoma in patients with impeded portal venous flow. *Radiology*. Sep 1999;212(3):665-668.
- [27] Risse JH, Grunwald F, Kersjes W, et al. Intraarterial HCC therapy with I-131-Lipiodol. *Cancer Biother Radiopharm*. Feb 2000;15(1):65-70.
- [28] Raoul JL, Guyader D, Bretagne JF, et al. Prospective randomized trial of chemoembolization versus intra-arterial injection of I-131-labeled-iodized oil in the treatment of hepatocellular carcinoma. *Hepatology*. Nov 1997;26(5):1156-1161.

- [29] Yoo HS, Lee JT, Kim KW, et al. Nodular hepatocellular carcinoma. Treatment with subsegmental intraarterial injection of iodine 131-labeled iodized oil. *Cancer*. Nov 1 1991;68(9):1878-1884.
- [30] Raoul JL, Bretagne JF, Caucanas JP, et al. Internal radiation therapy for hepatocellular carcinoma. Results of a French multicenter phase II trial of transarterial injection of iodine 131-labeled Lipiodol. *Cancer*. Jan 15 1992;69(2):346-352.
- [31] Leung WT, Lau WY, Ho S, et al. Selective internal radiation therapy with intra-arterial iodine-131-Lipiodol in inoperable hepatocellular carcinoma. *J Nucl Med*. Aug 1994;35(8):1313-1318.
- [32] Bhattacharya S, Novell JR, Dusheiko GM, Hilson AJ, Dick R, Hobbs KE. Epirubicin-Lipiodol chemotherapy versus 131iodine-Lipiodol radiotherapy in the treatment of unresectable hepatocellular carcinoma. *Cancer*. Dec 1 1995;76(11):2202-2210.
- [33] Rindani RB, Hugh TJ, Roche J, Roach PJ, Smith RC. 131I lipiodol therapy for unresectable hepatocellular carcinoma. *ANZ J Surg*. Mar 2002;72(3):210-214.
- [34] Borbath I, Lhommel R, Bittich L, et al. 131I-Labelled-iodized oil for palliative treatment of hepatocellular carcinoma. *Eur J Gastroenterol Hepatol*. Sep 2005;17(9):905-910.
- [35] Risse JH, Rabe C, Pauleit D, et al. Therapy of hepatocellular carcinoma with iodine-131-lipiodol. Results in a large German cohort. *Nuklearmedizin*. 2006;45(4):185-192.
- [36] Boucher E, Garin E, Guyllygomarc'h A, Olivie D, Boudjema K, Raoul JL. Intra-arterial injection of iodine-131-labeled lipiodol for treatment of hepatocellular carcinoma. *Radiother Oncol*. Jan 2007;82(1):76-82.
- [37] Kanhere HA, Leopardi LN, Fischer L, Kitchener MI, Maddern GJ. Treatment of unresectable hepatocellular carcinoma with radiolabelled lipiodol. *ANZ J Surg*. May 2008;78(5):371-376.
- [38] Chua TC, Chu F, Butler SP, et al. Intra-arterial iodine-131-lipiodol for unresectable hepatocellular carcinoma. *Cancer*. Sep 1 2010;116(17):4069-4077.
- [39] Raoul JL, Boucher E, Roland V, Garin E. 131-iodine Lipiodol therapy in hepatocellular carcinoma. *Q J Nucl Med Mol Imaging*. Jun 2009;53(3):348-355.
- [40] Ahmadzadehfar H, Biersack HJ, Ezziddin S. Radioembolization of liver tumors with yttrium-90 microspheres. *Semin Nucl Med*. Mar 2010;40(2):105-121.
- [41] Vente MA, Wondergem M, van der Tweel I, et al. Yttrium-90 microsphere radioembolization for the treatment of liver malignancies: a structured meta-analysis. *Eur Radiol*. Apr 2009;19(4):951-959.
- [42] Marelli L, Shusang V, Buscombe JR, et al. Transarterial injection of (131)I-lipiodol, compared with chemoembolization, in the treatment of unresectable hepatocellular cancer. *J Nucl Med*. Jun 2009;50(6):871-877.
- [43] Lau WY, Leung TW, Ho SK, et al. Adjuvant intra-arterial iodine-131-labelled lipiodol for resectable hepatocellular carcinoma: a prospective randomised trial. *Lancet*. Mar 6 1999;353(9155):797-801.
- [44] Buscombe JR. Interventional nuclear medicine in hepatocellular carcinoma and other tumours. *Nucl Med Commun*. Sep 2002;23(9):837-841.
- [45] Lau WY, Lai EC, Leung TW, Yu SC. Adjuvant intra-arterial iodine-131-labeled lipiodol for resectable hepatocellular carcinoma: a prospective randomized trial-update on 5-year and 10-year survival. *Ann Surg*. Jan 2008;247(1):43-48.
- [46] Boucher E, Bouguen G, Garin E, Guillygomarch A, Boudjema K, Raoul JL. Adjuvant intraarterial injection of 131I-labeled lipiodol after resection of hepatocellular carcinoma: progress report of a case-control study with a 5-year minimal follow-up. *J Nucl Med*. Mar 2008;49(3):362-366.

- [47] Ng KM, Niu R, Yan TD, et al. Adjuvant lipiodol I-131 after curative resection/ablation of hepatocellular carcinoma. *HPB (Oxford)*. 2008;10(6):388-395.
- [48] Partensky C, Sassolas G, Henry L, Paliard P, Maddern GJ. Intra-arterial iodine 131-labeled lipiodol as adjuvant therapy after curative liver resection for hepatocellular carcinoma: a phase 2 clinical study. *Arch Surg*. Nov 2000;135(11):1298-1300.
- [49] Chua TC, Saxena A, Chu F, et al. Hepatic resection with or without adjuvant iodine-131-lipiodol for hepatocellular carcinoma: a comparative analysis. *Int J Clin Oncol*. Nov 9 2010.
- [50] Raoul JL, Messner M, Boucher E, Bretagne JF, Campion JP, Boudjema K. Preoperative treatment of hepatocellular carcinoma with intra-arterial injection of 131I-labelled lipiodol. *Br J Surg*. Nov 2003;90(11):1379-1383.
- [51] Brans B, De Winter F, Defreyne L, et al. The anti-tumoral activity of neoadjuvant intra-arterial 131I-lipiodol treatment for hepatocellular carcinoma: a pilot study. *Cancer Biother Radiopharm*. Aug 2001;16(4):333-338.
- [52] Kwee SA, DeGrado TR, Talbot JN, Gutman F, Coel MN. Cancer imaging with fluorine-18-labeled choline derivatives. *Semin Nucl Med*. Nov 2007;37(6):420-428.
- [53] Talbot JN, Gutman F, Fartoux L, et al. PET/CT in patients with hepatocellular carcinoma using [(18)F]fluorocholine: preliminary comparison with [(18)F]FDG PET/CT. *Eur J Nucl Med Mol Imaging*. Nov 2006;33(11):1285-1289.
- [54] Yamamoto Y, Nishiyama Y, Kameyama R, et al. Detection of hepatocellular carcinoma using 11C-choline PET: comparison with 18F-FDG PET. *J Nucl Med*. Aug 2008;49(8):1245-1248.
- [55] Risse JH, Ponath C, Palmedo H, Menzel C, Grunwald F, Biersack HJ. Radiation exposure and radiation protection of the physician in iodine-131 Lipiodol therapy of liver tumours. *Eur J Nucl Med*. Jul 2001;28(7):914-918.
- [56] Becker S, Ardisson V, Lepareur N, et al. Increased Lipiodol uptake in hepatocellular carcinoma possibly due to increased membrane fluidity by dexamethasone and tamoxifen. *Nucl Med Biol*. Oct 2010;37(7):777-784.
- [57] Garin E, Laffont S, Rolland Y, et al. Safe radiation exposure of medical personnel by using simple methods of radioprotection while administering 131I-lipiodol therapy for hepatocellular carcinoma. *Nucl Med Commun*. Jun 2003;24(6):671-678.
- [58] Becker S, Laffont S, Vitry F, et al. Dosimetric evaluation and therapeutic response to internal radiation therapy of hepatocarcinomas using iodine-131-labelled lipiodol. *Nucl Med Commun*. Sep 2008;29(9):815-825.
- [59] Lui WY, Liu RS, Chiang JH, et al. Report of a pilot study of intra-arterial injection of I-131 lipiodol for the treatment of hepatoma. *Zhonghua Yi Xue Za Zhi (Taipei)*. Sep 1990;46(3):125-133.
- [60] Lambert B, Van de Wiele C. Treatment of hepatocellular carcinoma by means of radiopharmaceuticals. *Eur J Nucl Med Mol Imaging*. Aug 2005;32(8):980-989.
- [61] Jouneau S, Vauleon E, Caulet-Maugendre S, et al. 131I-Labeled Lipiodol-Induced Interstitial Pneumonia: A Series of 15 Cases. *Chest*. Oct 14 2010.
- [62] Toubeau M, Touzery C, Berriolo-Riedinger A, et al. 131I thyroid uptake in patients treated with 131I-Lipiodol for hepatocellular carcinoma. *Eur J Nucl Med*. May 2001;28(5):669-670.
- [63] Bacher K, Brans B, Monsieurs M, De Winter F, Dierckx RA, Thierens H. Thyroid uptake and radiation dose after (131)I-lipiodol treatment: is thyroid blocking by potassium iodide necessary? *Eur J Nucl Med Mol Imaging*. Oct 2002;29(10):1311-1316.



Hepatocellular Carcinoma - Clinical Research

Edited by Dr. Joseph W.Y. Lau

ISBN 978-953-51-0112-3

Hard cover, 330 pages

Publisher InTech

Published online 02, March, 2012

Published in print edition March, 2012

This book covers the clinical aspects of hepatocellular carcinoma. This book is a compendium of papers written by experts from different parts of the world to present the most up-to-date knowledge on the clinical aspects of hepatocellular carcinoma. This book is divided into three sections: (I) Diagnosis / Differential Diagnosis; (II) Surgical Treatment; (III) Non-surgical Treatment. There are 19 chapters covering topics from novel diagnostic methods to hepatic lesions mimicking hepatocellular carcinoma, from laparoscopic liver resection to major hepatectomy without allogeneic blood transfusion, from molecular targeted therapy to transarterial radioembolization, and from local ablative therapy to regional therapy. This volume is an important contribution to the clinical management of patients with hepatocellular carcinoma. The intended readers of this book are clinicians who are interested in hepatocellular carcinoma, including hepatologists, liver surgeons, interventional and diagnostic radiologists, pathologists and epidemiologists. General surgeons, general physicians, trainees, hospital administrators, and instruments and drug manufacturers will also find this book useful as a reference.

How to reference

In order to correctly reference this scholarly work, feel free to copy and paste the following:

Hojjat Ahmadzadehfar, Amir Sabet, Hans Jürgen Biersack and Jörn Risse (2012). Therapy of Hepatocellular Carcinoma with Iodine-131-Lipiodiol, Hepatocellular Carcinoma - Clinical Research, Dr. Joseph W.Y. Lau (Ed.), ISBN: 978-953-51-0112-3, InTech, Available from: <http://www.intechopen.com/books/hepatocellular-carcinoma-clinical-research/therapy-of-hepatocellular-carcinoma-with-iodine-131-lipiodiol>

INTECH
open science | open minds

InTech Europe

University Campus STeP Ri
Slavka Krautzeka 83/A
51000 Rijeka, Croatia
Phone: +385 (51) 770 447
Fax: +385 (51) 686 166
www.intechopen.com

InTech China

Unit 405, Office Block, Hotel Equatorial Shanghai
No.65, Yan An Road (West), Shanghai, 200040, China
中国上海市延安西路65号上海国际贵都大饭店办公楼405单元
Phone: +86-21-62489820
Fax: +86-21-62489821

© 2012 The Author(s). Licensee IntechOpen. This is an open access article distributed under the terms of the [Creative Commons Attribution 3.0 License](#), which permits unrestricted use, distribution, and reproduction in any medium, provided the original work is properly cited.