

The Most Important Local and Regional Treatment Techniques of Hepatocellular Carcinoma and Their Effect over a Long Term Overall Survival

Federico Cattin, Alessandro Uzzau and Dino De Anna
*Department of General Surgery, University of Udine School of Medicine
Italy*

1. Introduction

During the last years, many local and regional techniques have been introduced, helping, together with surgery, to treat the hepatocellular carcinoma, and contributing to an important improvement of disease free survival and overall survival of patients affected by this disease. These techniques, suitable also for metastatic lesions, can be performed as exclusive ones or following surgery, and help controlling tumor progression even when it is over any possible surgical approach.

Local and regional therapies can be divided into two groups: in the first one we can consider the techniques using heat to obtain their effect, in the second one we consider those using chemotherapeutic drugs to obtain necrosis of the neoplastic tissue. Necrosis can be obtained through the energy produced by radiofrequency probes, through the alcohol or acetic acid injection or through the injection of embolyzing substances, also together with chemotherapeutic drugs, into the hepatic artery. Last but not least, the injection of yttrium labeled microspheres is available. These are injected into the hepatic artery and are able to cytoreduce the tumor through a local irradiation.

2. Description

The most important techniques nowadays available are:

2.1 Percutaneous ethanol injection

This is the oldest technique, and it consists in the percutaneous injection of absolute ethanol into the lesion using a fine needle provided with one or more infusion holes. Ethylic alcohol is able to induce a neoplasm coagulative necrosis through cellular dehydration and protein denaturing. Moreover, it causes vascular thrombosis with occlusion of the small vessels which normally feed the tumor. This is a feasible technique for small lesions under 2 centimeters of diameter. Considering these lesions, ethanol has demonstrated its ability to induce a necrosis of more than 95 % of the tumor volume. This result is absolutely similar to

the one obtained with more recent techniques like radiofrequency ablation, which on the contrary gets better results if used on bigger nodules. In facts, in case of lesions 2-5 cm of diameter, PEI is able to produce a necrosis of just 50% of the neoplasm volume, and this percentage becomes inessential in case of even bigger cancers. On the contrary, even today PEI grants a curability percentage similar to that given by radiofrequency or advanced percutaneous techniques if we consider little HCCs.

Difficulties shown by PEI in treating medium and big lesions are characteristic of the injected drug: ethanol is not able to diffuse equally into the tumor, as it can not degrade the fibrous septa which are diffused into the nodule. In a 33% of cases these septa may cause a variable distribution of the drug in the lesion, and then a higher risk of relapse of disease. Moreover, big nodules are often well supplied of blood, and also blood circulation may determine a rapid ethanol wash out from the injected site, lowering the therapeutic effect of PEI. Even if PEI is a ultrasound-guided technique, the needle might be inserted in the peripheral part of the nodule, and then its farthest zones might not receive an adequate concentration of drug. In the end, percutaneous ethanol injection has a limited diffusion outside the lesion, and then it's not amenable to grant an adequate volume of oncologic safety based on healthy hepatic tissue around the tumor. This area has normally the highest probability to hide satellite nodules^{1,2,3}.

Percutaneous ethanol injection is a safe technique, easy, usually well tolerated and feasible also under local anesthesia in outpatients. Sometimes some sessions of therapy are required to achieve a positive oncologic result: most of the protocols schedule eight sessions, once or twice a week, for a whole amount of one or two months of treatment. Complications are linked to the particular kind of technique and to the treated organ: hepatic hematomas, hemoperitoneum, and alcohol diffusion in the blood vessels are the most probable of them, anyhow they are rare and easy to control. Worse complications are described in the Literature in a 0-2% of cases. Among them the tumor seeding along the needle path is included, and this event may happen during all the percutaneous treatments of neoplasm lesions^{1,4}.

3 years and 5 years survival after exclusive treatment are respectively 22% and 0%

2.2 Percutaneous acetic acid injection

Technically similar to the previous, acetic acid is able to enter easily into the cells, dissolve its lipids and destroy collagen. Acetic acid is used in a solution, and its efficacy rises as its concentration rises, until a plateau is reached when the concentration of drug is about 50%. This level has been defined during studies on mice, the exact one in humans has never been detected. Acetic acid has a cytotoxic effect three times higher than ethanol, and this is the reason why it reaches the same therapeutic result needing a lower number of sessions, improving patient's comfort and minimizing the risk of complications. PAI is in the end useful also for bigger lesions than those treated with PEI, as acetic acid spreads into the nodule through the collagen destruction^{1,3}.

In spite of these qualities, PAI is nowadays almost abandoned, turning to the advantage of modern techniques. There are many reasons for this: a remarkable risk of toxicity for intravascular diffusion of acid, considerably higher than the one linked to ethanol, risk of

tumor seeding along the needle path⁴, high level of pain (higher than the one linked to PEI) and then all the risks linked to the puncture of a high vascularized parenchyma, like the hepatic one, typical of every percutaneous treatment.

Percutaneous acetic acid injection seems more effective than PEI under a therapeutic point of view: the low pH characteristic of the acid is able to destroy any septum into the nodule, and so tumor necrosis is more homogeneous and safe. For this reason, PAI is healing as much as PEI and radiofrequency ablation if we consider small volume lesions, granting percentages of necrosis close to 95% if nodules are less than 2 cm of diameter^{5,6}. In this case and in selected groups disease free survival rate is 100% and 92% respectively at 1 and 2 years (Ohnishi et al.), noticeably higher than the one linked to PEI.

3 years and 5 years survival, on the contrary, after exclusive treatment are respectively 40% and 0%⁶.

2.3 Radiofrequency ablation

Radiofrequency ablation is a technique that induces tissue necrosis through cellular dehydration following a local heat growth. During this procedure, the patient is a part of a real and proper electric circuit, which comprises a generator, a needle to be inserted into the neoplasm, a wide surface plate to be used as an electric outflow, and of course patient's tissues. Heat growth is directly depending on tissue impedance against electric flow, measured in Ohm: as it is quite high, in the immediate surroundings of the entry point into the patient (the needle) a frictional verifiable thermic increase develops. It causes a coagulative necrosis of treated tissues, with a curative effect. Radiofrequency waves swing between 300 KHz and 2500 MHz, and the amount of necrotized tissue is depending on the heat, the time of exposure and the needle caliber.

A key point for a good radiofrequency procedure is the possibility to control the level of temperature reached during the treatment. In facts, a 55 degrees local temperature, kept for 4-6 minutes, is able to cause an irreversible cellular damage and then apoptosis. A 60-100 degrees local temperature causes an immediate tissue coagulation, as like as the one caused by an electrical scalpel during hemostasis, and then a mythochondrial and cytoplasmic enzymes damage, with a sudden cellular death. A temperature over 100 degrees induces tissue vaporization and carbonization⁵.

These different reactions must be considered under the point of view of the different ability damaged tissues have to transmit electricity. At a first time a neoplastic carbonization might seem a valid and final result, but it's fundamental to consider that a carbonized tissue has a higher resistance to electric flow than a damaged or healthy one, and then it provides a protective effect to the surrounding structures, which are shielded from any electric exposure. This is the reason why the technique is ineffective if a tissue carbonization happens around the needle.

The system allows to control the temperature reached into the area under treatment, thus avoiding this event. The temperature effective to treatment ranges between 55 and 100 degrees. Needles contain a probe, and any thermic growths are recognized through the continuous measurement of system impedance, direct function of heat growth and tissue change of state. In case of growth, this may be controlled through reducing the energy given

to the patient. Due to this, the complete time of treatment might grow up from 4-6 minutes. In our clinical experience, the medium length is about 10-12 minutes, but in some centers sessions lasting up to 30 minutes are performed.

Radiofrequency ablation therapy is a good option in hepatocellular carcinomas either alone, or in combination with surgery, and, even having different technical principles, it is a valid and modern alternative to percutaneous ethanol injection. It is able to reach the same results even through a lower number of treatment sessions, also for lesions more than 2 centimeters of diameter, or metastatic. Especially in these cases this technique has its best advantages in comparison to PEI, and represents a step forward in comparison to other percutaneous procedures.

Using a single needle, the volume of treated hepatic tissue is quite narrow, about 1.8 cm³. This volume may be enhanced using more powerful generators and needles chilled with saline, which allows a tissue impedance reduction and a growth of heat diffusion and energy delivery. Then, the use of multiple needles or single hooked needles is possible^{5,7}.

Using these devices, the treated volume may rise up to 3 cm³ and over. It's better in any case to use a single hooked needle, as it grants a similar treated volume if compared to multiple needles, but it has a bigger treatment evenness.

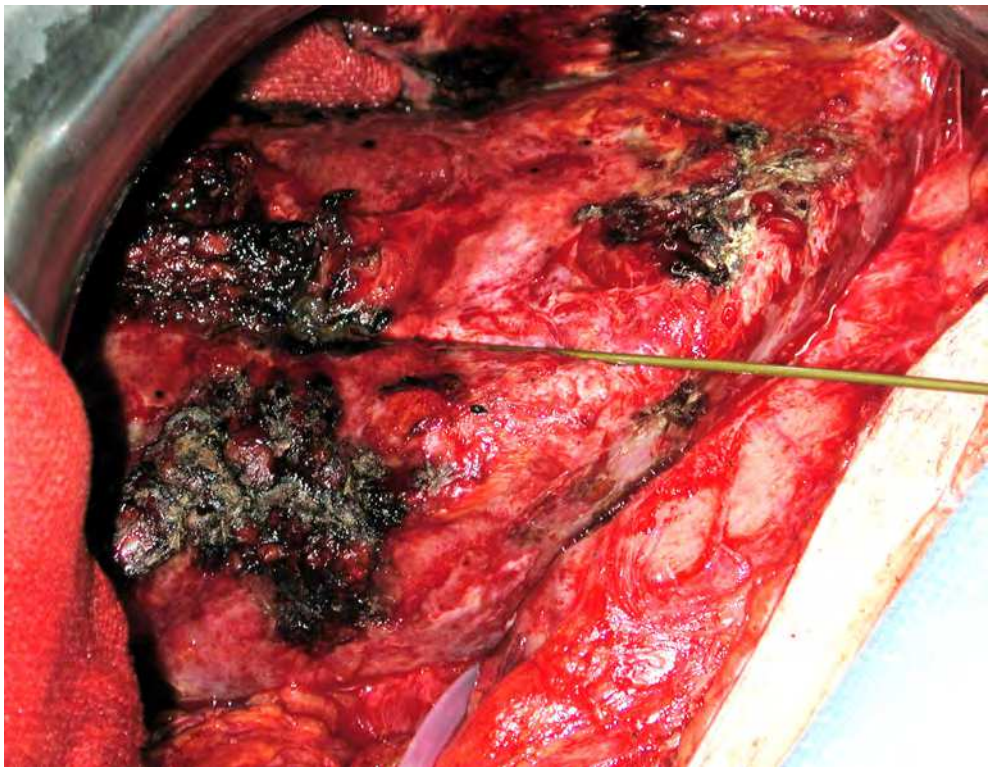


Fig. 1. Radiofrequency over resected liver

Radiofrequency is a versatile technique. It may be provided as an exclusive treatment, through percutaneous needle insertion, or it may follow surgery during an operation as a way to treat satellite lesions or to eliminate metastatic liver nodules during non hepatic surgery. Radiofrequency ablation as an exclusive technique may be provided under local anesthesia or conscious sedation. In some centers radiofrequency is used during surgery as a way to treat the surgical resection surface: it allows a coagulative necrosis of surface cells, thus providing a bigger oncologic safety than that obtained through resection itself.

Radiofrequency has a number of possible complications, linked to the needle insertion into the nodule and to the necrosis following the treatment. Complications described in Literature are, in order of probability, hepatic hematomas or hemoperitoneum needing blood supply, hepatic abscesses caused by necrosis infection and needing percutaneous drainage, thermic bile duct damages needing biliary drainage, hemothoraxes, bowel perforations caused by needle mispositioning, necrosis of organs close to liver due to thermic damage (especially when treating superficial liver lesions), hepatic failure. Neoplastic seeding along the needle path is quite high as a risk (about 2% of procedures), but it can be avoided keeping the system working during the needle extraction, and then performing a real and proper radiofrequency ablation over the tissues which have been in contact to the needle itself. To reach a good result, a temperature of about 75 degrees is important.

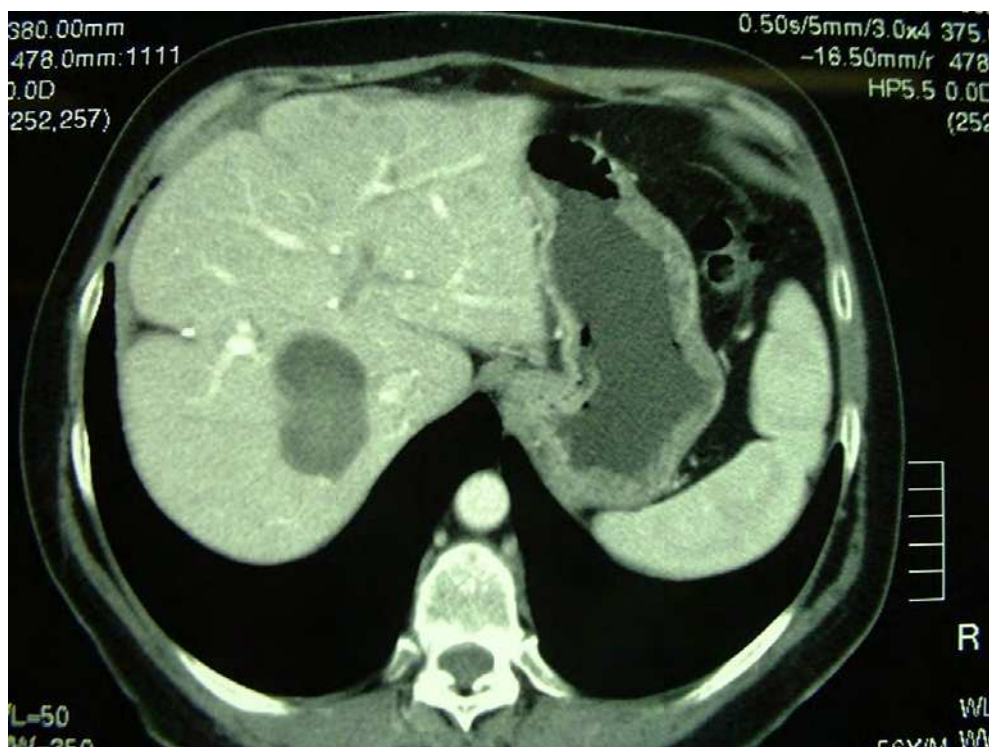


Fig. 2. A typical lesion suitable for radiofrequency during surgery

The strongest limit of this procedure is the presence of blood vessels more than 5 mm of diameter nearby the target lesion. Vessels can reduce the treatment efficacy through heat loss, and may be impossible to reach the 55 degrees temperature mandatory for the technique to be effective. Moreover, even if it's more effective than the previously described techniques, also radiofrequency is affected by the presence of collagen septa into the nodules: even if it's true that heat can destroy collagen, these septa can shield the tissue behind them from thermic effects. This is the reason why it's always impossible to predict the exact final amount of treated volume.

In the end, the only possibility to be certain to avoid any tumor relapse is to be sure to have destroyed every neoplastic cell. This is of course impossible. Heat damage induces the production of tissue growth factors by the cells surrounding the damaged ones, and these substances are the most important factors of disease relapse if any tumor cell survived the

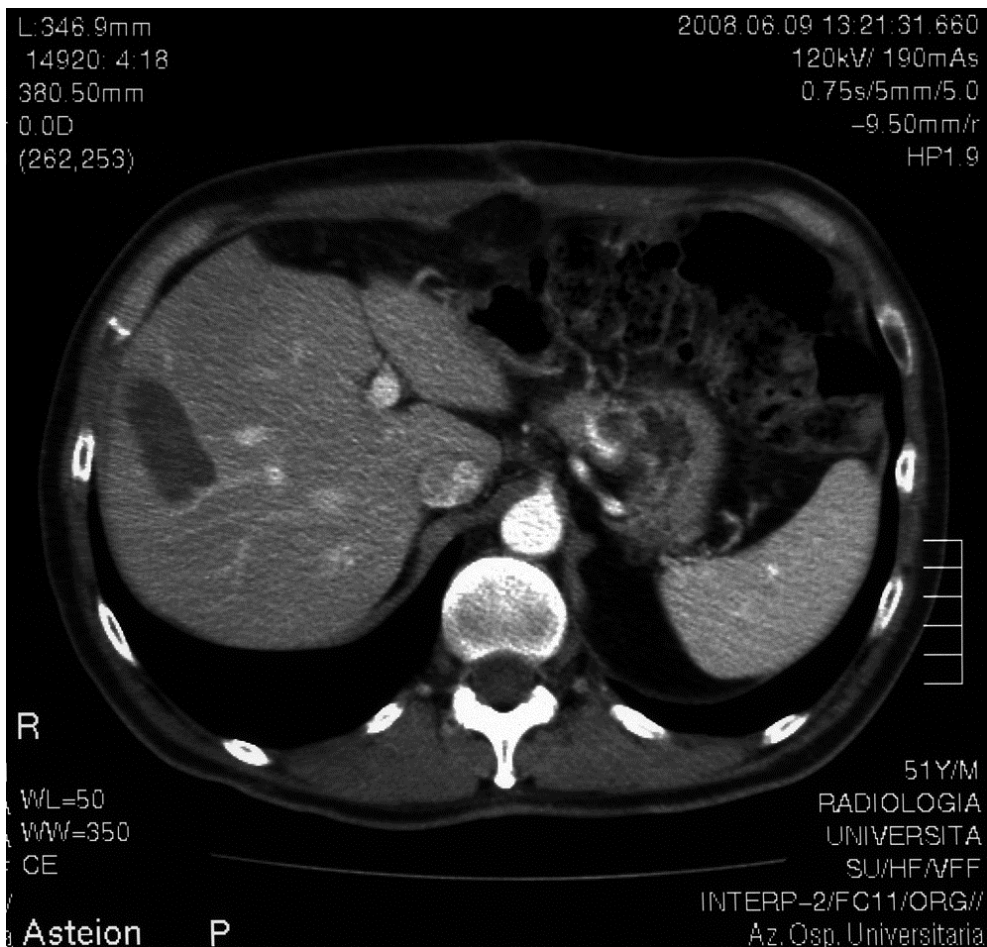


Fig. 3. A lesion suitable for percutaneous radiofrequency

procedure. This is the reason why 3 and 5 years survival rates after exclusive treatment are, respectively, 56-83% and 40-52%. Anyways, these rates are similar to surgical ones in case of surgery following disease relapse. This is the reason why, in these cases, nowadays radiofrequency ablation is a valid exclusive treatment⁸.

2.4 Cryotherapy

It consists in positioning a cryogenic probe into the nodule and then in its freezing up to a temperature between -100 and -196 degrees by using liquid nitrogen. The procedure lasts about 15 minutes until the tumor and healthy surrounding tissue frostbite is reached, through the development of cytoplasmic ice crystals, the cellular volume growth and the break of cytoplasmic membranes. Cold as a therapeutic agent against hepatocellular carcinoma makes also use of a particular cellular response to temperature decrease: cryoablation is able to inhibit cellular growth by stimulating a sort of cryoimmunity and by producing cytokines activating the natural killer cells, able to control tumor proliferation. This activation, typical of cryotherapy, is not visible in any other therapy against HCC.

Cryotherapy allows to visualize with millimetric precision the limit between treated area and surroundings during routine radiologic controls. Low temperature action in facts is extremely zone-specific, and as it grows over the freezing limit for hepatic cells, it's possible to meet healthy tissue, not damaged and well distinguishable from the treated area. So knowing exactly how much volume has been treated allows to plan possible further procedures.

Cryotherapy, very promising, is now performed in the operatory room as a surgical time during hepatic resection. This is due to the dimension of probes, bigger than those of radiofrequency ablation. Technical evolution has brought to project and production of thinner probes, available for percutaneous use. This could make this technique available also for non-surgical patients in the immediate future⁹.

Any of the two different approaches has of course pros and cons. Cryotherapy during surgery is made considering the possibility to explore all the parts of the abdomen and of the liver, looking for satellite nodules. Then, it's possible the exact positioning of the probe into the tumor, even if it is in areas not reachable through percutaneous puncture or close to other organs. Percutaneous cryotherapy is possible also for outpatients, allows a rapid recovery and an easy pain control. Percutaneous treatment requires two therapy sessions^{9,10}.

A real comparison between cryotherapy and the most used percutaneous technique - radiofrequency - is difficult to be done. The most important reason is the fact that nowadays radiofrequency is performed mostly as an exclusive and percutaneous technique, while cryotherapy is still a therapeutic option during surgery. Anyways, there is a number of capabilities which might make it even more effective once reached an adequate technical ability. First, cryotherapy induces the production of a group of cytokines inhibiting cellular growth, while radiofrequency induces the production of substances stimulating the relapse of disease. Second, cryotherapy shows an exact limit between treated and non-treated areas, and then allows to control the adequacy of treatment, while radiofrequency creates a shaded border. Third, during cryotherapy it's possible to verify, using ultrasounds, the blistering of ice crystals, and then assess the efficacy of therapy. Fourth, the procedure can be performed using multiple needles, without modifying the shape of the treated volume.

The most important complications typical of this procedure are the same of all the other percutaneous techniques. Using smaller probes than those used during intra-operative approach (about 3.5 mm of diameter) has minimized the worst complication following cryotherapy, which is the rupture of the frozen area and then the following bleeding. Even if this event is possible after any cryogenic probe insertion, the probability of it is directly proportional to the dimension of the used needles. Another complication is the local and systemic thermic shock, with MOF and disseminated intravascular coagulation. In Literature this event has a risk of 1% of incidence using the old needles, close to 0% using the new smaller ones.

As this is a new technique, and as it is now performed during surgery, it's difficult to provide survival rates linked to its exclusive use. Anyways, in the Literature some Authors show a 3 years survival of about 35%¹¹.

2.5 Chemoembolization (TACE)

This technique is performed through puncture of the common femoral artery and retrograde reach of a selected branch of the hepatic artery, or percutaneously through puncture of an infuse-a-port previously inserted into the right vessel. It consists in injecting resin microspheres linked to a chemotherapeutic drug (a cocktail of Mitomycin C, Adriamycin and Cisplatinum) or alone (in this case is correct to call the procedure not chemoembolization but only "embolization"). These spheres close the artery which provides blood to the liver volume in which there is the tumor. Occlusion causes an ischemic necrosis of the nodule and of the healthy surrounding tissue, and the presence of the chemotherapeutic drugs allows a lasting treatment. This technique is indicated especially for multifocal neoplasms, normally more than four nodules, but is useful also for a lower number of big lesions, or in any case of non surgical disease¹².

The possibility of using TACE for treatment of all the non surgical patients makes it good for those who would have a light risk of liver failure in case of surgery, and this is the reason why this technique is a good option for all the Child B and C patients. More indications are the absence of vascular and periepic infiltration and no extra-hepatic spread of disease. In all these cases, also according to the BCLC score, chemoembolization might be considered as a first line treatment for hepatocellular carcinoma.

During the first therapeutic trials, in order to gain a complete treatment, big volumes of hepatic healthy tissue were embolized together with the neoplasm. This could bring to a real risk of organ failure, especially in those patients with low liver function. This is the reason why technological evolution has helped physicians to embolyze liver arteries in an always more selective way, thus trying to perform selective procedures, even less invasive. The collaboration between CT scan techniques and intra-operative angiography allows the selection of just the sub-segmentary arteries bringing blood to the lesion. Nowadays also the digital angiography is available, able to give clear images during the procedure, tridimensional if needed. Superselective chemoembolization, as it is performed in very little vessels, requires a new carrier of the chemotherapeutic drug. So, in this case it's impossible to use the standard resin microspheres, but a different material, once used in radiology for hepatic contrast images and no longer in use, which is Lipiodol. This material, thick and able to link to HCC cells, has a disposition to settle and stay into the treated area, and it can

also be easily recognized also during a CT scan control without contrast because it is a radiological contrast by itself¹³.

As said, chemoembolizing treatment is generally performed linking a drug to a resin microsphere. This process is obviously not necessary to obtain just the embolization of the blood vessel going to the tumor. There is a debate in the Literature whether there is a real need to link the drug to the resin, or not, as the resin alone is able to close the vessel and maybe to eliminate the lesion. Some studies show an almost comparable 3 years overall survival between the first and the second therapeutic option, some other suggest to perform a more complete procedure, and this is the reason why the discussion remains unresolved^{13,14}.

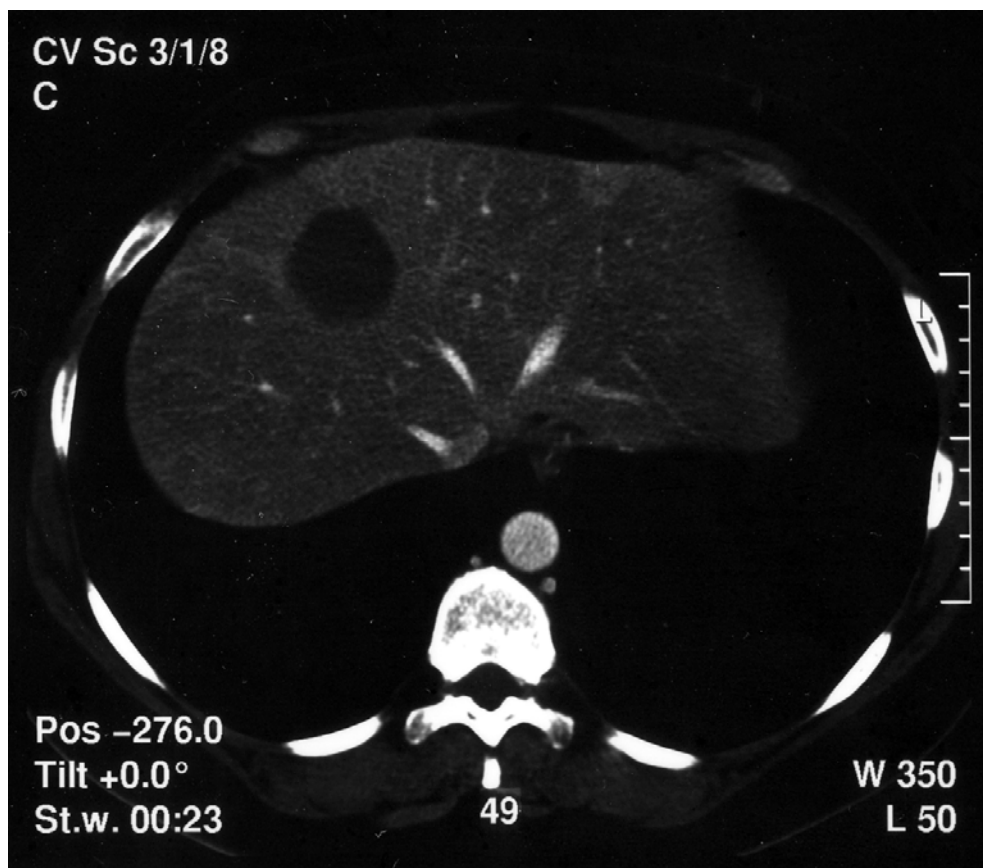

Fig. 4. A lesion following a TACE treatment seen with MR imaging

Chemoembolization does not show the complications typical of the percutaneous procedures with direct tumor puncture. Anyways, considering the loss of healthy liver tissue after TACE, it's mandatory to have a blood liver function test before performing the treatment, as destruction of a volume of liver, even if small in some cases, could bring to

organ failure. Moreover a pre-treatment angiographic study is required, looking for vascular anatomic variations or aberrant vessels, which could keep the lesion fed also after the procedure and cause a drug wash out. A pre-treatment angiographic study is important also, on the contrary, to look for anatomic variations to avoid possible ischemic necrosis of other organs close to the liver and not directly involved in the treatment.

The characteristic possibility of TACE to treat also big lesions is the reason why survival after exclusive treatment is a direct consequence of neoplasm dimension. In case of small lesions a survival of 59% after 5 years is described. In case of nodules more than 5 centimeters in diameter, 3 years and 5 years survival are respectively of 27% and 20%, as reported in the Literature¹⁵.

2.6 Yttrium microspheres embolization

This is a real and proper radioembolization, based on the finding that neoplastic liver tissue, as much as the metastatic one coming from other organs, is sensitive to therapeutic radiations. On the contrary, healthy liver tissue can be able to resist to cumulative doses even higher than 3000 Gy. Radioembolization is performed using two possible devices, which are resin microspheres covered with ⁹⁰Y, similar to those used for chemoembolization, or glass microspheres covered with the same radioactive material. In the USA, resin spheres are FDA authorized for any therapeutic use, while glass spheres are allowed only in case of non-surgical disease. In Europe both devices are allowed¹⁶.

Procedures linked to the Yttrium microspheres treatment are strictly similar to those characteristic of chemoembolization, the only important difference is the fact the intra-arterial drug injection does not require the vessel embolization. In this way the production of some cytokines is avoided, among them there is also the factor 1 α hypoxia induced and VEGF, able to stimulate the disease relapse over eventual not completely treated areas. This is the reason why there are some extended indications for this procedure in comparison with TACE: it's possible to perform it even in case of Portal Vein thrombosis, which is a contraindication for chemoembolization as it could bring to ischemic hepatitis, and it's particularly indicated for big lesions. Moreover, Yttrium microspheres appear easier to be tolerated than TACE, as they reduce post-treatment fever and post-chemotherapeutic diarrhea. On the contrary, patients who underwent this procedure often experience asthenia, and must be kept isolated for at least 24 hours as they are a source of ionizing dangerous waves. The general bearability of the treatment, anyways, makes it a valid option also for patients with a low performance status^{16,17}.

In the Literature there are always more papers trying to make a comparison between TACE and Yttrium microspheres. The two treatments are in facts quite similar, and results over disease free survival and overall survival are comparable. Today it's still difficult to project equivalence studies, as they require a very big sample population to give significant statistic results. It's demonstrated that radiometabolic treatment brings to an important improvement in terms of time to progression, which is the time between the treatment and the disease relapse. Moreover, if there is an adequate structure to accommodate them, older or weak people are some of the best patients to receive this treatment.

In the end, considering the wide amount of contact points between TACE and Yttrium microspheres treatment, technical evolution is moving towards the creation of a unifying

method, creating a sort of radioembolization, able to present the good actions of the two procedures, avoiding the bad ones.

Survival curves characteristic of Yttrium microspheres treatment as an exclusive one are quite the same of chemoembolization¹⁸.


3. Conclusions

Most of the techniques described have been performed in our institution, each one according to their indication, to treat hepatic lesions after surgery. We have noticed a growth of disease free survival and overall survival, experiencing how a combined approach to hepatocellular carcinoma is nowadays the most effective way to treat this disease.

4. References

- [1] Germani, G. et al. (2010), Clinical outcomes of radiofrequency ablation, percutaneous alcohol and acetic acid injection for hepatocellular carcinoma: a meta-analysis. *Journal of hepatology*, 52 (3), 380-388
- [2] Vilana, R. et al. (1992), Tumor size determines the efficacy of percutaneous ethanol injection for the treatment of small hepatocellular carcinoma. *Hepatology*, 16, 353-357
- [3] Lencioni, R. et al. (1997), Long-term results of percutaneous ethanol injection therapy for hepatocellular carcinoma in cirrhosis: a European experience. *European journal of radiology*, 1997, 7, 514-519
- [4] Stigliano, R. et al. (2007), Seeding following percutaneous diagnostic and therapeutic approaches for hepatocellular carcinoma. What is the risk and the outcome? Seeding risk for percutaneous approach of HCC. *Cancer treatment review*, 33, 437-447
- [5] Lencioni, R. et al. (2004), Percutaneous ablation of hepatocellular carcinoma: state of the art. *Liver transplantation*, 10 (2), Suppl 1, S91-S97
- [6] Ohnishi, K. et al. (1998), Prospective randomized controlled trial comparing percutaneous acetic acid injection and percutaneous ethanol injection for small hepatocellular carcinoma. *Hepatology*, 27, 67-72
- [7] Goldberg, S.N. et al. (2000), Thermal ablation therapies for focal malignancies: a unified approach to underlying principles, techniques and diagnostic imaging guidance. *American journal of roentgenology*, 174, 323-331
- [8] Choi, D. et al. (2007), Percutaneous radiofrequency ablation for recurrent hepatocellular carcinoma after hepatectomy: long-term results and prognostic factors. *Annals of surgical oncology*, 14 (8), 2319-29
- [9] Chen, H.W. et al. (2011), Ultrasound-guided percutaneous cryotherapy of hepatocellular carcinoma. *International journal of surgery*, 9 (2), 188-191
- [10] Han, B. et al. (2004), Improved cryosurgery by use of thermophysical and inflammatory adjuvants. *Technology cancer research and treatment*, 3, 103-111
- [11] Adam, R. et al. (2002), A comparison of percutaneous cryosurgery and percutaneous radiofrequency for unresectable hepatic malignancies. *Archives of surgery*, 137, 1332-1339

- [12] Takayasu, K. (2010), Chemoembolization for unresectable Hepatocellular carcinoma in Japan. *Oncology*, 78 (suppl.1), 135-141
- [13] Matsui, O. et al. (1994), Subsegmental transcatheter arterial embolization for small hepatocellular carcinomas: Local therapeutic effect and 5-year survival rate. *Cancer chemotherapy and pharmacology*, 33 (suppl), 84-88
- [14] Bronowicki, J.P. et al. (1994), Transcatheter oily chemoembolization for hepatocellular carcinoma: A 4-year study of 127 French patients. *Cancer*, 74, 16-24
- [15] Coldwell, D. et al. (2010), Radioembolization in the treatment of unresectable liver tumors: experience across a range of primary cancers. *American journal of clinical oncology*, online first (November 30)
- [16] Salem, R. et al. (2011), Radioembolization results in longer time-to-progression and reduced toxicity compared with chemoembolization in patients with hepatocellular carcinoma. *Gastroenterology*, 140, 497-507
- [17] Leelawat, K. et al. (2008), The effect of doxorubicin on the changes of serum vascular endothelial growth factor (VEGF) in patients with hepatocellular carcinoma after transcatheter arterial chemoembolization (TACE). *Journal of medical association of Thailand*, 91, 1539-1543
- [18] Virmani, S. et al. (2008), Comparison of hypoxia-induced factor 1 α expression before and after transcatheter arterial embolization in rabbit VX2 liver tumors. *Journal of vascular interventional radiology*, 19, 1483-1489



Hepatocellular Carcinoma - Clinical Research

Edited by Dr. Joseph W.Y. Lau

ISBN 978-953-51-0112-3

Hard cover, 330 pages

Publisher InTech

Published online 02, March, 2012

Published in print edition March, 2012

This book covers the clinical aspects of hepatocellular carcinoma. This book is a compendium of papers written by experts from different parts of the world to present the most up-to-date knowledge on the clinical aspects of hepatocellular carcinoma. This book is divided into three sections: (I) Diagnosis / Differential Diagnosis; (II) Surgical Treatment; (III) Non-surgical Treatment. There are 19 chapters covering topics from novel diagnostic methods to hepatic lesions mimicking hepatocellular carcinoma, from laparoscopic liver resection to major hepatectomy without allogeneic blood transfusion, from molecular targeted therapy to transarterial radioembolization, and from local ablative therapy to regional therapy. This volume is an important contribution to the clinical management of patients with hepatocellular carcinoma. The intended readers of this book are clinicians who are interested in hepatocellular carcinoma, including hepatologists, liver surgeons, interventional and diagnostic radiologists, pathologists and epidemiologists. General surgeons, general physicians, trainees, hospital administrators, and instruments and drug manufacturers will also find this book useful as a reference.

How to reference

In order to correctly reference this scholarly work, feel free to copy and paste the following:

Federico Cattin, Alessandro Uzzau and Dino De Anna (2012). The Most Important Local and Regional Treatment Techniques of Hepatocellular Carcinoma and Their Effect over a Long Term Overall Survival, Hepatocellular Carcinoma - Clinical Research, Dr. Joseph W.Y. Lau (Ed.), ISBN: 978-953-51-0112-3, InTech, Available from: <http://www.intechopen.com/books/hepatocellular-carcinoma-clinical-research/the-most-important-local-and-regional-treatment-techniques-of-hepatocellular-carcinoma-and-their-eff>

INTECH
open science | open minds

InTech Europe

University Campus STeP Ri
Slavka Krautzeka 83/A
51000 Rijeka, Croatia
Phone: +385 (51) 770 447
Fax: +385 (51) 686 166
www.intechopen.com

InTech China

Unit 405, Office Block, Hotel Equatorial Shanghai
No.65, Yan An Road (West), Shanghai, 200040, China
中国上海市延安西路65号上海国际贵都大饭店办公楼405单元
Phone: +86-21-62489820
Fax: +86-21-62489821

© 2012 The Author(s). Licensee IntechOpen. This is an open access article distributed under the terms of the [Creative Commons Attribution 3.0 License](#), which permits unrestricted use, distribution, and reproduction in any medium, provided the original work is properly cited.