

# Neuroendocrine Tumours of the Lung

Guadalupe Aparicio Gallego<sup>1</sup>, Vanessa Medina Villaamil<sup>1</sup>,  
Ana Capdevila Puerta<sup>2</sup>, Enrique Grande Pulido<sup>3</sup> and L.M. Antón Aparicio<sup>4,5</sup>

<sup>1</sup>*Biomedical Research Institute, A Coruña University Hospital, A Coruña,*

<sup>2</sup>*Anatomic Pathology Service, A Coruña University Hospital, A Coruña,*

<sup>3</sup>*Medical Oncology Service, Ramon y Cajal University Hospital, Madrid,*

<sup>4</sup>*Medical Oncology Service, A Coruña University Hospital, A Coruña*

<sup>5</sup>*Medicine Department, University of A Coruña, A Coruña  
Spain*

## 1. Introduction

Lung cancer arises from neoplastic changes of the epithelial cells in the lung. However, it is not known whether all or only a subset of these lung epithelial cells is susceptible to malignant transformation. Specifically, a major question is whether the changes need to take place in lung epithelial cells involving stem-cell-like properties. Lung cancer is a clinically, biologically, histologically, molecularly, and genetically heterogeneous disease. The underlying causes of this heterogeneity are unknown and could reflect changes occurring in cells with various potential for differentiation or represent different molecular changes occurring in the same lung epithelial target cells. Transformation from a normal to malignant lung cancer phenotype is thought to arise in a multistep fashion, through a series of genetic versus epigenetic alterations, ultimately evolving into an invasive cancer by clonal expansion. These progressive pathological changes in the bronchial epithelium occur primarily as one of three distinct morphological forms: squamous dysplasia, atypical adenomatous hyperplasia, and diffuse idiopathic pulmonary neuroendocrine cell hyperplasia. Bronchial squamous dysplasia and carcinoma in situ (CIS) are the recognised preneoplastic lesions for squamous cell carcinoma (SCC); atypical adenomatous hyperplasia (AAH), a putative preneoplastic lesion, for a subset of adenocarcinomas (ADC); and diffuse idiopathic pulmonary neuroendocrine cell hyperplasia (DIPNECH) for neuroendocrine lung carcinomas. Pulmonary neuroendocrine tumours comprise approximately 2% of all lung malignancies. According to the most recent World Health Organization classification, pulmonary neuroendocrine tumours are histologically divided into a three-tier, four-category system including low-grade (typical carcinoid), intermediate-grade (atypical carcinoid), and high-grade (small cell carcinoma and large cell neuroendocrine carcinoma) tumours. Nearly all lung cancers exhibit the morphological and molecular features of epithelial cells and are accordingly classified as carcinomas. The cells of origin of virtually all lung cancers reside in the epithelial lining of the airways. As more is learned about the origin of neuroendocrine lung tumours, it is also increasingly clear that the biology of neuroendocrine lung tumours arising in the central airways (i.e., SCLC) is distinct from that of peripheral airway lesions. The purpose of this chapter is not so much to recapitulate the

details of the neuroendocrine lung tumour classification but rather to provide an understanding of the main categories of lung carcinoma, to highlight potential pitfalls in the histopathological diagnosis of lung cancer, to summarise current information on molecular properties and cellular origins of individual neuroendocrine lung tumour subtypes, and to relate pathologies to biological behaviours.

## 2. Neuroendocrine system of the lung

The endocrine cells within the gut epithelium (foregut, midgut, and hindgut) constitute the largest population of hormone producing cells in the body. So far, approximately 10 different neuroendocrine lineages have been identified, and most of them show a specific rostro-caudal distribution. Pulmonary neuroendocrine cells (PNECs) are part of the diffuse neuroendocrine system (DNES) distributed throughout the body. The PNEC system (solitary PNECs and neuroepithelial bodies, or NEBs) consists of a distinct population of airway epithelial cells displaying endocrine and paracrine secretory mechanisms. Pulmonary neuroendocrine cells were readily demonstrated and uniformly distributed in normal adult human lungs. Overall, as identified by neurone specific enolase immunoreactivity, there were 10.5 neuroendocrine cells per 10 cm of epithelial length and 4 per 10,000 epithelial cells; they extended from the trachea to the alveolar ducts but none was seen in the alveoli (72% were in bronchi, 24% in bronchioles, and 4% in alveolar ducts). Of the cells identified by gastrin-releasing peptide immunoreactivity, there were 6.9 neuroendocrine cells per 10 cm of epithelial length and 2.4 per 10,000 epithelial cells. Of the cells identified by calcitonin immunoreactivity, there were 3.5 neuroendocrine cells per 10 cm of epithelial length and 1.3 per 10,000 epithelial cells. Minor cells contained serotonin (all in the terminal bronchioles), and in a small minority no peptide or amine was detected. It is currently thought that PNECs, like their counterparts in the gastrointestinal tract, are derived from multipotent epithelial progenitors, and that all epithelial cells arise from a single stem cell. All pulmonary epithelial cells including PNECs and non-NE airway epithelial cells are likely to be derived from a single stem cell. Epithelial lung stem cells, as in many organs, are often confined to discretely localised niches that are protected from environmental insults. In the lung, PNECs are associated with the stem cell niches in both the proximal and distal airways. One of the lung stem-cell niches is located in the trachea that reveals two stem-cell niches: gland ducts in the proximal compartment and select foci near the cartilage-intercartilage junction in the distal trachea. Other intrapulmonary stem cell niches include NEBs located at the airway bifurcation. Another stem cell niche is at the bronchoalveolar junctions, although PNECs may play a diminished role at this location. Among many functions assigned to them, there is a possible dual role: the regulation of lung maturation/growth and chemoreception. First, during the early stages of lung organogenesis, PNECs acting via their amine and peptide products may function as local modulators of lung growth and differentiation. Second, later in foetal life and in postnatal stages, PNECs and in particular innervated NEBs could play a role as airway chemoreceptors. The diffuse neuroendocrine system (DNES) of the lung involves neuroendocrine cells that have been shown to express a functional oxygen sensing mechanism. Aggregates of neuroendocrine cells, called neuroepithelial bodies (NEBs), are diffusely spread in the epithelium at all levels of the intrapulmonary airways, preferentially located at the airway bifurcation of the lungs. Neuroendocrine cells are selectively contacted by different nerve fibres. NEBs are contacted by at least three different nerve-fibre

populations: vagal sensory calbindin D28k, calcitonin gene related peptide (CGRP)/substance P (SP) innervation, and intrinsic pulmonary nitregeric neurons.

### **2.1 Neuroendocrine epithelial cells**

Neuroendocrine epithelial cells (NEC) of the respiratory system tend to occur either as single cells that are sparsely distributed throughout the epithelium of the tracheobronchial tract or in small, well-defined clusters that are supported by nonciliated bronchiolar (Clara) cells. The latter are referred to as neuroepithelial bodies (NEBs) and are located only in the epithelium of the intrapulmonary airways, often at or near a bronchiolar bifurcation. The solitary pulmonary NEC cells of most of the investigated species are fusiform or flask-shaped, resting on the basement membrane with an apical process pointing toward the airway lumen. Adult human NEC cells generally lack luminal contact. Although there are some differences between solitary NEC cells and NEBs, a large body of evidence points to their being a member of the amine precursor uptake and decarboxylation (APUD) cell series or of the paraneuron family. The endocrine system of the lung consists of at least two different cell categories. These categories exhibit similar main characteristics. They contain a biogenic amine and neuropeptide mediators, and their cytoplasm harbours neurosecretory-like granules. Regarding morphological features and location, these cells presumably have a receptor secretory function. Consequently, these classes of endocrine cells can be designated as paraneurons. Solitary NEC cells were found to be distributed over almost the entire respiratory system, while NEBs seemed to be restricted to the epithelium of the intrapulmonary airways. Neuroepithelial bodies generally consist of nonciliated, cylindrical cells with a palisade-like arrangement between the airway surface and the underlying connective tissue, although they may also appear as stratified cells. Most of the luminal side of the NEBs is covered by the supporting Clara cells. The NEBs are strategically located on the surface of the airway bifurcations. They, in fact, contain the serotonin-bioactive amine and neuropeptides, leading to the speculation of these cells as a homogeneous or heterogeneous class. They also exert control on pulmonary vessels and airway tone. The NEC cell may function as the transducer of the stimulus or the sensory nerve ending, the activity of the latter being modulated by the release of bioactive substances from NEC cells. Investigations have indicated the influence of NEC cells on epithelial cell differentiation, mucous secretion, and proliferation of local endoderm in developing airways.

### **2.2 Pulmonary neuroendocrine cells**

Pulmonary neuroendocrine cells (PNECs) are commonly organised into innervated clusters, called NEBs, which have been proposed to serve various functions, including the regulation of embryonic lung growth and maturation through the elaboration of a variety of potent neuropeptides. Several studies have suggested that PNECs are quiescent cells with limited self-renewal capacity. However, it was recently demonstrated that PNECs have a self-renewal capacity and can be activated to undergo multiple rounds of proliferation after TA (Clara) cell depletion. It has been suggested that PNEC-derived paracrine factors might play a role in the regulation of epithelial cell differentiation and proliferation during foetal lung development and possibly in the normal or injured adult lung. Cell proliferation has also been shown to contribute to the maintenance of PNE cells in the normal lung as well as in hyperplasia of this population in various disease states. PNE cells are known to act as a progenitor cell for the establishment of NEB hyperplasia and represent one of two

proliferative populations within hyperplastic NEBs of the naphthalene-injured lung. Participation of non-PNE progenitor cells in this process has also been demonstrated and may contribute to the intermediate phase of NEB hyperplasia. These data suggest that multiple cell types contribute to the maintenance and expansion of the NEB-associated PNE population and that progenitor selection may be a dynamic feature of NEB hyperplasia. Findings from various studies have established PNE cells as a progenitor population that is sufficient for the development of both NEB hypertrophy and hyperplasia. Although NEB dysplasia is correlated with preneoplastic conditions and PNE cells are thought to serve as a precursor for the development of small cell lung carcinoma, mechanisms regulating the expansion of the PNE cell population are not well understood. Based on studies performed in animal models, it has been suggested that NEB-associated progenitor cells that are phenotypically distinct from PNE cells contribute to PNE cell hyperplasia. However, when considering mechanisms that may account for PNE cell hyperplasia, the finding that multiple cell types proliferate in the NEB microenvironment raises the possibility that a non-PNE cell progenitor may yield progeny cells with the capacity to undergo PNE cell differentiation.

### **2.3 Neuroepithelial bodies**

Neuroendocrine bodies were illustrated in 1949 in the description of neuroendocrine cells in the bronchiolar mucosa. Neuroendocrine bodies consist of a cluster of 4 to 10 neuroendocrine cells. On well-oriented sections, they can extend from the subepithelial basement membrane to the airway lumens. They are found not only in the epithelium of bronchi and bronchioles, but also in alveoli. The neuroepithelial body (NEB) is a highly dynamic structure that responds to chronic airway injury through hyperplasia of the associated PNEC. NEB-associated epithelial cells share many morphological and biochemical characteristics with cells that are distributed throughout the airway. Pulmonary NEBs are prime candidates to serve as sensory end organs in the lung. NEBs consist of highly organised clusters of specialised cells with neuroendocrine characteristics, arranged into organoids that are dispersed throughout the epithelium at all levels of the intrapulmonary airways. Structurally, NEB cells harbour cytoplasmic neurosecretory granules that are known to contain monoamine, peptide, and purine transmitters. Neuroendocrine cells are able to synthesise and release ATP, monoamine, and peptide transmitters, resulting in autocrine, paracrine, or endocrine effects. Morphologically, NEBs resemble other known chemoreceptors, such as taste buds and carotid bodies, and are thought to represent “chemosensors” among other possible functions. Hypoxic conditions appear to depolarise NEB cells via a potassium channel-mediated mechanism. In particular, the extensively innervated aggregates of the neuroendocrine cells, called neuroepithelial bodies (NEBs), are diffusely spread in the epithelium at all levels of the intrapulmonary airways but are preferentially located at the airway bifurcation points in the lungs. Proportionally, most NEBs are found in the bronchioles and in the terminal respiratory bronchioles. The NEB microenvironment may represent an analogous structure within the conducting airway epithelium for maintenance of an airway stem-cell pool. It may influence the phenotype of the CE cells, blocking the differentiation from Clara to ciliated cells and preserving a population of regenerative cells that can contribute to epithelial renewal after exposure to Clara cell toxicants. Regeneration of the chronically injured airway epithelium is associated with alterations in the number and cellularity of the NEBs

as well as the enrichment of nascent epithelial cell populations of epithelial cells that are candidate stem cells. The NEB microenvironment is multifunctional, serving to maintain slow-cycling epithelial cells in the steady state epithelium and to stimulate the proliferation of TA cells either after airway injury or during airway development. Many studies have presented extensive evidence that NEBs in the lungs may be selectively contacted by at least 5 distinct nerve-fibre populations that are both sensory and motor in nature. In addition, they have different origins, indicating that NEBs should be regarded as very complex airway receptors that may be capable of accommodating various chemo- and mechano-sensory modalities.

### 2.3.1 Functions

It has been estimated that NEBs represent <1% of the epithelial cells in human lungs. Some of the supposed functions of NEB in mammalian lungs include the following: 1) the ability of NEB to function as transducers (hypoxia); 2) modulation of bronchomotor tone via targeting bronchial smooth muscle and the associated nerves located directly beneath NEB; 3) promotion and regulation of the growth of developing airways by stimulating the proliferation of local endoderm; 4) release of amine and peptide modulators; and 5) neonatal respiratory adaptation. The lung bud epithelium grows into the adjacent mesenchyme and starts branching to form the future bronchial tree. The various stages are divided into the embryonic, pseudoglandular, canalicular, saccular and alveolar/microvascular periods. Pulmonary neuroendocrine cells are the first specialised epithelial cell type to appear in lung development. In humans, ultrastructurally distinct primitive PNECs (pre-NE cells), which contain serotonin and neuro-specific enolase (NSE), can be detected in the beginning of the pseudoglandular period. Solitary and clustered PNECs contain bombesin, the major neuropeptide in human lungs, which appears in the early weeks of gestation. As the distal segments of the developing airways elongate, a process referred to as the canalicular period, PNECs differentiate first, followed by ciliated and secretory (Clara) cells. Parallel with the increasing number of peripheral airways, the number of PNECs also increases. In the developing bronchioles, small NEBs composed of 3-5 bombesin and serotonin-immunoreactive cells appear at the airway branching points, and rare nerve endings have been demonstrated to be in contact with NEBs already in the human foetal lung. Proposed roles for PNECs in foetal and newborn lung development include the regulation of branching morphogenesis as well as cellular growth and maturation.

### 2.3.2 Airway oxygen sensors

Since 1930, evidence has accumulated to suggest that NEBs may function as hypoxia-sensitive airway sensors. NEB cells express membrane-bound O<sub>2</sub> sensors and are the transducers of the hypoxic stimulus. NEB cells respond to acute hypoxia, but apparently not to hypercapnia with the degranulation of dense core vesicles and release of 5-hydroxytryptamine (5-HT). Morphologic and experimental studies to support NEB functions as hypoxia-sensitive airway chemoreceptors modulated by the central nervous system include the following: a) preferential location of NEB at airway branching points; b) apical microvilli in contact with the airway lumen; c) cytoplasmic neurosecretory granules containing monoamine and neuropeptides; d) afferent sensory innervation derived from the vagus nerve; and e) proximity to blood capillaries. NEBs are predominantly innervated by sensory nerve fibres derived from cell bodies in the nodose ganglion of the vagus nerve.

Morphological data support the role of NEBs as hypoxia-sensitive airway sensor systems. Studies on the effects of chronic hypoxia have shown induced cellular hyperplasia and hypertrophy in the peripheral chemoreceptors; chronic normobaric hypoxia showed a significant increase in the number of solitary pulmonary neuroendocrine cells (PNECs) as well as the enlargement of NEBs. NEB cells possess an oxygen-binding protein, cytochrome *b*, an NADPH oxidase located in the cellular membranes that acts as the O<sub>2</sub> receptor both during normoxia and hypoxia.

### 3. Pathology of neuroendocrine tumours of the lung

The neuroendocrine cell system is divided into cell types that form glands and diffusely distributed cells. This second group is collectively known as the diffuse neuroendocrine system (DNES), and its representatives are found in the lung, gastrointestinal tract, or urogenital tract. Neuroendocrine tumours of the lung arise from bronchial mucosal cells known as Kulchitsky cells, which are part of the DNES. The classification of lung neuroendocrine malignancies has been an evolving process (Table 1).

#### WHO/IASLC histological classification

---

##### Preinvasive Lesions

Diffuse idiopathic pulmonary neuroendocrine cell hyperplasia (DIPNECH)

##### Large Cells carcinoma (Variants)

Large cell neuroendocrine carcinoma (LCNEC)

Combined large cell neuroendocrine carcinoma (C-LCNEC)

##### Carcinoid tumour

Typical carcinoid (TC)

Atypical carcinoid (AC)

##### Small cell carcinoma

Combined small cell carcinoma

#### Non-small Cell Lung Carcinoma with Neuroendocrine Differentiation (NSCLC-NED)

---

WHO: World Health Organization; IASLC: International Association for the Study of Lung Cancer

\*From Travis WD, Colby TV, Corrin B, et al in collaboration with pathologists from 14 countries.

Histological typing of lung and pleural tumors. 3<sup>rd</sup> ed. Berlin: Springer Verlag, 1999, with permission.

Table 1. Lung tumours with neuroendocrine morphology include the low-grade typical carcinoid (TC), intermediate-grade atypical carcinoid (AC), and the high-grade LCNEC and SCLC.

These classifications date back to 1972, when atypical carcinoids were initially defined according to histological criteria, including the number of mitoses per high-power field (hpf), the presence of necrosis, increased cellularity with disorganisation, nuclear pleomorphism, hyperchromatism, and an abnormal nuclear to cytoplasmic ratio (Table 2).

In 1991, a new classification proposed 4 categories of neuroendocrine lung tumours that included the following: typical carcinoid (TC), which is a low-grade malignancy; atypical carcinoid (AC), which is a medium-grade malignancy; large-cell neuroendocrine carcinoma (LCNEC), which is a high-grade malignancy; and small-cell lung cancer (SCLC), which is also a high-grade malignancy. The 2004 WHO categorisation of tumours with neuroendocrine features included the classic carcinoid low-grade TC and intermediate-grade AC, as well as the high-grade malignancies LCNEC and SCLC.

Tumor	Mitoses	Nuclear chromatin	N/C ratio	Nucleoli	Necrosis	Shape
TC	<2/10 HPF	Finely granular	Moderate	Occasional	None	Round, oval
AC	2-10/10 HPF	Finely granular, occasional atypia	Moderate	Common	+(focal)	Round, oval
SCLC	≥11/10 HPF Median 80/10	Finely granular	High	Absent or inconspicuous	+(large zones)	Round, oval, spindle
LCNEC	>11/10 HPF Median 70/10	Vesicular or coarsely granular	Low	Very common	+(large zones)	Round, oval polygonal

N/C: nuclear/cytoplasmic; HPF: high power fields; LCNEC: large cell neuroendocrine carcinoma; SCLC: small cell lung carcinoma

Table 2. Histopathological Classification of Neuroendocrine Tumours of Lung

### 3.1 Tumourlets

Carcinoid tumours that grow in the peripheral lung and are smaller than 5 mm are referred to as tumourlets. By definition, tumourlets are comprised of increased numbers of individual cells, small group cells, or nodular aggregates of cells that are confined to the bronchial/bronchiolar epithelium (with larger lesions bulging into the lumen but not breaking the subepithelial basement membrane).

### 3.2 Diffuse Idiopathic Pulmonary Neuroendocrine Cell Hyperplasia

Diffuse idiopathic pulmonary neuroendocrine cell hyperplasia (DIPNECH) is a rare condition in which neuroendocrine cells proliferate throughout the peripheral airways in the form of neuroendocrine cell hyperplasia, tumourlets, and sometimes carcinoid tumours. In DIPNECH, neuroendocrine cell hyperplasia and tumourlets are thought to be a primary proliferation in contrast to the much more common situation where these lesions are seen as a reactive secondary lesion in the setting of airway inflammation and/or fibrosis. This condition is regarded as a precursor to carcinoid tumours because a subset of these patients experience one or more carcinoid tumours. More aggressive forms of lung carcinoma, including SCLC, have not been associated with DIPNECH.

### 3.3 Carcinoid tumours

Pulmonary or bronchial carcinoid tumours account for over 25% of all carcinoid tumours and for 1%-2% of all pulmonary neoplasms. Approximately 10%-20% of pulmonary carcinoids are typical carcinoids; the remaining 80%-90% are atypical carcinoids. Most of these tumours occur centrally and involve the main, lobar, or segmental airways. Sometimes they are located distal to the segmental bronchi; such tumours are the so-called peripheral carcinoids. Atypical carcinoids have been reported to be larger than typical carcinoids, with mean diameters of 3.6 cm and 2.3 cm, respectively. Moreover, atypical carcinoids are more likely to occur in the periphery of the lung than are typical carcinoids. It was generally accepted that a carcinoid tumour was a very slow-growing and benign neoplasm with no potential for invasiveness and no tendency to give rise to metastases. Carcinoid tumours have subsequently been reported in a wide range of organs, but they most commonly

involve the lungs and the gastrointestinal tract. The histopathologic features that distinguish atypical carcinoids from typical carcinoids are as follows: increased mitotic activity; greater cytological pleomorphism and higher nuclear to cytoplasmic ratios; increased cellularity and architectural irregularities, and more areas of tumour necrosis. In terms of histological features, typical carcinoids show no evidence of necrosis and fewer than 2 mitoses per 10 high-power fields (or 2 mm<sup>2</sup>) of viable tumour, whereas atypical carcinoids do have areas of necrosis and 2-10 mitoses per 10 high-power fields.

### **3.4 Large-Cell Neuroendocrine Carcinoma**

Large-cell neuroendocrine carcinoma (LCNEC) was proposed as the fourth category of pulmonary neuroendocrine tumours due to its distinct clinical and pathologic findings versus the typical carcinoid, atypical carcinoid, and SCLC. LCNEC is defined as a poorly differentiated and high-grade neuroendocrine tumour that morphologically is between an atypical carcinoid and SCLC. According to the WHO suggestions, the morphologic features of LCNEC represent a spectrum between those of atypical carcinoid and those of SCLC. In 70%-80% of cases, LCNEC appears as a peripheral mass or nodule, whereas 25% manifests as a central mass. Histopathologic diagnosis criteria for LCNEC are as follows: neuroendocrine morphologic features; a high mitotic rate (>10 per 10 high-power fields); necrosis (often large zones); cytologic features different from those of SCLC; and positive immunohistochemical staining for one or more neuroendocrine markers including chromogranin A, synaptophysin, and neural cell adhesion molecular (NCAM/CD56).

### **3.5 Small-cell lung carcinoma**

SCLC accounts for approximately 20% of all bronchogenic carcinomas. Approximately 90%-95% of SCLCs occur centrally, apparently arising in a lobar or main bronchus. In 5%-10% of cases, SCLC manifests as a peripheral nodule. These tumour cells are usually small with a round or fusiform shape and have high cellularity with a very high mitotic rate. SCLCs are highly proliferative and rarely are the mitotic rates less than 10 mitoses per 10 high-power fields. As such, virtually every high-power field contains one or more mitoses. The architecture of the tumour clusters is poorly preserved, with large areas of necrosis separating small islands of viable tumour. A distinguishing feature of SCLC is its expression of neuroendocrine markers including neuron specific enolase (NSE), synaptophysin, neural cell adhesion molecule (NCAM/CD56), and Leu-7 (CD57).

## **4. The neuroendocrine differentiation in lung tumours**

### **4.1 Non-small cell lung cancer (NSCLC)**

The hypothesis that tumours with neuroendocrine properties should be grouped into a single category is not universally accepted for several reasons. First, a large proportion of lung carcinomas have mixed non-neuroendocrine and neuroendocrine properties. This is particularly evident in molecular profiling studies where otherwise unremarkable adenocarcinomas have been shown to express clusters of genes that are thought to reflect neuroendocrine differentiation. Second, many of the markers that are regarded as neuroendocrine markers are expressed in a variety of cells in addition to neuroendocrine cells. Third, neuroendocrine markers are expressed during the embryonic development of the lung.



#### 4.1.1 Adenocarcinoma (ACA)

Pathology reports frequently mention the presence of NE immunophenotype or NE differentiation in NSCLC. Travis et al. have provided a new classification of the pulmonary NE proliferations and neoplasms of the lung, as part of the WHO classification of lung cancers. In this classification, NSCLC with NE differentiation (NSCLC-ND) detected only by immunostaining via electron microscopy is presented as a distinct entity in which no histological features of NE differentiation are appreciated on routine hematoxylin and eosin (HE). NSCLC represents a histologically heterogeneous group of tumours with variable clinical behaviours. Evidence for NE differentiation in non-small cell lung carcinomas (NSCLCs) is, at present, based on histochemical, ultrastructural, and immunohistochemical data. The existence of nonsmall cell lung carcinoma with neuroendocrine differentiation as a distinct entity, as well as its relevance for prognostic and treatment purpose, is controversial. A minority of NSCLCs (10-30%) show NE differentiation, and in contrast to large cell NE carcinoma, they show no evidence of this differentiation on routine light microscopic examination. Previous studies have identified NE differentiation in NSCLC in 10 to 70% of cases. Positivity for all 3 NE (Ch, SNP, and CD56) markers was not seen. The co-expression of SNP and Ch, the two most commonly used NE markers, accounted for only 0.2% (ACA) of the NSCLC. SNP staining was observed in a significant minority of NSCLC (7.5%), whereas Ch, the most specific NE marker, was very uncommon (0.4%) (Table3).

NSCLC Cell Type	Chromogranin (Ch)	Synaptophysin (SNP)	N-CAM (CD56)
Adenocarcinoma	0.4%	11.2%	5.1%
Squamous cell carcinoma	0.4%	4.3%	12.4%
Non-small cell carcinoma	0%	12%	7.4%
Large cell carcinoma	0%	9.3%	6.2%
Others	0%	0%	0%

Table 3. Immunoreactivity for Neuroendocrine Markers in Different Subtypes of NSCLC

As has been suggested, the derivation of all lung tumours from a common endodermal stem cell, along with the adoption of amine precursor uptake and decarboxylation properties by this endodermal stem cell, explains divergent differentiation in NE lung tumours and the occurrence of NE subsets in NSCLC.

#### 4.1.2 Large cell carcinoma (LCC)

Large cell carcinomas of the lung are classified into four types based on light microscopic evidence of neuroendocrine morphology. Immunohistochemical or electron microscopic assessments of neuroendocrine differentiation are categorised as follows: (1) large cell neuroendocrine carcinoma exhibits both neuroendocrine morphology and evidence of neuroendocrine differentiation; (2) large cell carcinoma with neuroendocrine differentiation exhibits neuroendocrine markers but lacks neuroendocrine morphology; (3) large cell carcinoma with neuroendocrine morphology exhibits neuroendocrine markers; and (4) classic large cell carcinoma exhibits neither neuroendocrine morphology nor differentiation. Neuroendocrine markers in NSCLC are expressed not only in large cell carcinoma but also in adenocarcinomas.

## 4.2 NETs of the lung with NE differentiation

Lung tumours with neuroendocrine morphology include the low-grade typical carcinoid (TC), intermediate-grade atypical carcinoid (AC), and the high-grade LCNEC and SCLC. Neuroendocrine differentiation may be detected by immunohistochemical or ultrastructural studies in 10% to 20% of histologically ordinary NSCLCs such as squamous cell carcinomas, adenocarcinomas, or large cell carcinomas.

### 4.2.1 Small cell lung carcinoma (SCLC)

SCLC tumors are considered poorly differentiated NE cancers in contrast to typical and atypical bronchial carcinoid tumors. In addition to SCLC, approximately 20-30% of NSCLC tumors express some degree of NE differentiation, predominantly in adenocarcinomas and large cell cancers. SCLC exhibits characteristic molecular abnormalities which partially overlap with those of NSCLC including frequent inactivation of the Rb-p16INK4A-related G1 checkpoint pathway, loss of p53, and frequent abnormalities in chromosome

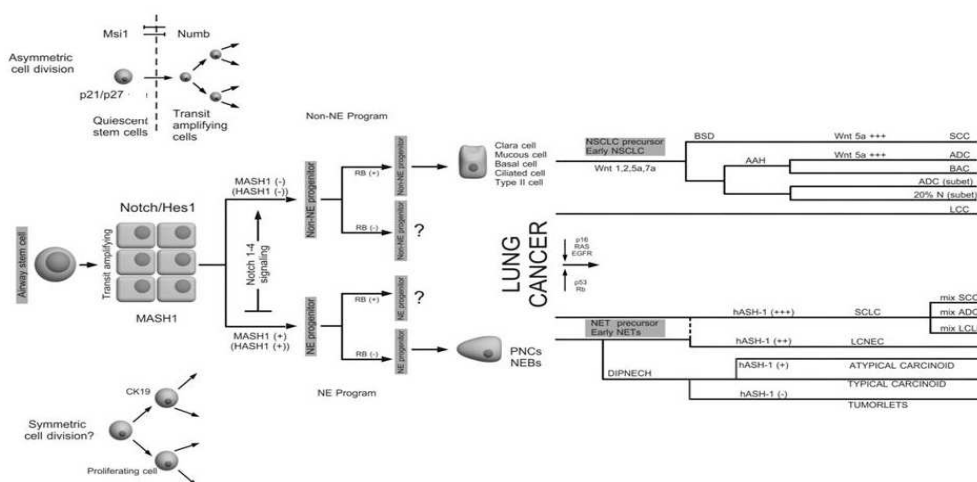


Fig. 1. Hypothetical carcinogenic pathway in lung cancer: The specification of distinct cell fates is often achieved through the activation of specific intercellular signaling pathways by growth factors whose expression must be spatially and temporally controlled to ensure accurate response. Typically, a target cell expresses an excess of receptors such that the availability of its ligands is rate-limiting for pathway activation. Overall, for a signal to elicit the desired response, the intensity and duration of ligand expression must be sufficient to meet its threshold concentration, and yet the signal response must be restricted to prevent excessive signaling. Excessive activation of a signaling pathway can have broad deleterious effects, thus prompting a requirement for antagonistic regulation. Abbreviations: AAA (Atypical Adenomatous Hyperplasia), ADC (Adenocarcinoma), BAC (Bronchioalveolar Carcinoma), BSD (Basal Squamous Dysplasia), DIPNECH (Diffuse Idiopathic Pulmonary Neuroendocrine Cell Hyperplasia), LCC (Large Cell Carcinoma), LCNEC (Large Cell Neuroendocrine Carcinoma), NEBs (Neuroepithelial Bodies), PNCs (Pulmonary Neuroendocrine Cells), SCC (Squamous Cell Carcinoma), SCLC (Small Cell Lung Carcinoma).

3p-associated tumor suppressor activity. In addition to these changes, SCLCs frequently overexpress myc genes, especially c-Myc, often via gene amplification events. Of all the genetic changes in SCLC, Rb gene mutations are utterly characteristic. Functioning RB protein is lacking in greater than 90% of SCLC and NSCLC with NE features.

### 4.2.2 Large cell neuroendocrine carcinoma (LCNEC)

The term combined LCNEC is used for those tumours associated with other histologic types of NSCLC. Most often this represents a component of adenocarcinoma. LCNEC must be distinguished from adenocarcinoma, SCLC, large cell carcinoma, and large cell carcinoma with neuroendocrine differentiation (LCC-ND).

## 5. Embryological pathways in lung tumours

### 5.1 Notch

The three main functions of Notch signalling in self-renewing tissues include stem-cell maintenance, binary cell-fate decisions, and induction of differentiation. A critical aspect of Notch function in both development and post-natal life is the maintenance of stem cell viability and asymmetric cell division. Intrinsic to this process is an unequal distribution of Notch signals in the daughter cells, with the Notch-active cell maintaining its stem cell




Fig. 2. Heat map for Notch1-4 expression in a serie of 64 carcinoids studied by tissue array technology in our lab gave the next information: The mean of expression for Notch1 is 2.33 and the mode 0. 76.6% of the samples showed no expression for this marker, 4.7% showed weak expression, 1.6% moderate expression; 4.7% of the samples showed strong reactivity for Notch1 in more than 75 % of tumour cells in the core biopsy arrayed, 12.5% of the samples did not show enough tissue for testing. The average expression for Notch2 is 8.56 and the mode 12. 7. 8% of the samples showed no expression for this marker, 4.7% showed weak expression, 17.2% moderate expression, 54.7% of the samples showed intense staining for Notch2 in almost all tumour cells present in the sample, 15.6% of the samples did not show enough tissue for testing. The average Notch3 expression is 6.3, and mode of 8. 10.9% of the samples showed no expression for this marker, and 25% showed weak expression, 14% moderate expression, 31.3% of the samples showed intense staining for Notch3 in almost all tumour cells present in the sample 18.8% of the samples did not show enough tissue for testing. Finally, for Notch4 we did not find reactivity in any of the 87, 5% samples with enough tissue for its evaluation.

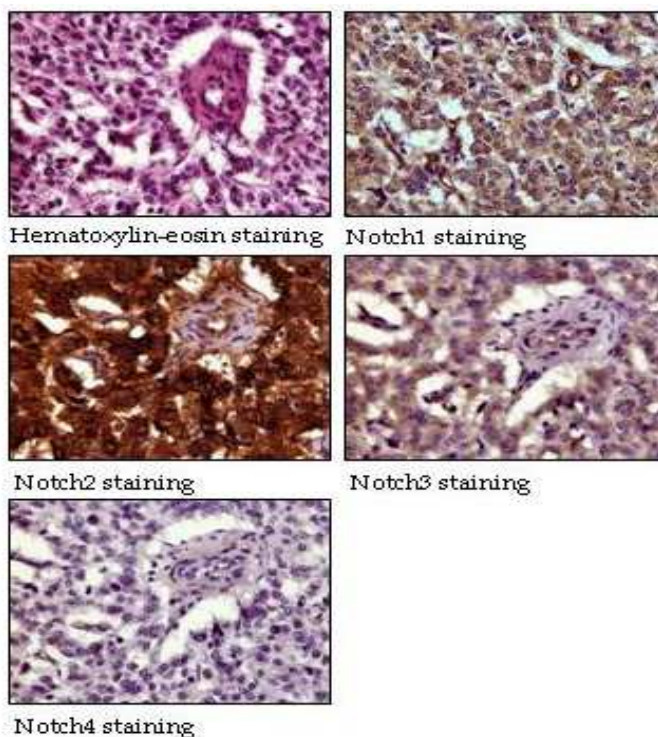


Fig. 3. Immunohistochemical findings for Notch1-4 in carcinoids tumors.

character and with transit-amplifying cells typically losing Notch activity. Interestingly, Notch function in lung cancer exhibits properties suggesting both tumour promotion and inhibition, depending on the tumour cell type. A prominent function of Notch signalling is to inhibit the transcriptional activities of the widely expressed E2A proteins. Notch signalling rapidly induces degradation and inactivation of E proteins and tissue-specific bHLH proteins such as hASH1. This inhibition may occur as a consequence of forming inhibitory complexes of E2A proteins with the Hes/HERP/HEY proteins, as well as the promotion of E2A protein ubiquitinylation and degradation by Notch. Notch1 and Notch2 proteins are frequently expressed in non-small-cell lung cancer (NSCLC), while Notch3 mRNA expression was detected in one-third of all NSCLC cell lines. NSCLC, which includes adenocarcinoma, squamous cell carcinoma, large cell undifferentiated carcinoma, and bronchoalveolar cell carcinoma, was initially shown to express significant levels of the Hes1 protein. In addition, there is an inverse correlation in these cell lines between the expressions of hASH1/ASCL1 and of the Hes1 protein. In contrast to NSCLC, where Notch is suspected to have a growth promoting function, SCLC appears to be growth inhibited, at least by the high level over-expression of activated Notch1 and Notch2. Notch1 is rarely detectable or inactive in SCLC, whereas a subset of SCLC exhibit Notch2. Notch3 mRNA expression was not detected in the SCLC cell lines. Expression of Notch3 has been reported to be common in NSCLC but not in SCLC. Significantly, Notch signaling has recently been shown to be induced by the ras pathway, which is active in a large fraction of NSCLC, but

only rarely in SCLC. Notch in the SCLC cells lead to a significant increase in Hes1 and a marked down-regulation of the neurally related transcription factors hASH1 and Hes6. The loss of hASH1 may be critical in mediating the growth inhibitory effect of Notch1 in SCLC, although a role for other as yet unidentified targets cannot be excluded. Activated Notch1 and Notch2, but not Hes1, caused a potent G1 arrest in the SCLC cells, accompanied by the marked up-regulation of p21<sup>wasl/cip1</sup>, overall abundance of p53, and a Rb mutant typifying the majority of SCLC

### 5.2 Hedgehog signalling in lung cancer

The hedgehog (Hh) signalling network functions in cell-cell communication and regulates pattern formation, proliferation, cell fate, and the stem/progenitor cell maintenance and self-renewal in many organs. A greatly simplified version of “canonical” hedgehog signalling in mammals typically involves two types of cells, a signalling cell expressing a member of the Hedgehog family of secreted ligands (*Sonic Hedgehog* (Shh), *Indian Hedgehog* (Ihh), or *Desert Hedgehog* (Dhh)) and a responding cell expressing one or more *Patched* family hedgehog receptors (*Patched-1* (PTCH2)). In the Hh pathway, increased signalling results in activation of the GLI oncogenes (GLI1, GLI2, and GLI3) that can regulate gene transcription. The Hh signalling pathway was originally shown to have persistent activation in SCLC with high expression of Shh, PTCK, and GLI1, but an important role in NSCLC, was also demonstrated.

### 5.3 BMPs and BMPRs

The BMPs comprise a branch of the TGF- $\beta$  superfamily that also plays a key role in development. Several BMP ligands and BMPRs including BMP3, 4 and 7 as well as type I BMPR are expressed during embryonic lung development. BMP4 mRNA is localized at high levels in the epithelium of distal tips of terminal buds, with lower levels in the adjacent mesenchyme. These loci of BMP expression overlap with the expression domains of some other important morphogenetic signaling molecules including HNF-3 $\beta$ , Wnt-2, Shh and FGF-10. Also, since BMPs and Shh are co-expressed in the same domains, and since Decapentaplegic, the *Drosophila* BMP homologue, is regulated by the Hedgehog signaling pathway, it seems possible that BMP-Shh interactions may prove to play key roles in lung morphogenesis. Recently published data on fibroblast growth factor interactions suggest that Shh, TGF- $\beta$ 1 and BMP4 all counteract the bud-promoting effects of FGF-10.

### 5.4 Wnt pathway in lung cancer

Wnt signaling has many functions in animal development including its development role in embryogenesis and in the adult lung. More specifically, studies of knockout mice demonstrated the importance of Wnt-2, Wnt-5a, and Wnt-7b in lung maturation. In addition to its role in stem cell self-renewal, tissue regeneration, and lung development, Wnt signaling is also intimately involved in tumorigenesis and cancer progression. For example, the organs where Wnt signaling influences stem cell self-renewal are the same organs where those Wnt-pathway-dependent cancers originate. Numerous reports have demonstrated aberrant Wnt activation in lung cancer. Overexpression of Wnt-1 has been demonstrated in NSCLC cell lines and primary cancer tissues. This activation can be caused by mutations and/or deregulation of many different Wnt signaling components. Mutations in Wnt pathway components are rarely found in lung cancer. Also overexpression of Wnt-2 in NSCLC has been demonstrated. The human Wnt-2 gene, located on chromosome 7q31.3, is

highly expressed in fetal lung. The link between Wnt-2 and tumorigenesis was first proposed after data indicated that Wnt-2 was amplified in human cancers. Indeed, in patients with NSCLC found that Wnt-5a expression in squamous cell carcinoma was significantly higher than that in adenocarcinoma. Recently there has been a suggested role for Wnt-7 in lung cancer. It has been reported that expression of Wnt-7a is downregulated in most lung cancer cell lines and tumor samples.

## 5.5 bHLH

Helix-loop-helix proteins are a diverse family of transcriptional regulators involved in fetal development and cancer. The 125 recognized human HLH proteins can be subdivided into 45 families, almost all of which have *Drosophila* representatives as well. These families include achaete-scute homologs, E proteins, Atonal, NeuroD, neurogenin, ID proteins, HES, and Hes-related proteins, and others. bHLH genes control cell differentiation in various tissues and are categorized into two distinct groups, activator genes and repressor genes. In mammals, bHLH genes such as mammalian achaete-scute complex homolog-1 (MASH1) and mammalian atonal homolog (MATH)-1 are expressed in neural precursor cells, and they up-regulate late-expressing bHLH genes such as NeuroD to direct terminal differentiation. On the other hand, HES1, one of the hairy and enhancer of split (HES) homologues, represses neuronal differentiation by the suppression of proneural bHLH factors. Repressive bHLH factors such as HES1 are regulated by the Notch pathway. The Notch ligands activate the Notch receptors, and the activated intracellular domain of the Notch receptors interacts with the DNA-binding protein RBP-Jk to activate the expression of repressive bHLHs such as HES1 and HES5, which, in turn, suppress the expression of activator bHLHs such as MASH1 and NeuroD. Immunohistochemical studies have revealed that Notch1, Notch3, Jagged1, and Jagged2 were expressed in neuroendocrine cells of the airway epithelium, while Dll1 was detected in the pulmonary neuroendocrine cells. Thus, the differentiation of the lung epithelial cells depends on a bHLH factor network, and the Notch pathway may be involved in determining the cell differentiation fate in the airway epithelium.

### 5.5.1 Achaete-scute homolog (ASH-1)

Mash1 (termed Hash1 in humans) plays a critical role in development of the central and autonomic nervous systems and in tissues of the so-called diffuse NE system including the adrenal medullary chromaffin cells, thyroid parafollicular C-cells, and pulmonary NE cells. MASH1 is important in the development of the diffuse neuroendocrine system, including pulmonary neuroendocrine cells. During neurogenesis, MASH1 expression is confined to mitotically active precursors where it is involved in the early stages of lineage commitment; in more mature neurons the expression is extinguished. MASH1 and mammalian atonal homolog-1 (Math1) up-regulate NeuroD in neural precursor cells to direct terminal differentiation, whereas HES1 represses neuronal differentiation by the suppression of proneural factors such as MASH1. In the developing mouse lung, Mash1 first becomes detectable at approximately E13.5 in neuroepithelial bodies (NEB'S), clusters of NE cells frequently located at branchpoints of large and medium-sized airways. Mash 1 expression in mouse lung peaks near birth and the declines in adulthood, following the peak and decline of lung NE cells. One target of achaete-scute proteins is the cell surface ligand delta, which leads to activation of the Notch pathway in adjoining cells and repression of the neuronal fate. In human lung tumours, the expression of hASH1 mRNA was significantly higher in

SCLC (75%) than in LCNEC (50%); conversely, HES1 mRNA was lower in SCLC (59%) than in LCNEC (87%). These findings reveal that SCLC more strongly expresses the neuroendocrine phenotype, while LCNEC shows characteristics that are more similar to the epithelium phenotype, suggesting that the biological characteristics of these two tumours are different. On the contrary, non-neuroendocrine carcinoma cells do not express hASH1 but show high HES1 expression. In NSCLC (squamous cell carcinoma vs. adenocarcinoma), the expression of hASH1 mRNA was lower, (0% vs. 15%, respectively), whereas HES1 mRNA was higher (10% vs. 100%, respectively). Neuroendocrine pulmonary carcinomas express MASH1 but not HES1, whereas adenocarcinoma and squamous cell carcinoma express HES1. Surprisingly, Merkel cell carcinoma, the cutaneous counterpart of small cell carcinoma MASH1, was completely negative in 100% of the cases.

### 5.5.2 Hairy and Enhancer-of-split (HES)

Hes1, a key effector of the Notch signalling pathway, is expressed broadly in non-neuroendocrine cells in the airway epithelium. In the developing lung, Notch1 and HES1 are strongly expressed in the non-neuroendocrine airway epithelial cells, whereas MASH1 is restricted to the clustered pulmonary neuroendocrine cells. HES1 directly represses hASH1 expression by binding to a class C site in the ASH1 promoter. Today, the published results suggest that the differentiation of neuroendocrine cells in normal lungs is affected by the absence of the MASH1 gene. Elements of the Notch signalling pathway, especially that of HES1, appear to be critical negative regulators of achaete-scute homolog 1 expression in normal lungs and in lung cancer. For example, HES1 transgenic knockout mice exhibit substantial hyperplasia and premature differentiation of lung NE cells associated with an increase in MASH1-expressing pulmonary epithelium. It has been shown that the over-expression of HES1 in SCLC cells leads to the repression of hASH1 expression via a transcriptional mechanism.

### 5.5.3 Retinoblastoma (Rb)

The RB gene is a prototypical tumour suppressor gene, and the loss of RB function is believed to be a key event in the initiation or progression of several human malignancies. Most RB gene alterations result in the loss of RB protein expression or in a truncated RB protein, which does not enter the nucleus. Thus, heterogeneous positive nuclear RB immunostaining is, in general, indicative of normal RB function, whereas negative intranuclear RB immunostaining in all tumour cells reflects aberrant RB protein expression. Typical and atypical carcinoids manifest a heterogeneous RB-positive staining pattern. Atypical carcinoids in general show an increase in the number of tumour cells with nuclear staining compared to typical carcinoids. In contrast, small-cell and large-cell neuroendocrine carcinomas fail to show RB staining in any tumour nuclei, indicating the loss of RB function. From these results, it can be concluded that a progressively higher degree of malignancy from typical carcinoids to atypical carcinoids to small-cell carcinomas is paralleled by the loss of neuroendocrine markers, increased proliferative markers, increased frequency of p53 immunostaining, and decreased frequency of RB immunostaining.

### 5.5.4 p53

Although p53 alterations have been previously studied in pulmonary neuroendocrine tumours, either these studies have used immunochemistry alone rather than genotypic

analysis or they have examined a limited spectrum of pulmonary neuroendocrine neoplasias. The distribution of p53 immunohistochemical staining has 4 patterns: negative in typical carcinoids (TCs), 50% of ACs, 20% LCNECs, and 12% SCLCs; less than 10% but more than 5-10 HPF (focal) in a subset (30%) of aggressive adenocarcinomas; and 50-100% of tumour cells (diffuse), exclusively seen in LCNECs and SCLCs. Three patterns of immunohistochemical staining intensities of the p53 protein were seen: negative; weak or mild; and moderate to marked staining. Similar to other cancers, multiple genetic events contribute to the development of neuroendocrine lung tumours. This has already been demonstrated in SCLCs, which are known to exhibit alterations in their oncogenes such as *c-myc* and in tumour suppressor genes such as p53 and Rb. In addition, it has been shown that alterations in oncogenes such as H-ras, c-myc, and c-raf-1 can modulate the expression of neuroendocrine antigens in lung cancer cell lines. Thus, evidence is accumulating that the expression of neuroendocrine differentiation in pulmonary neuroendocrine tumours is fundamentally controlled by multiple genetic determinants.

## 6. Conclusions

Although incidence of newly diagnosed patients with carcinoid tumors of the lung is low, the long survival for those with low and intermediate differentiation grade, and the deeper knowledge we now have on molecular processes that governs tumors growth make these tumors a challenging field in Oncology. Systemic treatment for metastatic carcinoid tumors of the lung has not change significantly in the last two decades, and this fact leads to a poor improvement in overall survival, contrary to what has happened in other solid tumors. Nowadays, most of researchers in neuroendocrine field consider that every single neuroendocrine tumors has its own features depending on the organ where it seats, the capacity to produce and secrete active hormones to blood stream, and the proliferation rate. Novel agents like antiangiogenic tyrosine kinase inhibitors, mTOR inhibitors or oral chemotherapeutic agents like temozolomide and capecitabine have been used to treat metastatic neuroendocrine tumors of the lung without a clear activity. Unfortunately, these clinical trials with new agents were not driven to lung tumors but to other neuroendocrine tumors of the gastrointestinal tract. Therefore, other pathways are needed to be investigated. A non insignificant number of recent publications are correlating embryological pathways with carcinoid tumors of the lung development. In this sense, some elements of the Notch signalling pathway, especially HES1, appear to be critical negative regulators of hASH-1 expression in normal lungs and in lung cancer. This fact may influence in carcinoid tumor development at this place. New compounds under clinical development targeting embryological pathways like Notch, Hedgehog or Wnt pathways may have a future impact in the treatment of disseminated carcinoids of the lung. The more we are able to select patients molecularly the greater the chance of success in future clinical trials conducted in this setting. However, none of this would be meaningless if the histological diagnosis is not accurate. There is a need to leverage the knowledge in the scientific community of the variety of neuroendocrine-derived tumors that may arise in the lung. The teamwork between pulmonologists, thoracic surgeons, pathologists, molecular biologists, oncologists, and radiotherapists is mandatory to offer to our patients the best treatment approach at the right time for their diseases.



## 7. References

### 7.1 Neuroendocrine system of the lung

- Dimaline RN, Struthers J. Expression and regulation of a vesicular monoamine transporter (VMAT2) in rat stomach a putative histamine transporter. *J Physiol.* 1996; 490: 249-56.
- Erickson JD, Schafer MK, Bonner TI, et al. Distinct pharmacological properties and distribution in neurons and endocrine cells of two isoforms of the human vesicular monoamine transporter. *Proc Natl Acad Sci USA.* 1996; 93: 5166-71.
- Feyrter F. Über diffuse endocrine epitheliale Organe. *Liepszig Zentr Inn Mediz.* 1938; 29: 545-71.
- Feyrter F. Über die peripheren endokrinen (parakrinen) Druesen des Menschen. 1993; Maudrich. Vienna.
- Jin L, Hemperly JJ, Lloyd RV. Expression of neural cell adhesion molecule in normal and neoplastic human neuroendocrine tissues. *Am J Pathol.* 1991; 138: 961-9.
- Komminoth P, Roth J, Lacke PM, et al. Polysialic of the neural cell adhesion molecule distinguishes small cell lung carcinoma from carcinoids. *Am J Pathol.* 1991; 139: 297-304.
- Lantuejoul S, Moro D, Michalides RJ, et al. Neural cell adhesion molecules (NCAM) and NCAM-PSA expression in neuroendocrine lung tumors. *Am J Surg Pathol.* 1998; 22: 1267-76.
- Lloyd RV, Wilson BS. Specific endocrine tissue marker defined by a monoclonal antibody. *Science.* 1983; 222: 628-30.
- Masson P. Carcinoid (argentaffin-cell tumors) and nerve hyperplasia of the appendicular mucosa. *Am J Pathol.* 1928; 4: 181-212.
- Pearse AG. The cytochemistry and ultrastructure of polypeptide hormone-producing cells of the APUD series and the embryologic, physiologic and pathologic implications of the concept. *J Histochem Cytochem* 1969;17:303-313
- Rode J, Dhillon AP, Doran JF, et al. PGP 9.5, a new marker for human neuroendocrine tumours. *Histopathology.* 1985; 9: 147-58.
- Wiedenmann B, Franke WW, Kuhn C, et al. Synaptophysin: a marker protein for neuroendocrine cells and neoplasms. *Proc Natl Acad Sci USA.* 1986; 83: 3500-4.
- Wilkinson KD, Lee KM, Desphande S, et al. The neuron-specific protein PGP 9.5 is a ubiquitin carboxyl-terminal hydrolase. *Science.* 1989; 246: 670-3.

### 7.2 Neuroendocrine epithelial cells

- DiAugustine RP, Sonstegard KS. Neuroendocrinelike (small granule) epithelial cell of the lung. *Environ Health Perspect.* 1984; 55: 271-95.
- Fujita T. concept of paraneurons. *Arch Histol Jpn.* 1977; 40 suppl: 1-2
- Fujita T. Present status of paraneuron concept. *Arch Histol Cytol.* 1989; 52 suppl: 1-8.
- Hoyt RF Jr, McNelly NA, Sorokin SP. Dynamics of neuroepithelial body (NEB) formation in developing hamster lung: light microscopic autoradiography after 3H-thymidine labelling in vivo. *Anat Rec.* 1990; 227: 340-50
- Hoyt RF Jr, McNelly NA, McDowell EM, Sorokin SP. Neuroepithelial bodies stimulate proliferation of airway epithelium in fetal hamster lung. *Am J Physiol.* 1991; 260: L234-L240

- Linnoila RI, Nettesheim P, Di Augustine RP. Lung endocrine-like cells in hamsters treated with diethylnitrosamine: alterations in vivo and in cell culture. *Proc Natl Acad Sci USA*. 1981; 78: 5170-4
- MacDowell EM, Sorokin SP, Hoyt RF Jr, Trump BF. An unusual bronchial carcinoid tumor: light and electron microscopy. *Hum Pathol*. 1981; 12 : 338-48.
- Pearse AGE. The cytochemistry and ultrastructure of polypeptide hormone-producing cells of the APUD series and the embryologic, physiologic and pathologic implications of the concept. *J Histochem Cytochem*. 1969; 17: 303-13.
- Polark JM, Bloom SR. Regulatory peptides. Localization and measurement. In: Becker KL, Gazdar AF, eds. *The endocrine lung in health and disease*. Philadelphia: Saunders; 198. P. 300-27.
- Scheuermann DW. Morphology and cytochemistry of the endocrine epithelial system in the lung. *Int Rev Cytol*. 1987; 106: 35-88.
- Simon J-P, Aunis D. Biochemistry of the chromogranin A protein family. *Biochem J*. 1989; 262: 1-13.

### **7.3 Neuroendocrine epithelial cells & pulmonary neuroendocrine cells**

- DiAugustine RP, Sonstegard KS. Neuroendocrinelike (small granule) epithelial cell of the lung. *Environ Health Perspect*. 1984; 55: 271-95.
- Fujita T. concept of paraneurons. *Arch Histol Jpn*. 1977; 40 suppl: 1-2
- Fujita T. Present status of paraneuron concept. *Arch Histol Cytol*. 1989; 52 suppl: 1-8.
- Hoyt RF Jr, McNelly NA, Sorokin SP. Dynamics of neuroepithelial body (NEB) formation in developing hamster lung: light microscopic autoradiography after 3H-thymidine labelling in vivo. *Anat Rec*. 1990; 227: 340-50
- Hoyt RF Jr, McNelly NA, McDowell EM, Sorokin SP. Neuroepithelial bodies stimulate proliferation of airway epithelium in fetal hamster lung. *Am J Physiol*. 1991; 260: L234-L240
- Linnoila RI, Nettesheim P, Di Augustine RP. Lung endocrine-like cells in hamsters treated with diethylnitrosamine: alterations in vivo and in cell culture. *Proc Natl Acad Sci USA*. 1981; 78: 5170-4
- McDowell EM, Sorokin SP, Hoyt RF J, Trump BF. An unusual bronchial carcinoid tumor: light and electron microscopy. *Hum Pathol*. 1981; 12: 338-48.
- Pearse AGE. The cytochemistry and ultrastructure of polypeptide hormone-producing cells of the APUD series and the embryologic, physiologic and pathologic implications of the concept. *J Histochem Cytochem*. 1969; 17: 303-13.
- Polark JM, Bloom SR. Regulatory peptides. Localization and measurement. In: Becker KL, Gazdar AF, eds. *The endocrine lung in health and disease*. Philadelphia: Saunders; 198. P. 300-27.
- Scheuermann DW. Morphology and cytochemistry of the endocrine epithelial system in the lung. *Int Rev Cytol*. 1987; 106: 35-88.
- Simon J-P, Aunis D. Biochemistry of the chromogranin A protein family. *Biochem J*. 1989; 262: 1-13.

### **7.4 Neuroepithelial body structure**

- Adriaensen D, Timmermans JT, Brouns I, et al. Pulmonary intraepithelial vagal nodose afferent nerve terminals are confined to neuroepithelial bodies: an anterograde tracing and confocal microscopy study in adult rats. *Tissue Res*. 1998; 293: 395-405.

- Adriaensen D, Sheurman DW. Neuroendocrine cells and nerves of the lung. *Anat Rev.* 1993; 236: 70-85.
- Adriaensen D, Brouns I, Van Genechten J, and Timmermans JP. Functional morphology of pulmonary neuroepithelial bodies: extremely complex airway receptors. *Anat Rec* 2003;270A:25-40
- Barth PJ, Wolf M, Ramaswamy A. Distribution and number of Clara cells in the normal and disturbed development of the human fetal lung. *Pediatr Pathol.* 1994; 14: 637-51.
- Brouns I, Adriaensen D, Burnstock G, Timmermans JP. Intraepithelial vagal sensory nerve terminals in rat pulmonary neuroepithelial bodies express P2X3 receptors. *Am J Respir Cell Mol Biol.* 2000; 23: 52-61.
- Brouns I, Van Genechten J, Sheuermann D, et al. Neuroepithelial bodies: a morphologic substrate for the link between neuronal nitric oxide and sensitivity to airway hypoxia? *J Comp Neurol.* 2002; 449: 343-54.
- Brouns I, Van Genechten J, Hayashi H, Gajda M, Gomi T, Burnstock G, Timmermans JP, and Adriaensen D. Dual sensory innervation of pulmonary neuroepithelial bodies. *Am J Respir Cell Mol Biol*2003;28:275-285
- Cho T, Chan W, Cutz E. Distribution and frequency of neuroepithelial bodies in post-natal rabbit lung: quantitative study with monoclonal antibody against serotonin. *Cell Tissue Res.* 1989; 255: 353-62.
- Cutz E, Gillan JE, Perrin DG. Pulmonary neuroendocrine cell system: an overview of cell biology. In *pulmonary Disease. Perspectives Pediatr Pathol.* F.B. Askin FB, Langston C, Rosenberg HS, Bertstein J (eds). Basel, Karger. 1995; 18: 32-70.
- Frölich F. Die 'Helle Zelle' der Bronchialschleimhaut und ihre Beziehungen zum problem der Chemoreceptoren. *Frankfurter Z Pathol.* 1949; 60: 517-59.
- Gould Ve, Linnoila RI, Memoli VA, Warren WH. Neuroendocrine components of the bronchiopulmonary tract: hyperplasias, dysplasias, and neoplasms. *Lab invest* 1983; 49: 519-37.
- Haller CJ. A Scanning and transmission electron microscopic study of the development of the surface structure of neuroepithelial bodies in the mouse lung. *Micron.* 1994; 25: 527-38.
- Hartness ME, Lewis A, Searle GJ, et al. Combined antisense and pharmacological approaches implicate hTASK as a airway O<sub>2</sub> sensing K<sup>+</sup> channel. *J Biol Chem.* 2001; 276: 26499-508.
- Hong KV, Reynolds SD, Giangreco A, et al. Clara cell secretory protein-expressing cells of the neuroepithelial body microenvironment include a label-retaining subset and are critical for epithelial renewal after progenitor depletion. *Am J Respir Cell Mol Biol* 2001;24:671-681
- Hoyt RF Jr, Sorokin SP, McDowell EM, McNelly NA. Neuroepithelial bodies and growth of the airway epithelium in developing hamster lung. *Anat. Rec.* 1993; 236: 15-22.
- Hoyt RF Jr, McNelly NA, McDowell EM, Sorokin SP. Neuroepithelial bodies stimulate proliferation of airway epithelium in fetal hamster lung. *Am J Physiol.* 1991; 260: L234-L240
- Kemp PJ, Searle GJ, Hartness ME, et al. Acute oxygen sensing in cellular models: relevance to the physiology of pulmonary neuroepithelial and carotid bodies. *Anat Rec* 2003;270A:41-50

- Khoor A, Gray ME, Singh G, Stahiman MT. Oncology of Clara cell-specific protein and its mRNA: their association with neuroepithelial bodies in human fetal lung and in bronchiopulmonary dysplasia. *J Histochem Cytochem.* 1996; 44: 1429-38.
- Lauweryns JM, Goddeeris P. Neuroepithelial bodies in the human child and adult lung. *Am Rev Respir Dis.* 1975; 111: 469-76.
- Lauweryns JM, Cokelaere M, Theunynck P. Neuroepithelial bodies in the respiratory mucosa of various mammals: a light optical, histochemical and ultrastructural investigation. *Z. ZelforshMidrosk Anat.* 1972; 135: 569-92.
- Linnoila RI. Effects of diethylnitrosamine on lung neuroendocrine cells. *Exp Lung Res* 1982; 3: 225-36.
- Magdaline SM, Barrish F, Fingold MJ, DeMayo FJ. Investigating stem cells in the lung *Adv Pediatr.* 1998; 45: 363-97.
- Reynolds SD, Giangreco A, Power JH et al. Neuroepithelial bodies of pulmonary airways serve as a reservoir of progenitor cells capable of epithelial regeneration. *Am J Pathol* 2000; 156: 269-278
- Rocall M, Springall DR, Maggioni M, et al. Early changes in the calcitonin generelated peptide (CGRP) content of pulmonary endocrine cells concomitant with vascular remodelling in the hypoxic rat. *Am J respire Cell Mol Biol.* 1993; 9: 467-74.
- Sorokin SP, Hoyt F. Neuroepithelial bodies and solitary small-granule cells. In *Lung cell Biology*. D. Massaro, editor. Marcel Dekker. New York; 1989. P. 191-344.
- Spindel ER. Roles of bombesin-like peptides in lung development and lung injury. *Am J Respir Cell Mol Biol.* 1996; 14: 407-8.
- Stevens TP, McBride JT, Peake JL, et al. Cell proliferation contributes to PNEC hyperplasia after acute airway injury. *Am J Physiol Lung cell Mol Physiol.* 1997; 272: L486-L493.
- Sunday ME, Willet CG, Patidar K, Graham SA. Modulation of oncogene and tumor suppressor gene expression in ahamster model of chronic lung injury with varying degrees of pulmonary neuroendocrine cell hyperplasia. *Lab Invest.* 1994; 70: 875-88.
- Van Lommel A, Bolle T, Fannes W, et al. The pulmonary neuroiendocrine system:the past decade. *Arch Histol Cytol* 1999;62:1-16
- Van Lommel A and Lauwerys JM. Neuroepithelial bodies in the Fawn Hooded rat lung: morphological and neuroanatomical evidence for a sensory innervation. *J Anat.* 1993; 183: 553-66.
- Van Genechten J, Brouns I, Burnstock G, et al. Quantification of neuroepithelial bodies and their innervation in Fawn-Hooded and Wistar rat lungs. *Am. J. Resp Cell Mol Biol.* 2004; 30: 20-30.

### **7.5 Stem cells and neuroepithelial bodies**

- Bishop AE. Pulmonary epithelial stem cells. *Cell Prolif.* 2003; 37: 89-96.
- Boers JE, Ambergen AW, Thunnissen FB. Number and proliferation of clara cells in normal human airway epithelium. *Am J Respir Crit Care Med.* 1999; 159: 1585.
- Emura E. Stem cells of the respiratory tract. *Paed Respir Rev.* 2002; 3: 36.
- Gosbey JR. Pulmonary neuroendocrine cell system in pediatric and adult lung disease. *Microsc Res Techn.* 1997; 37: 107.
- Inayama Y, Hook GE, Brody AR, et al. The differentiation potential of tracheal basal cells. *Lab Invest.* 1988; 58: 706.

- Linnoila RI, Mulshine JL, Steinberg SM, et al. Neuroendocrine differentiation in endocrine and nonendocrine lung carcinomas. *Am J Clin Pathol*. 1988; 90: 641-52.
- Linnoila RI. Effects of diethylnitrosamine on lung neuroendocrine cells. *Exp Lung Res* 1982; 3: 225-36.
- Liu JY, Nettesheim P, Randall SH. Growth and differentiation of tracheal epithelial progenitor cells. *Am J Physiol*. 1994; 266: 96.
- McDowell EM, Trump BF. Pulmonary small cell carcinoma showing tripartite differentiation in individual cells. *Hum Pathol*. 1981; 12: 296-94.
- Nettesheim P, jetten AM, Inayama Y, et al. Pathways of differentiation of airway epithelial cells. *Environ. Health Perspect*. 1990; 85: 317.
- Reynolds SD, Giangreco A, Power JH et al. Neuroepithelial bodies of pulmonary airways serve as a reservoir of progenitor cells capable of epithelial regeneration. *Am J Pathol* 2000; 156: 269-278
- Reynolds SD, Hong KU, Giangreco A, et al. Conditional Clara cells ablation reveals a self-renewing progenitor function of pulmonary neuroendocrine cells. *Am J Physiol Lung Cell Mol Physiol* 2000;278:L1256-L1263
- Sell S, Pierce G. Biology of disease: Maturation arrest of stem cell differentiation is a common pathway for the cellular origin of teratocarcinomas and epithelial cancers. *Lab Invest*. 1994; 70: 6-22.
- Sunday ME, Willet CG, Patidar K, Graham SA. Modulation of oncogene and tumor suppressor gene expression in hamster model of chronic lung injury with varying degrees of pulmonary neuroendocrine cell hyperplasia. *Lab Invest*. 1994; 70: 875-88.
- Sunday ME, Willet CG. Induction and spontaneous regression of intense pulmonary neuroendocrine cell differentiation in a model of preneoplastic lung injury. *Cancer Res*. 1992; 52: 2677s
- Taipale J, Beachy PA. The hedgehog and Wnt signalling pathways in cancer. *Nature*. 2001; 441: 349-54.
- Travis WD, Colby TV, Corrin B, et al. *Histological Typing of Lung and pleural tumors* (Springer, Berlin) 1999.
- Watkins DN, Berman DM, Burkholder SG, et al. Hedgehog signalling Within Airway epithelial progenitors and in small cell lung cancer. *Nature* 2003; 422: 313-7.

### **7.6 Pathology of neuroendocrine tumours of the lung**

- Aguayo SM, Millar YE, Waldron JA Jr et al. Brief report: idiopathic diffuse hyperplasia of pulmonary neuroendocrine cells and airways disease. *N Engl J med* 1992;327:1285-1288
- Arrigoni MG, Woolner LB, Bernatz PE. Atypical carcinoid tumors of the lung. *J Thorac Cardiovasc Surg* 192;64:413-421
- Aubry MC, Thomas CF Jr, Jett JR, Swensen SJ, Myers JL. Significance of multiple carcinoid tumors and tumorlets in surgical lung specimens: analysis of 20 patients. *Chest* 2007;131:1635-1643
- Beasley MB, Brambilla E, Travis WD. The 2004 World Health Organization classification of lung tumors. *Semin Roentgenol* 2005;40:90-97
- Brambilla E, Travis WD, Colby TV, Corrin B, Shimosato Y. The new World Health Organization classification of lung tumors. *Eur Respir J* 2001;18:1059-1068

- Cerilli LA, Ritter JH, Mills SE, Wick MR. Neuroendocrine neoplasms of the lung. *Am J Clin Pathol* 2001;116:S65-S96
- Cutz E. Neuroendocrine cells of the lung. An overview of morphologic characteristics and development. *Exp Lung Res* 1982;3:185-208
- Cutz E, Gillan JE, Perrin DG. Pulmonary neuroendocrine cell system: an overview of cell biology and pathology with emphasis on pediatric lung disease. In: Askin FB, Langston C, Rosemberg HS, Bertnstein J (eds). *Pulmonary Disease*. Karger:Basel, 1995
- Churg A, Warnock ML. Pulmonary tumorlet. A form of peripheral carcinoid. *Cancer* 1976;37:1469-1477
- Fink G, Krelbaum T, Yellin A, et al. Pulmonary carcinoid presentation, diagnosis, and outcome in 142 cases in Israel and review of 640 cases from the literature. *Chest* 2001;119:1647-1651
- Franklin WA. Diagnosis of lung cancer: pathology of invasive and preinvasive neoplasia. *Chest* 200;117:80S-89S
- Hage R, de la Riviere AB, Seldenrijk CA, van den Bosch JM. Update in pulmonary carcinoid tumors: a review article. *Ann Surg Oncol* 2003;10:697-704
- Hiroshima K, Iyoda A, Shida T, et al. Distinction of pulmonary large cell neuroendocrine carcinoma from small cell lung carcinoma: a morphological, immunohistochemical, and molecular analysis. *Mod Pathol* 2006;19:1358-1368
- Jiang SX, Kameya T, Shoji M, Dobashi Y, Shinada J, Yoshimura H. Large cell neuroendocrine carcinoma of the lung: a histologic and immunohistochemical study of 22 cases. *Am J Surg Pathol* 1998;22:5265-537
- Jung KJ, Lee KS, Han J, et al. Large cell neuroendocrine carcinoma of the lung: clinical, CT, and pathologic findings in 11 patients. *J Thorac Imaging* 2001;16:156-162
- Kaufmann O, Georgi T, Dietel M. Utility of 123C3 monoclonal antibody against CD56 (NCAM) for the diagnosis of small cell carcinomas on paraffin sections. *Hum Pathol* 1997;28:1373-1378
- Kloppel G. Tumour biology and histopathology of neuroendocrine tumours. *Best Pract Res Clin Endocrinol Metab* 2007;21:15-31
- Kulke MH, Mayer RJ. Carcinoid tumors. *N Engl J Med* 1999;340:858-869
- Lantuejoul S, Moro D, Michalides RJ, et al. Neural cell adhesion molecules (NCAM) and NCAM-PSA expression in neuroendocrine lung tumors. *Am J Surg Pathol* 1998;22:1267-1276
- Mazieres J, Daste G, Molinier L, et al. Large cell neuroendocrine carcinoma of the lung: pathological study and clinical outcome of 18 resected cases. *Lung Cancer* 2002;37:287-292
- Modlin IM, Sandor A. An analysis of 8305 cases of carcinoid tumors. *Cancer* 1997;79:813-829
- Modlin IM, Lye KD, Kidd M. A 5-decade analysis of 13,715 carcinoid tumors. *Cancer* 2003;97:934-959
- Muller NL, Miller RR. Neuroendocrine carcinomas of the lung. *Semin Roentgenol* 1990;25:96-104
- Nowell PC. The clonal evolution of tumor cell populations. *Science* 1976;194:23-28
- Nylen ES, Becker KL. The diffuse neuroendocrine system. In: Becker KL (ed). *Principles and Practice of Endocrinology and Metabolism*, 3<sup>rd</sup> edn. Lippincott Williams and Wilkins: Philadelphia, 2001

- Oberg K. Carcinoid tumors: current concepts in diagnosis and treatment. *Oncologists* 1998;3:339-345
- Oshiro Y, Kusumoto M, Matsuno Y, et al. CT findings of surgically resected large cell neuroendocrine carcinoma of the lung in 38 patients. *AJR Am J Roentgenol* 2004;182:87-91
- Quoix E, Fraser R, Wolkove N, Finkelstein H, Kreisman H. Small cell lung cancer presenting as a solitary pulmonary nodule. *Cancer* 1990;66:577-582
- Rosado de Christenson ML, Abbott GF, Kirejczyk WM, Galvin JR, Travis WD. Thoracic carcinoids: radiologic-pathologic correlation. *RadioGraphics* 1999;19:707-736
- Skuladottir H, Hirsch FR, Hansen HH, et al. Pulmonary neuroendocrine tumors: incidence and prognosis of histological subtypes. A population-based study in Denmark. *Lung Cancer* 2002;37:127-135
- Takei H, Asamura H, Maeshima A, et al. Large cell neuroendocrine carcinoma of the lung: a clinicopathologic study of eight-seven cases. *J Thorac Cardiovasc Surg* 2002;124:285-292
- Travis WD, Linnoila RI, Tsokos MG, et al. Neuroendocrine tumors of the lung with proposed criteria for large-cell neuroendocrine carcinoma. An ultrastructural, immunohistochemical, and flow cytometric study of 35 cases. *Am J Surg Pathol* 1991;15:529-553
- Travis WD, Rush W, Flieder DB, et al. Survival analysis of 200 pulmonary neuroendocrine tumors with clarification of criteria for atypical carcinoid and its separation from typical carcinoid. *Am J Surg Pathol* 1998;22:934-944
- Travis WD, Brambilla E, Muller-Hermelink H, Harris C. World Health Organization Classification of Tumors. Pathology and Genetics of Tumors of the Lung, Pleura, Thymus and Heart. Lyon, France. IARC Press; 2004
- Vadasz P, Palffy G, Egervary M, Schaff Z. Diagnosis and treatment of bronchial carcinoid tumors: clinical and pathological review of 120 operated patients. *Eur J Cardiothorac Surg* 1993;7:8-11
- Van Lommel A, Bolle T, Fannes W, et al. The pulmonary neuroendocrine system: the past decade. *Arch Histol Cytol* 1999;62:1-16
- Van Lommel A. Pulmonary neuroendocrine cells (PNEC) and neuroepithelial bodies (NEB): chemoreceptors and regulators of lung development. *Paediatric Respir Rev* 2001;2:171-176
- Warren WH, Could VE. Neuroendocrine tumors of the bronchopulmonary tract: a reappraisal of their classification after 20 years. *Surg Clin North Am* 2002;82:525-540
- Wistuba II, Gazdar AF. Lung cancer preneoplasia. *Annu Rev Pathol* 2006;1:331-348
- Yabuuchi H, Murayama S, Sakai S, et al. Resected peripheral small cell carcinoma of the lung: computed tomographic-histologic correlation. *J Thorac Imaging* 1999;14:105-108

### **7.7 The neuroendocrine differentiation in lung tumours**

- Abbott G, Papotti M, Viberti L, et al. Chromogranin A gene expression in non-small cell lung carcinomas. *J Pathol*. 1998; 186: 151-156.
- Baldi A, Groger AM, Esposito V, et al. Neuroendocrine differentiation in non-small cell lung carcinomas. *In Vivo*. 2000; 14: 109-114.

- Bhattacharjee A, Richards WG, Stauton J, et al. Classification of human lung carcinomas by mRNA expression profiling reveals distinct adenocarcinoma subclasses. *PNAS USA* 2001;98:13790-13795.
- Beer DG, Kardina SL, Huang CC, et al. Gene-expression profiles predict survival of patients with lung adenocarcinoma. *Nat Med* 2002;8:816-824.
- Bobrow LG, Happerfield L, Patel K. The expression of small cell lung cancer related antigens in foetal lung and kidney. *Br J Cancer* 1991; 14:56-58.
- Brambilla E, Lantuejoul S, Sturm N. Divergent differentiation in neuroendocrine lung tumors. *Semin Diagn Pathol.* 2000; 17: 138-148.
- Carles J, Rosell R, Ariza A, et al. Neuroendocrine differentiation as a prognostic factor in non-small cell lung cancer. *Lung Cancer.* 1993; 10: 209-219.
- Freeman M, Gurdon JB. Regulatory principles of developmental signaling . *Annu Rev Cell Dev Biol* 2002;18:515-539
- Garber MF, Troyanskaya OG, Schluens K, et al. Diversity of gene expression in adenocarcinoma of the lung. *PNAS USA* 2001;98:13784-13789
- Graziano SL, Tatum AH, Newman NB, et al. The prognostic significance of neuroendocrine markers and carcinoembryonic antigen in patients with resected stage I and II non-small cell lung cancer. *Cancer Res.* 1994; 54: 2908-2913.
- Iyoda A, Hiroshima K, Toyozaki T, et al. Clinical characterization of pulmonary large cell neuroendocrine carcinoma and large cell carcinoma with neuroendocrine morphology. *Cancer* 2001; 91: 1992-2000.
- Linnoila RI, Mulshine JL, Steinberg SM, et al. Neuroendocrine differentiation in endocrine and nonendocrine lung carcinomas. *Am J Clin Pathol.* 1998; 90: 641-652.
- Skov BG, Sorensen JB, Hirsch FR, et al. Prognostic impact of histologic demonstration of chromogranin A and neuron specific enolase in pulmonary adenocarcinoma. *Ann Oncol.* 1991; 2: 355-360.
- Travis WD, Linnoila RI, Tsokos MG, et al. Neuroendocrine tumors of the lung with proposed criteria for large-cell neuroendocrine carcinoma. An ultrastructural, immunohistochemical, and flow cytometric study of 35 cases. *Am J Surg Pathol.* 1991; 15: 529-553.
- World Health Organization. Epithelial tumours. In: *Histological typing of lung and pleural tumours.* 3<sup>rd</sup> ed. Berlin: Springer-Verlag, 1999:25-47.
- World Health Organization. *International Histological Classification of Tumours. Histological Typing of Lung and Pleural Tumours.* 3<sup>rd</sup> ed. Geneva: WHO; 1999.
- Yesner R. Heterogeneity of so-called neuroendocrine lung tumors. *Exp Mol Pathol* 2001; 70:179-182

### **7.8 Embryological signalling pathways in lung tumours**

- Adhikary S, Eilers M. Transcriptional regulation and transformation by Myc proteins. *Nat Rev Mol Cell Biol* 2005; 6:635-645.
- Apelqvist A, Li H, Sommer L, Beatus P, Anderson DJ, Honjo T, Hrabe de Angelis M, Lendahl U, Edlund H. Notch signaling controls pancreatic cells differentiation. *Nature* 1999; 400: 877-881.
- Artavanis-Tsakonas S, Rand MD, Lake RJ. Notch signalling: cell fate control and signal integration in development. *Science* 284:770-776, 1999.



- Barbareschi M, Girlando S, Mauri FA, et al. Tumor suppressor gene product, proliferation and differentiation markers in lung neuroendocrine neoplasms. *J Pathol* 1992; 166: 343-350.
- Bellusci S, Furuta Y, Rush MG, Henderson R, Winnier G, Hogan B. Involvement of Sonic Hedgehog (Shh) in mouse embryonic lung growth and morphogenesis. *Development* 1997; 124: 53-63.
- Bellusci S, Furuta Y, Rush MG, Henderson R, Winnier G, Hogan BL. Involvement of Sonic hedgehog (Shh) in mouse embryonic lung growth and morphogenesis, *Development* 1997; 124: 53-63.
- Bellusci S, Grindley J, Emoto H, Itoh N, Hogan BL. Fibroblast growth factor 10 (FGF10) and branching morphogenesis in the embryonic mouse lung. *Development* 1997; 124: 4867-4878.
- Bellusci S, Henderson R, Winnier G, Oikawa T, Hogan B. Evidence from normal expression and targeted misexpression that bone morphogenetic protein-4 (Bmp-4) plays a role in mouse embryonic lung morphogenesis. *Development* 1996; 122: 1693-1702.
- Borges MW, Linnoila RI, van de Velde HJ, Chen H, et al. An achaete-scute homologue essential for neuroendocrine differentiation in the lung. *Nature* 1997; 386:852-855
- Bray S. Notch signaling in *Drosophila*: three ways to use a pathway. *Semin Cell Dev* 1998;9:591-597.
- Broers JL, Viallet J, Jensen SM, et al. Expression of c-myc in progenitor cells of the bronchopulmonary epithelium and in a large number of non-small cell lung cancers. *Am J Respir Cell Mol Biol* 1993; 9:33-43.
- Cagle PT, El-Naggar AK, Xu HJ, et al. Differential retinoblastoma protein expression in neuroendocrine tumors of the lung. *Ann J Pathol* 1997, 150:393-400.
- Calvo R et al. Altered HOX and WNT7A expression in human lung cancer. *Proc Natl Acad Sci USA*. 2000; 97: 12776-12781.
- Chen H, Thiagalingam A, Chopra H, Borges MW, Feder JN, Nelkin BD, et al. Conservation of the *Drosophila* lateral inhibition pathway in human lung cancer: a hairy-related protein (HES-1) directly represses achaete-scute homolog-1 expression. *PNAS USA* 1997; 94:5355-5360
- Chen H, Thiagalingam A, Chopra H, Borges MW, et al. Conservation of the *Drosophila* lateral inhibition pathway in human lung cancer: a hairy-related protein (HES-1) directly represses achaete-scute homologue-1 expression. *PNAS USA* 1997; 94:5355-5360
- Clarke RB, Anderson E, Howell A, Potten CS. Regulation of human breast epithelial stem cells. *Cell Prolif* 2003; 36:45-58
- Dang TP, Eichenberg S, Gonzalez A, et al. Constitutive activation of Notch3 inhibits terminal differentiation in lungs of transgenic mice. *Oncogene* 2003; 22:1988-1997
- Dang TP, Gazdar AF, Virmani AK, Sepetavec T, Hande KR, Minna JD, Roberts JR, Carbone DP. Chromosome 19 translocation, overexpression of Notch3, and human lung cancer. *J Natl. Cancer Inst.* 2000; 92: 1355-1357.
- Dang TP, gazdar AF, Virmani AK, Sepetavec T, Hande KR, Minna JD, et al. Chromosome 19 translocation, overexpression of Notch3, and human lung cancer. *J Natl cancer Inst* 2000; 92:1355-1357
- Daniel VC, Peacock CD, Watkins DN. Developmental signaling pathways in lung cancer. *Respirology* 2006; 11:234-240

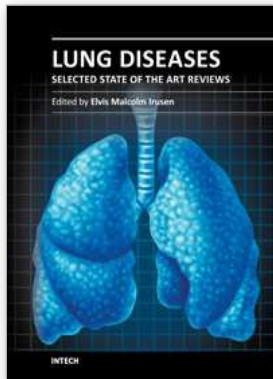
- Eberhard DA, Johnson BE, Amler LC, et al. Mutations in the epidermal growth factor receptor and in KRAS are predictive and prognostic indicators in patients with non-small-cell lung cancer treated with chemotherapy alone and in combination with erlotinib. *J Clin Oncol* 2005; 23:5900-5909
- Fitzgerald K, Harrington A, Leder P. Ras pathway signals are required for notch-mediated oncogenesis. *Oncogene* 19:4191-4198
- Fong KM, Sekido Y, Minna JD. Molecular pathogenesis of lung cancer. *J Throat Cardiovasc Surg* 1999; 118:1136-1152
- Franklin WA, Veve R, Hirsch FR, et al. Epidermal growth factor receptor family in lung cancer and premalignancy. *Semin Oncol* 2002; 29:3-14
- Fujino S, Enokibori T, Tezuka N, et al. A Comparison of epidermal growth factor receptor levels and other prognostic parameters in non-small cell lung cancer. *Eur J Cancer* 1996; 32A:2070-2074
- Fukui T, Kondo M, Ito G, et al. Transcriptional silencing of secreted frizzled related protein 1 (SFRP1) by promoter hypermethylation in non-small-cell lung cancer. *Oncogene* 2005; 24:6323-6327
- Gouyer V, Gazzeri S, Brambilla E, et al. Loss of heterozygosity at the RB locus correlates with loss of RB protein in primary malignant neuro-endocrine lung carcinomas. *Int J Cancer* 1994, 58:818-824.
- Gray GE, Mann RS, Mitsiadis E, Henrique D, Carnagin ML, Banks A, et al. Human ligands of the Notch receptor. *Am J Pathol* 1999; 154:785-794
- Haruki K, Kawaguchi KS, Eichenberg S, et al. Dominant-negative Notch3 receptor inhibits mitogen-activated protein kinase pathway and the growth of human lung cancers. *Cancer Res* 2005; 65:3555-3561
- He B et al. A monoclonal antibody against Wnt-1 induces apoptosis in human cancer cells. *Neoplasia* 2004; 6: 7-14.
- He B, You L, Uematsu K, et al. A monoclonal antibody against Wnt-1 induces apoptosis in human cancer cells. *Neoplasia* 2004; 6:7-14
- Huang CL et al. Wnt5a expression is associated with the tumor proliferation and the stromal vascular endothelial growth factor – an expression in non-small-cell lung cancer. *J Clin Oncol* 2005; 23: 8765-8773.
- Ito T, Udaka N, Yazawa T, Okudela K, et al. Basic helix-loop-helix transcription factors regulate the neuroendocrine differentiation of fetal mouse pulmonary epithelium. *Development* 2000; 127:3913-3921
- Jan YN, Jan LY. Genetic control of cell fate specification in *Drosophila* peripheral nervous system. *Annu Rev Genet* 28:373-393, 1994.
- Jensen J, Pedersen EE, Galante P, Hald J, Heller RS, Ishibashi M, Kageyama R, Guillemot F, Serup P, Madsen OD. Control of endodermal endocrine development by Hes-1. *Nat. Genet.* 2000; 24: 36-44.
- Jiang SX, Kameya T, Asamura H, Umezawa A, et al. hASH1 expression is closely correlated with endocrine phenotype and differentiation extent in pulmonary neuroendocrine tumors. *Modern Pathol* 2004; 17:222-229
- Kageyama R, Nakanishi S. Helix-loop-helix factors in growth and differentiation of the vertebrate nervous system. *Curr Opin Genet Dev* 7:659-665, 1997.
- Katoh M. Differential regulation of Wnt2 and Wnt2B expression in human cancer. *Int J Mol Med* 2001; 8: 657-660.

- Kegeyama R, Nakanish S. Helix-loop-helix factors in growth and differentiation of the vertebrate nervous system. *Curr Opin Genet Dev* 1997; 7:659-665
- Kunnimalaiyaan M, Chen H. Tumor suppressor role of Notch-1 signaling in neuroendocrine tumors. *The Oncologist* 2007; 12:535-542
- Lai SL, Brauch H, Knutsen T, et al. Molecular genetic characterization of neuroendocrine lung cancer cell lines. *Anticancer Res* 1995, 15:225-232.
- Lebeche D, Malpel S, Cardoso WV. Fibroblast growth factor interactions in the developing lung. *Mech. Dev.* 1999; 86: 125-136.
- Li C, et al. Wnt5a participates in distal lung morphogenesis. *Dev Biol* 2002: 248: 68-81.
- Mazieres J, He B, You L, et al. Wnt inhibitory factor-1 is silenced by promoter hypermethylation in human lung cancer. *Cancer Res* 2004; 64:4717-4720
- Miki M, Ball DW, Linnoila I. Insights into the achaete-scute homologue-1 gene (hASH1) in normal and neoplastic human lung. *Lung Cancer* 2011;
- Miyamoto Y, Maitra A, Ghosh B, Zechner U, Argani P, Iacobuzio-Donahue CA, et al. Notch mediates TGF alpha-induced changes in epithelial differentiation during pancreatic tumorigenesis. *Cancer Cell* 2003; 3:565-576
- Nasgashio R, Sato Y, Matsumoto T, Kageyama T, et al. The balance between the expression of hASH1 and HES1 differs between large cell neuroendocrine carcinoma and small cell carcinoma of the lung. *Lung Cancer* 2011;
- Nau MM, Brooks BJ Jr, Carney DN, et al. Human small-cell lung cancers show amplification and expression of the M-Myc gene. *PNAS USA* 1986; 83:1092-1096
- Nie L, Xu M, Vladimirova A, Sun XH. Notch-induce E2A ubiquitination and degradation are controlled by MAP kinase activities. *EMBO J* 2003;22:5780-5782
- Normanno N, Bianco C, Strizzi L, et al. The ErbB receptors and their ligands in cancer: an overview. *Curr Drug Targets* 2005;6:243-257
- Pao W, Wang TY, Riely GJ, et al. KRAS mutations and primary resistance of lung adenocarcinomas to gefitinib or erlotinib. *PLoS Med* 2005;2:E17
- Price JV, Savenye ED, Lum D, and Brechtkrutz A. *Genetics* 1997; 147:1139-1153
- Przygodzki RM, Finkelstein SD, Langer JC, et al. Analysis of p53, K-ras2, and C-raf-1 in pulmonary neuroendocrine tumors: correlation with histological subtype and clinical outcome. *Am J Pathol* 1996, 148:1531-1541.
- Radtke F, Raj K. The role of Notch in tumorigenesis: oncogene or tumor suppressor. *Nature rev Cancer* 2003; 3:756-767
- Ralston J, Chiriboga, Nonaka D. MASH1: a useful marker in differentiating pulmonary small cell carcinoma from Merkel cell carcinoma. *Modern Pathol* 2008; 21:1357-1362
- Riely GJ, Kris MG, Rosenbaum D, et al. Frequency and distinctive spectrum of KRAS mutations in never smokers with lung adenocarcinoma. *Clin Cancer Res* 2008; 14:5731-5734
- Rodenhuis S, Slebos RJ, Clinical significance of ras oncogene activation in human lung cancer. *Cancer Res* 1992; 52:S2665-S2669
- Rubin LL, de Sauvage FJ. Targeting the Hedgehog pathway in cancer. *Nat rev Drug Discov* 2006;5:1026-1033
- Rusch V, Baselga J, Cordon-Cardo C, et al. Differential expression of epidermal growth factor and its ligands in primary non-small cell lung cancers and adjacent benign lung. *Cancer Res*; 53:2379-2385

- Sasai Y, Kageyama R, Tagawa Y, Shiemoto R, et al. Two mammalian helix-loop-helix factors structurally related to *Drosophila hairy* and *Enhancer of split*. *Genes Dev* 6:2620-2634, 1992.
- Shu W et al. Wnt7b regulates mesenchymal proliferation and vascular development in the lung. *Development* 2002; 129: 4831-4842.
- Sriuranpong V, Borges MW, Ravi RK, Arnold DR, Nelkin BD, Baylin SB, et al. Notch signaling induces cell cycle arrest in small cell lung cancer cells. *Cancer Res* 2001; 61:3200-3205
- Sriuranpong V, Borges MW, Strock CL, Nakakura EK, Watkins DN, Blaumuller CM, et al. Notch signaling induces rapid degradation of achaete-scute homolog.1. *Mol Cell Biol* 2002; 22:3129-3139

### 7.10 The neuroendocrine pathway of differentiation

- Uematsu K, He B, You L, et al. Activation of the Wnt pathway in non small cell lung cancer: evidence of dishevelled overexpression. *Oncogene* 2003; 22:7218-7221
- Wang XY, el Dakir H, Naizhen X, et al. Achaete-scute-homolog-1 linked to remodeling and preneoplasia of pulmonary epithelium. *Lab Invest* 2007; 87:527-539
- Watkins DN, Berman DM, Burkholder SG, et al. Hedgehog signalling within airway epithelial progenitors and in small-cell lung cancer. *Nature* 2003; 422:313-317
- Weidenfeld J et al. The WNT7b promoter is regulated by TTF-1, GATA6, and Foxa2 in lung epithelium. *J Biol Chem* 2002; 277: 21061-21070.
- Weijzen S, Rizzo P, Braid M, Vaishnav R, Jonkheer SM, Zlobin A, et al. Activation of Notch-1 signaling maintains the neoplastic phenotype in human Ras-transformed cells. *Nat med* 2002; 8:979-986
- Winn Ra et al. Restoration of Wnt-7a expression reverses non-small cell lung cancer cellular transformation through frizzled-9-mediated growth inhibition and promotion of cell differentiation. *J Biol Chem* 2005; 280: 19625-19634.
- Winn RA, Van Scoyk M, Hammond M, et al. Antitumorigenic effect of Wnt 7a and Fzl 9 in non-small cell lung cancer cells is mediated through ERK-5-dependent activation of peroxisome proliferator-activated receptor gamma. *J Biol Chem* 2006; 281:26943-26950
- Wissman C, Wild PJ, Kaiser S, et al. WIF1, a component of the Wnt pathway, is down-regulated in prostate, breast, lung and bladder cancer. *J Pathol* 2003; 201:204-212
- Yamaguchi T et al. A Wnt5a pathway underlies outgrowth of multiple structures in the vertebrate embryo. *Development* 1999; 126: 1211-1223.
- Yoshida M C et al. Human HST1 (HSTF1) gene maps to chromosome band 11q13 and coamplifies with the INT2 gen in human cancer. *Proc Natl Acad Sci USA* 1998; 85: 4861-4864.
- You L et al. Inhibition of Wnt-2-mediated signaling induces programmed cell death in non small cell lung cancer cells. *Oncogene* 2004; 23: 6170-6174.
- You L, He B, Xu Z, et al. Inhibition of Wnt-2-mediated signaling induce programmed cell death in non-small-cell lung cancer cells. *Oncogene* 2004; 23:6170-6174
- Zayzafoon M, Abdulkadir SA, McDonald JM. Noct signaling and ERK activation are important for the osteomimetic properties of prostate cancer bone metastatic cell lines. *J Biol Chem* 2004; 279:3662-3670



## **Lung Diseases - Selected State of the Art Reviews**

Edited by Dr. Elvisegran Malcolm Irusen

ISBN 978-953-51-0180-2

Hard cover, 690 pages

**Publisher** InTech

**Published online** 02, March, 2012

**Published in print edition** March, 2012

The developments in molecular medicine are transforming respiratory medicine. Leading clinicians and scientists in the world have brought their knowledge and experience in their contributions to this book. Clinicians and researchers will learn about the most recent advances in a variety of lung diseases that will better enable them to understand respiratory disorders. This treatise presents state of the art essays on airways disease, neoplastic diseases, and pediatric respiratory conditions. Additionally, aspects of immune regulation, respiratory infections, acute lung injury/ARDS, pulmonary edema, functional evaluation in respiratory disorders, and a variety of other conditions are also discussed. The book will be invaluable to clinicians who keep up with the current concepts, improve their diagnostic skills, and understand potential new therapeutic applications in lung diseases, while scientists can contemplate a plethora of new research avenues for exploration.

### **How to reference**

In order to correctly reference this scholarly work, feel free to copy and paste the following:

Guadalupe Aparicio Gallego, Vanessa Medina Villaamil, Ana Capdevila Puerta, Enrique Grande Pulido and L.M. Antón Aparicio (2012). Neuroendocrine Tumours of the Lung, Lung Diseases - Selected State of the Art Reviews, Dr. Elvisegran Malcolm Irusen (Ed.), ISBN: 978-953-51-0180-2, InTech, Available from: <http://www.intechopen.com/books/lung-diseases-selected-state-of-the-art-reviews/neuroendocrine-tumours-of-the-lung>

**INTECH**  
open science | open minds

### **InTech Europe**

University Campus STeP Ri  
Slavka Krautzeka 83/A  
51000 Rijeka, Croatia  
Phone: +385 (51) 770 447  
Fax: +385 (51) 686 166  
[www.intechopen.com](http://www.intechopen.com)

### **InTech China**

Unit 405, Office Block, Hotel Equatorial Shanghai  
No.65, Yan An Road (West), Shanghai, 200040, China  
中国上海市延安西路65号上海国际贵都大饭店办公楼405单元  
Phone: +86-21-62489820  
Fax: +86-21-62489821

© 2012 The Author(s). Licensee IntechOpen. This is an open access article distributed under the terms of the [Creative Commons Attribution 3.0 License](#), which permits unrestricted use, distribution, and reproduction in any medium, provided the original work is properly cited.