

The Future of Cardiac Mapping

Pascal Fallavollita

*Chair for Computer Aided Medical Procedures & Augmented Reality,
Technische Universität München,
Germany*

1. Introduction

Severe disorders of the heart rhythm that can lead to sudden cardiac death (SCD) are often treated by radio-frequency (RF) catheter ablation. Using fluoroscopy as an imaging guide, the procedure consists of inserting a catheter inside the heart, near the area from which originates the abnormal cardiac electrical activity, then delivering RF currents through the catheter tip to ablate the arrhythmogenic area. Fluoroscopy is a conventional mapping technique that has been extremely useful in understanding and managing simpler arrhythmias. While the fluoroscopic procedure is still used in over 90% of ablations, its limitation in providing a reliable 3D geometry is evident when working upon complex cases like ventricular tachycardia (VT) or atrial fibrillation (AF) ablation. In turn, this results in impaired efficacy and length of the procedure lasting for several hours. Even though operator experience has decreased procedure times, radiation hazards still remain a major issue for the patient.

Recent 3D systems which integrate electrophysiological signals with anatomy to provide (3D+ t) geometry are extremely useful in situations where radiation needs to be limited as much as possible, and to increase the efficiency and shorten the duration of RF catheter ablation. During intracardiac mapping, it is not unusual to find sites at which the operator feels ablation is likely to succeed. Three-dimensional systems not only allow the surgeon to mark precise ablation points but also facilitate fixing reference points if the ablation process has to be repeated (Rajnish, 2009).

This chapter will summarize the most recent developments in catheter navigation and three-dimensional electroanatomic mapping. Conventional fluoroscopy techniques will be described followed by the CARTO and Ensite non-fluoroscopic mapping systems. Advances in ultrasound imaging for cardiac ablation guidance, and futuristic remote navigation technologies such as the Stereotaxis Magnetic Navigation system and the Hansen Sensei Robotic Catheter system will conclude the read.

2. Conventional catheter mapping

Every clinical electrophysiology (EP) laboratory is equipped with an X-ray system designed to provide fluoroscopic imaging of the heart. For many years this was the only form of procedural imaging available. A common characteristic of all X-ray images is that the soft

tissue of the myocardium cannot be visualized (Figure 1), nevertheless, the walls of the left atrium can be indirectly assessed by bolus injection of contrast, which can be augmented by manoeuvres that minimize atrial emptying such as adenosine or rapid ventricular pacing. However, the major disadvantage of using X-ray fluoroscopy as the sole imaging modality is that all images obtained are two-dimensional representations of three-dimensional structures (D'Silva & Wright, 2011).

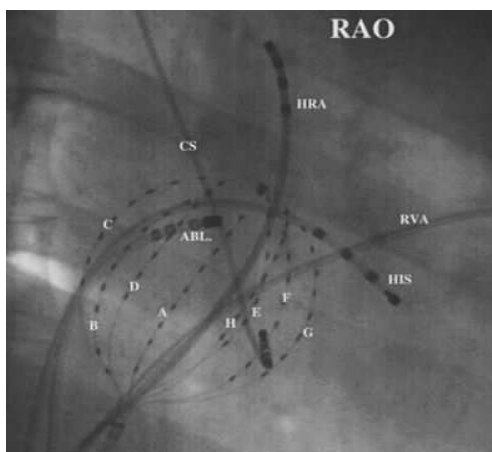


Fig. 1. A conventional fluoroscopy image showing a multielectrode basket array and other standard catheters inside the right atrium. Letters A to H identify basket splines and ABL indicates ablation catheter.

Image taken from Schmitt et al., 1999. (doi: 10.1161/01.CIR.99.18.2414).

2.1 Rotational angiography

Recently, three-dimensional rotational angiography (3DRA) has been introduced as an intraoperative modality for 3D imaging during cardiac ablation. In 3DRA, the C-arm typically performs a 200° rotation around the patient (Figure 2). Its cone-shaped radiation beam projects on a large flat-panel detector placed on the other end of the C-arm. A large number of two-dimensional projections are acquired over the course of the rotation. Reconstruction algorithms construct these into 3D images by volume or surface rendering. With adequate contrast agent administration and cardiac motion reduction (Figure 3), the image quality delivered by 3DRA has been shown to be comparable to or even exceeding classical cardiac computerized tomography (Wielandts et al., 2010). Three-dimensional rotational angiography images are more likely to represent the true anatomy than a remotely acquired image, such as CT or MRI, because of factors such as the patient's breathing and heart motion. This technique also reduces the financial and administrative burden of scheduling adjunctive and expensive imaging studies. In the case of patient movement, the geometry needs to be fully re-acquired; this can be promptly managed, but the consistent iodinated contrast agent load and radiation dose typically preclude the use of rotational angiography more than twice in a study (Casella et al., 2010).

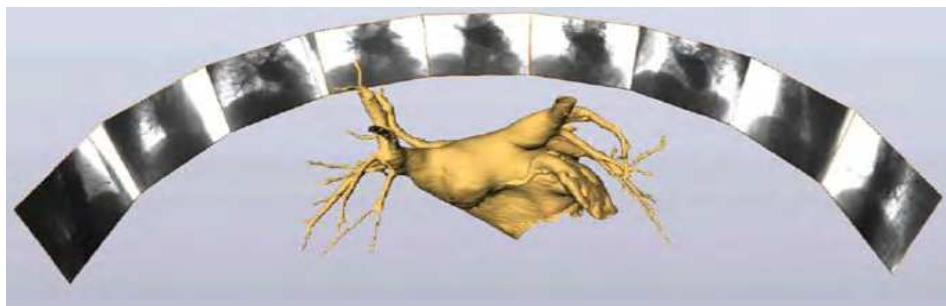


Fig. 2. A three-dimensional imaging sequence consists of 248 frames, imaged over a 200° rotation of the C-arm fluoroscope. Using advanced algorithms, a subsequent 3D volume reconstruction of the atrium is generated. Image taken from Wielandts et al., 2010.

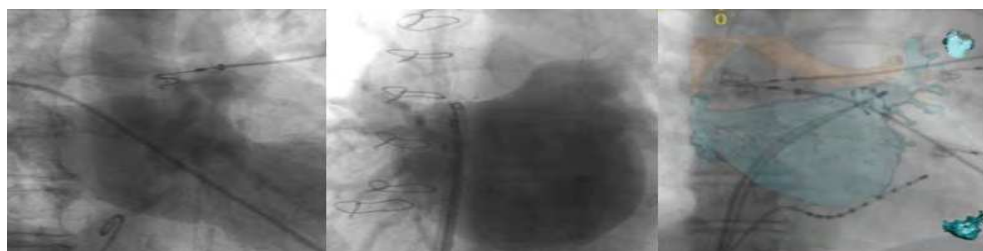


Fig. 3. Direct injection into the left atrium following segmentation of the resulting dataset. The subsequent 3D anatomical shell can then be superimposed on the live fluoroscopy. Image taken from D'Silva & Wright, 2011.

3. Electroanatomic mapping: CARTO

CARTO (*Biosense-Webster Inc, Diamond Bar, CA*) consists of a mapping catheter with miniaturized coils at the tip, a magnetic field generator located underneath the patient, a unit which analyses the current generated by the coils in the catheter-tip and a post-processing graphical display unit. The location pad fixed beneath the patient table has three coils that generate low magnetic fields (Figure 4). The emitted fields possess well-known temporal and spatial distinguishing characteristics that encode the mapping space around the patient's chest. The location is mapped in three-dimensions with reference to a fixed point. Each of the sensor locations is determined by its distance from the location pad. Three dimensional reconstruction is performed by calculating the distance between the two sensors. In case the patient moves, the distance of each sensor from the location pad is changed; however, the distance between the sensors is retained. The three distances determine the location, orientation and rotation of the catheter (Rajnish, 2009). Accuracy of the catheter tip location has been estimated to be within $0.54 \pm 0.05\text{mm}$ (LaPage & Saul, 2011).

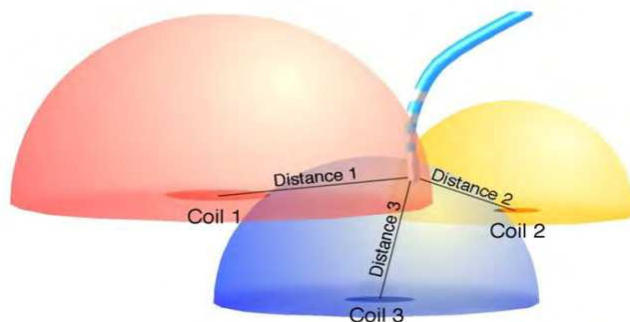


Fig. 4. Three electromagnetic fields originating from location pad coils. Spatial location of the catheter tip is accurately found by the electromagnetic fields, by determining the distance of the sensor on the catheter tip from each coil. This information is instantly computed to generate a real-time position of the catheter tip. Image courtesy of Biosense Webster.

The CARTO system is termed a point-by-point technology; multiple positions of the magnetic tip catheter are required inside the heart chamber to create a complete three-dimensional depiction of the chamber of interest (Figure 5). The activation time is referenced against an ECG lead or an intracardiac catheter (Rajnish, 2009).

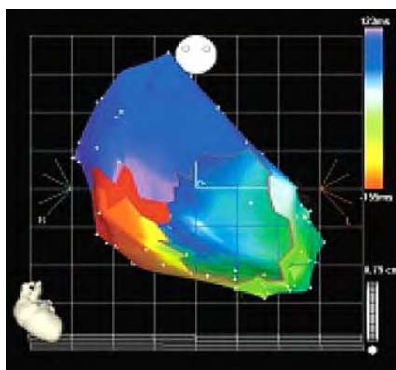


Fig. 5. Three dimensional anatomical reconstruction with superposition of activation times using the point-by-point CARTO technology. Earliest activation times are depicted in red. Image courtesy of Biosense Webster.

3.1 CARTO 3™

(Kabra & Singh, 2010) have recently reviewed the CARTO 3™ technology and some of the highlights of the system follow. First, the CARTO 3™ System is the third generation technology from Biosense Webster. Multiple catheter tips and curves can now be visualized on the electroanatomic map when compared to the traditional CARTO mapping system (Figure 6). In addition, CARTO 3™ uses a magnetic technology that calibrates the current-based technology, thereby minimizing distortions at the periphery

of the electrical field. Mapping is performed in two steps. Initially, the magnetic mapping permits precise localization of the catheter with the sensor. As the catheter with the sensor moves around a chamber, multiple locations are created and stored by the system. The system then integrates the current based points with their respective magnetic locations, resulting in a calibrated current based field that permits accurate visualization of catheters and their locations (Kabra & Singh, 2010). Each electrode emits a unique frequency allowing each to be clearly distinguished, especially when in close proximity to one another. Both the catheters with and without the magnetic sensors can be visualized without spatial distortions. Lastly, CARTO 3™ has 'Fast Anatomical Mapping' (FAM) feature that permits rapid creation of anatomical maps. Unlike point-by-point electroanatomical mapping, volume data can be collected with FAM. Catheters such as the multi-polar Lasso can further enhance the collection of points and increase the mapping speed (Kabra & Singh, 2010).

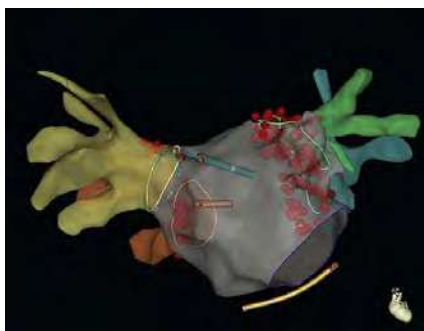


Fig. 6. The CARTO 3™ system with individually reconstructed catheters without spatial distortions. Image courtesy of Biosense Webster.

3.2 CARTOMerge

The major development for electroanatomic mapping in recent years has been the fusion of imaging technologies - MRI/CT - and electroanatomic mapping systems (Figure 7). The process of incorporating CT or MRI images into the electroanatomic mapping system involves 3D/3D registration of the catheter obtained geometry with the CT image. Typically, specific landmarks in the chamber are localized with the catheter and these points are then used to orient the CT/MRI image properly. (Rossillo et al, 2009) compared this method with a focused registration process during which they obtained multiple mapping points at each pulmonary vein using intracardiac echo guidance. They concluded that the focused registration process was a superior technique.

3.3 Advantages/disadvantages

The strengths of the CARTO technology are: (i) accurate heart chamber reconstruction, (ii) creation of linear ablations, (iii) color-coded activation maps, (iv) scar and ablation tagging capabilities. The weaknesses include: (i) incompatibility with other mapping catheters, (ii) limited utility in non-sustained arrhythmias, and (iii) orthogonal appearing volumes.

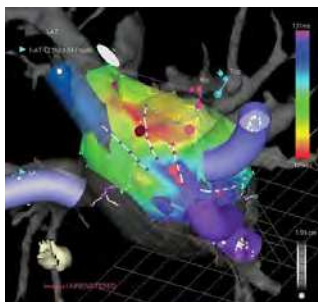


Fig. 7. The CARTOMerge technology allows the electroanatomic map of the left atrium using CARTO to be integrated with the CT/MRI images using CARTOMerge module. The circles depict the corresponding points on the two maps. Image taken from Thornton et al., 2008. (doi: doi:10.1093/europace/eun080)

3.4 Clinical study

In a recently published randomized study of 3DRA versus CARTO during atrial fibrillation ablation, the radiation exposure, procedural times and clinical outcomes at 10 months were similar in the groups investigated (Knecht et al, 2010). However the use of contrast makes it a less appealing option for patients with heart failure or renal failure. In addition, 3DRA was sensitive to patient movements during the study period. However further refinements are needed before it can be widely adopted. These include incorporation of respiratory and cardiac motion compensation and the ability to display electrogram data on the 3D (Kabra & Singh, 2010).

4. Electroanatomic mapping: ENSITE

The ENSITE system (*Endocardial Solutions, St. Jude Medical, Inc., St. Paul, MN, USA*) has two different techniques for mapping: the contact mapping system, wherein points assimilate anatomic and physiologic information in reference to five location patches applied to the skin at different places, and the non-contact mapping by a balloon array.

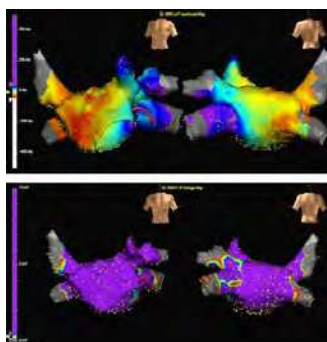


Fig. 8. Electroanatomical map acquired by the NavX system. (Top) Activation map of the left atrium during sinus rhythm, AP and PA views. (Bottom) Simultaneously-acquired voltage map of the left atrium. Image taken from Bhakta & Miller, 2008.

The contact mapping system, NavX™, is capable of displaying 3D positions of many catheters. This is achieved by applying a 5.6 kHz current through orthogonally-located skin patches on the patient. The recorded voltage and impedance at each catheter's electrodes generated from this current allows their distance from each skin patch to be triangulated with the help of a reference electrode. This determines their positions in space and the three-dimensional images of each catheter can then be displayed (Figure 8). Chamber geometry can be determined thereafter by moving a mapping catheter along the endocardial surface (Bhakta & Miller, 2008).

The non-contact mapping proceeds by using a multi electrode array (MEA). The array is comprised of 64 braided surgical-steel wires with a polyimide coating. The unipolar electrodes are created by removing a small area of insulation for each wire. The MEA is introduced into the body, like any other catheter through the femoral veins, and is inflated to 7.5 ml after positioning it at the centre of the chamber of interest (Figure 9).

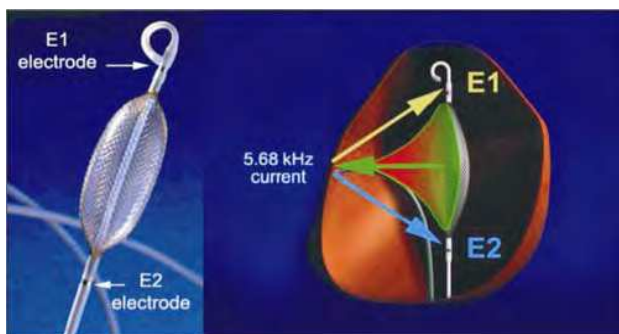


Fig. 9. Multi-electrode array balloon catheter and in its deployed state. Image courtesy of Endocardial Solutions.

The balloon electrodes make galvanic contact with the blood and sense the electrical potentials induced upon them by the electrical fields generated by myocardial activity. Two ring electrodes (E1 and E2) used to build the geometry of the chamber are located on the catheter shaft about 1 cm proximal and distal to the MEA (Rajnish, 2009). A third ring electrode meant to serve as a reference for unipolar signals is located on the catheter shaft about 16 cm proximal to the MEA. The ENSITE array and a conventional catheter are placed in the heart in the same chamber. The Patient Interface Unit (PIU) sends a 5.6 kHz signal through the conventional catheter electrode, E1 and E2 alternately receive and return the signal to the PIU (Rajnish, 2009). Each of the 64 electrodes on the ENSITE array electrode senses the strength of the 5.6 kHz signal until the respective array electrode locations in three-dimensional are measured (Figure 10).

The latest version of the system, the ENSITE Velocity, has been reviewed by (Eitel et al., 2010). (Casella et al., 2009) evaluated the accuracy of the GeoMap – a new feature of Ensite Velocity that allows multipoint simultaneous geometry acquisition and activation mapping. They performed a typical point-by-point map and then a GeoMap of the right ventricle in 13 patients and compared them with MRI data from those patients. The GeoMap acquired more points in less time. The two mapping techniques disagreed in only 3% of regions and the GeoMap was more accurate at identifying low voltage correlated with areas of motion abnormality on MRI. (Schneider et al., 2010) provided one of the few recent pediatric-

focused studies on noncontact mapping. They used the array in 20 patients with idiopathic ventricular tachycardia from the right ventricular outflow tract, left ventricle, or aortic root and achieved acute success in 17 of 18 patients for whom ablation was attempted with only three recurrences (LaPage & Saul, 2011). Previous versions of Ensite have been accurate within $0.7 \pm 1.5\text{mm}$.

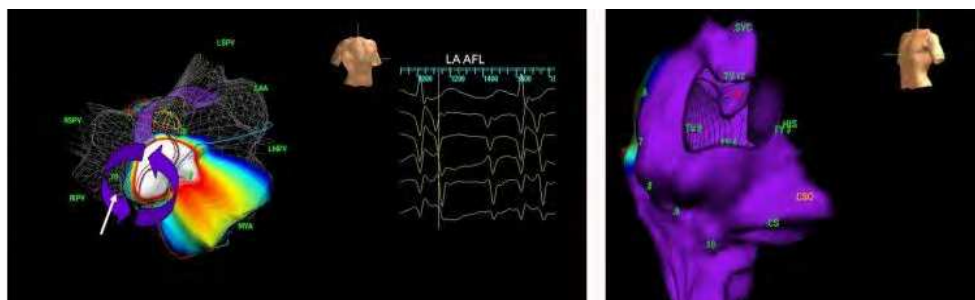


Fig. 10. Electroanatomic maps acquired by using a MEA. (Left) Activation map of macro-reentrant LA flutter. The arrows depict wave front propagation within the flutter circuit. (Right) Anatomical reconstruction of the RA. Image taken from Bhakta & Miller, 2008.

4.1 Advantages/disadvantages

The strengths of the ENSITE technology are: (i) accurate heart chamber reconstruction, (ii) ability to use with any other catheter, (iii) respiratory and cardiac motion compensation, (iv) multiple catheter location display, and (v) useful in treating poorly sustained arrhythmias. The weaknesses include: (i) inaccurate anatomical reconstructions, (ii) limited utility in non-sustained arrhythmias, and (iii) difficult balloon deployment.

4.2 Clinical study

Recently, two clinical studies were performed to assess the impact of the NavX mapping system when compared to conventional fluoroscopy ablation.

The first study (Kwong et al, 2011) sought to assess the impact on paediatric catheter ablation fluoroscopy times. The authors retrospectively analysed the procedural data during a 7-year period (2002 – 2008), which spanned the transition between the standard fluoroscopic mapping and adoption of routine NavX™ mapping for catheter ablation of atrioventricular nodal re-entrant tachycardia (AVNRT) and right-/left-sided accessory pathways (RAP/LAP). Overall, success rates were similar between the two mapping systems (95.7% for conventional vs. 95.9% for NavX™). Secondly, NavX™ mapping significantly reduced the ablation fluoro time ($15.9 + 14.3$ min vs. $11.0 + 8.9$ for NavX™) with a trend towards a decrease in total fluoro time ($26.4 + 15.6$ min vs. $23.8 + 11.1$ for NavX™). Lastly, the total procedure time was not significantly different between the two methods ($210.1 + 66$ vs. $222.8 + 61$ min for NavX™, $P = 0.7$). (Kwong et al, 2011) concluded that the NavX™ mapping reduced ablation fluoro times during paediatric catheter ablation, particularly in accessory pathways.

The second study (Liu et al., 2011) was to probe the feasibility and safety of non-fluoroscopic radiofrequency catheter ablation of atrioventricular nodal re-entrant tachycardia guided by Ensite NavX system. Non-fluoroscopic radiofrequency catheter ablation navigated by NavX system was performed in 18 cases (mean age $52.8 + 16.1$ years, range 24 – 77 years) of

atrioventricular nodal re-entrant tachycardia with normal cardiac anatomy. Using NavX, right atrial and coronary sinus geometries were reconstructed. Diagnostic electrophysiological study and radiofrequency catheter ablation were performed in all patients without use of fluoroscopy. Each site with His bundle potential were mapped and marked in the 3D geometry before ablation. The real-time position of ablation catheter was confirmed by the relative position between CS catheter and ablation catheter, which were monitored simultaneously in the Ensite NavX system. The authors show the success rate of procedure was 100%. The fluoroscopic duration of each case was zero. The average procedure duration was $97.5 + 19.8$ min (55 - 125 min, the coronary sinus access was obtained in $13.4 + 7.3$ min (8 - 30 min). (Liu et al., 2011) conclude that the preliminary study suggests that non-fluoroscopic catheter navigation for radiofrequency catheter ablation of atrioventricular nodal re-entrant tachycardia is safe and feasible.

5. Remote navigation systems

Is robotic guidance for cardiac ablation procedures the future? We attempt to answer this question in this section. Remote navigation systems or robotic cardiac catheter ablation was essentially developed to eliminate potential errors in catheter manipulation. Also, the use of robots could systematically decrease clinician fatigue and fluoroscopy exposure. Some electrophysiologists agree that areas between mitral valves and pulmonary veins are typically difficult to reach and position correctly the mapping catheter. Robotics can thus provide more accuracy in these cases. Currently there are two robotic systems -the Niobe Stereotaxis Magnetic Navigation System (*Stereotaxis, Inc., St Louis, Missouri, USA*) and the Hansen Sensei Robotic Catheter System (*Hansen Medical, Mountain View, California, USA*) depicted in Figure 11 and Figure 12. Both systems allow the physician to perform the mapping and ablation procedure while sitting in a control room remote from the patient [LaPage & Saul, 2011].

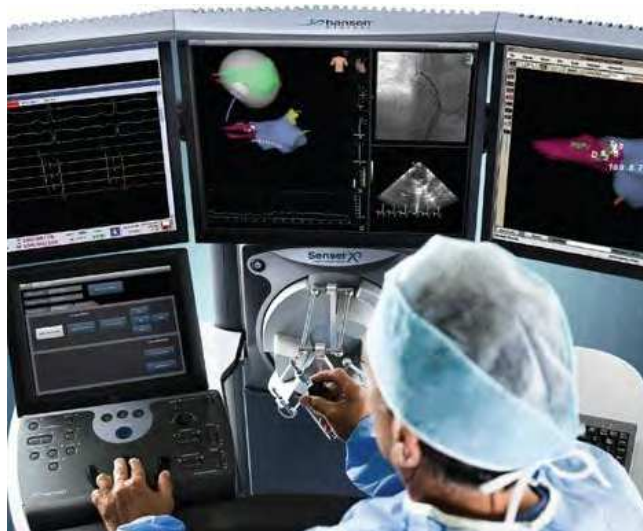

Fig. 11. The Hansen Sensei Robotic catheter system. Image taken from Hansen Medical.

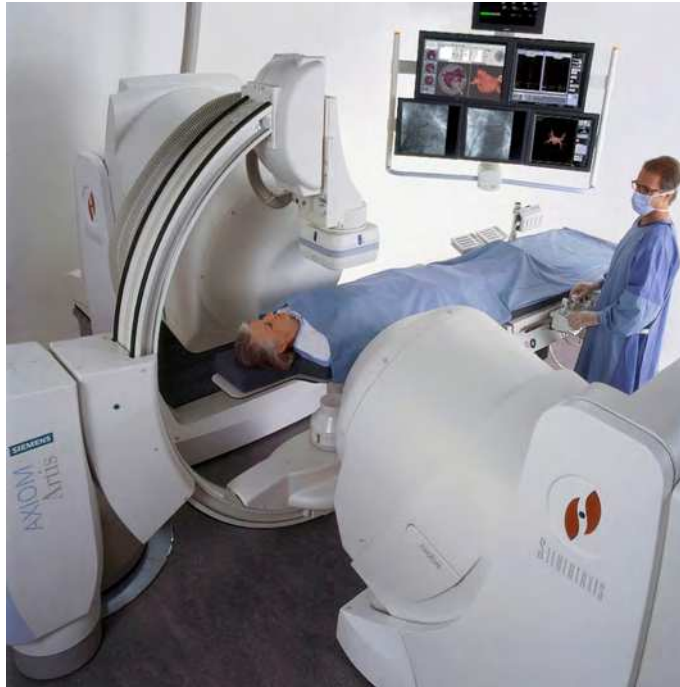

Fig. 12. Stereotaxis' Remote Magnetic Navigation System. Image taken from Stereotaxis.com.

The Stereotaxis system has been around for nearly a decade. Multiple studies have been published regarding its utility and several excellent review papers on the technology have been published (Xu et al., 2009; Wu et al., 2010; Thornton et al., 2010). The catheter has a magnet near the distal tip that can be oriented in any position using the fields produced by two magnets positioned bilaterally to the patient (LaPage & Saul, 2011). As an example application of Stereotaxis, (Azizian & Patel, 2011) used a magnetic tracking device to track the distal part of the ablation catheter in real time and a master-slave robot-assisted system is developed for actuation of a steerable catheter. The Sensei system facilitates catheter navigation through two coaxial sheaths steered with a pull wire mechanism controlled through a joystick remote control. The system is relatively novel and no pediatric applicable studies have been published. (Schmidt et al., 2009) achieved a high success rate using it for atrial fibrillation ablation and found the system equally compatible with both the CARTO and ENSITE systems. (LaPage & Saul, 2011) Both of these technologies have been integrated with electroanatomic mapping systems to store catheter location information for semi-automated re-navigation to regions of interest. These systems translate the operator's manipulation of a handle into precise movements of the catheter, thus allowing barely accessible regions of the heart to be reached, to create detailed electroanatomic mappings and precise ablation lesions (Casella et al., 2010).

5.1 Advantages/disadvantages

The strengths of the Sensei Hansen technology are: (i) can be used with any electroanatomic mapping system described previously, (ii) no fidelity devices or distortion effects, and (iii)

catheter stability. The limitations include: (i) sheath diameter and lengths and (ii) no catheter restriction.

The strengths of the Niobe Stereotaxis technology include: (i) low risk of perforation in anatomy, (ii) numerous experiments and trials published, (iii) semiautomatic mapping, and (iv) no fidelity devices or distortion effects. The limitations include: (i) restricted to expensive magnetic catheters, (ii) non real-time movement, and (iii) patients that have implanted devices.

5.2 Clinical study

(Chong et al., 2011a) performed two clinical studies using the Niobe Stereotaxis system. The first study aimed at determining the effectiveness and safety of single magnetic-guided catheter in the ablation of outflow tract tachycardias. At the outset of the clinical study, patients with symptomatic outflow tract tachycardia on surface ECG and without structural heart disease were recruited. Electrophysiology study and ablation were performed with the use of a single Navistar RMT Thermocool 8F ablation catheter. Both activation and pace mapping of ventricular tachycardia were performed. Three dimensional localization, using CARTO, was performed during activation mapping. As comparison, the patients were compared with a cohort of similar patients undergoing conventional catheter ablation via fluoroscopy. The results demonstrated that ablation was successful in all patients. Secondly, there was no difference in median procedure time between Niobe Stereotaxis (153 min) and conventional fluoroscopy (136 min) ablation groups. Nevertheless, the median fluoroscopy time was significantly reduced in the Niobe Stereotaxis group (8 vs. 29 min). (Chong et al., 2011a) concluded that the ablation of outflow tract ventricular tachycardia with a single magnetic-guided catheter is feasible, safe, and reduces fluoroscopy time.

In their second study, (Chong et al., 2011b) aimed at outlining their experiences in the ablation of incessant ventricular tachycardia with the use of the remote Niobe Stereotaxis magnetic-guided catheter system. In the course of the 1-year study, three patients with incessant ventricular tachycardia were recruited. All underwent ablation with Navistar RMT Thermocool 8F catheter guided via the Niobe Stereotaxis system and three dimensional localization using CARTO. Upon completion of procedure two of the patients' ventricular tachycardia could no longer be induced after successful ablation, and after a 12 month period, there was no recurrence. The third patient had ventricular ectopics and non-sustained ventricular tachycardia (NSVT) noted from two further sites these were ablated as well and there were no significant complications. Total fluoroscopy time was 17.4, 18.2, and 15.2 min, respectively, whereas the total procedure time was 3, 2, and 5 h, respectively. (Chong et al., 2011b) concluded that magnetic-guided catheter ablation is effective in the ablation of patients with incessant haemodynamically stable ventricular tachycardia.

(Zvereva et al., 2011) performed a prospective study to compare the incidence of oesophageal lesions using either the remote navigation system from Hansen Sensei to a manual approach for pulmonary vein isolation using a radiofrequency catheter. A total of 33 patients were recruited, 14 of which underwent manual approach. The oesophageal probe was placed and integrated with NavX™. When temperature rose to .39 FXC, ablation was immediately stopped until temperature decreased. Lastly, endoscopy was performed within 24 h after pulmonary vein isolation. Results demonstrated that in 2 of 19 patients with Hansen Sensei treatment had an oesophageal lesion found compared to only lesion found for 1 of 14 patients using the manual approach. Altogether, patients were comparable with

respect to arterial hypertension, incidence of paroxysmal and persistent atrial fibrillation, or left atrial diameter. The oesophageal lesions showed brisk healing after re-endoscopy within 2 weeks in all patients. (Zvereva et al., 2011) concluded that the incidence of oesophageal lesions in patients using Hansen Sensei compared with manually performed ablation is similar when low power settings at the posterior wall are used.

6. Ultrasound

The flexibility and ease of use of ultrasound has made it the imaging modality of choice in many intraoperative surgery rooms and laboratories worldwide. In this section we discuss specific applications of the common ultrasound instrumentation used in the electrophysiology laboratory.

6.1 CARTOSound

An extension to the CARTO mapping technology enabling ultrasound integration was created recently and termed, CARTOSound (*Biosense Webster Inc., Diamond Bar, California, USA*). It creates a three-dimensional image of a specific heart chamber undergoing cardiac ablation by utilizing an intracardiac ultrasound catheter. A first study (Schwartzman, & Zhong, 2010) evaluated the use of CARTOSound for left atrial navigation during atrial fibrillation ablation. The authors first integrated the images obtained from CARTOSound into a preoperative CT (Figure 13) and then assessed the accuracy of the CARTOSound volume representation of the left atrium from each of four different ultrasound positions (RA, left atrium, coronary sinus, and esophagus). It turns out that the most accurate representation of the chamber was obtained with the ultrasound catheter placed in the left atrium. Hence, at first sight, the CARTOSound chamber representation was found to be as accurate as the CT image (LaPage & Saul, 2011).

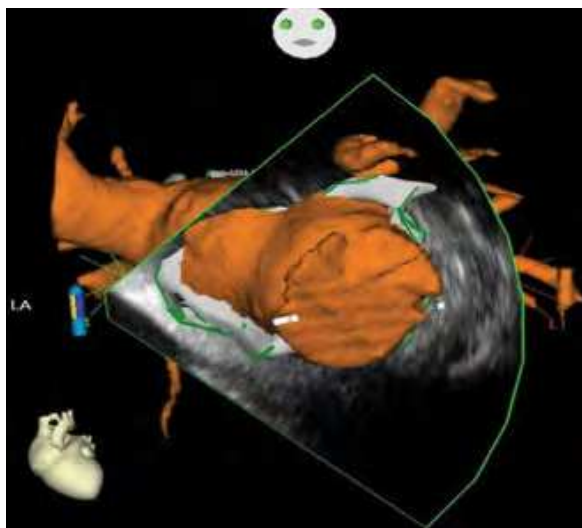


Fig. 13. The CARTOSound mapping technology that fused ultrasound images into the reconstructed volume. Image taken from Knecht et al., 2008. (doi: 10.1093/europace/eun227)

6.2 TEE imaging

Recently, real-time 3D transoesophageal echocardiography (TEE) has become available for clinical practice, offering clear and detailed rendering of the cardiac anatomy. The 3D TEE probe (*Matrix 3DTEE, Philips, Inc., Andover, MA*) allows for both 2D and 3D real-time imaging of both the left atrium and pulmonary veins. 3D TEE also provides excellent visualisation of the interatrial septum (Chierda et al., 2008a). A small study implied that 3D TEE guidance might provide safer trans-septal puncture in patients with unusual anatomy (Chierda et al., 2008b), as it offers the benefit of recognising some shapes of the atrial septum that are not well characterised by conventional two dimensional TEE. Despite these promising features, post-acquisition image processing is necessary and time-consuming. Moreover, general anaesthesia along with endotracheal intubation would be mandatory (Casella et al., 2010).

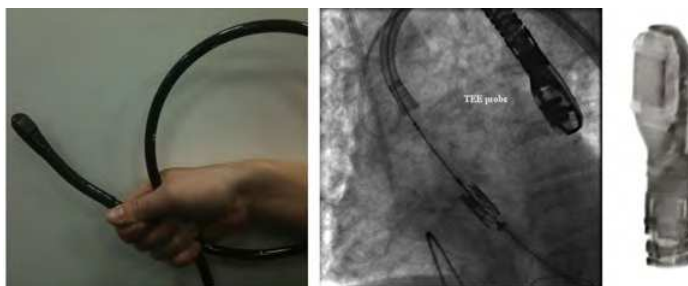


Fig. 14. The TEE probe and its tip sensor used to image left atrium or pulmonary veins during ablation procedures. Also shown is the TEE probe visible in X-ray. Image taken from King et al., 2010.

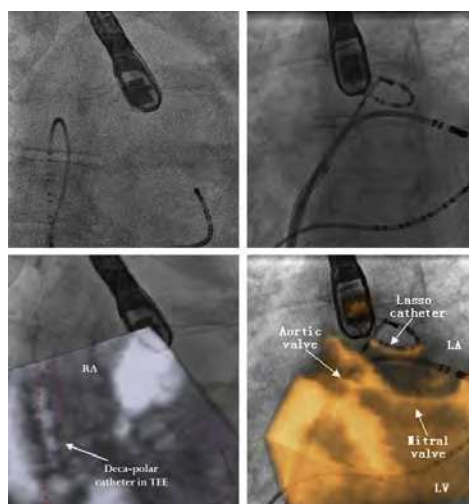


Fig. 15. (First column) the TEE volume shows a deca-polar catheter positioned in right atrium and dots highlight the position of the deca-polar catheter in the background of the X-ray image. (Second column), a lasso catheter was inserted into the left atrium with TEE volumes registered to X-ray images. Image taken from King et al., 2010.

6.3 ICE imaging

The first catheter-based 2D echocardiography systems were developed in the late 20th century for intracoronary imaging. They had high frequencies (20–40 MHz) and limited depth of penetration, making them suitable only for intravascular applications (Robinson & Hutchinson, 2010). Over the years, there has been a significant improvement in the technology with the advent of low frequency (12.5 - 9 MHz) and more recently the phased array (5.5 - 10 MHz) transducers which have been miniaturized and mounted on the catheters capable of percutaneous insertion (Pandian et al, 1990; Packer et al. 2002). Phased array ICE imaging uses a 64-element transducer on the distal end of an 8-10 French catheter. These catheters are capable of M-mode, pulsed, continuous wave and color Doppler (Daoud, 2005; Ren et al., 2002; Verma et al., 2002; Ferguson et al., 2009; Kabra & Singh, 2010.) During intervention, once transeptal access is achieved, ICE facilitates visualization of the left atrial and pulmonary venous anatomy. It also helps to assess the electrode-tissue contact. The images of ICE can be integrated with the electroanatomic mapping systems (CARTOSound) to generate the geometry of left atrium. A recent study demonstrated the feasibility of catheter ablation of atrial fibrillation without fluoroscopy using intracardiac echocardiography and electroanatomic mapping (Ferguson, 2009). Advances in intracardiac echocardiography include creation of accurate, real time three-dimensional ultrasound geometries that may obviate the need for pre-procedure CT/MRI imaging for catheter ablation of atrial fibrillation (Okumura, 2008). Other advantages over CT and MRI include ICE offering the advantage of showing the real-time detailed anatomy of the cardiac chambers that can be updated multiple times during the procedure. Furthermore, creating a 3D reconstruction without entering the LA may reduce procedural time, enhance the safety of catheter ablation procedures and eliminate geometrical distortion resulting from distension of the tissue. However, this technology bears an important financial burden because of the employment of expensive non-reusable ICE catheters (Casella et al., 2010).

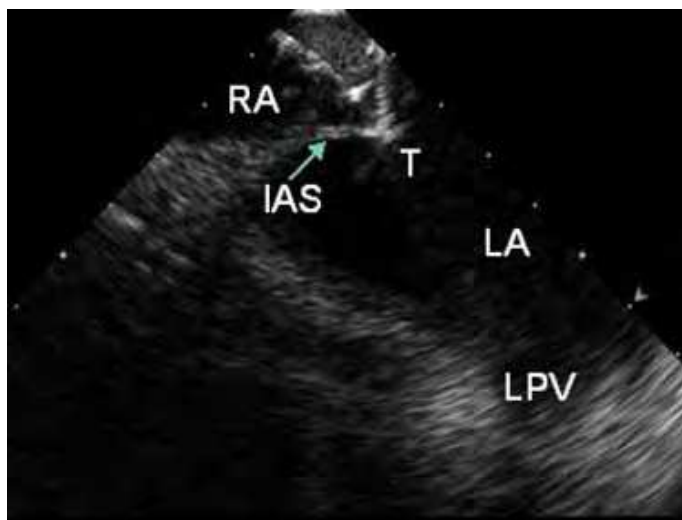


Fig. 16. ICE image showing left and right atria, interatrial septum, needle tenting and left pulmonary veins. Image taken from Robinson & Hutchinson, 2010.

7. Conclusion

In summary, this chapter presented the latest findings involving several electroanatomical mapping systems that are available to assist electrophysiologists in treating arrhythmias. Techniques are still evolving to address the challenge of a catheter-based cure. The chapter indicates that the registration of MRI/CT images to the existing fluoroscopy image or 3D anatomical map can facilitate navigation of the ablation catheter. In addition, robotic catheter navigation is now available as well. Each method, whether it is the conventional fluoroscopic treatment or the more sophisticated remote navigation systems has its own merits and weaknesses. While all these systems provide a wealth of data and reduce fluoroscopy times slightly, they cannot replace careful interpretation of data and strict adherence to electrophysiologic principles. Although these benefits are achieved at a greater cost, there may be long-term benefits to the community and catheter laboratory staff.

8. Acknowledgment

Dr. Pascal Fallavollita would like to acknowledge the support of the Chair for Computer Aided Medical Procedures & Augmented Reality, Technische Universität München.

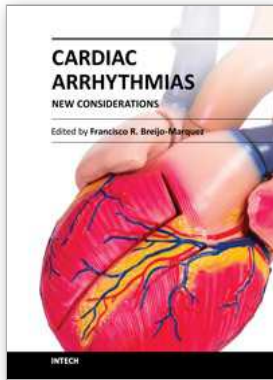
9. References

- Azizian, M. & Patel, R. (2011). Intraoperative 3D stereo visualization for image-guided cardiac ablation. *SPIE Medical Imaging: Visualization, Image-Guided Procedures, and Modeling*, Vol. 7964, pp. 79640F
- Bhakta, D. & Miller, JM. (2008). Principles of Electroanatomic Mapping. *Indian Pacing and Electrophysiology Journal*, (ISSN 0972-6292), Vol.8, Issue 1, pp. 32-50
- Casella, M.; Perna, F.; Dello Russo, A.; Pelargonio, G.; Bartoletti, S.; Ricco, A.; Sanna, T.; Pieroni, M.; Forleo, G.; Pappalardo, A.; Di Biase, L.; Natale, L.; Bellocchi, F.; Zecchi, P.; Natale, A. & Tondo, C. (2009). Right ventricular substrate mapping using the Ensite NavX system: accuracy of high-density voltage map obtained by automatic point acquisition during geometry reconstruction. *Heart Rhythm*, Vol.6, pp. 1598-1605
- Casella, M.; Perna, F.; Dello Russo, A.; Moltrasio, M.; Fassini, G.; Riva, S.; Zucchetti, M.; Majocchi, B.; Tundo, F.; Colombo, C.; De Juliis, P.; Giraldi, F.; Carbucicchio, C.; Fiorentini, C. & Tondo, C. (2010). Atrial Fibrillation Ablation - New Approaches, New Technologies. *European Cardiology*, Vol.6, Issue 3, pp. 71-6
- Chierchia, G.B.; Capulzini, L.; de Asmundis, C.; Sarkozy, A.; Roos, M.; Paparella, G.; Boussy, T.; Van Camp, G.; Kerkhove, D. & Brugada, P. (2008a) First experience with real-time three-dimensional transoesophageal echocardiography-guided transseptal in patients undergoing atrial fibrillation ablation. *Europace*, Vol. 10, pp. 1325-8
- Chierchia, G.B.; Van Camp, G., Sarkozy, A.; de Asmundis, C. & Brugada, P. (2008b). Double transseptal puncture guided by real-time three-dimensional transoesophageal echocardiography during atrial fibrillation ablation. *Europace*, Vol. 10, pp. 705-6

- Chong, D.; Ching, C.K.; Liew, R.; Galalardin; Khin, M.W. & Teo, W.S. (2011a). Outflow tract ventricular tachycardia ablation with a magnetic-guided catheter is effective, safe and reduces radiation exposure. *Europace*, Vol.13, suppl 1, pp. i47-i82, poster 008
- Chong, D.; Tan, B.Y.; Liew, R.; Ching, C.K. & Teo, W.S. (2011b). Ablation of incessant ventricular tachycardia using a remote magnetic-guided catheter: a tertiary centre case series. *Europace*, Vol.13, suppl 1, pp. i47-i82, poster 009
- Daoud E.G. (2005). Transseptal catheterization. *Heart Rhythm*, Vol.2, pp. 212-214
- D'Silva, A. & Wright, M. (2011). Advances in Imaging for Atrial Fibrillation Ablation. *Radiology Research and Practice*. Vol. 2011, Article ID 714864, 10 pages, doi:10.1155/2011/714864
- Eitel, C.; Hindricks, G.; Dages, N.; Sommer, P. & Piorkowski, C. (2010). EnSite Velocity cardiac mapping system: a new platform for 3D mapping of cardiac arrhythmias. *Expert Rev Med Devices*, Vol.7, pp.185-188
- Ferguson, J.D.; Helms, A.; Mangrum, J.M.; Mahapatra, S.; Mason, P.; Bilchick, K.; McDaniel, G.; Wiggins, D. & DiMarco, J.P. (2009). Catheter ablation of atrial fibrillation without fluoroscopy using intracardiac echocardiography and electroanatomic mapping. *Circ Arrhythm Electrophysiol*, Vol. 2, pp. 611-619
- Kabra, R. & Singh, J. (2010). Recent Trends in Imaging for Atrial Fibrillation Ablation. *Indian Pacing and Electrophysiology Journal*, Vol. 10, Issue5, pp. 215-227, 2010
- King, A.P.; Rhode, K.S.; Ma, Y.; Yao, C.; Jansen, C.; Razavi, R. & Penney, G. (2010). Registering preprocedure volumetric images with intraprocedure 3-D ultrasound using an ultrasound imaging model. *IEEE Transactions on Medical Imaging*, Vol. 29, pp. 924 - 937
- Knecht, S.; Nault, I.; Wright, M.; Matsuo, S.; Lellouche, N.; Somasundaram, P.E.; O'Neill, M.D.; Lim, K.T.; Sacher, F.; Deplagne, A.; Bordachar, P.; Méléze, H.; Clémenty, J.; Haïssaguerre, M.; & Jaïs, P. (2008). Imaging in catheter ablation for atrial fibrillation: enhancing the clinician's view. *Europace*, Vol.10, pp. iii2-iii7
- Knecht, S.; Wright, M.; Akrivakis, S.; Nault, I.; Matsuo, S.; Chaudhry, GM.; Haffajee, C.; Sacher, F.; Lellouche, N.; Miyazaki, S.; Forclaz, A.; Jadidi, AS.; Hocini, M.; Ritter, P.; Clémenty, J.; Haïssaguerre, M.; Orlov, M. & Jaïs, P. (2010). Prospective randomized comparison between the conventional electroanatomical system and three-dimensional rotational angiography during catheter ablation for atrial fibrillation. *Heart Rhythm*, Vol.7, Issue 4, pp. 459-65
- Kwong, W.; Neilson, AL.; Hamilton, RM.; Chiu, CC.; Stephenson, EA.; Gross, GJ.; Soucie, L. & Kirsh, JA. (2011). NavX mapping reduces ablation fluoroscopy times in paediatric catheter ablation. *Europace*, Vol.13, suppl 1, pp. i47-i82, poster 001.
- LaPage, MJ. & Saul, JP. (2011). Update on rhythm mapping and catheter navigation. *Current Opinion in Cardiology*, Vol.26, pp.79-85
- Liu, XQ.; Zhou, X.; Yang, G.; Zhong, GZ.; Shi, L.; Tian, Y.; Li, YB.; Wang, Au. & Yang XC. (2011). Radiofrequency catheter ablation for atrioventricular nodal re-entrant tachycardia without fluoroscopic guidance. *Europace*, Vol. 13, suppl 1, pp. i47-i82, poster 013
- Okumura, Y.; Henz, B.D.; Johnson, S.B.; Bunch, T.J.; O'Brien, C.J.; Hodge, D.O.; Altman, A.; Govari, A. & Packer, D.L. (2008). Three-dimensional ultrasound for image-guided

- mapping and intervention: Methods, Quantitative validation, and clinical feasibility of a novel multimodality image mapping system. *Circ Arrhythm Electrophysiol*, Vol. 1, pp. 110-119
- Packer, D.L.; Stevens, C.L.; Curley, M.G.; Bruce, C.J.; Miller, F.A.; Khandheria, B.K.; Oh, J.K.; Sinak, L.J. & Seward, J.B. (2002). Intracardiac phased-array imaging: methods and initial clinical experience with high resolution, under blood visualization-initial experience with intracardiac phased-array ultrasound. *J Am Coll Cardiol*. Vol.39, pp. 509-516
- Pandian, N.G.; Kreis, A.; Weintraub, A.; Motarjeme, A.; Desnoyers, M.; Isner, J.M.; Konstam, M.; Salem, D.N. & Millen, V. (1990). Real-time intravascular ultrasound imaging in humans. *Am J Cardiol*. Vol. 65, pp. 1392-1396
- Rajnish, J. (2009). Radiofrequency ablation for cardiac tachyarrhythmias: principles and utility of 3D mapping systems. *Current Science*, Vol.97, No.3, (August 2009), pp. 416-424
- Ren, J.F.; Marchlinski, F.E.; Callans, D.J.; Zado, E.S. (2002). Intracardiac Doppler echocardiographic quantification of pulmonary vein flow velocity: an effective technique for monitoring pulmonary vein ostia narrowing during focal atrial fibrillation ablation. *J Cardiovasc Electrophysiol*, Vol.13, pp. 1076-1081
- Rossillo, A.; Indiani, S.; Bonso, A.; Themistoclakis, S.; Corrado, A. & Raviele, A. (2009). Novel ICE-guided registration strategy for integration of electroanatomical mapping with three-dimensional CT/MR images to guide catheter ablation of atrial fibrillation. *J Cardiovasc Electrophysiol*, Vol 20, pp. 374-378
- Schmitt, C.; Zrenner, B.; Schneider, M.; Karch, M.; Ndrepepa, G.; Deisenhofer, I.; Weyerbrock, S.; Schrieck, J. & Schömig, A. (1999). Clinical Experience with a Novel Multielectrode Basket Catheter in Right Atrial Tachycardias. *Circulation*. Vol. 99, pp. 2414-2422
- Schmidt, S.; Tilz, R.R.; Neven, K.; Chun, J.K.R.; Fuernkranz, A. & Ouyang, F. (2009). Remote robotic navigation and electroanatomical mapping for ablation of atrial fibrillation: considerations for navigation and impact on procedural outcome. *Circ Arrhythmia Electrophysiol*, Vol. 2, pp. 120-128
- Schneider, H.E.; Kriebel, T.; Jung, K.; Gravenhorst, V.D. & Paul, T. (2010) Catheter ablation of idiopathic left and right ventricular tachycardias in the pediatric population using noncontact mapping. *Heart Rhythm*, Vol. 7, pp.731-739.
- Schwartzman, D. & Zhong, H. (2010). On the use of CartoSound for left atrial navigation. *J Cardiovasc Electrophysiol*; Vol. 21, pp. 656-664
- Thornton, A.S.; Rivero-Ayerza, M. & Jordaens, L. (2008) Ablation of a focal left atrial tachycardia via a retrograde approach using remote magnetic navigation. *Europace*, Vol. 10, Issue 6, pp. 687-689
- Thornton, A.S.; De Castro, C.A.; van Deel, E.; van Beusekom, H.M. & Jordaens, L.(2010). An in vivo comparison of radiofrequency cardiac lesions formed by standard and magnetically steered 4mm tip catheters. *Neth Heart J*, Vol. 18, pp. 66-71
- Verma, A.; Marrouche, N.F.; Natale, A. (2002). Pulmonary vein antrum isolation: intracardiac echocardiography-guided technique. *J Cardiovasc Electrophysiol*, Vol. 15, pp. 1335-1340
- Wielandts, J.Y.; De Buck, S.; Ector, J.; LaGerche, A.; Willems,R.; Bosmans, H. & Heidebuchel, H. (2010). Three-dimensional cardiac rotational angiography: effective radiation dose and imagequality implications. *Europace*, Vol.12, pp.194-201

- Wu, J.; Pflaumer, A.; Deisenhofer, I.; Hoppmann, P.; Hess, J. & Hessling, G. (2010) Mapping of atrial tachycardia by remote magnetic navigation in postoperative patients with congenital heart disease. *J Cardiovasc Electrophysiol*, Vol. 21, pp. 751-759
- Xu, D.; Yang, B.; Shan, Q.; Zou, J.; Chen, M.; Chen, C.; Hou, X.; Zhang, F.; Li, W.Q.; Cao, K. & Tse, H.F. (2009). Initial clinical experience of remote magnetic navigation system for catheter mapping and ablation of supraventricular tachycardias. *J Interv Card Electrophysiol*, Vol.25, pp. 171-174
- Zvereva, V.; Rillig, A.; Meyerfeldt, U. & Jung, W. (2011). Incidence of oesophageal lesions using either a remote robotic navigation system or a manual approach for *Europace*, Vol.13, suppl 1, pp. i47-i82, poster 009



Cardiac Arrhythmias - New Considerations

Edited by Prof. Francisco R. Breijo-Marquez

ISBN 978-953-51-0126-0

Hard cover, 534 pages

Publisher InTech

Published online 29, February, 2012

Published in print edition February, 2012

The most intimate mechanisms of cardiac arrhythmias are still quite unknown to scientists. Genetic studies on ionic alterations, the electrocardiographic features of cardiac rhythm and an arsenal of diagnostic tests have done more in the last five years than in all the history of cardiology. Similarly, therapy to prevent or cure such diseases is growing rapidly day by day. In this book the reader will be able to see with brighter light some of these intimate mechanisms of production, as well as cutting-edge therapies to date. Genetic studies, electrophysiological and electrocardiographic features, ion channel alterations, heart diseases still unknown, and even the relationship between the psychic sphere and the heart have been exposed in this book. It deserves to be read!

How to reference

In order to correctly reference this scholarly work, feel free to copy and paste the following:

Pascal Fallavollita (2012). The Future of Cardiac Mapping, Cardiac Arrhythmias - New Considerations, Prof. Francisco R. Breijo-Marquez (Ed.), ISBN: 978-953-51-0126-0, InTech, Available from:
<http://www.intechopen.com/books/cardiac-arrhythmias-new-considerations/the-future-of-cardiac-mapping>

INTECH

open science | open minds

InTech Europe

University Campus STeP Ri
Slavka Krautzeka 83/A
51000 Rijeka, Croatia
Phone: +385 (51) 770 447
Fax: +385 (51) 686 166
www.intechopen.com

InTech China

Unit 405, Office Block, Hotel Equatorial Shanghai
No.65, Yan An Road (West), Shanghai, 200040, China
中国上海市延安西路65号上海国际贵都大饭店办公楼405单元
Phone: +86-21-62489820
Fax: +86-21-62489821

© 2012 The Author(s). Licensee IntechOpen. This is an open access article distributed under the terms of the [Creative Commons Attribution 3.0 License](#), which permits unrestricted use, distribution, and reproduction in any medium, provided the original work is properly cited.