

## Cytokeratin 7 and 20

Agnieszka Jasik  
*National Veterinary Research Institute  
Poland*

### 1. Introduction

Intermediate filaments (IFs) are the most stable components in the cells, and are involved in many important physiological functions, including distribution of organelles, signal transduction, cell polarity and gene regulation. (Iwatsuki & Suda, 2010).

Cytokeratins (CK or CKs) are the largest complex group of IF proteins. These are proteins, that are crucial in the development and differentiation of epithelial cells, as well as essential for normal tissue structure and function. The first keratin protein nomenclature was published by Moll et al. (1982) and it has been repeatedly updated in recent years (Schweizer et al., 2006). Based on the results of ongoing research in human and other vertebrates, Szeverenyi et al. (2008) published a comprehensive catalogue of the human keratins, their amino acid sequence, the nucleotide sequence of the keratin genes in humans, as well as the same data of the orthologue keratins and keratin genes in various vertebrate species. Based on their molecular weights and isoelectric points CKs were catalogued and divided into two groups: type I and type II cytokeratins. The type I cytokeratins consist of acidic, low molecular weight (40-56.5 kDa) proteins including cytokeratins K9-K28 and hair keratins K31-K40. The type II cytokeratins consist of basic, high molecular weight (52-67 kDa) proteins including cytokeratins K1-K8, cytokeratins K71-K80 and hair keratins K81-K86 (Bragulla & Homberger, 2009; Iwatsuki & Suda, 2010; Moll et al., 2008; Schweizer et al., 2006). Cytokeratins are relatively resistant to degradation and show highly specific phenotypic expression depending on the type and differentiation of the epithelial cells. Hence, the different types of epithelia have specific for them pattern of keratin expression.

Based on biochemical and immunohistochemical studies, it was possible to explain and define the epithelial tissue-specific distribution of CKs but also to conclude that tumors arising from a given epithelium generally preserved this pattern of CK expression despite malignant transformation. Moreover, the cytokeratin expression patterns in a given type of tumor appear to be identical in primary tumors and their metastases, independent from the specific location and size (Lam et al., 2001; Moll et al., 1982). Therefore, antibodies against various cytokeratins are important in the accurate identification and classification of different types of carcinomas, whose origin is uncertain by routine light microscopy. In this context, the diverse expression patterns of CK7 and CK 20 among epithelial tumors have been proposed to help discriminating primary from metastatic carcinoma of various origins (Duval et al., 2000; Nikitakis et al., 2004; Wauters et al., 1995). Based on the differential

staining patterns for cytokeratins reported in the literature, in the following chapter, we focused on evaluation of utility of cytokeratins 7 and 20 both in differential diagnosis of tumors and identification of the primary site of tumor origin.

## **2. Characterization and distribution of cytokeratins 7 and 20 in tissues**

### **2.1 Cytokeratin 7**

Cytokeratin 7 (CK7) is a polypeptide with molecular weight 54 kDa and an isoelectric point at pH 6.0. (Bragulla & Homberger, 2009; Moll et al., 1982; Schweizer et al., 2006). This protein is encoded by the KRT7 gene, located on chromosome 12q13.13 (Bragulla & Homberger, 2009, Schweizer et al., 2006). In normal tissues, this basic (type II) keratin is found to be distributed in a wide variety of simple epithelia: in organs associated with the gastrointestinal tract (including only the gallbladder, hepatic ducts and pancreatic ducts), female genital tract (the ovary, endometrium, fallopian tube and cervix), breast, urinary tract (the cells of the renal tubule and collecting ducts of the kidney, as well as in the cells of the transitional epithelium of the mucosa of the renal pelvis, ureter and bladder), and respiratory tract (the sinonasal mucosa, trachea and lung) (Iwatsuki & Suda, 2010; Moll et al., 1982, 2008). Cytokeratin 7 is found in epithelial cells of fetal stomach, whereas in normal gastrointestinal epithelium is undetectable (Tatsumi et al., 2005). It is also one of the several cytokeratins, which are expressed in the developing teeth of human (in the developing stratified enamel organ) (Bragulla & Homberger, 2009). In endometrium, CK7 expression is high in secretory phase but low in the proliferative phase of the estrous cycle. Cytokeratin 7 is also expressed in the epithelial cells of the nail bed epidermis and in mesothelium and endothelial cells. Moreover, CK7 has been shown to be expressed to a different degree in the various epithelial salivary gland elements; more specifically, immunohistochemically the luminal cells of the salivary ducts are strongly positive for CK7, while the acinar, basal, and myoepithelial cells stain with less intensity (Nikitakis et al., 2004). Cytokeratin 7 was undetectable in hepatocytes, proximal and distal tubules of the kidney, and squamous cell epithelia.

### **2.2 Cytokeratin 20**

Cytokeratin 20 (CK20) is a newly described polypeptide with molecular weight 48.5 kDa and an isoelectric point at pH 5.66 (Bragulla & Homberger, 2009; Moll et al., 1993; Schweizer et al., 2006). This protein is encoded by the KRT20 gene, located on chromosome 17q21.2 (Bragulla & Homberger, 2009, Schweizer et al., 2006). CK20 was originally identified as protein "IT" in cytoskeletal extracts of intestinal epithelia. In normal human tissues this acidic (type I) keratin is found in more complex epithelia of the gastrointestinal tract (such as taste buds, gastric foveolar cells and intestinal epithelium), urothelial umbrella cells, squamous epithelia from any site and Merkel cells of the epidermis and hair follicle outer root sheath (Barret et al., 2000; Jovanovic et al., 2002; Moll et al., 2008). In human embryogenesis, it appears in the small intestinal epithelium at embryonic week 8 (Moll et al., 2008). No cytokeratin 20 expression was identified in mesothelium (Tot, 2002), sinonasal epithelia (Franchi et al., 2004) and any salivary gland epithelial elements (Nikitakis et al., 2004).

### 3. Application of cytokeratins 7 and 20 in diagnostic pathology

#### 3.1 Expression of CK7 in primary tumors and their metastases

The frequency of CK 7 expression is summarized in Figure 1. Generally positive immunohistochemical cytokeratin 7 expression has been identified in carcinomas of the breast, lung, endometrium and ovaries. Moreover, primary tumors of the sinonasal tract, thyroid gland, salivary gland, biliary and urinary tract stain strongly positive for CK7.

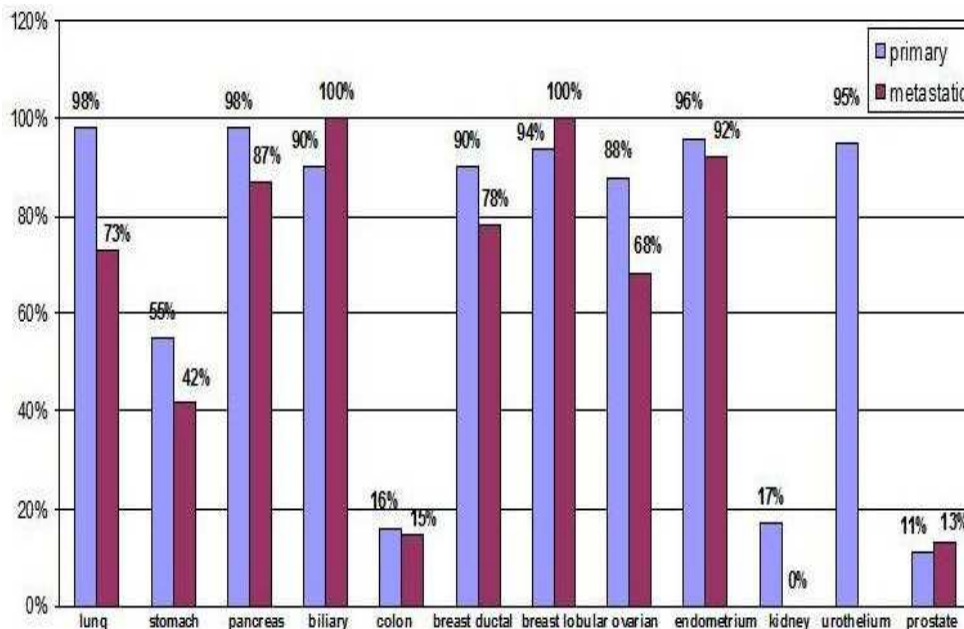


Fig. 1. Percentage of positive expression of CK7 in primary and metastatic adenocarcinomas (based on Tot, 2002)

Even some primary brain neoplasms, like choroid plexus tumors, as well as malignant mesotheliomas and synovial sarcomas are CK7+. Taking to account the different histological subtypes of cancer, CK7 positivity has been reported in 100% of cases of papillary thyroid carcinoma (86/86), follicular thyroid carcinoma (19/19) and medullary thyroid carcinoma (13/13) (Lam et al., 2001) as well as mucinous (6/6), nonmucinous (4/4) and mixed (6/6) bronchioloalveolar adenocarcinoma (Chu et al., 2000; Simsir et al., 2004).

The same percentage of positive immunostaining for CK7 was detected in seven histologic types of salivary gland carcinoma, including mucoepidermoid, adenoid cystic, polymorphous low grade, salivary duct, acinic cell, clear cell and basal cell (Nikitakis et al., 2004). Poorly differentiated and anaplastic thyroid carcinomas expressed CK7, but the number of immunoreactive cells was smaller than those in well-differentiated carcinomas. Similarly the percentage of CK7 positive cases of urothelial carcinoma was lower in high-grade tumors infiltrating the surrounding tissues (67%), than in low-grade urothelial carcinoma (100%) (Bassily et al., 2000). This may be due to the loss of cytokeratin expression during tumor progression into high-grade lesion.

It is also worth noting that distribution of cytokeratin 7 staining varied among different histological types of some tumors, which may be useful in their discrimination. An example of this is the report by Nikitakis et al. (2004) on salivary gland tumors, describing focal staining of CK7 in adenoid cystic carcinoma compared to the universally diffuse pattern in polymorphous low-grade adenocarcinoma. Also, there was a report of strong cytoplasmic and membrane CK7 staining in chromophobe variant of renal cell carcinoma distinguishing it from benign oncocytomas showing focal weak-to-moderate CK7 cytoplasmic staining (Campbell & Herrington, 2001). Among soft tissue sarcomas CK7 expression has been found in a small proportion of liposarcomas (7%), gastrointestinal stromal tumors (12%) and epithelioid (25%) (Humble et al., 2003) and synovial sarcomas. Other sarcomas, including malignant fibrous histiocytoma, leiomyosarcoma, angiosarcoma, malignant peripheral nerve sheath tumor, desmoids tumor, rhabdomyosarcoma and primitive neuroectodermal tumor were negative for CK7 (Campbell & Herrington, 2001). Prostate adenocarcinomas, hepatocellular carcinomas and most of gastric carcinomas also have been negative for keratin 7, despite of small proportion of these tumor cases showing CK7 positive expression (Bassily et al., 2000; Chu et al., 2000; Sawan, 2009).

Nevertheless, the lack of immunoreactivity in colorectal adenocarcinomas is the main point of diagnostic utility of this keratin in differentiation adenocarcinoma metastases in context of their possible primary tumor. Eighty-eight percent of metastases from colorectal adenocarcinoma to the lung, liver, lymph nodes, chin, small bowel, peritoneum and bone were negative for CK7 (Kummar et al., 2002). Respectively, 62.5 % (Rekhi et al., 2008) and 76.4% (Wauters et al., 1995) of colorectal adenocarcinoma metastases to the ovary were also negative for CK7. Despite the lack of expression of cytokeratin 7, some cases of colorectal adenocarcinoma show positive immunoreactivity for CK7. This positive rate for CK7 is 0-16% in primary tumors, and 8.3-19% in metastatic cancers. In contrast, almost 100% and 73% immunoreactivity for CK7 has been detected in primary and metastatic pulmonary adenocarcinomas respectively.

### 3.2 Expression of CK20 in primary tumors and their metastases

The frequency of CK 20 expression is summarized in Figure 2. CK20 expression is restricted to a few organ systems. Almost all cases of colon carcinoma (91-100%) were positive for CK20, as well as 64-78% of urothelial tumors, 78% of Merkel cell tumors, 50-71% of adenocarcinomas of the stomach, 55% of biliary adenocarcinomas and 44-62% of adenocarcinomas of the pancreas (Chu et al., 2000; Duval et al., 2000; Stopyra et al., 2001; Tot, 2002).

Moreover, high percentage (84%) of sinonasal intestinal-type adenocarcinomas (ITACs) was CK20 positive, which distinguished them from non-ITACs showing lack of immunoreactivity for CK20 (Franchi et al., 2004). Similarly, in the case of renal oncocytomas a high degree of CK20 positive immunoreactivity (80%) can be a useful diagnostic tool to distinguish them from renal cell carcinomas, in which no or weak positive reaction (range 0-7.7%) has been found (Stopyra et al., 2001).

In all of the colorectal lesions high CK20 positivity was found, including 100% in hyperplastic polyps, 95% in serrated adenomas, 90% in conventional adenomas and 92% in adenocarcinomas. Generally, pulmonary adenocarcinomas are negative for CK20 (Campbell & Herrington, 2001; Hatanaka et al., 2011; Kummar et al., 2002). Nevertheless, positive

immunoreactivity for CK20 has been detected in 5 (83%) of 6 cases of mucinous and in all (6) cases of mixed bronchioloalveolar carcinoma (Simsir et al., 2004), as well as in 5 (32%) of 16 cases of pulmonary adenocarcinoma with enteric differentiation (Hatanaka et al., 2011). All cases of nonmucinous bronchioloalveolar carcinomas were negative for CK20 (Simsir et al., 2004). For this reason, distinguishing primary pulmonary adenocarcinomas from metastases with strong CK20 expression may be difficult. There are some differences in CK20 expression in ovarian adenocarcinomas. About 67% of ovarian mucinous adenocarcinomas were positive for CK20, while among non-mucinous ovarian tumors 25% (62/246) expressed CK20 (Tot, 2002; Wauters et al., 1995). The lack of reaction, or sporadic focal and weak CK20 immunostaining is detected in salivary gland tumors, except small cell carcinomas, that frequently display diffuse positivity for CK20. Those cases included: 2 (7.7%) of 26 cases of mucoepidermoid carcinoma, 1 (4%) of 25 cases of adenoid cystic carcinoma and 3 (37.5%) of 8 cases of salivary duct carcinoma (Nikitakis et al., 2004), as well as 6 (10%) of 59 cases of prostate adenocarcinoma (Campbell & Herrington, 2001) and 2 (6%) of 30 cases of squamous cell carcinoma of the head and neck (Chu et al., 2000). So far, no cytokeratin 20 expression has been found in soft tissue sarcomas, such as epithelioid sarcoma, malignant fibrous histiocytoma, malignant peripheral nerve sheath tumor, leiomyosarcoma, angiosarcoma, desmoids tumor, rhabdomyosarcoma and primitive neuroectodermal tumor (Campbell & Herrington, 2002). Lack of CK20 reactivity was also reported in all thyroid carcinomas (Lam et al., 2001), thymomas, mesotheliomas (Campbell & Herrington, 2001), and squamous cell carcinomas of the cervix (Chu et al., 2000; Nikitakis et al., 2004).

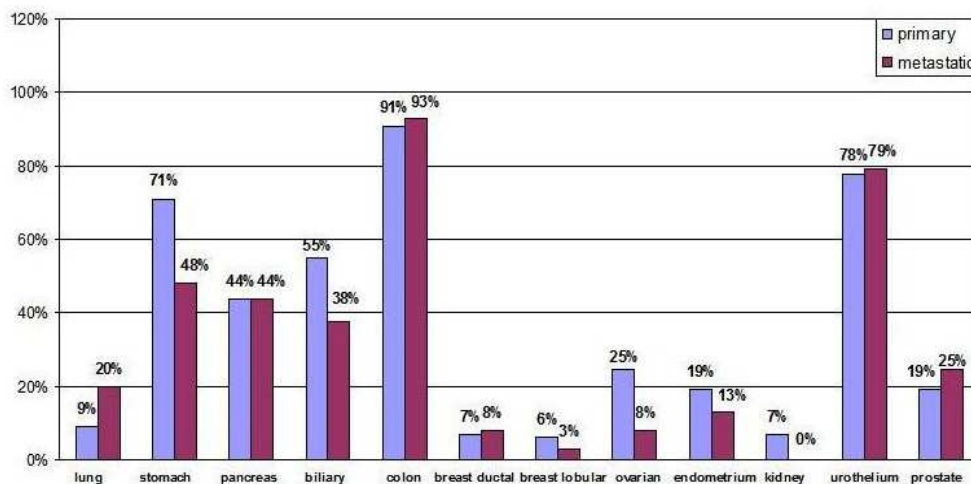


Fig. 2. Percentage of positive expression of CK20 in primary and metastatic adenocarcinomas (based on Tot 2002)

Strong stability of the CK20 expression in colorectal adenocarcinomas (Table 2), that retain during their metastatic progression allows for specific recognition of metastases of this type of tumor. Ninety-two percent of metastases of the colorectal cancers to the lung, liver, lymph nodes and small bowel were positive for CK20 (Tot, 2002; Kummar et al., 2002).

Colorectal adenocarcinomas metastatic to the ovary also showed CK20 positivity in all cases. However, in the latter case, primary mucinous ovarian carcinomas can not be excluded, due to their positive expression of CK20. The fact, that tumors retain expression of CK20 during their metastases, is useful in detection of circulating cancer cell in the peripheral blood, using reverse transcriptase (RT)-PCR analysis. It is a very helpful method to detect metastases at a very early stage of disease, especially in case of colorectal carcinoma, gastric and pancreatic adenocarcinoma as well as lung carcinoma (Moll et al., 2008; Wang et al., 2006). The same method is used in early detection of bladder cancer in voided urine (Pu et al., 2007).

### 3.3 CK7/CK20 phenotype in primary tumors and metastases

Among epithelial tumors approximately 80% are malignant (Chu et al., 2000).

Metastatic tumors from an unknown primary site are a common clinical problem, that leads to extensive and costly clinical and radiological examinations, sometimes with disappointing results. A proper diagnosis of the primary site is important for therapeutic decision-making and prognosis of particular tumor types.

Possibility of identifying the primary tumors in cases of unclear metastases is significantly increased when CK7 is used in combination with CK20, since many carcinomas exhibit characteristic CK7/CK20 phenotypes. For the determination of these phenotypes several monoclonal antibodies against CK7 and CK20 are used (Upasani et al., 2004). Most commonly used antibodies, their dilutions and the antigen retrieval methods are presented in Table 1. For comparison, the distribution of reported CK7/CK20 phenotype of different types of tumor in the reviewed literature is presented in Table 2. Differences between a specific type of tumor and its CK7/CK20 phenotype found in the collected literature make it difficult to compare the results. Therefore, the data presented in the table should be considered as a collection of information published so far.

The majority of the tumor cases from the gastrointestinal and genitourinary tracts, which have been described so far show CK7+/CK20+ phenotype. This phenotype is also very specific for mucinous and mixed bronchioloalveolar adenocarcinomas (BACs) and differs from typical CK7+/CK20- phenotype of conventional pulmonary adenocarcinoma. This immunohistochemical staining is crucial for distinguishing mucinous and mixed BACs from metastatic adenocarcinomas involving the lungs. Nevertheless, distinction of mucinous BACs from metastatic mucinous adenocarcinomas of gastrointestinal, pancreatic, and ovarian origins can be difficult, due to the same CK7+/CK20+ phenotype. To distinguish prostate carcinoma from urothelial carcinoma CK7+/CK20+ phenotype is helpful for ruling out prostate cancer, as it is extremely rarely (0-2%) present in prostate carcinoma (Bassily et al. 2000). Immunophenotype CK7-/CK20+ is most useful in distinguish primary and metastatic tumors from the colorectal tumors and Merkel cell carcinomas (Saeb-Lima et al., 2008). However, it should be kept in mind, that some of recently described primary pulmonary adenocarcinomas with enteric differentiation (12.5%) express the same phenotype (Hatanaka et al., 2011).

Large number of different type of tumors express different percentage of CK7+/CK20-phenotype (Table 2), that is the most specific for tumors of the lungs, sinonasal tract,

salivary gland and thyroid gland (Franchi et al., 2004; Lam et al., 2001; Kummar et al., 2002; Nikitakis et al., 2004). Therefore, it is not possible to differentiate these tumor types, based solely on cytokeratin 7 expression. Knowledge of the CK7/CK20 immunophenotype of tumors in case of distant metastases may be valuable in their definitive diagnosis, especially in the lack of a previous diagnosis of a primary tumor. It can be important in case of metastases of colorectal carcinoma and breast tumors to the skin (Fidler et al., 2007). Tumors of the skin and soft tissue, which have been reported so far, express mainly CK7-/CK20-phenotype, beside Merkel cell carcinomas.

Antibody	Clone	Dilution	Source	Antigen retrieval method
	OV-TL 12/30	1:12.5	Dako	without pretreatment
	OV-TL 12/30	1:50	Dako	0.05% pronase , 37 °C
	OV-TL 12/30	1:60	Dako	0.1% pronase, RT (10 min)
	OV-TL 12/30	1:100	Dako	0.01 M citrate buffer pH 6, microwave (15 min)
	OV-TL 12/30	1:100	Bio Genex	0.1% pronase in Tris-HCl buffer, 37°C (5 min)
Cytokeratin 7	OV-TL 12/30	1:200	Dako	0.01 M citrate buffer pH 6, microwave (5 min)
	OV-TL 12/30	1:800	Bio Genex	0.5% protease XIV 20°C (15 min)
	OV-TL 12/30	1:1900	Dako	proteinase K (ready-to-use), RT (10 min)
	LDS-68	1:32000	Sigma	0.4% pepsin in 0.01 N hydrochloric acid, 37°C (15 min)
Cytokeratin 20	Ks 20.8	1:10	Dako	0.1% pronase in Tris-HCl buffer, 37°C (5 min)
	Ks 20.8	1:10	Dako	without pretreatment
	Ks 20.8	1:50	Dako	boiled in 10 mm citrate buffer pH 6
	Ks 20.8	1:60	Dako	0.1% pronase, RT (10 min)
	Ks 20.8	1:60	Bio Genex	0.5% protease XIV 20°C (15 min)
	Ks 20.8	1:100	Dako	0.01 M citrate buffer pH 6, microwave (15 min)
Cytokeratin 20 (RTU-CK20)	Ks 20.8	ready to use	Novocastra	0.01 M citrate buffer pH 6, microwave (20 min)
Cytokeratin 20 (NCL-CK20)	Ks 20.8	1:1350	Novocastra	proteinase K (ready-to-use), RT (10 min)

Table 1. Monoclonal antibodies against CK7 and CK20, their dilution and the antigen retrieval methods

Organ	Tumor type/subtype	CK7+/CK20+ (%)	CK7+/CK 20 - (%)	CK7-/CK20+ (%)	CK7-/CK20- (%)
Lungs	mixed BAC	100	0	0	0
	mucinous BAC	83	17	0	0
	nonmucinous BAC	0	100	0	0
	PAED	18.75	68.75	12.5	0
	adenocarcinoma	8-10	84-96	0	0
	carcinoid tumors	0	22	0	78
	small cell carcinoma	0	43	0	57
	squamous cell carcinoma	0	47	0	53
	neuroendocrine carcinoma	0	56	0	44
Sinonasal tract	ITAC	80	8	4	8
	non-ITAC	0	100	0	0
Salivary gland	salivary duct carcinoma	37.5	62.5	0	0
	mucoepidermoid carcinoma	7.7	92.3	0	0
	AdCC	4	96	0	0
	PLGA	0	100	0	0
	ACC	0	100	0	0
	Ca-ex-MT	0	100	0	0
	CCC	0	100	0	0
	BCAC	0	100	0	0
Thyroid gland	papillary carcinoma	0	100	0	0
	follicular carcinoma	0	100	0	0
	insular carcinoma	0	60	40	0
	anaplastic carcinoma	0	84	0	16
	medullary carcinoma	0	100	0	0
Thymus	thymoma	0	0	0	100
Pancreas	adenocarcinoma	48-62	30-80	0-7	4-8
Liver	hepatocellular carcinoma	0	9-12.5	9	82-87.5
	neuroendocrine carcinoma	0	56	0	44
Biliary tract	cholangiocarcinoma	24-43	50-76	0	7-13
	gallbladder carcinoma	27	55	0	18
Stomach	gastric adenocarcinoma	13-33	24-25	33-37	10-25
Ovary	mucinous adenocarcinoma	76	14	0	0
	nonmucinous adenocarcinoma	7	93	0	0



Organ	Tumor type/subtype	CK7+/CK20+ (%)	CK7+/CK 20 - (%)	CK7-/CK20+ (%)	CK7-/CK20- (%)
Uterus	endometrial carcinoma	0	100	0	0
	cervical squamous cell carcinoma	0	87	0	13
Breast	infiltrating ductal carcinoma	0	95	0	5
	infiltrating lobular carcinoma	0	100	0	0
Kidney	renal oncocytoma	60	20	20	0
	renal cell carcinoma	0	11	0	89
Bladder	urothelial adenocarcinoma	61	21	4	14
	transitional cell carcinoma	25	63	4	8
Prostate	adenocarcinoma	0-2	0-9	0-14	81-100
Colon	serrated adenoma	71	4.5	25	0
	hyperplastic polyp	68	0	32	0
	adenocarcinoma	5-8.3	1-2.1	83-100	0-6.3
	conventional adenoma	5	0	85	10
	neuroendocrine carcinoma	0	56	0	44
Mesothelium	malignant mesothelioma	0	65	0	35
Skin and soft tissue	merkel cell carcinoma	0	0	78	12
	epithelioid sarcoma	0	0	0	100
	MPNST	0	0	0	100
	MFH	0	0	0	100
	leiomyosarcoma	0	0	0	100
	angiosarcoma	0	0	0	100
	desmoids tumor	0	0	0	100
	rhabdomyosarcoma	0	0	0	100
	primitive neuroectodermal tumor	0	0	0	100

Abbreviations: BAC, bronchioloalveolar adenocarcinoma; PAED, pulmonary adenocarcinoma with enteric differentiation; ITAC, intestinal-type adenocarcinoma; AdCC, adenoid cystic carcinoma; PLGA, polymorphous low-grade adenocarcinoma; ACC, acinic cell carcinoma; Ca-ex-MT, carcinoma ex mixed tumor; CCC, clear cell carcinoma; BCAC, basal cell adenocarcinoma; MPNST, malignant peripheral nerve sheath tumor; MFH, malignant fibrous histiocytoma.

Table 2. Distribution of CK7/CK20 phenotype in different types of tumors of different organs (based on references: Bassily et al., 2000; Cambell & Harrington, 2001; Chu et al., 2000; Duval et al., 2000; Hatanaka et al., 2011; Humble et al., 2003; Kummar et al., 2002; Lam et al., 2001; Nikitakis et al., 2004; Rekhi et al., 2008; Saeb-Lima et al., 2008; Sawan, 2009; Simsir et al., 2004; Stopyra et al., 2001; Tatsumi et al., 2005; Tot, 2002; Wauter et al., 1995)

#### 4. Conclusion

This chapter shows that the CK7/CK20 phenotype of tumors can be a valuable diagnostic marker in the determination of the primary site of origin of metastatic tumor (Fig. 1, 2, Table 2). Detection of CK7+/CK20- phenotype indicates metastatic carcinoma, most often from the lungs, salivary gland or breast in bone, ovaries, liver, colon and even in bone marrow. The CK7-/CK20+ phenotype indicates metastatic carcinoma, usually from the colorectal region mainly in lungs and ovaries. Whereas, the CK7-/CK20- phenotype indicates metastatic carcinoma often from the prostate, mainly in bone. However, the different CK7/CK20 immunophenotypes do not show 100% specificity and sensitivity for any tumor. Therefore, CK7 and CK20 should be used as a part of an immunohistochemical panel of antibodies. Despite the fact, that the data presented in this chapter come from reports from recent years, further studies involving cases of tumors with clearly identified primary location, tumor type and subtype are necessary to confirm these results and to extend CK phenotyping to rare tumor types. Moreover, further studies are needed for evaluation of RT-PCR for CK20 mRNA in serum, blood, urine for the identification of tumor cells. Due to the relatively widespread expression of cytokeratin 7 in epithelial cells of various organs, further research related to the gene KTR7 (Pujal et al., 2009) could be useful in therapeutic strategies for epithelial neoplasms.

#### 5. Acknowledgment


I am grateful to Dr Anna Kycko for her help in correcting the English language.

#### 6. References

- Barrett, A.W.; Cort, E.M.; Patel, P. & Berkovitz, B.K.B. (2000). An immunohistochemical study of cytokeratin 20 in human and mammalian oral epithelium. *Archives of Oral Biology*, Vol.45, No.10, pp.879-887, ISSN 0003-9969
- Bassily, N.H.; Vallorosi, Ch.J.; Akdas, G.; Montie, J.E. & Rubin, M.A. (2000). Coordinate expression of cytokeratins 7 and 20 in prostate adenocarcinoma and bladder urothelial carcinoma. *American Journal of Clinical Pathology*, Vol.113, No.3, pp.383-388, ISSN 0002-9173
- Bragulla, H.H. & Homberger, D.G. (2009). Structure and functions of keratin proteins in simple, stratified, keratinized and cornified epithelia. *Journal of Anatomy*, Vol.214, No.4, pp.516-559, ISSN 0021-8782
- Campbell, F. & Herrington, C.S. (2001). Application of cytokeratin 7 and 20 immunohistochemistry to diagnostic pathology. *Current Diagnostic Pathology*, Vol.7, No.2, pp.113-122, ISSN 0968-6053
- Chu, P.; Wu, E. & Weiss, L.M. (2000). Cytokeratin 7 and cytokeratin 20 expression in epithelial neoplasms: A survey of 435 cases. *Modern Pathology*, Vol.13, No.9, pp.962-972, ISSN 0893-3952
- Duval, J.V.; Savas, L. & Banner, B.F. (2000). Expression of cytokeratins 7 and 20 in carcinomas of the extrahepatic biliary tract, pancreas, and gallbladder. *Archives of Pathology & Laboratory Medicine*, Vol.124, No.8, pp.1196-1200, ISSN 0003-9985

- Fiddler, S.; Kaj, J.; Plochocki, M.; Filipczyk-Cisarż, E. & Ziemia, B. (2007). Upper limb amputation in the course of skin metastases of rectal cancer. *Onkologia w Praktyce Klinicznej*, Vol. 3, No.5, pp.259-262, ISSN 1734-3542
- Franchi, A.; Massi, D.; Plomba, A.; Biancalani, M. & Santucci, M. (2004). CDX-2, cytokeratin 7 and cytokeratin 20 immunohistochemical expression in the differential diagnosis of primary adenocarcinomas of the sinonasal tract. *Virchows Arch*, Vol.445, No.1, pp.63-67, ISSN 1432-2307
- Hatanaka, K.; Tsuta, K.; Watanabe, K.; Sugino, K. & Uekusa, T. (2011). Primary pulmonary adenocarcinoma with enteric differentiation resembling metastatic colorectal carcinoma: A report of the second case negative for cytokeratin 7. *Pathology Research and Practice*, Vol.207, No.3, pp.188-191, ISSN 0344-0338
- Humble, S.D.; Prieto, V.G. & Horenstein, M.G. (2003). Cytokeratin 7 and 20 expression in epithelioid sarcoma. *Journal of Cutaneous Pathology*, Vol.30, No.4, pp.242-246, ISSN 0303-6987
- Iwatsuki, H. & Suda, M. (2010). Seven kinds of intermediate filament networks in the cytoplasm of polarized cells: structure and function. *Acta Histochemica et Cytochemica*, Vol.43, No.2, pp.19-31, ISSN 0044-5991
- Jovanovic, I.; Tzardi, M.; Mouzas, I.A.; Micev, M.; Pesko, P.; Milosavljevic, T.; Zois, M.; Sganzos, M.; Delides, G. & Kanavaros, P. (2002). Changing pattern of cytokeratin 7 and 20 expression from normal epithelium to intestinal metaplasia of the gastric mucosa and gastroesophageal junction. *Histology and Histopathology*, Vol.17, No.2, pp.445-454, ISSN 0213-3911
- Kummar, S.; Fogarasi, M.; Canova, A.; Mota, A. & Ciesielski, T. (2002). Cytokeratin 7 and 20 staining for the diagnosis of lung and colorectal adenocarcinoma. *British Journal of Cancer*, Vol.86, No.12, pp.1884-1887, ISSN 0007-0920
- Moll, R.; Franke, W.W. & Schiller, D.L. (1982). The catalog of human cytokeratins: patterns of expression in normal epithelial, tumors and cultured cells. *Cell*, Vol.31, No.1, pp.11-24, ISSN 0092-8674
- Moll, R.; Zimbelmann, R.; Goldschmidt, M.D.; Keith, M.; Laufer, J.; Kasper, M.; Koch, P.J. & Franke, W.W. (1993). The human gene encoding cytokeratin 20 and its expression during fetal development and in gastrointestinal carcinomas. *Differentiation*, Vol.53, No.2, pp.75-93, ISSN 1432-0436
- Moll, R.; Divo, M. & Langbein, L. (2008). The human keratins: biology and pathology. *Histochemistry and Cell Biology*, Vol.129, No.6, pp.705-733, ISSN 0948-6143
- Nikitakis, N.G.; Tosios, K.I.; Papanikolaou, V.S.; Rivera, H.; Papanicolaou, S.I. & Ioffe, O.B. (2004). Immunohistochemical expression of cytokeratins 7 and 20 in malignant salivary gland tumors. *Modern Pathology*, Vol.17, No.4, pp.407-415, ISSN 0893-3952
- Pu, X-Y.; Wang, Z-P.; Chen, Y-R.; Wang, X-H.; Wu, Y-L. & Wang, H-P. (2008). The value of combined use of survivin, cytokeratin 20 and mucin 7 mRNA for bladder cancer detection in voided urine. *Journal of Cancer Research and Clinical Oncology*, Vol.134, No.6, pp.659-665, ISSN 0171-5216
- Pujal, J.; Huch, M.; José, A.; Abasolo, I.; Rodolosse, A.; Duch, A.; Sánchez-Palazón, L.; Smith, F.J.D.; McLean, W.H.I.; Fillat, C. & Real, F.X. (2009). Keratin 7 promoter selectively targets transgene expression to normal and neoplastic pancreatic ductal cells *in vitro* and *in vivo*. *The FASEB Journal*, Vol.23, No.5, pp.1366-1375, ISSN 0892-6638

- Rekhi, B.; George, S.; Madur, B.; Chinoy, R.F.; Dikshit, R. & Maheshwari, A. (2008). Clinicopathological features and the value of differential cytokeratin 7 and 20 expression in resolving diagnostic dilemmas of ovarian involvement by colorectal adenocarcinoma and vice-versa. *Diagnostic Pathology*, Vol.3, p.39, ISSN 1746-1596
- Saeb-Lima, M.; Montante-Montes de Oca, D. & Albores-Saavedra, J. (2008). Merkel cell carcinoma with eccrine differentiation: a clinicopathologic study of 7 cases. *Annals of Diagnostic Pathology*, Vol.12, No.6, pp.410-414, ISSN 1092-9134
- Sawan, A.S. (2009). The diagnostic value of immunohistochemistry in the diagnosis of primary and secondary hepatic carcinomas. *The Journal of King Abdulaziz University-Medical Sciences*, Vol.16, No.4, pp.37-48, ISSN 1319-1004
- Schweizer, J.; Bowden, P.E.; Coulombe, P.A.; Langbein, L.; Lane, E.B.; Magin, T.M.; Maltais, L.; Omary, M.B.; Parry, D.A.D.; Rogers, M.A. & Wright, M.W. (2006). New consensus nomenclature for mammalian keratins. *The Journal of Cell Biology*, Vol.174, No.2, pp.169-174, ISSN 0021-9525
- Simsir, A.; Wei, X-J.; Yee, H.; Moreira, A. & Cangiarella, J. (2004). Differential expression of cytokeratins 7 and 20 and thyroid transcription factor -1 in bronchioloalveolar carcinoma. An immunohistochemical study in fine-needle aspiration biopsy specimens. *American Journal of Clinical Pathology*, Vol.121, No.3, pp.350-357, ISSN 0002-9173
- Stopyra, G.A.; Warhol, M.J. & Mulhaupt, A.B. (2001). Cytokeratin 20 immunoreactivity in renal oncocytomas. *The Journal of Histochemistry & Cytochemistry*, Vol.49, No.7, pp.919-920, ISSN 0022-1554
- Szeverenyi, I.; Cassidy, A.J.; Chung, C.W.; Lee, B.T.; Common, J.E.; Ogg, S.C.; Chen, H.; Sim, S.Y.; Goh, W.L.; Ng, K.W.; Simpson, J.A.; Chee, L.L.; Eng, G.H.; Li, B.; Lunny, D.P.; Chuon, D.; Venkatesh, A.; Khoo, K.H.; McLean, W.H.; Lim, Y.P. & Lane, E.B. (2008). The human intermediate filament database: comprehensive information on a gene family involved in many human diseases. *Human Mutation*, Vol.29, No.3, pp.351-360, ISSN 1059-7794
- Tatsumi, N.; Mukaisho, K.; Mitsufuji, S.; Tatsumi, Y.; Sugihara, H.; Okanou, T. & Hattori, T. (2005). Expression of cytokeratins 7 and 20 in serrated adenoma and related diseases. *Digestive diseases and Sciences*, Vol.50, No.9, pp.1741-1746, ISSN 0163-2116
- Tot, T. (2002). Cytokeratins 20 and 7 as biomarkers: usefulness in discriminating primary from metastatic adenocarcinoma. *European Journal of Cancer*, Vol.38, No.6, pp.758-763, ISSN 0959-8049
- Upasani, O.S.; Vaidya, M.M. & Bhisey, A.N. (2004). Database on monoclonal antibodies to cytokeratins. *Oral Oncology*, Vol.40, No.3, pp.236-256, ISSN 1368-8375
- Wang, J-Y.; Wu, Ch-H.; Lu, Ch-Y.; Hsieh, J-S.; Wu, D-Ch.; Huang, S-Y. & Lin, S-R. (2006). Molecular detection of circulating tumor cells in the peripheral blood of patients with colorectal cancer using RT-PCR: significance of the prediction of postoperative metastasis. *World Journal of Surgery*, Vol.30, No.6, p.1007-1013, ISSN 0364-2313
- Wauters, C.C.A.P.; Smedts, F.; Gerrits, L.G.M.; Bosman, F.T. & Ramaekers, F.C.S. (1995). Keratins 7 and 20 as diagnostic markers of carcinomas metastatic to the ovary. *Human Pathology*, Vol.26, No.8, pp.852-855, ISSN 004



## **Cytokeratins - Tools in Oncology**

Edited by Dr. Gerhard Hamilton

ISBN 978-953-51-0047-8

Hard cover, 158 pages

**Publisher** InTech

**Published online** 29, February, 2012

**Published in print edition** February, 2012

The first chapters of the volume "Cytokeratins - Tools in Oncology" discuss multiple functions of cytokeratins in organization of the intermediary filaments in normal intestine and liver as well as microfold L cells and the usability of cytokeratins 7, 8 and 20 in tumor diagnosis in detail. Epithelial to mesenchymal transition as a mechanism important in pathogenesis is touched in another chapter, followed by several articles dealing with the role of cytokeratins for detection of disseminated tumor cells and as response markers during chemotherapy. This book is therefore destined to all cancer researchers and therapists who want to understand the diagnostic application of cytokeratins in histology and, especially, the use of anti-cytokeratin antibodies to identify viable residual tumor cells accounting for a higher risk of tumor recurrence or cancer cells responding to chemotherapy, respectively.

### **How to reference**

In order to correctly reference this scholarly work, feel free to copy and paste the following:

Agnieszka Jasik (2012). Cytokeratin 7 and 20, Cytokeratins - Tools in Oncology, Dr. Gerhard Hamilton (Ed.), ISBN: 978-953-51-0047-8, InTech, Available from: <http://www.intechopen.com/books/cytokeratins-tools-in-oncology/cytokeratins-7-and-20>

**INTECH**  
open science | open minds

### **InTech Europe**

University Campus STeP Ri  
Slavka Krautzeka 83/A  
51000 Rijeka, Croatia  
Phone: +385 (51) 770 447  
Fax: +385 (51) 686 166  
[www.intechopen.com](http://www.intechopen.com)

### **InTech China**

Unit 405, Office Block, Hotel Equatorial Shanghai  
No.65, Yan An Road (West), Shanghai, 200040, China  
中国上海市延安西路65号上海国际贵都大饭店办公楼405单元  
Phone: +86-21-62489820  
Fax: +86-21-62489821

© 2012 The Author(s). Licensee IntechOpen. This is an open access article distributed under the terms of the [Creative Commons Attribution 3.0 License](#), which permits unrestricted use, distribution, and reproduction in any medium, provided the original work is properly cited.