

# Complications Associated with Surgical Treatment of Hydrocephalus

Takeshi Satow, Masaaki Saiki and Takayuki Kikuchi  
*Department of Neurosurgery, Shiga Medical Center for Adults  
Japan*

## 1. Introduction

Excessive accumulation of cerebrospinal fluid (CSF) in the brain is a condition known as hydrocephalus. It may cause a life-threatening increase in intracranial pressure (ICP). Nonsurgical treatment of hydrocephalus includes continuous CSF drainage, repetitive lumbar punctures (Lim et al., 2009), or osmotic diuretics such as mannitol or glycerol, but their effects are transient and limited. Surgical treatment is needed to resolve the critical condition caused by increased ICP.

Hydrocephalus can be classified as communicating or obstructive (non-communicating). In selecting surgical treatment, it is important to judge which is involved. Communicating hydrocephalus occurs when CSF flow is not blocked at any part of the passages connecting the ventricles. In obstructive hydrocephalus, CSF flow is blocked along one or more narrow passages between the ventricles. Hydrocephalus is treated by surgical insertion of a shunt system, such as a ventriculoperitoneal shunt (VP shunt), lumboperitoneal shunt (LP shunt) or ventriculoatrial shunt (VA shunt). The LP shunt should not be used in patients with obstructive hydrocephalus, because it can induce tentorial herniation leading to death. A limited number of patients with obstructive hydrocephalus are candidates for third ventriculostomy by neuroendoscope. Below, we review articles focusing on complications associated with various types of CSF diversion procedure.

## 2. Complications associated with any shunts

Surgical techniques for treatment of hydrocephalus are well established, but are associated with a relatively high incidence of complications (Blount et al., 1993, Kang & Lee, 1999). Complications associated with shunt procedures include infection, malfunction (obstruction or disconnection) and silicone allergy, and overdrainage.

Infection of the shunt system is a troublesome and common complication. It is a major cause of morbidity and mortality in the treatment of hydrocephalus. The incidence of CSF shunt infection is approximately 2 - 22% in most neurosurgical units throughout the world (Schoenbaum et al., 1975, Mayhall et al., 1984, Spanu et al., 1986, Patir et al., 1992). The use of an antibiotic-impregnated shunt (AIS, impregnated with rifampicin and clindamycin) has been reported recently to reduce the incidence of shunt infection (Govender et al., 2003, Sciubba et al., 2005, Pattavilakom et al., 2007). AIS use is not common, however, so that it is difficult to determine the efficacy of AIS in preventing shunt infection (Steinbok et al., 2010).

Moreover, a systematic review by Ratilal et al. (2008) found that systemic prophylactic antibiotics prevented shunt infection better than AIS. There have been investigations of the effect of more simple techniques, focusing on intraoperative sterile conditions such as intraoperative irrigation (Hayashi et al., 2008, 2010), changing gloves before handling the shunt catheter (Sørensen et al., 2008, Rehman et al., 2010) or a double-gloving strategy (Tulipan & Cleves, 2006), and antimicrobial suture wound closure (Rozzelle et al., 2008). Where AIS is unavailable, we recommend the systemic administration of antibiotics, generous intraoperative irrigation and double-gloving.

Shunt malfunction is another common problem following CSF shunting. It leads to various symptoms including headache, nausea and vomiting, visual disturbance, seizures, changes in intellect or personality, disturbance of consciousness and sudden death. The ventricular side is reportedly obstructed more often (Cozzens & Chandler, 1997). Disconnection at any point of the shunt system is first investigated by plain radiograph and/or CT (Fig.1).

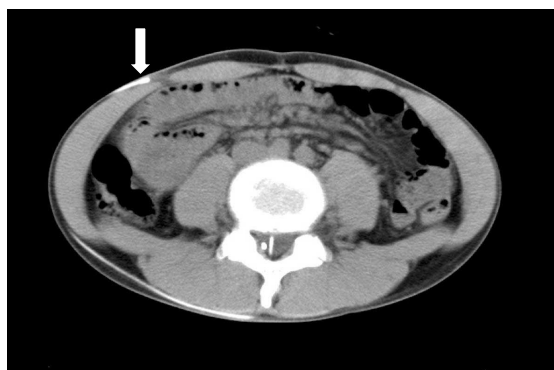


Fig. 1. CT scan of the abdomen

A patient with a previous LP shunt placement presented with it malfunctioning. CT showed it had disconnected where the catheter entered the peritoneal cavity (arrow).

Recently a programmable shunt valve has been used to control the CSF flow. Breakage of the programmable pressure valve is difficult to diagnose by plain radiograph or CT, however. Since the tract of shunt tube becomes calcified in patients harboring a shunt system for a long period, making diagnosis of its disconnection difficult, it might be advisable to carry out shuntgraphy to locate the occlusion of the shunt system. CSF infection must then be investigated. Fibrous tissue generated by long-lasting contact of the ventricular catheter with the choroid plexus can lead to its occlusion. High CSF cell count and protein levels are believed to be a cause of shunt malfunction, although not in all cases (Fulkerson et al., 2011). Even without infection, an allergic reaction to the shunt catheter occasionally leads to shunt malfunction (Jimenez et al., 1994, Hussain et al., 2005, Bezerra et al., 2011). In such cases, prolonged use of corticosteroid or replacement of the shunt system with a polyurethane-based system (Hussain et al., 2005) is appropriate.

In shunt malfunction, there have been numerous reports of malfunctions of the distal catheter (peritoneal tube). When malfunction at the distal catheter is suspected, plain radiograph and CT scan are performed. Bowel perforation (Fig.2) (Abu-Dalu et al., 1983, Sathyanarayana et al., 2000, Vinchon et al., 2006) and intra-abdominal pseudocyst formation

(Rainov et al., 1994; Anderson et al., 2003) are known to be a cause of distal catheter malfunction.



Fig. 2. Photograph of a patient with bowel perforation of a VP shunt. The peritoneal side of the catheter extruded from the anus. The shunt system was removed surgically. The peritoneal catheter was cut at the point where it perforated into the rectum, and the extruded distal catheter was pulled out from the side of the anus.

Latent infection could give rise to complications of this sort. In such cases, we carry out tentative externalization of the ventricular catheter after removing the peritoneal catheter and repairing the fistula point if necessary. Even without evidence of infection, we have occasionally experienced patients in whom a shunt of this sort has not been functional from the start (unnecessary shunt). Clearly it is important to consider the indication for CSF shunt before any implantation. Protrusion or migration of a peritoneal catheter has also been reported from other sites, including the heart (Fewel & Garton, 2004), pleural cavity (Doh et al., 1995), stomach (Alonso-Vanegas et al., 1994), a gastrostomy wound (Chan et al., 2003), mouth (Berhouma et al., 2008), scrotum (Oktem et al., 1998), umbilicus (Wani et al., 2002, Kanojia et al., 2008) and lumbar region (Kanojia et al., 2008). Also, very rare cases of knot formation of a peritoneal catheter, leading to obstruction of the shunt as well as small-bowel, have been reported (Starreveld et al., 1998, Woerdeman & Hanlo, 2006, Eftekhari & Hunn, 2008).

Constipation is often observed in bed-ridden patients. Infrequently it is a cause of shunt malfunction, due to increased intra-abdominal pressure (Powers et al., 2006, Martínez-Lage et al., 2008). Treatment of constipation could improve the neurological condition of such patients. Constipation should not be forgotten as a cause of shunt malfunction prior to revision surgery.

The sections below review complications associated with particular treatment methods.

### 3. Complication associated with particular shunts

#### 3.1 Ventriculoperitoneal shunt (VP shunt)

VP shunt is the most common procedure for treating hydrocephalus. Various reported complications derive from the VP shunt. As the VP shunt system is longer than the LP shunt or VA shunt, we speculate that migration is unlikely to occur in association with a VP shunt. Many reports (Ammar & Nasser, 1995, Acharya et al., 2002, Nadkarni et al., 2007, Chen et al., 2011) have found an upward migration of a VP shunt, however. Even in VP shunt implantation, firm fixation is recommended, particularly at the rectus abdominis fascia.

Pneumocephalus (Kawajiri et al., 1994, Villarejo et al., 1998, Barada et al., 2009) and pneumoventricle (Perrin & Bernstein, 2005) have been reported as a complication of VP shunt. This overdrainage complication seems to occur in association with VP shunt and also in other shunt operations. It is believed that this complication arises when a shunt is implanted in patients whose paranasal sinus is left open. Consequently, it is important to investigate the possibility of open paranasal sinuses, particularly when patients undergo shunt placement after a head injury or previous cranial surgeries involving the paranasal sinuses.

In patients with a brain tumor who underwent VP shunt, peritoneal dissemination of the tumor can take place (Berger et al., 1991, Newton et al., 1992, Rickert et al., 1998).

As in other cranial surgeries, patients with a ventricular catheter have a 5.5% risk of seizure in the first year after the operation (Dan & Wade, 1986). The efficacy of prophylactic use of anticonvulsants has never been established in patients undergoing shunt surgery, however. In addition, epileptic seizure could be a manifestation of shunt malfunction (Johnson et al., 1996).

Very rarely, superficial siderosis of the central nervous system (Fig.3) has been reported after VP shunt (Satow et al., 2010). This might be caused by repeated long-lasting contact of the ventricular catheter with the choroid plexus. Transient improvement of neurological symptoms such as ataxia was observed following prescription of corticosteroid. In such cases, replacement of the VP shunt by a lumboperitoneal shunt might be necessary.

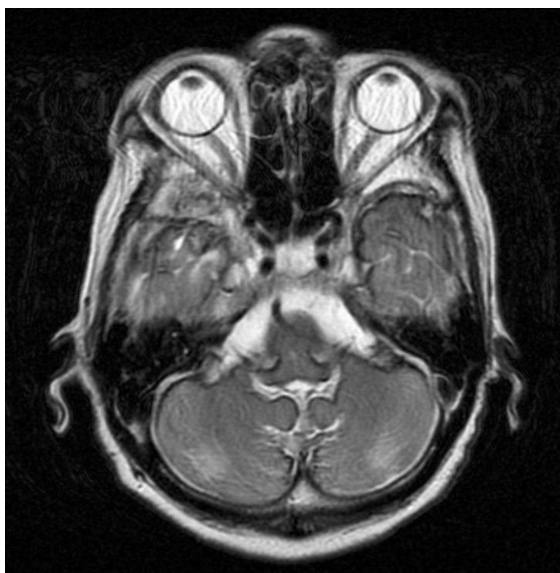


Fig. 3. MRI of the brain showing superficial siderosis after VP shunt (T2-weighted sequence)

A patient with normal pressure hydrocephalus underwent VP shunt placement. About 2 years after the operation, new symptoms developed including ataxia and hearing disturbance. MRI showed a rim of low-intensity enveloping the surface of the brain stem and cerebellum, which is the characteristic appearance of superficial siderosis of the central nervous system.

### 3.2 Lumboperitoneal shunt (LP shunt)

Lumboperitoneal shunt (LP shunt) is performed in patients with communicating hydrocephalus. It is also performed for the treatment of CSF fistula, idiopathic intracranial hypertension (Burgett et al., 1997) and slit-ventricle syndrome (Le et al., 2002). Complications such as infection and malfunction were reportedly lower in LP shunt than VP shunt (Aoki, 1990).

Acute subdural hematoma after minor head trauma is reported in about 2% of patients with LP shunt (Kamiryo et al., 2003). LP shunt is cautiously indicated for patients who do not live independently on a daily basis and who are prone to fall. Acquired Chiari malformation is a well-known complication after LP shunt (Payner et al., 1994, Wang et al., 2007). These complications are a manifestation of overdrainage. Complications due to overdrainage could be prevented by introducing a pressure control valve for the LP shunt (Wang et al., 2007).

Proximal migration of LP shunts have been reported (Yoshida et al., 2000, Satow et al., 2001, Rodrigues et al., 2005). Defects in the fixation device or increased intraabdominal pressure are believed to be a cause of proximal migration of the LP shunt. Recently, programmable shunt systems have become available for LP shunt (Toma et al., 2010), and these might act as an anchor to prevent migration of the LP shunt.

LP shunt surgery does not include cranial procedures, which causes surgeons to believe it is a safer treatment. However, it should be kept in mind that various serious complications can occur after LP shunt.

### 3.3 Ventriculoatrial shunt (VA shunt)

VA shunt has recently been performed on rare occasions. A distal shunt catheter is inserted into the right atrium via the facial vein or internal jugular vein. Consequently, once infection of the shunt system occurs, septicemia develops. Chronic infection of a VA shunt results in an immune-complex-mediated glomerulonephritis, called "shunt nephritis" (Sticker et al., 1968). This serious complication is caused by a skin commensal organism such as *Staphylococcus epidermidis* or other bacteria, and it requires revision of the shunt system. Very rarely, pulmonary hypertension caused by venous thrombus formation has been reported as a complication of VA shunt (Piatt & Hoffman, 1989, Tonn et al., 2005, Kluge et al., 2010); this could be lethal. As there are fatal cardiopulmonary complications associated with VA shunt, it should be used only in patients whose peritoneal cavity is not suitable for the placement of a distal shunt catheter.

### 3.4 Endoscopic third ventriculostomy

Endoscopic third ventriculostomy (ETV) is indicated and effective for obstructive hydrocephalus (Hellwig et al., 2005, Schroeder et al., 2007). Some authors have reported the use of ETV for communicating hydrocephalus (Gangemi et al., 2004, 2008, Hailong et al., 2008). The procedure did not need foreign materials such as a shunt catheter, so the incidence of infection is considered to be low. Moreover, in patients with shunt malfunction caused by infection of the shunt, ETV and removal of the shunt system are recommended.

Fatal complications have been also reported, including high-frequency tachypnea (Bernard et al., 2010), late failure (Drake et al., 2006, Lipina et al., 2007), and subarachnoid hemorrhage due to injury to the basilar artery (Schroeder et al., 1999, 2002). Although rare, overdrainage complication involving chronic subdural hematoma or fluid collection has

also been reported (Kim et al., 2004, Sqaramella et al., 2004). An overdrainage complication manifesting acute subdural hematoma can occur, leading to death (Fig. 4).

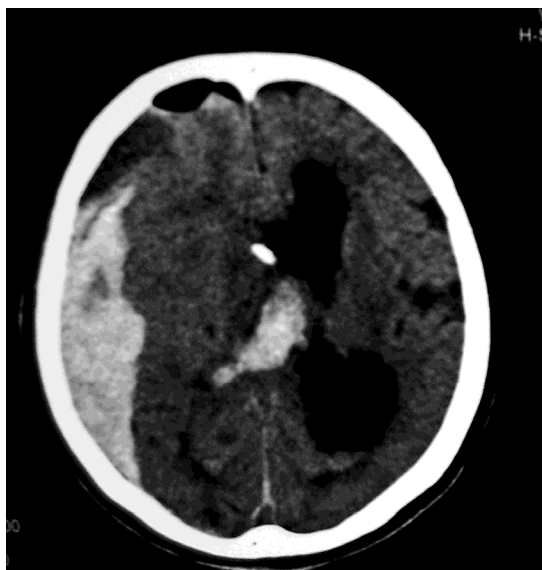


Fig. 4. Acute subdural hematoma (ASDH) after ETV for obstructive hydrocephalus due to brain stem hemorrhage.

One day after ETV, the patient developed dilation of pupils more on the right side. CT disclosed ASDH on the right side. When ETV was performed, external ventricular drainage was placed because of the likelihood of early failure of the ventriculostomy. Although ventricular drainage remained nonfunctioning, ASDH developed as an overdrainage complication of ETV. At surgical evacuation of the hematoma, the bleeding point was confirmed as a cortical artery around the sylvian fissure, far from the puncture point of the ETV.

#### 4. Conclusion

In this article we have reviewed various complications associated with CSF diversion procedures, which are performed routinely in neurosurgical practice for the treatment of hydrocephalus. There appear to be numerous ways of preventing those complications, developed by various physicians, as described in this article. In the literature of general surgery, complications associated with operation have usually been considered underreported (Wanzel et al., 2000). It is important to report these ways so as to reduce the rate of complication in this common neurosurgical operation.

#### 5. References

Abu-Dalu, K., Pade, D., Hadani, M., & Sahar, A. (1983). Colonic complications of ventriculoperitoneal shunts. *Neurosurgery*, Vol.13, pp. 167-169.

- Acharya, R., Bhutani, A., Saxena, H., & Madan, VS. (2002). Complete migration of ventriculoperitoneal shunt into the ventricle. *Neurol Sci*, Vol.23, pp. 75-77.
- Alonso-Vanegas, M., Alvarez, JL., Delgado, L., Mendizabal, R., Jiménez, JL., & Sanchez-Cabrera, JM. (1994). Gastric perforation due to ventriculo-peritoneal shunt. *Pediatr Neurosurg*, Vol.21, pp. 192-194.
- Ammar, A., & Nasser, M. (1995). Intraventricular migration of VP shunt. *Neurosurg Rev*, Vol.18, pp. 293-295.
- Anderson, CM., Sorrells, DL., & Kerby, JD. (2003). Intra-abdominal pseudocysts as a complication of ventriculoperitoneal shunts: a case report and review of the literature. *Curr Surg*, Vol.60, pp. 338-340.
- Aoki N. (1990). Lumboperitoneal shunt: clinical applications, complications, and comparison with ventriculoperitoneal shunt. *Neurosurgery*, Vol.26, pp. 998-1003.
- Barada, W., Najjar, M., & Beydoun, A. (2009). Early onset tension pneumocephalus following ventriculoperitoneal shunt insertion for normal pressure hydrocephalus: a case report. *Clin Neurol Neurosurg*, Vol.111, pp. 300-302.
- Berger, MS., Baumeister, B., Geyer, JR., Milstein, J., Kabev, PM., & LeRoux, PD. (1991). The risks of metastases from shunting in children with primary central nervous system tumors. *J Neurosurg*, Vol.74, pp. 872-877.
- Berhouma, M., Messerer, M., Houissa, S., & Khaldi, M. (2008). Transoral protrusion of a peritoneal catheter: a rare complication of ventriculoperitoneal shunt. *Pediatr Neurosurg*, Vol.44, pp. 169-171.
- Bernard, R., Vallee, F., Mateo, J., Marsella, M., George, B., Payen, D., & Chibbaro, S. (2010). Uncntrollable high-frequency tachypnea: a rare and nearly fatal complication of endoscopic third ventriculostomy: case report and literature review. *Minim Invasive Neurosurg*, Vol.53, pp. 270-272.
- Bezerra, S., Frigeri, TM., Severo, CM., Santana, JC., & Graeff-Teixeira, C. (2011). Cerebrospinal fluid eosinophilia associated with intraventricular shunts. *Clin Neurol Neurosurg*, Vol.113, pp. 345-349.
- Blount, JP., Campbell, JA., & Haines, SJ. (1993). Complications in ventricular cerebrospinal shunting. *Neurosurg Clin N Am*, Vol.4, pp. 633-656.
- Burgett, RA., Purvin, VA., & Kawasaki, A. (1997). Lumboperitoneal shunting for pseudotumor cerebri. *Neurology*, Vol.49, pp. 734-739.
- Chan, Y., Datta, NN., Chan, KY., Rehman, SU., Poon, CY., & Kwok, JC. (2003). Extrusion of the peritoneal catheter of a VP shunt system through a gastrostomy wound. *Surg Neurol*, Vol.60, pp. 68-69.
- Chen, HH., Riva-Cambrin, J., Brockmeyer, DL., Walker, ML., & Kestle, JR. (2011). Shunt failure due to intracranial migration of BioGlide ventricular catheter. *J Neurosurg Pediatr*, Vol.7, pp. 408-412.
- Cozzens, JW., & Chandler, JP. (1997). Increased risk of distal ventriculoperitoneal shunt obstruction associated with slit valves or distal slits in the peritoneal catheter. *J Neurosurg*, Vol.87, pp. 682-686.
- Dan, NG., & Wade, MJ. (1986). The incidence of epilepsy after ventricular shunting procedures. *J Neurosurg*, Vol.65, pp. 19-21.
- Doh, JW., Bae, HG., Lee, KS., Yun, IG., & Byun, BJ. (1995). Hydrothorax from intrathoracic migration of a ventriculoperitoneal shunt catheter. *Surg Neurol*, Vol.43, pp.340-343.

- Drake, J., Chumas, P., Kestle, J., Pierre-Kahn, A., Vinchon, M., Brown, J., Pollack, IF., & Arai, H. (2006). Late rapid deterioration after endoscopic third ventriculostomy: additional cases and review of the literature. *J Neurosurg*, Vol.105 (2 Suppl), pp. 118-126.
- Eftekhari, B., & Hunn, A. (2008). Ventriculoperitoneal shunt blockage due to spontaneous knot formation in the peritoneal catheter. Case report. *J Neurosurg Pediatr*, Vol.1, pp. 142-143.
- Fewel, ME., & Garton, HJ. (2004). Migration of distal ventriculoperitoneal shunt catheter into the heart. Case report and review of the literature. *J Neurosurg*, Vol.100 (2 Suppl Pediatrics), pp. 206-211.
- Fulkerson, DH., Vachhrajani, S., Bohnstedt, BN., Patel, NB., Patel, AJ., Fox, BD., Jea, A., & Boaz, JC. (2011). Analysis of the risk of shunt failure or infection related to cerebrospinal fluid cell count, protein level, and glucose levels in low-birth-weight premature infants with posthemorrhagic hydrocephalus. *J Neurosurg Pediatr*, Vol.7, pp. 147-151.
- Gangemi, M., Maiuri, F., Buonamassa, S., Colella, G., & de Divitiis, E. (2004). Endoscopic third ventriculostomy in idiopathic normal pressure hydrocephalus. *Neurosurgery*, Vol.55, pp. 129-134.
- Gangemi, M., Maiuri, F., Naddeo, M., Godano, U., Mascari, C., Broggi, G., & Ferroli, P. (2008). Endoscopic third ventriculostomy in idiopathic normal pressure hydrocephalus: an Italian multicenter study. *Neurosurgery*, Vol.63, pp. 62-67.
- Govender, ST., Nathoo, N., & van Dellen, Jr. (2003). Evaluation of an antibiotic-impregnated shunt system for the treatment of hydrocephalus. *J Neurosurg*, Vol.99, pp. 831-839.
- Hailong, F., Guangfu, H., Haibin, T., Hong, P., Yong, C., Weidong, L., & Dongdong, Z. (2008). Endoscopic third ventriculostomy in the management of communicating hydrocephalus: a preliminary study. *J Neurosurg*, Vol.109, pp. 923-930.
- Hayashi, T., Shirane, T., Kato, T., & Tominaga, T. (2008) Efficacy of intraoperative wound irrigation for preventing shunt infection. *J Neurosurg Pediatr*, Vol.2, pp. 25-28.
- Hayashi, T., Shirane, R., Yokosawa, M., Kimiwada, T., & Tominaga, T. (2010). Efficacy of intraoperative irrigation with saline for preventing shunt infection. *J Neurosurg Pediatr*, Vol.6, pp. 273-276.
- Hellwig, D., Grotenhuis, JA., Tirakotai, W., Riegel, T., Schulte, DM., Bauer, BL., & Bertalanffy, H. (2005). Endoscopic third ventriculostomy for obstructive hydrocephalus. *Neurosurg Rev*, Vol.28, pp. 1-34
- Hussain, NS., Wang, PP., James, C., Carson, BS., & Avellino, AM. (2005). Distal ventriculoperitoneal shunt failure caused by silicone allergy. Case report. *J Neurosurg*, Vol.102, pp. 536-539.
- Javadpour, M., May, P., & Mallucci, C. (2003). Sudden death secondary to delayed closure of endoscopic third ventriculostomy. *Br J Neurosurg*, Vol.17, pp. 266-269.
- Jimenez, DF., Keating, R., & Goodrich, JT. (1994). Silicone allergy in ventriculoperitoneal shunts. *Childs Nerv Syst*, Vol.10, pp. 59-63.
- Johnson, DL., Conry, J., & O'Donnell, R. (1996). Epileptic seizure as a sign of cerebrospinal fluid shunt malfunction. *Pediatr Neurosurg*, Vol.24, pp. 223-227.




- Kamiryō, T., Hamada, J., Fuwa, I., & Ushio, Y. (2003). Acute subdural hematoma after lumboperitoneal shunt placement in patients with normal pressure hydrocephalus. *Neurol Med Chir (Tokyo)*, Vol.43, pp. 197-200.
- Kang, JK., & Lee, IW. (1999). Long-term follow-up of shunting therapy. *Childs Nerv Syst*, Vol.15, pp. 711-717.
- Kanojia, R., Sinha, SK., Rawat, J., Wakhlu, A., Kureel, S., & Tandon, R. (2008). Unusual ventriculoperitoneal shunt extrusion: experience with 5 cases and review of the literature. *Pediatr Neurosurg*, Vol.44, pp. 49-51.
- Kawajiri, K., Matsuoka, Y., & Hayazaki, K. (1994). Brain tumor complicated by pneumocephalus following cerebrospinal fluid shunting-two case reports. *Neurol Med Chir (Tokyo)*, Vol.34, pp. 10-14.
- Kim, BS., Jallo, GI., Kothbauer, K., & Abbott, IR. (2004). Chronic subdural hematoma as a complication of endoscopic third ventriculostomy. *Surg Neurol*, Vol.62, pp. 64-68.
- Kluge, S., Baumann, HJ., Regelsberger, J., Kehler, U., Gliemroth, J., Koziej, B., Klose, H., & Meyer, A. (2010). Pulmonary hypertension after ventriculoatrial shunt implantation. *J Neurosurg*, Vol.113, pp. 1279-1283.
- Le, H., Yamini, B., & Frim, DM. (2002). Lumboperitoneal shunting as a treatment for slit ventricle syndrome. *Pediatr Neurosurg*, Vol.36, pp. 178-182.
- Lim, TS., Yong, SW., & Moon, SY. (2009). Repetitive lumbar punctures as treatment for normal pressure hydrocephalus. *Eur Neurol*, Vol.62, pp. 293-297.
- Lipina, R., Palecek, T., Reqli, S., & Kovarova, M. (2007). Death in consequence of late failure of endoscopic third ventriculostomy. *Childs Nerv Syst*, Vol.23, pp. 815-819.
- Martínez-Lage, JF., Martos-Tello, JM., Ros-de-San Pedro, J., & Almagro, MJ. (2008). Severe constipation: an under-appreciated cause of VP shunt malfunction: a case-based update. *Childs Nerv Syst*, Vol.24, pp. 431-435.
- Mayhall, CG., Archer, NH., Lamb, VA., Spadora, AC., Baggett, JW., Ward, JD., & Narayan, RK. (1984). Ventriculostomy-related infections. A prospective epidemiologic study. *N Engl J Med*, Vol.310, pp. 553-559.
- Nadkarni, TD., Menon, RK., Dange, NN., Desai, KI., & Goel, A. (2007). Cranial migration of complete ventriculoperitoneal shunt assembly. *J Clin Neurosci*, Vol.14, pp. 92-94.
- Newton, HB., Rosenblum, MK., & Walker, RW. (1992). Extraneural metastases of infratentorial glioblastoma multiforme to the peritoneal cavity. *Cancer*, Vol.69, pp. 2149-2153.
- Oktem, IS., Akdemir, H., Koç, K., Menkü, A., Tucer, B., Selçuklu, A., & Turan, C. (1998). Migration of abdominal catheter of ventriculoperitoneal shunt into the scrotum. *Acta Neurochir (Wien)*, Vol.140, pp.167-170.
- Patir, R., Mahapatra, AK., & Banerju, AK. (1992). Risk factors in postoperative neurosurgical infection. A prospective study. *Acta Neurochir (Wien)*, Vol.119, pp. 80-84.
- Pattavilakom, A., Xenos, C., Bradfield, O., & Danks, RA. (2007). Reduction in shunt infection using antibiotic impregnated CSF shunt catheters: an Australian prospective study. *J Clin Neurosci*, Vol.14, pp. 526-531.
- Payner, TD., Prenger, E., Berger, TS., & Crone, KR. (1994). Acquired Chiari malformations: incidence, diagnosis, and management. *Neurosurgery*, Vol.34, pp. 429-434.

- Perrin, RG., & Bernstein, M. (2005). Tension pneumoventricle after placement of a ventriculoperitoneal shunt: a novel treatment strategy. Case report. *J Neurosurg*, Vol.102, pp. 386-388.
- Piatt, JH. Jr, & Hoffman, HJ. (1989). Cor pulmonale: a lethal complication of ventriculoatrial CSF diversion. *Childs Nerv Syst*, Vol.5, pp. 29-31.
- Powers, CJ., George, T., & Fuchs, HE. (2006). Constipation as a reversible cause of ventriculoperitoneal shunt failure. Report of two cases. *J Neurosurg*, Vol.105 (3 Suppl), pp. 227-230.
- Rainov, N., Schobess, A., Heidecke, V., & Burkert, W. (1994). Abdominal CSF pseudocysts in patients with ventriculo-peritoneal shunts. Report of fourteen cases and review of the literature. *Acta Neurochir (Wien)*, Vol.127, pp. 73-78.
- Ratilal, B., Costa, J., & Sampaio, C. (2008). Antibiotic prophylaxis for surgical introduction of intracranial ventricular shunts: systematic review. *J Neurosurg Pediatr*, Vol.1, pp. 48-56.
- Rehman, AU., Rehman, TU., Bashir, HH., & Gupta, V. (2010). A simple method to reduce infection of ventriculoperitoneal shunts. *J Neurosurg Pediatr*, Vol.5, pp. 569-572.
- Rickert, CH., Reznik, M., Lenelle, J., & Rinaldi, P. (1998) Shunt-related abdominal metastasis of cerebral teratocarcinoma: report of an unusual case and review of the literature. *Neurosurgery*, Vol.42, pp. 1378-1382.
- Rodrigues, D., Nannapaneni, R., Behari, S., Prasad, M., Herwadkar, A., Gerber, CJ., & Mitchell, P. (2005). Proximal migration of a lumboperitoneal unishunt system. *J Clin Neurosci*, Vol.12, pp. 838-841.
- Rozzelle, CJ., Leonardo, J., & Li, V. (2008). Antimicrobial suture wound closure for cerebrospinal fluid shunt surgery: a prospective, double-blinded, randomized controlled trial. *J Neurosurg Pediatr*, Vol.2, pp. 111-117.
- Sathyanarayana, S., Wylen, EL., Baskaya, MK., & Nanda, A. (2000). Spontaneous bowel perforation after ventriculoperitoneal shunt surgery: case report and a review of 45 cases. *Surg Neurol*, Vol.54, pp. 388-396.
- Satow, T., Motoyama, Y., Yamazoe, N., Isaka, F., Higuchi, K., & Nabeshima, S. (2001). Migration of a lumboperitoneal shunt catheter into the spinal canal-case report. *Neurol Med Chir (Tokyo)*, Vol.41, pp. 97-99.
- Satow, T., Yamada, S., Yagi, M., & Saiki, M. (2010). Superficial siderosis of the central nervous system after ventriculoperitoneal shunt. *J Neurosurg*, Vol. 113, pp. 93-96.
- Schoenbaum, SC., Gardner, P., & Shillito, J. (1975). Infections of cerebrospinal fluid shunts: epidemiology, clinical manifestations, and therapy. *J Infect Dis*, Vol.131, pp. 443-452.
- Schroeder, HW., Warzok, RW., Assaf, JA., & Gaaf, MR. (1999). Fatal subarachnoid hemorrhage after endoscopic third ventriculostomy. Case report. *J Neurosurg*, Vol.90, pp. 153-155.
- Schroeder, HW., Niendorf, WR., & Gaaf, MR. (2002). Complications of endoscopic third ventriculostomy. *J Neurosurg*, Vol.96, pp. 1032-1040.
- Schroeder, HW., Oertel, J., & Gaab, MR. (2007). Endoscopic treatment of cerebrospinal fluid pathway obstructions. *Neurosurgery*, Vol.60(2 Suppl 1), pp. ONS44-51.
- Sciubba, DM., Stuart, RM., McGirt, MJ., Woodworth, GF., Samdani, A., Carson, B., & Jallo, GI. (2005). Effect of antibiotic-impregnated shunt in decreasing the incidence of

- shunt infection in the treatment of hydrocephalus. *J Neurosurg*, Vol.103 (2 Suppl), pp. 131-136.
- Spanu, G., Karussos, G., Adinolfi, D., & Bonfanti, N. (1986). An analysis of cerebrospinal fluid shunt infections in adults. A clinical experience of twelve years. *Acta Neurochir (Wien)*, Vol.80, pp. 79-82.
- Sqaramella, E., Castelli, G., & Sotgiu, S. (2004). Chronic subdural collection after endoscopic third ventriculostomy. *Acta Neurochir (Wien)*, Vol.146, pp. 529-530.
- Starreveld, Y., Poenaru, D., & Ellis, P. (1998). Ventriculoperitoneal shunt knot: a rare cause of bowel obstruction and ischemia. *Can J Surg*, Vol.41, pp. 239-240.
- Steinbok, P., Milner, R., Agrawal, D., Farace, E., Leung, GK., Ng, I., Tomita, T., Wang, E., Wang, N., Wong, GK., & Zhou, LF. (2010). A multicenter multinational registry for assessing ventriculoperitoneal shunt infections for hydrocephalus. *Neurosurgery*, Vol.67, pp.1303-1310.
- Sticker, GB., Shin, MH., Burke, EC., Holley, KE., Miller, RH., & Segar, WE. (1968). Diffuse glomerulonephritis associated with infected ventriculoatrial shunt. *N Engl J Med*, Vol.279, pp. 1077-1082.
- Sørensen, P., Ejlersen, T., Aaen, D., & Poulsen, K. (2008). Bacterial contamination of surgeons gloves during shunt insertion: a pilot study. *Br J Neurosurg*, Vol.22, pp.675-677.
- Toma, AK., Dherijha, M., Kitchen, ND., & Watkins, LD. (2010). Use of lumboperitoneal shunts with the Strata NSC valve: a single-center experience. *J Neurosurg*, Vol.113, pp. 1304-1308.
- Tonn, P., Gilsbach, JM., Kreitschmann-Andermahr, I., Franke, A., & Blindt, R. (2005). A rare but life-threatening complication of ventriculo-atrial shunt. *Acta Neurochir (Wien)*, Vol.147, pp. 1303-1304.
- Tulipan, N., & Cleves, MA. (2006). Effect of an intraoperative double-gloving strategy on the incidence of cerebrospinal fluid shunt infection. *J Neurosurg*, Vol.104 (1 Suppl), pp. 5-8.
- Villarejo, F., Carceller, F., Alvarez, C., Bencosme, J., Pérez Díaz, C., Goldman, L., & Pascual, A. (1998). Pneumocephalus after shunting for hydrocephalus. *Childs Nerv Syst*, Vol.14, pp. 333-337.
- Vinchon, M., Baroncini, M., Laurent, T., & Patrick, D. (2006). Bowel perforation caused by peritoneal shunt catheters: diagnosis and treatment. *Neurosurgery*, Vol.58 (1 Suppl), pp. ONS 76-82.
- Wang, VY., Barbaro, NM., Lawton, MT., Pitts, L., Kunwar, S., Parsa, AT., Gupta, N., & McDermott, MW. (2007). Complications of lumboperitoneal shunts. *Neurosurgery*, Vol.60, pp. 1045-1048.
- Wani, AA., Ramzan, A., & Wani, MA.. (2002). Protrusion of a peritoneal catheter through the umbilicus: an unusual complication of a ventriculoperitoneal shunt. *Pediatr Surg Int*, Vol.18, pp. 171-172.
- Wanzel, KR., Jamieson, CG., & Bohnen, JM.. (2000). Complications on a general surgery service: incidence and reporting. *Can J Surg*, Vol.43, pp. 113-117.
- Woerdeman, PA., & Hanlo, PW. (2006). Ventriculoperitoneal shunt occlusion due to spontaneous intraabdominal knot formation in the catheter. Case report. *J Neurosurg*, Vol.105 (3 Suppl), pp. 231-232.

---

Yoshida, S., Masunaga, S., Hayase, M., & Oda, Y. (2000). Migration of the shunt tube after lumboperitoneal shunt-two case reports. *Neurol Med Chir (Tokyo)*, Vol.40, pp. 594-596.



## **Hydrocephalus**

Edited by Dr Sadip Pant

ISBN 978-953-51-0162-8

Hard cover, 214 pages

**Publisher** InTech

**Published online** 24, February, 2012

**Published in print edition** February, 2012

Description of hydrocephalus can be found in ancient medical literature from Egypt as old as 500 AD. Hydrocephalus is characterized by abnormal accumulation of cerebrospinal fluid (CSF) in the ventricles of the brain. This results in the rise of intracranial pressure inside the skull causing progressive increase in the size of the head, seizure, tunneling of vision, and mental disability. The clinical presentation of hydrocephalus varies with age of onset and chronicity of the underlying disease process. Acute dilatation of the ventricular system manifests with features of raised intracranial pressure while chronic dilatation has a more insidious onset presenting as Adams triad. Treatment is generally surgical by creating various types of cerebral shunts. Role of endoscopic has emerged lately in the management of hydrocephalus.

### **How to reference**

In order to correctly reference this scholarly work, feel free to copy and paste the following:

Takeshi Satow, Masaaki Saiki and Takayuki Kikuchi (2012). Complications Associated with Surgical Treatment of Hydrocephalus, Hydrocephalus, Dr Sadip Pant (Ed.), ISBN: 978-953-51-0162-8, InTech, Available from: <http://www.intechopen.com/books/hydrocephalus/complications-associated-with-surgical-treatment-of-hydrocephalus>

**INTECH**  
open science | open minds

### **InTech Europe**

University Campus STeP Ri  
Slavka Krautzeka 83/A  
51000 Rijeka, Croatia  
Phone: +385 (51) 770 447  
Fax: +385 (51) 686 166  
[www.intechopen.com](http://www.intechopen.com)

### **InTech China**

Unit 405, Office Block, Hotel Equatorial Shanghai  
No.65, Yan An Road (West), Shanghai, 200040, China  
中国上海市延安西路65号上海国际贵都大饭店办公楼405单元  
Phone: +86-21-62489820  
Fax: +86-21-62489821

© 2012 The Author(s). Licensee IntechOpen. This is an open access article distributed under the terms of the [Creative Commons Attribution 3.0 License](#), which permits unrestricted use, distribution, and reproduction in any medium, provided the original work is properly cited.