

HCV-Recurrence After Liver Transplantation

Dennis Eurich, Marcus Bahra and Peter Neuhaus
*Charité Campus Virchow / General, Visceral and Transplant Surgery / Berlin,
Germany*

1. Introduction

Hepatitis-C-virus (HCV) represents one of the most serious threats for human liver and chronic HCV-infection results in the development of liver cirrhosis and hepatocellular carcinoma (HCC). HCV is an enveloped RNA-virus belonging to the flaviviridae family. Currently six identified HCV-genotypes, different in their geographic distribution define the severity of pathogenic effect, disease course and treatment results. About 1.5% of the European population are HCV-positive. Although the natural history of HCV-infection is rather slow, highly variable disease progression may lead to a rapid loss of liver function [1, 2]. An estimated annual incidence of new infections (3-4 millions) explains 170 million HCV-positive people worldwide. 80% of all HCV-infections become chronic and fewer than 25% of HCV-positive individuals are clinically apparent presenting either in a clinically stable state with few only symptoms or with fully decompensated liver disease with a dire prognosis [1, 3, 4]. Once chronic HCV-infection is established, the rates of spontaneous viral clearance remain discouraging.

The development of liver fibrosis is the main determinant of morbidity and mortality of HCV-positive patients [1]. Fibrosis results from excessive formation of extracellular matrix (ECM). The established imbalance of fibrogenesis and fibrolysis during chronic liver damage, which leads to scarring of the liver, is accompanied by a progressive loss of liver function despite the use of antiviral or anti-inflammatory agents [1, 5]. HCV-re-infection can trigger the excess synthesis and deposition of ECM usually by activation of cytokine release [1, 5]. Activated macrophages, lymphocytes, bile duct epithelia but also endothelia and myofibroblasts are sources of fibrogenic cytokines and growth factors that can stimulate hepatic stellate cells HSCs to produce ECM-molecules leading to fibrosis during chronic liver injury [1, 5]. The most prominent fibrogenic cytokine seems to be the transforming growth factor- β 1 (TGF- β 1), which is released during inflammation, tissue regeneration and fibrogenesis. TGF- β 1 is considered to play a pivotal role in the hepatic fibrogenesis strongly increasing the production and deposition of ECM-components [1, 6]. Fibrosis progression is influenced by a whole range of virus, host and environmental factors. Advanced age, male gender, race (black), viral co-infection (HBV), alcohol intake and genetic background seem to influence the course of the disease [7-10]. For patients with HCV-induced end-stage liver disease (ESLD) liver transplantation (LT) remains the treatment of choice according to functional (cirrhosis CHILD B-C) or neoplastic (HCC) severity of hepatic injury [11]. 30-50% of all LTs are performed due to HCV-associated ESLD thus representing one of the leading LT-indications.

Regarding the recurrence of pre-transplant diseases after LT, HCV-re-infection may represent one of the most important threats to graft and patient survival after primarily successful transplantation. Although remarkable differences in the course of HCV-infection exist between pre- and post-transplant settings, the uniform picture of liver or graft cirrhosis is similar and comparable to a certain extent.

2. HCV-recurrence after liver transplantation

HCV-recurrence after LT is one of the most important issues regarding the spectrum of current graft diseases. Despite comparable pathophysiological processes, the course of graft hepatitis is usually more progressive compared to the natural setting of HCV-infection [11-15].

2.1 Epidemiological and etiological aspects

Most of the patients either show biochemical or histological signs of inflammation, whereas 30% of all graft recipients develop graft cirrhosis within 5 years after LT, leading to an impaired patient survival and a dubious transplant success. Progressive loss of graft function may even require re-transplantation despite of consistent antiviral treatment [16].

Arbitrary in use and manifold in extent, the term “HCV-recurrence” implies the whole spectrum of graft disease such as asymptomatic infection, graft-hepatitis, fibrosis and eventually transplant cirrhosis. The uniform picture of end stage graft disease comprises scar formation and replacement of liver parenchyma by connective tissue as a result of accelerated fibrogenesis [1, 17, 18]. Clinical presentation of graft function loss is very similar to the natural setting though more rapid and progressive. Ascites, variceal bleeding, encephalopathy and jaundice are common results of graft decompensation.

Patient survival with HCV-recurrence is dramatically compromised compared to non-HCV-related transplants [15]. Several studies pointed out significantly lower survival rates in HCV-positive recipients due to accelerated fibrosis development. Survival analysis performed in a cohort of 2294 patients (Charité, Berlin, Germany since 1988) demonstrated highly significant differences (unpublished data) comparing 455 HCV-positive to 1839 HCV-unrelated transplants ($p < 0.001$; fig.1).

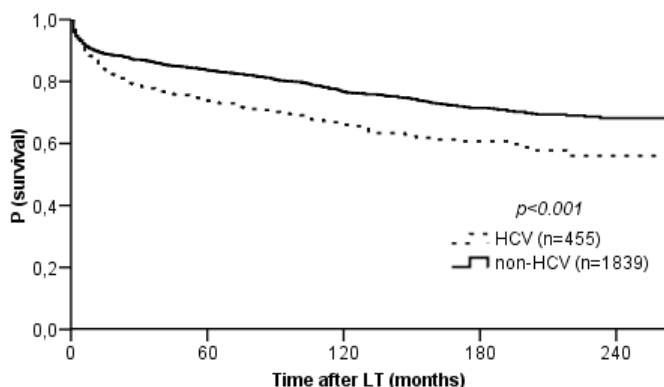


Fig. 1. Disease-related post-transplant survival

Persisting in the extrahepatic reservoir, HCV reappears as a universal post-transplant phenomenon, leading to the development of graft disease in a highly variable manner. At the moment of hepatectomy HCV-load may become even undetectable indicating the importance of the liver as major HCV-reservoir. After transplantation, HCV-redistribution arises from extrahepatic sources (lymphatic tissue) and HCV-viremia reappears within first post-transplant days [19, 20]. Molecular analysis has shown that postoperative viral strains are identical to those detected before transplantation. HCV-load literally explodes after one week achieving values of one logarithmic step higher compared to pre-transplant condition basically due to indispensable immunosuppressive medication [21]. Among currently known genetic HCV-variants (1-5), genotype-1b predominates in the post-transplant setting due to selection as the most stubborn [22].

2.2 Diagnostics

HCV-recurrence, ranging from asymptomatic viremia to rapid fibrosis progression requires an exact description and diagnostic assessment of injury extent. Clinical presentation of HCV-recurrence is frequently unspectacular, basically corresponding to HCV-infection in the natural setting. Though highly variable and unreliable, general discomfort and fatigues may appear as first symptoms of HCV-recurrence. In contrast, advanced stages may clinically result in jaundice, hemorrhage, edema, ascites, encephalopathy, infection, secondary organ failure according to the degree of functional deterioration. Therefore, standardized quantification of graft damage and disease extent must be performed, in order to identify high-risk-patients, initiate antiviral treatment and monitor further development.

2.2.1 Clinical and biochemical aspects

After successful LT, graft function is usually followed-up according to local protocols. Clinical presentation after LT is usually unremarkable unless advanced graft disease has already developed and symptoms of liver insufficiency become apparent [21]. Elevated aminotransferases (2-4-fold) are frequently observed along with normal parameters of synthesis and excretion as a biochemical expression of inflammatory activity in parenchyma. Severe HCV-recurrence may lead to variably impaired detoxification and synthesis similar to the natural course of HCV-associated liver disease [16]. However, the differentiation of HCV-associated graft hepatitis from acute cellular rejection (ACR) is frequently impossible, based on laboratory data, only. Taken a sufficient level of immunosuppression and a detectable HCV-load, HCV-recurrence seems to be probable after the exclusion of immunological, metabolic, vascular and biliary causes for biochemical abnormalities. Therefore, graft biopsy must urgently be performed as diagnostic gold standard [21].

2.2.2 Histology

As a very reliable method, histological analysis of graft tissue usually helps to determine the etiology of graft malfunction especially in combination with supportive results of other paraclinical examinations such as laboratory analysis, cholangiography and Doppler-sonography. The histological picture of HCV-re-infection usually implies a mild sinusoidal infiltration by lymphocytes and mononuclear cells resulting in a variable degree of portal

inflammation. HCV-associated inflammation may trigger an excessive synthesis of ECM-components and result in the accumulation of collagens.

The imbalance between synthesis and degradation of connective tissue defines the progression of fibrosis [1]. Once the diagnosis of HCV-related graft hepatitis is made, the indication to antiviral treatment should be evaluated in order to prevent aggravation. The development of fibrosis is not linear [21, 23]. Since the accumulation of connective tissue and pathologic alteration of histological structure are definitive endpoints of HCV- recurrence, serial biopsies and long-term follow-up are highly indispensable for the assessment of HCV-related damage (fig. 2) [21, 24, 25].

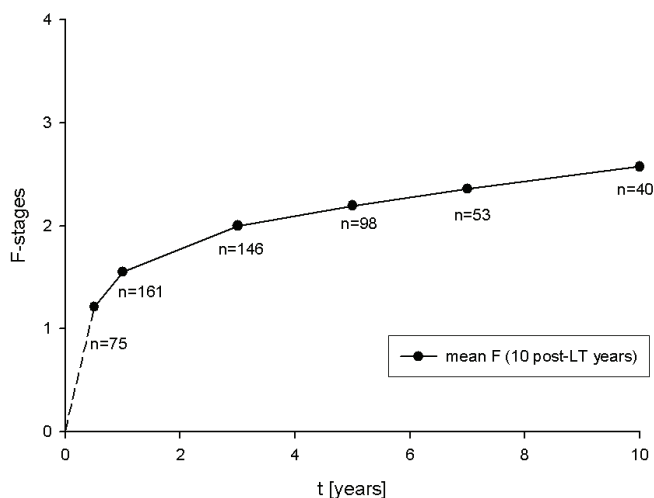


Fig. 2. Post-transplant dynamics of fibrosis

Along with several available and currently accepted scores, hepatic fibrosis is frequently characterized by a semiquantitative score, proposed by Scheuer & Desmet [26]. Using a scale (0-4), fibrosis is staged as ordinal data values (0: absent, 1: mild without septa, 2: moderate with few septa, 3: numerous septa without cirrhosis and 4: cirrhosis). Although no arithmetic procedures can be performed with ordinal data, Desmet and Scheuer-score appears to be superior in reproducibility over other semiquantitative systems in fibrosis assessment [27]. In a recent analysis according to Desmet and Scheuer, accepted time-related rates of graft cirrhosis development (30% after 5 and 50% after 10 years) could be confirmed in a representative cohort of more than 400 transplants with HCV-recurrence (Charité, Berlin, Germany). Advanced fibrosis stages (3-4) were observed in 39.2% after 5 and 47.5% after 10 post-transplant years, respectively, emphasizing the importance of a universal term definition (fig. 3).

Apart from fibrosis quantification, microscopic evaluation of inflammatory pattern helps to differentiate severe cellular rejection from HCV-infection in spite of significant biochemical similarities [28]. Low levels of immunosuppression may induce an ACR-event. Due to frequently simultaneous occurrence of acute cellular rejection and HCV-re-infection in the early post-operative period, these entities tend to be easily misdiagnosed. Classified according

to Banff-criteria, ACR may present microscopically as an accumulation of mononuclear cells (lymphocytes, eosinophil and neutrophil granulocytes) including endothelitis, portal, centrolubular inflammation and biliary alterations [28].

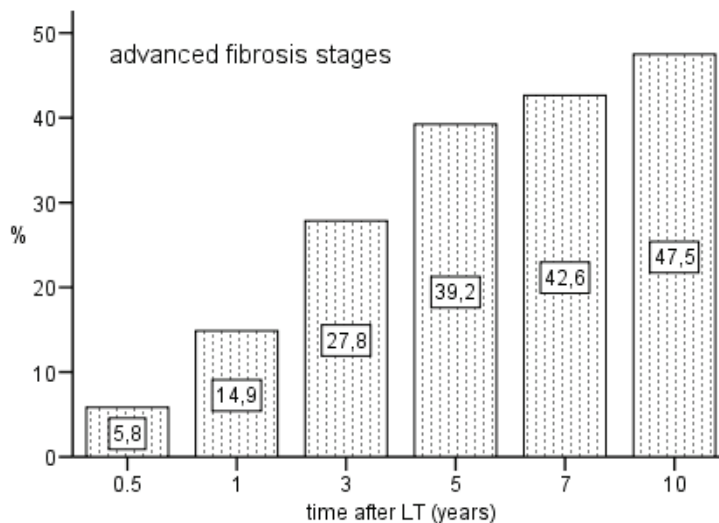


Fig. 3. Progression to advanced fibrosis stages

Currently ACR is treated by the application of intravenous steroid pulses for 3-5 days. In few cases, mono- or polyclonal antibodies are administered in case of steroid resistant rejection [21]. HCV-exacerbation is widely accepted as an inevitable side effect of ACR-treatment due to limited alternatives. Morphologically, mild forms of ACR hardly differ from HCV-re-infection due to principal differences in the pathogenesis. Regarding the danger of steroid-associated HCV-exacerbation, steroid-based treatment is recommended in moderate and severe degrees of ACR in HCV-positive transplants according to current standards. In contrast, mild ACR should be treated by the administration of higher calcineurin inhibitor doses (CNIs) and MMF-complementation as dual immunosuppressive medication. Therefore, the diagnosis must be based on the histological analysis of graft biopsy as most reliable method [21, 27].

3. Risk factors

The progression of HCV-associated graft disease is influenced by a whole range of virus, donor, recipient and environmental factors. The variety of relevant confounders exhibiting variable impact, their interaction in genetically unique living individuals resulting from a successful LT have been in the center of attention for many decades. Some risk factors for the development of graft fibrosis have been identified during the scientific attempt to unravel the mystery and to understand the substance of HCV-recurrence in detail [21, 29]. However, the majority of observations were based on low sample size. Nevertheless, the existence of virological, immunological, surgery-related and even historical confounders illustrates the complexity and variability of the issue (table 1).

Variables		
donor and surgery	age	>50 years
	warm and cold ischemia	long ischemia
	organ quality	steatosis, iron concentration
	genetics	IL28B
host	age	older age
	gender	male
	race	black
	genetics	IL28B, TGF- β 1
immunology	blood group	mismatch
	histocompatibility	mismatch
	immunosuppression	type, high levels
	ACR-episodes	ACR-occurrence
	ACR-treatment	corticosteroids, OKT-3
	co-infection	CMV
HCV-related	genotype	Ib
	viremia level	early peak
antiviral treatment	non-response	pre- and post-transplant

Table 1. Variables related to the severity of HCV-recurrence

3.1 Donor- and surgery-related factors

Liver graft has been quickly suspected to affect HCV-recurrence as a dominant location of pathologic events. Several studies detected a negative effect on HCV-recurrence regarding donor age, organ quality, histocompatibility matching, steatosis and iron concentration [30, 31]. Furthermore, transplant-related factors such as duration of organ harvesting, warm and cold ischemia time (transport and implantation) have been shown to contribute to HCV-related post-transplant events and processes [21]. Genetic variance of growth factors and cytokines in donor is currently suspected to impact on the progression and treatment of HCV-associated graft disease [32, 33].

3.2 Host-related factors

The development of fibrosis seems to be twice as fast in males compared to female recipients. In contrast to the controversially discussed role of recipient age, black race and male gender have been shown to negatively affect fibrosis progression [22]. Cytokines and growth factors are final effectors in the pathogenesis and may theoretically play a key role in fibrogenesis [1, 34]. Analogously to donor, genetic polymorphisms of recipient cytokines are being currently intensively investigated and seem so far to modulate the course of HCV-recurrence and antiviral treatment success. This issue will be presented below.

3.3 Viral factors

The impact of viral properties on the course of HCV-associated graft disease has been assessed by several studies, obtaining partially controversial results. Progression of graft hepatitis-C seems to be accelerated in patients with HCV-genotype-1b, high pre-transplant HCV-RNA-load and early post-transplant peak of viremia [29, 35-37]. Interestingly, HCV-core protein has been demonstrated to promote inflammation by the release of oxidative stress and to reinforce apoptosis and steatosis. During inflammation, activated hepatic stellate cells generate ECM-components and determine the rate of graft fibrosis progression. Furthermore, CMV-coinfection seems to reinforce fibrosis progression [25, 36].

3.4 Immunologic factors

Along with histocompatibility mismatch, mode of immunosuppression, the occurrence of acute cellular rejection and its treatment have been identified as dominant confounders of HCV-related graft disease [21, 22].

3.4.1 Immunosuppressive medication

Highly complicated interaction and vulnerable balance in the immune answer to HCV is compromised by the inevitable use of immunosuppressive medication. The inappropriate T-cell mediated response to HCV-re-infection is accused to be responsible for disease progression. Stronger immunosuppressive regimen may accelerate fibrosis progression [38, 39]. Calcineurin-inhibitors (cyclosporine and tacrolimus) represent the backbone of current immunosuppressive medication and have been suspected to influence the extent of HCV-recurrence. In spite of similar pharmacological mechanisms, cyclosporine has been proposed to have a positive effect on interferon-based antiviral treatment. However, clinical significance currently remains unclear [40]. Levels of HCV-viremia seem to be the CNI-type [41].

Mycophenolate mofetil (MMF) inhibits the lymphocyte proliferation and may decrease the overall inflammatory activity in the graft. MMF was strongly suspected to have a positive impact on fibrogenesis [42]. However, the theoretically promising antiviral effect of MMF in-vitro could not be demonstrated as substantial, regarding fibrosis development. Nevertheless, dual immunosuppression based on CNIs and MMF is frequently used in patients with HCV-recurrence and is believed to exhibit a positive effect on the severity of HCV-recurrence [42].

Sirolimus as a representative of mTOR-inhibitors seems to decelerate fibrosis progression in graft re-infection by blocking post-receptor signal transduction and interleukin-2-dependant proliferation. Although, no definite statement can currently be made, sirolimus may represent a reasonable therapeutic option [43, 44].

3.4.2 Acute cellular rejection

The occurrence of acute cellular rejection (ACR), its severity and frequency have been reported to aggravate the course of HCV-related graft disease [16]. Administration of corticosteroid pulses and antibodies (OKT-3) in case of steroid-resistant rejection as ACR-therapy are associated with a significant elevation of viral load and accelerated fibrosis

development [21, 22]. The extent of immunosuppression, CNI-type and previous episodes of rejection are widely considered to affect the incidence of ACR. Furthermore, individually different genetic background of ACR-mediating cytokines might be involved in the pathogenesis [45]. Furthermore, individually different genetic background of ACR-mediating cytokines might be involved in the pathogenesis [45]. Mannose-binding-lectin-2 (MBL-2) plays an important role in the innate immune system acting as opsonine by activation antibody-independent pathway of the complement system [46, 47]. Polymorphisms of MBL-2-gene (rs7096206; G/C) have been shown to affect the occurrence of ACR in a homogenous cohort of HCV-re-infected patients (Eurich et al).

3.5 Antiviral therapy

Antiviral therapy is the cornerstone of graft cirrhosis prevention in HCV-infected recipients. The clinical and histological course of hepatitis-C is inseparably associated with antiviral treatment strategies. Recent introduction of new formulations of interferons (IFN) such as pegylated interferons (PEG-IFN) in the treatment of HCV-infection before and after LT revealed promising results. Application of pegylated interferon (α -2a and ribavirin (RBV) provide a sustained virologic response (SVR) in 40-50% of all treated cases with HCV-genotype 1 and in 80% with genotypes 2 or 3. In post-transplant setting, the success of antiviral therapy is significantly lower, and only a maximum of 30-40% of all patients achieve SVR [21, 39]. Some evidence exists that IFN/RBV-treatment may prevent graft cirrhosis even in unsuccessfully treated patients. Interestingly, fibrosis progression may occur in spite of successful IFN-based antiviral treatment [48]. Hence, this issue remains controversial. Moreover, immunologically active IFN may trigger rejection (5-6%) and induce chronic rejection processes during the antiviral treatment [12, 49].

3.6 Genetic diversity

HCV-re-infection can trigger the excess synthesis and deposition of ECM usually by activation of cytokine release. Activated macrophages, lymphocytes, bile duct epithelia but also endothelia and myofibroblasts are sources of fibrogenic cytokines and growth factors that can stimulate hepatic stellate cells HSCs to produce ECM-molecules leading to fibrosis during chronic liver injury [50, 51]. Genetic polymorphisms of enzymatic systems, cytokines and growth factors which are involved in the process of immunomodulation, inflammation, ECM-turnover and anti-oxidative stress defense, may explain the widely different individual extent of HCV-induced graft damage [52-54]. Highly variable rates of functional impairment defined by inflammation, tissue remodeling but also antiviral capabilities and antiviral therapy response suggest the existence of endogenous risk compounds both in natural and post-transplant settings of the disease [33]. The maximal capacity to produce different levels of cytokines in response to noxious stimulation has been shown to be under genetic control and differs among liver graft recipients [32, 55]. Genetically different backgrounds in transplant population, consisting of donor and recipient, may differently contribute to disease development. Although the exact mechanism is not yet understood in detail both, donor and recipient genetics may interact. The expression of disease-related effectors may be individual, time and tissue dependant [56]. Therefore, the interaction between two different individual backgrounds may theoretically influence post-transplant processes in the graft and be therefore pathogenetically relevant [57].

3.6.1 Genetic variants in donor

The ability to produce different levels of cytokines in response to stimulation is suspected to be gene-associated [58]. Liver graft is usually colonized by recipient cell populations such as endothelia and lymphatic tissue thus theoretically forming a functional chimerism of donor and recipient regarding biochemical processes [56, 59]. Furthermore, the impact of genetic differences in donor and recipient may vary according to the duration of post-transplant follow-up [57]. Results of intensive investigations demonstrated that donor polymorphisms of IL-28B-gene may partially predict the outcome of antiviral treatment [60].

3.6.2 Genetic variants in recipient

Genetic polymorphisms of enzymatic systems, cytokines and growth factors which are involved in the process of immunomodulation, inflammation, ECM-turnover and anti-oxidative stress defense may explain the widely different individual extent of HCV-induced graft damage [61].

3.6.2.1 Transforming growth factor- β 1 (TGF- β 1)

As a multifunctional polypeptide with fibrogenic, an anti-inflammatory and anti-proliferative property, TGF- β 1 is considered to play a pivotal role in the hepatic fibrogenesis strongly upregulating the production and deposition of ECM-components [10, 17, 62]. Similarly to the natural setting of HCV-infection, functionally relevant polymorphisms of TGF- β 1 at codon 25 are associated with the rapid development of HCV-induced graft fibrosis.

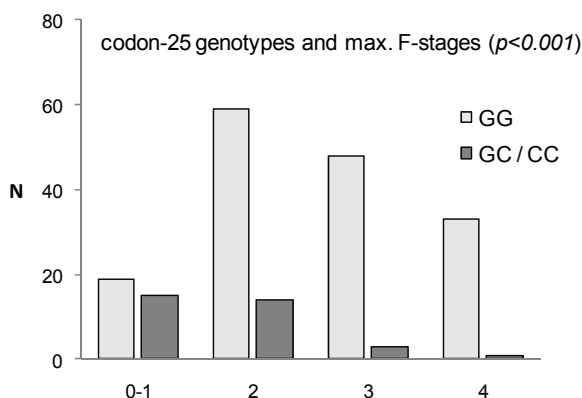


Fig. 4. Genotype distribution (TGF- β 1) within maximal fibrosis stages

C-allele of the TGF- β 1-gene (codon 25) has been identified as marker for graft fibrosis development and was observed significantly less frequently in advanced fibrosis stages compared to lower ones (fig. 4; $p=0.001$) [63].

3.6.2.2 Interleukine-28B (IL-28B)

According to numerous studies, genetic variants of IL-28B seem to be significantly involved in the pathogenesis of HCV-related graft inflammation and antiviral therapy response [60,

64, 65]. IL-28B-gene encodes an antiviral protein - IFN- λ with antiviral properties in response to IFN- α , and is upregulated by peripheral blood mononuclear cells and hepatocytes during HCV-infection [40, 66-68]. Recently, a significant association of IL-28B-genotype distribution was observed with the median grade of inflammation ($p < 0.001$), mean levels of aminotransferases (ALT: $p = 0.001$, AST: $p = 0.003$; fig.5), median pre-treatment viremia level within 1 year after LT ($p = 0.046$) and interferon-based antiviral therapy failure ($p < 0.001$). IL-28B polymorphism (rs8099917) seems to influence the degree of graft inflammation at biochemical and histological levels [64].

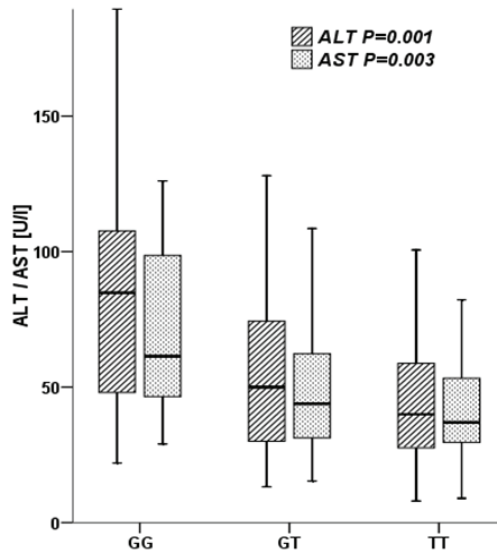


Fig. 5. Levels of aminotransferases according to IL-28B-genotypes

Among successfully treated patients G-allele was significantly less frequent and GG-genotype was not present at all [64]. G-allele might serve as a marker for graft inflammation and as predictor for unfavorable antiviral therapy outcome in HCV-re-infected LT-population [60, 64].

The identification of non-invasive inflammation and fibrosis markers might help to differentiate re-infected patients with stable graft function without significant inflammation or fibrosis progression from patients at risk for short-term graft damage and define the indication for antiviral treatment.

3.7 Organ allocation system

Methodological changes in the principals of graft allocation may affect the course of HCV-associated graft disease. Since December 2006 liver graft allocation has been carried out according to MELD-score, which primarily assesses the impairment of liver function and secondarily reflects the extent of kidney damage. Some evidence arises about the negative impact of the current allocation system regarding survival, rate of re-transplantation, fibrosis progression and success of antiviral treatment. Therefore, the MELD-score, as an

apparently reasonable attempt to improve the procedure of organ distribution, must undergo a critical analysis in future.

4. Antiviral therapy

The indication for HCV-treatment after LT depends on the individual clinical and biochemical condition after a definitive stabilization of the graft function, which is usually achieved within six post-operative months [69]. Analogously to the natural setting, therapy regimen is based on the administration of pegylated interferon- α 2a (Peg-IFN- α 2a) and ribavirin (RBV) for 12-18 months. Interferons are natural proteins with antiviral, antiproliferative and immunomodulatory features. They are responsible for the intracellular RNA-degradation and the inhibition of RNA-translation. Among all known interferons (IFN- α , IFN- β , Peg-IFN- α 2b), pegylated IFN- α 2a seems to have the highest antiviral potency, though similar to Peg-IFN- α 2b, demonstrating superior treatment results in patients with HCV-re-infection [19, 70-75]. Attenuation of renal clearance and improved biochemical stability may explain prolonged half-time and therapeutical advantages observed. Ribavirin inhibits inosinmonophosphate-dehydrogenase and reduces the intracellular concentration of guanosin. RBV-monotherapy may significantly decrease the HCV-load (1 log step).

For a better comparability of results, the treatment outcome has been divided into widely accepted terms: end of treatment response (ETR: HCV-negativity at the end of treatment), sustained virologic response (SVR: HCV-RNA-negativity 6 months after therapy completion), relapse (detectable HCV-RNA after therapy completion), breakthrough (detectable HCV-RNA during treatment after initial therapy response) and non-response (persistent HCV-load under treatment). SVR before transplantation is observed in 50% of all treated cases with HCV-genotype-1 and in 80% with genotypes 2-3 [74]. As long as IFN- α remains the backbone of antiviral therapy, the identification of predictors for the therapy outcome is crucial. 50% of graft recipients survive 10 years without any significant fibrosis progression and in some cases even without antiviral treatment (own data, Charité, Berlin, Berlin). Therefore, unnecessary exposition to adverse therapy events in non-responders could be avoided by improved predictability. HCV-genotype and early viral kinetics are predominantly considered to be important for therapy performance and its potential modification [69, 76]. Apart from the identified factors (high levels of immunosuppression, corticosteroid-based ACR-treatment and HCV-genotype-1b), unfavorable host- and donor-related genetic confounders are suspected to exert a negative influence on the course and success of antiviral treatment [22, 69, 77]. According to several studies, genetic variants of IL-28B are strongly considered to affect the antiviral therapy results [64, 78, 79]. Along with other accepted predictive parameters, IL-28B-genotyping may be a useful diagnostic instrument for the indication and performance of antiviral therapy before and after LT [52, 60, 78, 80].

4.1 Current treatment standards

The aim of antiviral treatment implies the reduction or complete HCV-clearance as responsible noxious agent in the development of HCV-associated graft disease. In spite of low success rates, HCV-infection is treated by subcutaneous administration of 180 μ g of Peg-IFN- α 2a once a week and oral intake of RBV up to three times per day [22, 35, 81]. The cumulative duration of antiviral treatment comprises 12-18 months.

The major advantage of peg-interferon $\alpha 2a$ and ribavirin-therapy consists in the summation of the antiviral potency. However, bone marrow toxicity, psychiatric disorders and rejection frequently limit therapy success. Due to high rates of predominantly hematological adverse events (anemia, leucopenia) and a significant risk of graft decompensation, antiviral treatment should be performed under a close patient monitoring. Myelotoxic effect of IFN results in the suppression of granulocytes and thrombocytes, whereas RBV induces anemia [77, 82]. Therapeutical support of hematological and mental disorders may frequently be necessary. Frequently observed anemia may result in the reduction of the RBV-dose or in the administration of erythropoietin. Leucopenia may require a dose reduction of IFN or administration of granulocyte stimulating growth factors. Mood disorders may be handled by antidepressants or social support. While performing a strenuous, expensive and frequently futile effort of virus elimination, 60-70% of transplants with HCV-graft hepatitis are treated without sustained virologic response [72].

4.2 Alternative strategies

Demonstrating poor treatment results and serious adverse events of IFN-based therapy, reasonable alternative treatment options are needed to complement or to replace the standard therapeutical approach. Silibinin experiences its renaissance in the treatment of chronic liver diseases although it has been known for years as hepatoprotective herbal and used by patients suffering from chronic liver disease of various causes [83-85]. In contrast to unclear antiviral efficacy of oral silibinin treatment, according to the results of published studies, a significant antiviral effect could be observed after intravenous administration of silibinin [84, 86-90]. Next to three other flavonolignan isomers (isosilybin, silydianin and silychristin) silibinin is the most pharmacologically active component of *Silybum marianum* and has been shown to improve biochemical markers of liver function and symptoms in a range of conditions including acute and chronic viral hepatitis, alcoholic liver disease and drug-related liver injury [83, 91-94]. As a potent free radical scavenger, silibinin has been shown to reduce the initiation of pathogenetically important lipid peroxidation and to lower HCV-RNA-load [92, 95, 96]. The substance exerts a direct antiviral effect on the HCV-replicon system inhibiting RNA-dependant HCV-polymerase. Furthermore, silibinin has been shown to affect the major actors in scar tissue formation suppressing TGF- $\beta 1$ -synthesis and HSC-activity [92, 97, 98].

The evidence of antiviral efficacy of silibinin in patients with HCV-related liver damage is limited due to a paucity of representative clinical trials, in spite of its popularity among patients suffering from various chronic liver diseases [92, 99]. Recent reports have demonstrated significant antiviral properties of intravenously administered silibinin in IFN-non-responders in the natural setting of HCV-infection, convincingly suggesting a dose- and treatment duration-dependent antiviral effect [92]. Several observations based on unfortunately low sample size cohorts, demonstrated that intravenous administration of silibinin after LT may be an effective therapeutic approach in the treatment of HCV-reinfection, even in non-responders to IFN-based therapy [99, 100]. Rapid normalization of aminotransferases and an exponential decline of HCV-load during silibinin treatment have been reported (fig. 6) [100]. Moreover, sustained viral elimination may apparently occur even after treatment with silibinin, only. Interestingly, in patients treated directly after LT, no significant antiviral effect could be observed, probably due to initially high levels of

immunosuppression (unpublished data, Charité, Berlin). Although no large scale studies have been carried out yet, silibinin might be an effective therapeutic approach in the treatment of HCV-re-infection and should be evaluated further. Any kind of antiviral supplementation to current therapy regimen should be welcome in the age of donor organ shortage to strengthen current antiviral therapy regimen and to avoid graft loss with subsequent re-transplantation.

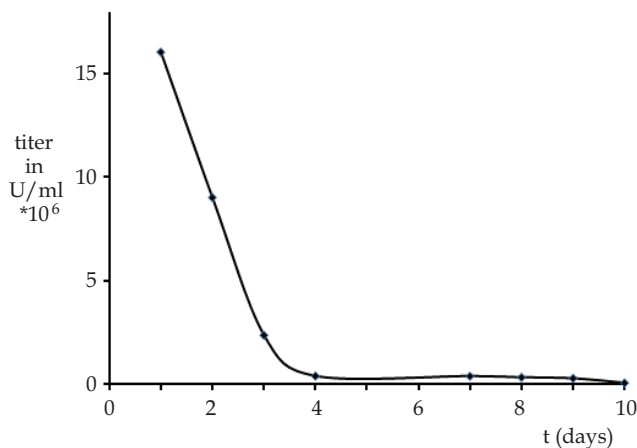


Fig. 6. HCV-load during silibinin treatment after LT

Randomized, placebo-controlled clinical trials with a representative number of graft recipients suffering from HCV-re-infection are needed to definitely answer the question of the efficacy of intravenous silybium marianum solution and its antiviral potential. As long as IFN- α remains the backbone of antiviral therapy, the identification of predictors for therapy outcome is crucial. Regarding potential therapy success, frequent severe adverse events of IFN-RBV-therapy are commonly accepted. An unnecessary exposition to adverse therapy events in non-responders could thus be avoided by an improved predictability.

4.3 Re-transplantation

Re-transplantation is frequently required (up to 10%) in patients with HCV-related graft cirrhosis as the only option of treatment [12, 15]. Significantly decreased survival rates after re-transplantation compared to first LT are in the center of scientific attention and long-term outcome has been reported to be inferior to other indications [3, 11, 39]. Physical condition, MELD-score, technical obstacles and antiviral therapy response are currently accepted as predictors for graft and patient survival after re-LT [39, 101].

5. Summary and future prospective

As long as HCV-recurrence exists as currently inevitable phenomenon, HCV will continue to endanger the success of LT. While performing a strenuous, expensive and frequently futile effort of interferon-based virus elimination, 60-70% of graft recipients are still treated without achieving SVR, thus leaving overall poor results. The natural course of HCV-

recurrence is not uniform and is influenced by a whole variety of factors. Therefore, the identification of non-invasive inflammation and fibrosis markers might help to differentiate re-infected patients with stable graft function without significant inflammation or fibrosis progression from patients at risk for short-term graft damage and define the indication for antiviral treatment. Moreover, it is indispensable to identify patients who are likely to respond to IFN-based antiviral treatment. The individual variability of disease development may be divided roughly into three different patient groups (A: no fibrosis progression, B: treatable progression and C: untreatable progression of graft dysfunction). The indication for antiviral therapy in group B seems to be more urgent in contrast to group A, which may stay stable for several years regarding their graft function, thus avoiding possibly unnecessary exposition to pharmaceutical side effects. Group-C- patients, as high risk patients may require treatment adjustment regarding its intensity, duration and mode including alternative therapeutical strategies.

Although HCV-recurrence represents an inevitable post-transplant phenomenon, the development of advanced fibrosis stages is highly variable or even individual. Furthermore, the outcome of antiviral treatment seems to depend on multiple factors, too. In spite of recent advances in HCV-graft-hepatitis treatment, prediction of therapy response and risk stratification in graft fibrosis progression, a further extensive investigation is still required. Improvement in prevention, prediction of disease course, individualized antiviral treatment and alternative antiviral medication may help to increase survival rates after LT for an HCV-associated graft disease.

6. References

- [1] Schuppan D, Krebs A, Bauer M *et al.* Hepatitis C and liver fibrosis. *Cell Death Differ* 2003 Jan;10 Suppl 1:S59-67.
- [2] Rossol S. [Chronic HCV infections. A model disease for therapy, economics and social medical aspects]. *Gesundheitswesen* 2007 Mar;69(3):146-150.
- [3] Burra P. Hepatitis C. *Semin Liver Dis* 2009 Feb;29(1):53-65.
- [4] Thomas DL, Astemborski J, Rai RM *et al.* The natural history of hepatitis C virusinfection: host, viral, and environmental factors. *JAMA* 2000 Jul 26;284(4):450-456.
- [5] Friedman SL. Mechanisms of disease: Mechanisms of hepatic fibrosis and therapeutic implications. *Nat Clin Pract Gastroenterol Hepatol* 2004 Dec;1(2):98-105.
- [6] Friedman SL. Molecular regulation of hepatic fibrosis, an integrated cellular response to tissue injury. *J Biol Chem* 2000 Jan 28;275(4):2247-2250.
- [7] Svrtlih N, Jevtovic D, Simonovic J *et al.* Older age at the time of liver biopsy is the important risk factor for advanced fibrosis in patients with chronic hepatitis C. *Hepatogastroenterology* 2007 Dec;54(80):2324-2327.
- [8] Sterling RK, Stravitz RT, Luketic VA *et al.* A comparison of the spectrum of chronic hepatitis C virus between Caucasians and African Americans. *Clin Gastroenterol Hepatol* 2004 Jun;2(6):469-473.
- [9] Gitto S, Micco L, Conti F *et al.* Alcohol and viral hepatitis: a mini-review. *Dig Liver Dis* 2009 Jan;41(1):67-70.
- [10] Powell EE, Edwards-Smith CJ, Hay JL *et al.* Host genetic factors influence disease progression in chronic hepatitis C. *Hepatology* 2000 Apr;31(4):828-833.

- [11] Neumann UP, Berg T, Bahra M *et al.* Long-term outcome of liver transplants for chronic hepatitis C: a 10-year follow-up. *Transplantation* 2004 Jan 27;77(2):226-231.
- [12] Berenguer M. Recurrent allograft disease: viral hepatitis. *Acta Gastroenterol Belg* 2005 Jul-Sep;68(3):337-346.
- [13] Berenguer M, Prieto M, Palau A *et al.* Severe recurrent hepatitis C after liver retransplantation for hepatitis C virus-related graft cirrhosis. *Liver Transpl* 2003 Mar;9(3):228-235.
- [14] Prieto M, Berenguer M, Rimola A *et al.* Liver transplantation in hepatitis C. A Spanish multi-centre experience. *Eur J Gastroenterol Hepatol* 1998 Sep;10(9):771-776.
- [15] Forman LM, Lewis JD, Berlin JA *et al.* The association between hepatitis C infection and survival after orthotopic liver transplantation. *Gastroenterology* 2002 Apr;122(4):889-896.
- [16] Berenguer M. Natural history of recurrent hepatitis C. *Liver Transpl* 2002 Oct;8(10 Suppl 1):S14-18.
- [17] Friedman SL. Stellate cells: a moving target in hepatic fibrogenesis. *Hepatology* 2004 Nov;40(5):1041-1043.
- [18] Friedman SL. Molecular mechanisms of hepatic fibrosis and principles of therapy. *J Gastroenterol* 1997 Jun;32(3):424-430.
- [19] Neumann UP, Neuhaus P. Course and treatment of recurrent Hepatitis C after liver transplantation. *Minerva Gastroenterol Dietol* 2004 Mar;50(1):61-66.
- [20] Garcia-Retortillo M, Fornis X, Feliu A *et al.* Hepatitis C virus kinetics during and immediately after liver transplantation. *Hepatology* 2002 Mar;35(3):680-687.
- [21] Neumann UP, Berg T, Bahra M *et al.* Fibrosis progression after liver transplantation in patients with recurrent hepatitis C. *J Hepatol* 2004 Nov;41(5):830-836.
- [22] Roche B, Sebagh M, Canfora ML *et al.* Hepatitis C virus therapy in liver transplant recipients: response predictors, effect on fibrosis progression, and importance of the initial stage of fibrosis. *Liver Transpl* 2008 Dec;14(12):1766-1777.
- [23] Schmeding M, Neumann UP, Puhl G *et al.* Hepatitis C recurrence and fibrosis progression are not increased after living donor liver transplantation: a single center study of 289 patients. *Liver Transpl* 2007 May;13(5):687-692.
- [24] Desmet VJ, Gerber M, Hoofnagle JH *et al.* Classification of chronic hepatitis: diagnosis, grading and staging. *Hepatology* 1994 Jun;19(6):1513-1520.
- [25] Roche B, Samuel D. Risk factors for hepatitis C recurrence after liver transplantation. *J Viral Hepat* 2007 Nov;14 Suppl 1:89-96.
- [26] Shuhart MC, Bronner MP, Gretch DR *et al.* Histological and clinical outcome after liver transplantation for hepatitis C. *Hepatology* 1997 Dec;26(6):1646-1652.
- [27] Goldin RD, Goldin JG, Burt AD *et al.* Intra-observer and inter-observer variation in the histopathological assessment of chronic viral hepatitis. *J Hepatol* 1996 Nov;25(5):649-654.
- [28] Anonymous. Banff schema for grading liver allograft rejection: an international consensus document. *Hepatology* 1997 Mar;25(3):658-663.
- [29] Zimmermann T, Otto C, Hoppe-Lotichius M *et al.* Risk factors in patients with rapid recurrent hepatitis C virus-related cirrhosis within 1 year after liver transplantation. *Transplant Proc* 2009 Jul-Aug;41(6):2549-2556.

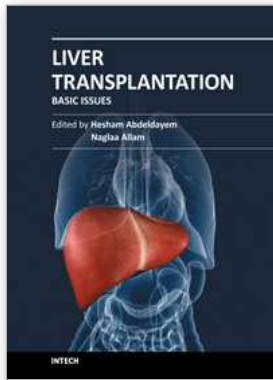
- [30] Lake JR, Shorr JS, Steffen BJ *et al.* Differential effects of donor age in liver transplant recipients infected with hepatitis B, hepatitis C and without viral hepatitis. *Am J Transplant* 2005 Mar;5(3):549- 557.
- [31] Bahra M, Jacob D, Neumann UP *et al.* Influence of donor histology on outcome in patients undergoing transplantation for hepatitis C. *Transplantation* 2007 Jul 27;84(2):144-148.
- [32] Barrett S, Collins M, Kenny C *et al.* Polymorphisms in tumour necrosis factor-alpha, transforming growth factor-beta, interleukin-10, interleukin-6, interferon gamma, and outcome of hepatitis C virus infection. *J Med Virol* 2003 Oct;71(2):212-218.
- [33] Ben-Ari Z. Role of cytokine gene polymorphism in recurrent HCV infection after liver transplantation. *Liver Transpl* 2006 Nov;12(11):1723-1724.
- [34] Ben-Ari Z, Mor E, Papo O *et al.* Cytokine gene polymorphisms in patients infected with hepatitis B virus. *Am J Gastroenterol* 2003 Jan;98(1):144-150.
- [35] Shackel NA, Jamias J, Rahman W *et al.* Early high peak hepatitis C viral load levels independently predict hepatitis C-related liver failure post-liver transplantation. *Liver Transpl* 2009 Jul;15(7):709- 718.
- [36] Gayowski T, Singh N, Marino IR *et al.* Hepatitis C virus genotypes in liver transplant recipients: impact on posttransplant recurrence, infections, response to interferon alpha therapy and outcome. *Transplantation* 1997 Aug 15;64(3):422-426.
- [37] Prieto M, Berenguer M, Rayon JM *et al.* High incidence of allograft cirrhosis in hepatitis C virus genotype 1b infection following transplantation: relationship with rejection episodes. *Hepatology* 1999 Jan;29(1):250-256.
- [38] Lake JR. The role of immunosuppression in recurrence of hepatitis C. *Liver Transpl* 2003 Nov;9(11):S63-66.
- [39] Bahra M, Neumann UP, Jacob D *et al.* Outcome after liver re-transplantation in patients with recurrent chronic hepatitis C. *Transpl Int* 2007 Sep;20(9):771-778.
- [40] Marcello T, Grakoui A, Barba-Spaeth G *et al.* Interferons alpha and lambda inhibit hepatitis C virus replication with distinct signal transduction and gene regulation kinetics. *Gastroenterology* 2006 Dec;131(6):1887-1898.
- [41] Zervos XA, Weppeler D, Fragulidis GP *et al.* Comparison of tacrolimus with neoral as primary immunosuppression in hepatitis C patients after liver transplantation. *Transplant Proc* 1998 Jun;30(4):1405-1406.
- [42] Bahra M, Neumann UI, Jacob D *et al.* MMF and calcineurin taper in recurrent hepatitis C after liver transplantation: impact on histological course. *Am J Transplant* 2005 Feb;5(2):406-411.
- [43] Kniepeiss D, Iberer F, Grasser B *et al.* Sirolimus and mycophenolate mofetil after liver transplantation. *Transpl Int* 2003 Jul;16(7):504-509.
- [44] Asthana S, Toso C, Meeberg G *et al.* The impact of sirolimus on hepatitis C recurrence after liver transplantation. *Can J Gastroenterol* Jan;25(1):28-34.
- [45] Fiore CE, Pennisi P, Tamborino C. YKL-40 and graft rejection. *Am J Med* 2000 Jun 1;108(8):688- 689.
- [46] Eurich D, Boas-Knoop S, Morawietz L *et al.* Association of mannose-binding lectin-2 gene polymorphism with the development of hepatitis C-induced hepatocellular carcinoma. *Liver Int* Aug;31(7):1006-1012.

- [47] Fildes JE, Shaw SM, Walker AH et al. Mannose-binding lectin deficiency offers protection from acute graft rejection after heart transplantation. *J Heart Lung Transplant* 2008 Dec;27(12):1353-1356.
- [48] Cicinnati VR, Iacob S, Klein CG et al. Ribavirin with either standard or pegylated interferon to treat recurrent hepatitis C after liver transplantation. *Aliment Pharmacol Ther* 2007 Jul 15;26(2):291-303.
- [49] Xirouchakis E, Triantos C, Manousou P et al. Pegylated-interferon and ribavirin in liver transplant candidates and recipients with HCV cirrhosis: systematic review and meta-analysis of prospective controlled studies. *J Viral Hepat* 2008 Oct;15(10):699-709.
- [50] Cisneros L, Londono MC, Blasco C et al. Hepatic stellate cell activation in liver transplant patients with hepatitis C recurrence and in non-transplanted patients with chronic hepatitis C. *Liver Transpl* 2007 Jul;13(7):1017-1027.
- [51] Friedman SL. Hepatic stellate cells. *Prog Liver Dis* 1996;14:101-130.
- [52] Iadonato SP, Katze MG. Genomics: Hepatitis C virus gets personal. *Nature* 2009 Sep 17;461(7262):357-358.
- [53] Bataller R. [Genetic polymorphisms and liver diseases]. *Gastroenterol Hepatol* 2003 May;26(5):307-309.
- [54] Madsen HO, Garred P, Thiel S et al. Interplay between promoter and structural gene variants control basal serum level of mannan-binding protein. *J Immunol* 1995 Sep 15;155(6):3013-3020.
- [55] Mas VR, Fisher RA, Maluf DG et al. Polymorphisms in cytokines and growth factor genes and their association with acute rejection and recurrence of hepatitis C virus disease in liver transplantation. *Clin Genet* 2004 Mar;65(3):191-201.
- [56] Sommereyns C, Paul S, Staeheli P et al. IFN-lambda (IFN-lambda) is expressed in a tissue-dependent fashion and primarily acts on epithelial cells in vivo. *PLoS Pathog* 2008 Mar;4(3):e1000017.
- [57] Hove WR, van Hoek B, Bajema IM et al. Extensive chimerism in liver transplants: vascular endothelium, bile duct epithelium, and hepatocytes. *Liver Transpl* 2003 Jun;9(6):552-556.
- [58] Cervera C, Balderramo D, Suarez B et al. Donor mannose-binding lectin gene polymorphisms influence the outcome of liver transplantation. *Liver Transpl* 2009 Oct;15(10):1217-1224.
- [59] Moroso V, Metselaar HJ, Mancham S et al. Liver grafts contain a unique subset of natural killer cells that are transferred into the recipient after liver transplantation. *Liver Transpl* Jul;16(7):895-908.
- [60] Charlton MR, Thompson A, Veldt BJ et al. Interleukin-28B polymorphisms are associated with histological recurrence and treatment response following liver transplantation in patients with hepatitis C virus infection. *Hepatology* Jan;53(1):317-324.
- [61] Ben-Ari Z, Pappo O, Druzd T et al. Role of cytokine gene polymorphism and hepatic transforming growth factor beta1 expression in recurrent hepatitis C after liver transplantation. *Cytokine* 2004 Jul 7;27(1):7-14.
- [62] Bissell DM. Chronic liver injury, TGF-beta, and cancer. *Exp Mol Med* 2001 Dec 31;33(4):179-190.

- [63] Eurich D, Bahra M, Boas-Knoop S et al. Transforming growth factor beta1 polymorphisms and progression of graft fibrosis after liver transplantation for hepatitis C virus--induced liver disease. *Liver Transpl Mar*;17(3):279-288.
- [64] Eurich D, Boas-Knoop S, Ruehl M et al. Relationship between the interleukin-28b gene polymorphism and the histological severity of hepatitis C virus-induced graft inflammation and the response to antiviral therapy after liver transplantation. *Liver Transpl Mar*;17(3):289-298.
- [65] Rauch A, Kutalik Z, Descombes P et al. Genetic variation in IL28B is associated with chronic hepatitis C and treatment failure: a genome-wide association study. *Gastroenterology Apr*;138(4):1338-1345, 1345 e1331-1337.
- [66] Robek MD, Boyd BS, Chisari FV. Lambda interferon inhibits hepatitis B and C virus replication. *J Virol 2005 Mar*;79(6):3851-3854.
- [67] O'Brien TR. Interferon-alfa, interferon-lambda and hepatitis C. *Nat Genet 2009 Oct*;41(10):1048-1050.
- [68] Sheppard P, Kindsvogel W, Xu W et al. IL-28, IL-29 and their class II cytokine receptor IL-28R. *Nat Immunol 2003 Jan*;4(1):63-68.
- [69] Cescon M, Grazi GL, Cucchetti A et al. Predictors of sustained virological response after antiviral treatment for hepatitis C recurrence following liver transplantation. *Liver Transpl 2009 Jul*;15(7):782-789.
- [70] Brady DE, Torres DM, An JW et al. Induction pegylated interferon alfa-2b in combination with ribavirin in patients with genotypes 1 and 4 chronic hepatitis C: a prospective, randomized, multicenter, open-label study. *Clin Gastroenterol Hepatol Jan*;8(1):66-71 e61.
- [71] Burra P, Targhetta S, Pevero S et al. Antiviral therapy for hepatitis C virus recurrence following liver transplantation: long-term results from a single center experience. *Transplant Proc 2006 May*;38(4):1127-1130.
- [72] Everson GT, Kulig CC. Antiviral therapy for hepatitis C in the setting of liver transplantation. *Curr Treat Options Gastroenterol 2006 Dec*;9(6):520-529.
- [73] Neumann U, Puhl G, Bahra M et al. Treatment of patients with recurrent hepatitis C after liver transplantation with peginterferon alfa-2B plus ribavirin. *Transplantation 2006 Jul 15*;82(1):43-47.
- [74] Rodriguez-Luna H, Khatib A, Sharma P et al. Treatment of recurrent hepatitis C infection after liver transplantation with combination of pegylated interferon alpha2b and ribavirin: an open-label series. *Transplantation 2004 Jan 27*;77(2):190-194.
- [75] Schmitz V, Kiessling A, Bahra M et al. Peginterferon alfa-2b plus ribavirin for the treatment of hepatitis C recurrence following combined liver and kidney transplantation. *Ann Transplant 2007*;12(3):22-27.
- [76] Terrault NA, Berenguer M. Treating hepatitis C infection in liver transplant recipients. *Liver Transpl 2006 Aug*;12(8):1192-1204.
- [77] Bahra M, Neumann UP, Jacob D et al. Fibrosis progression in hepatitis C positive liver recipients after sustained virologic response to antiviral combination therapy (interferon-ribavirin therapy). *Transplantation 2007 Feb 15*;83(3):351-353.
- [78] Ge D, Fellay J, Thompson AJ et al. Genetic variation in IL28B predicts hepatitis C treatment- induced viral clearance. *Nature 2009 Sep 17*;461(7262):399-401.

- [79] McCarthy JJ, Li JH, Thompson A *et al.* Replicated Association Between an Interleukin-28B Gene Variant and a Sustained Response to Pegylated Interferon and Ribavirin. *Gastroenterology* Feb 19.
- [80] Tanaka Y, Nishida N, Sugiyama M *et al.* Genome-wide association of IL28B with response to pegylated interferon-alpha and ribavirin therapy for chronic hepatitis C. *Nat Genet* 2009 Oct;41(10):1105-1109.
- [81] Schmidt SC, Bahra M, Bayraktar S *et al.* Antiviral Treatment of Patients with Recurrent Hepatitis C After Liver Transplantation with Pegylated Interferon. *Dig Dis Sci* 2009 Oct 2.
- [82] Samuel D, Bizollon T, Feray C *et al.* Interferon-alpha 2b plus ribavirin in patients with chronic hepatitis C after liver transplantation: a randomized study. *Gastroenterology* 2003 Mar;124(3):642-650.
- [83] Schumann J, Prockl J, Kiemer AK *et al.* Silibinin protects mice from T cell-dependent liver injury. *J Hepatol* 2003 Sep;39(3):333-340.
- [84] Stickel F, Schuppan D. Herbal medicine in the treatment of liver diseases. *Dig Liver Dis* 2007 Apr;39(4):293-304.
- [85] Saller R, Meier R, Brignoli R. The use of silymarin in the treatment of liver diseases. *Drugs* 2001;61(14):2035-2063.
- [86] Gordon A, Hobbs DA, Bowden DS *et al.* Effects of *Silybum marianum* on serum hepatitis C virus RNA, alanine aminotransferase levels and well-being in patients with chronic hepatitis C. *J Gastroenterol Hepatol* 2006 Jan;21(1 Pt 2):275-280.
- [87] Hawke RL, Schrieber SJ, Soule TA *et al.* Silymarin Ascending Multiple Oral Dosing Phase I Study in Noncirrhotic Patients With Chronic Hepatitis C. *J Clin Pharmacol* 2009 Oct 19.
- [88] Falasca K, Ucciferri C, Mancino P *et al.* Treatment with silybin-vitamin E-phospholipid complex in patients with hepatitis C infection. *J Med Virol* 2008 Nov;80(11):1900-1906.
- [89] Pradhan SC, Girish C. Hepatoprotective herbal drug, silymarin from experimental pharmacology to clinical medicine. *Indian J Med Res* 2006 Nov;124(5):491-504.
- [90] Gazak R, Walterova D, Kren V. Silybin and silymarin--new and emerging applications in medicine. *Curr Med Chem* 2007;14(3):315-338.
- [91] Buzzelli G, Moscarella S, Giusti A *et al.* A pilot study on the liver protective effect of silybin- phosphatidylcholine complex (IdB1016) in chronic active hepatitis. *Int J Clin Pharmacol Ther Toxicol* 1993 Sep;31(9):456-460.
- [92] Ferenci P, Scherzer TM, Kerschner H *et al.* Silibinin is a potent antiviral agent in patients with chronic hepatitis C not responding to pegylated interferon/ribavirin therapy. *Gastroenterology* 2008 Nov;135(5):1561-1567.
- [93] Loguercio C, Federico A, Trappoliere M *et al.* The effect of a silybin-vitamin-e-phospholipid complex on nonalcoholic fatty liver disease: a pilot study. *Dig Dis Sci* 2007 Sep;52(9):2387-2395.
- [94] Saller R, Brignoli R, Melzer J *et al.* An updated systematic review with meta-analysis for the clinical evidence of silymarin. *Forsch Komplementmed* 2008 Feb;15(1):9-20.
- [95] Gazak R, Sedmera P, Vrbacky M *et al.* Molecular mechanisms of silybin and 2,3-dehydrosilybin antiradical activity--role of individual hydroxyl groups. *Free Radic Biol Med* 2009 Mar 15;46(6):745-758.

- [96] Dehmlow C, Murawski N, de Groot H. Scavenging of reactive oxygen species and inhibition of arachidonic acid metabolism by silibinin in human cells. *Life Sci* 1996;58(18):1591-1600.
- [97] Trappoliere M, Caligiuri A, Schmid M *et al.* Silybin, a component of silymarin, exerts anti-inflammatory and anti-fibrogenic effects on human hepatic stellate cells. *J Hepatol* 2009 Jun;50(6):1102-1111.
- [98] Boigk G, Stroedter L, Herbst H *et al.* Silymarin retards collagen accumulation in early and advanced biliary fibrosis secondary to complete bile duct obliteration in rats. *Hepatology* 1997 Sep;26(3):643- 649.
- [99] Biermer M, Berg T. Rapid suppression of hepatitis C viremia induced by intravenous silibinin plus ribavirin. *Gastroenterology* 2009 Jul;137(1):390-391.
- [100] Eurich D, Bahra M, Berg T *et al.* Treatment of hepatitis C-virus-reinfection after liver transplant with silibinin in nonresponders to pegylated interferon-based therapy. *Exp Clin Transplant* Feb;9(1):1-6.
- [101] Neff GW, O'Brien CB, Nery J *et al.* Factors that identify survival after liver retransplantation for allograft failure caused by recurrent hepatitis C infection. *Liver Transpl* 2004 Dec;10(12):1497-1503.



Liver Transplantation - Basic Issues

Edited by Prof. Hesham Abdeldayem

ISBN 978-953-51-0016-4

Hard cover, 418 pages

Publisher InTech

Published online 15, February, 2012

Published in print edition February, 2012

This book covers a wide spectrum of topics including history of liver transplantation, ischemia-reperfusion injury, immunology of liver transplantation, viral hepatitis and liver transplantation, other indications for liver transplantation, prognostic factors and perioperative period. The authors of the chapters are experts in their respective fields. They are proponents covering different aspects of liver transplantation and come from many centers across the world. The interdisciplinary approach and the authority of the contributors resulted in a valuable reference to anyone interested in developing a global view in liver transplantation including medical students, residents, fellows, nurses, and practicing physicians and surgeons as well as researchers in the field of liver transplantation.

How to reference

In order to correctly reference this scholarly work, feel free to copy and paste the following:

Dennis Eurich, Marcus Bahra and Peter Neuhaus (2012). HCV-Recurrence After Liver Transplantation, Liver Transplantation - Basic Issues, Prof. Hesham Abdeldayem (Ed.), ISBN: 978-953-51-0016-4, InTech, Available from: <http://www.intechopen.com/books/liver-transplantation-basic-issues/hcv-recurrence-after-liver-transplantation>

INTECH
open science | open minds

InTech Europe

University Campus STeP Ri
Slavka Krautzeka 83/A
51000 Rijeka, Croatia
Phone: +385 (51) 770 447
Fax: +385 (51) 686 166
www.intechopen.com

InTech China

Unit 405, Office Block, Hotel Equatorial Shanghai
No.65, Yan An Road (West), Shanghai, 200040, China
中国上海市延安西路65号上海国际贵都大饭店办公楼405单元
Phone: +86-21-62489820
Fax: +86-21-62489821

© 2012 The Author(s). Licensee IntechOpen. This is an open access article distributed under the terms of the [Creative Commons Attribution 3.0 License](#), which permits unrestricted use, distribution, and reproduction in any medium, provided the original work is properly cited.