

Surgical Treatment After Spinal Trauma in Patients with Ankylosing Spondylitis

Stamatios A. Papadakis¹, Konstantinos Kateros², Spyridon Galanakis¹,
George Machairas¹, Pavlos Katonis³ and George Sapkas⁴

¹*D' Department of Orthopaedics, "KAT" General Hospital, Athens,*

²*A' Department of Orthopaedics, "G. Gennimatas" General Hospital, Athens,*

³*Department of Orthopaedics, University of Crete, Herakleion,*

⁴*A' Department of Orthopaedics, University of Athens,*

"Attikon" University Hospital, Haidari,

Greece

1. Introduction

Ankylosing Spondylitis (AS) is a chronic inflammatory disease which is characterized by pain and progressive stiffness and which spinal and sacroiliac joints are mainly affected. It affects mostly males, having a male-to-female ratio approximately 3-4:1 and the onset occur between the 15th and the 35th year of life (Bechterew, 1979; Calin, 1985; van der Linden et al., 2005).

Ankylosing Spondylitis transforms the flexible spinal column into a stiff rod; the stiffened spine cannot bear normal loads in comparison with a healthy spine. In addition, it has been established that bone mineral density loss occurs early in the AS disease course and is associated with inflammation correlated with increased bone resorption (van der Horst-Bruinsma, 2006). The kyphotic deformation of the spine that exists makes the ankylosing and osteoporotic spine susceptible to stress fractures under the impact of small forces and loads (van der Linden et al., 2005). The diffuse paraspinal ossification and inflammatory osteitis of advanced AS creates a fused, brittle spine that is susceptible to fracture (De Peretti et al, 2004; Einsiedel et al, 2006; Hanson and Mirza, 2000; van der Horst-Bruinsma, 2006; Taggard and Traynelis, 2000;). Patients suffering from AS may undergo a fracture with minimal (Graham and Van Peteghem, 1989; Hanson and Mirza, 2000; Trent et al., 1988; Whang et al, 2009), or even no history of injury (Olerud et al., 1996; Westerveld et al., 2009; Yau and Chan, 1974).

The most frequent site, where a fracture is located is the cervical spine (75%) especially its lower part, and the cervical-thoracic junction, following by the thoracolumbar junction (T10-L2). The drastic increase in stiffness at the cervicothoracic junction, combined with the lever arm of the fused cervical spine and weight of the head, makes fractures at the C6-C7 and C7-T1 levels most common. The lumbar and thoracic spines are more resistant to fracture because the anterior and posterior longitudinal ligaments are more thoroughly ossified than in the cervical spine. (Bohlman, 1979; Hanson and Mirza, 2000; Osgood et al., 1973; Surin,

1980; Taggard and Traynelis, 2000; Trent et al., 1988; Westerveld et al., 2009; Yau and Chan, 1974). Disruption of all the three columns of the spine predisposes to displacement and neurological injury (Gelman and Ueber, 1978; Rasker et al., 1996).

When a fracture occurs in a patient with AS it should be considered as high-risk injury, especially when it is located in the cervical-thoracic junction of the spine (Fast et al., 1986; Sharma and Mathad, 1988). The most unstable types are shearing fractures. They may have severe neurological symptoms or may lead to haemothorax or rupture of the aorta, which are serious complications (Juric et al., 1990; Sharma and Mathad, 1988). Secondary neurological aggravation may be possible due to displacement of the fractured segments, which happens mainly in hyperextension injuries (Whang et al., 2009). Furthermore, where an interval occurs between trauma and the onset of neurologic signs or worsening of the neurologic picture the formation of an epidural hematoma should be suspected and excluded by means of an MRI scan (Thumbic et al., 2007). Diagnosis can be difficult due to pre-existing spinal alterations (distortion of the normal spinal anatomy by ectopic bone formation, erosions, sclerosis, disk ossification, vertebral wedging). The standard radiographs are inadequate to fully evaluate shearing fractures due to osteoporosis, and the position of the shoulders (which are usually located at a higher position). Thus, these fractures can be missed in the first examination and in the later stages, are characterized by vertebral corrosion, collapse and deformity. A misdiagnosed fracture can possibly lead to pseudarthrosis or Andersson lesion.

2. Diagnostic approach and clinical / radiological findings

The low grade of clinical suspicion makes the diagnosis difficult. The low imaging quality due to osteoporosis and the position of the shoulders (which usually are located in higher position) raise the difficulty level. Shearing fractures are possible to be missed in the first examination. All the available radiological tools should be used in order to validate the diagnosis, particularly when the injury concerns the occipital-cervical, the cervical-thoracic, the thoracolumbar or the lumbar-sacral junctions (Figures 1, 2, 3).

Plain radiographs (face, profile and oblique views) of the injured region may not reveal the fracture, giving only indirect information, such as widening of the disk space and discontinuity of the ossified paraspinal ligaments (Hanson and Mirza, 2000) which unfortunately are not able to set the diagnosis. In later stages these fractures are characterized by vertebral corrosion, collapse and deformity. A misdiagnosed fracture possibly leads to pseudarthrosis.

The neurological disorders may be established at the time of injury but it is not unusual to be established progressively with several days delay. It is not an exaggeration to say, that new back pain in patients with ankylosing spondylitis should be assumed to be caused by a fracture until proven otherwise (Einsiedel et al., 2006; Hanson and Mirza, 2000; Trent et al., 1988). Thus, thorough clinical and radiological assessment should be performed in these patients and should be repeated for the first few weeks, especially if the patient complains for indefinable pain or if neurological disorders are noted. The clinical doctor should always have in mind that the simple radiological evaluation of these injuries may not be able to reveal the fractures from the very first time. CT and MRI are valuable tools in order to reveal these fractures.

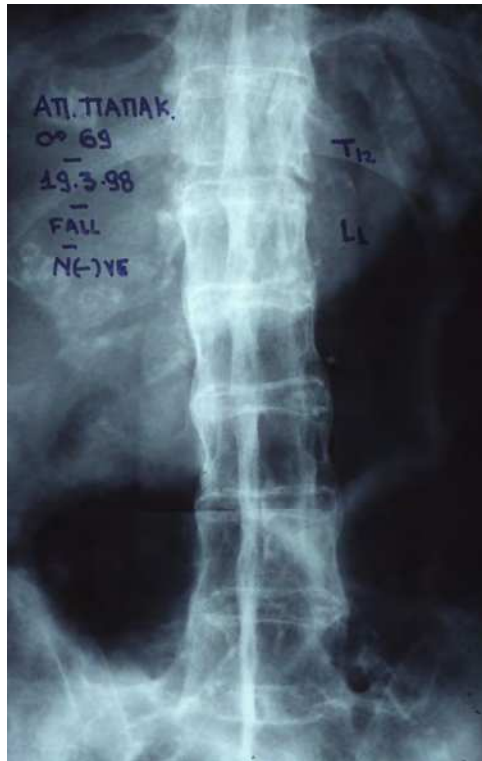

Fig. 1. Anteroposterior radiograph showing Chance type fracture due to a hyperextension injury at T12-L1 level.

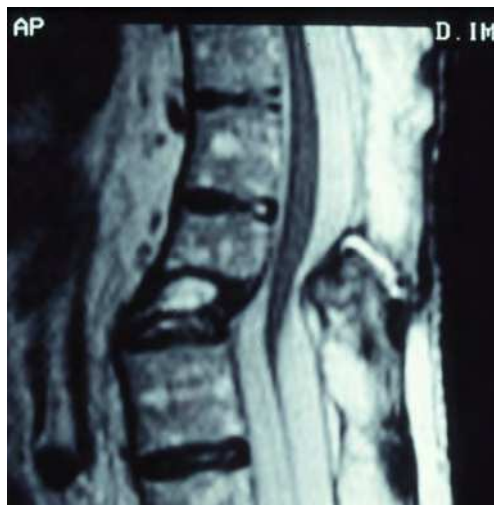

Fig. 2. Lateral MRI of the same case with a Chance type of fracture at T12-L1 level.

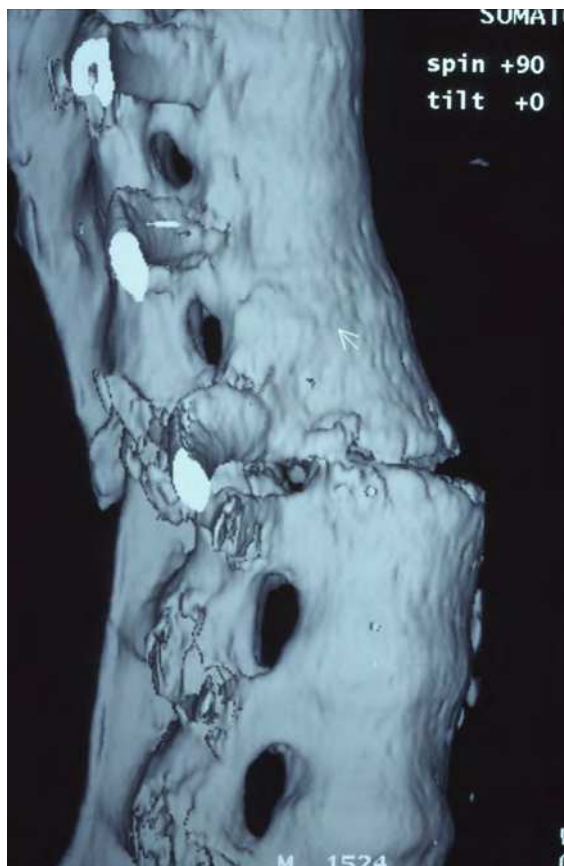

Fig. 3. Lateral 3D reconstruction image of the same case.

Preoperative evaluation of the cervical spine is essential when manipulating the neck during intubation and patient positioning. Physicians also must be aware that, because the atlanto-occipital joint is last to fuse, atlantoaxial instability may occur. Instability is usually demonstrated on lateral flexion-extension views of the neck, where the atlantodens and posterior atlantodens intervals are measured. An atlantodens interval >3.5 mm is indicative of instability. A difference of 7 mm indicates disruption of the alar ligaments, and a difference >9 to 10 mm or a posterior atlantodens interval >14 mm is associated with an increased risk of neurologic injury and usually requires surgical intervention (Kubiak et al, 2005). However, there are no guidelines for the management of atlantoaxial subluxation in patients with AS. Such management is similar to that performed in patients with rheumatoid arthritis (Ramos-Remus et al., 2006).

3. Surgical treatment

The majority of the cervical spine fractures occur at the level of the intervertebral disc and result in anatomic displacement and instability (Graham and Van Peteghem, 1987; Fox et al.,

1993; Kanter et al., 2008). Under these circumstances a potential neurological deficit is often and that necessitate early and aggressive surgical management with posterior and/or anterior fixation techniques to enable neural decompression, spinal stability, and optimal functionality (Broom and Raycroft, 1988; Deutsch and Haid, 2008).

A surgical intervention is necessary in cases of traumatic instability, significant deformity, and persistent degenerative radiculopathy with axial pain. In addition, selection of the patients that require surgical treatment is based on the degree of deformity, the level of pain and disability, and the medical status of the patient (Mundwiler et al., 2008).

3.1 Anesthesia options

It is well documented that a crucial step in airway management and prior to any surgical intervention, is a smooth and successful intubation (Hoh et al., 2008; Sciubba et al., 2008). The risks during obtaining airway access are significantly increased in patients with AS. The presence of large anterior cervical osteophytes may prohibit successful visualization of the larynx and may prevent endotracheal intubation due to significant mass obstruction. In addition, intubation may be impossible in cases in which the patient cannot extend his neck. Therefore, relatively minor flexion or extension forces during head positioning for intubation could lead to the creation of iatrogenic fractures or neurological injury by the intubation professional (Palmer, 1993). With modern anesthesia techniques, however, awake intubation allows for constant neurological monitoring during induction and insertion of an endotracheal tube. Fiberoptic visualization facilitates inserting a nasotracheal tube to secure airway access in patients with fixed cervical flexion (Hoh et al., 2008).

With endotracheal intubation, airway access is secured throughout the duration of the procedure. With a secured airway, the procedure can be performed in the prone position, facilitating placement of instrumentation, particularly at the upper thoracic levels, and reduces the risk of air embolism. General anesthesia also ensures patient comfort throughout the procedure. General anesthesia, however, impairs the ability to monitor neurological function, particularly immediately. While a wake-up test definitively demonstrates the patient's neurological function, expert anesthesia is required to perform a safe and timely evaluation. In a recent study, have been considered that as a special consideration for patients with AS, informed consent should include obtaining a consent for tracheotomy in the event that an obstructive cervical osteophyte or severe cervical flexion deformity prevent successful intubation (Cesur et al., 2005).

3.1.1 Patient positioning

Proper positioning of a patient with AS in the operating room or the ICU is imperative not only for the patient with an unstable fracture, but in all AS patients because of their increased risk of iatrogenic injury. During head positioning, the surgeon must take into account the sagittal alignment of the cervical spine, which may often be significantly kyphotic. When fractures already exist in these patients, inadequate assessment of the mass of the head and the extent of cervical kyphosis can have disastrous effects such as complete spinal cord damage and possible death (Hunter and Dubo, 1978; Sciubba et al., 2008).

In surgical procedures, preoperative halo placement and traction have shown success in improving stability during positioning (Chin and Ahn, 2007; Simmons et al., 2006;

Upadhyay et al., 1991). To allow a certain degree of freedom for patients with AS in the operating room or ICU, a number of adaptations to patient beds have been developed to accommodate prolonged immobilization. Such advances have particular relevance for the AS population because they allow the patient to maintain a more comfortable kyphotic condition with cervical traction.

3.1.2 Neurological monitoring

The ability to monitor the neurological status of any patient during positioning or surgical manipulation is extremely important in any spine surgery (Sciubba et al., 2008). In 1974 Scoliosis Research Society found that aggressive surgeries to correct deformities were associated with severe postoperative neurological deficits, and thus the society advised the universal use of intraoperative monitoring. In patients with AS, this statement is especially relevant. The surgeon must first decide whether the patient should receive general anesthesia at all. Because of the potentially hazardous nature of osteotomy procedures, a local anesthetic can be administered for frequent neurological assessments during deformity correction.

Urist (1958) was one of the first to report success with cervical osteotomy with the patient in the sitting position and with local anesthesia. Such operations carry a high risk of neurological complications due to the potential for iatrogenic cervical subluxation and spinal cord compromise, and thus continual feedback on neurological status provided by the awake patient is especially important (Belanger et al., 2005; Chin and Ahn, 2007). Nevertheless, performing these complex corrective spinal procedures on awake patients is a challenging task and is done on a rare basis.

Many complex spine surgeries however, require patients to be in the prone position for prolonged periods with extensive soft tissue exposure, making awake surgeries uncomfortable or completely infeasible for the patient. Hence, the wake-up test, which introduced by Vazuelle et al. in 1973, has been used to monitor the neurological status of patients undergoing prolonged spine deformity surgeries in the prone position.

Nowadays, placement of the patient in the prone position under general anesthesia is the preferred method for most spine surgeries, including those in patients with AS because it allows the surgeon easier access and manipulations of the spine, and the patient can tolerate a longer procedure (Bridwell et al., 2003, 2004; Hitchon et al., 2002, 2006; Langeloo et al., 2006).

Some surgeons feel that the cervical spine region is at a particularly high risk for neurovascular complications compared with the lumbar or thoracic area due to the higher level of the associated spine cord and accompanying vertebral arteries (Simmons et al., 2006). Therefore, if the decision has been made to proceed using general anesthesia, with or without the use of wake-up tests, many authors have stated that neurophysiological monitoring is absolutely required (Chin and Ahn, 2007; Langeloo et al., 2006; Law, 1959). Common techniques include spinal cord evoked potentials introduced by Tamaki and Yamane, (1975), somatosensory cortical evoked potentials introduced by Nash and Brown, (1979), spinal somatosensory evoked potentials introduced by Shimoji et al. (1971), and muscle MEPs introduced by Merton and Morton, (1980). Unfortunately, such studies may not be sensitive enough to reliably predict neurological damage (Tamaki and Kubota, 2007).

Because there may exist discrepancies in sensitivity among the various monitoring techniques, it is now recommended that multiple and continuous neurological monitoring methods be used in addition to wake-up tests so that any false negatives provided by the electrophysiological recording are eliminated (Chin and Ahn, 2007; Tamaki and Yamane, 1975).

3.2 Management of a fracture

Conservative treatment either by prolonged bed rest in traction or in a cervical collar, or by early realignment and immobilization in a halo vest has been advocated because of supposed higher mortality after surgery (Graham and Van Peteghem, 1987). However, maintaining reduction is a major concern for conservative treatment: distraction, halo vest application, and transfer to a stretcher have led to secondary dislocation and neurological deterioration. Furthermore, immobilization in a halo has been associated with serious complications. Poor bone quality, vulnerable skin, and difficulty in achieving good alignment are additional arguments against the use of a halo (Schroder et al., 2003).

Surgical treatment is more commonly used, especially in patients with neurologic compromise, obscured visual fields, pseudarthrosis, or recurrent fracture. When traction or internal fixation is used to manage these injuries, the neck should be aligned to prefracture position, not necessarily to a normal position. Minor findings in patients with AS may be associated with substantial instability in the cervical spine, secondary to the altered biomechanics of the fused spine in addition to osteopenia and the concentration of forces at the cervico-occipital and cervico-thoracic junctions. The choice of the stabilization method is depending on the patient's personality, the type of the injury and the surgeon's experience. Currently, surgical stabilization with a rigid fixation is the choice of treatment that many surgeons perform (Figures 4, 5, 6).

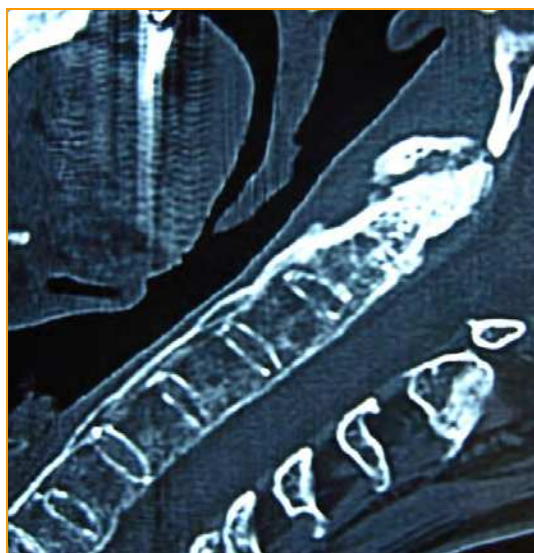

Fig. 4. CT image showing a fracture of the axis at the Cervical Spine.

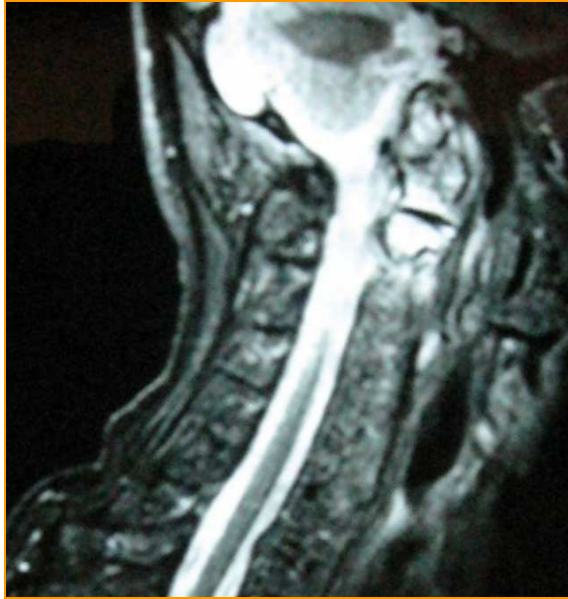

Fig. 5. MRI of the same patient with a fracture of the axis.

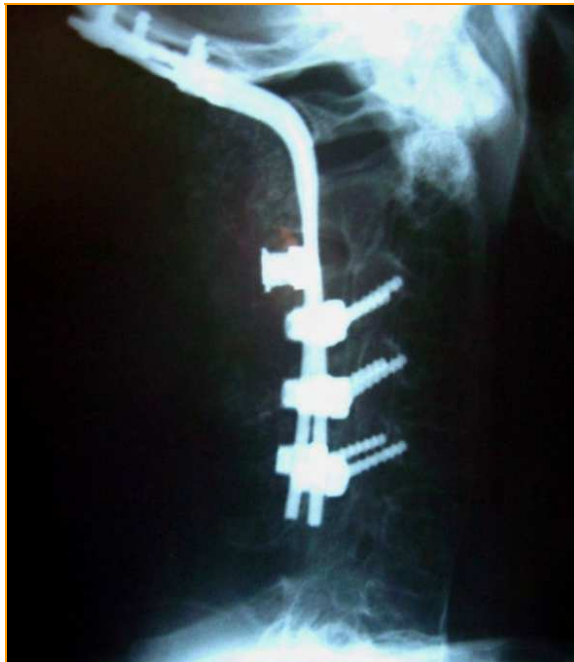


Fig. 6. The patient was treated with occipitocervical fusion by using a screw-rod stabilizing system.

In a review study by Westerveld et al., (2009) authors have recommended the follows:

1. Patients with an ankylosed spine have an increased fracture risk even after minor trauma,
2. Delayed diagnosis of fractures in patients with ankylosing spinal disorders often occur due to both doctor and patient related factors,
3. Fractures of the ankylosed spine tend to be unstable, because ossified ligaments and surrounding tissue also fracture,
4. An intrinsic unstable fracture configuration may lead to primary and secondary neurological deficit,
5. The clinical outcome of patients fracturing their ankylosed spine is worse compared to the general spine trauma population,
6. Surgical treatment may be favorable for patients with an ankylosed spine and spinal fracture, as this treatment option may be associated with lower complication and mortality rates and may lead to neurological improvement more frequently,
7. The presence of ankylosed spine segments should alert the treating physician for unstable spine fractures in every trauma patient,
8. In trauma registries ankylosed conditions of the spine should be registered separately, in order to acquire more knowledge on the patterns and prognosis of these injuries.

In a retrospective review of 12 patients with AS and 18 patients with diffuse idiopathic skeletal hyperostosis (DISH), authors mentioned that the treatment algorithm for managing spinal trauma is similar for both of these disorders, and the specific approach that is selected may be influenced by the type of injury, degree of spinal instability, and neurologic status of the individual (Wang et al., 2009). On the basis of these criteria, most of the injuries in those series were addressed with surgical intervention to more reliably stabilize the spine and prevent further neurologic decline. Although the operative rate observed for the AS group was higher than that of the DISH patients (83.3% vs. 66.7%, respectively), which may reflect the relatively greater neurologic impairment that was displayed by the subjects with AS, this difference was not found to be statistically significant. Even if it may not be feasible to formulate a definitive treatment protocol from the results of the above case series, it is clear that there are several important technical considerations that merit further discussion. As both of these diseases are associated with the development of kyphotic deformities, it is essential that the preinjury alignment of the spine be restored to achieve an adequate and hopefully stable reduction of the fracture. The authors recommended against any attempts to improve upon the preinjury sagittal alignment of these patients in the acute setting because aggressive manipulation may result in an unstable spinal construct that may subject the spinal cord or nerve roots to further harm; consequently, osteotomies and other corrective procedures should be delayed until the original injury has resolved so that they may be performed in a more controlled fashion. Although low-weight traction may be employed for selected cervical lesions to facilitate angular correction and postural positioning with wedge inserts may be useful for addressing any sagittal plane abnormalities associated with thoracolumbar injuries, the application of any type of distraction force is strictly contraindicated in these clinical scenarios because of the increased risk of precipitating a secondary neurologic insult at the level of an unstable spinal segment, particularly in the cervical spine.

It is generally assumed that the stabilization of cervical fractures is better performed with anterior and posterior support of the spine. Sapakas et al., (2009) presented their surgical

experience of spinal fractures occurring in patients suffering from AS and to highlight the difficulties that exist as far as both diagnosis and surgical management. In this study, twenty patients suffering from ankylosing spondylitis were operated due to a spinal fracture. The fracture was located at the cervical spine in 7 cases, at the thoracic spine in 9, at the thoracolumbar junction in 3 and at the lumbar spine in one case (Table 1). Three of the cervical fractures were managed by both anterior and posterior approaches while all the rest were managed only by posterior approach, having no intra-operative complications, but one case with superficial wound infection and two cases (patients with cervical injuries) with loosening of posterior screws without loss of stability. Early mobilization was encouraged in all the patients. Cervical collars were used for 3-6 months, and thoracolumbar spinal orthoses were used for 6-12 months. Neurological defects were revealed in 10 patients. In four of them, neurological signs were progressively developed after a time period of 4 to 15 days. The initial radiological study was negative for a spinal fracture in twelve patients (60%). Authors noted that there was a statistically significant improvement of Frankel neurological classification between the preoperative and postoperative evaluation, only 35% of patients presented an improvement (10% from Frankel D, 10% from Frankel C to Frankel D, 10% from Frankel B to Frankel E and 5% from Frankel D to Frankel E) while 65% of patients were in stable condition (15% from Frankel A to Frankel A and 50% from Frankel E to Frankel E). The authors concluded that operative treatment for AS is useful and effective. It usually succeeds the improvement of the patients' neurological status. They also stated that taking into consideration the cardiovascular problems that these patients have, anterior and posterior stabilization aren't always possible, and in such cases, posterior approach can be performed and give excellent results, while total operation time, blood loss and other complications are decreased.

Olerud et al., (1996) believe that in the cervical spine, where implant loosening is a considerable problem, the failure of support is presented mainly in cases where only anterior or only posterior stabilization was applied because the stabilizing system may not be able to confront the forces which act on it. Thus, both anterior and posterior stabilization of the spine should be applied, especially for the cervical and the thoraco-lumbar spine. Nevertheless, in everyday practice posterior stabilization is usually performed. This is in order to reduce the possible causal factors of intra-operative and postoperative complications, taking into consideration that the most of these patients have cardiovascular and pulmonary disorders caused by restrictive ankylosis of the thoracic cage and prolonging the operating time by performing double stabilization and thoracotomy aggravates cardiovascular function. Moreover, the anterior approach to the cervical-thoracic junction is extremely difficult in these patients due to the great inclination and the kyphosis that exists at this region.

Long stabilizing systems that offer support to a greater area of the spine and the parallel use of braces postoperatively have been used in order to strengthen the stabilization. Serin et al., (2004) showed that four levels posterior fixation is superior to two levels posterior fixation and a four levels fixation plus offset hook is the most stable. Tezeren and Kuru (2005) demonstrated that final outcome regarding sagittal index and anterior body compression is better in the long segment instrumentation group than in the short segment instrumentation group.

#	Age (years)	Sex	Mechanism of injury	Level of fracture/Type	Neurological status preoperatively	Treatment/Levels of Fusion	Neurological status postoperatively
1	80	M	Fall	C2/Type II	Frankel C	Posterior instrumentation/ Occipito-C4	Frankel D
2	65	M	Fall	C2/Type I	Frankel E	Posterior instrumentation/ Occipito-C4	Frankel E
3	60	M	Fall	C6 - C7/A.3.1.1	Frankel E	Anterior + Posterior instrumentation/ C4-T2	Frankel E
4	38	M	Fall from height	C6 - C7/A.2.3.1	Frankel C	Anterior + Posterior instrumentation/ C4-T2	Frankel E
5	67	M	Fall	C6-C7/B.3.2.2	Frankel C	Posterior instrumentation/ C4-T2	Frankel E
6	69	F	Fall	C6 - C7/C.2.2.1	Frankel A	Anterior + Posterior instrumentation/ C4-T2	Frankel A
7	55	M	Fall	C6 - C7/A.3.1.1	Frankel E	Posterior instrumentation/ C4-T2	Frankel E
8	39	M	Fall	T5 - T6/ A.3.3.1	Frankel D	Posterior instrumentation/ T3-T8	Frankel E
9	23	F	Fall	T8/A.3.2.3	Frankel E	Posterior instrumentation/ T6-T10	Frankel E
10	53	M	Fall	T8 - T9/B.2.2.2	Frankel C	Posterior instrumentation/ T6-T11	Frankel D
11	65	F	Fall	T8 - T9/B.1.1.1	Frankel E	Posterior instrumentation/ T6-T11	Frankel E
12	57	M	Fall	T9/A.3.2.3	Frankel E	Posterior instrumentation/ T7-T11	Frankel E
13	64	M	Fall	T10 - T11/C.2.2.1	Frankel A	Posterior instrumentation/ T8-L1	Frankel A
14	79	M	Fall	T10 - T11/A.3.2.1	Frankel B	Posterior instrumentation/ T8-L1	Frankel D
15	40	M	Fall	T10 - T11/C.2.1.3	Frankel A	Posterior instrumentation/ T8-L1	Frankel A
16	52	M	Car Accident	T11 - T12/B.1.1.1	Frankel E	Posterior instrumentation/ T9-L2	Frankel E

17	69	F	Fall	T12 - L1/A.3.2.3	Frankel E	Posterior instrumentation/ T10-L2	Frankel E
18	38	M	Fall	T12 - L1/A.3.2.3	Frankel E	Posterior instrumentation/ T10-L2	Frankel E
19	40	M	Fall	T12 - L1/B.1.1.1	Frankel E	Posterior instrumentation/ T10-L2	Frankel E
20	55	M	Fall	L1 - L2/ B.1.1.1	Frankel B	Posterior instrumentation/ T12-L4	Frankel D

Table 1. Patients' data. (Adapted from Sapkas et al, BMC Musculoskeletal Disorders 2009 2, 10(1), 96)

3.2.1 Perioperative complications

1. Intraoperative blood loss: Operations involving patients with AS have been associated with increased perioperative blood loss (Nash and Brown, 1979; Palm et al., 2002). It may partly be caused by high intra-abdominal pressures due to difficulties in patient positioning (de Kleuver, 2006).
2. Trauma to dura mater: Due to chronic inflammation of the disease adhesions between dura mater, ligamentum flavum and bone may exist, making easier possible lacerations and tears of the dura.
3. Poor bone quality and internal fixation: The spine in AS is osteoporotic, due to the chronic inflammation and the bone atrophy. The consumption of corticosteroid drugs in the long run takes a serious part in this process making implant loosening a considerable problem.

4. Conclusions

Even minor injuries may cause fractures in an ankylosing spine. Patients with AS who sustain injuries of the spine are at greater risk of developing neurological impairment. These neurological disorders may be established at the time of injury but it is not unusual for them to become progressively, with several days delay. It is not an exaggeration to say that new back pain in patients with AS should be assumed to be caused by a fracture until proven otherwise. Thus, thorough clinical and radiological assessment should be performed in these patients and should be repeated for the first few weeks, especially if the patient complains of indefinable pain or if neurological disorders are noted. Accident and Emergency physicians should always bear in mind that simple radiological evaluation of these injuries may not be able to reveal fractures at first. CT and MRI are valuable tools in order to reveal these fractures.

The operative treatment of these injuries is useful and effective for these patients. It usually succeeds the improvement of the patients' neurological status, apart from cases where paraplegia is already established. However, the operative treatment is very demanding, especially when the cervical spine is concerned. Both anterior and posterior stabilization offer better support. Taking into consideration the cardiovascular and pulmonary problems

that these patients have, anterior and posterior stabilization aren't always possible. There is a need for wider multicenter studies to get a correct picture of the incidence and the problems encountered in management of vertebral column trauma in AS.

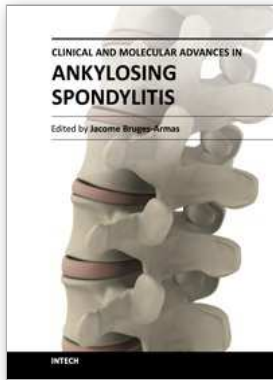
5. References

- Bechterew, VM. (1979). The classic stiffening of the spine in flexion, a special form of disease. *Clinical Orthopaedics and Related Research*, Vol.143, (September 1979), pp. 4-7
- Belanger, TA.; Milam, RA IV.; Roh, JS.; & Bohlman, HH. (2005). Cervicothoracic extension osteotomy for chin-on-chest deformity in ankylosing spondylitis. *Journal of Bone and Joint Surgery Am*, Vol.87, No.8, (August 2005), pp. 1732-1738
- Bohlman, HH. (1979). Acute fractures and dislocation of the cervical spine. An analysis of three hundred hospitalized patients and review of the literature *Journal of Bone and Joint Surgery Am*, Vol.61, No.8, (December 1979), pp. 1119-1142
- Bridwell, KH.; Lewis, SJ.; Edwards, C.; Lenke, LG.; Iffrig, TM.; Berra, A.; Baldus, C.; & Blanke, K. (2003). Complications and outcomes of pedicle subtraction osteotomies for fixed sagittal imbalance. *Spine (Phila Pa 1976)*, Vol.28, No.18, (September 2003), pp. 2093-2101
- Bridwell, KH.; Lewis SJ.; Rinella A.; Lenke LG.; Baldus C.; & Blanke K. (2004). Pedicle subtraction osteotomy for the treatment of fixed sagittal imbalance. Surgical technique. *Journal of Bone and Joint Surgery Am*, Vol.26, (March 2004) (1 Suppl), pp. 44-50
- Broom MJ.; & Raycroft, JF. (1988). Complications of fractures of the cervical spine in ankylosing spondylitis. *Spine (Phila, Pa 1976)*, Vol.13, No.7, (July 1988), pp. 763-766
- Calin A. (1985). Ankylosing spondylitis. *Clinics in Rheumatic Diseases*, Vol.11, No.1 (April 1985), Review, pp. 41-60
- Cesur M.; Alici HA.; & Erdem, AF. (2005). An unusual cause of difficult intubation in a patient with a large cervical anterior osteophyte: a case report. *Acta Anaesthesiologica Scandinavica*, Vol.49, No.2, (February 2005), pp. 264-266
- Chin, KR.; & Ahn, J. (2007). Controlled cervical extension osteotomy for ankylosing spondylitis utilizing the Jackson operating table: technical note. *Spine (Phila Pa 1976)*, Vol.32, No.17, (August 2007), pp. 1926-1929
- De Peretti, F.; Sane, JC.; Dran, G.; Razafindratsiva C.; & Argenson C. (2004). Ankylosed spine fractures with spondylitis or diffuse idiopathic skeletal hyperostosis: diagnosis and complications. *Revue de Chirurgie Orthopédique et Réparatrice de l'Appareil Moteur*, Vol.90, No.5, (September 2004), pp. 456-465.
- Deutsch, H.; & Haid Jr, RW. (2008). Cervical ankylosing spondylitis, in Mummaneni PV.; Lenke LG.; & Haid Jr, RW (eds): *Spinal Deformity: A Guide to Surgical Planning and Management*. St. Louis: Quality Medical Publishing, 2008, pp 307-330, ISBN: 978-1-57626-189-7
- Einsiedel, T.; Schmelz, A.; Arand, M.; Wilke, HJ.; Gebhard, F.; Hartwig, E.; Kramer, M.; Neugebauer, R.; Kinzl, L.; & Schultheiss, M. (2006). Injuries of the cervical spine in patients with ankylosing spondylitis: experience at two trauma centers. *Journal of Neurosurgery Spine*, Vol.5, No.1, (July 2006), pp. 33-45.
- Fast, A.; Parikh, S.; & Marin, EL. (1986). Spine fractures in ankylosing spondylitis. *Archives of Physical Medicine and Rehabilitation*, 67:595-597. Sep;67(9):595-597.

- Fox, MW.; Onofrio, BM.; & Kilgore, JE. (1993). Neurological complications of ankylosing spondylitis. *Journal of Neurosurgery*, Vol.78, No.6, (June 1993), pp. 871-878
- Gelman, MI.; & Unger, JS. (1978). Fractures of the thoracolumbar spine in ankylosing spondylitis. *American Journal of Roentgenology*, Vol.130, No.3, (March 1978), pp. 485-491.
- Graham, B.; & Van Peteghem, PK. (1989). Fractures of the spine in ankylosing spondylitis. Diagnosis, treatment, and complications. *Spine (Phila Pa 1976)*, Vol.14, No.8, (August 1989), pp. 803-807
- Hanson, J.; & Mirza, S. (2000). Predisposition for spinal fracture in Ankylosing spondylitis. *American Journal of Roentgenology*, Vol.174, No.1, (January 2000), pp. 150.
- Hitchon, PW.; From, AM.; Brenton, MD.; Glaser, JA.; & Torner, JC. (2002). Fractures of the thoracolumbar spine complicating ankylosing spondylitis. *Journal of Neurosurgery*, Vol.97, (2 Suppl), (September 2002), pp.218-222
- Hitchon, PW.; Torner, J.; Eichholz, KM.; & Beeler, SN. (2006) Comparison of anterolateral and posterior approaches in the management of thoracolumbar burst fractures. *Journal of Neurosurgery Spine*, Vol.5, No.2, (August 2006), pp. 117-125
- Hoh, DJ.; Khoueir, P.; & Wang, MY. (2008). Management of cervical deformity in ankylosing spondylitis. *Neurosurgical Focus*, Vol.24, No.1:E9.
- van der Horst-Bruinsma, IE: Clinical aspects of ankylosing spondylitis. In *Ankylosing Spondylitis. Diagnosis and Management*. Edited by van Royen BJ.; & Dijkmans BAC. New York, London: Taylor and Francis; 2006, pp. 45-70
- Hunter, T.; & Dubo, H. (1978). Spinal fractures complicating ankylosing spondylitis. *Annals of Internal Medicine*, Vol.88, No.4, (April 1978), pp. 546-549
- Juric, S.; Coumas, JM.; Giansiracuse, DF.; & Irwin, RS. (1990). Hemothorax—an unusual presentation of spinal fracture in ankylosing spondylitis. *Journal of Rheumatology*, Vol.17, No.2, (February 1990), pp. 263-266
- Kanter, AS.; Wang, MY.; & Mummaneni, PV. (2008). A treatment algorithm for the management of cervical spine fractures and deformity in patients with ankylosing spondylitis. *Neurosurgical Focus*, Vol.24, No.1, E11
- Kubiak, EN.; Moskovich, R.; Errico, TJ.; & Di Cesare, PE. (2005) Orthopaedic management of ankylosing spondylitis. *Journal of the American Academy of Orthopaedic Surgeons*, Vol.13, No.4, (July-August 2005), pp. 267-78
- Langeloo, DD.; Journee, HL.; Pavlov, PW.; & de Kleuver, M. (2006) Cervical osteotomy in ankylosing spondylitis: evaluation of new developments. *European Spine Journal*, Vol.15, No.4, (April 2006, Epub 2005 June), pp. 493-500
- Law, WA: Osteotomy of the cervical spine. (1959). *Journal of Bone and Joint Surgery Br*, Vol.41, (August 1959), pp. 640-641
- van der Linden, S.; van der Heijde, D.; & Braun, J. (2008). *Ankylosing Spondylitis*. In *Harris: Kelley's Textbook of Rheumatology*. 8th edition. Philadelphia: WB Saunders Co, pp. 1169-1189, ISBN: 978-1-4160-3285-4
- Merton, PA.; & Morton, HB. (1980). Stimulation of the cerebral cortex in the intact human subject. *Nature* Vol.285, No.5762, (May 1980), p. 227
- Mundwiler, ML.; Siddique, K.; Dym, JM.; Perri, B.; Johnson, P.; & Weisman, MH. (2008). Complications of the spine in ankylosing spondylitis with a focus on deformity correction. *Neurosurgical Focus*, Vol.24, No.1, E6, Review

- Nash, CL Jr.; & Brown, RH. (1979). The intraoperative monitoring of spinal cord function: its growth and current status. *The Orthopedic Clinics of North America*, Vol.10, No.4, (October 1979), pp. 919-926
- Olerud, C.; Frost, A.; & Bring, J. (1996). Spinal fractures with ankylosing spondylitis. *European Spine Journal*, Vol.5, No.1, pp. 51-55.
- Osgood, C.; Martin, L.; & Ackerman, E. (1973). Fracture dislocation of the cervical spine with ankylosing spondylitis. *Journal of Neurosurgery*, Vol.39, No.6, (December 1973). pp. 764-769.
- Palm, O.; Moum, B.; Ongre, A.; & Gran, JT. (2002). Prevalence of ankylosing spondylitis and other spondyloarthropathies among patients with inflammatory bowel disease: a population study (the IBSEN study). *Journal of Rheumatology*, Vol.29, No.3, (March 2001), pp. 511-515
- Palmer, AR: Tracheal intubation and cervical injury. (1993). *Canadian Journal of Anaesthesia* Vol.40, May, (5 Pt 1), pp. 470-471
- Rasker, JJ.; Prevo, RL.; & Lanting, PJH. (1996) Spondylodiscitis in ankylosing spondylitis, infection or trauma? A description of six cases. *Scandinavian Journal of Rheumatology*, Vol.25, No.1, pp. 52-57.
- Sapkas, G.; Kateros, K.; Papadakis, SA.; Galanakos, S.; Brilakis, E.; Machairas, G.; Katonis, P. (2009). Surgical outcome after spinal fractures in patients with ankylosing spondylitis. *BMC Musculoskeletal Disorders*, Vol.2, No.10, (August 2009), p. 96
- Schroder, J.; Liljenqvist, U.; Greiner, C.; & Wassmann, H. (2003). Complications of halo treatment for cervical spine injuries in patients with ankylosing spondylitis – report of three cases. *Archives of Orthopaedic and Trauma Surgery* Vol.123, No.(2-3), (April 2003, Epub 2003 Mar 25), pp. 112-114
- Sciubba, DM.; Nelson, C.; Hsieh, P.; Gokaslan, ZL.; Ondra, S.; & Bydon, A. (2008). Perioperative challenges in the surgical management of ankylosing spondylitis. *Neurosurgical Focus*, Vol.24, No.1:E10.
- Serin, E.; Karakurt, L.; Yilmaz, E.; Belhan, O.; & Varol, T. (2004). Effects of two-levels, four-levels, and four-levels plus offset-hook posterior fixation techniques on protecting the surgical correction of unstable thoracolumbar vertebral fractures: a clinical study. *European Journal of Orthopaedic Surgery and Traumatology*, Vol.14, No.1, pp. 1-6.
- Sharma, RR.; & Mathad, NV. (1988). Traumatic spinal fracture in ankylosing spondylitis (a case report). *Postgraduate Medicine*, Vol.34, No.3, (July 1988), pp. 193-195.
- Shimoji, K.; Higashi, H.; & Kano, T. (1971). Epidural recording of spinal electrogram in man. *Electroencephalography and Clinical Neurophysiology*, Vol.30, No.3, (March 1971), pp. 236-239
- Simmons, ED.; DiStefano, RJ.; Zheng, Y.; & Simmons, EH. (2006) Thirty-six years experience of cervical extension osteotomy in ankylosing spondylitis: techniques and outcomes. *Spine (Phila, Pa 1976)*, Vol.31, No.26, (December 2006), pp. 3006-3012
- Surin, V. (1980). Fractures of the cervical spine in patients with ankylosing spondylitis. *Acta Orthopaedica Scandinavica*, Vol.51, No.1, (February 1980), pp. 79-84.
- Taggard, D.; & Traynelis, V. (2000). Management of cervical spinal fractures in ankylosing spondylitis with posterior fixation. *Spine (Phila, Pa 1976)*, Vol.25, No.16, (August 2000), pp. 2035-2039.

- Tamaki, T.; & Kubota, S. (2007). History of the development of intraoperative spinal cord monitoring. *European Spine Journal*, Vol.16, Suppl 2, (November 2007, Epub 2007 Aug) pp. S140-6. 1.
- Tamaki, T.; & Yamane, T. (1975). Proceedings: Clinical utilization of the evoked spinal cord action potential in spine and spinal cord surgery. *Electroencephalography and Clinical Neurophysiology*, Vol.39, No.5, (November 1975), pp. 539
- Tezeren, G.; & Kuru, I. (2005). Posterior fixation of thoracolumbar burst fracture: short-segment pedicle fixation versus long-segment instrumentation. *Journal of Spinal Disorders and Techniques*, Vol.18, No.6, (December 2005), pp. 485-488.
- Thumbikat, P.; Hariharan, RP.; Ravichandran, G.; McClelland, MR.; & Mathew, KM. (2007). Spinal cord injury in patients with ankylosing spondylitis. A 10-Year Review. *Spine (Phila, Pa 1976)*, Vol.32, No.26, (December 2007), pp. 2989-2995.
- Trent, S.; Armstrong, GW.; & O'Neil, J. (1988). Thoracolumbar fractures in ankylosing spondylitis. High-risk injuries. *Clinical Orthopaedics and Related Research*, Vol.227, (February 1988), pp. 61-66.
- Upadhyay, SS.; Ho, EK.; & Hsu, LC. (1991). Positioning for plain spinal radiography producing paraplegia in a patient with ankylosing spondylitis. *British Journal of Radiology*, Vol.64, No.762 (June 1991), pp. 549-551
- Urist, MR. (1958). Osteotomy of the cervical spine; report of a case of ankylosing rheumatoid spondylitis. *Journal of Bone and Joint Surgery Am*, Vol.40, No.4 (July 1958), pp. 833-843
- Vauzelle, C.; Stagnara, P.; & Jouvinroux, P. (1973). Functional monitoring of spinal cord activity during spinal surgery. *Clinical Orthopaedics and Related Research*, Vol.93, (June 1973), pp. 173-178
- Westerveld, LA.; Verlaan, JJ.; & Oner, FC. (2009). Spinal fractures in patients with ankylosing spinal disorders: a systematic review of the literature on treatment, neurological status and complications. *European Spine Journal*, Vol.18, No.2, (February 2009, Epub 2008 Sep 13), pp. 145-156
- Whang, PG.; Goldberg, G.; Lawrence, JP.; Hong, J.; Harrop, JS.; Anderson, DG.; Albert, TJ.; & Vaccaro, AR. (2009). The management of spinal injuries in patients with ankylosing spondylitis or diffuse idiopathic skeletal hyperostosis: a comparison of treatment methods and clinical outcomes. *Journal of Spinal Disorders and Techniques*, Vol.22, No.2, (April 2009), pp. 77-85
- Yau, A.; & Chan, R. (1974). Stress fracture of the fused lumbo-dorsal spine in ankylosing spondylitis. *Journal of Bone and Joint Surgery Br*, Vol.56, No.4, (November 1974), pp. 681-687



Clinical and Molecular Advances in Ankylosing Spondylitis

Edited by Dr. Jacome Bruges-Armas

ISBN 978-953-51-0137-6

Hard cover, 164 pages

Publisher InTech

Published online 22, February, 2012

Published in print edition February, 2012

The first section of the book entitled Clinical and Molecular Advances in Ankylosing Spondylitis is a review of the clinical manifestations of Ankylosing Spondylitis (AS) and Spondyloarthritis (SpA). The book includes chapters on Bone Mineral Density measurements, two chapters on the temporomandibular joints, axial fractures, clinical manifestations, diagnosis, and treatment. Molecular genetics and immune response are analyzed in the second section of the book; information on HLA-B*27, other MHC genes and the immune response of AS patients to bacteria is reviewed and updated. Two chapters are dedicated to recent information on non-MHC genes in AS susceptibility, and to new data on disease pathways generated from gene expression studies on peripheral blood.

How to reference

In order to correctly reference this scholarly work, feel free to copy and paste the following:

Stamatios A. Papadakis, Konstantinos Kateros, Spyridon Galanacos, George Machairas, Pavlos Katonis and George Sapkas (2012). Surgical Treatment After Spinal Trauma in Patients with Ankylosing Spondylitis, Clinical and Molecular Advances in Ankylosing Spondylitis, Dr. Jacome Bruges-Armas (Ed.), ISBN: 978-953-51-0137-6, InTech, Available from: <http://www.intechopen.com/books/clinical-and-molecular-advances-in-ankylosing-spondylitis/surgical-treatment-after-spinal-trauma-in-patients-with-ankylosing-spondylitis>

INTECH

open science | open minds

InTech Europe

University Campus STeP Ri
Slavka Krautzeka 83/A
51000 Rijeka, Croatia
Phone: +385 (51) 770 447
Fax: +385 (51) 686 166
www.intechopen.com

InTech China

Unit 405, Office Block, Hotel Equatorial Shanghai
No.65, Yan An Road (West), Shanghai, 200040, China
中国上海市延安西路65号上海国际贵都大饭店办公楼405单元
Phone: +86-21-62489820
Fax: +86-21-62489821

© 2012 The Author(s). Licensee IntechOpen. This is an open access article distributed under the terms of the [Creative Commons Attribution 3.0 License](#), which permits unrestricted use, distribution, and reproduction in any medium, provided the original work is properly cited.