

# Aquatic Sports Dermatoses: Clinical Presentation and Treatment Guidelines

Jonathan S. Leventhal and Brook E. Tloutan  
NYU School of Medicine, Department of Dermatology New York, NY,  
USA

## 1. Introduction

Aquatic sport dermatoses include a variety of skin conditions that occur in athletes who participate in sporting activities in or on the water. Chemicals and microbes inhabiting the aquatic environment are often responsible for the development of these cutaneous conditions. We review common water sports dermatoses and divide them based on activities that occur in saltwater, freshwater and activities outside the water. Some of the water sports represented in the review include swimming, diving, scuba diving, snorkeling and water polo which are mainly based in the water, as well as sailing, rowing, fishing, surfing, whitewater rafting and water-skiing which are based on the water and outside the water. Aquatic sports dermatoses are presented according to their etiology including infectious and organism-related, contact dermatitis and miscellaneous causes. We also describe conditions specifically associated with water sports including sailing, rowing, fishing and surfing. This comprehensive review focuses on the key recognizable clinical features and principles of management of aquatic sports dermatoses. Our aim is to help sports medicine physicians, dermatologists and other health care providers recognize and treat water sport dermatoses in athletes.

## 2. Freshwater

### 2.1 Infectious and organism-related

#### 2.1.1 Swimming pool granuloma

Swimming pool granuloma, also known as fish tank granuloma or fish fancier's granuloma is caused by infection with atypical mycobacteria, including *Mycobacterium marinum* and *Mycobacterium scrofulaceum*. Swimmers may be infected from exposure to freshwater or saltwater. Fish, dolphins, snails and water fleas are proposed vectors of disease transmission (Hummer *et al.*, 1986).

Clinical presentation. Individuals present with verrucous nodules or plaques that occasionally ulcerate approximately 6 weeks after inoculation. The lesions commonly manifest in the upper extremities, particularly the fingers, and may spread linearly demonstrating a sporotrichoid pattern along the route of lymphatics (Ang *et al.*, 2000; Gluckman, 1995). Diagnosis is best made with biopsy of skin lesions for histopathologic examination and culture. Rare and severe infection may occur from direct extension from the skin to the bones and joints resulting in osteomyelitis, arthritis and tenosynovitis

(Clark *et al.*, 1990; Collins *et al.*, 1988). Disseminated infection typically occurs in immunosuppressed hosts and may be fatal (Tchornobay *et al.*, 1992; King *et al.*, 1983). Management. The first-line treatment includes oral clarithromycin 500 mg twice daily for 6 weeks. Oral minocycline 100 mg twice daily may also be used, but mycobacterial resistance to minocycline has been reported (Adams, 2006).

### 2.1.2 Hot tub folliculitis

Hot tub folliculitis, also known as *Pseudomonas aeruginosa* folliculitis and “splash rash” is an infection caused by *Pseudomonas aeruginosa* after exposure to contaminated water. Swimming pools, showers, baths, hot tubs, saunas and water slides are associated with this condition (Chandrasekar *et al.*, 1984; Fox & Hambrick, 1984; Zichini *et al.*, 2000).

Clinical presentation. Individuals present with follicular-based macules and papulopustules that typically manifest 8–48 hours after exposure with contaminated water (Fox & Hambrick, 1984; Highsmith *et al.*, 1985). The lesions usually heal without scarring, although post-inflammatory hyperpigmentation and desquamation of the skin may occur less commonly. Systemic symptoms occasionally occur and include fever, malaise, sore throat, otalgia, lymphadenopathy, nausea and diarrhea. Rare complications which typically occur in immunosuppressed individuals include abscess formation, ecythma gangrenosum, subcutaneous nodules and cellulitis (Berger *et al.*, 1995; El Baze *et al.*, 1985). Use of a Wood’s lamp may help detect hot tub folliculitis in the early stages by visualizing a pale green fluorescence (Amichai *et al.*, 1994).

Management. In immunocompetent individuals treatment is not required and infection typically resolves spontaneously in less than 2 weeks. Supportive treatment includes acetic acid 5% compresses used for 20 minutes 2-4 times daily for symptomatic relief (Tlougan *et al.*, 2010a). Only in severe cases should the use of antibiotics be considered.

### 2.1.3 Diving suit dermatitis

Diving suit dermatitis is an infection caused by *Pseudomonas aeruginosa* serotypes O:10 and O:6, which are different from the serotypes associated with hot tub folliculitis.

Clinical presentation. Individuals present with erythematous papules that are diffusely scattered on the trunk and extremities. Rarely, systemic symptoms may manifest including fever, headache and malaise (Tlougan *et al.*, 2010a).

Management. First-line treatment consists of oral antibiotics such as ciprofloxacin 500 mg twice daily. Preventive methods include cleaning diving suits with 0.45% lactic acid after each use and showering immediately after diving (Tlougan *et al.*, 2010a).

### 2.1.4 Pitted keratolysis

Pitted keratolysis is an infection caused by *Corynebacterium* or *Kytococcus sedentarius*. This condition is usually seen in individuals who walk barefoot and is associated with excessive sweating (Shelley & Shelley, 1982; Zaias, 1982).

Clinical presentation. Individuals present with superficial pinpoint or ringed erosions with multiple shallow and sharply punched-out (1-3 mm) pits. The lesions have a “dirty” appearance and a foul odor (Tlougan *et al.*, 2010a).

Management. The infection generally responds well to topical or oral erythromycin, topical clindamycin or topical 5% benzoyl peroxide (Pharis *et al.*, 1997). Pitted keratolysis may clear on its own with elimination of excess moisture.

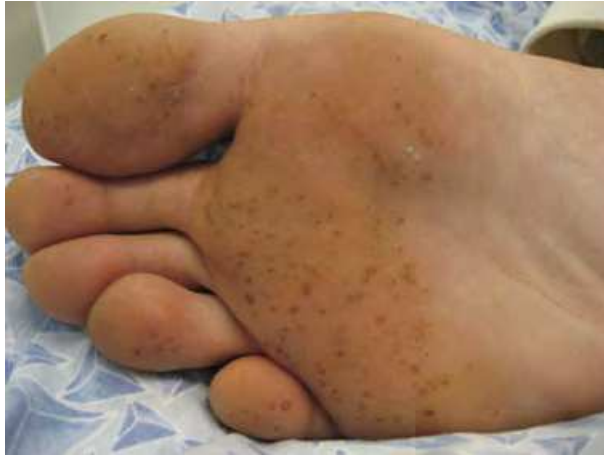

Fig. 1. Pitted keratolysis. Multiple shallow punched-out pits on anterior sole of foot (Tlougan *et al.*, 2010a). Reproduced with permission from *International Journal of Dermatology*.

### 2.1.5 Bikini bottom

Bikini bottom is a deep bacterial folliculitis typically caused by *Streptococcus* or *Staphylococcus aureus*. It usually occurs in swimmers who wear tight-fitted wet swimwear for prolonged periods of time (Saltzer *et al.*, 1997).

Clinical presentation. Individuals present with firm nodules that manifest along the inferior gluteal crease (Basler *et al.*, 1998).

Management. First-line treatment includes a course of oral antibiotics for 10 days, such as Cephalexin (Basler *et al.*, 1998). Prevention of this condition includes prompt removal of wet swimwear.

### 2.1.6 Swimmer's Itch

Swimmer's itch, also known as Schistosome dermatitis, clam-digger's itch or cercarial dermatitis, is caused by infection with larvae from the fluke family Schistosomatidae. The condition typically occurs in swimmers exposed to freshwater, but may also occur in saltwater (Mulvihill & Burnett 1990). Rodents and birds are the primary hosts that release ova containing the immature larvae which mature in snails (Wolf *et al.*, 1995). The larvae infect humans through penetration of the skin and eventually die causing an immunologic reaction and sensitization two weeks after initial contact. Further exposures result in lesions within hours (Wolf *et al.*, 1995).

Clinical presentation. Individuals present with multiple erythematous pruritic papules (3-5 mm) with occasional urticarial plaques (Adams, 2006; Hicks, 1977). Systemic symptoms occur rarely and include fever, chills and lymphadenopathy (Cort, 1950; Wall, 1976).

Management. Lesions typically resolve spontaneously within 3 to 7 days, but topical corticosteroids and antihistamines may help relieve pruritus. Only severe cases require systemic corticosteroids (Adams, 2006).

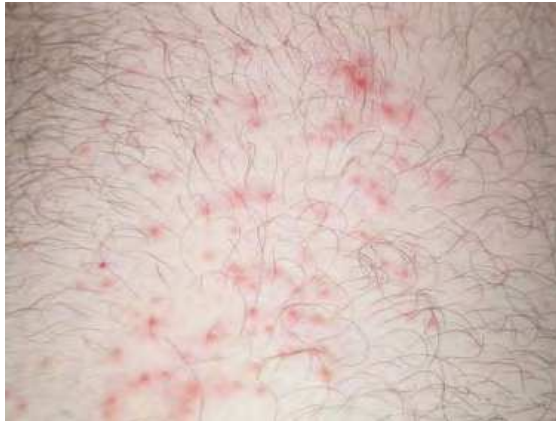

Fig. 2. Swimmer's itch. Scattered erythematous papules on thigh of a swimmer (Tlougan *et al.*, 2010a). Reproduced with permission from *International Journal of Dermatology*.

### 2.1.7 Molluscum contagiosum

Molluscum contagiosum, also known as "water warts" is a cutaneous viral infection caused by the poxvirus *Molluscum contagiosum* (Gottlieb & Myskowski, 1994). Various studies have documented an association between this infection and water exposure (Niizeki *et al.*, 1984; Weismann *et al.*, 1973).

Clinical presentation. Individuals present with pearly-white or skin-colored papules and nodules that may demonstrate a central dimple or umbilication (Tlougan *et al.*, 2010a).

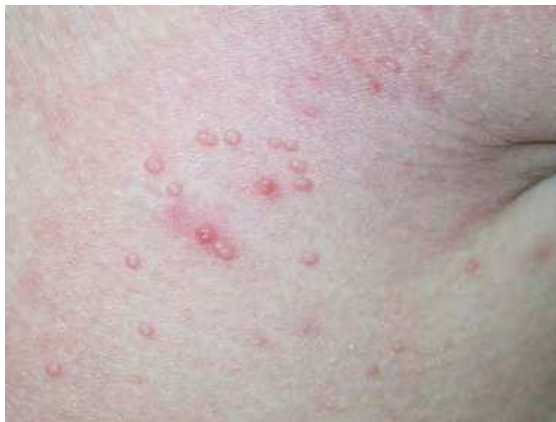

Fig. 3. Molluscum contagiosum. Several 1-2 mm pearly dome-shaped papules with central umbilication (Tlougan *et al.*, 2010a). Reproduced with permission from *International Journal of Dermatology*.

Management. Lesions usually resolve spontaneously without scarring within one year but may persist longer. Therapeutic options to facilitate the resolution of lesions include curettage, liquid nitrogen, trichloroacetic acid and cantharidin. Other off-label options include topical 5-FU or imiquimod (Tlougan *et al.*, 2010a).

### 2.1.8 Warts

Verrucae or warts are caused by human papillomavirus (HPV) and are common in swimmers and individuals that use communal showers (Gentles & Evans, 1973; Johnson, 1995; Penso-Assathiany *et al.*, 1999).

Clinical presentation. Individuals present with well-defined, papillomatous or verrucous papules with a roughened surface. Plantar warts appear as endophytic papules or plaques of the soles with black specs at the center (Tlougan *et al.*, 2010a).

Management. Therapeutic options include mechanical destruction with liquid nitrogen, laser and curettage. Methods of chemical destruction include salicylic acid, cantharidin and trichloroacetic acid. Athletes may apply imiquimod, 5-FU, squaric acid (SADBE) and diphenylcyclopropenone (DPCP) for self-management of these lesions. (Tlougan *et al.*, 2010a). Recalcitrant warts may be treated with injected *Candida antigen*, mumps antigen or bleomycin. (Tlougan *et al.*, 2010a). Oral cimetidine has been shown to be effective in some studies, although its clinical utility remains debated (Orlow & Paller, 1993; Tlougan *et al.*, 2010a).

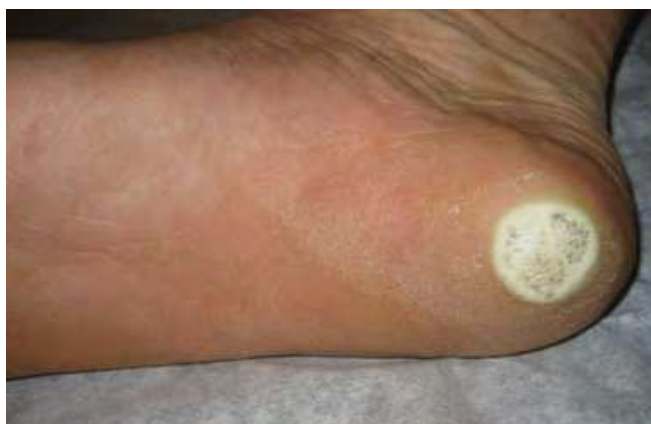

Fig. 4. Verrucae. Plantar wart with roughened surface and black specs at the center (Tlougan *et al.*, 2010a). Reproduced with permission from *International Journal of Dermatology*.

### 2.1.9 Athlete's foot

Athlete's foot, also known as tinea pedis, is a common cutaneous fungal infection caused by dermatophytes. Infection may be transmitted through swimming pools, pool decks and shower floors (Bolanos, 1991; Kamihama *et al.*, 1997).

Clinical presentation. Individuals typically present with the interdigital subtype that manifests as erythema and scaling with or without pruritus. Other clinical forms include the moccasin subtype with plantar erythema, scaling and hyperkeratosis and the inflammatory subtype with painful bullae or pruritic vesicles (Tlougan *et al.*, 2010a).

Management. First-line therapy includes topical antifungal agents used twice daily to affected areas for one to several months. Systemic antifungal agents such as terbinafine 250 mg daily or itraconazole 200 mg daily for 2 weeks may be required for more extensive or refractory lesions. Infection may be prevented by wearing protective sandals in public

showers or pool decks. Athletes may prophylactically apply topical antifungal agents twice weekly to prevent reinfection (Adams, 2006).

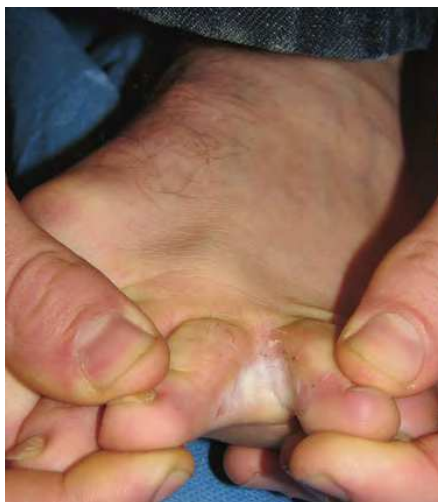

Fig. 5. Athlete's foot. Interdigital subtype of tinea pedis with erythema and scaling between digits (Tlougan *et al.*, 2010a). Reproduced with permission from *International Journal of Dermatology*.

## 2.2 Contact dermatoses

Contact	Dermatosis	Offending Agent
Allergic	Swim goggles dermatitis	dibutylthiourea (rubber accelerator)
	Nose clip & ear plug dermatitis	rubber accelerator compounds
	Diving mask dermatitis	isopropylparaphenylenediamine (IPPD)
	Wet suit dermatitis	diethylthiourea dibutylthiourea diphenylthiourea ethyl butylthiourea para-tertiary-butylphenol-formaldehyde resin
	Swim fin dermatitis	dibutylthiourea diethylthiourea IPPD
	Swim cap dermatitis	mercaptobenzothiazole
	Pool water dermatitis	bromine chlorine potassium peroxymonosulfate (PPMS)
Irritant	Pool dermatitis	bromine chlorine

Table 1. Freshwater contact dermatoses

### 2.2.1 Swimming gear

Athletes may develop contact dermatitis to a variety of components found in swimming gear. Swim goggles, nose clips and ear plugs may result in dermatitis from exposure to rubber accelerators with dibutylthiourea (Azurdia & King, 1998; Cronin & Rubber, 1980; Goette, 1984; Romaguiera *et al.*, 1988). Diving mask dermatitis, also known as scuba diver facial dermatitis, may result from exposure to isopropylparaphenylenediamine (IPPD), a rubber antioxidant in face masks (Maibach, 1975; Maibach, 1975; Tuyp, 1983). Swim fin dermatitis may also occur from contact sensitivity to IPPD, in addition to other components including dibutylthiourea and diethylthiourea (Balestrero *et al.*, 1999; Fisher, 1999). Swim cap dermatitis may result from contact sensitivity to mercaptobenzothiazole (Cronin & Rubber, 1980). Other components of swim gear that may elicit a contact allergy include diphenylthiourea, para-tertiary-butylphenol-formaldehyde resin and ethyl butylthiourea found in swim suits, as well as Tego103G, a disinfectant of wet suits (Boehncke *et al.*, 1997; Munro *et al.*, 1989; Nagashima *et al.*, 2003; Reid *et al.*, 1993).

Clinical presentation. Individuals with swim goggles dermatitis present with pruritic, periorbital erythema with vesicles, and yellow exudative lesions in severe cases (Tlougan *et al.*, 2010a). Diving mask dermatitis presents with redness and pruritus over areas of direct contact (Fisher, 1980; Maibach, 1975; Tuyp, 1983). Individuals with contact dermatitis to swim caps, ear plugs and nose clips present with well-defined, erythematous, scaling plaques and occasionally vesicles over areas in direct contact with the offending agent. Wet suit dermatitis manifests as a pruritic, vesicular or eczematous eruption on the neck, trunk and extremities (Tlougan *et al.*, 2010a).

Management. Mainstay treatment for swim goggle dermatitis includes the use of medium-potency topical corticosteroids, while systemic steroids may be required in severe cases. Topical immunomodulators may also be effective in mild and chronic conditions (Tlougan *et al.*, 2010a). For contact allergies to other types of swim gear described above, avoidance of the offending allergen and use of silicone based gear is recommended (Fisher, 1980; Goette, 1984; Taylor & Rubber, 1986).

### 2.2.2 Pool and pool water dermatitis

Pool dermatitis is an irritant dermatitis to chemicals in swimming pools, particularly chlorine and bromine.

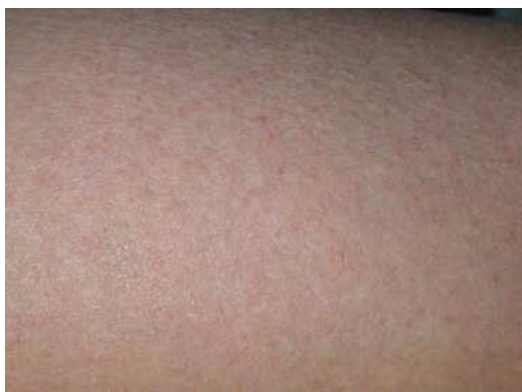

Fig. 6. Pool dermatitis. Eczematous plaques in uncovered areas in a swimmer (Tlougan *et al.*, 2010a). Reproduced with permission from *International Journal of Dermatology*.

One study found that swimmers developed more severe cutaneous eruptions after swimming in brominated pools compared to chlorinated pools (Penny, 1991). In contrast to pool dermatitis, pool water dermatitis is an allergic contact dermatitis to chlorinated or brominated compounds in the water. Potassium peroxymonosulfate (PPMS) which is another decontaminant used in pools and hot tubs may also cause pool water dermatitis (Gilligan *et al.*, 2010).

**Clinical presentation.** Individuals with pool dermatitis present with pruritic, urticarial or eczematous plaques in uncovered areas of skin (Penny, 1991; Rycroft & Penny, 1983). Individuals with pool water dermatitis present with pruritic, erythematous, scaling plaques in uncovered areas of the skin (Fitzgerald *et al.*, 1995; Sasseville *et al.*, 1999).

**Management.** Avoidance of the offending irritant and halogenated water is recommended for sensitized athletes (Penny, 1991). Diligent use of emollients is also imperative.

## **2.3 Miscellaneous**

### **2.3.1 Purpura gogglorum**

Purpura gogglorum or periocular purpura induced by goggles is thought to be caused by collision forces, suction trauma or pressure of the goggles on the periocular soft tissue (Jonasson, 1997; Jowett & Jowett, 1997; Metzger & Berlob, 1992).

**Clinical presentation.** Individuals present with purpura around the eyes.

**Management.** These lesions usually heal spontaneously. In severe cases with vision changes and extensive swelling and facial tenderness, referral to the emergency department to evaluate for possible fracture of facial bones is warranted (Tloughan *et al.*, 2010a).

### **2.3.2 Platform purpura**

Platform purpura is a skin condition that occurs during a missed dive in which the forces upon entering the pool are transmitted to the skin of the thighs (Tloughan *et al.*, 2010a).

**Clinical presentation.** Individuals present with symmetrical, erythematous plaques on the thighs that may be painful (Tloughan *et al.*, 2010a).

**Management.** Supportive care includes nonsteroidal anti-inflammatory drugs and application of warm compresses for 5–10 minutes two or three times daily for pain relief. The lesions typically resolve within a few days (Tloughan *et al.*, 2010a).

### **2.3.3 Aquagenic pruritus**

Aquagenic pruritus occurs after brief exposure to water at any temperature and is associated with mast cell degranulation, elevated blood levels of histamine and local release of acetylcholine in the skin (Greaves, 1992).

**Clinical presentation.** Individuals present with pruritus or a tingling, burning or stinging sensation after exposure to water without any apparent skin changes. The symptoms last between 10 minutes and a couple of hours (Steinman & Greaves, 1985).

**Management.** Phototherapy, particularly PUVA and narrow-band UVB may help relieve pruritus, while some patients may respond to antihistamines (Greaves, 1992; Xifra *et al.*, 2005).

### **2.3.4 Aquagenic, cold and cholinergic urticaria**

Aquagenic urticaria is a rare type of physical urticaria that occurs upon contact with any form of water at any temperature (Hide *et al.*, 2000; Shelley & Rawnsley, 1964). In contrast,



cold urticaria occurs in athletes exposed to cold water and is also associated with winter sports (Sarnaik *et al.*, 1986). While essential acquired cold urticaria is the most common type of cold urticaria, secondary causes include cryoglobulinemia and connective tissue disorders (Sarnaik *et al.*, 1986). Familial cold autoinflammatory syndrome is another condition that manifests with cold urticaria in addition to periodic fever and joint pain (Hoffman *et al.*, 2001). Cholinergic urticaria is the most common subtype of physical urticaria found in athletes, and is typically induced by physical exertion, exposure to heat or emotional stress (Jorizzo, 1987).

**Clinical presentation.** Individuals with aquagenic urticaria present with urticarial wheals on any submerged skin surface shortly after contact with water. Occasionally, only a focal urticarial eruption may occur (Shelley & Rawnsley, 1964). Systemic symptoms occur rarely and include headache and respiratory distress (Baptist & Baldwin, 2005; Luong & Nguyen, 1998). Cold urticaria presents with erythematous, edematous papules along cold-exposed skin surfaces that are very pruritic. Individuals may also present with systemic symptoms including anaphylaxis and loss of consciousness which may result in drowning (Sarnaik *et al.*, 1986). Cold urticaria may be differentiated from aquagenic urticaria by placement of an ice cube on the forearm for several minutes, with resulting development of a square urticarial plaque during rewarming of the skin (Blanco *et al.*, 2000). Individuals with cholinergic urticaria typically present initially with itching or burning, with subsequent development of flushing and hives minutes after the onset of physical activity (Jorizzo, 1987). The diagnosis is supported by exercise testing, sauna test or hot bath challenge with a resulting urticarial eruption (Jorizzo, 1987).

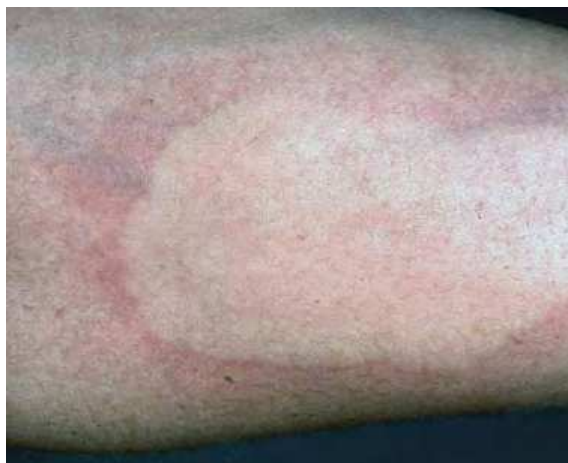

Fig. 7. Cold urticaria. Square urticarial plaque develops after placement of an ice cube on the forearm skin during rewarming of the skin (Tlougan *et al.*, 2010a). Reproduced with permission from *International Journal of Dermatology*.

**Management.** Individuals with aquagenic urticaria may respond to antihistamines and anticholinergic agents. Other alternative treatment options include PUVA and UVB (Juhlin & Malmros-Enander, 1986; Parker *et al.*, 1992). Individuals with cold urticaria generally respond well to antihistamines (Juhlin, 2004; Zuberbier *et al.*, 2006). Health care providers

should also consider secondary causes of cold urticaria including cryoglobulinemia and connective tissue disorders and treat the underlying conditions (Sarnaik *et al.*, 1986). It is recommended that affected athletes wear protective clothing when exposed to cold environments. Traditional therapy for cholinergic urticaria includes antihistamines and leukotriene inhibitors (Otto & Calabria, 2009).

### **2.3.5 Green hair**

Green hair occurs in swimmers with blonde, gray or white hair after exposure to copper in pool water. Frequent hot air drying, brushing, sun exposure, peroxide bleaching and use of alkaline or tar shampoos increases the likelihood of developing green hair (Carson, 1977; Holmes & Goldsmith, 1974).

Clinical presentation. Individuals present with green-colored hair after swimming (Goette, 1978).

Management. Effective treatment options for green hair include 3-5% hydrogen peroxide and copper chelating shampoos (Adams, 2001).

### **2.3.6 Swimmer's shoulder**

Swimmer's shoulder typically occurs during the crawl stroke in which the athlete's chin rubs against the shoulder while turning the head to breathe, with the development of irritation dermatitis (Koehn, 1991).

Clinical presentation. Individuals present with erythematous and slightly roughened plaques on the anterior aspect of the shoulder after swimming (Tlougan *et al.*, 2010a).

Management. Lesions typically heal without treatment, while application of petroleum jelly or polysporin ointment may provide additional relief (Tlougan *et al.*, 2010a).

### **2.3.7 Pool palms**

Pool palms describe a type of frictional dermatitis resulting from repetitive rubbing of the skin surfaces against rough surfaces in the pool (Blauvelt *et al.*, 1992; Wong & Rogers, 2007).

Clinical presentation. Individuals present with symmetric erythematous plaques on the convexities of the palmar hands and fingers (Lacour, 1995).

Management. This condition usually resolves spontaneously after cessation of the irritating activity (Tlougan *et al.*, 2010a).

## **3. Saltwater**

### **3.1 Infectious and organism-related**

#### **3.1.1 Cnidarial dermatoses**

Cnidarial dermatoses result from contact with marine invertebrates of the phylum *Cnidaria*. These organisms contain nematocysts on their tentacles which may pierce the skin and release toxins that may result in cutaneous as well as systemic reactions. Several organisms known to affect water athletes and swimmers include Portuguese man-of-war, jelly fish, sea anemones, fire corals and red sea corals.

Clinical presentation. Individuals stung by Portuguese man-of-war present with pain after the initial sting, followed by development of a pruritic, erythematous, urticarial eruption that subsides after a few days. Violaceous lesions and vesicles occasionally occur, while

systemic symptoms including anaphylaxis are rare (Adams, 2006). Similarly, jellyfish stings present with initial stinging sensation followed by urticarial or papulovesicular lesions in a linear distribution (Burnett, 1992; Currie & Jacups, 2005). Delayed reactions including hyperpigmentation, lipodystrophy, keloid-like scars and erythema nodosum may result, while severe reactions including respiratory distress and cardiac arrest rarely occur (Burnett *et al.*, 1986; Manowitz & Rosenthal, 1979; Tamanaha & Izumi, 1996; Veraldi & Carrera, 2000).

Individuals stung by sea anemones present with an initial stinging or burning sensation with erythema, edema, petechial hemorrhages and ecchymoses. Eventually, an erythematous, papulovesicular eruption develops and local necrosis, ulceration and desquamation may occur (Halstead, 1988). Bathing or showering exacerbates the stinging or burning sensation. Severe side effects include acute renal failure and fulminant hepatic failure (Garcia *et al.*, 1994; Mizuno *et al.*, 2000). Seabather's eruption results from contact with larvae of the adult sea anemone and the thimble jellyfish and presents similarly with systemic symptoms occurring in up to 10% of cases. (Freudenthal & Joseph, 1993; MacSween & Williams, 1996; Sams, 1949; Tomchik *et al.*, 1993).

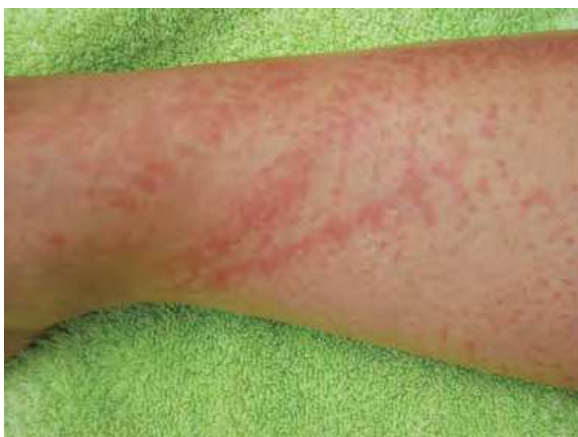

Fig. 8. Jellyfish sting. Linear erythematous plaques, which may be vesicular or urticarial (Tlougan *et al.*, 2010b). Reproduced with permission from *International Journal of Dermatology*.

Individuals stung by the fire coral present with erythematous, burning lesions caused by formic acid on the coral's outer shell. Individuals stung by the red soft coral present with urticarial eruption of the hands and arms with vesicular-bullous lesions, in addition to conjunctivitis, rhinitis and asthma from release of a toxin (Addy, 1991; Canarasa *et al.*, 1993; Fisher, 1999; Miracco *et al.*, 2001; Onizuka *et al.*, 2001).

**Management.** Supportive care for Cnidarial dermatoses includes application of warm compresses, topical corticosteroids and antihistamines for symptomatic relief. Some authors recommend applying sand to the affected areas to facilitate removal of the nematocysts. Severe anaphylactic reactions require epinephrine. Clinicians should consider pain management and tetanus prophylaxis as well (Tlougan *et al.*, 2010b).

For jellyfish stings, application of vinegar may provide relief. Some authors recommend prompt placement of meat tenderizer to help inactive toxins (Freiman *et al.*, 2004). It is important to note that swimmers should not immerse themselves in freshwater after being stung by saltwater Cnidaria because this may activate nematocysts (Tlougan *et al.*, 2010b).

Treatment of fire coral dermatitis includes application of ammonium to neutralize formic acid (Tlougan *et al.*, 2010b).

### 3.1.2 Echinodermata dermatoses

Echinodermata dermatoses result from contact with marine invertebrates from the phylum *Echinodermata*. Organisms which may result in injury to aquatic athletes and swimmers include sea stars, sea urchins and sea cucumbers.

Clinical presentation. Individuals in contact with the spines of seastars may present with puncture wounds and a burning sensation which may persist for one month (Auerbach, 1991). Contact with sea urchin spines may result in a painful puncture wound with surrounding erythema and edema, while broken spines may remain lodged in the skin. Rarely, tenosynovitis and systemic reactions including nausea, syncope and respiratory distress may occur (Baden, 1987). Contact with sea cucumbers may present as a burning irritant dermatitis. The sea cucumber toxin holothurin, a potent cardiac glycoside, may cause a chemical conjunctivitis and even blindness, while ingestion may result in death (Tlougan *et al.*, 2010b).



Fig. 9. Sea urchin spine. Spine punctured through the skin with resulting pain, redness and swelling (Tlougan *et al.*, 2010b). Reproduced with permission from *International Journal of Dermatology*.

Management. Symptomatic relief for individuals affected by seastars and sea urchins includes warm compresses, topical corticosteroids and antihistamines. Anaphylaxis should be promptly treated with epinephrine. Athletes affected by sea cucumbers should immediately irrigate the wound with warm water, soap, vinegar or isopropyl alcohol to rinse off the holothurin toxin. Healthcare providers should treat eye injury with topical anesthesia, irrigation and consultation with an ophthalmologist (Tlougan *et al.*, 2010b).

### 3.1.3 Sponge dermatitis

Marine sponge dermatitis results from contact with marine invertebrates of the phylum *Porifera*. Marine sponges with sharp spicules can cause minor abrasions upon contact with swimmers. In addition, marine sponges may cause an irritant dermatitis as well as local and systemic reactions from the production of crinitoxins by some species (Brown & Shepherd, 1992; Sims & Irei, 1979).

Clinical presentation. Individuals present with a stinging sensation followed by pain, pruritus, and swelling shortly after contact with the organism. Severe effects may result from the crinitoxins with cutaneous manifestations including vesiculations, bullae, desquamation, in addition to delayed allergic contact reactions, erythema multiforme and rarely anaphylaxis (Brown & Shepherd, 1992).

Management. Similar to Cnidarial dermatoses, management includes symptomatic relief as described above and epinephrine for anaphylactic reactions (Tlougan *et al.*, 2010b).

## 3.2 Contact dermatitis

### 3.2.1 Seaweed dermatitis

Seaweed dermatitis is a type of contact dermatitis that results from irritants produced from *Lynghya majuscula*, a blue-green alga that is prevalent in the Pacific, Indian, and Caribbean oceans (Chu, 1959; Osborne *et al.*, 2001).

Clinical presentation. Individuals present with blisters and desquamation with associated stinging, burning, or pruritic sensation within 24 hours after contact (Gauer & Arnold, 1961; Izumi & Moore, 1987). The lesions progress to an erythematous dermatitis that commonly surrounds the perineal and perianal areas lasting for about one week. Ingestion or inhalation of the irritants may result in burning of the upper gastrointestinal tract and respiratory irritation (Anderson *et al.*, 1988; Marshall & Vogt, 1994).

Management. Supportive therapy includes symptomatic relief with cool compresses, treatment with topical corticosteroids, antihistamines and analgesics (Izumi & Moore, 1987).

## 4. On the water

### 4.1 Sailing/rowing

#### 4.1.1 Pulling boat hands

Pulling boat hands is due to a combination of mechanical injury and exposure to cold, and is usually seen in sailors, rowers and crew team members (Toback *et al.*, 1985). There is a strong association between this condition and Raynaud's phenomenon, which causes pallor and numbness of the distal digits with resulting color changes from white to blue to red (Toback *et al.*, 1985).

Clinical presentation. Individuals present with erythematous papules, macules, nodules and blisters that may be painful and pruritic. The lesions typically manifest over the distal dorsal aspect of the hands and proximal phalanges, with sparing of the skin over the metacarpophalangeal (MCP) joints and fingertips (Tlougan *et al.*, 2010c).

Management. The mainstay treatment includes topical corticosteroids, while supportive care includes use of moisturizers, gloves and freshwater soaks (Tlougan *et al.*, 2010c).

#### 4.1.2 Sailor's marks

Sailor's marks are associated with repetitive contact and friction between the rope and hands of sailors, with resulting thickening of the skin (Unal *et al.*, 2005).

Clinical presentation. Individuals present with hyperkeratotic thickening of the superficial skin, with band-shaped calluses that manifest bilaterally on the dorsolateral and palmar regions of the first MCP joint and the mediopalmar site of the fifth MCP joint (Tlougan *et al.*, 2010c).

Management. Prevention of the condition includes wearing protective gloves while sailing (Tlougan *et al.*, 2010c).

#### 4.1.3 Rowing blisters

Rowing blisters result from friction between rower's hands and the oar handles (Rumball *et al.*, 2005).

Clinical presentation. Individuals present with painful blisters that typically manifest on the anterior surfaces of the fingers and palms (Tlougan *et al.*, 2010c).

Management. Treatment consists of supportive care of the blisters by draining the lesions without disruption of the roof of the blister up to three times in the first day, and application of petroleum jelly and occlusive dressing (Tlougan *et al.*, 2010c).

### 4.2 Fishing

#### 4.2.1 Fishing rod dermatitis

Fishing rod dermatitis is a contact dermatitis that results from exposure to isopropylparaphenylenediamine (IPPD) or other closely related components of carbon-fiber fishing rods (Minciullo *et al.*, 2004).

Clinical presentation. Individuals present with unilateral erythematous, scaly hand plaques (Tlougan *et al.*, 2010c).

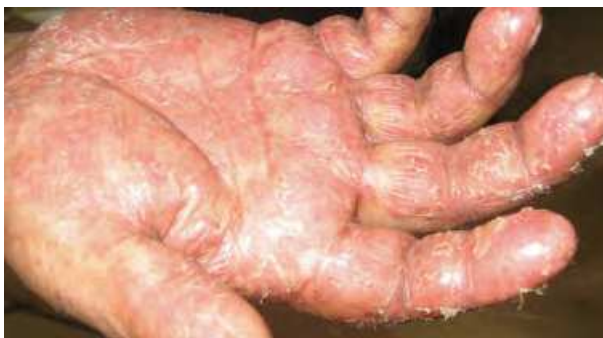

Fig. 10. Fishing rod dermatitis. Erythematous, scaly plaques on the hand (Tlougan *et al.*, 2010c). Reproduced with permission from *International Journal of Dermatology*.

Management. Treatment consists of topical corticosteroids and oral antihistamines. Preventive methods include using a protective cover and insulating tape over the fishing handles and avoidance of IPPD fishing rods (Tlougan *et al.*, 2010c).

#### 4.2.2 Live fish bait allergy

Live fish bait allergy occurs from exposure to the insects and worms used as fish bait. Contact dermatitis may result from exposure to various species of worms such as *Lumbrinereis latreilli*, *Nereis versicolor* and *Chironomus thummi thummi*, as well as larvae of the maggot *Calliphora*

*vomitoria* (Camarasa & Serra-Baldrich, 1993; De Jaegher & Goossens, 1999; Janssens *et al.*, 1995; Usamentiaga *et al.*, 2005; Virgili *et al.*, 2001). Additionally, fisherman may develop allergic contact dermatitis to azo compounds used to dye maggots (Warren & Marren, 1997).

**Clinical presentation.** Individuals typically present with bilateral pruritus and edema of the hands, and occasionally with hyperkeratotic lesions of the thumbs and index fingers (Virgili *et al.*, 2001). Fish bait allergy may cause an urticarial eruption, respiratory reactivity or rhinoconjunctivitis (Bernstein *et al.*, 1983; Siracusa *et al.*, 1994).

**Management.** Individuals gradually improve with avoidance of the offending allergens (Tlougan *et al.*, 2010c).

#### **4.2.3 Erysipeloid**

Erysipeloid, also known as “fish poison”, “shrimp poison”, “crab poison” and “scallop poison” is a bacterial infection of traumatized skin by *Erysipelothrix rhusiopathiae*, mostly seen in fisherman (Burke *et al.*, 2006; Reboli & Farrar, 1989). Infection most commonly results in localized cutaneous disease, while disseminated cutaneous disease and generalized systemic infections may occur as well (Barnett *et al.*, 1983).

**Clinical presentation.** Patients typically present with well-circumscribed, violaceous, edematous plaques on the fingers and hands that are painful and tender to palpation. The lesions generally display central clearing over time and vesicles may develop as well (Gorby & Peacock, 1998; Reboli & Farrar, 1989). Systemic infection may manifest with constitutional symptoms such as fever and malaise, as well as septicemia, arthritis, empyemas, endocarditis and cerebral abscesses (Gorby & Peacock, 1998; Reboli & Farrar, 1989).

**Management.** Mainstay treatment of localized cutaneous and diffuse cutaneous forms of disease includes a one week course of penicillin (Varella & Nico, 2005). Severe systemic reactions require larger doses of penicillin G (Reboli & Farrar, 1989). Erythromycin may be used in individuals with penicillin allergy.

#### **4.2.4 Rubber boot dermatitis**

Rubber boot dermatitis is an allergic contact dermatitis that fisherman develop after exposure to rubber fishing boots (Ross, 1969).

**Clinical presentation.** Individuals present with a diffuse eczematous eruption throughout the leg. If the lesions progress without treatment, a pompholyx-like eruption may manifest on the palms and soles with scaling, thickening, fissures and exfoliation of the skin (Tlougan *et al.*, 2010c).

**Management.** Topical corticosteroids and antihistamines are the mainstay treatment. Oral steroids may be required for severe infections. Prevention includes avoidance of rubber boots in sensitized fisherman (Tlougan *et al.*, 2010c).

### **4.3 Surfing**

#### **4.3.1 Surfer's nodules**

Surfer's nodules are a type of athlete's nodules and occur from repetitive contact and pressure between the surfboard and surfer's bony prominences such as the knees and ankles (Basler., 1989; Erickson & Von Gemmingen, 1967). Some authors also propose that this condition may represent a foreign body reaction to sand or other foreign material (Pharis *et al.*, 1997).

**Clinical presentation.** Individuals usually present with nontender, fibrotic nodules on the pretibial surface of the leg or the mid-dorsum of the foot (Cohen *et al.*, 1990).

Management. Treatment consists of topical keratolytics such as salicylic acid and lactic acid. Other therapeutic modalities include intralesional corticosteroids, topical corticosteroids and excision of the lesions (Adams *et al.*, 2006). Prevention of this condition includes the use of protective padding on the knees and ankles (Cohen *et al.*, 1990).

#### 4.3.2 Surf rider's dermatitis

Surf rider's dermatitis is a type of irritant contact dermatitis that is generally seen in surfers and users of belly boards, boogie boards and body boards. Friction, shearing forces and pressure between the athlete's body and the surfing board contribute to the development of the eruption (Bischof, 1995). Allergic reactions to surfing board polymers and wax may also occur (Tennstedt *et al.*, 1981).

Clinical presentation. Individuals present with painful erythematous and edematous lesions on the nipples. Surfers may also present with small abrasions and fissures (Tloughan *et al.*, 2010c).

Management. The lesions resolve spontaneously without treatment. Supportive care includes analgesics for pain relief as well as protective dressings and soft clothing (Tloughan *et al.*, 2010c).

### 5. Conclusion

Aquatic sports dermatoses consist of a variety of cutaneous conditions that occur in athletes who participate in activities on or in the water. Certain conditions are specifically associated with freshwater or saltwater, while others may occur in both settings. Furthermore, participation in particular sporting activities predisposes athletes to certain dermatoses. The approach to athletes with water-related dermatoses consists of taking an appropriate history to recognize the type of water sport, nature of the water exposure with regards to duration in or on the water, saltwater versus freshwater, and any related equipment or contact with organisms. The etiologies of water-related dermatoses are usually infectious and organism-related or result from contact dermatitis. Our review highlights the key physical findings that are most consistent with particular aquatic sports dermatoses. We discuss first-line treatment guidelines and preventive measures that should help guide healthcare providers in the management of athletes with water-related skin conditions.

### 6. References

- Adams BB. Sports Dermatology. New York, NY: Springer, 2006.
- Adams BB. Skin infections in athletes. *Dermatol Nurs* 2008; 20: 39–44.
- Addy JH. Red sea coral contact dermatitis. *Intl J Derm* 1991; 30: 271–273.
- Amichai E, Finkelstein E, Halevy S. Early detection of pseudomonas infection using a Wood's lamp (letter). *Clin Exp Dermatol* 1994; 19: 449.
- Anderson B, Sims J, Liang A, et al.. Outbreak of eye and respiratory irritation in Lahaina, Maui, possibly associated with *Microcoleus lyngbyaceus*. *J Environ Health* 1988; 50: 205–209.
- Ang P, Rattana-Apiromyakij N, Goh CL. Retrospective study of *Mycobacterium marinum* skin infections. *Int J Dermatol* 2000; 39: 343–347.
- Auerbach PS. Marine envenomations. *N Engl J Med* 1991; 325: 486–493.



- Azurdia RM, King CN. Allergic contact dermatitis due to phenolformaldehyde resin and benzoyl peroxide in swimming goggles. *Contact Derm* 1998; 38: 234-235.
- Baden HP. Injuries from sea urchins. *Clin Dermatol* 1987; 5: 112-117.
- Balestrero S, Cozzani E, Ghigliotti G, et al.. Allergic contact dermatitis from a wet suit. *J Eur Acad Dermatol Venereol* 1999; 13: 228-229.
- Baptist AP, Baldwin JL. Aquagenic urticaria with extracutaneous manifestations. *Allergy and Asthma Proc* 2005; 26: 217-220.
- Barnett JH, Estes AS, Wirman JA, et al.. Erysipeloid. *J Am Acad Dermatol* 1983; 9: 116-123.
- Basler RS. Skin injuries in sports medicine. *J Am Acad Dermatol* 1989; 21: 1257-1262.
- Basler RSW, Basler DL, Basler GC, et al.. Cutaneous injuries in women athletes. *Dermatol Nurs* 1998; 10: 9-18.
- Berger TG, Kaveh S, Becker D, et al.. Cutaneous manifestations of pseudomonas infections in AIDS. *J Am Acad Dermatol* 1995; 32: 279-280.
- Bernstein DI, Gallagher JS, Bernstein IL. Mealworm asthma: clinical and immunologic studies. *J Allergy Clin Immunol* 1983; 72: 475-480.
- Bischof RO. Surf rider's dermatitis. *Contact Derm* 1995; 32: 247.
- Blanco J, Ramirez M, Garcia F, et al.. Localized aquagenic urticaria. *Contact Derm* 2000; 42: 303-304.
- Blauvelt A, Duarte AM, Schachner LA. Pool palms. *J Am Acad Dermatol* 1992; 27: 92.
- Boehncke WH, Wessman D, Zollner TM, et al.. Allergic contact dermatitis from diphenylthiourea in a wet suit. *Contact Derm* 1997; 36: 271.
- Bolanos B. Dermatophyte feet infection among students enrolled in swimming courses at a university pool. *Bol Asoc Med P R* 1991; 83: 181-184.
- Brown CK, Shepherd SM. Marine trauma, envenomation and intoxications. *Emerg Med Clin N Am* 1992; 10: 385-408.
- Burke WA, Griffith DC, Scott CM, et al.. Skin problems related to the occupation of commercial fishing in North Carolina. *N C Med J* 2006; 67: 260-265.
- Burnett JW, Galton GJ, Burnett HW. Jellyfish envenomation syndromes. *J Am Acad Dermatol* 1986; 14: 100-104.
- Burnett JW. Human injuries following jellyfish stings. *Md Med J* 1992; 41: 509-513.
- Burton GRN, et al.. *Microbiology for the Health Sciences*, 5th edn. Philadelphia, PA: JB Lippincott, 1996; 18.
- Camarasa JG, Serra-Baldrich E. Contact urticaria from a worm (*Nereis versicolor*). *Contact Derm* 1993; 28: 248-249.
- Camarasa JG, Nuges AE, Serra-Baldrich E. Red sea coral contact dermatitis. *Contact Derm* 1993; 29: 285-286.
- Carson TE. Green hair. *JAMA* 1977; 238: 1025.
- Chandrasekar PH, Rolston KVI, Kannagara DW, et al.. Hot tub associated dermatitis due to *Pseudomonas aeruginosa*. *Arch Dermatol* 1984; 120: 1337-1340.
- Chu GWTC. Seaweed dermatitis apparently caused by a marine alga. *Laboratory Observations. Proceedings of the 34th Annual Meeting of the Hawaiian Academy of Science*, 1959:19.
- Clark RB, Spector H, Friedman DM, et al.. Osteomyelitis and synovitis produced by *Mycobacterium marinum* in a fisherman. *J Clin Microbiol* 1990; 28: 2570-2572.
- Cohen PR, Eliezri YD, Silvers DN. Athlete's nodules. *Sports Med* 1990; 10: 198-203.


- Collins RJ, Chow SP, Ip FK, et al.. Synovial involvement by *Mycobacterium marinum*. A histopathological study of 25 culture-proven cases. *Pathology* 1988; 20: 340-345.
- Cort WW. Studies on schistosome dermatitis: XI. Status of knowledge after more than twenty years. *Am J Hyg* 1950; 52: 251-307.
- Cronin E. Rubber. In: Cronin E, ed. *Contact Dermatitis*. New York: Churchill Livingstone, 1980: 752.
- Currie BJ, Jacups SP. Prospective study of *Chironex fleckeri* and other box jellyfish stings in the "Top end" of Australia's Northern Territory. *Med J Aust* 2005; 183: 631-636.
- De Jaeger C, Goossens A. Protein contact dermatitis from midge larvae (*Chironomus thummi thummi*). *Contact Derm* 1999; 41: 173.
- El Baze P, Thyss A, Caldani C, et al.. *Pseudomonas aeruginosa* o-II folliculitis. Development into ecthyma gangrenosum in immunosuppressed patient. *Arch Dermatol* 1985; 121: 873-876.
- Erickson JG, Von Gemmingen GR. Surfer's nodules and other complications of surfing. *JAMA* 1967; 201: 134-136.
- Fisher AA. Water-related dermatoses: Part I. *Cutis* 1980; 136: 139-140.
- Fisher AA. Sports-related cutaneous reactions: Part II. Allergic contact dermatitis to sports equipment. *Cutis* 1999; 63: 202-204.
- Fitzgerald DA, Wilkinson SM, Bhaggoe R, et al.. Spa pool dermatitis. *Contact Derm* 1995; 33: 53.
- Folster-Holst R, Disko R, Rowert J, et al.. Cercarial dermatitis contracted via contact with an aquarium: case report and review. *Br J Dermatol* 2001; 145: 638-640.
- Fox AB, Hambrick GW Jr. Recreationally associated *Pseudomonas aeruginosa* folliculitis. *Arch Dermatol* 1984; 120: 1304-1307.
- Freiman A, Barankin B, Elpern DJ. Sports dermatology. Part 2: swimming and other aquatic sports. *CMAJ* 2004; 171: 1339-1341.
- Freudenthal AR, Joseph PR. Seabather's eruption. *N Engl J Med* 1993; 329: 542-544.
- Garcia PJ, Schein RM, Burnett JW. Fulminant hepatic failure from a sea anemone sting. *Ann Intern Med* 1994; 120: 665-666.
- Gauer FH, Arnold HL Jr. Seaweed dermatitis: first report of a dermatitis-producing marine alga. *Arch Dermatol* 1961; 84: 720-732.
- Gentles JC, Evans EG. Foot infections in swimming baths. *Br Med J* 1973; 3: 260-262.
- Gilligan P, Vander Horst A, Zirwas MJ. Allergy to a Hot Tub Water Treatment Chemical: An Unexpectedly Common Cause of Generalized Dermatitis in Men. *J Clin Aesthetic Dermatol* 2010; 3: 54-56.
- Gluckman SJ. *Mycobacterium marinum*. *Clin Dermatol* 1995; 13: 273-276.
- Goette DK. Swimmer's green hair. *Arch Dermatol* 1978; 114: 127-128.
- Goette DK. Raccoon-like periorbital leukoderma from contact with swim goggles. *Contact Derm* 1984; 0: 129-131.
- Gorby GL, Peacock JE Jr. *Erysipelothrix rhusiopathiae* endocarditis: microbiologic, epidemiologic, and clinical features of an occupational disease. *Rev Infect Dis* 1998; 10: 317-318.
- Gottlieb SL, Myskowski PL. *Molluscum contagiosum*. *Int J Dermatol* 1994; 33: 453-461.
- Greaves MW, Handfield-Jones SE. Aquagenic pruritus: pharmacological findings and treatment. *Eur J Dermatol* 1992; 2: 482-484.

- Halstead BW. *Poisonous and Venomous Marine Animals of the World*. Princeton, NJ, USA: Darwin Press, 1988.
- Handzel O, Halperin D. Necrotizing (malignant) external otitis. *Am Fam Physician* 2003; 68: 309-312.
- Harries MJ, Lear JT. Occupational skin infections. *Occup Med (Lond)* 2004; 54: 441-449.
- Headly AW, Knight DE. Scanning sports. *Physician Sports Med* 1976; 4: 102.
- Hicks JH. Swimming and the skin. *Cutis* 1977; 19: 448-450.
- Hide M, Yamamura Y, Sanada S, et al.. Aquagenic urticaria: a case report. *Acta Derm Venereol* 2000; 80: 148-149.
- Highsmith AK, Le PN, Khabbaz RF, et al.. Characteristics of *Pseudomonas aeruginosa* isolated from whirlpools and bathers. *Infect Control* 1985; 6: 407-412.
- Hoffman HM, Wanderer AA, Broide DH. Familial cold autoinflammatory syndrome: phenotype and genotype of an autosomal dominant periodic fever. *J Allergy Clin Immunol* 2001; 108: 615-620.
- Holmes LB, Goldsmith LA. The man with green hair. *N Engl J Med* 1974; 291: 1037.
- Hummer D, Pitlik SD, Block C, et al.. Aquarium-borne *Mycobacterium marinum* skin infection. Report of a case and review of the literature. *Arch Dermatol* 1986; 122: 698-703.
- Izumi AK, Moore RE. Seaweed (*Lyngbya majuscula*) dermatitis. *Clin Dermatol* 1987; 5: 92-100.
- Janssens V, Morren M, Dooms-Goossens A, et al.. Protein contact dermatitis: myth or reality? *Br J Dermatol* 1995; 132: 1-6.
- Johnson LW. Communal showers and the risk of plantar warts. *J Fam Pract* 1995; 40: 136-138.
- Jonasson F. Swimming goggles causing severe eye injuries. *Br Med J* 1997; 1: 881-883.
- Jorizzo JL. Cholinergic urticaria. *Arch Dermatol* 1987; 123: 455-7.
- Jowett NI, Jowett SG. Ocular purpura in a swimmer. *Postgrad Med J* 1997; 73: 819-820.
- Juhlin L, Malmros-Enander I. Familial polymorphous light eruption with aquagenic urticaria: successful treatment with PUVA. *Photo-dermatology* 1986; 3: 346-349.
- Juhlin L. Inhibition of cold urticaria by desloratadine. *J Dermatolog Treat* 2004; 15: 51-59.
- Kamihama T, Kimura T, Hosokawa JI, et al.. Tinea pedis outbreak in swimming pools in Japan. *Public Health* 1997; 111: 249-253.
- King A, Fairley J, Rasmussen J. Disseminated cutaneous *Mycobacterium marinum* infections. *Arch Dermatol* 1983; 119: 268-270.
- Koehn GG. Skin injuries in sports medicine. *J Am Acad Dermatol* 1991; 24: 152.
- Kush BJ, Hoadley AW. A preliminary survey of the association of *Pseudomonas aeruginosa* with commercial whirlpool bath waters. *Am J Public Health* 1980; 70: 279-281.
- Lacour JP, El Baze P, Castanet J, et al.. Diving suit dermatitis caused by *Pseudomonas aeruginosa*: two cases. *J Am Acad Dermatol* 1994; 31: 1055-1056.
- Lacour JP. Dermatitis palmaire juvenile des piscines. *Ann Dermatol Venereol* 1995; 122: 695-696.
- Luong KV, Nguyen LT. Aquagenic urticaria: report of a case and review of the literature. *Ann Allergy Asthma Immunol* 1998; 80: 483-485.
- MacSween RM, Williams HC. Seabather's eruption - a case of Caribbean itch. *Br Med J* 1996; 312: 957-958.

- Maibach H. Scuba diver facial dermatitis: allergic contact dermatitis to N-isopropyl-N-phenylpara-phenylenediamine. *Contact Derm* 1975; 1: 330.
- Manowitz NR, Rosenthal RR. Cutaneous-systemic reactions to toxins and venoms of common marine organisms. *Cutis* 1979; 23: 450-454.
- Mantoux F, Hass H, Lacour JP. Wet suit-related *Pseudomonas aeruginosa* dermatitis in a child. *Pediatr Dermatol* 2003; 20: 458-459.
- Marshall KL, Vogt RL. Illness associated with eating seaweed, Hawaii, 1994. *West J Med* 1998; 169: 293-295.
- Metzer A, Berlob P. Suction purpura. *Arch Dermatol* 1992; 128: 822-824.
- Minciullo PL, Patafi M, Ferlazzo B, et al.. Contact dermatitis from a fishing rod. *Contact Derm* 2004; 50: 322.
- Miracco C, Lalinga AV, Sbano P, et al.. Delayed skin reaction to red sea coral injury showing superficial granulomas and atypical CD30+ lymphocytes: report of a case. *Br J Derm* 2001; 145: 849-851.
- Mizuno M, Nishikawa K, Yuzawa Y, et al.. Acute renal failure after a sea anemone sting. *Am J Kidney Dis* 2000; 36: E10.
- Mulvihill CA, Burnett JW. Swimmer's itch: a cercarial dermatitis. *Cutis* 1990; 46: 211-213.
- Munro CS, Shields TG, Lawrence TM. Contact allergy to Tego 103G disinfectant in a deep-sea diver. *Contact Derm* 1989; 21: 278-279.
- Nagashima C, Tomitaka-Yagami A, Matsunaga K. Contact dermatitis due to para-tertiary-butylphenol-formaldehyde resin in a wetsuit. *Contact Derm* 2003; 49: 267-268.
- Niizeki K, Kano O, Kondo Y. An epidemic study of molluscum contagiosum. Relationship to swimming. *Dermatologica* 1984; 169: 197-198.
- Onizuka R, Kamiya H, Muramoto K, et al.. Purification of the major allergen of red soft coral (*Dendronephthya nipponica*). *Int Arch Allergy Immunol* 2001; 125: 135-143.
- Orlow SJ, Paller A. Cimetidine therapy for multiple viral warts in children. *J Am Acad Dermatol* 1993; 28: 794-6.
- Osborne NJT, Webb PM, Shaw GR. The toxins of *Lyngbya majuscula* and their human and ecological effects. *Environ Int* 2001; 27: 381-392.
- Otto HF, Calabria CW. A case of severe refractory chronic urticaria: a novel method for evaluation and treatment. *Allergy Asthma Proc* 2009; 30: 333-7.
- Parker RK, Crowe MJ, Guin JD. Aquagenic urticaria. *Cutis* 1992; 50: 283-284.
- Penny PT. Hydrotherapy pools of the future - the avoidance of health problems. *J Hosp Infect* 1991; 18(Suppl.1): 535-542.
- Penso-Assathiany D, Flahault A, Roujeau JC. Warts, swimming pools and atopy: a case control study conducted in a private dermatology practice. *Ann Dermatol Venereol* 1999; 126: 696-698.
- Pharis DB, Teller C, Wolf JE Jr. Cutaneous manifestations of sports participation. *J Am Acad Dermatol* 1997; 36: 448-459.
- Reboli AC, Farrar WE. *Erysipelothrix rhusiopathiae*: an occupational pathogen. *Clin Microbiol Rev* 1989; 2: 354-359.
- Reid CM, Van Grutten M, Rycroft RJ. Allergic contact dermatitis from ethylbutylthiourea in neoprene. *Contact Derm* 1993; 28: 193.
- Romaguiera C, Grimalt F, Vilaplana J. Contact dermatitis from swimming goggles. *Contact Derm* 1988; 18: 178-179.

- Ross JB. Rubber boot dermatitis in Newfoundland: a survey of 30 cases. *Can Med Assoc J* 1969; 100: 13-19.
- Rumball JS, Lebrun CM, Di Ciacca SR, et al.. Rowing injuries. *Sports Med* 2005; 35: 537-555.
- Rycroft RJG, Penny PT. Dermatoses associated with brominated swimming pools. *BMJ* 1983; 287: 462.
- Saltzer KR, Schutzer PJ, Weinberg JM, et al.. Diving suit dermatitis: a manifestation of *Pseudomonas folliculitis*. *Cutis* 1997; 59: 245-246.
- Sarnaik AP, Vohra MP, Sturman SW, et al.. Medical problems of the swimmer. *Clin Sports Med* 1986; 5: 47-64.
- Sams WM. Seabather's eruption. *Arch Dermatol Syph* 1949; 60: 227-237.
- Sasseville D, Geoffrion G, Lowry RN. Allergic contact dermatitis from chlorinated swimming pool water. *Contact Derm* 1999; 41: 347-348.
- Sausker WF. *Pseudomonas aeruginosa* folliculitis ("splash rash"). *Clin Dermatol* 1987; 5: 62-67.
- Shelley WB, Rawnsley HM. Aquagenic urticaria: contact sensitivity reaction to water. *JAMA* 1964; 189: 406-408.
- Shelley WB, Shelley ED. Coexistent erythrasma, trichomycosis axillaries, and pitted keratolysis: an overlooked corynebacterial triad? *J Am Acad Dermatol* 1982; 7: 752-757.
- Sims JK, Irei MY. Human Hawaiian marine sponge poisoning. *Hawaii Med J* 1979; 38: 263-270.
- Sinnott JT, Trout T, Berger L. The swimming-pool granuloma that wouldn't heal. *Hosp Pract* 1988; 23: 82-84.
- Siracusa A, Bettini P, Bacocoli R, et al.. Asthma caused by live fish bait. *J Allergy Clin Immunol* 1994; 93: 424-430.
- Spitalny KC, Vogt RL, Witherell LE. National survey on outbreaks associated with whirlpool spas. *Am J Public Health* 1984; 74: 725-726.
- Steinman HK, Greaves MW. Aquagenic pruritus. *J Am Acad Dermatol* 1985; 13: 91-96.
- Taylor JS. Rubber. In: Fisher AA, ed. *Contact Dermatitis*, 3rd edn. Philadelphia: Lea and Febiger, 1986: 603-643.
- Tamanaha RH, Izumi AK. Persistent cutaneous hypersensitivity reaction after a Hawaiian box jellyfish sting (*Carybdea alata*). *J Am Acad Dermatol* 1996; 35: 991-993.
- Tchornobay AM, Claudy AL, Perrot JL, et al.. Fatal disseminated *Mycobacterium marinum* infection. *Int J Dermatol* 1992; 31: 286-287.
- Tennstedt D, Lachapelle JM. Windsurfer dermatitis from black rubber components. *Contact Derm* 1981; 7: 160-161.
- Tloughan BE, Podjasek JO, Adams BB. Aquatic sports dermatoses: Part 1 - In the Water: Freshwater Dermatoses. *Int J Dermatol*. 2010; 49: 874-885
- Tloughan BE, Podjasek JO, Adams BB. Aquatic Sports Dermatoses. Part 2 - In the Water: Saltwater Dermatoses. *Int J Dermatol*. 2010; 49: 994-1002.
- Tloughan BE, Podjasek JO, Adams BB. Aquatic sports dermatoses: Part 3 - On the water. *Int J Dermatol*. 2010; 49: 1111-1120.
- Toback AC, Korson R, Krusinski PA. Pulling boat hands: a unique dermatosis from coastal New England. *J Am Acad Dermatol* 1985; 12: 649-655.
- Tomchik RS, Russell MT, Samant AM, et al.. Clinical perspectives on Seabather's eruption, also known as 'sea lice'. *JAMA* 1993; 269: 1669-1672.

- Tuyp E, Mitchell JC. Scuba diver facial dermatitis. *Contact Derm* 1983; 9: 334-335.
- Unal VS, Sevin A, Dayican A. Palmar callus formation as a result of mechanical trauma during sailing. *Plast Reconstr Surg* 2005; 115: 2161-2162.
- Usamentiaga P, Rodriguez F, Martin-Gil D, et al.. Protein contact dermatitis by fishing bait (*Lumbrinereis latreilli*). *Contact Derm* 2005; 53: 236-237.
- Varella TCN, Nico MMS. Erysipeloid. *Int J Dermatol* 2005; 44: 497-498.
- Veraldi S, Carrera C. Delayed cutaneous reaction to a jellyfish. *Int J Dermatol* 2000; 38: 28-29.
- Virgili A, Ligrone L, Bacilieri S, et al.. Protein contact dermatitis in a fisherman using maggots of a flesh fly as bait. *Contact Derm* 2001; 44: 262-263.
- Walker N. Molluscum contagiosum and its distribution. *Br J Dermatol* 1910; 22: 284-286.
- Wall RC. An analysis of the current status of the schistosome dermatitis problem in Michigan. *Sterkiana* 1976; 1: 63-64.
- Warren LJ, Marren P. Textile dermatitis and dyed maggot exposure. *Contact Derm* 1997; 36: 106.
- Watts RW, Dall RA. An outbreak of *Pseudomonas aeruginosa* folliculitis in women after leg-waxing (letter). *Med J Aust* 1986; 144: 163-164.
- Weismann K. An epidemic of molluscum contagiosum originating in an outdoor public swimming-pool. An analysis of 125 consecutive cases. *Ugeskr Laegr* 1973; 135: 2151-2156.
- Wolf P, Schaffler K, Cerroni L, et al.. Cercarial dermatitis in Styria. *Z Hautkr* 1995; 70: 136-140.
- Wong L, Rogers M. Pool palms. *Pediatr Dermatol* 2007; 24: 95.
- Xifra A, Carrascosa JM, Ferrandiz C. Narrow-band ultraviolet B in aquagenic pruritus. *Br J Derm* 2005; 153: 1233-1234.
- Zaias N. Pitted and ringed keratolysis. *J Am Acad Dermatol* 1982; 7: 787-791.
- Zichichi L, Asta G, Noto G. *Pseudomonas aeruginosa* folliculitis after shower/bath exposure. *Int J Dermatol* 2000; 39: 270-273.
- Zuberbier T, Bindslev-Jensen C, Canonica W, et al. EAACI/GA2LEN/EDF guideline: management of urticaria. *Allergy* 2006; 61: 321-331.



## **An International Perspective on Topics in Sports Medicine and Sports Injury**

Edited by Dr. Kenneth R. Zaslav

ISBN 978-953-51-0005-8

Hard cover, 534 pages

**Publisher** InTech

**Published online** 17, February, 2012

**Published in print edition** February, 2012

For the past two decades, Sports Medicine has been a burgeoning science in the USA and Western Europe. Great strides have been made in understanding the basic physiology of exercise, energy consumption and the mechanisms of sports injury. Additionally, through advances in minimally invasive surgical treatment and physical rehabilitation, athletes have been returning to sports quicker and at higher levels after injury. This book contains new information from basic scientists on the physiology of exercise and sports performance, updates on medical diseases treated in athletes and excellent summaries of treatment options for common sports-related injuries to the skeletal system.

### **How to reference**

In order to correctly reference this scholarly work, feel free to copy and paste the following:

Jonathan S. Leventhal and Brook E. Tlougan (2012). Aquatic Sports Dermatoses: Clinical Presentation and Treatment Guidelines, An International Perspective on Topics in Sports Medicine and Sports Injury, Dr. Kenneth R. Zaslav (Ed.), ISBN: 978-953-51-0005-8, InTech, Available from:  
<http://www.intechopen.com/books/an-international-perspective-on-topics-in-sports-medicine-and-sports-injury/aquatic-sports-dermatoses-clinical-presentation-and-treatment-guidelines>

**INTECH**  
open science | open minds

### **InTech Europe**

University Campus STeP Ri  
Slavka Krautzeka 83/A  
51000 Rijeka, Croatia  
Phone: +385 (51) 770 447  
Fax: +385 (51) 686 166  
[www.intechopen.com](http://www.intechopen.com)

### **InTech China**

Unit 405, Office Block, Hotel Equatorial Shanghai  
No.65, Yan An Road (West), Shanghai, 200040, China  
中国上海市延安西路65号上海国际贵都大饭店办公楼405单元  
Phone: +86-21-62489820  
Fax: +86-21-62489821

© 2012 The Author(s). Licensee IntechOpen. This is an open access article distributed under the terms of the [Creative Commons Attribution 3.0 License](#), which permits unrestricted use, distribution, and reproduction in any medium, provided the original work is properly cited.