

# The Role of Endoscopic Ultrasound to Diagnose, Exclude or Establish the Parenchymal Changes in Chronic Pancreatitis

José Celso Ardengh<sup>1</sup> and Eder Rios Lima-Filho<sup>2</sup>

<sup>1</sup>Endoscopy Unit, Hospital 9 de Julho, São Paulo,

<sup>2</sup>Endoscopy Unit, Division of Surgery and Anatomy, Ribeirão Preto School of Medicine, University of São Paulo, Brazil

## 1. Introduction

Chronic pancreatitis (CP) can be defined as an inflammatory disease with progressive and irreversible morphological changes (1). There is loss of endocrine and / or exocrine function, with or without pain (2-6). The structure is altered by inflammation, necrosis, fibrosis and loss of exocrine and endocrine elements (5,6).

Alcoholism accounts for 70 to 80% of CP ; 10 to 20% are idiopathic and the remaining 5-10% are caused by hypercalcemia, trauma, hereditary diseases, hyperlipidemia (types I, IV and V) or nutritional causes (tropical pancreatitis) (3, 5, 6).

CP is associated with a mortality rate of approximately 50% within 20 to 25 years after its onset (2,6). About 15 to 20% of patients die due to complications associated with attacks of CP, and most of the remaining deaths are due to trauma, malnutrition, infection or smoking (often associated with alcoholism) (2,6). Very little is known about the actual prevalence or incidence of CP, although estimates indicate an incidence of 3.5 to 4 cases per 100.000 (2,6).

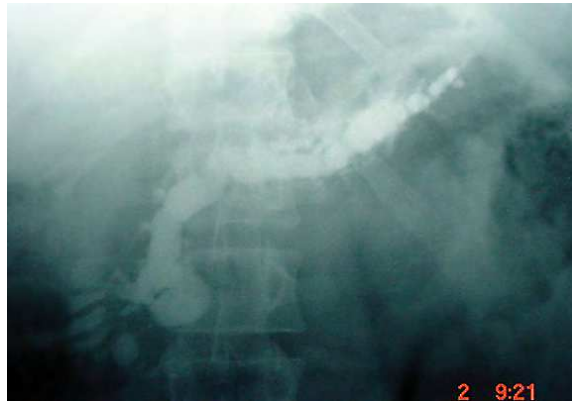## 2. Symptomatology

Clinical presentation of CP is characterized by attacks of pain (1). This is intense, localized in the epigastrium, radiating to the back and may also be present in the right or left hypochondria and be associated with nausea and vomiting (1). Usually lasts for hours, although some patients experience continuous pain for days or weeks (3, 5, 6). Along with the destruction of pancreatic tissue there are signs of endocrine pancreatic insufficiency (impaired glucose tolerance, diabetes mellitus) and / or exocrine (steatorrhea) (3, 5, 6).

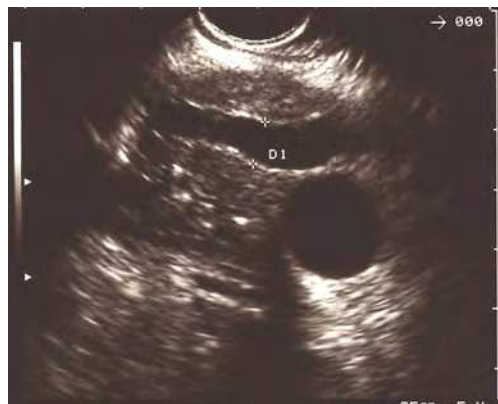## 3. Diagnosis

The diagnosis is based on morphological (abnormalities of pancreatic channels) and functional criteria (pancreatic insufficiency). Although it is easy in advanced forms (Figure 1), in early stages, diagnosis is difficult (7). Ideal diagnostic criteria would be histological (8). However, pancreatic biopsy is susceptible to serious complications, especially in normal or

slightly impaired pancreas. In addition, irregular distribution of lesions can lead to diagnostic errors (false-negative) (8,9).



(a)



(b)

Fig. 1. Image obtained by wirsungography (a): dilation of MPD and secondary branches. It suggests CP. Echoendoscopic image (b) of the same patient. Besides dilatation of main pancreatic duct (MPD), there are hyperechoic streaks, and hypoechoic areas permeating normal parenchyma.

The development of a technique that could be able to detect early morphological abnormalities and besides that could search for specific cellular or CP biochemical markers in pancreatic juice would represent a significant advance in this field (6,9).

#### 4. Imaging

Similar to AP, US is considered the first exam for patients with suspected CP (7). It shows localized or diffuse increase in pancreatic volume, irregularities and dilations of main pancreatic duct (MPD), or cystic collections adjacent to the gland, and pancreatic

calcifications (Figure 2) (2,9-11). Intravenous injection of secretin may be useful in early forms of CP, enhancing discrete changes in MPD caliber (12). Sensitivity and specificity of ultrasound to diagnose CP ranges from 50 to 70% and 80 to 90%, respectively (6, 10, 13).

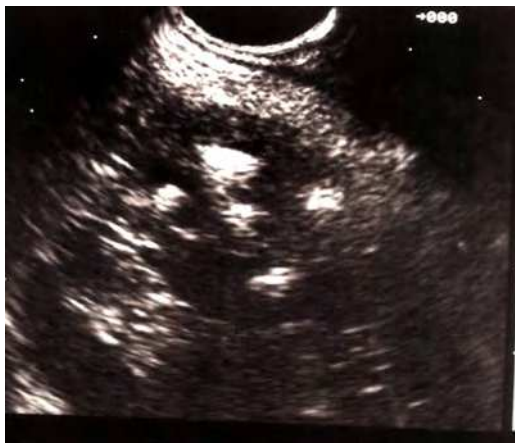

Fig. 2. Echoendoscopic image showing multiple hyperechoic areas with posterior acoustic shadow in a patient with calcifying CP.

A study comparing US, CT and endoscopic retrograde cholangiopancreatography (ERCP) demonstrated that US has a sensitivity of 58% and specificity of 75% to diagnose CP (14). CT is more sensitive and accurate than plain films or US. The suggestive findings of CP include: glandular atrophy, irregularities in pancreatic contours, dilation and irregularities of pancreatic channels with pancreatic calcifications (15). CT is the most sensitive test to detect calcifications and it is still important to search for complications such as pseudocysts. CT sensitivity varies from 74 to 90% and its specificity is over 85% to diagnose CP (2,6). In aforementioned study, CT had a sensitivity of 75% and specificity of 95% (14).

Magnetic resonance imaging (MRI) and magnetic resonance cholangiopancreatography (MRCP) are new non-invasive methods, (no sedation, no contrast, no endoscope insertion). They can obtain images of both parenchyma (MRI) and hepatic and biliary channels (MRCP). They can identify pancreatic atrophy, MPD stenosis or dilation, collateral branches dilation and intracanalicular lesions (16-18).

Our experience is according to literature, and shows that the concordance between MRCP and ERCP varies from 83% to 92% in canalicular dilation, 70% to 92% in canalicular stenosis and 92% to 100% when intracanalicular lesions are present (16, 18, 19). Often, minor abnormalities detectable by ERCP are often undetectable by MRCP and, the rate of false-positive results in canalicular stenosis is high (16,18). Although MRCP is useful to detect moderate and advanced forms of CP, it has a limited value in the early stages (9,18).

Intravenous administration of secretin during MRCP is an alternative to enhance image of MPD in the early stages of CP, as it improves the diagnostic yield (20,21). Image interpretation should be cautious, keeping in mind that artifacts may occur during its reconstruction, leading to a misconception of obstruction, stenosis and stones (21, 22).

ERCP is considered the "gold standard" for diagnosis and treatment of CP (6, 9). Its sensitivity ranges from 74% to 95% and specificity from 90% to 100% (14). A recent study including 202 patients with suspected CP tried to compare the results of ERCP and pancreatic stimulation by secretin-pancreozymin test (TSP), as it is a more sensitive method to assess pancreatic function. The results showed significant correlation between ERCP and TSP, although in 21% of patients, they were discordant and in 15% the results have been contradictory (normal ERCP and abnormal TSP, or vice-versa) (23).

ERCP has some limitations to diagnose CP. Failure in pancreatic channels opacification occurs in 7.5% of cases, particularly when there is an obstruction in the papillary region caused by a stone (9). Invasive nature of ERCP leads to a risk of acute pancreatitis in 5% to 10% of cases, especially in normal or slightly altered pancreas (24). Pancreatography can be normal in 15% of CP and diagnosis is based on clinical course, pancreatic function tests or other imaging methods (6). This occurs more frequently in non-calcified forms of CP (2, 5, 6, 9).

Recently, Tamura et al. (18) compared ERCP to MRI in patients with CP. The authors studied the results of both methods to measure the diameter and characteristics of MPD. The study showed that ERCP tends to overestimate MPD caliber and that MRI is more accurate to define discrete changes in its caliber (18)

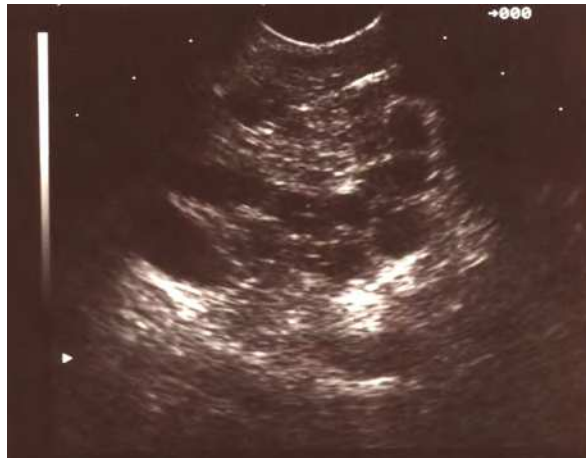## 5. Echoendoscopy

Echoendoscopy can evaluate in detail all the pancreatic parenchyma as well MPD with no fluoroscopy or contrast (25). Moreover, it is a less invasive method and so, unlike ERCP, the patient has no risk of acute pancreatitis. Echoendoscopic criteria for CP are based on parenchyma and canalicular abnormalities (Table 1) (26,27).

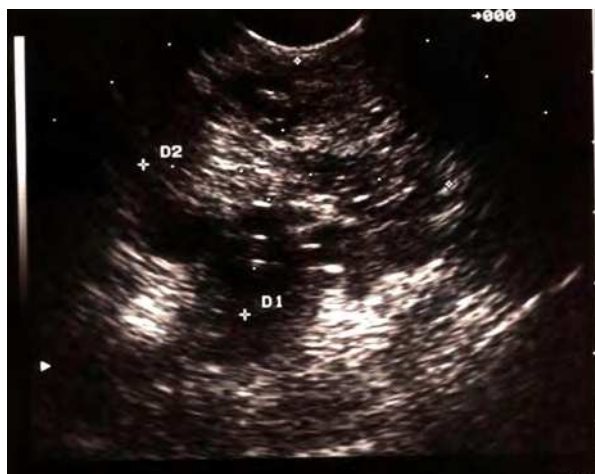Type of change	Catalano et al.		Sahai et al.	
	Parenchyma	Ductal	Parenchyma	Ductal
Echotexture	Heterogeneous	---	---	---
Focus	Echogenic (1 to 3 mm)	---	Hyperechoic	---
Streaks (interlobular septa)	Hyperechoic	---	Hyperechoic	---
Lobulation	Present	---	Present	---
Pancreatic duct				
Diameter	---	> 3 mm	---	Dilated
Appearance	---	Tortuous	---	Irregular
Hyperechoic focus	---	Present	---	---
inside				
Hyperechoic wall	---	---	---	Present
Secondary ducts	---	Ectasia	---	Visible
Calcifications and cysts	> 5mm	---	Present	

Table 1. Echoendoscopic criteria for chronic pancreatitis.

US establishes criteria only in severe CP. There are no criteria for mild and moderate CP (28). Figures 3, 4, 5 and 6 show different echoendoscopic degrees of CP. EE has described new imaging criteria to diagnose CP (29).

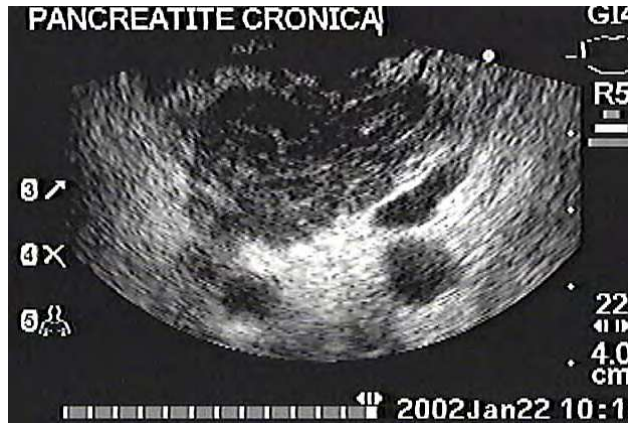

(a)

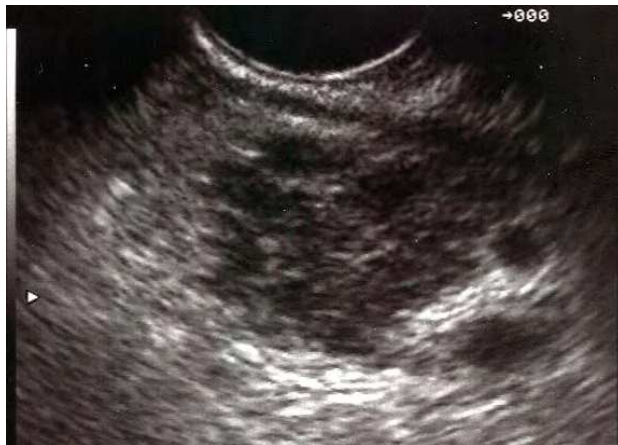

(b)

Fig. 3. Echoendoscopic images in patients with abdominal pain. (a) Hypoechoic areas, intermingled with normal parenchyma and hyperechoic streaks. The aspect remembers a "honeycomb". This aspect suggests early-stage chronic pancreatitis. (b) The same aspect, but more pronounced.

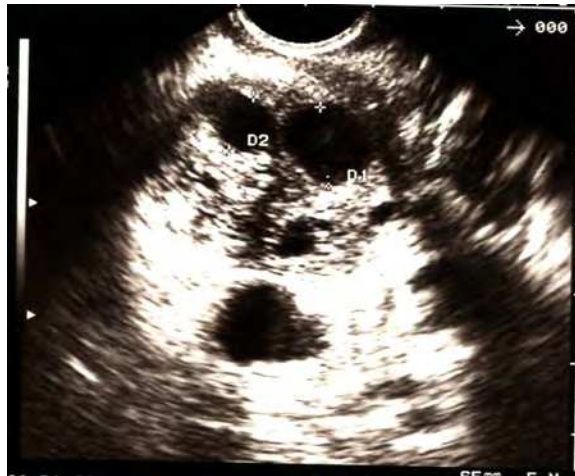

(a)

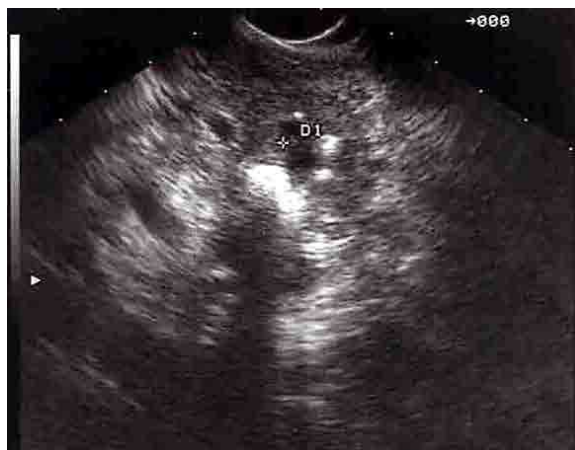

(b)

Fig. 4. Echoendoscopic image of a lobulated pancreatic gland, with hyperchoic striations interspersed with oval hypochoic areas, and discrete posterior hyperchoic enhancement. This aspect suggests moderate CP.

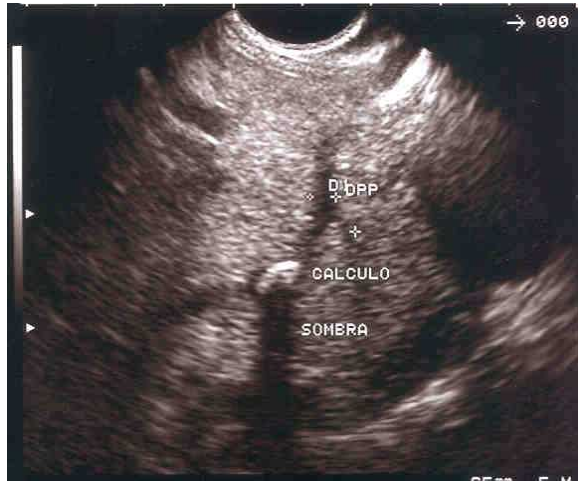


(a)

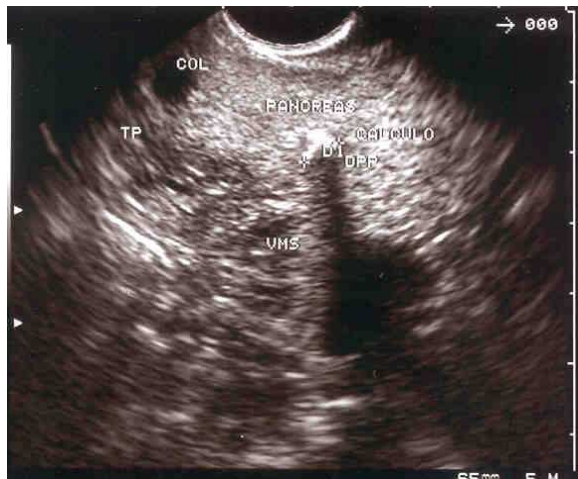

(b)

Fig. 5. Echoendoscopic aspect of calcifying CP. Hyperechoic areas with acoustic shadow and lobular aspect of the gland. (a) dilation of MPD and secondary ducts.



(a)



(b)

Fig. 6. Echoendoscopic images showing MPD with a single stone.



## 6. Echoendoscopy to diagnose early stage chronic pancreatitis

Diagnosis of early stage is a huge challenge. The inability to obtain biopsies makes this presumptive diagnosis difficult. The available diagnostic imaging methods do not offer greater benefits. EE is a promising diagnostic modality and unlike ERCP does not have the same complication rate. Minimal changes in echotexture are difficult to interpret because there is no gold standard (Figure 7).

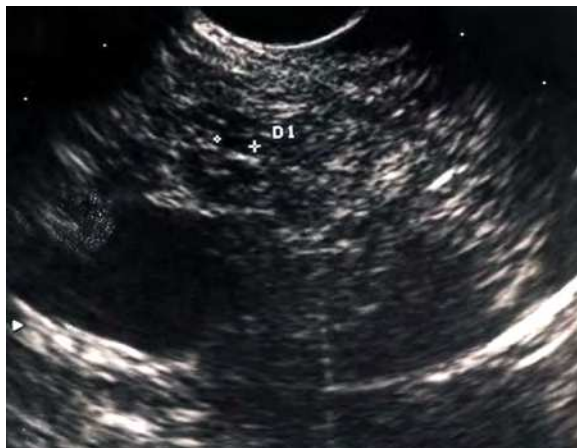

Fig. 7. Echoendoscopic image of pancreas showing parenchymal changes such as: longitudinal hyperechoic streaks, hypoechoic areas, secondary duct dilation and hypoechogenicity of the entire gland.

There is some evidence in the literature suggesting that these early changes may progress to a more advanced disease (30). It is generally accepted that in the absence of all criteria, CP is unlikely, whereas when there is 5 or more of these criteria CP is likely, even when ERCP and pancreatic function tests are normal. Significance of 1-4 criteria is still uncertain, particularly if other diagnostic methods such as ERCP and functional tests are normal (30). In these cases, there is strong evidence of CP, even if these changes detected by EE could not be confirmed by other diagnostic modalities. A question still remains : How can we improve and understand the abnormalities detected by EE when other tests are normal? The answer can only be obtained from studies with more rigorous methodology.

Yusoff & Sahai (31) prospectively studied 1157 patients. The most important predictive factor for parenchymal abnormalities was alcohol intake, male, clinical suspicion of pancreatic disease and smoking. The authors conclude that many variables can change echoendoscopic aspects and severe abnormalities may be found in asymptomatic individuals. The diagnosis of CP by EE needs to be assessed by clinical, functional and histological tests.

In our department we investigated the meaning of echoendoscopic criteria for MPD and parenchyma abnormalities in patients without suspicion of CP compared to chronic alcoholics (alcohol intake exceeding 80g/ day). Two hundred and twenty-eight patients underwent EE. One hundred and eighty-nine were prospectively studied, using criteria of

Catalano et al. (26) and Sahai et al. (27). Alcoholic patients ( $p < 0.001$ ) showed more abnormalities than nonalcoholic for both scores (parenchyma and MPD). Comparison of ROC curve between the two groups showed a better specificity and sensitivity when the two scores were combined (29). Our results demonstrate a correlation between these signals and the disease, but it is important to emphasize that, in our opinion, echo-guided fine needle aspiration can aid diagnosis and, beyond a shadow of doubts, will be the gold standard for diagnosis of CP, particularly in early phase.

## 7. Comparison between EE and ERCP

Three studies compared EE to ERCP in order to correlate ultrasonographic and wirsungography signs with severity of CP. In the first, 35 patients with CP were analyzed. Sixty per cent of patients had a history of alcohol intake. There was clear correlation between alcohol abuse and CP ( $p < 0.05$ ) as well with abnormalities of MPD by EE with ERCP ( $p < 0.01$ ). These authors conclude that EE should be the first line method for diagnosis of parenchymal and MPD abnormalities (32).

In the second study, the sensitivity and specificity of EE were 85%. CP is likely because it has a positive predictive value of 85% when more than two criteria (for all CP) or more than six criteria (for moderate and severe forms) are present. Moderate or severe CP is unlikely when less than three criteria are present (negative predictive value  $> 85\%$ ). Independent predictive factors of CP were: calcifications ( $p = 0.000001$ ), history of alcoholism ( $p = 0.002$ ) and total number of criteria ( $p = 0.008$ ) (27).

In the third study, EE and ERCP were compared with a functional (secretin test) and showed a sensitivity and specificity of 84% and 98% to diagnose CP. Although correlation between EE and ERCP is excellent in normal pancreas or in moderate or advanced forms of CP, in early forms it is poor (26). Another study reported sensitivity and specificity of 87% and 89% to diagnose CP (33).

Another study compared the agreement among 11 experienced echoendoscopists to diagnose CP. There was agreement for a definitive diagnosis of CP (Kappa index = 0.45). Agreement was higher for criteria such as ductal dilatation (kappa = 0.6) and lobular aspect (kappa = 0.51). All other parameters showed poor agreement (kappa  $< 0.4$ ). The authors conclude that EE is reliable to diagnose CP, with good correlation among experienced observers (34).

## 8. Echoendoscopy (EE) alone and associated with fine needle aspiration (FNA-EE)

Hollerbach et al. (8) has recently reported the value of EE with fine needle aspiration puncture (FNAB) to diagnose CP. They concluded that EE is so sensitive and effective as ERCP to detect CP, particularly in early cases. However, echoendoscopic aspects are poor, especially in patients with early disease. EE-FNA is safe and increases negative predictive value of EE. A negative puncture and the absence of echoendoscopic findings of CP could exclude it. It is noteworthy that cytology alone does not increase the specificity of the method, suggesting that tissue collection could impose the use of EE-FNA as a routine to diagnose CP at any stage.

We agree with it.

Patients with CP show another diagnostic difficulty : differential diagnosis between a real pancreatic mass and a pseudotumour. This diagnosis is relatively difficult to make and an accurate diagnosis could avoid unnecessary surgical treatment (35). Several techniques associated with EE have been described for this purpose. The use of Echo-guided Power Doppler for differential diagnosis showed sensitivity and specificity of 93% and 77% respectively (35). The use of contrast agent (Sonovue) seems to increase sensitivity and specificity rates to 91% compared to EE alone versus 73% and 93% vs. 83%, respectively (36). Echo-guided elastography also contributes for diagnosis, but studies are still preliminary and need further confirmation (35).

EE-FNA has a sensitivity, specificity, positive and negative predictive value and accuracy of 87.5%, 100%, 100%, 98.1% and 98.3% respectively, for differential diagnosis between inflammatory mass and CP (37).

## 9. Conclusion

EE has continuously gained importance and has proven to be of clinical value in patients with CP, as it has a low complication rate when compared to ERCP. Some authors indicate EE for examining CP, as it is the imaging method of choice to assess MPD and parenchyma criteria, but there are some limitations. EE has two main limitations that prevent it being the gold standard: the lack of standard criteria for appropriate education and learning (38).

EE is difficult to learn and therefore, teaching has to be standardized. Moreover, a general platform to compare Cambridge criteria is necessary, in order to be accepted as the gold standard to diagnose CP. Except calcifications, the difficulties in assessing some parenchymal criteria depend on differentiation of the natural aging process, the sequelae of pancreatic fibrosis, acute ingestion of alcohol and the advanced stage of CP. Another important point to mention is that the differentiation of hypoechoic (inflammatory x cancer) and cystic lesions (inflammatory x neoplastic) is difficult. In this area, complementary imaging methods have also low sensitivity. Thus there is no doubt that EE has proven to be useful to diagnose CP and its complications (38).

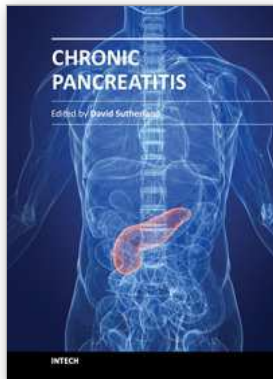
## 10. References

- [1] Kataoka K, Kanemitsu D, Sakagami J, Mitsufuji S, Okanoue T. [Clinical symptoms and diagnostic standards in chronic pancreatitis]. *Nippon Naika Gakkai Zasshi* 2004;93(1):29-37.
- [2] Steer ML, Waxman I, Freedman S. Chronic pancreatitis. *N Engl J Med* 1995;332(22):1482-90.
- [3] Mergener K, Baillie J. Chronic pancreatitis. *Lancet* 1997;350(9088):1379-85.
- [4] Lankisch PG. Progression from acute to chronic pancreatitis: a physician's view. *Surg Clin North Am* 1999;79(4):815-27, x.
- [5] Clain JE, Pearson RK. Diagnosis of chronic pancreatitis. Is a gold standard necessary? *Surg Clin North Am* 1999;79(4):829-45.
- [6] Dimagno MJ, Dimagno EP. Chronic pancreatitis. *Curr Opin Gastroenterol* 2006;22(5):487-497.

- [7] Mayerle J, Stier A, Lerch MM, Heidecke CD. [Chronic pancreatitis. Diagnosis and treatment]. *Chirurg* 2004;75(7):731-47; quiz 748.
- [8] Hollerbach S, Klamann A, Topalidis T, Schmiegell WH. Endoscopic ultrasonography (EUS) and fine-needle aspiration (FNA) cytology for diagnosis of chronic pancreatitis. *Endoscopy* 2001;33(10):824-31.
- [9] Liguory C, Silva MB, de Paulo GA. O Papel da Endoscopia nas Pancreatites Crônicas. In: SOBED, editor. *Endoscopia Digestiva*. 3a ed. Rio de Janeiro: Medsi Editora Médica e Científica Ltda; 2000.
- [10] Niederau C, Grendell JH. Diagnosis of chronic pancreatitis. *Gastroenterology* 1985;88(6):1973-95.
- [11] Bolondi L, Li Bassi S, Gaiani S, Barbara L. Sonography of chronic pancreatitis. *Radiol Clin North Am* 1989;27(4):815-33.
- [12] Glaser J, Mann O, Pausch J. Diagnosis of chronic pancreatitis by means of a sonographic secretin test. *Int J Pancreatol* 1994;15(3):195-200.
- [13] Bastid C, Sahel J, Filho M, Sarles H. Diameter of the main pancreatic duct in chronic calcifying pancreatitis. Measurement by ultrasonography versus pancreatography. *Pancreas* 1990;5(5):524-7.
- [14] Buscail L, Escourrou J, Moreau J, Delvaux M, Louvel D, Lapeyre F, et al. Endoscopic ultrasonography in chronic pancreatitis: a comparative prospective study with conventional ultrasonography, computed tomography, and ERCP. *Pancreas* 1995;10(3):251-7.
- [15] Bearcroft PW, Gimson A, Lomas DJ. Non-invasive cholangio-pancreatography by breath-hold magnetic resonance imaging: preliminary results. *Clin Radiol* 1997;52(5):345-50.
- [16] Takehara Y, Ichijo K, Tooyama N, Kodaira N, Yamamoto H, Tatami M, et al. Breath-hold MR cholangiopancreatography with a long-echo-train fast spin-echo sequence and a surface coil in chronic pancreatitis. *Radiology* 1994;192(1):73-8.
- [17] Cardone G, Di Girolamo M, Messina A, Chichiarelli A, Innacoli M, Di Cesare E, et al. [Magnetic resonance in the study of inflammatory diseases of the pancreas]. *Radiol Med (Torino)* 1995;90(1-2):62-9.
- [18] Tamura R, Ishibashi T, Takahashi S. Chronic pancreatitis: MRCP versus ERCP for quantitative caliber measurement and qualitative evaluation. *Radiology* 2006;238(3):920-8.
- [19] Szejnfeld J, Nakao FS, Araújo I, DiPpolito G, Ferrari AP. MRCP and ERCP: a comparison in 45 patients. *HPB* 1999;1(2):61-64.
- [20] Nicaise N, Pellet O, Metens T, Deviere J, Braude P, Struyven J, et al. Magnetic resonance cholangiopancreatography: interest of IV secretin administration in the evaluation of pancreatic ducts. *Eur Radiol* 1998;8(1):16-22.
- [21] Merkle EM, Baillie J. Exocrine pancreatic function: evaluation with MR imaging before and after secretin stimulation. *Am J Gastroenterol* 2006;101(1):137-8.
- [22] Yamaguchi K, Chijiwa K, Shimizu S, Yokohata K, Morisaki T, Tanaka M. Comparison of endoscopic retrograde and magnetic resonance cholangiopancreatography in the surgical diagnosis of pancreatic diseases. *Am J Surg* 1998;175(3):203-8.
- [23] Lankisch PG, Seidensticker F, Otto J, Lubbers H, Mahlke R, Stockmann F, et al. Secretin-pancreozymin test (SPT) and endoscopic retrograde cholangiopancreatography

- (ERCP): both are necessary for diagnosing or excluding chronic pancreatitis. *Pancreas* 1996;12(2):149-52.
- [24] Cotton PB, Lehman G, Vennes J, Geenen JE, Russell RC, Meyers WC, et al. Endoscopic sphincterotomy complications and their management: an attempt at consensus. *Gastrointest Endosc* 1991;37(3):383-93.
- [25] Ardengh JC, Pauphilet C, Ganc AJ, Colaiacovo W. Endoscopic ultrasonography of the pancreas: technical aspects. *GED* 1994;13(2):61-68.
- [26] Catalano MF, Lahoti S, Geenen JE, Hogan WJ. Prospective evaluation of endoscopic ultrasonography, endoscopic retrograde pancreatography, and secretin test in the diagnosis of chronic pancreatitis. *Gastrointest Endosc* 1998;48(1):11-7.
- [27] Sahai AV, Zimmerman M, Aabakken L, Tarnasky PR, Cunningham JT, van Velse A, et al. Prospective assessment of the ability of endoscopic ultrasound to diagnose, exclude, or establish the severity of chronic pancreatitis found by endoscopic retrograde cholangiopancreatography. *Gastrointest Endosc* 1998;48(1):18-25.
- [28] Irisawa A, Mishra G, Hernandez LV, Bhutani MS. Quantitative analysis of endosonographic parenchymal echogenicity in patients with chronic pancreatitis. *J Gastroenterol Hepatol* 2004;19(10):1199-205.
- [29] Thuler FP, Costa PP, Paulo GA, Nakao FS, Ardengh JC, Ferrari AP. Endoscopic ultrasonography and alcoholic patients: can one predict early pancreatic tissue abnormalities? *Jop* 2005;6(6):568-74.
- [30] Raimondo M, Wallace MB. Diagnosis of early chronic pancreatitis by endoscopic ultrasound. Are we there yet? *Jop* 2004;5(1):1-7.
- [31] Yusoff IF, Sahai AV. A prospective, quantitative assessment of the effect of ethanol and other variables on the endosonographic appearance of the pancreas. *Clin Gastroenterol Hepatol* 2004;2(5):405-9.
- [32] Alempijevic T, Kovacevic N, Duranovic S, Krstic M, Ugljesic M. [Correlation between findings of echosonography and endoscopic retrograde cholangiopancreatography examination in chronic pancreatitis patients]. *Vojnosanit Pregl* 2005;62(11):821-5.
- [33] Wiersema MJ, Hawes RH, Lehman GA, Kochman ML, Sherman S, Kopecky KK. Prospective evaluation of endoscopic ultrasonography and endoscopic retrograde cholangiopancreatography in patients with chronic abdominal pain of suspected pancreatic origin. *Endoscopy* 1993;25(9):555-64.
- [34] Wallace MB, Hawes RH, Durkalski V, Chak A, Mallery S, Catalano MF, et al. The reliability of EUS for the diagnosis of chronic pancreatitis: interobserver agreement among experienced endosonographers. *Gastrointest Endosc* 2001;53(3):294-9.
- [35] Saftoiu A, Popescu C, Cazacu S, Dumitrescu D, Georgescu CV, Popescu M, et al. Power Doppler endoscopic ultrasonography for the differential diagnosis between pancreatic cancer and pseudotumoral chronic pancreatitis. *J Ultrasound Med* 2006;25(3):363-72.
- [36] Hocke M, Schulze E, Gottschalk P, Topalidis T, Dietrich CF. Contrast-enhanced endoscopic ultrasonography in discrimination between focal pancreatitis and pancreatic cancer. *World J Gastroenterol* 2006;12(2):246-50.
- [37] Ardengh JC, Paulo GA, Cury MS, Hervoso CM, Ornellas LC, Lima LFP, et al. The role of endoscopic ultrasound (EUS) with fine needle aspiration (EUS-FNA) in the differential diagnosis of focal chronic pancreatitis (FCP) and pancreatic adenocarcinoma (PAC). *Gastrointest Endosc* 2005;61(5):AB270.

- [38] Jensen C, Dietrich CF. [Endoscopic ultrasound in chronic pancreatitis]. *Z Gastroenterol* 2005;43(8):737-49.



## **Chronic Pancreatitis**

Edited by Prof. David Sutherland

ISBN 978-953-51-0011-9

Hard cover, 138 pages

**Publisher** InTech

**Published online** 15, February, 2012

**Published in print edition** February, 2012

Chronic pancreatitis is a disease of diverse etiologies in which pain can be devastating, severely impairing quality of life, and treatment is a challenge. This book covers cutting edge basic science research and clinical diagnosis and treatment issues in chronic pancreatitis. Basic science chapters include studies on amelioration of chronic pancreatitis in rats by bone marrow derived mesenchymal cells; on gene therapy using HSV-Enkephalin to reduce fibrosis, inflammation and pain in a rats; and on pancreatic acinar and island neogenesis according to vascular and matrix dynamics of human and animal tissue. In regard to the clinical aspects, the role of endoscopic ultrasound in detecting the changes of chronic pancreatitis are addressed as well as the endoscopic treatment via duct drainage procedures or stone removal. Finally, the surgical options for chronic pancreatitis (there are well over 20 procedures) are extensively discussed, with a final chapter on total pancreatectomy and islet autotransplant to definitively remove the root cause of the pain with preservation of endocrine function. This book will be valued by basic scientists and clinicians striving to understand the mechanisms of pain in chronic pancreatitis and the treatment options in patients so afflicted.

### **How to reference**

In order to correctly reference this scholarly work, feel free to copy and paste the following:

José Celso Ardengh and Eder Rios Lima-Filho (2012). The Role of Endoscopic Ultrasound to Diagnose, Exclude or Stablish the Parenchimal Changes in Chronic Pancreatitis, Chronic Pancreatitis, Prof. David Sutherland (Ed.), ISBN: 978-953-51-0011-9, InTech, Available from:

<http://www.intechopen.com/books/chronic-pancreatitis/the-role-of-endoscopic-ultrasound-to-diagnose-exclude-or-stablish-the-parenchimal-changes-in-chronic>

**INTECH**  
open science | open minds

### **InTech Europe**

University Campus STeP Ri  
Slavka Krautzeka 83/A  
51000 Rijeka, Croatia  
Phone: +385 (51) 770 447  
Fax: +385 (51) 686 166  
[www.intechopen.com](http://www.intechopen.com)

### **InTech China**

Unit 405, Office Block, Hotel Equatorial Shanghai  
No.65, Yan An Road (West), Shanghai, 200040, China  
中国上海市延安西路65号上海国际贵都大饭店办公楼405单元  
Phone: +86-21-62489820  
Fax: +86-21-62489821

© 2012 The Author(s). Licensee IntechOpen. This is an open access article distributed under the terms of the [Creative Commons Attribution 3.0 License](#), which permits unrestricted use, distribution, and reproduction in any medium, provided the original work is properly cited.