

Fetal Yawning

Olivier Walusinski

*Family Physician. Private Practice
France*

1. Introduction

The introduction of ultrasound exploration during pregnancy has led to very important conclusions concerning fetal behavioural milestones. For example, the development of oral sensorimotor functions such as swallowing (essential for survival) can be assessed from normal or abnormal neurobehavioral development during the fetal period. While the assessment of these functions takes a long time, another daily behaviour can be detected during an ultrasound examination: yawning. Before the development of real-time imaging techniques, it was impossible to assess facial movements, swallowing and thus yawning. Only the overall movements of the trunk and limbs could be perceived by the mother or by someone touching her belly with their hand. In this chapter, we will show the usefulness of ultrasound in exploring facial mobility, particularly yawning, and in drawing conclusions on harmonious fetal cerebral development.

The phenomenon of yawning is just as intriguing and fascinating as sleep, yet understanding of its causes and consequences has defied the human mind for centuries. Phylogenetically and ontogenetically primitive, this motor behaviour has been remarkably well preserved during evolution and is nearly universal in vertebrates. It appears closer to an emotional stereotypy than to a reflex. Yawning is a stereotyped and often repetitive motor act characterized by gaping of the mouth accompanied by a long inspiration of air or fluid, followed by a brief acme and a short expiration. It is not merely a simple opening of the mouth, but a complex coordinated movement bringing together a flexion followed by an extension of the neck, a wide dilatation of the laryngopharynx with strong stretching of the diaphragm and anti-gravity muscles. Highly stereotypical because no environmental input changes the sequence of movements, it is observed in cold-blooded and warm-blooded vertebrates, from reptiles with rudimentary 'archaic' brains to human primates, in water, air and land environments. The ethology, neurophysiology and neuropsychology literature describes yawning as a transitional behaviour associated with wake/sleep rhythms and hunger/satiety fluctuations, where it externalizes a group of possible vigilance-stimulating mechanisms and attests to the central role of the diencephalon and notably the hypothalamus in homeostasis (Walusinski, 2004; Guggisberg, 2010).

All the movements that a newborn is able to produce originate during the fetal phase and are performed throughout the life span. The fetus exhibits a wide range of behaviours starting with slow flexion and extension of the spine and limbs at around 7 weeks gestation. The variety of movements increases rapidly over the next three to four weeks and many

different movement patterns have been described, including breathing, truncal rotation, limb flexion/extension, sucking and yawning (de Vries, 1982).

2. How to recognize a fetal yawn during ultrasound examination

During ultrasound facial examination, yawning can be seen accidentally. Yawning consists of a slow opening of the mouth with simultaneous downward movements of the tongue and is usually combined with retroflexion of the head. This phase occupies 50 to 75% of the

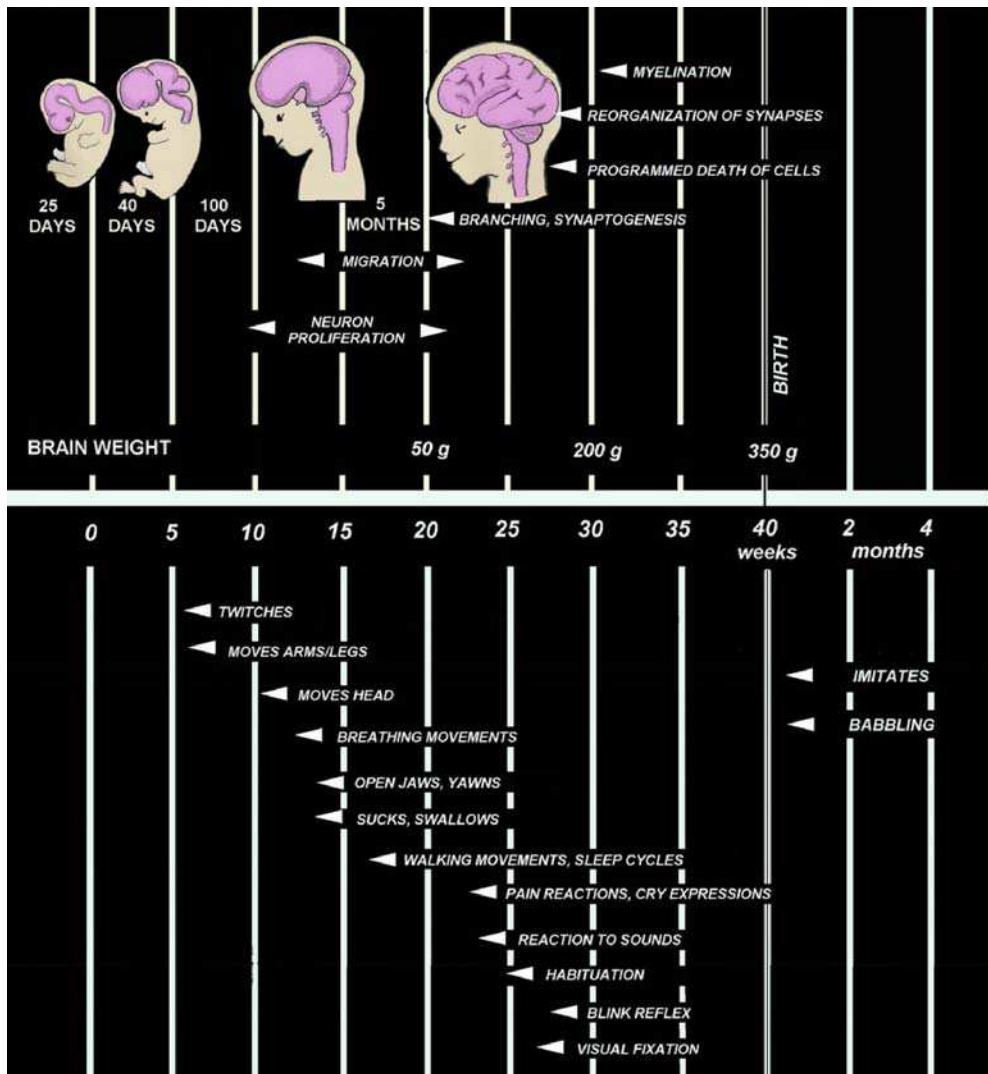


Fig. 1. Development of brain and fetal central nervous system and chronology of the functional development of fetal movements

yawning cycle. After reaching its maximum opening, the mouth remains wide open for 5 to 15 s and returns to its resting closed position within seconds. This harmonious sequence is markedly different from a brief swallowing episode. Using a colour Doppler technique, it is possible to observe the flow of amniotic fluid through the fetal mouth, oropharynx and trachea to the lungs. Contrary to adults, yawning is non-repetitive in the fetus. It is part of a generalized stretch, not just a matter of opening one's mouth. It especially involves the muscles of the respiratory tract (diaphragm, intercostals), face and neck. Fetal yawning can be recognized as one of the movement patterns consistently present starting at around 11-12 weeks of pregnancy (fig. 2). The frequency of yawning gradually increases between 12 and 24 weeks (fig. 3 and 4). During this time, it is possible to observe 40 to 60 yawns per day, and it is the best time to assess yawning with ultrasound examination. A plateau is reached, after which the number of yawns decreases slightly until term. Thus, yawning occurs regularly at a rate of about 1 to 3 yawns per hour. It is obviously by chance or after a long investigation that a yawn can be observed. Furthermore, occiput anterior fetal position unfortunately impedes adequate observation of yawning (Sepulveda, 1995; Masuzaki, 1996).

3. Yawning and neurodevelopmental assessments

Yawning is a phylogenetically old, stereotyped phenomenon. Its survival without evolutionary variations suggests a particular importance as far as development. The strong muscular contraction during yawning has a metabolically high cost. If we agree with Darwin's evolutionary propositions, the costs of brain activity must be outweighed by the developmental advantages. Thus, one structural hypothesis is activation of neurotrophins, which leads to a cascade of new synapse formation or recruitment as well as activation through the diencephalon, brainstem and spinal cord. Activity-dependent development has been clearly shown to be one mechanism by which early sensory or motor experience can affect the course of neural development. This mechanism may be a ubiquitous process in brain maturation, by which activity in one brain region can influence development of other regions. Fetal yawning can be seen as a mechanism that influences functional determination of the moving parts of the musculoskeletal system and contributes to joint development and maintenance.

Fetal movements become more regular and coordinated as a result of increased maturation of the nervous system. At the beginning of the third month, the embryo becomes a fetus with the occurrence of the first oral and pharyngeal motor sequences, controlled by neurological brainstem development and the development of the suction-swallowing activity and yawning. Indeed, suction and yawning have the same embryological origin, which shows the importance of the brainstem in the neurophysiological development of oropharyngeal activity coordinated by respiratory, cardiac and digestive regulations, which have the same neuroanatomical location. The cephalic pole comprises an original embryological encephalo-facial and encephalo-cervical segmentation with a strict topographical correspondence: the naso-frontal and premaxillary structures are connected to the forebrain; the maxillo-mandibular and anterior cervical structures are connected to the 41 brainstem and its nerves. The major structures of the brainstem are formed by the 7-8th postconceptional week, although brainstem maturation continues until the 8th postconceptional month. In addition to its many subnuclei, the brainstem gives rise to a variety of descending spinal motor tracts and hosts the nuclei of five cranial nerves (VIII-XII). Formation of the pons begins almost simultaneously, but its maturation is more prolonged. The structures of the pons include cranial nerves V-VIII and the medial

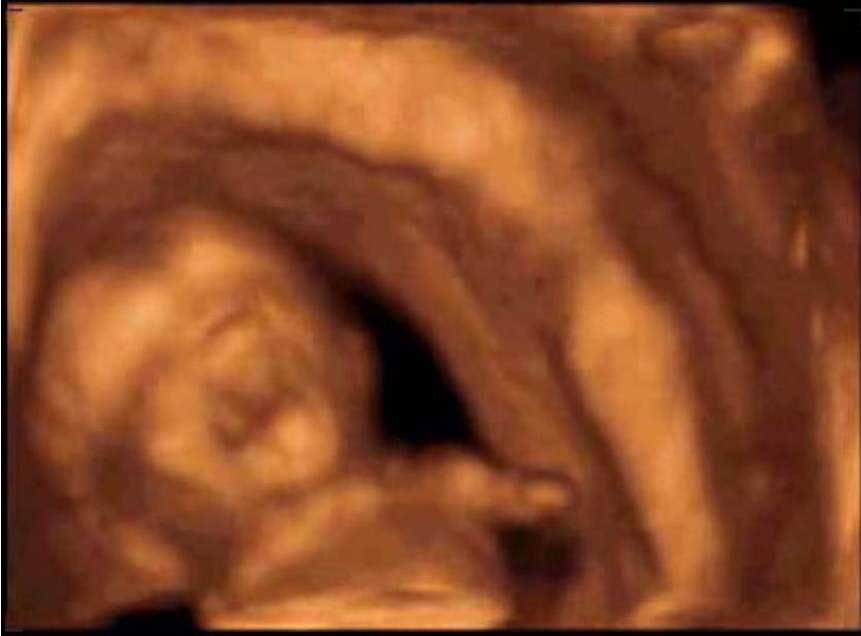

Fig. 2. Fetal yawn at 12 weeks of pregnancy (3D). Fetus weighing 80g

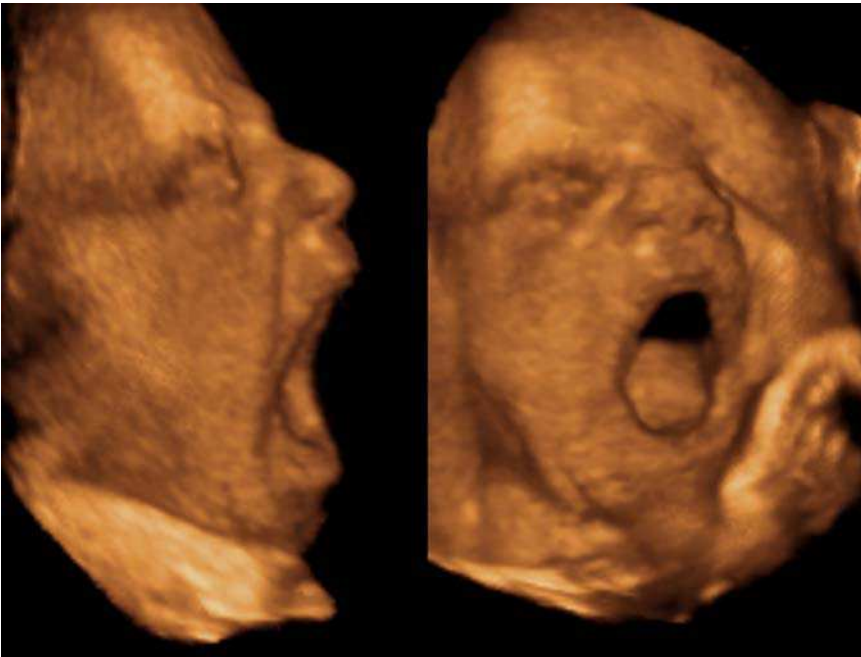

Fig. 3. Fetal yawn at 23 weeks of pregnancy (3D). Fetus weighing 200g

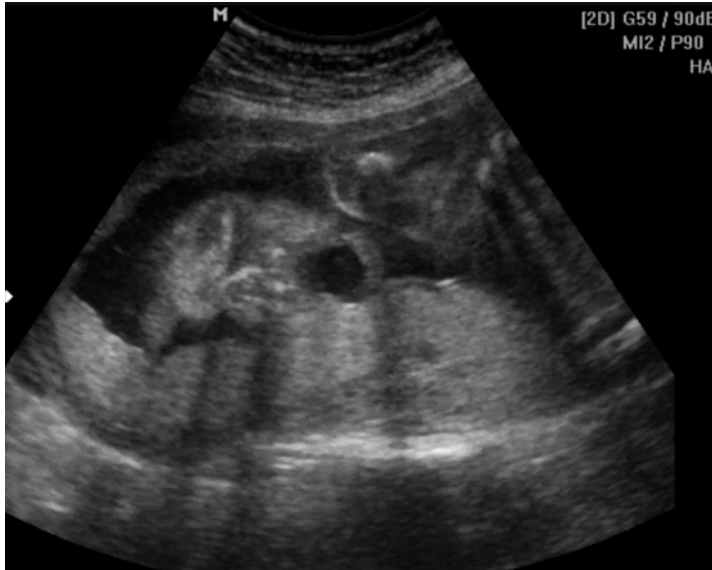

Fig. 4. Fetal yawn at 23 weeks of pregnancy (2D). Fetus weighing 200g

longitudinal fasciculus (MLF), pontine tegmentum, raphe nucleus and locus coeruleus, which exert widespread influence on arousal, including the sleep-wake cycle. Therefore, these structures exert tremendous influence on gross body movements, head turning, heart rate, and respiratory movements, as well as swallowing, yawning, suckling, hiccups, and 7 facial grimacing movements (Santagati, 2003; Kontges, 1996; Jacob, 2000; Sadler, 2009) (Fig. 1).

The emergence of different behavioural states is one of the most significant aspects of early brain maturation in the fetus. In early intra-uterine life, a diffuse collection of phasic and cyclic motor events occur that gradually coalesce. For the fetus, wakefulness and sleep are reliably characterized, respectively, by periods of myoclonic twitching and movements of the limbs against a background of muscle atonia. Periods of twitching are almost always followed by the abrupt onset of high-amplitude, wakeful behaviours. The emergence of distinct states is followed by dramatic changes in the level, duration and cyclicity. An ultradian rhythm may be observed: during a 60 to 90 minute period, there is an alternation of movement characterized by motor activity and movement characterized by rest, as in newborns. The switchover from periods of rest to periods of activity is accompanied by a yawn. Thus, a periodicity of one or two yawns per hour can be seen. Repetitive motions gradually determine the shape and composition of moving structures, as well as their associated neural control pathways. The precociousness and stability of yawning suggest that these characteristics contribute to such development. Furthermore, since a forced inspiration is a critical component of yawning, a potential role for expanding fetal terminal alveoli by the inspired fluid is possible (Marder, 2005).

4. Yawning as a testimony to safe neurological development

In pregnant women, the methods of assessing fetal wellbeing include the biophysical profile; however, this method is limited. Thus, infants must develop safe and effective

respiration and oral feeding skills after birth if they are to survive. For this to occur, infants must have the necessary anatomical structures and adequate central control to coordinate swallowing, ventilation, sleep and arousal. Yawning is associated with all of these behaviours and thus is useful to observe. Fetal facial expressions and movements are known to be an indirect expression of cerebral functional maturity during the fetal period. Facial expressions during this period correspond to facial expression during the neonatal period. Ultrasound has become essential for assessing neurophysiological development as well as detecting anatomical pathology. 4D ultrasound makes it straightforward to comprehend morphological dynamics such as yawning or sucking. As we have seen, yawning can provide information about neurodevelopment and the development of behavioural rhythms (alternation between motor activity, rest and sleep). When fetal activity appears abnormal, nervous system development may be disturbed. Yawning indicates harmonious development of both the brainstem and the peripheral neuromuscular function, testifying to the induction of an ultradian rhythm of vigilance (Rogers, 2005; Einspieler, 2005; Kurjak, 2008). (Ultradian rhythms are recurrent periods or cycles repeated throughout a 24-hour circadian day. In contrast, infradian rhythms, such as the human menstrual cycle, have periods longer than a day. The descriptive term ultradian is used in sleep research in reference to the 90-120 minute cycling of the sleep stages during human sleep).

5. Fetal pathologies assessed by yawning exploration

Yawns recur regularly, about one or two per hour. When a yawn is observed during a 4D US examination, it is obviously by chance or after very long investigation. Yawning appears preferentially after a period of rest, and indicates waking. If normal swallowing is seen (much more frequent), yawning seems of no additional interest with regard to harmonious brainstem maturation. Inversely, the lack or dysfunction of swallowing requires taking the time to understand the set of phasic and cyclic motor events characterizing the ultradian fetal rhythm, thereby increasing the opportunity to observe a yawn. If the ultrasound examination suggests the absence of yawning and swallowing, it is imperative to search for developmental and anatomical abnormalities (van Woerden, 1988).

The lack of fetal yawning, frequently simultaneous to the lack of associated swallowing may be a key to predicting brainstem dysfunction after birth. It is thus imperative to search for mandibular hypoplasia and glossoptosis, often associated with cleft palate (Luedders, 2011; Palit, 2008). For example, Pierre Robin sequence is characterized by a posterior U-shaped cleft palate, retrognathia and glossoptosis. Several arguments favour an embryonic origin consisting of an anomaly in caudal hind brain development. Feeding disorders are the most important functional symptom. Mother testimonies are consistent with the lack of yawning at birth and its progressive appearance during the first year of life, simultaneous to the acquisition of the swallowing reflex necessary for feeding. Pierre Robin syndrome can be seen as the prenatal brainstem dysfunction responsible for orofacial maldevelopment, which can be diagnosed at 23 weeks gestation during a 4D ultrasound examination (Bromley, 1994; Rotten, 2001).

Petrikovsky et al. (1999) report that clusters of yawns were observed in a series of anaemic fetuses and suggest that yawning repetitiveness helps to track fetal anaemia, although fetal yawning has no effect on O₂ pressure. Yawning can be seen as the exteriorization of a homeostatic process, the balance between adrenergic and cholinergic stimulation of the autonomic nervous system. We believe this function is already active in the fetus.

Although no data has actually been collected, we have made a non-exhaustive inventory of congenital pathologies in which yawning research is relevant:

- Mandibular hypoplasia is a frequently encountered craniofacial difference and can be classified into congenital and developmental types:
 - Mandibulofacial dysostosis with a variety of limb abnormalities
- Any syndrome (primary bilateral or unilateral growth anomalies), associated or not with temporo / mandibular joint ankylosis, aglossia / microglossia: Francheschetti syndrome, Goldenhar syndrome, Richner-Hanhart syndrome.
- Moebius syndrome comprises a congenital facial diplegia and bilateral abducens nerve palsies by degenerative and involved nuclei of the VI, VII, and XII nerves. Simultaneous occurrence of limb malformations with cranial nerve dysfunction suggests a disruption of normal morphogenesis during a critical period in embryonic brainstem development, most likely starting at 4 to 7 weeks of gestation. Instances of bilateral paresis of the soft palate and scattered instances of dysphagia (some of which resolve in infancy) have been reported. In this type of functional problem, the inability to close the mouth is constant.
- Watershed infarcts in the fetal and neonatal brainstem are clinically expressed as multiple cranial neuropathies, failure of central respiratory drive and dysphagia.
- Goldenhar Syndrome includes malformations primarily involving the jaw, mouth and ears and, in most cases, affects one side of the body. It represents defects in the embryonic first and second brachial arches, the first pharyngeal pouch and brachial cleft, and the primordia of the temporal bone.
- Joubert syndrome is a rare, genetic disorder characterized by absence or underdevelopment of the cerebellar vermis and a malformed brainstem. The most common features include ataxia, an abnormal breathing pattern, sleep apnea, abnormal eye and tongue movements, and hypotonia.
- It is possible to complete this catalogue by referring to Congenital trismus, Crisponi syndrome, Stüve-Wiedemann syndrome, etc.

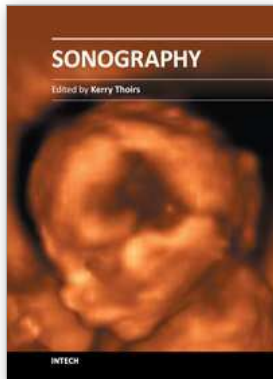
6. Conclusion

An entirely new paradigm has emerged in fetal medicine, given that the advances in prenatal imaging allow one to see and diagnose disease not previously detected. Clinicians can better plan for the delivery of the neonate, with identified anomalies being optimally managed and the impact on the neonate's health minimized. There exists a sound rationale for including systematic observations of spontaneous motor activity in the neurological assessment of fetuses. Yawning, as spontaneous motility linked to brainstem activities, appears to be a good parameter for indicating such wellbeing and harmonious development. Thus, brainstem maturation could be associated with changes in the yawning pattern. A difficult task is qualitative evaluation of general and partial movements in order to distinguish normal from abnormal performance. Yawning is a basic behaviour that is easy to recognize and highly valuable in assessing brainstem activity. It is advisable to include the fetal yawning examination in the systematic week 23 ultrasound scan. Future studies will improve its diagnostic value in detecting neuromuscular developmental abnormalities as well as fetal behavioural abnormalities.

A complete review on yawning can be founded in the book: "The Mystery of Yawning in Physiology and Disease". Walusinski O. ed. Basel. Karger. 2010. 160p.

7. References

- Bromley B, Benacerraf BR. Fetal Micrognathia: Associated Anomalies and Outcome. *J Ultrasound Med.* 1994;13:529-533.
- de Vries JL, Visser GH, Prechtl FM. The emergence of fetal behaviour. *Early Hum Dev* 1982;7:301-322.
- Einspieler C, Prechtl HF. Prechtl's assessment of general movements: a diagnostic tool for the functional assessment of the young nervous system. *Ment Retard Dev Disabil Res Rev.* 2005;11:61-67.
- Guggisberg AG, Mathis J, Schnider A, Hess CW. Why do we yawn? *Neurosci Biobehav Rev.* 2010;34:1267-1276
- Jacob J, Guthrie S. Facial visceromotor neurons display specific rhombomere origin and axon pathfinding behavior. *J Neurosci* 2000;20:7664-7671.
- Kontges G, Lumsden A. Rhombencephalic neural crest segmentation is preserved throughout craniofacial ontogeny. *Development* 1996;122:3229-3242.
- Kurjak A, Tikvica A, Stanojevic M, Miskovic B, Ahmed B, Azumendi G, Di Renzo GC. The assessment of fetal neurobehavior by three-dimensional and four-dimensional ultrasound. *J Matern Fetal Neonatal Med.* 2008;21:675-684.
- Luedders DW, Bohlmann MK, Germer U, Axt-Flidner R, Gembruch U, Weichert J. Fetal micrognathia: objective assessment and associated anomalies on prenatal sonogram. *Prenat Diagn.* 2011;31:1461-51.
- Marder E, Rehm KJ. Development of central pattern generating circuits. *Curr Opin Neurobiol.* 2005;15:86-93.
- Masuzaki H, Masuzaki M. Color Doppler imaging of fetal yawning. *Ultrasound Obstet Gynecol* 1996;8:355-356.
- Palit G, Jacquemyn Y, Kerremans M. An objective measurement to diagnose micrognathia on prenatal ultrasound. *Clin Exp Obstet Gynecol.* 2008;35:121-123.
- Petrikovsky BM, Kaplan GP, Holsten N. Fetal yawning activity in normal and high-risk fetuses: a preliminary observation. *Ultrasound Obstet Gynecol* 1999;13:127-130.
- Rogers B, Arvedson J. Assessment of infant oral sensorimotor and swallowing function. *Ment Retard Dev Disabil Res Rev.* 2005;11:74-82.
- Rose RJ. Prenatal programming of behavior. *Neurosci Biobehav Rev.* 2005;29:321-327.
- Rotten D, Levaillant JM, Martinez H., Ducou le Pointe H, Vicaut E. The fetal mandible: a 2D and 3D sonographic approach to the diagnosis of retrognathia and micrognathia. *Ultrasound Obstet Gynecol.* 2002;19:122-130.
- Sadler, T.W. Langman's Medical Embriology. Williams & Wilkins, Baltimore. 2009. 414p.
- Santagati F, Rijli F. Cranial neural crest and the building of the vertebrate head. *Nature Rev Neurosci* 2003;4:806-818.
- Sepulveda W, Mangiamarchi M. Fetal yawning. *Ultrasound Obstet Gynecol* 1995;5:57-59.
- van Woerden EE, van Geijn HP, Caron FJ, van der Valk AW, Swartjes JM, Arts NF. Fetal mouth movements during behavioural states 1F and 2F. *Europ J Obstet Gynecol Reprod Biol* 1988;29:97-105.
- Walusinski O, Deputte B. The phylogeny, ethology and nosogeny of yawning. *Rev Neurol* 2004;160:1011-1021.
- Yigiter AB, Kavak ZN. Normal standards of fetal behavior assessed by four-dimensional sonography. *J Matern Fetal Neonatal Med.* 2006;19:707-721.



Sonography

Edited by Dr. Kerry Thoires

ISBN 978-953-307-947-9

Hard cover, 346 pages

Publisher InTech

Published online 03, February, 2012

Published in print edition February, 2012

Medical sonography is a medical imaging modality used across many medical disciplines. Its use is growing, probably due to its relative low cost and easy accessibility. There are now many high quality ultrasound imaging systems available that are easily transportable, making it a diagnostic tool amenable for bedside and office scanning. This book includes applications of sonography that can be used across a number of medical disciplines including radiology, thoracic medicine, urology, rheumatology, obstetrics and fetal medicine and neurology. The book revisits established applications in medical sonography such as biliary, testicular and breast sonography and sonography in early pregnancy, and also outlines some interesting new and advanced applications of sonography.

How to reference

In order to correctly reference this scholarly work, feel free to copy and paste the following:

Olivier Walusinski (2012). Fetal Yawning, Sonography, Dr. Kerry Thoires (Ed.), ISBN: 978-953-307-947-9, InTech, Available from: <http://www.intechopen.com/books/sonography/fetal-yawning>

INTECH

open science | open minds

InTech Europe

University Campus STeP Ri
Slavka Krautzeka 83/A
51000 Rijeka, Croatia
Phone: +385 (51) 770 447
Fax: +385 (51) 686 166
www.intechopen.com

InTech China

Unit 405, Office Block, Hotel Equatorial Shanghai
No.65, Yan An Road (West), Shanghai, 200040, China
中国上海市延安西路65号上海国际贵都大饭店办公楼405单元
Phone: +86-21-62489820
Fax: +86-21-62489821

© 2012 The Author(s). Licensee IntechOpen. This is an open access article distributed under the terms of the [Creative Commons Attribution 3.0 License](#), which permits unrestricted use, distribution, and reproduction in any medium, provided the original work is properly cited.