

Neoadjuvant Chemotherapy for Soft Tissue Sarcoma of the Extremity or Trunk, Gastrointestinal Stromal Tumors, and Retroperitoneal Sarcoma

Lloyd Mack and Walley Temple
*University of Calgary
 Canada*

1. Introduction

Soft tissue sarcomas (STS) are a heterogeneous group of tumors (Table 1) that account for approximately 1% of all adult cancer (Clark et al., 2005). There are more than 50 subtypes that are stratified by their histological appearance, presence or absence of characteristic gene translocations, or sensitivity to chemotherapy. They can be found in nearly any site in the body, but upper and lower extremity soft tissue sarcomas make up approximately 60% of all cases (Zagars et al., 2003). Soft tissue sarcomas of the trunk make up another 10% with retroperitoneal tumors comprising approximately 15% (Stoeckle et al., 2001). Gastrointestinal stromal tumors are the most common mesenchymal tumor of the gastrointestinal tract (Miettinen M & Lasota, J 2006). They can occur anywhere along the gastrointestinal tract but are most commonly found in the stomach (60%) or small intestine (30%). Other sites are quite rare including rectum (3%), colon (1-2%), and esophagus (<1%).

Histology	Subtype
Malignant fibrous histiocytoma	
Liposarcoma	Well-differentiated, myxoid, round cell, pleomorphic
Leiomyosarcoma	
Synovial	Monophasic, biphasic
Fibrosarcoma	
Rhabdomyosarcoma	Embryonal, alveolar, pleomorphic
Malignant peripheral nerve sheath tumor	
Angiosarcoma	Hemangiopericytoma, lymphangiosarcoma
Undifferentiated/ unclassified	
Rare/ miscellaneous	Alveolar soft parts, clear cell, epithelioid, malignant mesenchymal, malignant granular cell, mixed mesodermal, endometrial stromal

Table 1. Common Histologies and Subtypes of Soft Tissue Sarcoma

The incidence rate for soft tissue sarcoma is approximately 6/ 100000/ year (Ferrari et al., 2011). Soft tissue sarcomas make up a small fraction of the overall cancer burden. However, it occurs in all ages including young adults so there is a disproportionately high economic impact in a working population. Approximately 3300 to 6000 gastrointestinal stromal tumors are diagnosed annually in the United States with an estimated incidence of 0.68/ 100000/ year (Tran et al., 2005). The true incidence may be higher depending on the proportion of gastrointestinal tumors being tested for c-kit or platelet-derived growth factor receptor alpha (PDGFRA).

The heterogeneity of these tumors presents a challenge in the diagnosis and treatment of soft tissue sarcomas and their relative infrequency limits the ability to conduct meaningful clinical trials. This chapter will focus on neoadjuvant chemotherapy for adult soft tissue sarcomas primarily of the extremity and trunk. Separate sections on retroperitoneal sarcomas and gastrointestinal stromal tumors (GIST) will focus on their unique biology and potential neoadjuvant treatment strategies.

2. Initial assessment

All patients with a suspected soft tissue sarcoma are assessed with a full history concentrating on presenting symptoms such as mass, pain, and neurovascular deficits as well as constitutional symptoms. For suspected STS of the retroperitoneum or for primary GIST, attention is directed to complaints associated with an abdominal mass, early satiety, back pain and the development of lymphedema or leg discomfort as well as symptoms of gastrointestinal hemorrhage and bowel or urinary obstruction. Physical examination includes the chest to rule out obvious findings of metastatic disease such as pleural effusion, abdomen for organomegaly or mass, and evaluation of the involved extremity and draining lymph node basins. For the extremity, assessment of tumor size, determination of whether a mass is mobile and superficial versus fixed and deep to muscular fascia, and an appropriate neurovascular assessment including documentation of limb function is required.

Initial imaging includes plain radiographs of the affected area, chest x-ray and cross-sectional imaging of the mass with either computer tomography (CT) scan or magnetic resonance imaging (MRI). MRI usually gives the most information regarding invasion of important neurovascular structures in STS of the extremity or trunk (Heslin & Smith, 1999). CT is often quite comparable and can assess potential periosteal or bony invasion, although uncommon. CT scan of the chest, abdomen and pelvis is appropriate for the initial evaluation of retroperitoneal tumors and GISTs.

Image or surgeon directed core biopsy obtaining multiple samples generally makes the diagnosis of STS in >90% of cases (Hoeber et al., 2001; Welker et al., 2000). In cases where core biopsy is non-diagnostic, an incisional biopsy is needed and should be performed by an experienced soft tissue oncology surgeon. The incision is made longitudinally on the limb directly over the palpable mass so the biopsy tract or incision can be removed at the time of definitive surgery. Small (≤ 3 cm), superficial soft tissue masses can be removed by excisional biopsy, again using a longitudinal incision with minimal skin flaps, careful hemostasis, and a complete yet minimal margin. GISTs are usually biopsied via an endoscopic approach when in the stomach, duodenum or rectum; or by percutaneous approach or surgery if inaccessible via endoscopy. Retroperitoneal sarcomas are more commonly being diagnosed with image directed core biopsy, especially in centers where a neoadjuvant approach to treatment is considered.

Pathologic assessment is performed by a pathologist experienced in the diagnosis and grading of STS including microscopic evaluation, immunohistochemistry, and cytogenetic and molecular pathologic evaluation as appropriate (Coindre et al., 1988). This may include fluorescent in situ hybridization (FISH) or RT-PCR assessing for recurrent chromosomal translocations which may be present in up to one third of sarcomas. For GIST, c-Kit (CD117 (KIT)) immunohistochemistry staining is positive in 95% of cases (Fletcher et al., 2002). Analysis for known mutations of KIT and PDGF genes may be used in morphologically typical GIST that are CD117 negative. Mitotic count is prognostic and should be expressed as the number of mitoses per 50 high-power fields. Further, mutational analysis has predictive value for sensitivity to molecular targeted therapy.

Staging recommendations include CT chest for extremity or trunk STS and CT chest, abdomen, and pelvis for retroperitoneal sarcoma and GIST subtypes. CT abdomen and pelvis is also employed for some subtypes of STS including myxoid liposarcoma which has a more variable metastatic pattern. Sentinel lymph node biopsy is considered in uncommon histological subtypes of extremity soft tissue sarcoma including clear cell, epithelioid, or angiosarcoma where lymph node metastases are more common (Maduekwe et al., 2009).

3. Local treatment

3.1 Local treatment for soft tissue sarcoma of the extremity or trunk

Level I evidence confirms equivalent outcomes with limb-sparing surgery and adjuvant irradiation compared to amputation or wide excision alone (Pisters et al., 1994; Rosenberg et al., 1982; Yang et al., 1998). The ideal specific combinations of surgery, radiotherapy and possible chemotherapy remain controversial. Multidisciplinary discussions and planning is vital; final treatment recommendations often depend more on location of the tumor and local expertise than overall evidence.

Most centers follow treatment protocols using either pre-operative or post-operative irradiation and limb-sparing, function-preserving surgery for STS. The optimum timing of radiation therapy was evaluated in a randomized control trial that showed no overall differences in local control, disease-free survival or overall survival between treatment arms (O'Sullivan et al., 2002). Wound complications were higher (35% v 17%; $p=0.01$) in the group treated with pre-operative radiation, and were most significant in the lower limb. Those treated with postoperative radiation had better function at 6 weeks post surgery but no significant differences at later time points (Davis et al., 2002). However, there was more late radiation morbidity from fibrosis in the postoperative radiation arm. Significant fibrosis was associated with more joint stiffness and edema adversely affecting patient function (Davis et al., 2005).

Soft tissue sarcomas superficial to muscular fascia or atypical lipomas/ well-differentiated liposarcomas are more often treated with limb-sparing surgery alone with clear microscopic margins (Kooby et al., 2004; Pisters et al., 2007). However, combination of limb sparing surgery and irradiation in some fashion is the standard of care for the majority of soft tissue sarcomas of the extremity or trunk.

3.2 Identification of high-risk soft tissue sarcoma

Important factors predictive of a higher local recurrence for STS include positive margins following resection, presentation with locally recurrent disease, and high grade pathology (Eilber et al., 2003; Pisters et al., 1996). Prognostic factors predictive of systemic recurrence

and death include older age at diagnosis (> 60 years), increasing tumor size (>5, 5 to 10, or > 10 cm), higher tumor grade, depth (deep to muscular fascia) and site (head and neck, abdominal, retroperitoneal and trunk worse than extremity) (Coindre et al., 2001; Kattan et al., 2002; Pisters et al., 1996). In a large series of 1225 patients treated with limb-sparing surgery and radiation for localized STS, the risk of local or distant relapse was highest in the first few years, with approximately two thirds of recurrences by 2 years and more than 90% by 5 years (Zagars et al., 2003). Unfortunately, approximately 50% of those with high risk STS die of their disease. Hence, it is in these high risk sub-groups that the role of chemotherapy is usually explored.

4. Effective chemotherapeutic agents

Doxorubicin is the most active agent in metastatic STS excluding GISTs with response rates from 20-30% (Edmonson et al., 1993; Eriksson 2010). Ifosfamide is the second most commonly used agent with response rates of 15-30%. Combination chemotherapy of doxorubicin and ifosfamide or cyclofosfamide appears to have an increased tumor response in the metastatic setting but the toxicity is similarly increased (Eriksson 2010). A randomized trial is currently enrolling comparing doxorubicin alone versus doxorubicin plus ifosfamide in the metastatic setting (Verschraegen et al., 2010). At present, either doxorubicin or ifosfamide or the combination is considered first line for metastatic soft tissue sarcoma. Similarly, doxorubicin or ifosfamide or the combination is the most common agents used in the adjuvant setting.

Other potential agents for treatment of soft tissue sarcomas in the metastatic setting include dacarbazine or its oral analogue temozolomide (often in the multidrug combination of MAID - mesna, doxorubicin, ifosfamide and dacarbazine), gemcitabine, taxanes such as paclitaxel, the combination of gemcitabine and docetaxel, vinca alkaloids such as vinorelbine, trabectedin, as well as etoposide. Although these agents have been used as second or third line in the metastatic setting, use in the adjuvant setting is uncommon.

4.1 Adjuvant chemotherapy for soft tissue sarcoma of the extremity and trunk

The use of adjuvant chemotherapy in soft tissue sarcoma is controversial. Some randomized trials have suggested chemotherapy improves disease-free and overall survival while many have not (Frustaci et al. 2001). Issues with the study of adjuvant chemotherapy in STS include the lack of a highly effective agent, the heterogeneity of tumors within the grouping STS, the rareness of the disease, and the potential dilution of effect in clinical trials by inclusion of all patients regardless of risk, including those unlikely to benefit.

The largest meta-analysis of doxorubicin-based chemotherapy assessed individual patient data from 14 trials and did show an improvement in disease-free survival but no improvement in overall survival (Tierney et al., 1997). However, subset analysis notes an absolute 7% improvement in disease-free survival and an absolute 4% improvement in overall survival for the subgroup of patients with STS of the trunk or extremity with tumors greater than 5 cm and high grade (grades 2 or 3 out of 3). Other subtypes of STS by location, size, or grade showed no differences in disease-free or local survival. The same meta-analysis notes insufficient evidence to make recommendations for adjuvant chemotherapy for retroperitoneal sarcomas. Further, it was felt there are insufficient data to determine whether single-agent doxorubicin or combination chemotherapy should be recommended. An updated meta-analysis with four additional trials including the use of ifosfamide in the

adjuvant studies found the hazard ratios of local, distant and overall survival were 0.73 (95% CI 0.56-0.95), 0.65 (95% CI 0.53-0.80), and 0.67 (95% CI 0.56-0.82) respectively in favor of adjuvant chemotherapy (Pervaiz et al., 2008).

5. Neoadjuvant therapies for soft tissue sarcoma of the extremity and trunk

Early administration of chemotherapy in STS can theoretically treat micro-metastatic disease, decrease the rate of distant metastatic disease and improve overall survival. Early non-randomized trials suggest a higher response rate for primary tumors compared to chemotherapy given in the setting of distant metastases (Rouessse et al., 1987). Therefore, preoperative chemotherapy may have a role in downstaging primary tumors to improve resectability. Finally, response to chemotherapy *in vivo* could affect choices of postoperative adjuvant chemotherapy.

5.1 Neoadjuvant systemic chemotherapy

One randomized trial has assessed neoadjuvant systemic chemotherapy for STS. The small (134 patients) multicenter trial by Gortzak et al. (2001) assessed preoperative chemotherapy with doxorubicin and ifosfamide vs. no preoperative therapy in patients aged 15-75 with high risk STS. High risk was defined as tumors ≥ 8 cm of any grade, or grade II/III tumors < 8 cm, or grade II/III locally recurrent tumors or grade II/III tumors with inadequate surgery performed in the previous 6 weeks which required further surgery. Preoperative chemotherapy consisted of three cycles of doxorubicin (q 3 weeks -50mg/m² bolus) and ifosfamide (5 g/m²) by 24-hour infusion. Surgery occurred within 3 weeks of completion of chemotherapy. Surgery was planned at randomization in both arms and could include amputation, compartmental resection, wide or marginal excision. Postoperative radiation could be used if marginal surgery, for microscopically positive margins with no possibility of further surgery with limb salvage, or in cases of surgery for local recurrence. Although 150 were initially entered into the trial, 134 were eligible with randomization of 67 to each arm. The response rate was 28% in the chemotherapy arm (8% complete, 20% partial); no different than the usual response in the setting of metastatic disease. Side effects from chemotherapy arm included alopecia, nausea and emesis (95%), and leukocytopenia (32%). There was an 8% grade IV leukocytopenia rate and one grade V complication (death) from febrile neutropenia. Surgical outcomes included 88% limb salvage and 12% amputation rate. At median follow-up of 7.3 years, 5-year disease-free survival was 52% and 56% in the surgery alone and chemotherapy arms respectively ($p=0.35$). Overall 5-year survival was 64 and 65% respectively ($p=0.22$). A priori sample size calculations estimated 269 patients were required to detect a 15% increase in 5-year survival. Although closed prior to its planned accrual, it was felt the study results made it unlikely that a major survival benefit would be achieved with preoperative systemic doxorubicin and ifosfamide. The authors note preoperative chemotherapy was feasible and did not compromise subsequent surgery, radiation treatments or wound healing.

A retrospective analysis by Meric et al. (2000) had similar findings with regards to surgical complications. They compared 204 patients having surgery first to 105 who had preoperative chemotherapy with various regimes including combinations or single agent doxorubicin, ifosfamide, dacarbazine, cyclophosphamide, or mesna. Generally, those in the neoadjuvant chemotherapy group had large tumors (12 vs. 8 cm), a higher proportion of high grade tumors (90 vs. 64%) and were younger (age 47 vs. 55 years of age). The incidence

of surgical complications was similar (34 vs. 41% for extremity; 29 vs 34% for retroperitoneal/ visceral) with the majority of complications being wound infections or other wound complications. The main predictors of wound complications were preoperative radiation, autologous flap coverage, and those with lower extremity tumors, rather than the use of neoadjuvant chemotherapy.

A two center retrospective analysis by Grobmyer et al. ((2004) assessed preoperative systemic chemotherapy with doxorubicin, ifosfamide and mesna followed by surgery (74 patients) versus surgery alone (282 patients) for the time period 1990-2001. Inclusion criteria included high-grade, deep, >5cm extremity soft tissue sarcomas. Overall, there was a younger median age in the group treated with neoadjuvant chemotherapy (50 years vs. 62 years) and more of the synovial sarcoma histological subtype. Size was similar but slightly larger in the neoadjuvant group (median 12 cm vs. 10 cm). With potential imbalances that may favor the surgery alone arm, the unadjusted hazard ratio for the effect of neoadjuvant chemotherapy on disease-specific survival was 0.75 (95% CI:0.45-1.2). Following multivariate analysis including factors size, histology and age, the HR for the effect of neoadjuvant chemotherapy on disease-specific survival was 0.52 (95%CI:0.30-0.92). Three year disease-specific survival for tumors greater than 10 cm was 83 % (72-95) vs. 62% (53-71) for those treated with neoadjuvant chemotherapy vs. surgery alone respectively. The authors felt the study suggests an association between neoadjuvant chemotherapy and disease-specific survival but caution the retrospective nature of the study had distinct limitations.

At present, there is no convincing evidence for the routine use of systemic dose neoadjuvant chemotherapy alone in the treatment of soft tissue sarcoma of the extremity. However, neoadjuvant protocols continue to be developed. The overall challenge with neoadjuvant systemic chemotherapy has been the lack of a highly effective agent.

5.2 Neoadjuvant chemoradiation

A number of primarily single center trials assess the approach of neoadjuvant chemoradiation in the treatment of STS. Advantages of combining chemotherapy and radiation include the potential of using a lower dose of radiation and possibly avoiding side effects such as wound complications associated with high dose preoperative radiation. Downstaging can occur and resection margins may be less radical, especially near critical neurovascular structures. Although the literature often suggests neoadjuvant chemotherapy given with radiation may still theoretically treat micro-metastatic disease, it is important to recognize that the chemotherapy dose is often significantly reduced, in which case it is being used primarily as a radiosensitizer. Generally trials can be divided into those with neoadjuvant chemoradiation usually with chemotherapy as a radiosensitizer versus trials with systemic neoadjuvant chemotherapy with radiation interdigitated between cycles.

Based on a prior pilot study, an important phase II trial by the Radiation Therapy Oncology Group assessed systemic dose preoperative chemotherapy interdigitated with preoperative radiation therapy followed by 3 cycles of postoperative chemotherapy (Delaney et al., 1996; Kraybill et al., 2006). Sixty-six patients were enrolled with 64 analyzed. Preoperative chemotherapy consisted of 3 cycles of mesna, doxorubicin, ifosfamide and dacarbazine (MAID) with 44 Gy of preoperative radiation; twenty-two Gy was given in 11 daily fractions between cycle 1 and 2 as well as cycle 2 and 3. Seventy-nine percent completed preoperative chemotherapy and 59% completed all chemotherapy. Three patients died from grade 5 toxicity (hematologic/ infectious) and 83% had grade 4 toxicities with the majority being

hematologic. There was a 22% partial response rate based on radiology and 27% had no viable tumor at pathologic review. Sixty-one patients came to surgery with 58 R0 resections including 5 amputations. The 3-year rate of local regional failure was 10.1%. Three year disease-free, distant disease-free, and overall survival was 56.6%, 64.5%, and 75.1% respectively. The three-year survival rates were promising compared to the literature dealing primarily with large, high grade tumors. The trial authors conclude that an aggressive neoadjuvant regime can be delivered in a cancer cooperative group. However, the substantial toxicity of the treatment precludes its use outside of clinical trials. It is suggested the future of this regime may be a modified version with possible targeted therapies and reduced doses of cytotoxic agents.

The most recent publication of neoadjuvant chemoradiation where full dose chemotherapy is used involves 25 patients with intermediate or high-grade soft tissue sarcomas with 3 cycles of pre and postoperative epirubicin and ifosfamide with 28 Gy of irradiation given in 8 fractions during cycle 2 of chemotherapy (Ryan et al., 2008). Sixteen patients completed the entire treatment but 21 had grade 4 toxicity which was generally hematologic such as febrile neutropenia and anemias. Postoperative wound complications occurred in 20%. Forty percent of resected specimens showed >95% pathologic necrosis. The 2-year overall and disease-free survival rates were 84 and 62%. Although the high pathologic response rate was encouraging, the relatively high rate of major toxicity limited the use of this protocol.

Overall, full dose systemic chemotherapy with interdigitated radiation has not been successful in convincingly improving disease-free or overall survival for patients with high-risk tumors. Although higher response rates have been reported, these generally have trended with higher toxicity.

A phase I trial of concurrent preoperative doxorubicin and radiation used full-dose radiation (50Gy) with varying doses of 4-day continuous doxorubicin (Pisters et al., 2004). This is the only reported trial of truly concurrent chemoradiation. The maximum tolerated dose of continuous-infusion doxorubicin was 17.5mg/m²/week. Among 22 patients treated with this dose and full-dose radiation, 50% had a greater than 90% tumor necrosis rate including 2 patients with a complete pathologic response. Six patients (23%) experienced major wound complications requiring hospital admission; two patients required re-operation.

An early neoadjuvant chemoradiation regime where chemotherapy was used as a radiosensitizer was developed and popularized by Eilber et al. (2003) at the University of California, Los Angeles (UCLA). An initial protocol combined intra-arterial doxorubicin and sequential hypofractionated radiation (35 Gy in 3.5 Gy fractions) followed by limb-sparing surgery. In a small series, all patients avoided amputation and the local recurrence rate was 3%; the best local control rate in the literature. However, postoperative wound complications were considerable with 23% of patients requiring re-operation. Following further experimentation of the protocol, the most widely published regime included 28 Gy in 3.5 daily fractions. Further, intra-arterial chemotherapy was changed to being given intravenously. Eilber et al. (2001) noted that a pathologic complete response following neoadjuvant chemoradiation was associated with improved local recurrence as well as overall survival.

Further modification of the Eilber protocol occurred at the University of Calgary (Mack et al., 2005). This protocol uses 3 consecutive days of systemic doxorubicin with sequential 10 fractions of 3 Gy preoperative irradiation; total dose 30 Gy. The largest report of this protocol assessed 75 consecutive patients with a 3% 5 year local recurrence rate and a 63% 5

year overall survival. The major wound complication rate of 4% was much lower than other preoperative full-dose radiation protocols. Although local recurrence rates are quite favorable, overall survival data appears unchanged compared to the literature. Wanebo et al. (1995) also reported on 66 patients treated with preoperative doxorubicin and 3-4600 cGY of radiation. In this trisentre study, the 5-year local recurrence rate was 2% and 5 year overall survival was 59%. Other series have been published using various modifications of the Eilber protocol or neoadjuvant chemoradiation strategies with similarly low local recurrence rates (Goodnight et al., 1985; Levine et al., 1993; Pisters et al., 2002). Therefore, the role of using chemotherapy as a radiosensitizer has promise in terms of local control but not in terms of distant disease control or overall survival. Thus far, this approach has been explored primarily in single centers and has not been studied in a comparative trial.

5.3 Neoadjuvant chemotherapy and regional hyperthermia

Another modification of neoadjuvant chemotherapy is the combination of chemotherapy or radiation with hyperthermia; the tumor is heated to improve the effects of the chemotherapy or radiation. The theory of using hyperthermia is that heat kills cells via thermal toxicity, increases drug efficacy, and induces a tumoricidal immune response.

In a phase III trial of 341 patients with large, high-grade sarcomas (extremity or trunk), patients were randomized to neoadjuvant etoposide, ifosfamide and doxorubicin plus or minus concurrent hyperthermia (Issels et al., 2010). Treatment response was 12.7% in the neoadjuvant chemotherapy arm and 28.8% in the neoadjuvant chemotherapy with hyperthermia arm. The majority of patients (90%) went on to surgery with 6.7% and 8.9% having an amputation in the combination arm and chemotherapy arm respectively. However, only about two thirds had a definitive surgical resection with approximately one third not having a definitive surgery as felt to be impossible. The reasons for unresectability were not explicitly described. The R0 resection rate was quite low at 51% and 41.6% in the combination and chemotherapy alone arms respectively. Approximately two thirds of patients had adjuvant radiation. Local control was improved in the hyperthermia arm (HR 0.58, 95% CI 0.41-0.83; $p=0.003$) compared to the chemotherapy alone group. Further, overall survival was better in the combined arm (HR 0.66; 95% CI 0.45-0.98, $p=0.038$).

Although there have been other phase II trials of this combination treatment, few centers have adopted the approach (Schlemmer et al., 2010). At present, the potential benefits of this new intervention are restricted to patients with very high-risk soft tissue sarcomas in the context of a clinical trial.

5.4 Isolated limb infusion or perfusion

Isolated limb perfusion (ILP) uses high-dose regional chemotherapy where the blood supply to the limb is isolated from the rest of the body by an extracorporeal circulation. It involves a complex and invasive technique by clamping and cannulating the major artery and vein after heparinization of the patient, connection to an oxygenated high-flow extracorporeal circuit, ligation of collateral vessels, and the application of a tourniquet at the root of the limb to occlude superficial veins (Hoekstra 2008). Isolated limb infusion (ILI) is a modified, more minimally invasive technique via percutaneously placed catheters (Kroom & Thompson 2009). Further, ILI is low flow and performed under hypoxic conditions. The intent is still to provide regional chemotherapy but without the potential morbidity of a surgical procedure.

Most commonly, agents used for soft tissue sarcoma of the extremity include tumor necrosis factor- α (TNF- α), melphalan, doxorubicin, cisplatin, carboplatin and actinomycin-D (Hoekstra 2008; Kroon & Thompson 2009). TNF- α is only available in Europe. The use of either procedure is limited to large soft tissue tumors initially felt to be unresectable without amputation. It is sometimes used in a palliative fashion in those with large unresectable and symptomatic tumors in the setting of small volume metastatic disease. Although relatively toxic to local tissues, it also has quite high response rates and may allow limb salvage in 70-90% in the short-term and as high as 60% at 5 to 10 years (Di Filippo et al., 2009; Grunhagen et al., 2005; Moncrieff et al., 2008). Complete and partial response rates range from 0-70% and 0-74% respectively (Hoekstra 2008). A randomized trial found no differences in response with varying doses of TNF- α but systemic toxicity did correlate with higher drug dosage (Bonvalot et al., 2005).

6. Retroperitoneal sarcoma

6.1 Local treatment for retroperitoneal sarcomas

Unlike extremity/ trunk STS where surgery and radiation is accepted as the standard of care, the most appropriate treatment of retroperitoneal sarcoma is less clear. En bloc resection of the retroperitoneal STS plus adjacent organs to obtain a negative margin is the most common treatment (Lewis et al., 1998). Unfortunately, as many as 20-60% of tumors are deemed unresectable at presentation or gross residual disease remains after a resection attempt (Catton et al., 1994; Lewis et al., 1998; Sindelar et al., 1993) In this group, there is no survival benefit to partial or incomplete gross resection (Lewis et al., 1998). Even when completely resected, about 25% of cases have microscopically positive margins; potentially higher depending on the intensity of the pathologic evaluation. In a large series, 19% and 41% local recurrence rates at 2 and 5 years respectively were described for those having a complete resection (Lewis et al., 1998). Local recurrence without the development of systemic disease is the leading cause of death in retroperitoneal sarcomas.

Some centers are commonly using preoperative irradiation in an effort to improve upon local control and possibly overall survival for retroperitoneal sarcoma. Theoretical advantages of preoperative irradiation include the gross tumor volume is more clearly demarcated since still in situ, radiosensitive viscera are displaced by the tumor outside of the radiation field, the biologically effective dose is lower preoperatively as the tumor is still well oxygenated, a higher dose can be delivered to the tumor since there are fewer surgical adhesions (less scar), and the tumor is treated preoperatively prior to potential contamination by surgery (Raut & Pisters 2006). Two prospective protocols from the MD Anderson Cancer Center and the University of Toronto employed pre-operative irradiation (45-50 Gy) followed by surgery (Pawlik et al., 2006). At median follow-up of 40 months, combined results showed 5-year local recurrence free, disease free and overall survival rates of 60%, 46%, and 61% respectively. Using 45 Gy of pre-operative irradiation but with the use of surgically placed intra-abdominal spacers to displace small intestine and allow maximal irradiation to the tumor margin, White et al. (2007) describe an 80% 5 year local control rate in a series of 23 patients.

Unfortunately, a phase III trial randomizing between preoperative external beam irradiation (45-50.4 Gy) and surgery versus surgery alone was closed due to poor accrual (Raut & Pisters 2006).

6.2 Neoadjuvant chemotherapy and chemoradiation

The high local recurrence rate after surgery alone has led to combined modality approaches to potentially improve local control. As noted, preoperative irradiation protocols are the most commonly explored. However, there have also been a few attempts of neoadjuvant chemotherapy or neoadjuvant chemoradiation protocols. A study of 16 patients with 3 to 5 cycles of preoperative chemotherapy alternating with irradiation therapy led to 11 surgical resections and 4 R0 resections in advanced, large (median 17 cm) retroperitoneal sarcomas (Robertson et al., 1995). Two further studies of concurrent chemoradiation noted feasible complication rates (11% admission rate for toxicity) and a fairly high (26%) complete pathologic response rate (Eilber et al., 1995; Pisters et al., 2003). Finally, a retrospective review of 55 patients having neoadjuvant chemotherapy (plus preoperative radiation in 56%) found no difference in disease-specific or overall survival compared to predicted outcomes (Donahue et al. 2010). However, those with a greater than 95% pathologic necrosis (25% of cohort) had much improved disease-specific survival compared to non-responders.

A phase II trial of preoperative combined modality treatment for intermediate or high-grade retroperitoneal sarcoma with doxorubicin and ifosfamide followed by preoperative irradiation followed by surgery and an intraoperative or postoperative boost was closed due to poor accrual (Raut & Pisters 2006). Concerns regarding the rare incidence of this tumor subtype and institution specific protocols were the most likely reasons for insufficient timely accrual.

7. Gastrointestinal stromal tumors (GISTs)

7.1 Local treatment of gastrointestinal stromal tumors

The mainstay of treatment for GIST is complete surgical excision with negative margins without dissection of clinically negative nodes (Dematteo et al., 2002). Adjuvant irradiation does not have a role for these intra-abdominal tumors.

7.2 Role of imatinib

The prognosis of GISTs is primarily related to mitotic index and tumor size (Table 2) (Fletcher et al., 2002). The risk of relapse is based on these factors as well as site, surgical margins and whether tumor rupture has occurred (Casali & Blay, 2009). Most patients with localized disease and deemed low risk have surgery alone.

For patients with intermediate or high-risk tumors, adjuvant imatinib is considered. Imatinib is a highly active targeted therapy for patients with GIST. The ACOSOG Z9001 trial compared one year of adjuvant imatinib with placebo in patients with complete resection of their primary GIST which was intermediate or high-risk based on size alone (Dematteo et al., 2007). Based on 756 patients and an interim analysis, the relapse free survival at one year was 97% in the imatinib arm compared to 83% in the placebo arm. This was highly significant and the trial was unblinded; those on placebo crossed over to one year of adjuvant imatinib. There was no overall survival benefit at this point in the trial and this may never be demonstrated due to the crossover of patients after the interim analysis. Therefore, the use of adjuvant imatinib in all patients has been questioned until an overall survival benefit can be demonstrated. Fortunately, a European placebo controlled trial continues and is powered to detect overall survival differences (Joensuu et al., 2011).

	Size	Mitotic Count
Very low risk	< 2 cm	<5/ 50 high power fields (HPF)
Low risk	2-5 cm	<5/ 50 HPF
Intermediate risk	< 5 cm	6-10/ 50 HPF
	5-10 cm	<5/ 50 HPF
High risk	>5 cm	>5/ 50 HPF
	>10 cm	Any mitotic count
	Any size	>10/ 50 HPF

Table 2. Approach for Defining Risk of Aggressive Behavior in GISTs.

Finally, those patients presenting with locally advanced inoperable tumors or with metastatic disease, palliative intent chemotherapy with imatinib is the standard of care (Blanke et al., 2008). Objective response rates of 50-60% occur with only 10-15% of tumors having primary progression. The first-line dose is 400 mg per day; however, those with exon 9 KIT mutations appear to do better with 800 mg daily (Verweij et al., 2004). Further, in cases of tumor progression, imatinib is increased to 800 mg daily. Second-line therapy includes sunitinib and other anti-tyrosine kinase agents or clinical trial (Casali & Blay, 2010). Gastrointestinal stromal tumors are considered refractory to conventional, systemic chemotherapy (Trent et al., 2003).

7.3 Neoadjuvant imatinib in gastrointestinal stromal tumors (GISTs)

Since GISTs have a high response (50-60%) to imatinib in the metastatic setting, neoadjuvant strategies have been explored to attempt to reduce the surgical procedure required or downstage (Blanke et al., 2008 Verweij et al., 2004). Currently, ESMO guidelines recommend neoadjuvant imatinib in patients for whom a complete R0 resection is not feasible and for patients who are candidates for less mutilating surgery (Casali & Blay, 2009). Similarly, NCCN guidelines recommend neoadjuvant imatinib for marginally resectable tumors or resectable tumors with risk of significant morbidity. Finally, Canadian guidelines consider neoadjuvant imatinib if surgery may result in significant morbidity of loss of organ function (Blackstein et al., 2006). Generally, in these scenarios, subsequent surgery is considered 4-12 months later after maximal tumor response (Figure 1).

A phase II trial of neoadjuvant imatinib was reported by Eisenberg et al. (2009) for advanced primary (30 patients) and metastatic/recurrent yet operable (22 patients) gastrointestinal stromal tumors. Imatinib was used for 8-12 weeks prior to surgery at 600 mg per day. Generally, imatinib was tolerated with 21% grade 3 complications, 12% grade 4 and 2% grade five complications. The response rates by RECIST criteria for primary tumors is partial (7%), stable (83%), and unknown (10%). For those with metastatic/ recurrent yet operable tumors the response was partial (4.5%), stable (91%), and progression (4.5%). Postoperative complications were consistent with a surgical patient series with extensive and re-operative surgery. The type of surgery performed included a single or partial organ resection (53%), multi-organ resection (36%), as well as combinations of organs and peritoneal implants (11%). In the advanced primary tumor group, an R0 resection (no residual gross or microscopic disease) was possible in 77%, R1 (no residual gross disease but microscopic residual) in 15% and R2 (gross disease remaining) in 8%. In the metastatic or recurrent yet operable setting, similar rates were 58%, 5%, and 32% respectively for R0, R1, and R2 resections. The two-year progression free survival was 80.5% and 82.7% in the two

groups. The 2-year overall survival was 93.3% and 90.9% in the group with advanced primary versus metastatic or recurrent yet operable disease, respectively. The overall conclusions of this multicenter trial were that neoadjuvant imatinib in the case of locally advanced primary or metastatic GIST was feasible, requires multidisciplinary considerations, and was not associated with increased postoperative complications.

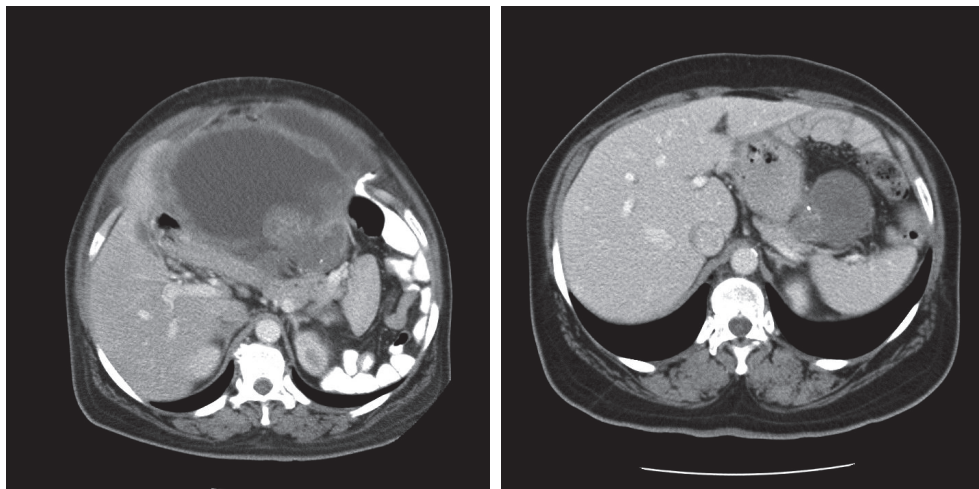


Fig. 1. CT Scans showing Large GIST Before (left) and After (right) Neoadjuvant Imatinib.

8. Future directions

The main difficulties with the use of neoadjuvant therapies for soft tissue sarcoma of the extremity, trunk or retroperitoneum include issues with the lack of a highly effective agent, the heterogeneity of tumors subtypes, the rareness of patients with the disease for participation in clinical trials, and the potential dilution of effect in clinical trials by inclusion of all patients regardless of risk, including those unlikely to benefit. By contrast, patients with gastrointestinal stromal tumors now have a highly effective agent (imatinib) in the metastatic setting with the potential of exploring additional neoadjuvant protocols.

Identification of similar chromosomal translocations and gene microarray technology are playing increasing roles in the diagnosis of soft tissue sarcoma and potential identification of therapeutic targets (Borden et al., 2003; Nielsen et al., 2006). Dynamic positron emission technology (PET) imaging is being used to evaluate treatment responses after initial cycles of neoadjuvant chemotherapy (Dimitrakopoulou-Strauss et al., 2010). Further, there does appear to be a histopathologic correlation of treatment response and PET imaging which may allow early treatment decisions as to continuing or discontinuing neoadjuvant chemotherapy (Benz et al., 2009).

9. Conclusion

Although limb-sparing, function-preserving surgery plus radiation in some fashion is the current standard of care for soft tissue sarcoma of the extremity or trunk, neoadjuvant chemotherapy and chemoradiation strategies continue to be explored and employed

especially in large, high-risk tumors. At present, the success of these strategies have been limited primarily due to the lack of an effective agent in soft tissue sarcoma, especially in terms of distant disease free and overall survival rates. The development of new, targeted therapies based on the distinct histologic and biologic differences among subtypes of soft tissue sarcoma is required.

The use of a highly effective agent, imatinib as well as other tyrosine kinase inhibitors in the treatment of gastrointestinal stromal tumors, either neoadjuvantly, adjuvantly, or in the metastatic setting will hopefully correlate with similar development of targeted therapies for soft tissue sarcoma.

10. References

- Benz, M.R., Czernin, J., Allen-Auerbach, M.S., Tap, W.D., Dry, S.M., Elashoff, D., Chow, K., Evilevitch, V., Eckardt, J.J., Phelps, M.E., Weber, W.A., & Eilber, F.C. (2009). FDG-PET/CT imaging predicts histopathologic treatment responses after the initial cycle of neoadjuvant chemotherapy in high-grade soft-tissue sarcomas. *Clinical cancer research*, Vol. 15, No. 8, (April 2009), pp. 2856-63, ISSN 1078-0432.
- Blanke C.D., Demetri, G.D, von Mehren, M. Heinrich, M.C., Eisenberg, B., Fletcher, J.A., Corless, C.L., Fletcher, C.D., Roberts, P.J., Heinz, D., Wehre, E., Nikolova, Z., & Joensuu, H. (2008). Long-term results from a randomized phase II trial of standard-versus higher-dose imatinib mesylate for patients with unresectable or metastatic gastrointestinal stromal tumours expressing KIT. *Journal of clinical oncology*, Vol. 26, No. 4, (February 2008), pp. 620-5, ISSN 1527-7755.
- Bonvalot, S., Laplanche, A., Lejeune, F., Stoeckle, E., Le Pechoux, C., Vanel, D., Terrier, P., Lumbroso, J., Ricard, M., Antoni, G., Cavalcanti, A., Robert, C., Lassau, N., Blay, J.Y., & Le Cesne, A. (2005). Limb salvage with isolated perfusion for soft tissue sarcoma: could less TNF-alpha be better? *Annals of oncology*, Vol. 16, No. 7, (July 2005), pp. 1061-8, ISSN 1569-8041.
- Borden, E.C., Baker, L.H., Bell, R.S., Bramwell, V., Demetri, G.D., Eisenberg, B.L., Fletcher, C.D., Fletcher, J.A., Ladanyi, M., Meltzer, P., O'Sullivan, B., Parkinson, D.R., Pisters, P.W., Saxman, S., Singer, S., Sundaram, M., van Oosterom, A.T., Verweij, J., Waalen, J., Weiss, S.W., & Brennan, M.F. (2003). Soft tissue sarcomas of adults: state of the translational science. *Clinical cancer research*, Vol. 9, No. 3, (June 2003), pp. 1941-56, ISSN 1078-0432.
- Casali, P.G. & Blay, J.-Y. (2010). Gastrointestinal stromal tumours: ESMO clinical practice guidelines for diagnosis, treatment and follow-up. *Annals of Oncology*, Vol. Suppl. 5, (May 2010), pp. v98-102, ISSN 1569-8041.
- Catton, C.N., O'Sullivan, B., Kotwall, C., Cummings, B., Hao, Y., & Fornasier, V. (1994). Outcome and prognosis in retroperitoneal soft tissue sarcoma. *International journal of radiation oncology biology physics*, Vol. 29, No. 5, (July 1994), pp. 1005-1010.
- Clark, M.A., Fisher, C., Judson, I., & Thomas, J.M. (2005). Soft-tissue sarcomas in adults. *New England journal of medicine*, Vol. 353, pp. 701-11, ISSN 0028-4793.
- Coindre, J., Nguyen, B.B., Bonichon, F., de Mascarel, I., & Trojani, M. (1988). Histopathologic grading in spindle cell soft tissue sarcomas. *Cancer*, Vol. 61, No. 11, (June 1988), pp. 2305-9, ISSN 1097-0142.
- Coindre, J.M., Terrier, P., Guillou, L., Doussal, V.L., Collin, F., Ranchere, D., Sastre, X., Vilain, M.O., Bonichon, F., & Bui, B.N. (2001). Predictive value of grade for

- metastasis development in the main histologic types of adult soft tissue sarcomas: a study of 1240 patients from the French Federation of Cancer Centers Sarcoma Group. *Cancer*, Vol. 91, No. 10, (May 2001), pp. 1914-26, ISSN 1097-0142.
- Davis, A.M., O'Sullivan, B, Bell, R.S., Turcotte, R., Catton, C.N., Wunder, J.S., Chabot, P., Hammond, A., Benk, V., Isler, M., Freeman, C., Goddard, K., Bezjak, A., Kandel, R.A., Sadura, A., Day, A., James, K., Tu, D., Pater, J., & Zee, B. (2002). Function and health status outcomes in a randomized trial comparing preoperative and postoperative radiotherapy in extremity soft tissue sarcoma. *Journal of clinical oncology*, Vol. 20, No. 22, (November 2002), pp. 4472-7, ISSN 1527-7755.
- Davis, A.M., O'Sullivan, B, Turcotte, R., Bell, R., Catton, C., Chabot, P., Wunder, J., Hammond, A., Benk, V., Kandel, R., Goddard, K., Freeman, C., Sadura, A., Zee, B., Day, A., Tu, D., Pater, J., A Canadian Sarcoma Group and NCI Canada Clinical Trials Group Randomized Trial. (2005). Late radiation morbidity following randomization to preoperative versus postoperative radiotherapy in extremity soft tissue sarcoma. *Radiotherapy and oncology*, Vol. 75, No. 1, (April 2005), pp. 48-53, ISSN 0167-8140.
- DeLaney, T.F., Spiro, I.J., Suit, H.D., Phil, D., Gebhardt, M.C., Hornicek, F.J., Mankin, H.J., Rosenberg, A.L., Rosenthal, D.E., Miryousefi, F., Ancukiewicz, M., & Harmon, D.C. (2003). Neoadjuvant chemotherapy and radiotherapy for large extremity soft-tissue sarcomas. *International journal of radiation oncology biology and physics*, Vol., 56, No. 4, (July 2003), pp. 1117-27, ISSN 0360-3016.
- DeMatteo, R.P., Heinrich, M.C., El-rifai, W.M. & Demetri, G. (2002). Clinical management of gastrointestinal stromal tumors: before and after STI-571. *Human pathology*, Vol. 33, No. 5, (May 2002), pp. 466-77, ISSN 0046-8177.
- Di Fiiippo, F., Giacomini, P., Rossi, C.R., Santinami, M., Garinei, R., Anza, M., Deraco, M., Botti, C., Perri, P., Cavaliere, F., Di Angelo, P., Sofra, C., Sperduti, I., Pasqualoni, R., Di Filippo, S., Corrias, F., Armenti, A., & Ferraresi, V. (2009). Hyperthermic isolated perfusion with tumor necrosis factor-alpha and doxorubicin for the treatment of limb-threatening soft tissue sarcoma: the experience of the Italian Society of Integrated Locoregional Treatment in Oncology (SITILO). *In vivo*, Vol. 23, No. 2, (March 2009), pp. 363-7, ISSN 1791-7549.
- Dimitrakopoulou-Stauss, A., Strauss, L.G., Egerer, G., Vasamillette, J., Mechtersheimer, G., Schmitt, T., Lehner, B., Haberkorn, Stroebel, P., & Kasper, B. (2010). Impact of dynamic ¹⁸F-FDG PET on the early prediction of therapy outcome in patients with high-risk soft-tissue sarcomas after neoadjuvant chemotherapy: a feasibility study. *Journal of nuclear medicine*, Vol. 51, No. 4, (April 2010), pp. 551-8. ISSN 0161-5505.
- Donahue, T.R., Kattan, M.W., Nelson, S.D., Tap, W.D., Eilber, F.R., Eilber, F.C. (2010). Evaluation of neoadjuvant therapy and histopathologic response in primary, high-grade retroperitoneal sarcomas using the sarcoma nomograms. *Cancer*, Vol. 1116, No. 16, (August 2010), pp. 3883-91, ISSN 1097-0142.
- Edmonsom, J.H., Ryan, L.M., Blum, R.H., Brooks, J.S., Shiraki, M., Frytak, S., & Parkinson, D.R. (1993). Randomized comparisons of doxorubicin alone versus ifosfamide plus doxorubicin or mitomycin, doxorubicin, and cisplatin against advanced soft tissue sarcoma. *Journal of clinical oncology*, Vol. 11, No. 7, (July 1999), pp. 1269-75, ISSN 1527-7755.

- Eilber, F.C., Morton, D.L., Eckardt, J., Grant, T., & Weisenburger, T. (1984). Limb salvage for skeletal and soft tissue sarcomas. *Cancer*, Vol. 53, No. 12, (June 1984), pp. 2579-84, ISSN 1097-0142.
- Eilber, F., Eckardt, J., Rosen, G., Forscher, C., Selch, M., & Fu, Y-S. (1995). Preoperative therapy for soft tissue sarcoma. *Hematology/oncology clinics of North America*, Vol. 9, No. 4, (August 1995), pp. 817-23, ISSN 0889-8588.
- Eilber, F.C., Rosen, G., Eckardt, J., Forscher, C., Nelson, S.D., Selch, M., Dorey, F., & Eilber, F.R. (2001). Treatment-induced pathologic necrosis; a predictor of local recurrence and survival in patients receiving neoadjuvant therapy for high-grade extremity soft tissue sarcomas. *Journal of clinical oncology*, Vol. 19, No. 13, (July 2001), pp. 3203-9, ISSN 1527-7755.
- Eilber, F.C., Rosen, G., Nelson, S.D., Selch, M., Dorey, F., Eckardt, J., & Eilber, F.R. (2003). High-grade extremity soft tissue sarcomas: factors predictive of local recurrence and its effect on morbidity and mortality. *Annals of surgery*. Vol. 237, No. 2, (February 2003), pp. 218-26, ISSN 0003-4932.
- Eisenberg, B.L., Harris, J., Blanke, C., Demetri, G.D., Heinrich, M.C., Watson, J.C., Hoffman, J.P., Okuno, S., Kane, J.M., & von Mehren, M. (2009). Phase II trial of neoadjuvant/ adjuvant imatinib mesylate (IM) for advanced primary and metastatic/ recurrent operable gastrointestinal stromal tumor (GIST) – early results of RTOG 0132. *Journal of surgical oncology*. Vol. 99, No. 1, (January 2009), pp. 42-7, ISSN 1096-9098.
- Eriksson, M. (2010). Histology-driven chemotherapy of soft-tissue sarcoma. *Annals of oncology*, Vol. 21, No. Suppl. 7, (October 2010), pp. vii270-76, ISSN 1569-8041.
- Ferrari, A., Sultan, I., Huang, T.T., Rodriguez-Galindo, C., Shehadeh, C., Meazza, C., Ness, K.K., Casanova, M., & Spunt, S.L. (2011). Soft tissue sarcoma across the age spectrum: a population-based study from the surveillance epidemiology and end results database. *Pediatric blood & cancer*, Vol. 57, No. 6, (December 2011), pp. 943-9, ISSN 1545-5017.
- Fletcher, C.D.M., Berman, J.J., Corless, C., Gorstein, F., Lasota, J., Longley, B.J., Miettinen, M., O'Leary, T.J., Remotti, H., Rubin, B.P., Shmookler, B., Sobin, L.H., & Weiss, S.S. (2002). Diagnosis of gastrointestinal stromal tumors: a consensus approach. *Human pathology*. Vol. 33, No. 5, (May 2002), pp. 459-65, ISSN 0046-8177.
- Frustaci, S., Gherlinzoni, F., De Paoli, A., et al. (2001). Adjuvant chemotherapy for adult soft tissue sarcomas of the extremities and girdles: results of the Italian randomized cooperative trial. *Journal of clinical oncology*, Vol. 19, No. 5, (March 2001), pp. 1238-1247, ISSN 1527-7755.
- Goodnight, J.E.J., Bargar, W.L., Voegeli, T., & Blaisdell, F.W. (1985). Limb-sparing surgery for extremity sarcomas after preoperative intraarterial doxorubicin and radiation therapy. *American journal of surgery*. Vol.150, No. 1, (July 1985), pp. 109-13, ISSN 0002-9610.
- Gortzak, E., Azzarelli, A., Buesa, J., Bramwell, V.H.C., van Coevorden, F., van Geel, A.M., Ezzat, A., Santoro, A., Oosterhuis, J.W., van Glabbeke, M., Kirkpatrick, A., Verweij, J., the E.O.R.T.C. soft tissue bone sarcoma group and the National Institute of Canada clinical trials group/ Canadian sarcoma group. (2001). A randomized phase II study on neo-adjuvant chemotherapy for 'high-risk' adult soft-tissue sarcoma. *European journal of cancer*, Vol. 37, No. 1, (June 2001), pp. 1096-1103, ISSN 0959-8049.


- Grobmyer, S.R., Maki, R.G., Demetri, G.D., Mazumdar, M., Riedel, E., Brennan, M.F. & Singer, S. (2004). Neo-adjuvant chemotherapy for primary high-grade extremity soft tissue sarcoma. *Annals of oncology*, Vol. 15, No. 11, (November 2004), pp.1667-72, ISSN 1569-8041.
- Grunhagen, D.J., Brunstein, F., Graveland, W.J., van Geel, A.N., de Wilt, J.H., & Eggermont, A.M. (2005). Isolated limb perfusion with tumor necrosis factor and melphalan prevents amputation in patients with multiple sarcomas in arm or leg. *Annals of surgical oncology*, Vol. 12, No. 6, (June 2005), pp. 473-9, ISSN 1534-4681.
- Heslin, M.J. & Smith, J.K. (1999). Imaging of soft tissue sarcomas. *Surgical oncology clinics of North America*, Vol. 8, No. 1, (January 1999), pp. 91-107, ISSN 1055 3207.
- Hoeber, I., Spillane, A.J., Fisher, C., & Thomas, J.M. (2001). Accuracy of biopsy techniques for limb and limb girdle soft tissue tumors. *Annals of surgical oncology*, Vol., 8, No. 1, pp. 80-7, ISSN 1534-4681.
- Hoekstra, H.J. (2008). Extremity perfusion in soft tissue sarcoma. *Surgical oncology clinics of North America*, Vol. 17, No. 4, (October 2008), pp. 805-24, ISSN 1055 3207.
- Issels, R.D., Lindner, L.H., Verweij, J., Wust, P., Reichardt, P., Schem, B-C., Abdel-Rahman, S., Daugaard, S., Salat, C., Wendtner, C-M., Vujaskovic, Z., Wessalowski, R., Jauch, K-W., Durr, H.R., Ploner, F., Baur-Melnk, A., Mansmann, U., Hiddemann, W., Blay, J-Y., & Hohenberger, P. (2010). Neo-adjuvant chemotherapy alone or with regional hyperthermia for localized high-risk soft-tissue sarcoma: a randomised phase 3 multicentre study. *Lancet oncology*, Vol. 11, No 6, (June 2010), pp. 561-70, ISSN 1474-5488.
- Joensuu, H., Eriksson, M., Hartmann, J., Sudby Hall, K., Schutte, J., Reichardt, A., Schlemmer, E., Wardelmann, G., Ramadori, S., Al-Batran, E., Nilsson, B.E., Monge, O., Kallio, R., Sarlomo-Rikala, M., Bono, P., Leinonen, M., Hohenberger, P. Alvegard, T., & Reichardt, P. (2011). Twelve versus 36 months of adjuvant imatinib (IM) as treatment of operable GIST with a high risk of recurrence: final results of a randomized trial. *Journal of clinical oncology*, Vol. 29, No. 18, (June 2011). ISSN 1527-7755.
- Kattan, M.W., Leung, D.H., & Brennan, M.F. (2002). Postoperative nomogram for 12-year sarcoma-specific death. *Journal of clinical oncology*, Vol. 20, No. 3, (February 2002), pp. 791-6, ISSN 1527-7755.
- Kraybill, W.G., Harris, J., Spiro, I.J., Ettinger, D.S., DeLaney, T.F., Blum, R.H., Lucas, D.R., Harmon, D.C., Letson, G.D., & Eisenberg, B. (2006). Phase II study of neoadjuvant chemotherapy and radiation therapy in the management of high-risk, high-grade, soft tissue sarcomas of the extremities and body wall: radiation therapy oncology group trial 9514. *Journal of clinical oncology*, Vol. 24, No.4, (February 2006), pp. 619-25, ISSN 1527-7755.
- Kraybill, W.G., Harris, J, Spiro, I.J., Ettinger, D.S., Delaney, T.F., Blum, R.H., Licas, D.R., Harmon, D.C., Letson, G.D., & Eisenberg, B. (2010). Long-term results of a phase 2 study of neoadjuvant chemotherapy and radiotherapy in the management of high-risk, high-grade, soft tissue sarcomas of the extremities and body wall. *Cancer*, Vol. 116, No. 19, (November 2010), pp. 4613-21, ISSN 1097-0142.
- Kroon, H.M. & Thompson, J.F. (2009). Isolated limb infusion: a review. *Journal of surgical oncology*, Vol. 100, No. 2, (August 2009), pp. 169-77, ISSN1096-9098.

- Kooby, D.A., Antonescu, C.R., Brennan, M.F., & Singer, S. (2004). Atypical lipomatous tumor/ well-differentiated liposarcoma of the extremity and trunk wall: importance of histological subtype with treatment recommendations. *Annals of surgical oncology*, Vol. 11, No. 1, (January 2004), pp. 78-84, ISSN 1534-4681.
- Levine, E.A., Trippon, M., & DasGupta, T.K. (1993). Preoperative multimodality treatment for soft tissue sarcomas. *Cancer*, Vol. 71, No. 11, (June 1993), pp. 3685-9, ISSN 1097-0142.
- Lewis, J.J., Leung, D., Woodruff, J.M., & Brennan, M.F. (1998). Retroperitoneal soft-tissue sarcoma: analysis of 500 patients treated and followed at a single institution. *Annals of surgery*, Vol. 228, No. 3, (September 1998), pp. 355-65, ISSN 0003-4932.
- MacDermid, D.M., Miller, L.L., Peabody, T.D., Simon, M.A., Luu, H.H., Haydon, R.C., Montag, A.G., Undevia, S.D., & Connell, P.P. (2010). Primary tumor necrosis predicts distant control in locally advanced soft-tissue sarcomas after preoperative concurrent chemoradiotherapy. *International journal of radiation oncology, biology, and physiology*, Vol. 76, No. 4, (March 2010), pp. 1147-53, ISSN 0360-3016.
- Mack, L.A., Crowe, P.J., Yang, J.L., Schachar, N.S., Morris, D.G., Kurien, E.C., Temple, C.L.F., Lindsay, R.L., Magi, E., DeHaas, W.G., & Temple, W.J. (2004). Preoperative chemoradiotherapy (modified Eilber protocol) provides maximum local control and minimal morbidity in patients with soft tissue sarcoma. *Annals of surgical oncology*, Vol. 12, No. 8, (August 2004), pp. 646-53, ISSN 1534-4681
- Maduekwe, U.N., Hornicek, F.J., Springfield, D.S., Raskin, K.A., Harmon, D. C., Choy, E. Rosenberg, A.E., Nielsen, G.P., DeLaney, T.F., Chen, Y.L., Ott, M.J., & Yoon, S.S. (2009). Role of sentinel node biopsy in the staging of synovial, epithelioid, and clear cell sarcomas. *Annals of surgical oncology*, Vol. 16, No. 5, (May 2009), pp. 1356-63, ISSN 1534-4681.
- Meric, F., Milas, M., Hunt, K.K., Hess, K.R., Pisters, P.W.T., Hildebrandt, G., Patel, S.R., Benjamin, R.S., Plager, C., Papadopolous, N.E.J., Burgess, M.A., Pollock, R.E., & Feig, B.W. (2000). Impact of neoadjuvant chemotherapy on postoperative morbidity in soft tissue sarcomas. *Journal of clinical oncology*, Vol. 18, No. 19, (October 2000), pp. 3378-83, ISSN 1527-7755.
- Miettinen, M. & Lasota, J. (2006). Gastrointestinal stromal tumors: pathology and prognosis at different sites. *Seminars in diagnostic pathology*, Vol. 23, No. 2, (May 2006), pp. 70-83, ISSN 0740-2570.
- Moncrieff, M.D., Kroon, H.M., Kam, P.C., Stalley, P.D., Scolyer, R.A., & Thompson, J.F. (2008). Isolated limb infusion for advanced soft tissue sarcoma of the extremity. *Annals of surgical oncology*, Vol. 15, No. 10, (October 2008), pp. 2749-56, ISSN 1534-4681.
- Nielsen, T.O. & West, R.B. (2010). Translating gene expression into clinical care: sarcomas as a paradigm. *Journal of clinical oncology*, Vol. 28, No.10, (April 2010), pp. 1796-805, ISSN 1527-7755.
- O'Sullivan, B., Davis, A.M., Turcotte, R., Catton, C.N., Wunder, J., Kandel, R., Goddard, K., Sadura, A., Pater, J., & Zee, B. (2002). Preoperative versus postoperative radiotherapy in soft-tissue sarcoma of the limbs: a randomised trial. *Lancet*, Vol. 359, No. 9325, (June 2002), pp. 2235-41, ISSN 0140-6736.
- Pawlik, T.M., Pisters, P.W.T., Mikula, L., Feig, B.W., Hunt, K.K., Cormier, J.N., Ballo, M.T., Catton, C.N., Jones, J.J., O'Sullivan, B., Pollock, R.E., & Swallow, C.J. (2006). Long-

- term results of two prospective trials of preoperative external beam radiotherapy for localized intermediate- or high-grade retroperitoneal soft tissue sarcoma. *Annals of surgical oncology*, Vol. 13, No. 4, (February 2006), pp. 508-17, ISSN 1534-4681.
- Pervaiz, N., Colterjohn, N., Farrokhyar, F., Tozer, R., Figueredo, A., & Ghert, M. (2008). A systematic meta-analysis of randomized controlled trials of adjuvant chemotherapy for localized resectable soft-tissue sarcoma. *Cancer*, Vol. 113, No. 3, (August 2008), pp. 573-81, ISSN 1097-0142.
- Pisters, P.W., Harrison, L.B., Woodruff, J.M. Gaynor, J.J., & Brennan, M.F. (1994). A prospective randomized trial of adjuvant brachytherapy in the management of low-grade soft tissue sarcomas of the extremity and superficial trunk. *Journal of clinical oncology*, Vol. 12, No. 6, (June 1994), pp. 1150-5, ISSN 1527-7755.
- Pisters, P.W.T., Leung, D.H.Y., Woodruff, J., Shi, W., & Brennan, M.F. (1996). Analysis of prognostic factors in 1,041 patients with localized soft tissue sarcoma of the extremities. *Journal of clinical oncology*, Vol. 14, No. 5, (May 1996), pp. 1679-89, ISSN 1527-7755.
- Pisters, P.W.T., Ballo, M.T., & Patel, S.R. (2002). Preoperative chemoradiation treatment strategies for localized sarcoma. *Annals of surgical oncology*, Vol. 9, No. 6, (July 2002), pp. 535-42. ISSN 1534-4681.
- Pisters, P.W., Ballo, M.T., Fenstermacher, M.J., Feig, B.W., Hunt, K.K., Raymond, K.A., Burgess, M.A., Zagars, G.K., Pollock, R.E., Benjamin, R.S., & Patel, S.R. (2003). Phase I trial of preoperative concurrent doxorubicin and radiation therapy, surgical resection, and intraoperative electron-beam radiation therapy for patients with localized retroperitoneal sarcoma. *Journal of clinical oncology*, Vol. 21, No. 16, (August 2003), pp. 3092-7, ISSN1527-7755.
- Pisters, P.W.T., Patel, S.R., Prieto, V.G., Thall, P.F., Lewis, V.O., Feig, B.W., Hunt, K.K., Yasko, A.W., Lin, P.P. Jacobson, M.G., Burgess, M.A., Pollock, R.E., Zagars, G.K., Benjamin, R.S., & Ballo, M.T. (2004). Phase I trial of preoperative doxorubicin-based concurrent chemoradiation and surgical resection for localized extremity and body wall soft tissue sarcomas. *Journal of clinical oncology*, Vol. 22, No 16, (August 2004), pp. 3375-3380, ISSN1527-7755.
- Pisters, P.W., Pollock, R.E., Lewis, V.O., Yasko, A.W., Cormier, J.N., Respondek, P.M., Feig, B.W., Hunt, K.K., Lin, P.P., Zagars, G., Wei, C., & Ballo, M.T. (2007). Long-term results of prospective trial of surgery alone with selective use of radiation for patients with T1 extremity and trunk soft tissue sarcomas. *Annals of surgery*, Vol. 246, No. 4, (October 2007), pp. 675-81, ISSN 0003-4932.
- Raut, C.P., Pisters, P.W.T. (2006). Retroperitoneal sarcomas: combined-modality treatment approaches. *Journal of surgical oncology*, Vol. 94, No. 1, (July 2006), pp.81-7, ISSN 1096-9098.
- Robertson, J.M., Sondak, V.K., Weiss, S.A., Sussman, J.J., Chang, A.E., & Lawrence, T.S. (1995). Preoperative radiation therapy and iododeoxyuridine for large retroperitoneal sarcomas. *International journal of radiation oncology biology physics*, Vol. 31, No. 1, (January 1995), pp. 87-92, ISSN 0360-3016.
- Rosenberg, S.A., Tepper, j, Glatstein, E. Costa, J., Baker, A., Brennan, M., DeMoss, E.V., Seipp, c., Sindelar, W.F., Sugarbaker, P., & Wesley, R. (1982). The treatment of soft-tissue sarcomas of the extremities: prospective randomized evaluations of (1) limb-sparing surgery plus radiation therapy compared with amputation and (2) the role

- of adjuvant chemotherapy. *Annals of surgery*, Vol. 196, No. 3, (September 1982), pp. 305-15, ISSN 0003-4932.
- Rouesse, J.G., Friedman, S., Sevin, D.M., le Chevalier, T., Spielmann, M.L., Contesso, G., Sarrazin, D.M., & Genin, J.R. (1987). Preoperative induction chemotherapy in the treatment of locally advanced soft tissue sarcomas. *Cancer*, Vol. 60, No. 3, (August 1987), pp. 296-300, ISSN 1097-0142.
- Ryan, C.W., Montag, A.G., Hosenpud, J.R., Samuels, B., Hayden, J.B., Hung, A.Y., Mansoor, A., Peabody, T.D., Mundt, A.J., & Undevia, S. (2008). Histologic response of dose-intense chemotherapy with preoperative hypofractionated radiotherapy for patients with high-risk soft tissue sarcomas. *Cancer*, Vol. 112, No. 11, (June 2008), pp. 2432-9, ISSN 1097-0142.
- Schlemmer, M., Wendtner, C.M., Lindner, L., Abdel-rahman, S., Hiddemann, W., & Issels, R.D. (2010). Thermochemotherapy in patients with extremity high-risk soft tissue sarcoma (HR-STs). *International journal of hyperthermia*, Vol. 26, No. 2, (March 2010), pp. 127-135, ISSN 1464-5157.
- Sindelar, W.F., Kinsella, T.J., Chen, P.W., DeLaney, T.F., Tepper, J.E., Rosenberg, S.A., & Glatstein, E. (1993). Intraoperative radiotherapy in retroperitoneal sarcomas. *Archives of surgery*, Vol. 28, No. 4, (April 1993), pp. 402-10, ISSN 0004-0010.
- Stoeckle E, Coidre, J.B., Bonvalot, S., Kantor, G., Terrier, P., Bonichon, F., Nguyen Bui, B., & French Federation of Cancer Center Sarcoma Group. (2001). Prognostic factors in retroperitoneal sarcoma: a multivariate analysis of a series of 165 patients of the French Cancer Center Federation Sarcoma Group. *Cancer*, Vol. 92, No. 2, pp. 359-68, ISSN 1097-0142.
- Tierney, J.F., Stewart, L.A., & Parmar, M.K.B. (1997). Adjuvant chemotherapy for localized resectable soft-tissue sarcoma of adults: meta-analysis of individual data. *Lancet*, Vol. 350, No. 9092, (December 1997), pp. 1647-54, ISSN 0140-6736.
- Tran, T., Davila, J.A., & El-Serag, H.B. (2005). The epidemiology of malignant gastrointestinal stromal tumors: an analysis of 1,458 cases from 1992 to 2000. *American journal of gastroenterology*, Vol. 100, No. 1, (January 2005), pp. 162-8, ISSN 0002-9270.
- Trent, J.C., Beach, J., Burgess, M.A., Papadopolous, N., Chen, L.L., Benjamin, R.S., & Patel, S.R. (2003). A two-arm phase II study of temozolomide in patients with advanced gastrointestinal stromal tumors and other soft tissue sarcomas. *Cancer*, Vol. 98, No. 12, (December 2003), pp. 2693-99, ISSN 1097-0142.
- Verweij, J., Casali, P.G., Zalcberg, J., LeCesne, A., Reichardt, P., Blay, J.Y., Issels, R., van Oosterom, A., Hogendoorn, P.C., Van Glabbeke, M., Bertulli, R., & Judson, I. (2004). Progression-free survival in gastrointestinal stromal tumors with high-dose imatinib: randomized trial. *Lancet*, Vol. 364, No. 9440, pp. 1127-34, ISSN 0140-6736.
- Verschraegen, C.F., Chawla, S.P., Mita, M.M., Ryan, C.W., Blakely, L., Keedy, V.L., Santoro, A., Buck, J.Y., Maki, J.J., & Lewis, J.J. (2010). A phase II, randomized, controlled trial of palifosfamide plus doxorubicin versus doxorubicin in patients with soft tissue sarcoma (PICASSO). *Journal of clinical oncology*, Vol. 28, No. 15s, (May 2010), pp. 15s, ISSN 1527-7755.
- Wanebo, H.J., Temple, W.J., Popp, M.B., Constable, W., Aron, B., & Cunningham, S.L. (1995). Preoperative regional therapy for extremity sarcoma. A tricenter update. *Cancer*, Vol. 75, No. 9, (May 1995), pp. 2299-2306, ISSN 1097-0142.

- Welker, J.A., Henshaw, R.M., Jelinek, J., Shmookler, B.M., & Malawer, M.M. (2000). The percutaneous needle biopsy is safe and recommended in the diagnosis of musculoskeletal masses. *Cancer*, Vol. 89, No. 12, (December 2000), pp. 2677-86, ISSN 1097-0142.
- White, J.S., Biberdort, D., DiFrancesco, L.M., Kurien, E., & Temple, W.J. (2007). Use of tissue expanders and pre-operative external beam radiotherapy in the treatment of retroperitoneal sarcoma. *Annals of surgical oncology*, Vol. 14, No. 2, (February 2007), pp. 583-90, ISSN 1534-4681.
- Yang, J.C., Chang, A.E., Baker, A.R., Sindelar, W.F., Danforth, D.N., Topalian, S.L., DeLaney, T., Glatstein, E., Steinberg, S.M., Merino, M.J., & Rosenberg, S.A. (1998). Randomized prospective study of the benefit of adjuvant radiation therapy in the treatment of soft tissue sarcomas of the extremity. *Journal of clinical oncology*, Vol. 16, No. 1, (January 1998), pp. 197-203, ISSN 1527-7755.
- Zagars, G.K., Ballo, M.T., Pisters, P.W.T., Pollock, R.E., Benjamin, R.S. & Evans, H.L. (2003). Prognostic factors for patients with localized soft-tissue sarcoma treated with conservation surgery and radiation therapy: an analysis of 1225 patients. *Cancer*, Vol. 97, No. 10, (May 2003), pp. 2530-43, ISSN 1097-0142.



Neoadjuvant Chemotherapy - Current Applications in Clinical Practice

Edited by Dr. Oliver Bathe

ISBN 978-953-307-994-3

Hard cover, 268 pages

Publisher InTech

Published online 01, February, 2012

Published in print edition February, 2012

The most significant advances in cancer therapy in recent years have involved the development of systemic therapeutics. With improvements in response rates in solid tumors, opportunities have arisen to enhance the effectiveness of surgery. Administration of systemic therapy prior to surgery - neoadjuvant chemotherapy - represents one approach by which clinicians have successfully reduced the extent of surgery and, in some instances, positively impacted on clinical outcomes. This collection of works by expert clinicians from a variety of disciplines represents an exploration of the current knowledge of the role of neoadjuvant chemotherapy in diverse tumor types.

How to reference

In order to correctly reference this scholarly work, feel free to copy and paste the following:

Lloyd Mack and Walley Temple (2012). Neoadjuvant Chemotherapy for Soft Tissue Sarcoma of the Extremity or Trunk, Gastrointestinal Stromal Tumors, and Retroperitoneal Sarcoma, Neoadjuvant Chemotherapy - Current Applications in Clinical Practice, Dr. Oliver Bathe (Ed.), ISBN: 978-953-307-994-3, InTech, Available from: <http://www.intechopen.com/books/neoadjuvant-chemotherapy-current-applications-in-clinical-practice/neoadjuvant-chemotherapy-for-soft-tissue-sarcoma-of-the-extremity-or-trunk-gastrointestinal-stromal->

INTECH
open science | open minds

InTech Europe

University Campus STeP Ri
Slavka Krautzeka 83/A
51000 Rijeka, Croatia
Phone: +385 (51) 770 447
Fax: +385 (51) 686 166
www.intechopen.com

InTech China

Unit 405, Office Block, Hotel Equatorial Shanghai
No.65, Yan An Road (West), Shanghai, 200040, China
中国上海市延安西路65号上海国际贵都大饭店办公楼405单元
Phone: +86-21-62489820
Fax: +86-21-62489821

© 2012 The Author(s). Licensee IntechOpen. This is an open access article distributed under the terms of the [Creative Commons Attribution 3.0 License](#), which permits unrestricted use, distribution, and reproduction in any medium, provided the original work is properly cited.