

Acellular Dermal Matrix for Optimizing Outcomes in Implant-Based Breast Reconstruction: Primary and Revisionary Procedures

Ron Israeli

*Hofstra North Shore-LIJ School of Medicine
USA*

1. Introduction

The benefits of using acellular dermal matrices (ADMs) in implant-based breast reconstruction have recently been reported both for primary reconstructions as well as revisionary procedures. Techniques using ADMs in these settings have been shown to assist in controlling implant position by defining the inframammary fold (IMF) and lateral mammary fold (LMF). In addition, they may provide a decreased risk of capsular contracture and may be used in the management of already developed contractures. The purpose of this chapter is to review the newest trends in the use of ADMs in implant-based breast reconstruction. A direct-to-implant approach to primary breast reconstruction following nipple-areola sparing mastectomy (NASM) is detailed and the revisionary procedures highlighted include the correction of implant malposition and the management of capsular contracture.

2. Primary reconstruction

Immediate direct-to-implant breast reconstruction after skin-sparing or NASM (Breuing & Warren, 2005; Breuing & Colwell, 2007; Cassileth et al., 2011; Salzberg, 2006; Salzberg et al., 2011; Topol et al., 2008; Wang et al., 2008; Zienowicz & Karacaoglu, 2007) is gaining popularity as a viable alternative to immediate expander/implant reconstruction which is the current standard of care for implant-based breast reconstruction postmastectomy (American Society of Plastic Surgeons [ASPS], 2009). While both approaches allow immediate creation of the breast mound offering psychologic and aesthetic benefits, the direct-to-implant approach allows maximal use of the preserved mastectomy skin at the time of reconstruction. This eliminates the need for serial tissue expansions and potentially avoids a second surgery.

The use of ADMs has greatly facilitated direct-to-implant as well as expander/implant reconstruction. By extending the reach of the pectoralis major muscle, ADMs not only provide complete coverage of the subpectorally placed implant or expander but they also increase the volume of the subpectoral pocket. In expander/implant reconstructions, the increased

subpectoral volume allows greater initial expansion of the expander, thus reducing the total number of expansions and time to full expansion (Collis et al., 2011; Hanna et al., 2011; Spear et al., 2008). In direct-to-implant reconstructions, the increased subpectoral volume allows a permanent implant to be placed in suitable patients. Several series have reported low complication rates and good aesthetic outcomes with ADM-assisted direct-to-implant reconstruction (Breuing & Warren, 2005; Breuing & Colwell, 2007; Cassileth et al., 2011; Salzberg, 2006; Salzberg et al., 2011; Topol et al., 2008; Zienowicz & Karacaoglu, 2007) that are comparable to those reported with ADM-assisted expander/implant reconstructions (S. Becker et al., 2009; Newman et al., 2011; Rawlani et al., 2011). In particular, in the largest series (260 patients representing 466 reconstructions) with the longest follow-up (mean 28.9 months; range 0.3-97.7 months), the overall complication rate was 3.9%. Complications included implant loss 1.3%, skin breakdown/necrosis 1.1%, hematoma 1.1%, ADM exposure 0.6%, capsular contracture 0.4%, and infection 0.2% (Salzberg et al., 2011).

2.1 Review of experience

The author's initial clinical experience with the use of ADM-assisted immediate direct-to-implant reconstruction following NASM consists of 47 reconstructions (24 therapeutic and 23 prophylactic) performed in 27 patients from January 2007 to June 2009 (Israeli et al., 2011). Patients were selected to undergo ADM-assisted immediate direct-to-implant reconstruction if they were not candidates for or did not desire an autologous procedure. Patients had an average age of 49 years (range 27-72 years). During the early postoperative period (<30 days) complications occurred in 21 breasts and included mild nipple-areola skin slough (13), moderate nipple-areola skin slough (2), full-thickness nipple loss (2), cellulitis (3), and capsular contracture (1). All cases of nipple-areola skin slough were resolved with local care and all cases of cellulitis were resolved with oral antibiotics. There were no cases of device loss or failed reconstruction during an average follow-up period of 17 months (range 2-28 months). There was one case of NA occult tumor that required NA removal. Two patients required revisionary surgery; one patient underwent implant exchange as she desired a larger implant and the other underwent nipple reconstruction to regain nipple projection after nipple flattening. Our results suggest that ADM-assisted direct-to-implant breast reconstruction can be reliably accomplished after NASM and are in concordance with other published series of ADM-assisted direct-to-implant reconstruction (Breuing & Warren, 2005; Breuing & Colwell, 2007; Cassileth et al., 2011; Salzberg, 2006; Salzberg et al., 2011; Topol et al., 2008; Zienowicz & Karacaoglu, 2007).

The success of direct-to-implant reconstruction after NASM is dependent on proper patient selection. Patients with evidence of direct nipple involvement of tumor, Paget's disease, inflammatory breast cancer, tumor size > 3 cm, or tumor < 2 cm from nipple center may not be suitable candidates for NASM because of an increased risk of local tumor recurrence (Brachtel et al., 2009; Cunnick & Mokbel, 2006). Following NASM, the quality of the preserved skin is an important consideration for direct-to-implant reconstruction because extremely thin skin or compromised skin increases the risk of ischemia and skin necrosis which can eventually lead to implant loss (Woerdeman et al., 2006). Moreover, patients with preoperative macromastia or breast ptosis who undergo direct-to-implant reconstruction are at increased risk of perioperative complications and revisionary surgery (Roostaeian et al.,

2011). Further, age > 65 years and comorbid conditions such as smoking, obesity, and hypertension increase the risk of perioperative complications and the latter three also increase the risk of reconstructive failure (McCarthy et al., 2008). Thus, a careful evaluation of these risk factors needs to be taken into consideration when selecting patients for direct-to-implant reconstruction.

2.2 Operative details

The use of ADM to extend the pectoralis major muscle at the lower pole to provide complete soft tissue coverage of the implant (Figure 1) has been previously described (Breuing & Warren, 2005; Salzberg, 2006; Zienowicz & Karacaoglu, 2007). NASM is performed via a periareolar incision (Figures 2A & 2B). In some patients, a lateral extension to the periareolar incision may be required to facilitate mastectomy. Following

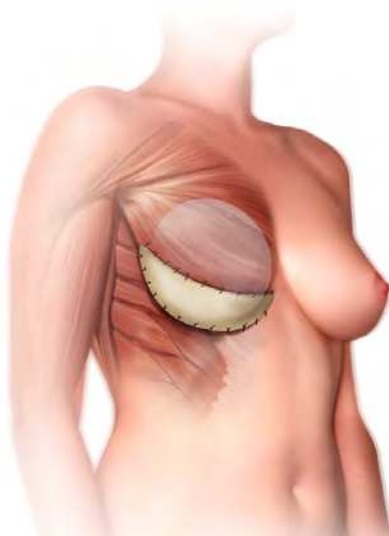


Fig. 1. ADM placement at the inferolateral border of the implant.

mastectomy, nipple coring is performed (Figure 2C) and specimens are taken and sent for permanent fixation and evaluation of tumor presence. Immediate reconstruction is then performed with subpectoral implant placement. The inferolateral origin of the pectoralis major muscle is elevated off the chest wall and a subpectoral pocket is created based on the dimensions of the previous breast perimeter and the desired implant size. The LMF is defined and marked on the chest wall in continuity with the IMF. A prehydrated sheet of ADM (AlloDerm®, human acellular dermal matrix, LifeCell Corporation, Branchburg, NJ) is then sutured to the chest wall using running 2-0 Vicryl sutures (Ethicon, Inc., Somerville, NJ) along the marked fold. The deep dermal side of the ADM is placed facing the overlying lower breast skin. An implant is introduced into the subpectoral pocket under the muscle. The ADM is then brought over the implant, tapered as needed, and secured to the free border of the pectoralis muscle using running 2-0 Vicryl sutures,

completely covering the implant (Figure 2D). Mastectomy flaps are then tailored as necessary and closed in layers over two closed suction drains brought out laterally. One drain is placed between the ADM and the overlying skin at the IMF and a second drain is placed deep to the superior mastectomy skin.

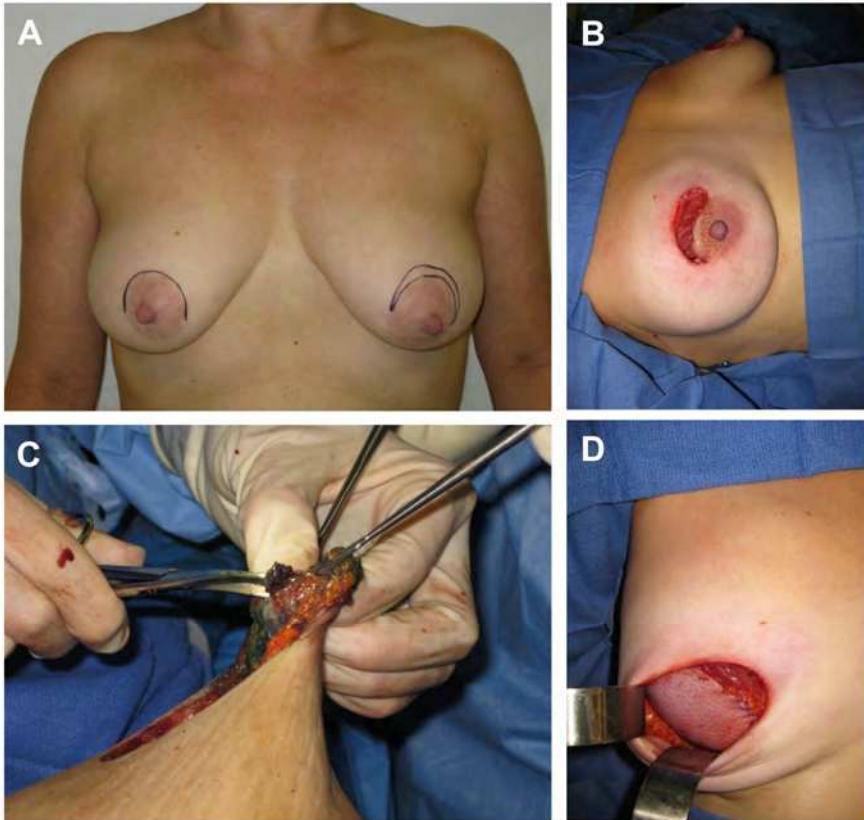


Fig. 2. Operative details. A: Preoperative markings. B: Periareolar incision. C: Nipple coring. D: ADM-assisted reconstruction.

2.3 Patient cases

Case 1

Patient is a 53-year-old with the BRCA 2 genetic mutation and a family history of breast cancer. She opted to undergo prophylactic mastectomy with immediate implant-based breast reconstruction. Physical examination revealed no contraindications for NASM. She had nearly symmetric B-cup breasts with grade 2 ptosis (Figure 3). Patient underwent NASM via the supra-areolar approach. Immediate ADM-assisted, direct-to-implant breast reconstruction was performed with 400 cc, smooth round gel implants. Her postoperative course was uneventful. At 11-month follow-up, she exhibited good symmetry, lower-pole projection, and volume match compared with preoperative size with well-camouflaged periareolar scars.

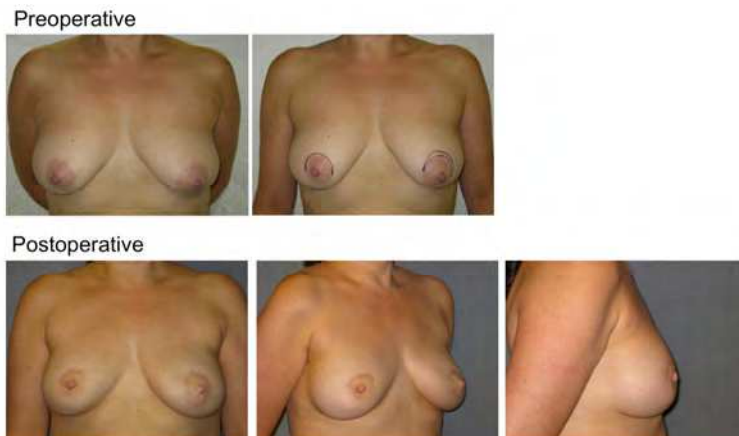


Fig. 3. A 53-year-old patient who underwent bilateral prophylactic mastectomy via the supra-areolar approach and received smooth round gel implants. Her postoperative course was uneventful. Postoperative: at 11 months follow-up.

Case 2

Patient is a 46-year-old diagnosed with right invasive ductal carcinoma. She elected to undergo right therapeutic mastectomy and left prophylactic mastectomy. There were no contraindications to proceeding with NASM. She had bilateral B-cup breasts with a slightly more ptotic right side. Patient underwent bilateral NASM via the supra-areolar approach with immediate ADM-assisted breast reconstruction using 325 cc smooth round gel implants. She had an uneventful postoperative course. At 4-month follow-up, she had good implant position, breast symmetry, and a well-healed periareolar scar.

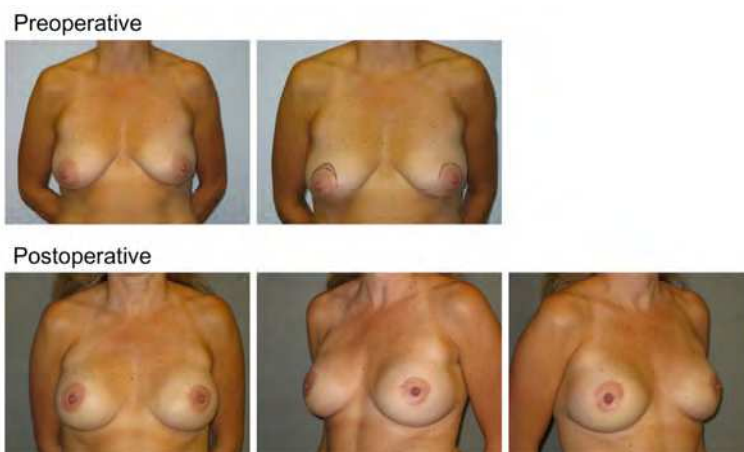


Fig. 4. A 46-year-old patient who underwent bilateral mastectomy, left prophylactic and right therapeutic for invasive ductal carcinoma, via the supra-areolar approach and received smooth round gel implants. Postoperative: at 4 months follow-up.

3. Revisionary procedures

Implant-based reconstruction is the most widely used approach to breast reconstruction postmastectomy because of its simplicity (ASPS, 2009). As opposed to autologous procedures, it is technically less demanding, has shorter operative times, results in brief hospital stays, has decreased short-term costs, and has no associated donor site morbidity (Ahmed et al., 2005). In addition, good to excellent aesthetic outcomes and high patient satisfaction have been reported with this approach (Cordeiro & McCarthy, 2006). Despite these benefits, implant-based reconstruction is not without concerns; it is associated with a high rate of implant-related complications notably capsular contracture, implant malposition, asymmetry, and rippling (Cunningham & McCue, 2009; Handel et al, 2006; Spear et al, 2007). Consequently, rates of revisionary surgery are also high; approximately 34%-52% of reconstruction patients undergo revision surgery within 3-6 years of their primary procedure and 36% of revision reconstruction patients undergo further revisionary surgery (Cunningham & McCue, 2009; Handel et al, 2006; Spear et al, 2007).

Corrective techniques for capsular contracture, implant malposition, and rippling have traditionally involved capsulotomy or capsulectomy, implant pocket change, implant replacement, use of capsular flaps, or a combination of these (Baxter, 2003; Maxwell & Gabriel, 2009). These techniques, however, have not always been reliable and recurrence is common (H. Becker et al, 2005; Chasan & Francis, 2008; Massiha, 2002; Spear et al., 2003). Given the safety, efficacy, and aesthetic results obtained with the use of ADM in primary breast reconstruction, there is an emerging trend to use ADM for the correction and prevention of implant-related complications in both reconstructive and aesthetic patients. The feasibility of using ADM for the correction of visible implant rippling and breast deformities due to implant malposition was initially reported almost a decade ago in breast reconstruction and aesthetic patients (Baxter, 2003; Duncan, 2001). Since then several studies have demonstrated a significant reduction in recurrence and improved cosmesis with the use of ADM for the correction of capsular contracture, implant malposition, and rippling (Breuing & Colwell, 2007; Maxwell & Gabriel, 2009; Grabov-Nardini et al., 2009; Hartzell et al., 2010; Spear et al., 2011). Overall, > 87% of implant-related complications were successfully managed using ADMs. Although promising, it should be noted that the follow-up period in most of these studies was relatively short averaging 9-12 months which may not be sufficiently long to evaluate recurrence rates.

3.1 Correction of implant malposition

Implant malposition manifesting as inferior, medial (symmastia), or lateral malposition is a commonly encountered complication of implant-based reconstructions. In primary reconstruction patients, a 20% reoperation rate due to implant malposition has been reported over a 6-year period (Spear et al., 2007). A number of factors may cause implant malposition including inadequate or excessive pocket dissection; overzealous release of the IMF, lateral and/or medial release of breast tissues, or lateral and/or medial release of the pectoralis major muscle; placement of excessively large implants; or attenuated capsular tissues (Baxter, 2003). Traditional approaches to surgical correction of implant malposition have included capsulorrhaphy with or without mirror-image capsulotomy (Chasan, 2005; Chasan & Francis, 2008; Spear & Little, 1988), implant site change from subglandular to

subpectoral or subpectoral to neosubpectoral (Maxwell et al., 2009; Spear et al., 2009), and use of an adjustable implant (H. Becker et al., 2005). These approaches are often technically demanding and not always reliable (Spear et al., 2011). Capsulorrhaphy, the mainstay of corrective surgery, often does not sufficiently prevent the implant from falling against the suture line or moving across it (Voice & Carlsen, 2001). Consequently, reinforcement of the suture line with capsular flaps has been attempted (Voice & Carlsen, 2001) and a recent case study has noted success with this technique, albeit with a short follow-up period of 3-6 months (Yoo & Lee, 2010). However, capsular flaps have limited applicability in patients with attenuated capsules who are unlikely to have adequate tissue. As an alternative to capsular flaps, recent studies have advocated the use of ADM to reinforce the capsulorrhaphy suture line and maintain the implant within its pocket (Maxwell & Gabriel, 2009; Hartzell et al., 2010; Spear et al., 2011). In addition, the use of ADM also helps to redefine the IMF and LMF. Successful correction of implant malposition has been reported with the use of ADM with good aesthetic results, no recurrence, and minimal complications and failures.

3.1.1 Review of experience

The author's initial clinical experience with the correction of implant malposition with ADM assistance is derived from 12 patients who collectively had 21 inferior and lateral implant malpositions (Israeli & Cody, 2011). Patients were treated between December 2009 and March 2010. All patients underwent corrective surgery as described below with ADM reinforcement of the capsulorrhaphy suture line. Patients have been followed for a mean of 7 months (range 3-15 months) with no evidence of complications or recurrences. Proper implant position was reestablished in all patients with well-defined folds.

3.1.2 Operative details

The technique of using ADM to reinforce fold correction after capsulorrhaphy has been recently reported (Spear et al., 2011). The essential steps of corrective surgery include fold recreation by capsulorrhaphy, reinforcement of the fold with overlapping ADM secured to capsule, and pocket size correction, including mirror image capsulotomy when necessary (Figure 5).

Preoperatively, planned capsulorrhaphy fold correction and IMF position are marked with the patient in the upright standing position (Figure 6). The implant is accessed and removed via the previous mastectomy incision. If needed, the new IMF location can be remarked intraoperatively with the help of 25-gauge needles (Figures 7A & 7B). A capsulorrhaphy is then performed to create the new IMF and LMF with several rows of running 0-TiCron™ sutures (Covidien, Mansfield, MA) to the chest wall (Figure 7C). The desired fold location can be verified with the help of a sizer or implant. If needed, a superior capsular incision is made along the entire superior aspect of the breast to allow for improved implant positioning. The newly created IMF and IMF positions are then reinforced with a sheet of prehydrated ADM (AlloDerm) (Figure 7D). The ADM is placed over the fold suture line, with its deep dermal side facing the skin flaps, overlapping ~1.5 to 2 cm on either side of the repair. It is secured with multiple interrupted or with running 2-0 Vicryl sutures through the capsule to the chest wall posteriorly and to the capsule over

the anterior surface along the entire length of the IMF and LMF. A new implant is introduced into the pocket and muscle, capsule, and skin closure are performed completing the corrective surgery (Figure 8).

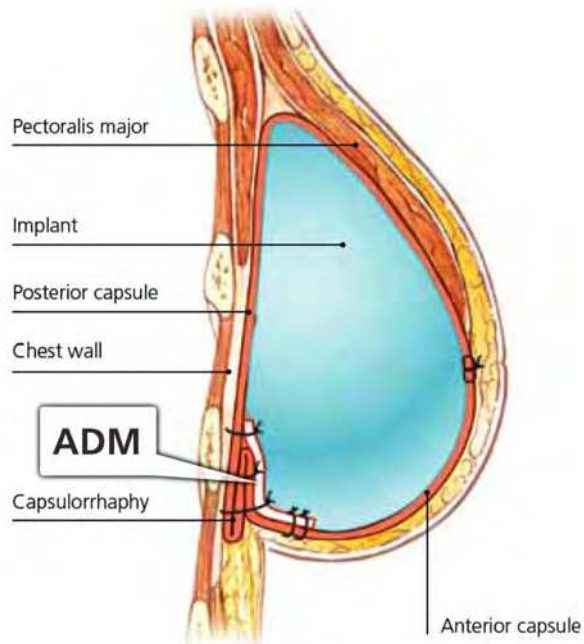


Fig. 5. Schematic representation of ADM reinforcement of recreated IMF and LMF. Illustration with permission from LifeCell Corporation (Branchburg, New Jersey).

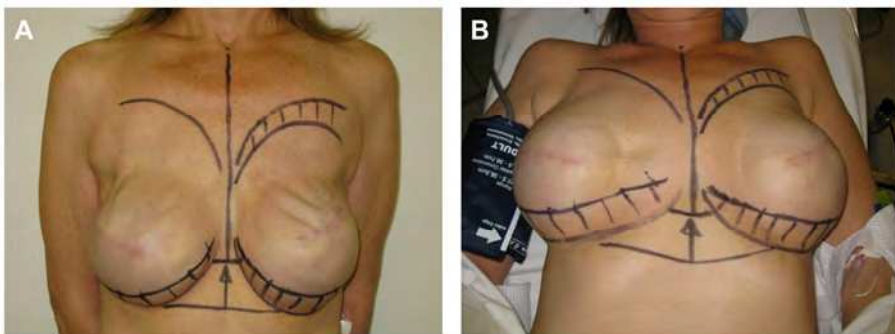


Fig. 6. Preoperative markings. A: Midline, planned capsulorrhaphy fold corrections, and planned IMF positions are marked with patient upright. The extent of inferior malposition is noted in this position. B: Examination of the patient in the supine position reveals the extent of lateral malposition.

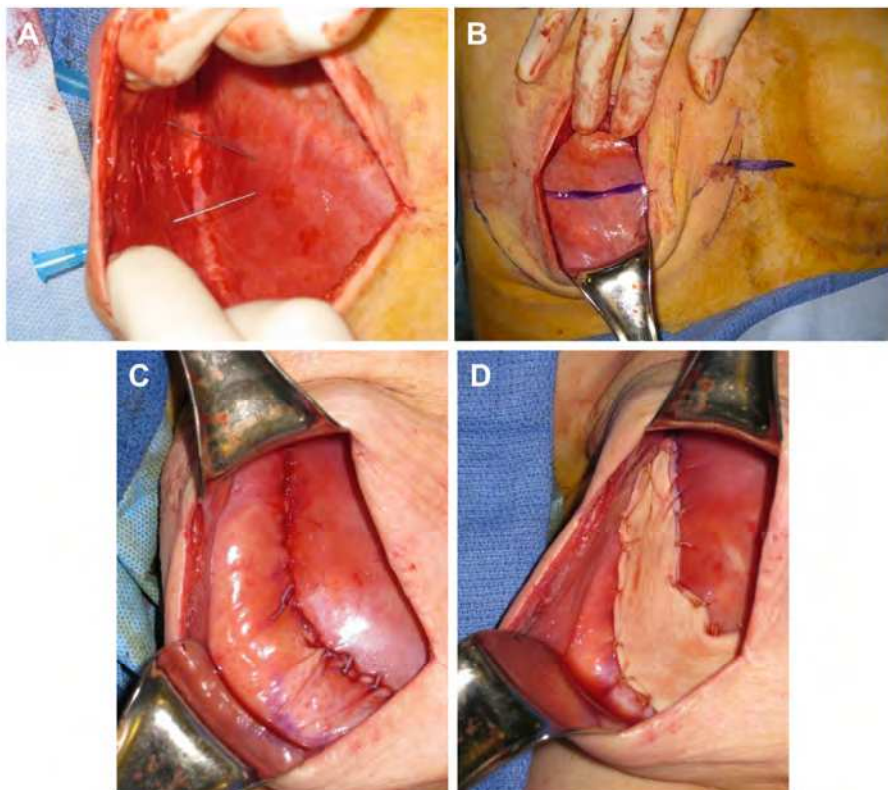


Fig. 7. Intraoperative view. A: The location of the new IMF is defined intraoperatively with the help of 25-gauge needles. B: The blue marking on the capsule indicates the new IMF position. C: Recreation of the new IMF and LMF by capsulorrhaphy. D: Reinforcement of the capsulorrhaphy suture line with ADM.

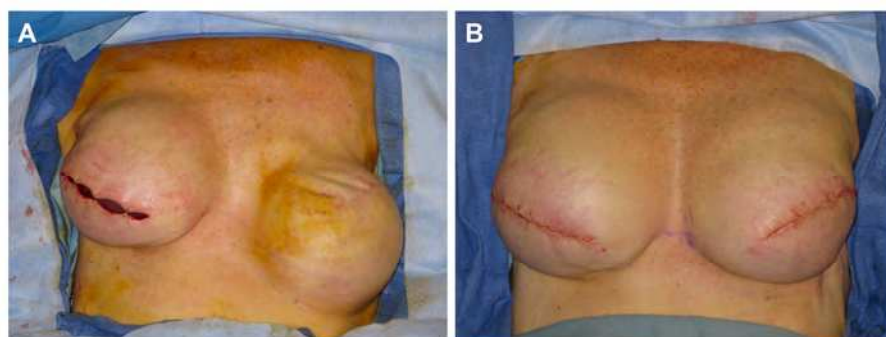


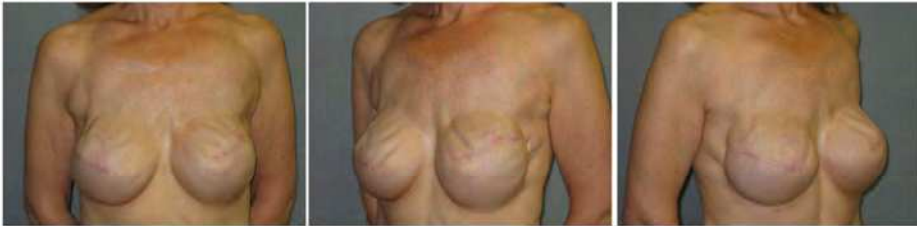Fig. 8. Immediate postoperative stage. A: Revisionary surgery completed on right breast; implant is repositioned higher up on the chest wall compared with the unrevised left breast. B: Completion of revisionary surgery on the left breast establishes symmetry.

3.1.3 Patient cases

Case 3

A 48-year-old woman with a history of lobular carcinoma in situ presented with inferior implant malposition, breast asymmetry, and severe implant rippling at the superomedial aspect of her breasts after second stage bilateral tissue expander/implant reconstruction (Figure 9). Her implant-related problems were due to loss of IMFs and LMFs. To address these, she underwent bilateral recreation of the folds by capsulorrhaphy. Because she had thinned tissue, her native tissues were insufficient to reinforce the folds and ADM was used to reinforce the folds. An implant exchange was also performed and her silicone implants (450 cc) were replaced with slightly larger silicone implants (475 cc) to better fit the pocket size correction. The larger implants would also help toward reducing rippling. At 7 months post-revisionary surgery, the patient exhibited well-proportioned, symmetrical breasts with good contour as a result of well-defined IMFs and LMFs. Implant rippling was greatly reduced.

Preoperative



Postoperative

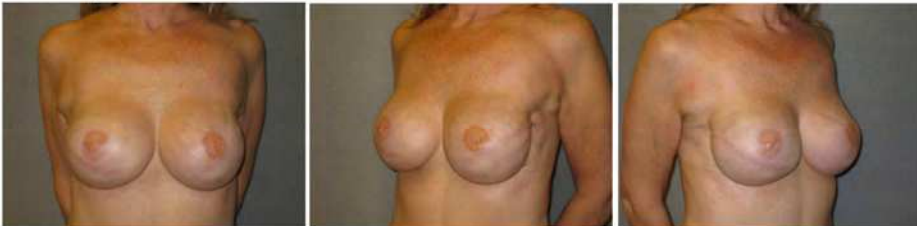

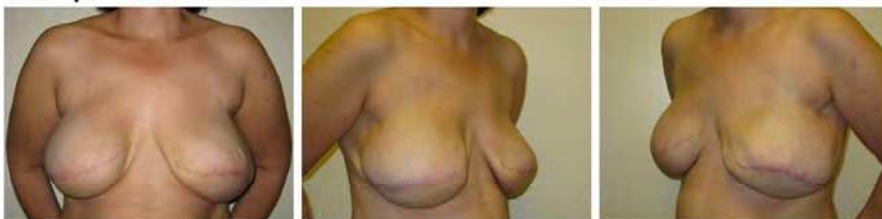Fig. 9. Preoperative stage: patient presented with implant malposition, asymmetry, and significant implant rippling after second stage bilateral tissue expander/implant breast reconstruction. Postoperative stage: at 7 months of follow-up (with interim nipple-areola reconstruction) after correction of implant malposition using the technique described. The IMF and LMF are well-defined and rippling is improved.

Case 4

A 45-year-old woman with a history of left breast cancer presented with implant malposition and significant rippling after first stage bilateral tissue expander breast reconstruction. She was found to have inferior and lateral implant malposition as well as excess breast skin laxity with rippling. She underwent bilateral IMF and LMF correction with capsulorrhaphy. Each fold repair was reinforced with ADM and the breast skin

envelope was tapered to accommodate 450 cc silicone gel implants. At 7 months after undergoing expander-implant exchange with revision reconstruction, the patient is found to have good breast contour and symmetry. Due to the improved balance between her breast skin, fold placement and implant position, her rippling is markedly reduced.

Preoperative



Postoperative

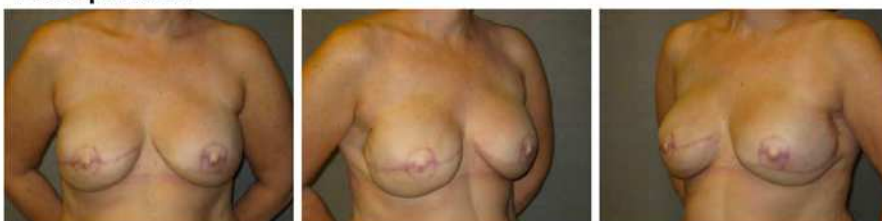

Fig. 10. Preoperative stage: patient presented with implant malposition and significant rippling after first stage bilateral tissue expander breast reconstruction. Postoperative stage: at 7 months of follow-up (with interim nipple-areola reconstruction) after correction of implant malposition using the technique described. The IMF and LMF are well-defined and rippling is improved.

3.2 Correction of capsular contracture

Capsular contracture is the most common complication associated with implant-based breast reconstruction (Adams, 2009). Core clinical studies from device manufacturers have reported a 6-year cumulative incidence of capsular contracture rate of 14%-16% in primary and 25% in revision reconstruction patients (Cunningham & McCue, 2009; Spear et al., 2007). Capsular contracture was also the most common reason for revisionary surgery in these studies.

The true cause of capsular contracture is unknown. Current evidence suggests that subclinical infection with biofilm-forming or nonbiofilm-forming bacteria may be a primary cause. A causal link between subclinical infection, biofilm formation, and capsular contracture has been demonstrated in a recent porcine study (Tamboto et al., 2010). Irrespective of the cause of capsular contracture, it is believed that inflammation at the cellular level eventually leads to pathologic capsular contracture (Adams, 2010). Support for this hypothesis comes from a clinical study where foreign body inflammatory response in capsular tissue was shown to be directly correlated to capsule thickness and Baker score (Prantl et al., 2007).

Traditionally, corrective surgery for capsular contracture has entailed open capsulotomy or partial/total capsulectomy, followed by implant site change, and implant exchange (Maxwell & Gabriel, 2009), although this does not always prevent recurrence. More recently, ADMs have been used at the inferolateral pole after capsulotomy or capsulectomy to help correct and prevent capsular contracture (Breuing & Colwell, 2007; Hartzell et al., 2010; Maxwell & Gabriel, 2009; Spear et al., 2011). In ADM-assisted implant-based primary reconstructions, a low rate of capsular contracture (0%-2%) has been observed (S. Becker et al., 2009; Bindingnavele et al., 2007; Breuing & Colwell, 2007; Namnoum, 2009; Salzberg, 2006; Salzberg et al., 2011; Spear et al., 2008; Zienowicz & Karacaoglu, 2007), suggesting that ADMs may help prevent or reduce the risk of capsular contracture; hence, the rationale for using ADMs for the correction and prevention of capsular contracture. Animal and clinical studies suggest that ADMs may prevent capsular contracture by minimizing the inflammatory response, thereby reducing capsule formation around implants (Basu et al., 2010; Komorowska-Timek et al., 2009; Orenstein et al., 2010; Stump et al., 2009; Uzunismail et al., 2008). Published series have reported successful correction of > 90% of grade 3/4 capsular contractures with the use of ADMs with no recurrences during a mean follow-up period of 9-21 months (Breuing & Colwell; 2007; Maxwell & Gabriel, 2009; Hartzell et al., 2010; Spear et al., 2011).

3.2.1 Review of experience

Between November 2005 and April 2010, the author used ADM for the correction of capsular contracture (grade 3 or 4) in 18 patients (21 breasts) (Israeli, 2011). All patients developed capsular contracture after tissue expander/implant reconstruction postmastectomy. Nine breasts had received prior radiotherapy. During a follow-up period of 3-43 months, initial successful correction of capsular contracture (ie, achievement of grade ≤ 2) was noted in 17 patients. There was 1 case of early post-operative cellulitis requiring oral antibiotics in a patient with a history of radiotherapy who later developed recurrent contracture. There were no cases of implant loss.

3.2.2 Operative details

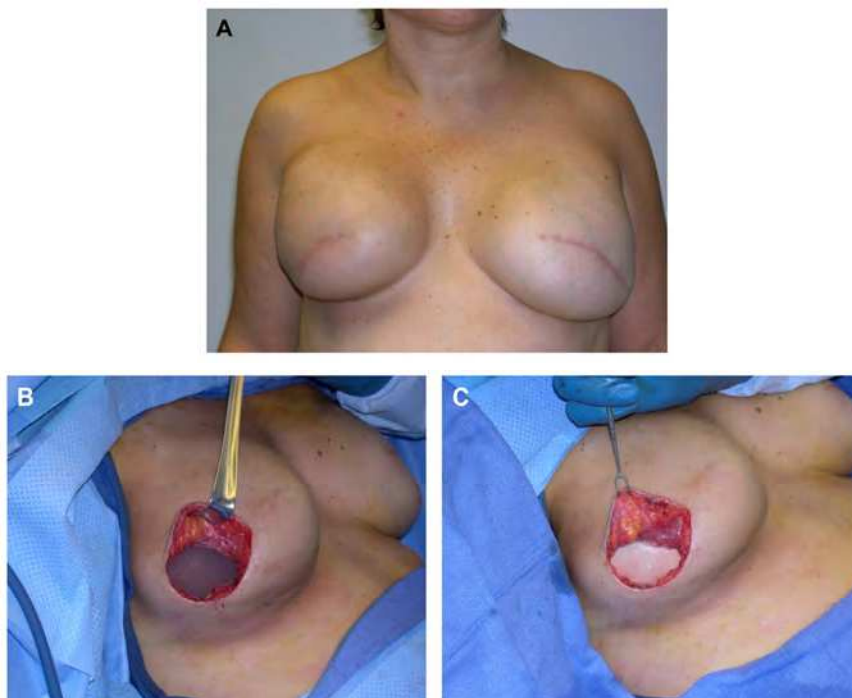
We have previously described the technique of using ADM for the correction of capsular contracture (Israeli & Feingold, 2011) which is essentially the same as for a primary reconstruction (Figure 1). Key steps of corrective surgery include capsulectomy, expansion of implant pocket using a sheet of ADM, and redefining the IMF and LMF. Using the previous mastectomy incision, the implant or expander is accessed and removed. A circumferential capsulotomy is performed around the implant pocket at the level of the chest wall and the inferolateral border of the pectoralis major muscle is mobilized. A partial anterior capsulectomy is performed, the extent of which depends on capsule thickness, recreating the original inferolateral defect postmastectomy prior to primary reconstruction. Steps are then taken to correct this defect by recreating the IMF and LMF as in a primary reconstruction. A sheet of prehydrated ADM (AlloDerm) of standard thickness is utilized to recreate the inframammary and lateral mammary folds. The size of ADM used is dependent on the extent of capsulectomy performed. The ADM is placed at the inferolateral border of the breast and is secured laterally, inferiorly, and medially to the chest wall with 2-0 Vicryl sutures. The ADM is placed with the deep

dermal side facing the inferior breast skin. A new implant is introduced into the pocket and with the patient in a sitting position proper implant and inframammary fold position are verified. The superior edge of the ADM is then sutured to the elevated lower border of the pectoralis major muscle or to the superior border of the capsulectomy defect. Through a separate lateral stab incision, one closed suction drain is placed along the inframammary fold between the ADM and the skin flap inferiorly where the capsulectomy was completed. Final incision closure is performed in standard fashion.

3.2.3 Patient cases

Case 5

A 44-year-old woman with a history of infiltrating ductal carcinoma and ductal carcinoma-in-situ on her right breast presented with right capsular contracture (grade 3) after first stage bilateral ADM-assisted expander reconstruction (Figure 11A). Capsular contracture developed secondary to radiotherapy. Corrective surgery for capsular contracture was performed in conjunction with second stage implant reconstruction and included capsulectomy (Figure 11B) followed by expansion of the implant pocket using a sheet of ADM (AlloDerm) and repositioning of the IMF (Figure 11C). On the left breast, excess skin was excised laterally to improve the breast contour during exchange. No complications occurred during a follow-up period of 10 months (Figures 11D & 11E). Capsular contracture was successfully treated and breast projection and ptosis on the irradiated side were well-matched to the contralateral nonirradiated side.



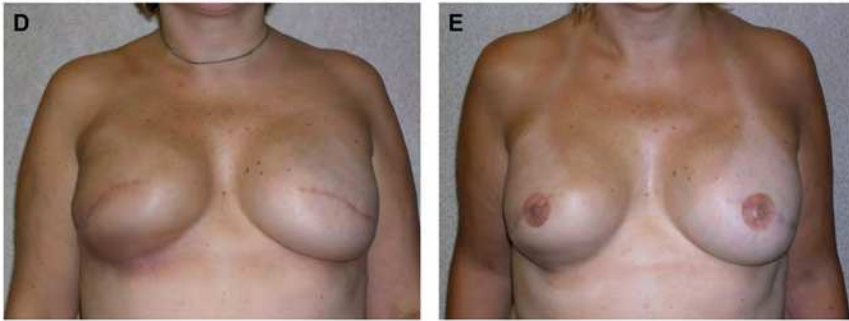
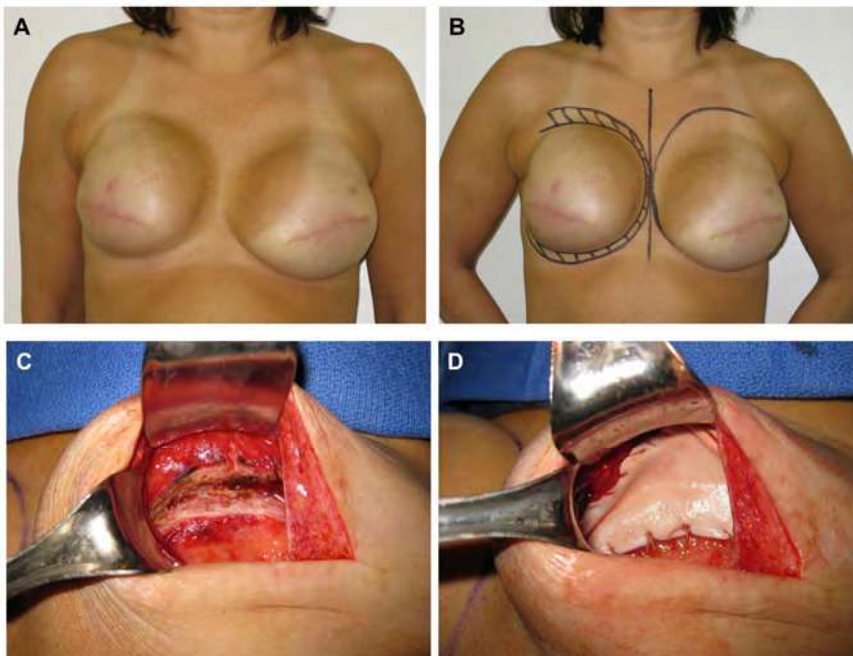


Fig. 11. Correction of capsular correction in the setting of radiation. A: Right breast capsular contracture after bilateral ADM-assisted expander reconstruction followed by postoperative radiation of the right breast. B: Expander exchange for implant after capsulectomy. C: ADM used in redefining the pocket. D: At 3 months postoperative. E: At 10 months postoperative with interim nipple areola reconstruction and tattooing.

Case 6

A 46-year-old woman presented with early right capsular contracture (grade 3) and left inferior implant malposition after ADM-assisted implant reconstruction (Figures 12A & 12B). On her right breast, she underwent partial capsulectomy at the IMF (Figure 12C) followed by reinforcement of the capsulectomy site with ADM (Figure 12D) as corrective



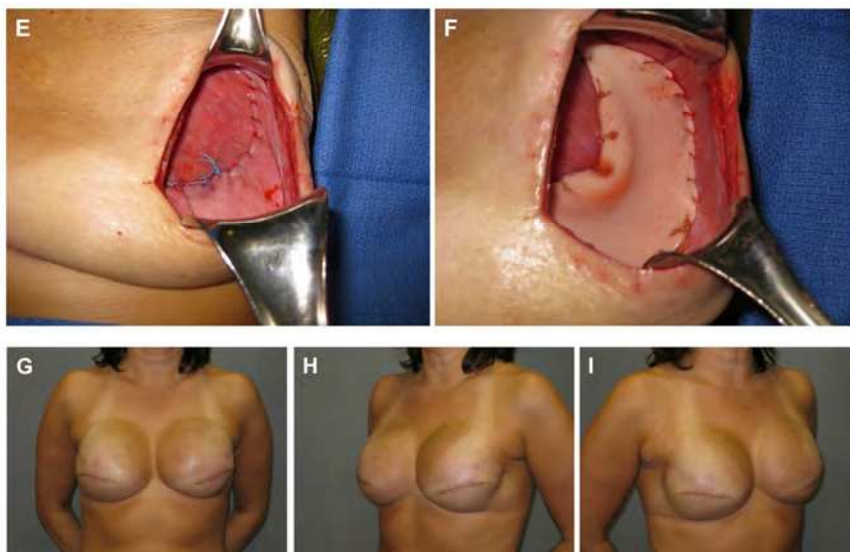


Fig. 12. Correction of right breast capsular contracture and correction of left breast inferior malposition. A: Early right capsular contracture and left malposition after bilateral ADM-assisted implant reconstruction. B: Planned corrective surgery included right capsulotomy with ADM reinforcement and left IMF/LMF capsulorrhaphy with ADM reinforcement. C: Right breast after IMF capsulotomy. D: Right breast, ADM secured in place overlapping IMF capsulotomy. E: Left breast after IMF and LMF capsulorrhaphy. F: Left breast, ADM secured in place reinforcing IMF and LMF capsulorrhaphy. G-I: At 4 months postoperative.

surgery for capsular contracture. On her left breast, she underwent capsulorrhaphy at the IMF and LMF (Figure 12E) with reinforcement of suture lines with ADM (Figure 12F) to address implant malposition. Both breasts were fitted with new implants. Four-month postoperative photographs showed correction of capsular contracture and inferior malposition (Figures 12G-I).

4. Conclusion

ADMs have become an integral part of implant-based breast reconstruction with the expectation that their use would result in low complication rates, improved aesthetic outcomes, and greater patient satisfaction. In the setting of immediate postmastectomy breast reconstruction, the ADM acts as an extension to the pectoralis muscle thereby allowing a direct-to-implant and potentially single-stage approach. This technique is particularly effective in patients that are candidates for NASM, where the entire breast skin envelope is preserved. Emerging evidence also indicates that ADMs may play a role in revisionary surgery assisting in reestablishing proper implant positioning and preventing capsular contracture. The ability of ADMs to fulfill these roles is attributed to their biomechanical properties of strength and pliability and biologic property of supporting tissue regeneration.

5. Acknowledgement

The author would like to thank LifeCell Corporation (Branchburg, NJ) for editorial assistance.

6. References

- Adams, W. P., Jr. (2009). Capsular contracture: What is it? What causes it? How can it be prevented and managed? *Clinics in Plastic Surgery*, Vol.36, No.1, (January 2009), pp. 119-126, vii, ISSN 0094-1298
- Adams, W. P., Jr. (2010). Discussion: Subclinical (biofilm) infection causes capsular contracture in a porcine model following augmentation mammoplasty. *Plastic and Reconstructive Surgery*, Vol.126, No.3, (September 2010), pp. 843-844, ISSN 0032-1052
- Ahmed, S., Snelling, A., Bains, M., & Whitworth, I. H. Breast reconstruction. (2005). *British Medical Journal*, Vol.330, No.7497, (April 2005), pp. 943-948, ISSN 0959-8138
- American Society of Plastic Surgeons. (2010). 2009 Reconstructive Breast Procedures. In: *American Society of Plastic Surgeons*, September 13, 2011, Available from <http://www.plasticsurgery.org/Documents/news-resources/statistics/2009-statistics/2009breastreconsurgery.pdf>
- Basu, C. B., Leong, M., & Hicks, M. J. (2010). Acellular cadaveric dermis decreases the inflammatory response in capsule formation in reconstructive breast surgery. *Plastic and Reconstructive Surgery*, Vol.126, No.6, (December 2010), pp. 1842-1847, ISSN 0032-1052
- Baxter, R. A. (2003). Intracapsular allogenic dermal grafts for breast implant-related problems. *Plastic and Reconstructive Surgery*, Vol.112, No.6, (November 2003), pp. 1692-1696, ISSN 0032-1052
- Becker, H., Shaw, K. E., & Kara, M. (2005). Correction of symmastia using an adjustable implant. *Plastic and Reconstructive Surgery*, Vol.115, No.7, (June 2005), pp. 2124-2126, ISSN 0032-1052
- Becker, S., Saint-Cyr, M., Wong, C., Dauwe, P., Nagarkar, P., Thornton, J. F., & Peng, Y. (2009). AlloDerm versus DermaMatrix in immediate expander-based breast reconstruction: a preliminary comparison of complication profiles and material compliance. *Plastic and Reconstructive Surgery*, Vol.123, No.1, (January 2009), pp. 1-6, ISSN 0032-1052
- Bindingnavele, V., Gaon, M., Ota, K. S., Kulber, D.A., & Lee, D. J. (2007). Use of acellular cadaveric dermis and tissue expansion in postmastectomy breast reconstruction. *Journal of Plastic, Reconstructive and Aesthetic Surgery*, Vol.60, No.11, (n.d.), pp. 1214-1218, ISSN 1748-6815
- Brachtel, E. F., Rusby, J. E., Michaelson, J. S., Chen, L. L., Muzikansky, A., Smith, B. L., & Koerner, F. C. (2009). Occult nipple involvement in breast cancer: clinicopathologic findings in 316 consecutive mastectomy specimens. *Journal of Clinical Oncology*, Vol.27, No.30, (October 2009), pp. 4948-4954, ISSN 0732-183X
- Breuing, K. H., & Colwell, A.S. (2007). Inferolateral AlloDerm hammock for implant coverage in breast reconstruction. *Annals of Plastic Surgery*, Vol.59, No.3, (September 2007), pp. 250-255, ISSN 0148-7043

- Breuing, K. H., & Warren, S. M. (2005). Immediate bilateral breast reconstruction with implants and inferolateral AlloDerm slings. *Annals of Plastic Surgery*, Vol.55, No.3, (September 2005), pp. 232-239, ISSN 0148-7043
- Cassileth, L., Kohanzadeh, S., & Amersi, F. (2011). One-Stage Immediate Breast Reconstruction With Implants: A New Option for Immediate Reconstruction. *Annals of Plastic Surgery*, (Jul 5 2011), [Epub ahead of print], ISSN 0148-7043
- Chasan, P. E. (2005). Breast capsulorrhaphy revisited: A simple technique for complex problems. *Plastic and Reconstructive Surgery*, Vol.115, No.1, (Januar 2005), pp. 296-301, ISSN 0032-1052
- Chasan, P. E., & Francis, C. S. (2008). Capsulorrhaphy for revisionary breast surgery. *Aesthetic Surgery Journal*, Vol.28, No.1, (January-February 2008), pp. 63-69, ISSN 1090-820X
- Collis, G. N., Terkonda, S. P., Waldorf, J. C., & Perdakis, G. (2011). Acellular Dermal Matrix Slings in Tissue Expander Breast Reconstruction: Are There Substantial Benefits? *Annals of Plastic Surgery*, (Aug 5 2011), [Epub ahead of print], ISSN 0148-7043
- Cordeiro, P. G., & McCarthy, C. M. (2006). A single surgeon's 12-year experience with tissue expander/implant breast reconstruction: part II. An analysis of long-term complications, aesthetic outcomes, and patient satisfaction. *Plastic and Reconstructive Surgery*, Vol.118, No.4, (September 2006), pp. 832-839, ISSN 0032-1052
- Cunnick, G. H., & Mokbel, K. (2006). Oncological considerations of skin-sparing mastectomy. *International Seminars in Surgical Oncology*, Vo.3, (May 2006), pp. 14, ISSN 1477-7800
- Cunningham, B., & McCue, J. (2009). Safety and effectiveness of Mentor's MemoryGel implants at 6 years. *Aesthetic Plastic Surgery*, Vol.33, No.3, (May 2009), pp. 440-444, ISSN 0364-216X
- Duncan, D. I. (2001). Correction of implant rippling using allograft dermis. *Aesthetic Surgery Journal*, Vol.21, No.1, (January 2001), pp. 81-84, ISSN 1090-820X
- Grabov-Nardini, G., Haik, J., Regev, E., & Winkler, E. (2009). AlloDerm sling for correction of synmastia after immediate, tissue expander, breast reconstruction in thin women. *Eplasty*, Vol.9, (November 2009), pp. e54, ISSN 1937-5719
- Handel, N., Cordray, T., Gutierrez, J., & Jensen, J. A. (2006). A long-term study of outcomes, complications, and patient satisfaction with breast implants. *Plastic and Reconstructive Surgery*, Vol.117, No.3, (March 2006), pp. 757-767, ISSN 0032-1052
- Hanna, K. R., Degeorge, B. R. Jr, Mericli, A. F., Lin, K. Y., & Drake, D. B. (2011). Comparison Study of Two Types of Expander-Based Breast Reconstruction: Acellular Dermal Matrix-Assisted Versus Total Submuscular Placement. *Annals of Plastic Surgery*, (Aug 22 2011), [Epub ahead of print], ISSN 0148-7043
- Hartzell, T. L., Taghnia, A. H, Chang, J., Lin, S. J, & Slavin, S. A. (2010). The use of human acellular dermal matrix for the correction of secondary deformities after breast augmentation: results and costs. *Plastic and Reconstructive Surgery*, Vol.126, No.5, (November 2010), pp. 1711-1720, ISSN 0032-1052
- Israeli, R. (2011). Correction of capsular contracture with acellular dermal matrix. Poster presented at Breast Cancer Coordinated Care Conference, Washington, DC, February 3-5, 2011.

- Israeli, R., & Cody, D. G. (2011). Correction of implant malposition after breast reconstruction using acellular dermal matrix. Poster presented at Breast Cancer Coordinated Care Conference, Washington, DC, February 3-5, 2011.
- Israeli, R., Cody, D. G., Busch-Devereaux, E., Mishkit, A., & Romanelli, J. N. (2011). Periareolar approach to nipple-areola sparing mastectomy and acellular dermal matrix-assisted direct-to-implant breast reconstruction. Poster presented at Breast Cancer Coordinated Care Conference, Washington, DC, February 3-5, 2011.
- Israeli, R., & Feingold, R. S. (2011). Acellular dermal matrix in breast reconstruction in the setting of radiotherapy. *Aesthetic Surgery Journal*, Vol.31 (7 suppl), (September 2011), pp. 51S-64S, ISSN
- Komorowska-Timek, E., Oberg, K. C., Timek, T. A., Gridley, D. S., & Miles, D. A. (2009). The effect of AlloDerm envelopes on periprosthetic capsule formation with and without radiation. *Plastic and Reconstructive Surgery*, Vol.123, No.3, (March 2009), pp. 807-816, ISSN 0032-1052
- Massiha, H. (2002). Scar tissue flaps for the correction of postimplant breast rippling. *Annals of Plastic Surgery*, Vol.48, No.5, (May 2002), pp. 505-507, ISSN 0148-7043
- Maxwell, G. P., Birchenough, S. A., & Gabriel, A. (2009). Efficacy of neopectoral pocket in revisionary breast surgery. *Aesthetic Surgery Journal*, Vol.29, No.5, (September-October 2009), pp. 379-385, ISSN 1090-820X
- Maxwell, G. P. & Gabriel, A. (2009). Use of the acellular dermal matrix in revisionary aesthetic breast surgery. *Aesthetic Surgery Journal*, Vol.29, No.6, (November-December 2009), pp. 485-493, ISSN 1090-820X
- McCarthy, C. M., Mehrara, B. J., Riedel, E., Davidge, K., Hinson, A., Disa, J. J., Cordeiro, P. G., & Pusic, A. L. (2008). Predicting complications following expander/implant breast reconstruction: an outcomes analysis based on preoperative clinical risk. *Plastic and Reconstructive Surgery*, Vol.121, No.6, (June 2008), pp. 1886-1892, ISSN 0032-1052
- Namnoon, J. D. (2009). Expander/implant reconstruction with AlloDerm: recent experience. *Plastic and Reconstructive Surgery*, Vol.124, No.2, (August 2009), pp. 387-394, ISSN 0032-1052
- Newman, M. I., Swartz, K. A., Samson, M. C., Mahoney, C. B., & Diab, K. (2011). The true incidence of near-term postoperative complications in prosthetic breast reconstruction utilizing human acellular dermal matrices: a meta-analysis. *Aesthetic Plastic Surgery*, Vol.35, No.1, (February 2011), pp. 100-106, ISSN 0364-216X
- Orenstein, S. B., Qiao, Y., Kaur, M., Klueh, U., Kreutzer, D. L., & Novitsky, Y. W. (2010). Human monocyte activation by biologic and biodegradable meshes in vitro. *Surgical Endoscopy*, Vol.24, No.4, (April 2010), pp. 805-811, ISSN 0930-2794
- Prantl, L., Schreml, S., Fichtner-Feigl, S., Pöppl, N., Eisenmann-Klein, M., Schwarze, H., & Füchtmeier, B. (2007). Clinical and morphological conditions in capsular contracture formed around silicone breast implants. *Plastic and Reconstructive Surgery*, Vol.120, No.1, (July 2007), pp. 275-284, ISSN 0032-1052
- Rawlani, V., Buck, D. W. 2nd, Johnson, S. A., Heyer, K. S., & Kim, J. Y. (2011). Tissue expander breast reconstruction using prehydrated human acellular dermis. *Annals of Plastic Surgery*, Vol.66, No.6, (June 2011), pp. 593-597, ISSN 0148-7043
- Roostaeian, J., Pavone, L., Da Lio, A., Lipa, J., Festekjian, J., & Crisera, C. (2011). Immediate placement of implants in breast reconstruction: patient selection and outcomes.

- Plastic and Reconstructive Surgery*, Vol.127, No.4, (April 201001), pp. 1407-1416, ISSN 0032-1052
- Salzberg, C. A. (2006). Nonexpansive immediate breast reconstruction using human acellular tissue matrix graft (AlloDerm). *Annals of Plastic Surgery*, Vol.57, No.1, (July 2006), pp. 1-5, ISSN 0148-7043
- Salzberg, C. A., Ashikari, A. Y., Koch, R. M., & Chabner-Thompson, E. (2011). An 8-year experience of direct-to-implant immediate breast reconstruction using human acellular dermal matrix (AlloDerm). *Plastic and Reconstructive Surgery*, Vol.127, No.2, (February 2011), pp. 514-524, ISSN 0032-1052
- Spear, S. L., Carter, M. E., & Ganz, J. C. (2003). The correction of capsular contracture by conversion to "dual-plane" positioning: Technique and outcomes. *Plastic and Reconstructive Surgery*, Vol.112, No.2, (August 2003), pp. 456-466, ISSN 0032-1052
- Spear, S. L., Dayan, J. H., Bogue, D., Clemens, M. W., Newman, M., Teitelbaum, S., & Maxwell, G. P. (2009). The "neosubpectoral" pocket for the correction of symmastia. *Plastic and Reconstructive Surgery*, Vol.124, No.3, (September 2009), pp. 695-703, ISSN 0032-1052
- Spear, S. L., & Little, J. W. III. (1988). Breast capsulorrhaphy. *Plastic and Reconstructive Surgery*, Vol.81, No.2, (February 1988), pp. 274-279, ISSN 0032-1052
- Spear, S. L., Murphy, D. K., Slicton, A., & Walker PS; Inamed Silicone Breast Implant U.S. Study Group. (2007). Inamed silicone breast implant core study results at 6 years. *Plastic and Reconstructive Surgery*, Vol.120(7 Suppl 1), (December 2007), pp. 8S-16S, ISSN 0032-1052
- Spear, S. L., Parikh, P. M., Reisin, E., & Menon, N. G. (2008). Acellular dermis-assisted breast reconstruction. *Aesthetic Plastic Surgery*, Vol.32, No.3, (May 2008), pp. 418-425, ISSN 0364-216X
- Spear, S. L., Seruya, M., Clemens, M. W., Teitelbaum, S., & Nahabedian, M. Y. (2011). Acellular dermal matrix for the treatment and prevention of implant-associated breast deformities. *Plastic and Reconstructive Surgery*, Vol.127, No.3, (March 2011), pp. 1047-1058, ISSN 0032-1052
- Stump, A., Holton, L. H. 3rd, Connor, J., Harper, J. R., Slezak, S., & Silverman, R. P. (2009). The use of acellular dermal matrix to prevent capsule formation around implants in a primate model. *Plastic and Reconstructive Surgery*, Vol.124, No.1, (July 2009), pp. 82-91, ISSN 0032-1052
- Tamboto, H., Vickery, K., & Deva, A. K. (2010). Subclinical (biofilm) infection causes capsular contracture in a porcine model following augmentation mammoplasty. *Plastic and Reconstructive Surgery*, Vol.126, No.3, (September 2010), pp. 835-842, ISSN 0032-1052
- Topol, B. M., Dalton, E. F., Ponn, T., & Campbell, C. J. (2008). Immediate single-stage breast reconstruction using implants and human acellular dermal tissue matrix with adjustment of the lower pole of the breast to reduce unwanted lift. *Annals of Plastic Surgery*, Vol.61, No.5, (November 2008), pp. 494-499, ISSN 0148-7043
- Uzunismail, A., Duman, A., Perk, C., Findik, H., & Beyhan, G. (2008). The effects of acellular dermal allograft (AlloDerm®) interface on silicone-related capsule formation – experimental study. *European Journal of Plastic Surgery*, Vol.31, No.4, (n.d.), pp. 179-185

- Voice, S. D., & Carlsen, L. N. (2001). Using a capsular flap to correct breast implant malposition. *Aesthetic Surgery Journal*, Vol.21, No.5, (September 2001), pp. 441-444, ISSN 1090-820X
- Wang, H. Y., Ali, R. S., Chen, S. C., Chao, T. C., & Cheng, M. H. (2008). One-stage immediate breast reconstruction with implant following skin-sparing mastectomy in Asian patients. *Annals of Plastic Surgery*, Vol.60, No.4, (April 2008), pp. 362-366, ISSN 0148-7043
- Woerdeman, L. A., Hage, J. J., Smeulders, M.J., Rutgers, E. J., & van der Horst, C. M. (2006). Skin-sparing mastectomy and immediate breast reconstruction by use of implants: An assessment of risk factors for complications and cancer control in 120 patients. *Plastic and Reconstructive Surgery*, Vol.118, No.2, (August 2006), pp. 321-330, ISSN 0032-1052
- Yoo, G., & Lee, P. K. (2010). Capsular flaps for the management of malpositioned implants after augmentation mammoplasty. *Aesthetic Plastic Surgery*, Vol.34, No.1, (February 2010), pp. 111-1115, ISSN 0364-216X
- Zienowicz, R. J., & Karacaoglu, E. (2007). Implant-based breast reconstruction with allograft. *Plastic and Reconstructive Surgery*, Vol.120, No.2, (August 2007), pp. 373-381, ISSN 0032-1052



Selected Topics in Plastic Reconstructive Surgery

Edited by Dr Stefan Danilla

ISBN 978-953-307-836-6

Hard cover, 242 pages

Publisher InTech

Published online 20, January, 2012

Published in print edition January, 2012

Plastic Surgery is a fast evolving surgical specialty. Although best known for cosmetic procedures, plastic surgery also involves reconstructive and aesthetic procedures, which very often overlap, aiming to restore functionality and normal appearance of organs damaged due to trauma, neoplasm, ageing tissue or iatrogenesis. First reconstructive procedures were described more than 3000 years ago by Indian surgeons that reconstructed nasal deformities caused by nose amputation as a form of punishment. Nowadays, many ancient procedures are still used like the Indian forehead flap for nasal reconstruction, but as with all fields of medicine, the advances in technology and research have dramatically affected reconstructive surgery.

How to reference

In order to correctly reference this scholarly work, feel free to copy and paste the following:

Ron Israeli (2012). Acellular Dermal Matrix for Optimizing Outcomes in Implant-Based Breast Reconstruction: Primary and Revisionary Procedures, Selected Topics in Plastic Reconstructive Surgery, Dr Stefan Danilla (Ed.), ISBN: 978-953-307-836-6, InTech, Available from: <http://www.intechopen.com/books/selected-topics-in-plastic-reconstructive-surgery/acellular-dermal-matrix-for-optimizing-outcomes-in-implant-based-breast-reconstruction-primary-and-r>

INTECH
open science | open minds

InTech Europe

University Campus STeP Ri
Slavka Krautzeka 83/A
51000 Rijeka, Croatia
Phone: +385 (51) 770 447
Fax: +385 (51) 686 166
www.intechopen.com

InTech China

Unit 405, Office Block, Hotel Equatorial Shanghai
No.65, Yan An Road (West), Shanghai, 200040, China
中国上海市延安西路65号上海国际贵都大饭店办公楼405单元
Phone: +86-21-62489820
Fax: +86-21-62489821

© 2012 The Author(s). Licensee IntechOpen. This is an open access article distributed under the terms of the [Creative Commons Attribution 3.0 License](#), which permits unrestricted use, distribution, and reproduction in any medium, provided the original work is properly cited.