

Radiology in Infective Endocarditis

C. Prados, C. Carpio, A. Santiago, I. Silva and R. Álvarez-Sala
*Pulmonology Service, La Paz University Hospital, Autónoma University, Madrid
Spain*

1. Introduction

In the last 50 years, the incidence of infective endocarditis (IE) has remained between 2 and 6 per 100.000 individuals in the general population per year and its mortality has fluctuated between 10% and 30%, depending on the type of pathogen. Historically, chronic rheumatic heart disease had been the primary risk factor for IE but in the last years, new at-risk groups have emerged like individuals undergoing hemodialysis, patients with catheters and elderly people with degenerative valve lesions. IE is characterized by the infection of the endocardium, most commonly by bacteria. Although the primary focus of the infection is confined to the endocardium, microbial shedding by continuous bacteremia and embolization of vegetation fragments makes IE a true systemic infection. This disease, therefore, is positioned at the crossroads of multiple medical specialties, including cardiology, cardiac surgery, infectious diseases, internal medicine, neurology, and intensive care. Valve vegetations are specific pathologic findings of this disease. They are the result of the combination of thrombus with bacteria and leucocytes. The size and mobility of valvular vegetations are important predictors of whether or not the patient will develop septic emboli. These lesions usually affect valve endocardium, but it also could involve papillary muscles, mural endocardium and the great vessels. IE is fatal if it is not treated early with antibiotics. Negative prognostic factors are fungal etiology, involvement of the aortic valve, and presence of large vegetations. Patients with a left-sided endocarditis have a higher mortality in comparison to patients with right-sided endocarditis

The mean age of patients with IE has increased from 30 years in the 1950s, to 50 years in the 1980s. The higher frequency of IE diagnosis in older individuals probably reflects the clustering of more than one risk factor in the elderly. The results of epidemiological studies vary depending on the population analyzed and the microbial pathogens tend to differ between the various groups.

2. Classification

IE can be classified in four categories:

- Native valve endocarditis
- Intravenous drug abuse endocarditis (IVDA)
- Prosthetic valve endocarditis
- Pacemaker endocarditis and nosocomial endocarditis

Left-sided native valve endocarditis is the most frequent form of endocarditis, representing more than 60% of all cases. In-hospital mortality is approximately 15%. Pre-existing lesions can favor attachment of circulating bacteria and promote IE. Frequently, congenital or acquired valve diseases are present (rheumatic fever, degenerative cardiopathies, mitral valve prolapse). Mitral -valve prolapsed is a relatively common condition and have a 10-100-fold increased risk of IE. Degenerative valve lesions are present in up to 25% of patients with IE and they involve local inflammation, microulcers, and microthrombi of the endothelium. Degenerative valve lesions might increase the risk of IE in up to 50% of patients older than 60 years of age. Alpha-hemolytic streptococci or enterococci typically are the causative agents of this type endocarditis.

IVDA endocarditis usually occurs on healthy right heart valves, and 50% of these infections involve the tricuspid valve. Although highly population-specific, right-sided IE has represented up to 5-10% of cases in general surveys. This form of IE has a better prognosis than left-sided IE and in-hospital mortality is <10%, although mortality of up to 50% has been observed in patients with AIDS, especially in advanced cases. Intravenous-drug users, including those with HIV, are a group that primarily consists of relatively young adults. The risk of IE is approximately four to five times higher in those with < 200 CD4 per mm³. The tricuspid valve is usually affected in these patients and *Staphylococcus aureus* is the most common causative organism.

Prosthetic valve endocarditis is the most-severe form of IE, and is associated with high mortality that ranges from 20% to >40%. It occurs in 1-5% of patients with prosthetic valves and accounts for up to 20% of all cases of IE. It is classified as 'early' or 'late' infection on the basis of the time period between surgery and the onset of IE. Early and late prosthetic valve endocarditis are defined, as occurring either within or more than 12 months after surgery, respectively. Early prosthetic valve endocarditis is often caused by surgery-related and drug-resistant microbes such as methicillin-resistant staphylococci and late endocarditis is due to infection with oral streptococci and Gram-negative bacteria of the HACEK group.

Pacemaker endocarditis are produced by infections of these devices within a few months of implantation. The rate of pacemaker endocarditis is estimated at 0.55 cases per 1,000 pacemakers recipients per year. These infections always require ablation of the material in addition to antibiotic therapy. Of pacemaker infections, 75% are produced by staphylococci.

3. Etiology and pathophysiology

The pathogens involved in IE depend on the different categories of endocarditis. The most frequent IE pathogens are Gram-positive bacteria (*S. aureus*, *Streptococcus* spp., and enterococci) and they are responsible for more than 80% of all IE cases. These bacteria have great ability to adhere to and colonize damaged valves and are equipped with several surface adhesins that mediate attachment to extracellular host matrix proteins. The clumping factor A and the fibronectin-binding protein A are involved in valve colonization and invasion of *S. aureus*. Fibrinogen-binding mediates the primary attachment of the bacteria to nonbacterial thrombotic endocarditis, and subsequent binding of fibronectin triggers endothelial cell internalization, followed by local proinflammatory and procoagulant responses.

Skin microorganisms are responsible for the vast majority of infections in IVDA endocarditis but contamination of drugs and material employed by drug abusers, also contribute to the bacteremia. Aortic and mitral valves are affected in 25% of cases of IVDA endocarditis. The pathogenic mechanisms that explain the increased prevalence of right sided IE in injection drug users are not fully elucidated. Damage to the right sided valves from injected particulate matter in the setting of injected bacterial loads is thought to be important, while subtle abnormalities of immune function may also have a role in pathogenesis. Cocaine use is associated with an increased incidence of endocarditis greater than heroin use, but this finding is not fully explained.

Pulmonary valve is only involved in less than 2% of cases. It is also reported that 6% of patients presents both right and left endocarditis at the same time.

With respect to the pathophysiology, there are many mechanisms proposed to the development of this disease. Endothelial damage can be caused by turbulent blood flow associated with congenital heart disease or prosthetic valves, by electrodes or catheters, or, in intravenous-drug users, from repeated intravenous injection of particulate material. Alternatively, endothelial damage can result from inflammation, for example in patients with rheumatic carditis or in elderly individuals with degenerative valve lesions. Other theories, however, defend the so-called "immunological hypothesis" which explains that the valve affection is secondary to immunological mechanisms that cause local inflammation.

4. Clinical manifestations

Symptoms of IE are related to the infectious condition of the process. General manifestations like persistent fever, chills, pleuritic chest pain, cough and hemoptysis have been described. Embolic events occur in approximately one-third of cases, more frequently in patients with intravenous drug use, right-sided endocarditis or positive blood cultures.

The most common extra-cardiac organ system involved in infective endocarditis is the central nervous system and could produce embolic stroke, intracranial hemorrhage, intracranial mycotic aneurysm, brain abscess and meningitis. With respect to the respiratory system, it has been reported septic pulmonary embolism like a clinical presentation of this condition. In right-sided endocarditis, pulmonary embolic manifestations are frequently present. Septic pulmonary emboli are detected in more than 80% of cases, and may be associated with pleuritic chest pain and dyspnea.

5. Radiology

A chest radiograph should be done routinely but the findings are not specified. Fifty percent of patients with IVDA endocarditis have radiologic opacities and 50-60 % of injection drug users with definite IE have multiple pulmonary opacities (figure 1 and figure 2). The typical radiograph pattern of septic emboli is peripheral, poorly marginated bilateral lung nodules that often demonstrate cavitory changes and moderately thick irregular walls. Also cardiomegaly, pleural effusion and radiographic signs of left heart failure (septal thickening, air bronchogram, pleural effusion) are reported.

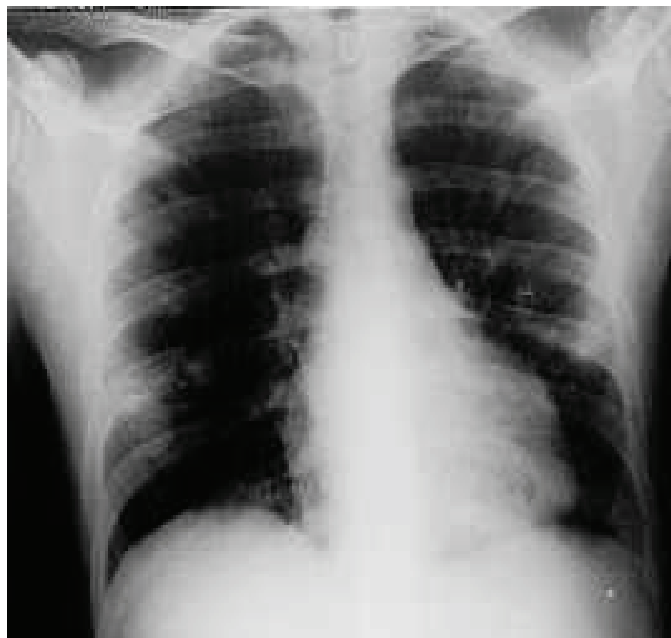


Fig. 1. Chest X-ray showing bilateral opacities and nodules, corresponding to septi emboli

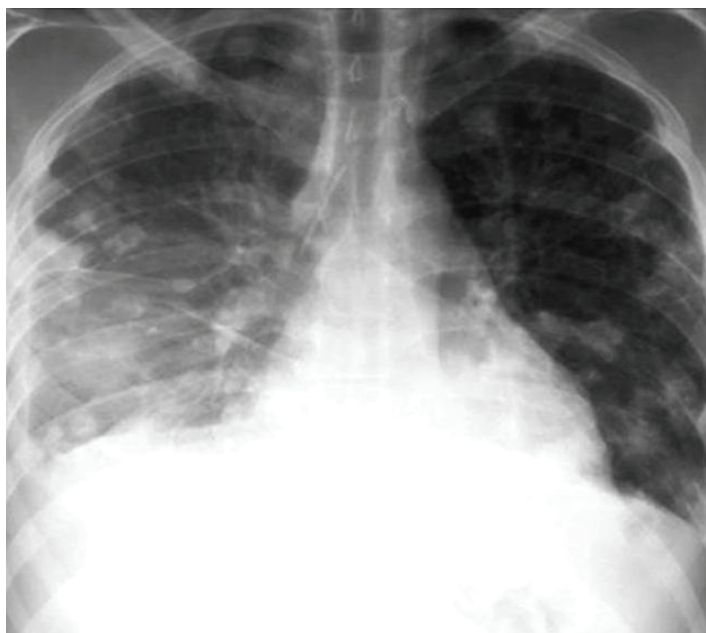


Fig. 2. Chest X-ray showing bilateral opacities. Also it can be observed the presence of pleural fluid

Computed tomography findings include:

- Peripheral triangle opacities, corresponding to regions of pulmonary infarcts produced by septic embolism.
- Peripheral, poorly marginated bilateral lung nodules.
- Cavitory nodules with thick irregular walls. These nodules typically measure 5-35 mm, have a peripheral and basilar predominance, and demonstrate air-bronchograms. The nodule may increase in number and change from day to day (figure 3).
- "Feeding vessel sign" that consists of a distinct vessel leading directly into the center of a nodule.
- Radiologic findings suggestive of empyema like pleural effusion, thickening and enhancement of the visceral and parietal pleurae and inflammation of the extrapleural fat. Also, empyema had been described as a pleural collection that is immobile on decubitus views. Pleural fluid, pericardic fluid and pneumothorax.
- Unilateral or bilateral interstitial lung infiltrate.

In many instances, these radiological findings precede the clinical manifestations of IE. Also, the follow up of septic emboli could be performed by computed tomography.

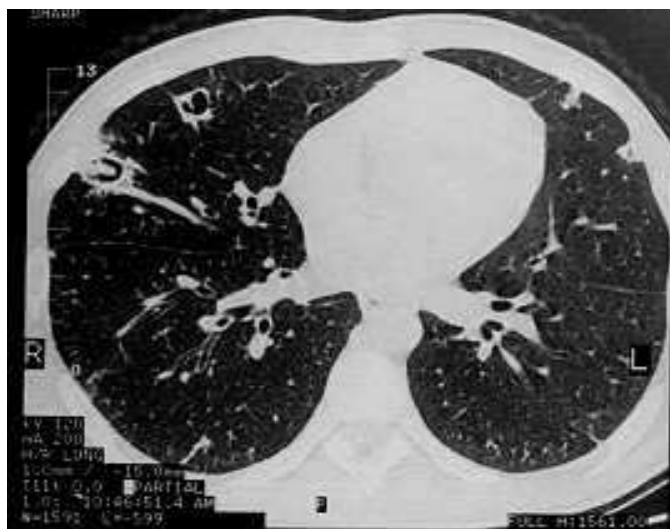


Fig. 3. Computed tomography scan showing peripheral cavitary nodules with thick irregular walls from 1 to 3 cm of size

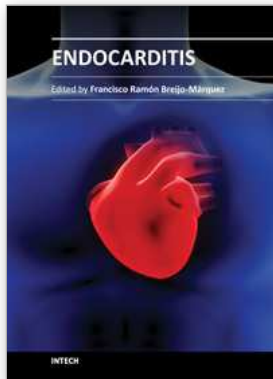
These radiological findings are more common in IVDA endocarditis but also they can be found, less commonly, in other types of right IE, like endocarditis associated to pacemaker and intravascular devices. It is important to differentiate other radiologic presentation of IVDA, like ground-glass opacities, pulmonary hemorrhage, air trapping and pulmonary hypertension. When IE affects left chambers, radiographic findings are less frequent. Furthermore, they only appear in the context of heart complications: increased cardiothoracic ratio (secondary to pericardial effusion) and signs of left heart failure resulting from chordal rupture or valve failure.

6. Conclusion

Although echocardiography is the gold standard in the diagnosis of IE, the presence of many radiological findings could suggest its diagnosis.

7. References

- Bittermann V, Pros SA. Manifestaciones osteoarticulares de endocarditis. *Semin Fund Esp Reumatol*. 2010;11:152-8.
- Nandakumar R, Raju G. Isolated tricuspid valve endocarditis in nonaddicted patients: A diagnostic challenge. *Am J Med Sci* 1997;314:207-12.
- Lacassin F, Lepout C. Infectious endocarditis, risk factors, prevention. Research group for infectious endocarditis and jury of the consensus conference. *Rev Med Interne*. 1993; 14(9):871-6.
- Clifford SP, Eykyn SJ, Oakley CM. Staphylococcal tricuspid valve endocarditis in patients with structurally normal hearts and no evidence of narcotic abuse. *QJM* 1994;87:755-7.
- Naidoo DP. Right-sided endocarditis in the non-drug addict. *Postgrad Med J* 1993;69:615-20.
- Prados C, Galera R, Santiago A. Unilateral interstitial lung pattern as a first sign of a bacterial endocarditis. *Arch Bronconeumol*. 2010;46:206-7.
- Nguyen E, Silva I, Souza C, Müller N. Pulmonary complications of illicit drug use differential diagnosis based on CT findings. *J Thorac Imaging* 2007;22:199-206.



Endocarditis

Edited by Prof. Francisco Ramón Breijo-Márquez

ISBN 978-953-307-901-1

Hard cover, 152 pages

Publisher InTech

Published online 20, January, 2012

Published in print edition January, 2012

Endocarditis is a disease that occurs as a result of the inflammation of the endocardium. It is an inflammatory process located in the inner lining of the cardiac chambers and native or prosthetic valves. It is characterized by colonization or invasion of the heart valve vegetations composed of platelets forming, fibrin and microcolonies of microorganisms, and occasionally of inflammatory cells. Other structures may also be affected, such as the interventricular septum, chordae tendineae, the mural endocardium or even intra-cardiac implants. The book covers, with scientific rigour, the most prevalent causes and current treatments of endocarditis, as well as the cases when the organs remote from the heart are affected by this disease.

How to reference

In order to correctly reference this scholarly work, feel free to copy and paste the following:

C. Prados, C. Carpio, A. Santiago, I. Silva and R. Álvarez-Sala (2012). Radiology in Infective Endocarditis, Endocarditis, Prof. Francisco Ramón Breijo-Márquez (Ed.), ISBN: 978-953-307-901-1, InTech, Available from: <http://www.intechopen.com/books/endocarditis/radiology-in-infective-endocarditis>

INTECH

open science | open minds

InTech Europe

University Campus STeP Ri
Slavka Krautzeka 83/A
51000 Rijeka, Croatia
Phone: +385 (51) 770 447
Fax: +385 (51) 686 166
www.intechopen.com

InTech China

Unit 405, Office Block, Hotel Equatorial Shanghai
No.65, Yan An Road (West), Shanghai, 200040, China
中国上海市延安西路65号上海国际贵都大饭店办公楼405单元
Phone: +86-21-62489820
Fax: +86-21-62489821

© 2012 The Author(s). Licensee IntechOpen. This is an open access article distributed under the terms of the [Creative Commons Attribution 3.0 License](#), which permits unrestricted use, distribution, and reproduction in any medium, provided the original work is properly cited.