

Evaluation of Subvalvular Apparatus by 2-D Transthoracic Echocardiography

Yasushige Shingu, Suguru Kubota and Yoshiro Matsui
*Hokkaido University Graduate School of Medicine,
Department of Cardiovascular Surgery
Japan*

1. Introduction

Functional mitral regurgitation (MR) is one of the major contributing factors for heart failure and hospitalization in both nonischemic and ischemic dilated cardiomyopathy. The limitation of undersized mitral annuloplasty has been recognized. Recurrent late MR is associated with continued left ventricular (LV) remodeling and enhanced papillary muscle displacement outside posterior ring after mitral annuloplasty. Understanding of the tethering mechanism provided both annular and subvalvular targets for therapy and several procedures have been reported.

Kron et al. reported a novel approach to reduce tethering length and improve coaptation by approximating displaced posterior papillary muscle toward the annulus. Hvass et al. evolved a papillary muscle sling procedure using an ePTFE tube graft around the muscles and reported improved mitral tethering. Messas et al. proposed a chordal cutting procedure. Langer et al. reported transaortic repositioning of posterior papillary muscle to the midseptal fibrous annulus in a procedure named "RING plus STRING". Our group has reported papillary muscle approximation and its suspension to the mitral artificial ring.

However, there exists no standard method to determine the indication and effects of those various procedures and it makes the comparison between the procedures difficult. Although it would be ideal to determine 3-dimensional anatomy of submitral apparatus, we discuss here the usefulness and importance of 2-D transthoracic echocardiography in this area.

2. Methods

We developed our own submitral procedure, i.e., papillary muscle approximation and its suspension to the mitral ring. According to the method reported by Matsunaga et al., we measure the pre and postoperative values of those parameters relating to the submitral apparatus using 2-D transthoracic echocardiography in patients who need this submitral procedure for functional MR.

2.1 Submitral procedure

Fig. 1 shows our own surgical submitral procedure. Our recent surgical strategy for functional MR is to reconstruct the annulus and subvalvular apparatus of the mitral valve.

It consists of mitral annuloplasty with a semi-rigid total ring, papillary muscle approximation (PMA), and papillary muscle suspension (PMS). PMA is a surgical method to join the entire papillary muscle side-by-side from the bases to the heads by three pledgeted mattress sutures of 3-0 prolene. Shortening the distance between the papillary muscles reduces the lateral and backward tethering of the mitral valve. PMA is usually performed when the papillary muscle distance in the end-diastole is greater than 30 mm in the short axis view of the transthoracic echocardiography. We recently developed a PMS that fixes the distance between the approximated papillary muscle heads and the mitral annulus. This adjunctive method places a subvalvular CV-4 ePTFE suture between the site of the chordal attachment of the approximated papillary muscles and the mitral annulus. This suture is passed through the annuloplasty ring. We adjusted the length of artificial chordae to accomplish enough mitral coaptation length by saline infusion test. We believe that PMS maintains the mitral complex geometry and prevents future mitral tethering deterioration. PMA and PMS are usually performed by left ventriculotomy. The subjects were retrospectively divided into two groups: posterior-directional PMS (pPMS: ~ 2007, n=8) and anterior-directional PMS (aPMS: 2008 ~, n=12). The ePTFE suture was sewn to the middle of the posterior annuloplasty ring in the pPMS group and the anterior annuloplasty ring in the aPMS group. Nine (45%) patients had ischemic and 11 (55%) patients had non-ischemic etiology. Most of the patients had NYHA class over III. Mean age was 62 ± 9 years and MR grade was 3.4 ± 0.8 .

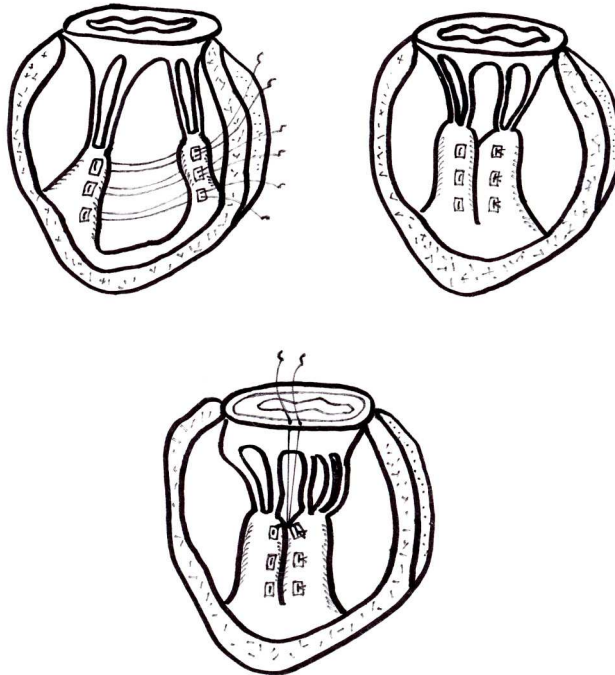


Fig. 1. Submitral procedure named papillary muscle approximation and suspension.

Mitral complex reconstruction consists of mitral annuloplasty with a semi-rigid total ring, papillary muscle approximation (PMA), and papillary muscle suspension (PMS). The entire papillary muscles are joined side-by-side from the bases to the heads by three pledgeted mattress sutures of 3-0 prolene.

Figure 2 shows a surgical method of LV volume reduction surgery named "Overlapping left ventriculoplasty". To reshape the severely remodeled LV, we perform Overlapping left ventriculoplasty, as previously reported. This procedure is based on volume reduction without a patch or ventriculectomy. Basically, it is adopted to cases with LV end-diastolic dimension greater than 65 mm.

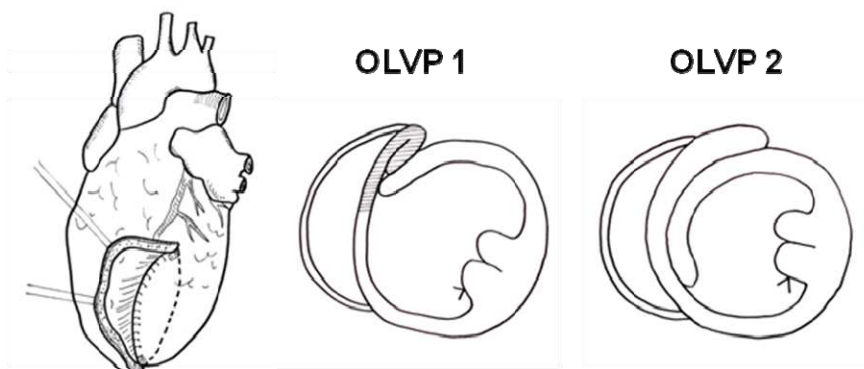


Fig. 2. LV volume reduction surgery named "Overlapping left ventriculoplasty (OLVP)".

LV anterior free wall incision is made parallel to the left anterior descending artery. Left incision margin is sutured to the septal wall, and part of excluded myocardium is sutured to just above the first suture line when the septal wall is scar (OLVP 1). When the septal wall is viable mostly in the idiopathic dilated cardiomyopathy, the excluded myocardium is largely overlapped on the lateral LV wall (OLVP 2).

2.2 Measurement of cardiac function and anatomy of submitral apparatus by 2-D transthoracic echocardiography

Preoperative and postoperative echocardiographic studies were performed a few days before and about four weeks after the operations, respectively. We used a Sonos 5500 ultrasound system (Philips Medical Systems, Andover, Massachusetts, USA) with a 3S transducer (3-5 MHz), a Vivid Seven system (GE/Vingmed, Milwaukee, Wis, USA) with an M3S (2.5-3.5 MHz) transducer, or an Aplio system (Toshiba Medical Systems, Tokyo, Japan) with a 2.5 MHz transducer. These were performed by experienced examiners who were blinded about the study population. The following basic variables were measured from the parasternal long axis view: LV end-diastolic and end-systolic dimensions (mm), LV percent fractional shortening (%), left atrial dimension (mm), interventricular septal thickness and left ventricular posterior wall thickness (mm). Left ventricular ejection fraction (%) was measured by biplane method of discs. On an apical long-axis color Doppler flow image, a sample volume of pulsed Doppler was located at the tip of the mitral valve leaflets to obtain

the transmitral flow velocity. Peak early and late transmitral flow velocities (E and A, respectively, cm/s), the ratio of early to late peak velocities (E/A), and the deceleration time (ms) of the early transmitral flow velocity were measured. MR grade was categorized from +1 to +4 by color Doppler images.

Fig. 2 shows the parameters of the submitral apparatus reported by Matsunaga et al. Based on this, we measured the following parameters of mitral systolic tethering on the apical 2 chamber view for the posterior papillary muscle and the apical 4 chamber view for the anterior papillary muscle: mitral valve coaptation height (mm), tenting area (cm²), papillary muscle tethering distance (mm), papillary muscle depth (mm), and papillary muscle angle(°). We averaged these values measured by 2 and 4 chamber view. The papillary muscle distance was measured on the short axis view of the papillary muscle level in end-diastole. In the apical 2 chamber view, to determine diastolic mitral tethering, the mitral inflow direction was measured using Doppler color flow mapping at the time of maximal early diastolic rapid filling, as the line connecting the center of the filling flow signal at the mitral annulus and chordal levels between the leaflets and papillary muscles. The angle between this line and the annulus was measured as the mitral inflow angle. The echocardiographic study and the use of the clinical records for research were approved by the institutional ethics review board.

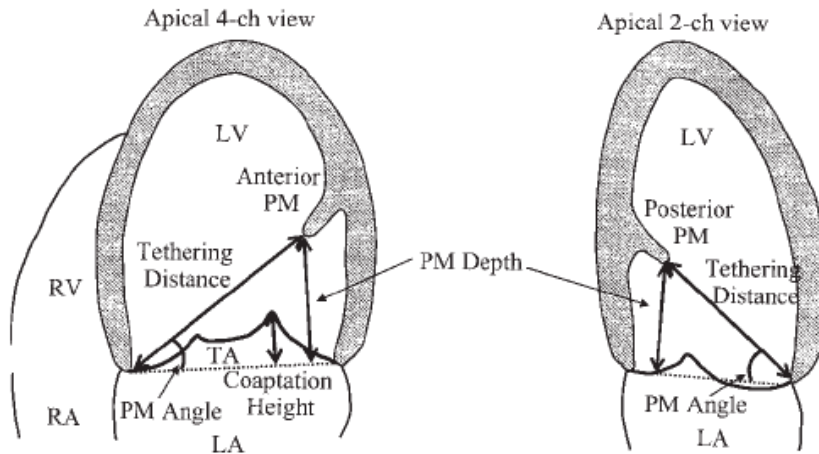


Fig. 2. Measurement of the parameters of the submitral apparatus.

The parameters for the anterior papillary muscle were measured on the apical 4-chamber view and those for the posterior papillary muscle were measured on the apical 2-chamber view. These values were averaged. LA, left atrium; LV, left ventricle; PM, papillary muscle; RA, right atrium; RV, right ventricle; TA, tenting area.

2.3 Statistical analysis

All the descriptive data are given as mean \pm standard deviation. Statistical analysis was performed with SPSS version 17.0 software (SPSS Inc. Chicago, Ill). The *t* test was used for

comparing the continuous variables between independent groups. The paired *t* test was used for comparing the continuous variables before and after the operation. A *p* value <0.05 was considered statistically significant.

3. Results

Table 1 shows preoperative patients' characteristics and operative data. Most of the cases had NYHA class over III. All patients underwent PMA and PMS procedures. Overlapping left ventriculoplasty was performed in 11 (55%) patients.

	all cases (n=20)
age (years)	62±9
male/female	17/3
ischemic/idiopathic etiology	9/11
NYHA class III/IV	13/5
beta blocker (%)	16 (80%)
chronic atrial fibrillation (%)	4 (20)
operative data	
cardiopulmonary bypass time (min)	258±54
aortic cross clamp time (min)	144±40
CABG (%)	8 (40)
tricuspid valve annuloplasty (%)	17 (85)
MAZE (%)	5 (25)
intraoperative IABP	5 (25)
left ventricular volume reduction (overlapping) (%)	11 (55)
posterior directional PMS (%)	8 (40)
anterior directional PMS (%)	12 (60)

Values±standard deviation. CABG, coronary artery bypass grafting; IABP, intra aortic balloon pumping; PMS, papillary muscle suspension.

Table 1. Preoperative patients' characteristics and operative data

Table 2 shows pre and postoperative functional parameters of all patients. LV end-diastolic and systolic diameters significantly decreased after operation. While transmitral E and A waves increased, E/A did not change. MR grade significantly decreased after operation (3.4±0.8 vs 0.2±0.4, *p*<0.001). Deceleration time significantly increased after operation.

Deceleration time was below 150 ms in only 3 cases (15%) after operation, although it was below 150 ms in 10 cases (50%) before operation.

	preOP (n=20)	postOP (n=20)	P value
LVDd (mm)	73±9	64±8	<0.001
LVDs (mm)	64±10	55±8	<0.001
FS (%)	12±5	14±7	0.38
LVEF (%)	27±6	30±7	0.077
IVST (mm)	9.5±1.9	10±2.0	0.11
PWT (mm)	9.0±1.6	9.4±1.6	0.068
E (m/s)	1.1±0.3	1.3±0.3	0.006
A (m/s)	0.5±0.3	0.8±0.5	0.024
E/A	2.9±1.9	2.4±1.5	0.33
DcT (ms)	167±66	223±71	0.008
MR grade	3.4±0.8	0.2±0.4	<0.001

Values±standard deviation. A, late diastolic wave; DcT, deceleration time; E, early diastolic wave; FS, fractional shortening; IVST, interventricular septal thickness; LVDd, left ventricular end-diastolic dimension; LVDs, left ventricular end-systolic dimension; LVEF, left ventricular ejection fraction; MR, mitral regurgitation; PWT, posterior wall thickness. P values were derived from paired t test.

Table 2. Pre and postoperative functional parameters of all patients

Table 3 shows pre and postoperative values of parameters for the submitral apparatus. Our data are the average of the parameters for the anterior and posterior papillary muscles and the normal values are those of the posterior papillary muscle. Mitral valve coaptation height and tenting area significantly decreased after operation. While tethering distance and papillary muscle angle significantly improved to normal values for reference, papillary muscle distance, which indicates the distance between papillary muscle heads to the mitral annular plain, did not change. By PMA, papillary muscle distance significantly decreased below the normal value after operation.

	preOP (n=20)	postOP (n=20)	normal values
coaptation height (mm)	11±3	5±3*	-
tenting area (cm ²)	2.3±0.7	0.6±0.3*	-
tethering distance (mm)	44±6	37±6*	33±5
papillary muscle depth (mm)	29±4	29±6	27±6
papillary muscle angle (°)	42±7	52±10*	51±7
papillary muscle distance (mm)	35±7	13±6*	25±1

Values±standard deviation. The normal values were derived from the reports by Nordblom P et al. and Vergnat M et al. *P<0.001.

Table 3. Pre and postoperative values of parameters for the submitral apparatus

Table 4 shows the postoperative values of parameters for the submitral apparatus, transmitral flow, and stroke volume index in the posterior directional PMS group and the anterior directional PMS group. Papillary muscle angle was significantly larger in the anterior PMS group than posterior PMS group, which suggests more anterior repositioning of the papillary muscles in the anterior PMS group. Peak mitral pressure gradient, which derives from mitral E wave, was smaller in the anterior PMS group than the posterior PMS group. There was no deference in stroke volume index between the groups. LV inflow angle was significantly larger in the anterior PMS group, which may be also an evidence of more anterior repositioning of the papillary muscles in the anterior PMS group.

	posterior PMS (n=8)	anterior PMS (n=12)	P value
coaptation height (mm)	3.3±1.2	5.9±3.3	0.055
tenting area (cm ²)	0.41±0.32	0.69±0.29	0.056
tethering distance (mm)	37±5	37±6	0.92
papillary muscle depth (mm)	26±6	30±5	0.11
papillary muscle angle (°)	46±9	56±9	0.025
papillary muscle distance (mm)	13±4	12±8	0.71
E (m/s)	1.6±0.2	1.1±0.2	0.001
DcT (ms)	186±45	247±80	0.073
peak pressure gradient (mmHg)	10±3	5±2	0.001
left ventricular inflow angle	60±6	78±9	<0.001
stroke volume index (ml/m ²)	28±5	33±11	0.23

Values±standard deviation. DcT, deceleration time; E, early diastolic wave; PMS, papillary muscle suspension. P values were derived from t test.

Table 4. Postoperative values of parameters for the submitral apparatus, transmitral flow, and stroke volume index in the posterior directional PMS group and the anterior directional PMS group.

4. Discussion

We demonstrate that we can precisely assess the change of geometry of the submitral apparatus after operation by using 2-D transthoracic echocardiography. The geometry of the submitral apparatus dramatically changed after operation and most of the parameters normalized in the anterior PMS group. Furthermore, we could detect the postoperative geometric deference between the two methods of papillary muscle suspension i.e. anterior and posterior direction. The papillary muscles positioned more anterior in the anterior PMS group compared to the posterior PMS group. This effect corresponded to the optimal diastolic LV filling i.e. lower transmitral gradient in the anterior PMS group.

There exists no standard method to determine the indication and effects of the surgical submitral procedures. Most of the clinical data after other submitral procedures are only

basic echocardiographic values and MR grade. We performed PMA and PMS based on the criteria of preoperative papillary muscle distance > 30mm in short axis view and assessed the geometry of the submitral apparatus both before and after surgery. Therefore, this chapter would be the first step for establishing a guideline for proper comparison between the deferent submitral procedures by using 2-D transthoracic echocardiography.

4.1 Modalities for assessment of subvalvular apparatus

In order to clarify the mechanism of functional MR, there have been amounts of experimental studies in which 3-dimensional anatomy of submitral apparatus has been documented in several large animal models. In those models, they needed to place tantalum myocardial makers to detect the motion by videofluoroscopy and it cannot be used in clinic. Three-dimensional echocardiography has recently emerged and it enabled comprehensive preoperative evaluation of prolapsed mitral valve. Furthermore, mitral tenting volume has been studied in normal and patients with functional MR by using this modality. However, the analysis of submitral apparatus including papillary muscles is still controversial. The quality of the transthoracic echocardiography would be one problem especially in the early postoperative period. In our recent study using 2-D transthoracic echocardiography, all the measurements were completed without difficulty even in the postoperative state.

Vergnat et al recently reported the anatomy of the submitral apparatus using 3-D echocardiography. In their study, the normal tethering distance was 37 mm for the anterior and 39 mm for the posterior papillary muscles, respectively. These values well corresponds to the postoperative values in our population. Normal inter-papillary distance was reported 25 mm. By our PMA procedure, the distance is over-corrected from 35 mm to 13 mm on average after surgery. Although we need 3-D echocardiography to assess specific volume like mitral tenting volume, 2-D echocardiography would be enough to assess the length between the anatomical points of mitral valve complex.

4.2 Submitral procedures for functional MR

Our surgical strategy consists of mitral annuloplasty with semi-rigid total ring, PMA and PMS. Although we first performed posterior-directional PMS (pPMS) because it was easy, even through the mitral annulus from left atrial approach, we considered more physiological geometry of mitral complex and recently changed the PMS direction from the posterior to the anterior. Anterior-directional PMS (aPMS) is sometimes difficult due to submitral apparatus, but it becomes easier with a large needle even through mitral annulus. We recently preferred a true-sized ring to an undersized one because adequate coaptation length is accomplished with subvalvular reconstruction. Although this is a short-term study, we found no recurrence of significant mitral regurgitation during two years of follow-up (data are not shown).

Kron et al. reported a novel approach to reduce tethering length and improve coaptation by approximating displaced posterior papillary muscle toward the annulus. The efficacy of this procedure was confirmed in an acute experimental model of posterior myocardial infarction. Hvass et al evolved a papillary muscle sling procedure using an ePTFE tube graft around the muscles and reported improved mitral tethering. Messas et al. proposed a chordal cutting procedure. Basal chordal cutting eliminates the anterior leaflet bend and can

make the leaflets less taut and improve coaptation. Although several surgeons have performed this procedure and argued for its efficacy without left ventricular dysfunction, we still do not know the long-term clinical effect. Furthermore, adverse effects of chordal cutting have also been reported. Borger et al. reported that the late recurrence of a grade 2 MR was 15% two years after chordal cutting. Langer et al. reported transaortic repositioning of posterior papillary muscle to the midseptal fibrous annulus in a procedure named "RING plus STRING". They first determined in an experimental model of sheep the geometric and functional effects of this procedure. STRING alone did not significantly shift the posterior papillary muscle to the septum and did not improve MR. The major deference between "RING plus STRING" and our PMA and PMS is the direction of the papillary muscle suspension. While the direction of suspension by "STRING" is lateral side of the anterior mitral annulus, we place the suspension in the middle of the anterior mitral annulus in the PMA and PMS procedure. As determined by transthoracic echocardiography in this chapter, the approximated papillary muscles shift to antero-septal side of the ventricle, papillary muscle angle normalizes, and MR disappears by our anterior directional PMS procedure.

As mentioned above, thus far various kinds of surgical methods have emerged to correct the geometry of the submitral apparatus and to prevent late recurrence of MR. However, there exists no standard method to determine the indication and effects of those various procedures and it makes the comparison between the procedures difficult. In this chapter, we suggested the usefulness and importance of 2-D transthoracic echocardiography in this controversial issue. By the routine assessment of submitral apparatus pre and postoperatively, we may compare the results of different procedures and it would be also important information for the mechanism of late recurrence of functional MR.

4.3 Beneficial effects of antero-septal directional papillary muscle suspension – prevention of functional mitral stenosis after surgery

Left ventricular inflow angle was significantly larger in the anterior PMS group and mitral peak pressure gradient was significantly smaller in the anterior PMS group than the posterior PMS group. We consider that mitral valve tethering during diastole could be ameliorated by anterior PMS which can relocate the papillary muscles toward antero-septal side of the ventricle but not posterior side. Furthermore, because stroke volume index was relatively larger even with lower transmitral gradient, mitral valve opening area during diastole may be larger in the anterior PMS group

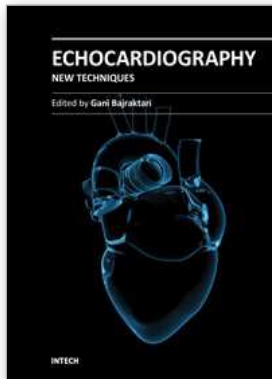
In the recent report by Kubota et al, they have given a new insight in the mechanism of "functional mitral stenosis (MS)" after mitral annuloplasty (MAP) for ischemic MR. Persistent subvalvular leaflet tethering in the presence of down-sized MAP causes functional MS, which is related to heart failure symptom after surgery. Down-sized MAP has been a standard procedure for ischemic MR and believed to be safe and effective over ten years. In 2008 Magne et al. first reported functional MS after MAP. However its mechanism was not clarified in this study. On the other hand, Kubota et al. examined subvalvular apparatus during exertion and indicated that not only MAP but also further mitral tethering causes functional MS. This study has a considerable impact on the surgical strategy for ischemic MR in the future. It would be necessary to consider not only the elimination of MR but also functional effects of various submitral procedures.

5. Conclusion

We can precisely assess the change of geometry of the submitral apparatus after operation by using 2-D transthoracic echocardiography. It would be useful for the comparison between different surgical procedures.

6. References

- Borger MA, Murphy PM, Alam A, et al. (2007) *J Thorac Cardiovasc Surg. Initial results of the chordal-cutting operation for ischemic mitral regurgitation.* 133:1483-1492.
- Goetz WA, Lim HS, Pekar F, et al. (2003) *Circulation. Anterior mitral leaflet mobility is limited by the basal stay chords.* 107:2969 -2974.
- Hvass U, Tapia M, Baron F, et al. (2003) *Ann Thorac Surg. Papillary muscle sling: a new functional approach to mitral repair in patients with ischemic left ventricular dysfunction and functional mitral regurgitation.* 75:809-811.
- Kron IL, Green GR & Cope JT. (2002) *Ann Thorac Surg. Surgical relocation of the posterior papillary muscle in chronic ischemic mitral regurgitation.* 74:600-601.
- Kubota K, Otsuji Y, Ueno T, et al. (2010) *J Thorac Cardiovasc Surg. Functional mitral stenosis after surgical annuloplasty for ischemic mitral regurgitation: Importance of subvalvular tethering in the mechanism and dynamic deterioration during exertion.* 140:617-623.
- Langer F, Rodriguez F, Ortiz S, et al. (2005) *Circulation. Subvalvular repair: the key to repairing ischemic mitral regurgitation?* 112:383-389.
- Langer F, Schäfers HJ. (2007) *J Thorac Cardiovasc Surg. RING plus STRING: papillary muscle repositioning as an adjunctive repair technique for ischemic mitral regurgitation.* 133:247-249.
- Magne J, Sénéchal M, Mathieu P, et al. (2008) *J Am Coll Cardiol. Restrictive annuloplasty for ischemic mitral regurgitation may induce functional mitral stenosis.* 51:1692-1701.
- Matsui Y, Suto Y, Shimura S, et al. (2005) *Ann Thorac Cardiovasc Surg. Impact of papillary muscles approximation on the adequacy of mitral coaptation in functional mitral regurgitation due to dilated cardiomyopathy.* 11:164-171.
- Matsunaga A, Tahta SA & Duran CM. (2004) *J Heart Valve Dis. Failure of reduction annuloplasty for functional ischemic mitral regurgitation.* 13:390-397.
- Messas E, Guerrero JL, Handschumacher MD, et al. (2001) *Circulation. Chordal cutting: a new therapeutic approach for ischemic mitral regurgitation.* 104:1958-1963.
- Messas E, Pouzet B, Touchot B, et al. (2003) *Circulation. Efficacy of chordal cutting to relieve chronic persistent ischemic mitral regurgitation.* 108:111-115.
- Nordblom P, Bech-Hanssen O. (2007) *Echocardiography. Reference values describing the normal mitral valve and the position of the papillary muscles.* 24:665-672.
- Rodriguez F, Langer F, Harrington KB, et al. (2004) *Circulation. Cutting second-order chords does not prevent acute ischemic mitral regurgitation.* 110:91-97.
- Shingu Y, Yamada S, Ooka T, et al. (2009) *Circ J. Papillary muscle suspension concomitant with approximation for functional mitral regurgitation.* 73:2061-2067.
- Vergnat M, Jassar AS, Jackson BM, et al. (2011) *Ann Thorac Surg. Ischemic mitral regurgitation: a quantitative three-dimensional echocardiographic analysis.* 91:157-164.



Echocardiography - New Techniques

Edited by Prof. Gani Bajraktari

ISBN 978-953-307-762-8

Hard cover, 218 pages

Publisher InTech

Published online 18, January, 2012

Published in print edition January, 2012

The book "Echocardiography - New Techniques" brings worldwide contributions from highly acclaimed clinical and imaging science investigators, and representatives from academic medical centers. Each chapter is designed and written to be accessible to those with a basic knowledge of echocardiography. Additionally, the chapters are meant to be stimulating and educational to the experts and investigators in the field of echocardiography. This book is aimed primarily at cardiology fellows on their basic echocardiography rotation, fellows in general internal medicine, radiology and emergency medicine, and experts in the arena of echocardiography. Over the last few decades, the rate of technological advancements has developed dramatically, resulting in new techniques and improved echocardiographic imaging. The authors of this book focused on presenting the most advanced techniques useful in today's research and in daily clinical practice. These advanced techniques are utilized in the detection of different cardiac pathologies in patients, in contributing to their clinical decision, as well as follow-up and outcome predictions. In addition to the advanced techniques covered, this book expounds upon several special pathologies with respect to the functions of echocardiography.

How to reference

In order to correctly reference this scholarly work, feel free to copy and paste the following:

Yasushige Shingu, Suguru Kubota and Yoshiro Matsui (2012). Evaluation of Subvalvular Apparatus by 2-D Transthoracic Echocardiography, Echocardiography - New Techniques, Prof. Gani Bajraktari (Ed.), ISBN: 978-953-307-762-8, InTech, Available from: <http://www.intechopen.com/books/echocardiography-new-techniques/evaluation-of-subvalvular-apparatus-by-2-d-transthoracic-echocardiography>

INTECH
open science | open minds

InTech Europe

University Campus STeP Ri
Slavka Krautzeka 83/A
51000 Rijeka, Croatia
Phone: +385 (51) 770 447
Fax: +385 (51) 686 166
www.intechopen.com

InTech China

Unit 405, Office Block, Hotel Equatorial Shanghai
No.65, Yan An Road (West), Shanghai, 200040, China
中国上海市延安西路65号上海国际贵都大饭店办公楼405单元
Phone: +86-21-62489820
Fax: +86-21-62489821

© 2012 The Author(s). Licensee IntechOpen. This is an open access article distributed under the terms of the [Creative Commons Attribution 3.0 License](#), which permits unrestricted use, distribution, and reproduction in any medium, provided the original work is properly cited.