

# Expression of Tumor Necrosis Factor-Alpha (TNF- $\alpha$ ), TNF- $\alpha$ Converting Enzyme and Matrix Metalloproteinase-3 in SAPHO Syndrome Synovium - A Rare Case Accompanied by Acrodermatitis Continua of Hallopeau: A Case Report and Review of Anti-TNF- $\alpha$ Therapy

Koichiro Komiya<sup>1</sup>, Nobuki Terada<sup>1</sup>,

Yoshikazu Mizoguchi<sup>2</sup> and Harumoto Yamada<sup>3</sup>

<sup>1</sup>Department of Orthopaedic Surgery, Fujita Health University Second Hospital

<sup>2</sup>Department of Pathology, Fujita Health University Second Hospital

<sup>3</sup>Department of Orthopaedic Surgery, Fujita Health University  
Japan

## 1. Introduction

Synovitis-acne-pustulosis-hyperostosis-osteitis (SAPHO) syndrome is a rare disorder characterized by osteoarticular and dermatological manifestations. The denotation was first proposed by Chamot et al. in 1987 after investigation of 85 cases (Chamot et al., 1987). The most common site of SAPHO syndrome is the upper anterior chest wall, characterized by predominantly osteosclerotic lesions and hyperostosis. The axial skeleton and peripheral bones can be involved. Peripheral synovitis is also common. Skin manifestations include palmoplantar pustulosis (PPP), severe acne and various patterns of psoriasis.

The pathogenesis of SAPHO syndrome has not been determined. Most of the reported series to date are anecdotal, small or uncontrolled, thus a variety of therapeutic approaches exist. Treatment remains empirical with several drugs including non-steroidal anti-inflammatory drugs (NSAIDs), corticosteroids, antibiotics, disease modifying anti-rheumatic drugs (DMARDs) and/or bisphosphonates (BPs), but results are inconsistent and usually variable. Recently, some successful experiences with anti-tumor necrosis factor-alpha (TNF- $\alpha$ ) agents for refractory cases have been reported (Asmussen, 2003; Ben Abdelghani et al., 2010; Castellvi et al., 2010; Deutschmann et al., 2005; Iqbal & Kolodney, 2005; Kyriazis et al., 2004; Massara et al., 2006; Moll et al., 2008; Olivieri et al., 2002; Sabugo et al., 2008; Wagner et al., 2002; Widmer et al., 2003). The therapeutic strategy was largely originated from that for spondyloarthropathies, because accumulated arguments indicate that SAPHO syndrome can be classified with the inflammatory spondyloarthropathies (Takigawa et al., 2008) and treatment with anti-TNF- $\alpha$  agents is now well established in spondyloarthropathies or rheumatoid arthritis (RA). Chronic proliferative synovitis is one of the most important

pathological features in RA, and proliferated synovium is a major source of proinflammatory cytokines and proteinases. TNF- $\alpha$  is a key cytokine, which triggers the inflammatory cascade and stimulates the production of matrix degradable proteinases such as matrix metalloproteinases (MMPs) (Okada, 2005). TNF- $\alpha$  converting enzyme (TACE) processes a membrane form of TNF- $\alpha$  to a soluble form (Moss et al., 1997), and the binding of the latter form to TNF receptors triggers pathological events in RA (Christodoulou & Choi, 2006; Horiuchi et al., 2010; Ohta et al., 2001). Although synovitis is one of the major manifestations of SAPHO syndrome, detailed information on the pathological features is still lacking.

In this chapter, we describe a patient with SAPHO syndrome accompanied by marked knee synovitis and acrodermatitis continua of Hallopeau (ACH) as a skin manifestation. ACH is a rare acropustular eruption, characterized by sterile pustules, paronychia and atrophic skin changes, onychodystrophy and osteolysis of the distal phalanges of the fingers and toes (Ryan et al., 2009). ACH is considered to be a localized subtype of pustular psoriasis (Yerushalmi et al., 2000) and our report is a first case of ACH as a skin manifestation of SAPHO syndrome. We focused on synovitis, analyzed synovial tissues histopathologically and demonstrated the expression of TNF- $\alpha$ , TACE and MMP-3 in SAPHO syndrome synovium. We also concisely review cases treated with anti-TNF- $\alpha$  agents in the literature and discuss the therapeutic strategy for SAPHO syndrome.

## 2. Case report

A 76-year-old Japanese man first presented to a neighborhood university hospital in 1993 with subungual pustules, erythema and onychodystrophy on all fingers and toes. A diagnosis of ACH was histologically confirmed at the time. He had been treated with topical corticosteroid and vitamin D3. In January 2006, he presented to our department for the first time with persistent swelling and pain in his left knee. Physical examination showed marked patellar ballottement with local heat. A knee puncture yielded 60mL of yellow cloudy joint fluid, but cultures for bacteria were negative. For other osteoarticular symptoms, moderate lower back and buttock pain existed but no other joint pain, costa-sterno-clavicular joint included, was found. At the time, dermatological symptoms of ACH still remained on all fingers and toes (Figure 1a, b). Laboratory tests showed almost within normal value including indices of inflammation (erythrocyte sedimentation rate 10mm/hour, C-reactive protein level 0.19mg/dL [normal <0.30mg/dL]) and rheumatoid factor was negative. Radiographic study revealed characteristic osteolysis in phalanges of fingers and toes (Figure 1c, d). Magnetic resonance imaging revealed knee synovitis and bone marrow edema at the second lumbar vertebral body (Figure 2), compatible with sterile osteitis.

We made a diagnosis of SAPHO syndrome because the presence of ACH (a variant of pustular psoriasis), knee synovitis, and osteitis of the vertebral body were sufficient to the criteria. The patient was treated with NSAIDs for osteoarticular symptoms and topical treatment for skin lesions.

In October 2007, arthroscopic surgery was performed for knee synovitis. Intra-operative findings showed marked proliferation of villous contoured synovial tissues with rich blood circulation (Figure 3a). Continuous paraffin sections of biopsied synovial tissues were used for histopathological analyses, and standard microscopic study showed hyperplastic synovitis with lymphocytes infiltration and many blood vessels similar to RA (Figure 3b, c, d). Immunohistochemistry revealed the expression of TNF- $\alpha$  (Figure 3e), TACE (Figure 3f)

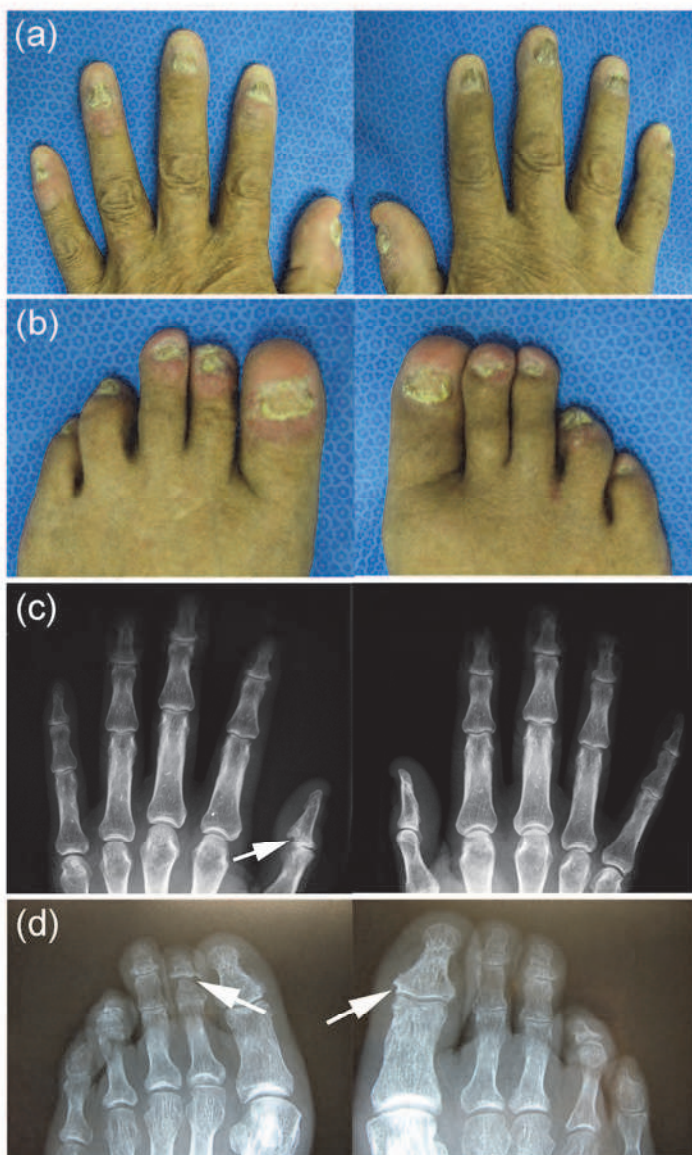

Fig. 1. Clinical findings of fingers (a), toes (b), and radiographs of bilateral fingers (c) and toes (d) in a patient with SAPHO syndrome accompanied by acrodermatitis continua of Hallopeau. Erythema, pustules and onychodystrophy are present on all fingers and toes, which are compatible with the dermatological features of acrodermatitis continua of Hallopeau (a, b). Characteristic osteolysis of acrodermatitis continua of Hallopeau are observed in phalanges of fingers (c) and toes (d).

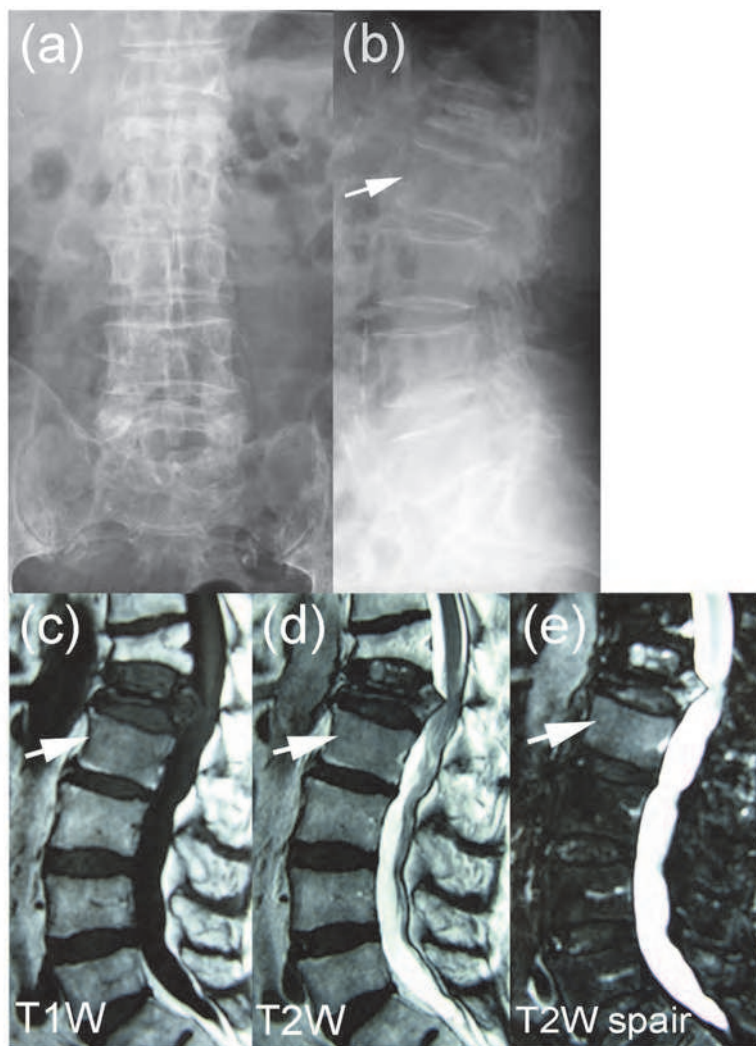


Fig. 2. Radiographic study (a, b) and magnetic resonance imaging (c, d, e) of lumbar spine in a patient with SAPHO syndrome accompanied by acrodermatitis continua of Hallopeau. Bone marrow edema at the second lumbar vertebral body (arrow) is compatible with sterile osteitis.

and MMP-3 (Figure 3g) in synovial cells of the lining layer. TNF- $\alpha$  and TACE were expressed dominantly in CD68 positive synovial cells of the lining and sublining layer, whereas MMP-3 was expressed dominantly in CD68 negative synovial cells of the lining layer (Figure 3e-h). Primary antibodies used for these analyses were polyclonal antibodies for TNF- $\alpha$  (654250; Calbiochem, Germany), TACE (sc-25782; Santa Cruz Biotechnology, USA), monoclonal antibodies for MMP-3 (55-2A2; Daiichi Fine Chemical Co., Japan) and CD68 (M0814; DakoCytomation, Denmark). After arthroscopic synovectomy, his knee symptoms immediately diminished. In 2008, additional administration of alendronate (35

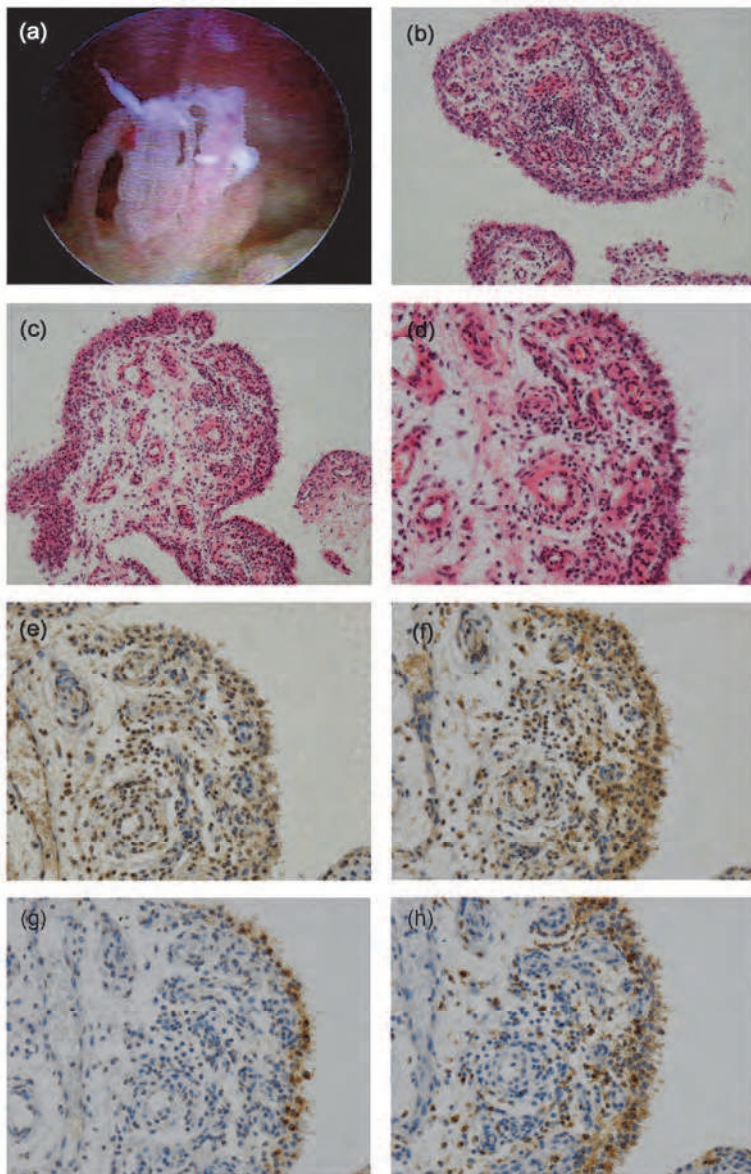


Fig. 3. Macro- and microscopic findings of knee synovitis in a patient with SAPHO syndrome accompanied by acrodermatitis continua of Hallopeau. Arthroscopy reveals RA like villous contoured synovial tissues with rich blood circulation (a). Continuous paraffin sections (b-h) were stained with hematoxylin and eosin (b-d) or immunostained with antibodies against TNF- $\alpha$  (e), TACE (f), MMP-3 (g), or CD68 (h). Note that hyperplastic synovitis with lymphocytes infiltration, rich blood vessels similar to RA (b, c, d), and TNF- $\alpha$ , TACE and MMP-3 are expressed in synovial lining cells (e-g).

mg/week) was started. In the four year follow-up period, there has been no recurrence of knee synovitis, no exacerbation of dermatological symptoms of ACH, and the patient has had only mild low back pain which have responded to NSAIDs and alendronate.

### 3. Discussion

In the present case, we investigated the histopathological features of SAPHO syndrome synovitis. Arthroscopic findings showed moderate proliferation of villous contoured synovial tissues with rich blood circulation. Microscopic findings showed hyperplastic synovitis with lymphocytes infiltration and many blood vessels. Further immunohistochemistry showed that TNF- $\alpha$  and TACE were expressed dominantly in CD68 positive macrophage like synovial cells of lining and sublining layer while MMP-3 was expressed dominantly in CD68 negative fibroblast like synovial cells of lining layer. These histopathological features were overlapped with those of RA synovitis. But the extent of each microscopic feature, such as hyperplasticity of lining layers, lymphocytes infiltration and vascular density, seemed to be more marked in RA than SAPHO syndrome. Furthermore, in our previously reported a case of SAPHO syndrome accompanied by marked knee synovitis and PPP as a skin manifestation, the histopathological features of synovitis were also similar to this case (Komiya et al., 2009). Although it is difficult to compare with past cases for lack of reports with detailed histopathological analyses of SAPHO syndrome synovitis, it is speculated that TNF- $\alpha$  may be produced abundantly and well activated by TACE in SAPHO synovitis, and this condition at least partially have a common with RA synovial pathogenesis.

SAPHO syndrome is characterized by the osteoarticular and dermatological symptoms that were compiled by French rheumatologists after a national survey carried in 1987 (Chamot et al., 1987). The acronym SAPHO stands for synovitis, acne, pustulosis, hyperostosis, osteitis (Chamot et al., 1987). As described by Kahn et al. in 1994, three diagnostic criteria characterize SAPHO syndrome: 1) multifocal osteomyelitis with or without skin manifestations; 2) sterile acute or chronic joint inflammation associated with either pustular psoriasis or palmo-plantar pustulosis, or acne, or hidradenitis; 3) sterile osteitis in the presence of one of the skin manifestations (Kahn et al., 1993, 1994). According to Kahn, one of the criteria is sufficient for the diagnosis of SAPHO syndrome.

The etiology and prevalence of SAPHO syndrome has not been determined because of the variety in clinical appearance. Although the osteoarticular symptoms of SAPHO syndrome are most commonly observed in the anterior chest wall and the spine, the taxonomic concept of spinal lesions of SAPHO syndrome is still confused and controversial; whether SAPHO syndrome is classified in to seronegative spondyloarthritis (SNSA) or not (Hayem et al., 1999; Higashi et al., 2005). Accumulated data suggested that SAPHO syndrome can be classified into SNSA; a high prevalence of axial involvement (up to 90%), an increased frequency of positive HLA-B27 (15%), and an association with psoriasis and inflammatory bowel syndrome in 13% of cases (Ben Abdelghani et al., 2010; Kahn et al., 1992). Furthermore, many researchers have supported a link between SAPHO syndrome and SNSA. Maugars reported that 43% and 33% of 19 SAPHO syndrome patients fulfilled the criteria of European Spondylarthropathy Study Group (ESSG) (Dougados et al., 1991) and Amor (Amor et al., 1990), respectively (Maugars et al., 1995). Hukuda et al. reported that

4.7% and 0.3% of Japanese 990 SNSA patients showed PPP and SAPHO syndrome, respectively (Hukuda et al., 2001). Takigawa et al. reported that 23% of 13 SAPHO syndrome patients met the criteria of SNSA regardless of whether ESSG or Amor criteria were used (Takigawa et al., 2008). In their series, if PPP is added as a skin lesion to the criteria of spondyloarthritis, 100% and 92% of their cases would fulfill the diagnostic criteria of ESSG and Amor, respectively. Sonozaki proposed pustulotic arthro-osteitis is one subtype of SNSA (Sonozaki et al., 1981). Thus Takigawa et al. proposed that SAPHO syndrome, especially spinal lesions related to PPP, should be recognized as a subtype of SNSA (Takigawa et al., 2008).

The treatment of SAPHO syndrome remains empirical. In practice, NSAIDs are applied for osteoarticular symptoms and topical treatment for skin lesions. This first-line treatment is effective in two-thirds of cases (Hayem et al., 1999). In cases not respond to the first-line treatment, the second-line treatment, including glucocorticoids, BPs, and DMARDs such as methotrexate and sulfasalazine, is considered, but results are usually inconsistent and insufficient (Hayem et al., 1999). Recently some successful experiences with anti-TNF- $\alpha$  agents for recalcitrant cases of SAPHO syndrome have been reported (Asmussen, 2003; Ben Abdelghani et al., 2010; Castellvi et al., 2010; Deutschmann et al., 2005; Iqbal & Kolodney, 2005; Kyriazis et al., 2004; Massara et al., 2006; Moll et al., 2008; Olivieri et al., 2002; Sabugo et al., 2008; Wagner et al., 2002; Widmer et al., 2003). This therapeutic strategy was largely originated from that for spondyloarthropathies in which the efficacy and safety of anti-TNF- $\alpha$  therapy is well established (Davis et al., 2003; Mease et al., 2000; Moreland et al., 1999).

TNF- $\alpha$  is a proinflammatory cytokine found in increased concentrations in the joints and skin of patients with RA, psoriatic arthritis and psoriasis, and plays crucial roles in the pathogenesis of these chronic inflammatory disease (Bradley, 2008; Ettehadi et al., 1994; Feldmann & Maini, 2001; Partsch et al., 1997; Tutrone et al., 2001). In RA synovium, TNF- $\alpha$  is produced abundantly and contribute to the pathogenesis by inducing the production of other proinflammatory cytokines, chemokines, and MMPs (Brennan et al., 1995; Ivashkiv, 1996; MacNaul et al., 1990). TNF- $\alpha$  is generated as a proform called transmembrane TNF- $\alpha$  that is consist of 233 amino acid residues (26kDa) and expressed on TNF- $\alpha$ -producing cells as a homotrimer (Kriegler et al., 1988; Luettiq et al., 1989; Pennica et al., 1984). This transmembrane TNF- $\alpha$  is cleaved between alanine<sup>76</sup>-valine<sup>77</sup> bond by TACE, resulting in the release of soluble TNF- $\alpha$  that is consist of 157 amino acid residues (17kDa). Soluble TNF- $\alpha$  is a homotrimer of 17-kDa cleaved monomers and transmembrane TNF- $\alpha$  also exists as a homotrimer of 26-kDa uncleaved monomers (Tang et al., 1996). Both soluble and transmembrane TNF- $\alpha$  mediate pleiotrophic effects (apoptosis, cell proliferation and cytokine production) through binding to type 1 and type 2 TNF receptors (TNF-R1 and TNF-R2), but transmembrane TNF- $\alpha$  is supposed to mediate its biological activities mainly through TNF-R2 (Bazzoni & Beutler, 1996; Black et al., 1997; Grell et al., 1995; Moss et al., 1997; Vandenabeele et al., 1995). The remaining of cytoplasmic domain of transmembrane TNF- $\alpha$  after cleavage with TACE migrated back into the nucleus of the transmembrane TNF- $\alpha$ -expressing cells and is supposed to mediate cytokine production (Domonkos et al., 2001). It is very interesting that transmembrane TNF- $\alpha$  transmits signals both as a ligand and as a receptor. Differential clinical efficacies of anti-TNF- $\alpha$  agents may be explained by their different action on transmembrane TNF- $\alpha$ -expressing cells (Horiuchi et al., 2010).

TACE plays a crucial role in post-translational regulation of TNF- $\alpha$ . Binding of soluble TNF- $\alpha$  to TNF receptors activate various pathological events including the production of MMPs. TACE is a member of the ADAM (a disintegrin and metalloproteinase) family proteins, which possess characteristics of both cell surface adhesion molecules and proteinases. Some of the ADAM family proteins, including TACE, are considered to be responsible for the proteolytic processing of ectodomain of various cell surface molecules such as cytokines, cytokine receptors, adhesion molecules, and enzymes (Klein & Bischoff, 2011; Okada, 2005; Seals & Courtneidge, 2003). Several studies indicate that TACE levels are elevated in RA joints compared with osteoarthritis or normal articulations, suggesting that abnormal TACE activity contributes to TNF- $\alpha$  action in RA pathogenesis (Ohta et al, 2001). In the present case and in our previously reported case (Komiya et al., 2009), we demonstrated the expression of TNF- $\alpha$ , TACE and MMP-3 in SAPHO syndrome synovitis, thus it is speculated that TACE play roles in the pathogenesis of SAPHO syndrome synovitis through the processing of TNF- $\alpha$ , which triggers a cascade of pathological events through a mechanism similar to RA.

To our knowledge, 26 cases of SAPHO syndrome treated with anti-TNF- $\alpha$  agents (infliximab, etanercept or adalimumab) have been described, all of them showing a sustained response of osteoarticular manifestations (Asmussen, 2003; Ben Abdelghani et al., 2010; Castellvi et al., 2010; Deutschmann et al., 2005; Iqbal & Kolodney., 2005; Kyriazis et al., 2004; Massara et al., 2006; Moll et al., 2008; Olivieri et al., 2002; Sabugo et al., 2008; Wagner et al, 2002; Widmer et al., 2003), but not favorable for cutaneous manifestations in some cases (Ben Abdelghani et al., 2010; Massara et al., 2006). In the 26 previously reported cases in the literature, clinical response was rapid after within 2 infusions of anti-TNF- $\alpha$  agent in most of cases (24/26 cases, 92%). Clinical response was maintained in all cases, and clinical remission, which usually described as no recurrence of osteoarticular pain, was maintained with a follow up 8 to 42 months during treatment. Thus it is considered that the efficacy of anti-TNF- $\alpha$  agents on osteoarticular symptoms is reliable. Whereas, relapse or worsening of the skin lesion after anti-TNF- $\alpha$  therapy was observed in 5/26 cases (19%) (Ben Abdelghani et al., 2010; Massara et al., 2006). ACH, a skin lesion of this case, is a rare chronic pustular eruption of the distal portions of the hands and feet, characterized by sterile pustules, paronychia and atrophic skin changes, onychodystrophy and osteolysis of the distal phalanges (Puig et al., 2010; Ryan et al., 2009). It is considered by many to be a localized variant of pustular psoriasis. (Kurooka et al., 2010; Yerushalmi et al., 2000). ACH is notoriously difficult to treat, with limited success with numerous agents including topical treatments, photochemotherapy, ciclosporin, methotrexate, retinoids, dapsone and tetracyclines (Nikkels et al., 1999). Recently successful treatment of ACH with anti-TNF- $\alpha$  agents have been reported (Ahmad & Rogers, 2007; Bonish et al., 2006; Kazinski et al., 2005; Mang et al., 2004; Ryan et al., 2009). But in some cases of ACH, failed treatment with anti-TNF- $\alpha$  agents have been also reported (Adisen et al., 2007; Thielen et al., 2008; Ryan et al., 2009). In a recent review, 120 patients (with RA, ankylosing spondylitis, psoriasis, Crohn disease, SAPHO syndrome, psoriatic arthritis, and other diagnosis) from the literature who developed pustular lesions during treatment with anti-TNF- $\alpha$  agents were reported (Wollina et al., 2008). Psoriasis (except palmoplantar pustular type) was the most common adverse effect during anti-TNF- $\alpha$  agent treatment (n=73), followed by PPP (n=37). The reasons for these negative or paradoxical effects of anti-TNF- $\alpha$  agents on cutaneous



manifestations have not yet been determined. One possible reason is that TNF- $\alpha$  is a pivotal mediator of the activation of neutrophils (Lebwohl, 2003), because in SAPHO syndrome, skin lesions are usually characterized by neutrophil infiltration similar to those of pustular psoriasis. Another possible reason for deterioration of skin pustules could be activation of *Propionibacterium acnes* with anti TNF- $\alpha$ . *P. acnes* is anaerobic skin saprophyte, which has been strongly implicated in SAPHO syndrome (Perry & Lambert, 2006). Assmann et al. showed positive bacteriological cultures for *P. acnes* in 14 of 21 (67%) patients who had undergone a needle biopsy of osteitis lesions (Assmann et al., 2009). Rozin reported that *P. acnes* was positive in 38/90 cases (42%) in bone lesions in cases of SAPHO syndrome in the literature (Rozin, 2009). Bacterial or viral infections induces rheumatic condition, thus *P. acnes* could be an important pathogen in SAPHO syndrome. Thus, taking into consideration of *P. acnes*, combination of anti-TNF- $\alpha$  agents and antibiotics may prevent the exacerbation of skin lesion.

In cases not respond to the first-line treatment, BPs could be a good therapeutic modality except anti-TNF- $\alpha$  agents. Recently some successful treatments of SAPHO syndrome with BPs have been reported (Amital et al., 2004; Colina et al., 2009; Siau & Laversuch, 2010). BPs are potent inhibitors of osteoclastic bone resorption and are an important therapeutic modality in the management of Paget's disease, multiple myeloma, malignancy-associated hypercalcaemia, bone metastasis and osteoporosis. Not only the effect on bone remodeling, BPs have also an anti-inflammatory effect by suppressing the production of proinflammatory cytokines, such as interleukin (IL)-1, TNF- $\alpha$ , IL-6, and by inhibiting the antigen-presenting capacity of macrophages (de Vries et al., 1982; Pennanen et al., 1995). Amital et al. reported successful treatment with pamidronate in 10 patients with SAPHO syndrome (Amital et al., 2004). Intravenous administration of pamidronate was effective for not only osteoarticular manifestations but also skin lesions (Amital et al., 2004). Oral administration of BPs is also effective in treating SAPHO syndrome (Ichikawa et al., 2009). The modulation ability of BPs for anti-inflammatory cytokines, including TNF- $\alpha$ , could be a reason for their efficacy in several rheumatological conditions, such as ankylosing spondylitis, hypertrophic osteoarthropathy, reflex sympathetic dystrophy, diabetic neuropathic arthropathy and the SAPHO syndrome (de Vries et al., 1982; Garske & Bell, 2002; Guignard et al., 2002; Kubalek et al., 2001; Maksymowych et al., 2002; Marshall et al., 2002; Maugars et al., 1995; Pennanen et al., 1995; Selby et al., 1994). Ben Abdelghani et al. reported five cases not respond to BPs and four of these cases responded to anti-TNF- $\alpha$  therapy (Ben Abdelghani et al., 2010). Thus, anti-TNF- $\alpha$  therapy seems effective even for cases resistant to BPs.

The difficulties in the treatment of SAPHO syndrome are integrated into its complicated, not single, pathogenesis. Our experience support the importance of TNF- $\alpha$  and TACE in the pathogenesis of SAPHO syndrome, but further investigations are clearly needed to elucidate this rare and complicated disorder.

#### 4. Conclusion

We describe a rare case of SAPHO syndrome accompanied by marked knee synovitis and ACH as a skin manifestation. We demonstrated the expression of TNF- $\alpha$ , TACE and MMP-3 in SAPHO syndrome synovium and also shown the similarity between SAPHO syndrome

and RA synovitis. These new findings support the recently reported successful treatment of osteoarticular manifestations of SAPHO syndrome with anti-TNF- $\alpha$  agents.

## 5. References

- Adisen, E., Oztas, M., & Gurer, MA. (2007). Lack of efficacy of etanercept in acrodermatitis continua of Hallopeau. *International Journal of Dermatology*, Vol.46, No.11, pp. 1205-1207.
- Ahmad, K. & Rogers, S. (2007). Two years of experience with etanercept in recalcitrant psoriasis. *The British Journal of Dermatology*, Vol.156, No.5, pp. 1010-1014.
- Amital, H., Applbaum, YH., Asmar, S., Daniel, N., & Rubinow, A. (2004). SAPHO syndrome treated with pamidronate: an open-label study of 10 patients. *Rheumatology (Oxford)*, Vol.43, No.5, pp. 658-661.
- Amor, B., Dougados, M., & Mijiyawa, M. (1990). Criteria of the classification of spondyloarthropathies. *Revue du Rhumatisme et des Maladies Osteoarticulaires*, Vol.57, No.2, pp. 85-89.
- Asmussen, KH. (2003). Successful treatment of SAPHO syndrome with infliximab. A case report [abstract]. *Arthritis and Rheumatism*, Vol.48, S621A.
- Assmann, G., Kueck, O., Kirchhoff, T., Rosenthal, H., Voswinkel, J., Pfreundschuh, M., Zeidler, H., & Wagner, AD. (2009). Efficacy of antibiotic therapy for SAPHO syndrome is lost after its discontinuation: interventional study. *Arthritis Research & Therapy*, Vol.11, No.5, R140.
- Bazzoni, F. & Beutler, B. (1996). The tumor necrosis factor ligand and receptor families. *The New England Journal of Medicine*, Vol.334, No.26, pp. 1717-1725.
- Ben Abdelghani, K., Dran, DG., Gottenberg, JE., Morel, J., Sibilia, J., & Combe, B. (2010). Tumor necrosis factor-alpha blockers in SAPHO syndrome. *The Journal of Rheumatology*, Vol.37, No.8, pp. 1699-1704.
- Black, RA., Rauch, CT., Kozlosky, CJ., Peschon, JJ., Slack, JL., Wolfson, MF., Castner, BJ., Stocking, KL., Reddy, P., Srinivasan, S., Nelson, N., Boiani, N., Schooley, KA., Gerhart, M., Davis, R., Fitzner, JN., Johnson, RS., Paxton, RJ., March, CJ., & Cerretti, DP. (1997). A metalloproteinase disintegrin that releases tumor-necrosis factor-alpha from cells. *Nature*, Vol.385, No.6618, pp. 729-733.
- Bonish, B., Rashid, RM., & Swan, J. (2006). Etanercept responsive acrodermatitis continua of Hallopeau: Is a pattern developing? *Journal of Drugs in Dermatology*, Vol.5, No.9, pp. 903-904.
- Bradley, JR. (2008). TNF-mediated inflammatory disease. *Journal of Pathology*, Vol.214, No.2, pp. 149-160.
- Brennan, FM., Maini, RN., & Feldmann, M. (1995). Cytokine expression in chronic inflammatory disease. *British Medical Bulletin*, Vol.51, No.2, pp. 368-384.
- Castellvi, I., Bonet, M., Nazarez, JA., & Molina-Hinojosa, JC. (2010). Successful treatment of SAPHO syndrome with adalimumab: a case report. *Clinical Rheumatology*, Vol.29, No.10, pp. 1205-1207.
- Chamot, AM., Benhamou, CL., Kahn, MF., Beranek, L., Kaplan, G., & Prost, A. (1987). Acne-pustulosis-hyperostosis-osteitis syndrome. Results of a national survey. 85

- cases. *Revue du Rhumatisme et des Maladies Osteoarticulaires*, Vol.54, No.3, pp. 187-196.
- Christodoulou, C. & Choy, EH. (2006). Joint inflammation and cytokine inhibition in rheumatoid arthritis. *Clinical and Experimental Medicine*, Vol.6, No.1, pp. 13-19.
- Colina, M., La Corte, R., & Trotta, F. (2009). Sustained remission of SAPHO syndrome with pamidronate: a follow-up of fourteen cases and a review of the literature. *Clinical and Experimental Rheumatology*, Vo.27, No.1, pp. 112-115.
- Davis, JC Jr., van der Heijde, D., Braun, J., Dougados, M., Cush, J., Clegg, DO., Kivitz, A., Fleischmann, R., Inman, R., & Tsuji, W.; Enbrel Ankylosing Spondylitis Study Group. (2003). Recombinant human tumor necrosis factor receptor (etanercept) for treating ankylosing spondylitis: a randomized, controlled trial. *Arthritis and Rheumatism*, Vol.48, No.11, pp. 3230-3236.
- Deutschmann, A., Mache, CJ., Bodo, K., Zebedin, D., & Ring, E. (2005). Successful treatment of chronic recurrent multifocal osteomyelitis with tumor necrosis factor-blockage. *Pediatrics*, Vol.116, No.5, pp. 1231-1233.
- de Vries, E., van der Weij, JP., van der Veen, CJ., van Paassen, HC., Jager, MJ., Sleeboom, HP., Bijvoet, OL., & Cats, A. (1982). In vitro effect of (3-amino-1-hydroxypropylidene)-1, 1-bisphosphonic acid (APD) on the function of mononuclear phagocytes in lymphocyte proliferation. *Immunology*, Vol.47, No.1, pp. 157-163.
- Domonkos, A., Udvardy, A., Laszlo, L., Nagy, T., & Duda, E. (2001). Receptor-like properties of the 26 kDa transmembrane form of TNF. *European Cytokine Network*, Vol.12, No.3, pp. 411-419.
- Dougados, M., van der Linden, S., Juhlin, R., Huitfeldt, B., Amor, B., Calin, A., Dijkmans, B., Olivieri, I., & Pasero, G. (1991). The European Spondyloarthritis Study Group preliminary criteria for the classification of spondyloarthritis. *Arthritis and Rheumatism*, Vol.34, No.10, pp. 1218-1227.
- Ettehad, P., Greaves, MW., Wallach, D., Aderka, D., & Camp, RD. (1994). Elevated tumor necrosis factor-alpha (TNF-alpha) biological activity in psoriatic skin lesions. *Clinical and Experimental Immunology*, Vol.96, No.1, pp. 146-151.
- Feldmann, M. & Maini, RN. (2001). Anti-TNF alpha therapy of rheumatoid arthritis: what have we learned? *Annual Review of Immunology*, Vol.19, pp. 163-196.
- Garske, LA. & Bell, SC. (2002). Pamidronate results in symptom control of hypertrophic pulmonary osteoarthropathy in cystic fibrosis. *Chest*, Vo.121, No.4, pp. 1363-1366.
- Grell, M., Douni, E., Wajant, H., Lohden, M., Clauss, M., Maxeiner, B., Georgopoulos, S., Lesslauer, W., Kollias, G., Pfizenmaier, K., & Scheurich, P. (1995). The transmembrane form of tumor necrosis factor is the prime activating ligand of the 80 kDa tumor necrosis factor receptor. *Cell*, Vol.83, No.5, pp. 793-802.
- Guignard, S., Job-Deslandre, C., Sayag-Boukris, V., & Kahan, A. (2002). Pamidronate treatment in SAPHO syndrome. *Joint Bone Spine*, Vol.69, No.4, pp. 392-396.
- Hayem, G., Bouchaud-Chabot, A., Benali, K., Roux, S., Palazzo, E., Silbermann-Hoffman, O., & Meyer, O. (1999). SAPHO syndrome: a long-term follow-up study of 120 cases. *Seminars in Arthritis and Rheumatism*, Vol.29, No.3, pp. 159-171.

- Higashi, S., Nakamura, T., Tomoda, K., Tsukano, M., Sakaguchi, M., & Kuga, F. (2005). A study of ten Japanese patients with seronegative spondyloarthropathy: a tentative proposal. *Modern Rheumatology*, Vol.15, No.5, pp. 329-335.
- Horiuchi, T., Mitoma, H., Harashima, S., Tsukamoto, H., & Shimoda, T. (2010). Transmembrane TNF- $\alpha$ : structure, function and interaction with anti-TNF agents. *Rheumatology (Oxford)*, Vol.49, No.7, pp. 1215-1228.
- Hukuda, S., Minami, M., Saito, T., Mitsui, H., Matsui, N., Komatsubara, Y., Makino, H., Shibata, T., Shingu, M., Sakou, T., & Shichikawa, K. (2001). Spondyloarthropathies in Japan: nationwide questionnaire survey performed by the Japan Ankylosing Spondylitis Society. *The Journal of Rheumatology*, Vol.28, No.3, pp. 554-559.
- Ichikawa, J., Sato, E., Haro, H., Ando, T., Maekawa, S., & Hamada, Y. (2009). Successful treatment of SAPHO syndrome with an oral bisphosphonate. *Rheumatology International*, Vol.29, No.6, pp. 713-715.
- Iqbal, M. & Kolodney, MS. (2005). Acne fulminans with synovitis-acne-pustulosis-hyperostosis-osteitis (SAPHO) syndrome treated with infliximab. *Journal of the American Academy of Dermatology*, Vo.52, No.5 (Suppl 1), S118-120.
- Ivashkiv, LB. (1996). Cytokine expression and cell activation in inflammatory arthritis. *Advances in Immunology*, Vol.63, pp. 337-376.
- Kahn, MF., Bouchon, JP., Chamot, AM., & Palazzo, E. (1992). Chronic Enterocolopathies and SAPHO syndrome. 8 cases. *Revue du Rhumatisme et des Maladies Osteoarticulaires*, Vo.59, No.2, pp. 91-94.
- Kahn, MF. (1993). Psoriatic arthritis and synovitis, acne, pustulosis, hyperostosis, and osteitis syndrome. *Current Opinion in Rheumatology*, Vol.5, No.4, pp. 428-435.
- Kahn, MF. & Kahn, MA. (1994). The SAPHO-syndrome, In: *Psoriatic Arthritis (Baillere's Clinical Rheumatology)*. Wright V. & Helliwell P., Vol.8/2, pp. 333-362, Baillere Tindall, ISBN 0702018201.
- Kazinski, K., Joyce, KM., & Hodson, D. (2005). The successful use of etanercept in combination therapy for treatment of acrodermatitis continua of Hallopeau. *Journal of Drugs in Dermatology*, Vol.4, No.3, pp. 360-364.
- Klein, T. & Bischoff, R. (2011). Active metalloproteases of the A Disintegrin and Metalloprotease (ADAM) family: biological function and structure. *Journal of Proteome Research*, Vol.10, No.1, pp. 17-33.
- Komiya, K., Yamada, H., Terada, N., Mizoguchi, Y., Yamada, M., Suzuki, M., & Kato, S. (2009). Expression of tumor necrosis factor-alpha converting enzyme and matrix metalloproteinase-3 in proliferated synovium in a patient with synovitis-acne-pustulosis-hyperostosis-osteitis syndrome: a case report. *Journal of medical case reports*, 3:9123. (doi: 10.4076/1752-1947-3-9123).
- Kriegler, M., Perez, C., DeFay, K., Albert, I., & Lu, SD. (1988). A novel form of TNF/cashectin is a cell surface cytotoxic transmembrane protein: ramifications for the complex physiology of TNF. *Cell*, Vol.53, No.1, pp. 45-53.
- Kubalek, I., Fain, O., Paries, J., Kettaneh, A., & Thomas, M. (2001). Treatment of reflex sympathetic dystrophy with pamidronate: 29 cases. *Rheumatology (Oxford)*, Vol.40, No.12, pp. 1394-1397.

- Kurooka, S., Tsuruta, D., Hino, M., Yanagihara, S., & Ishii, M. (2010). Acrodermatitis continua of Hallopeau appearing at specific, high leucocyte counts. *The British Journal of Dermatology*, Vol.163, No.2, pp. 428-430.
- Kyriazis, NC., Tachoula, AV., & Sfontouris, CI. (2004). Successful treatment of refractory SAPHO syndrome with infliximab [abstract]. *Annals of the Rheumatic Diseases*, Vol.63, 388-9A.
- Lebwohl, M. (2003). Psoriasis. *Lancet*, Vol.361, No.9364, pp. 1197-1204.
- Luettig, B., Decker, T., & Lohmann-Matthes, ML. (1989). Evidence for the existence of two form membrane tumor necrosis factor: an integral protein and a molecule attached to its receptor. *Journal of Immunology*, Vol.143, No.12, pp. 4034-4038.
- MacNaul, KL., Chartrain, N., Lark, M., Tocci, MJ., & Hutchinson, NI. (1990). Discoordinate expression of stromelysine, collagenase, and tissue inhibitor of metalloproteinases-1 in rheumatoid human synovial fibroblasts. Synergistic effects of interleukin-1 and tumor necrosis factor-alpha on stromelysine expression. *The Journal of Biological Chemistry*, Vol.265, No.28, pp. 17238-17245.
- Maksymowych, WP., Jhangri, GS., Fitzgerald, AA., LeClercq, S., Chiu, P., Yan, A., Skeith, KJ., Aaron, SL., Homik, J., Davis, P., Sholter, D., & Russell, AS. (2002). A six-month randomized, controlled, double-blind, dose-response comparison of intravenous pamidronate (60 mg versus 10 mg) in the treatment of nonsteroidal antiinflammatory drug-refractory ankylosing spondylitis. *Arthritis and Rheumatism*, Vol.46, No.3, pp. 766-773.
- Mang, R., Ruzicka, T., & Stege, H. (2004). Successful treatment of acrodermatitis Hallopeau by the tumor necrosis factor-alpha inhibitor infliximab (Remicade). *The British Journal of Dermatology*, Vol.150, No.2, pp. 379-380.
- Marshall, H., Bromilow, J., Thomas, AL., & Arden, NK. (2002). Pamidronate: a novel treatment for the SAPHO syndrome? *Rheumatology (Oxford)*, Vol.41, No.2, pp. 231-233.
- Massara, A., Cavazzini, PL., & Trotta, F. (2006). In SAPHO syndrome anti-TNF-alpha therapy may induce persistent amelioration of osteoarticular complaints, but may exacerbate cutaneous manifestations. *Rheumatology*, Vol.45, No.6, pp. 730-733.
- Maugars, Y., Berthelot, JM., Ducroux, JM., & Prost, A. (1995). SAPHO syndrome: a followup study of 19 cases with special emphasis on enthesitis involvement. *The Journal of Rheumatology*, Vol.22, No.11, pp. 2135-2141.
- Mease, PJ., Goffe, BS., Metz, J., VanderStoep, A., Finck, B., & Burge, DJ. (2000). Etanercept in the treatment of psoriatic arthritis and psoriasis: a randomized trial. *Lancet*, Vol.356, No.9227, pp. 385-390.
- Moll, C., Hernandez, MV., Canete, JD., Gomez-Puerta, JA., Soriano, A., Collado, A., & Sanmarti, R. (2008). Ilium osteitis as the main manifestation of the SAPHO syndrome: response to infliximab therapy and review of the literature. *Seminars in Arthritis and Rheumatism*, Vol.37, No.5, pp. 299-306.
- Moreland, LW., Schiff, MH., Baumgartner, SW., Tindall, EA., Fleischmann, RM., Bulpitt, KJ., Weaver, AL., Keystone, EC., Furst, DE., Mease, PJ., Ruderman, EM., Horwitz, DA., Arkfeld, DG., Garrison, L., Burge, DJ., Blosch, CM., Lange, ML.,


- McDonnell, ND., & Weinblatt, ME. (1999). Etanercept therapy in rheumatoid arthritis. A randomized, controlled trial. *Annals of Internal Medicine*, Vol.130, No.6, pp. 478-486.
- Moss, ML., Jin, SL., Becherer, JD., Bickett, DM., Burkhart, W., Chen, WJ., Hassler, D., Leesnitzer, MT., McGeehan, G., Milla, M., Moyer, M., Rocque, W., Seaton, T., Schoenen, F., Warner, J., & Willard, D. (1997). Structural features and biochemical properties of TNF-alpha converting enzyme (TACE). *Journal of Neuroimmunology*, Vol.72, No.2, pp. 127-129.
- Nikkels, AF., Nikkels-Tassoudji, N., & Pierard, GE. (1999). Breaking the relentless course of Hallopeau's acrodermatitis by dapsone. *European Journal of Dermatology*, Vol.9, No.2, pp. 126-128.
- Ohta, S., Harigai, M., Tnaka, M., Kawaguchi, Y., Sugiura, T., Takagi, K., Fukasawa, C., Hara, M., & Kamatani, N. (2001). Tumor necrosis factor-alpha (TNF-alpha) converting enzyme contributes to production of TNF-alpha in synovial tissues from patients with rheumatoid arthritis. *Journal of Rheumatology*, Vol.28, No.8, pp. 1756-1763.
- Okada, Y. (2005). Proteinases and matrix degradation, In: *Kelley's Textbook of Rheumatology (7th edition)*, Harris ED Jr., Budd RC., Ruddy S., Genovese MC., Firestein GS., & Sargent JS., pp. 63-81, Elsevier Saunders, ISBN 0721601413, Philadelphia
- Olivieri, I., Padula, A., Ciancio, G., Salvarani, C., Niccoli, L., & Cantini, F. (2002). Successful treatment of SAPHO syndrome with infliximab: report of two cases. *Annals of the Rheumatic Diseases*, Vo.61, No.4, pp. 375-376.
- Partsch, G., Steiner, G., Leeb, BF., Dunky, A., Broll, H., & Smolen, JS. (1997). Highly increased levels of tumor necrosis factor-alpha and other proinflammatory cytokines in psoriatic arthritis synovial fluid. *Journal of Rheumatology*, Vol.24, No.3, pp. 518-523.
- Pennanen, N., Lapinjoki, S., Urtti, A., & Monkkonen, J. (1995). Effect of liposomal and free bisphosphonates on the IL-1beta, IL-6, and TNF alpha secretion from RAW264 cells in vitro. *Pharmaceutical Research*, Vol.12, No.6, pp. 916-922.
- Pennica, D., Nedwin, GE., Hayflick, JS., Seeburg, PH., Derynck, R., Palladino, MA., Aggarwal, BB., & Goeddel, DV. (1984). Human tumor necrosis factor: precursor structure, cDNA cloning, expression and homology to lymphotoxin. *Nature*, Vol.312, No.5996, pp. 724-729.
- Perry, AL. & Lambert, PA. (2006). Propionibacterium acnes. *Letters in Applied Microbiology*, Vol.42, No.3, pp. 185-188.
- Puig, L., Barco, D., Vilarrasa, E., & Alomar, A. (2010). Treatment of acrodermatitis continua of Hallopeau with TNF-blocking agents: case report and review. *Dermatology*, Vol.220, No.2, pp. 154-158.
- Rozin, AP. (2009). SAPHO syndrome: Is a range of pathogen-associated rheumatic disease extend? *Arthritis Research & Therapy*, Vol.11, No.6, 131. (doi:10.1186/ar2837), Available from <http://arthritis-research.com/content/11/6/131>

- Ryan, C., Collins, P., Kirby, B., & Rogers, S. (2009). Treatment of acrodermatitis continua of Hallopeau with adalimumab. *The British Journal of Dermatology*, Vol.160, No.1, pp. 203-205.
- Sabugo, F., Liberman, C., Niedmann, JP., Soto, L., & Cuchacovich, M. (2008). Infliximab can induce a prolonged clinical remission and a decrease in thyroid hormonal requirements in a patient with SAPHO syndrome and hypothyroidism. *Clinical Rheumatology*, Vol.27, No.4, pp. 533-535.
- Seals, DF. & Courtneidge, SA. (2003). The ADAMs family of metalloproteases: multidomain proteins with multiple functions. *Genes and Development*, Vo.17, No.1, pp. 7-30.
- Selby, PL., Young, MJ., & Boulton, AJ. (1994). Bisphosphonates: a new treatment for diabetic Charcot neuroarthropathy? *Diabetic Medicine*, Vol.11, No.1, pp. 28-31.
- Siau, K. & Laversuch, CJ. (2010). SAPHO syndrome in an adult with ulcerative colitis responsive to intravenous pamidronate: a case report and review of the literature. *Rheumatology International*, Vol.30, No.8, pp. 1085-1088.
- Sonozaki, H., Kawashima, M., Hongo, O., Yaoita, H., Ikeno, M., Matsuura, M., Okai, K., & Azuma, A. (1981). Incidence of arthro-osteitis in patients with pustulosis palmaris et plantaris. *Annals of the Rheumatic Disease*, Vol.40, No.6, pp. 554-557.
- Tagigawa, T., Tanaka, M., Nakanishi, K., Misawa, H., Sugimoto, Y., Takahata, T., Nakahara, H., Nakahara, S., & Ozaki, T. (2008). SAPHO syndrome associated spondylitis. *European Spine Journal*, Vol.17, No.10, pp. 1391-1397.
- Tang, P., Hung, M-C., & Klostergaard, J. (1996). Human pro-tumor necrosis factor is a homotrimer. *Biochemistry*, Vol.35, No.25, pp. 8216-8225.
- Thielen, AM., Barde, C., Marazza, G., & Saurat, JH. (2008). Long-term control with etanercept (Enbrel) of a severe acrodermatitis continua of Hallopeau refractory to infliximab (Remicade). *Dermatology*, Vol.217, No.2, pp. 137-139.
- Tutrone, WD., Kagen, MH., Barbagallo, J., & Weinberg, JM. (2001). Biologic therapy for psoriasis: a brief history, II. *Cutis*, Vol.68, No.6, pp. 367-372.
- Vandenabeele, P., Declercq, W., Beyaert, R., & Fiers, W. (1995). Two tumor necrosis factor receptors: structure and function. *Trends in Cell Biology*, Vol.5, No.10, pp. 392-399.
- Wagner, AD., Andresen, J., Jendro, MC., Hulsemann, JL., & Zeidler, H. (2002). Sustained response to tumor necrosis factor alpha-blocking agents in two patients with SAPHO syndrome. *Arthritis and Rheumatism*, Vol.46, No.7, pp. 1965-1968.
- Widmer, M., Weishaupt, D., Bruhlmann, P., Michel, BA., & Forster, A. (2003). Infliximab in the treatment of SAPHO syndrome: clinical experience and MRI response [abstract]. *Annals of the Rheumatic Diseases*, Vol.62, 250-1A.
- Wollina, U., Hansel, G., Koch, A., Schonlebe, J., Kostler, E., & Haroske, G. (2008). Tumor necrosis factor-alpha inhibitor-induced psoriasis or psoriasiform exanthemata: first 120 cases from the literature including a series of six new patients. *American Journal of Clinical Dermatology*, Vol.9, No.1, pp. 1-14.

---

Yerushalmi, J., Grunwald, MH., Hallel-Halevy, D., Avinoach, I., & Halevy, S. (2000). Chronic pustular eruption of the thumbs. Diagnosis: acrodermatitis continua of Hallopeau (ACH). *Archives of Dermatology*, Vol.136, No.7, pp. 925-930.





## **Rheumatoid Arthritis - Treatment**

Edited by Dr. Andrew Lemmey

ISBN 978-953-307-850-2

Hard cover, 366 pages

**Publisher** InTech

**Published online** 18, January, 2012

**Published in print edition** January, 2012

The purpose of this book is to provide up-to-date, interesting, and thought-provoking perspectives on various aspects of research into current and potential treatments for rheumatoid arthritis (RA). This book features 17 chapters, with contributions from numerous countries (e.g. UK, USA, Canada, Japan, Sweden, Turkey, Bosnia and Herzegovina, Slovakia), including chapters from internationally recognized leaders in rheumatology research. It is anticipated that Rheumatoid Arthritis - Treatment will provide both a useful reference and source of potential areas of investigation for research scientists working in the field of RA and other inflammatory arthropathies.

### **How to reference**

In order to correctly reference this scholarly work, feel free to copy and paste the following:

Koichiro Komiya, Nobuki Terada, Yoshikazu Mizoguchi and Harumoto Yamada (2012). Expression of Tumor Necrosis Factor-Alpha (TNF- $\alpha$  TNF- $\alpha$  Converting Enzyme and Matrix Metalloproteinase-3 in SAPHO Syndrome Synovium - A Rare Case Accompanied by Acrodermatitis Continua of Hallopeau: A Case Report and Review of Anti-TNF- $\alpha$  Therapy, Rheumatoid Arthritis - Treatment, Dr. Andrew Lemmey (Ed.), ISBN: 978-953-307-850-2, InTech, Available from: <http://www.intechopen.com/books/rheumatoid-arthritis-treatment/expression-of-tumor-necrosis-factor-alpha-tnf-tnf-converting-enzyme-and-matrix-metalloproteinase-3-i>

**INTECH**  
open science | open minds

### **InTech Europe**

University Campus STeP Ri  
Slavka Krautzeka 83/A  
51000 Rijeka, Croatia  
Phone: +385 (51) 770 447  
Fax: +385 (51) 686 166  
[www.intechopen.com](http://www.intechopen.com)

### **InTech China**

Unit 405, Office Block, Hotel Equatorial Shanghai  
No.65, Yan An Road (West), Shanghai, 200040, China  
中国上海市延安西路65号上海国际贵都大饭店办公楼405单元  
Phone: +86-21-62489820  
Fax: +86-21-62489821

© 2012 The Author(s). Licensee IntechOpen. This is an open access article distributed under the terms of the [Creative Commons Attribution 3.0 License](#), which permits unrestricted use, distribution, and reproduction in any medium, provided the original work is properly cited.