

EMG and Evoked Potentials in the Operating Room During Spinal Surgery

Induk Chung and Arthur A. Grigorian

Georgia Neurosurgical Institute and Mercer University School of Medicine, Macon, GA, USA

1. Introduction

EMG is an important clinical electrodiagnostic tool to assess function of neuromuscular tissue. It assesses spinal motor nerve roots and determines correct placement of hardware in surgical procedures, including cervical, thoracic, and lumbosacral spinal decompression, instrumentation, and fixation of spinal deformity. Evoked potentials provide information on vascular compromise of the spinal cord and nerves. Hence, concurrent recordings of EMG and evoked potentials can assess function integrity of the spinal cord and nerve more accurately. In this chapter, we will discuss application of EMG and evoked potentials in spinal surgery.

2. EMG recording techniques in the operating room (OR)

2.1 Recording electrodes

Surface, intramuscular, and subdermal needle electrodes are used to record EMG activity in the OR. Surface electrodes may not be used because of their inability to detect neurotonic discharges in spine surgery (Skinner et al., 2008). In addition, sweat causes electrodes to detach from the skin, preventing stable recording during lengthy surgery (Chung, unpublished data). Both intramuscular and subdermal needle electrodes are sufficient to detect neurotonic discharges (Skinner et al., 2008). Intramuscular needle electrodes may have an advantage to record EMG activity when the subcutaneous tissue is thick. Subdermal needle electrodes (13 mm length and 0.4 mm diameter) are generally used to record EMG in the OR, and we also routinely use subdermal needle electrodes in our practice.

2.2 Recording parameters

EMG is a simple and reliable technique which does not interfere with the surgical procedure. It is important to use proper recording parameters to achieve EMG recordings to obtain high signal-to-noise ratio. Recommended parameters of routine free-run EMG are low-frequency filter (LFF) of 20-30 Hz, high frequency filter (HFF) of 1-3 KHz, a gain of 500-5,000, a sensitivity of 50-500 μ V, and a sweep speed of 10-200 msec per division (Toleikis et al., 2000; Bose et al., 2002; Chung et al., 2009). LFF of greater than 50 Hz and HFF of less than 3 KHz should be avoided. Impedance of subdermal needle electrodes is recommended to be less than 5 K Ω , for impedance greater than 5 K Ω may mask real EMG activity. If impedance of all electrodes is too high, ground electrode should be replaced. If a particular electrode gives high impedance, the electrode should be replaced.

2.3 Muscle group selections and electrode placement

EMG in spinal surgery should cover all nerve roots at risk innervated by surgical levels. In routine EMG, depending on the surgical levels and number of channels available, bipolar electrodes (an active and a reference) are placed subdermally over the belly of each muscle group of interest. Electrodes should be placed ~1 cm apart with care and secured with tape to prevent dislodgement. EMG should be recorded from the bilateral muscle groups to increase specificity of nerve root activation. If fewer channels are available in the monitoring equipment, an active electrode is placed in one muscle and a reference electrode is placed in other muscle. Multiple nerve roots can be monitored with this montage, but it may be difficult to identify specific nerve root at risk. Table 1 indicates representative muscle groups to be recorded during spinal surgery (Leppanen, 2008).

Cervical	Muscle
C2, C3, C4	Trapezius, Sternomastoid (spinal portion of the spinal accessory nerve)
C5, C6	Deltoid, Biceps
C6	Triceps, Extensor Carpi Radialis
C7	Flexor Carpi Radialis
C8, T1	Abductor Pollicis Brevis, Abductor Digiti Minimi
Thoracic	
T5, T6	Upper Rectus Abdominis
T7, T8	Middle Rectus Abdominis
T9, T10, T11	Lower Rectus Abdominis
T12	Inferior Rectus Abdominis
Lumbar	
L2, L3, L4	Vastus Medialis, Adductor Magnus
L4, L5, S1	Vastus Lateralis, Tibialis Anterior
L5, S1	Proneous Longus, Gastrocnemius
Sacral	
S1, S2	Gastrocnemius
S2, S3, S4	External anal sphincter

Table 1. Representative muscle groups innervated by the cervical, thoracic, lumbar, and sacral nerve roots.

3. EMG recording

3.1 Neuromuscular junction (NMJ) recording

Blockade of NMJ significantly attenuates motor activity. Short acting muscle relaxants may be used to facilitate intubation, but long acting muscle relaxants should be avoided. If pre-existing nerve root injury should be identified, succinylcholine, an NMJ blocking agent, is recommended to use. However, succinylcholine should not be used for patients with malignant hyperthermia (Minahan et al., 2000).

There are electrical stimulation techniques to monitor status of NMJ, and these are single twitch, train-of-four (TOF) twitch ratio, tetanus, post-tetanic stimulation, and pulse or double burst technique (Leppanen, 2008). TOF twitch ratio is routinely used during surgery. Electrical stimulation (stimulation frequency of 1 Hz, duration of 300~500 msec, and intensity of 10~40 mA) is delivered to a peripheral nerve 4 times, and 4 resulting compound muscle action potentials (CMAPs) are recorded. TOF is monitored from the thenar eminence following stimulation of the median nerve, the abductor pollicis brevis following stimulation of the ulnar nerve at the wrist, the tibialis anterior following stimulation of the peroneal nerve at the knee, or the abductor hallucis following stimulation of the posterior tibial nerve. It is recommended that TOF should be monitored in a muscle of the extremity where EMG activity is being monitored (Minahan et al., 2000; Leppanen, 2008). Four of four twitch ratio is obtained if less than 75% of NMJ is blocked. Three of four twitch ratio is obtained with 75% blockade, 2 of 4 with 80% blockade, and 1 of 4 with 90% blockade. No twitch is obtained if 100% of NMJ is blocked (Leppanen, 2008). It is not desirable to use muscle relaxants during surgical procedures where direct stimulation of pedicle screws and nerve roots are required (Minahan et al., 2000).

3.2 Free-run EMG

The dorsal and ventral roots split into rootlets and minirootlets. The nerve root is susceptible to mechanical injury at the area that the split is present. The axons at this point are enclosed by a thin root sheath and cerebrospinal fluid meninges, but lack epineurium and perineurium. Hypovascularity at the junction of the proximal and middle 1/3 of the dorsal and ventral roots place nerve roots more susceptible to injury (Berthold et al., 1984). Intraoperative free-run EMG is utilized to detect motor nerve root compromise during decompression for spinal stenosis and spondylosis, correction of spinal deformity, radiculopathy secondary to disc herniation, and removal of tumor involving neural tissue in anterior and posterior surgical approaches (Holmes et al., 1993; Beatty et al., 1995; Maguire et al., 1995; Welch et al., 1997; Balzer et al., 1998; Toleikis et al., 2000; Bose et al., 2002; Chung et al., 2011).

To determine any pre-existing nerve root injury, baseline EMG recording is made before surgery starts. EMG recording is then made continuously throughout the surgical procedure. Pre-existing nerve root injury will be shown as spontaneous activity with low amplitude and periodic activity, whereas a normal free-run EMG response is absence of activity. If small amplitude, low frequency, or isolated discharge occurs at times which do not correlate with surgical manipulation of nerve roots, the EMG may not be pathologic. Mechanically elicited activity is characterized as polyphasic or a burst pattern consisting of single or nonrepetitive asynchronous potentials (Fig. 1A). Tonic or train activity consisting of multiple or repetitive synchronous discharges may last for several minutes (Fig. 1B). Burst potentials are associated with direct nerve trauma such as tugging, displacement, free irrigation, electrocautery, and application of soaked pledgets, but may not be associated with neural insult. Train activity is related to sustained traction and compression of nerve roots, and it is more associated with neural injury. When these patterns occur, the surgeon should be notified and corrective maneuver should occur. Audio and visual signal recognitions are available in most monitoring equipment. For communication with the operating surgeon, it is recommended to use audio signal through loud speakers for immediate feedback.

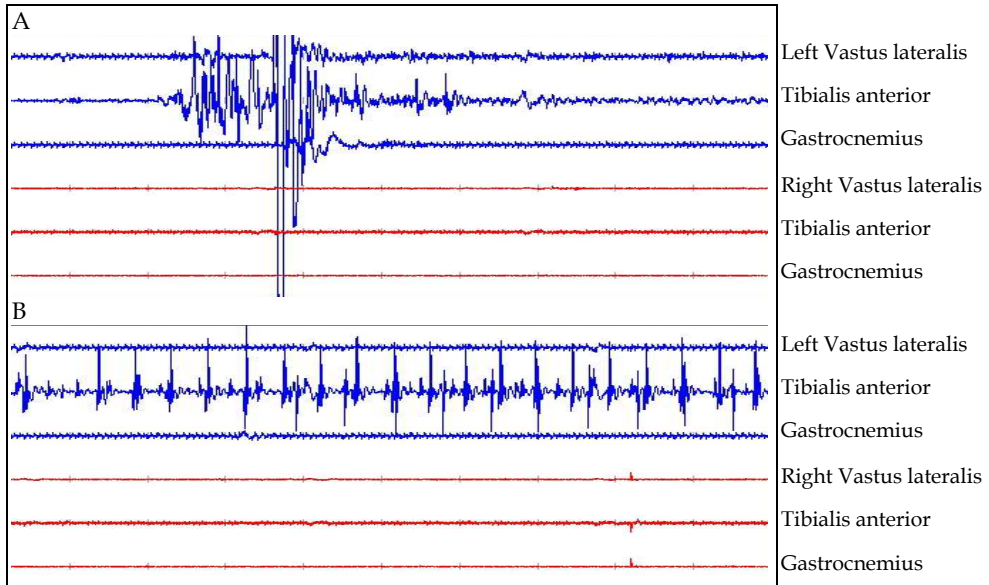


Fig. 1. Free-run EMG. EMG activity was recorded from the vastus lateralis, tibialis anterior, and gastrocnemius muscles during posterior spinal decompression. Bursts (A) and prolonged trains (B) of EMG activity are present in the left tibialis anterior muscle during decompression of nerve roots. Sensitivity 100 μ V, time base 2 sec.

3.3 Stimulated EMG

3.3.1 Monitoring segmental motor nerve root function

Segmental nerve root monitoring involves monitoring of function of the motor unit axon. This is achieved by recording free-run and electrically stimulated EMG activity from the muscle fibers of the motor units. When EMG activity is recorded with needle electrodes, the activity recorded may be the result of activation of only a few motor units innervating that muscle. Other motor units may be activated, but this activation will go undetected because of the location of the recording electrodes. A monopolar EMG needle records the summated activity of 9 to 17 muscle fibers (Leppanen, 2008).

Motor nerve root stimulation technique is applied when motor axons and non-neural tissue (tumor, scar) should be identified and differentiated between motor and sensory roots. When scar tissue is present from previous surgical procedures, electrical stimulation can identify where the motor axons lie within the scar tissue. The direct nerve root stimulation technique is also used to determine a degree of decompression of compressed nerve roots. A nerve root is stimulated using an insulated ball-tip probe, and a reference needle electrode placed around the site of incision. The current (duration of 0.1 msec, frequency of 1-3 Hz) is gradually increased until stimulus evoked EMG responses or CMAPs are recorded from the muscle innervated by the nerve root. Stimulation threshold should not be greater than several milliamperes for uninjured motor nerve roots when neural tissue is directly stimulated. If tumor or scar is stimulated and threshold is greater than this value, viable neural tissue lies within the tumor or scar or no neural tissue is involved (Holland et al., 1998; Leppanen, 2008).

3.3.2 Evaluation of pedicle screws

3.3.2.1 Pedicle screw stimulation technique

Electrophysiological pedicle screw stimulation technique has been developed to assess whether the screws have been placed within the pedicle bone. The principle of the pedicle screw stimulation technique is that the electrical resistance of bone is higher than that of surrounding fluid and soft tissue. If an implanted pedicle screw is completely surrounded by bone, the screw is electrically shielded and electrical stimulation of the screw will fail to activate the nerve (Fig. 2A). However, if there is a breach in the medial wall of the pedicle, a low resistance pathway is formed between the screw and the adjacent tissue (Fig. 2B and C). Application of electrical current to the screw will result in stimulation of the nerve root and a subsequent muscle contraction, which is recorded as a CMAP. Constant current or constant voltage stimulations can be used, and constant current stimulation appears less variable than constant voltage stimulation. For direct screw stimulation, monopolar, cathodal, constant current stimulation (duration of 0.2 msec, frequency of 1~3 Hz) is delivered using an insulated ball-tip probe, and the anodal reference needle electrode is placed in or around the site of incision. The current is gradually increased until CMAPs are elicited (Leppanen, 2008).

3.3.2.2 Evaluation of lumbosacral pedicle screws

Spinal instrumentation technique with pedicle screws and rods has long been used correct spinal instability and deformity, for it provides rigidity for the vertebral motion segment. However, incorrect placement of screws results in considerable radicular pain or postoperative neurological deficits (Matsuzaki et al., 1990; West et al., 1991). Although intraoperative fluoroscopy or postoperative radiography guide screw placement, these image studies may not detect functional integrity of pedicle screws. For instance, pedicle screw stimulation technique was 93% sensitive, whereas radiography was 63% sensitive to detect drill bits and screws that had breached the cortex (Maguire et al., 1995). Pedicle screw stimulation could detect incorrect screw placement in 8 out of 90 patients that was not identified on radiograph (Glassman et al., 1995). With 102 pedicle screws placed in 18 patients, 7 mA was delivered to test correct placement of screws. Electrophysiological evidence of a perforation was seen in 13% of the patients, but palpation or visualization could not detect this perforation (Calancie et al., 1994).

It appears that there is close correlation between the intensity of screw stimulation to elicit CMAPs and the risk for neurological injury associated with the screw placement. A stimulation threshold of 10~15 mA was associated with adequate screw position in 512 pedicle screws implanted to 90 patients, but exploration of the pedicle was recommended. A stimulation threshold of greater than 15 mA indicated adequate screw position. A threshold of 5~10 mA was used as an indicator of abnormal thresholds (Glassman et al., 1995). With 3,409 pedicle screws placed in 662 patients, a threshold of 7~10 mA was associated with pedicle breach or a slight medial exposure of the screw. With threshold of 5~7 mA, there was a 58% likelihood that the screw should be removed and redirected. A stimulation threshold of less than 5 mA was associated with a significant cortical perforation and direct contact with a nerve root (Toleikis et al., 2000). A stimulus threshold of less than 6 mA correlated with misplaced drill bits and screws that breached the cortex in 144 screws and 95 drill bits tested in 29 patients (Maguire et al., 1995).

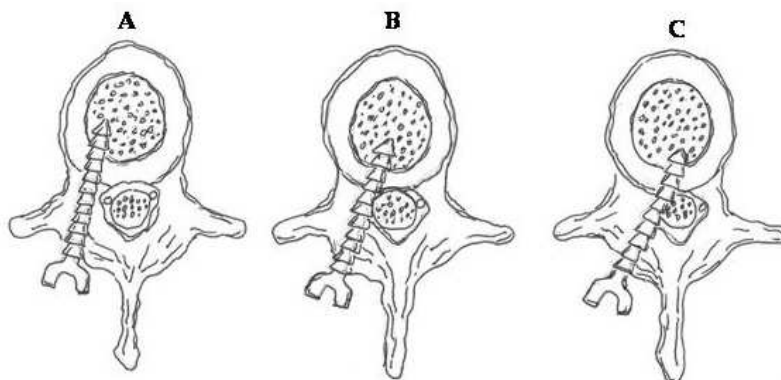


Fig. 2. Placement of pedicle screws. Screws are placed within the pedicle (A), close to the medial wall of the pedicle (B), or breach the cortex to make a direct contact with a nerve root (C).

Fig. 3 is a representative trace of CMAPs following stimulation of a pedicle screw. CMAPs were recorded mostly from the right vastus lateralis and tibialis anterior muscles with a stimulation threshold of 17 mA, indicating that the pedicle screw was placed securely within the pedicle bone.

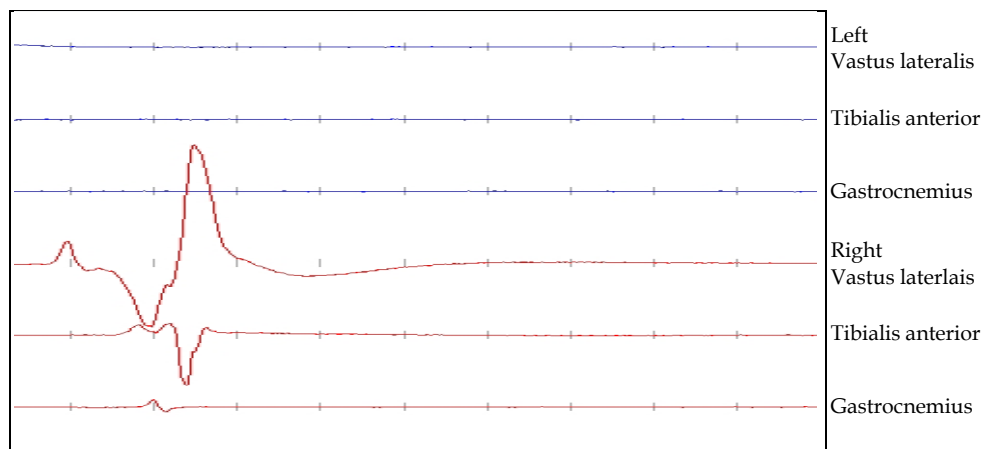


Fig. 3. CMAPs were elicited following electrical stimulation of the pedicle screw. EMG was recorded from the bilateral vastus lateralis, tibialis anterior, and gastrocnemius muscles. Current (duration of 0.2 msec, frequency of 1 Hz) was slowly increased to right L4 pedicle screw head via monopolar ball-tip probe. CMAPs were recorded mostly from the right vastus lateralis and tibialis anterior muscles at the current threshold of 17 mA. Sensitivity 200 μ V, timebase 0.1 sec.

3.3.2.3 Evaluation of cervical pedicle screws

C5 nerve root palsy is most commonly attributed to direct nerve root injury secondary to manipulation or traction of the nerve root and a segmental spinal cord injury secondary to

ischemia. Free-run EMG monitoring could detect potential injury to single nerve root (Fan et al., 2002; Bose et al., 2004; Hillbrand et al., 2004; Khan et al., 2006). Simulated EMG technique for posterior cervical screws is also a useful tool to guide screw placement. Djurasovic and colleagues (2005) tested the lateral mass and pedicle screws (122 lateral mass screws and 25 C7 pedicle screws) implanted in 26 patients. A stimulation threshold of 15 mA provided a 99% positive predictive value (89% sensitivity and 87% specificity) that the screw was within the lateral mass or pedicle. A stimulation threshold of 10~15 mA provided a 13% predictive value (66% sensitivity and 90% specificity) that the screw was within the lateral mass or pedicle. A stimulation threshold of less than 10 mA provided a 100% predictive value that the screw was malpositioned (70% sensitivity and 100% specificity).

3.3.2.4 Evaluation of thoracic pedicle screws

Placement of thoracic pedicle screws is a considerable technical challenge because of the smaller pedicle size (Cinotti et al., 1999). The risk of misplacement of screws in the thoracic spine ranged between 16% and 41% even with careful probing of the pedicle wall (Vaccaro et al., 1995; Xu et al., 1999). Simulation threshold values did not seem to reflect whether the screws were correctly positioned nor predict postoperative outcomes associated with the screw placement (Danesh-Clough et al., 2001). With 87 thoracic pedicle screws placed in 22 patients, 81 screws had a stimulus threshold >11 mA and 6 screws had thresholds \leq 11 mA, of which 3 showed cortical breakthrough. However, new postoperative neurologic complications did not result in any of the 22 patients (Shi et al., 2003). Two hundred and nine thoracic pedicle screws were placed in 29 patients. Five of 6 screws penetrated cortical bone in one patient, but no new postoperative neurologic deficit, visceral injuries, or pedicle screw instrumentation failure was developed in this patient (Kuntz et al., 2004). Six hundred and seventy-seven thoracic pedicle screws were placed in 92 patients, and 27 screws had a stimulation threshold of <6.0 mA and 6 of 27 screws had medial wall perforations. There were no new postoperative neurologic deficits or radicular chest wall complaints (Raynor et al., 2002). One hundred and sixteen thoracic pedicle screws were placed in 7 patients. There were medial wall defects in 19 screws, and average stimulus thresholds of these pedicle screws were 19.8 ± 5.3 mA. Eight of these 19 screws had thresholds 25~30 mA (Donohue et al., 2008).

4. Evoked potentials

Free-run and stimulated EMG can detect injury to neural tissue during surgical manipulations. However, the same technique fails to detect malpositioned thoracic pedicle screws and predict postoperative outcomes. Literature indicates that evoked potential monitoring assesses integrity of the spinal cord and nerve roots and improve clinical efficacy of EMG monitoring.

4.1 Somatosensory evoked potential (SSEPs) and recording technique

SSEP is an evoked response generated from nerve tracts and nuclei in the brain after peripheral nerve stimulation. Typically, the median or ulnar nerves at the wrist is stimulated to acquire SSEPs from the upper extremities and the posterior tibial nerve at the ankle or the peroneal nerve at the fibular head to acquire SSEPs from the lower extremities. The ascending sensory volley enters the spinal cord through dorsal nerve roots at several segmental levels and ascends to the sensory cortex. SSEPs are mediated by primarily through the dorsal column (Nuwer, 1999) or dorsal spinocerebellar tracts (York,

1985). SSEPs are used to assess the functional status of somatosensory pathways during surgical procedures which affect peripheral nerve or plexus (Prielipp et al., 1999; Chung et al., 2009), spinal cord (deformity correction, traumatic spinal fracture, tumor removal, Duffau, 2008), and brain (carotid endarterectomy, aneurysm repair, Friedman et al., 1991; Lam et al., 1991).

For upper extremity SSEP recordings, cortical (C3, C4 of the international 10-20 system, reference to Fz) and subcortical SSEPs (cervical spinous process, reference to Fz) are monitored upon alternate stimulation of the median or ulnar nerve at the wrist (stimulation intensity of ~20 mA, stimulation frequency of 3.1 Hz, stimulation duration of 0.5 msec) through surface electrodes (Fig. 4, left panel). For lower extremity SSEP recordings, cortical (Cz, reference to Fz) and subcortical SSEP (cervical spinous process, reference to Fz) are monitored upon alternate stimulation of the posterior tibial nerve at the ankle or peroneal nerve at the popliteal fossa (stimulation intensity of ~30 mA, stimulation frequency of

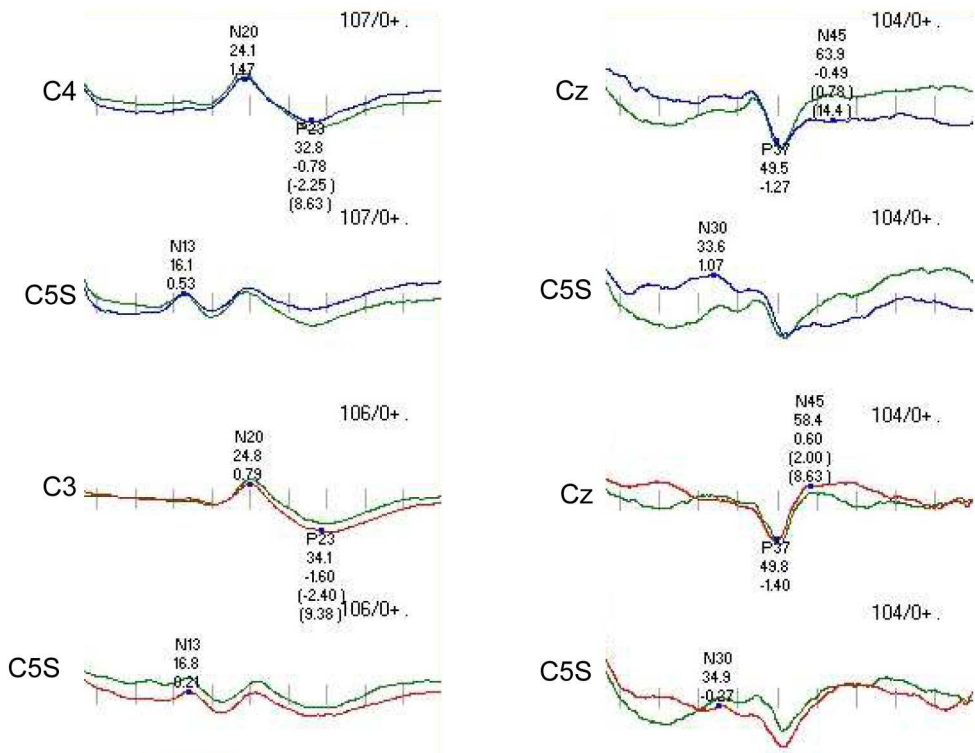


Fig. 4. Representative traces of SSEPs. Traces on the left column are upper-extremity SSEPs recorded from C3, C4 for cortical response and C5 spinous process for subcortical response following alternate stimulation of the ulnar nerve at the wrist (Timebase 50 msec). Lower-extremity SSEPs are shown in the right column. SSEPs were recorded from Cz and C5 spinous process following alternate stimulation of the posterior tibial nerve at the ankle (Timebase 100msec). The number of averaged samples, latency (msec), and amplitude (μ V) are indicated in the trace. Parentheses indicate interpeak latency and interpeak amplitude.

3.1 Hz, a stimulation duration of 0.5 msec) through surface electrodes (Fig. 4, right panel). A few hundreds of samples (sampling rate of 8 kHz) are required to average to increase a signal-to-noise ratio. Signals were amplified (gain of 5,000~20,000) and filtered (LFF of 30 Hz, HFF of 300 Hz). Impedance of electrodes should be ~5 K Ω . All of these electrical connections are grounded at patient's shoulder (Balzer et al., 1998; Chung et al., 2009).

4.2 Motor evoked potentials (MEPs) and recording technique

MEPs assess functional integrity of the anterolateral column of the spinal cord. MEPs provide information about long tract function, segmental interneurons, and anterior gray matter function. Epidural stimulation of the spinal cord and transcranial electrical (TES) or magnetic stimulation (TMS) of the motor cortex of the brain are the techniques used to obtain MEPs. TES is the most favorite technique utilized in the OR (McDonald, 2002, 2006). TES technique involves eliciting CMAPs after transcranial electrical stimulation of motor area at 1~2cm anterior to C3 and C4, referenced to C4 and C3 (Calancie et al., 1998; Chung et al., 2011) or C1 and C2, reference to C2 and C1 (Bose et al., 2004; Drake et al., 2010). For electrical stimulation, an internal or external stimulator can be used. Some monitoring equipment has its own internal stimulator. An external cortical stimulator is also used for this purpose. Digitimer™ D185 Multipulse stimulator (Digitimer Ltd., Welwyn Garden City, UK) is the only FDA approved stimulator for this clinical use. It has capabilities to control inter-stimulation interval (ISI) and stimulation intensity up to 1,000 volts. Multipulse stimulation technique (4~6 repetitive stimulations and ISI of 1~2 msec) is usually applied (Calancie et al., 1998; Bose et al., 2004; Drake et al., 2010; Chung et al., 2011). Stimulation thresholds range between a few hundreds and several hundreds of volts to elicit CMAPs depending on pathophysiological status of the spinal cord, depth of anesthesia, and bone thickness. Evoked CMAPs are recorded from the muscles of upper and lower extremities as indicated in Table 1.

Representative traces of MEPs are shown in Fig. 5. After TES, evoked CMAPs were recorded from the muscles of upper and lower extremities during placement of thoracic pedicle screws. Stable CMAPs were present in all the muscles during pedicle screw placement, and the patient did not develop new postoperative complication. We have been routinely testing MEPs during all cervical and thoracic spine surgery for the past over ten years, and the presence of stable MEPs is the most reliable indicator to assess cervical and thoracic spinal cord and nerve root function, instead of stimulation of mass and pedicle screws (Chung, unpublished data).

There are safety concerns to test MEPs for patients. High voltage transcranial electrical stimulation causes jaw movement, resulting in tongue laceration and mandibular fracture in 0.2% of the patients undergoing TES. Bite blocks should be placed to prevent these complications. MEPs should not be tested for patients with pre-existing history of seizure, intracranial injury, or presence of intracranial metal implants (McDonald, 2002, 2006).

4.3 Dermatome somatosensory evoked potentials (DSSEPs) and recording technique

Researchers have demonstrated that SSEPs increase specificity of EMG during lumbosacral (Holmes et al., 1993; Balzer et al., 1998; Chung, unpublished data) and anterior spine surgery (Chung et al., 2011). However, one can argue that SSEPs can not detect injury in a single nerve root because multiple nerve roots contribute to generate SSEPs. Dermatome somatosensory evoked potentials (DSSEPs) are suggested to use when assessing function of individual nerve roots. Stimulation is achieved with paired patch paste skin electrode placed 3-4 cm apart at dermatome sites such as L3 at anterior mid-thigh, L4 at medial

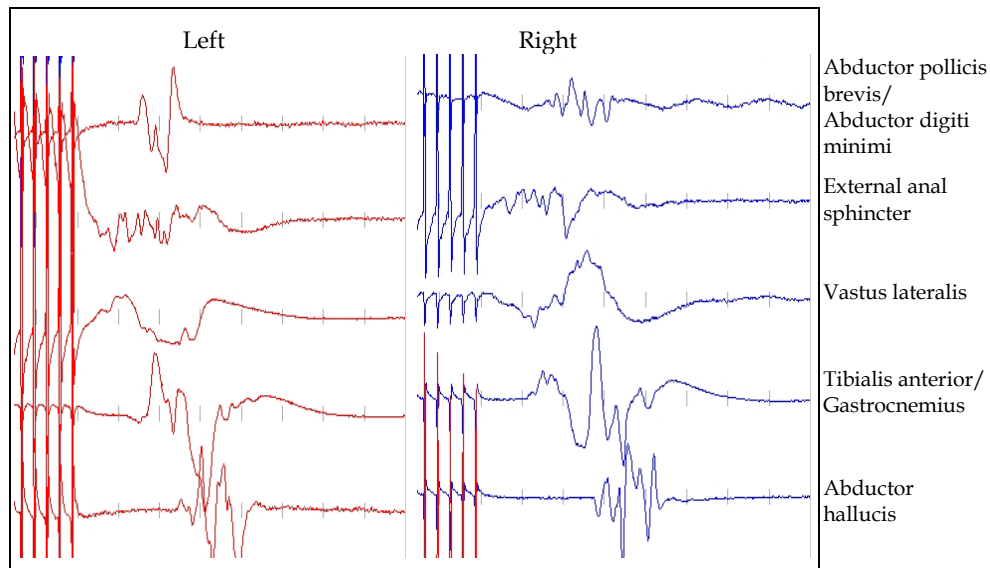


Fig. 5. MEPs were obtained after transcranial electrical stimulation (325V, ISI of 2 msec, 5 repetitive pulse trains). CMAPs were recorded from the abductor pollicis brevis/abductor digiti minimi, external anal sphincter, vastus lateralis, tibialis anterior/gastrocnemius, and abductor hallucis muscles bilaterally. Timebase 100 msec, 100msec, vertical scales 50-200 μ V.

midcalf, L5 at the dorsum of the foot, and S1 at the lateral aspect of the foot. Responses are recorded from cervical spinous process. Recording parameters are stimulation intensity of \sim 40 mA, duration of 0.3 msec, frequency of 5.1 Hz, LFF of 30 Hz, and HFF of 1 KHz. Each trial usually consists of 500 samples (Tsai et al., 1997). Clinical efficacy of intraoperative DSSEPs appears controversial. DSSEPs are sensitive to detect nerve root compression and mechanical manipulation, but insensitive to nerve root decompression. DSSEPs can detect a misplaced pedicle screw only when the screw directly contacts and mechanically injures a nerve root (Toleikis, 1993). DSSEPs are difficult to record and often require averaging \sim 500 samples to increase a signal-to-noise ratio, indicating that DSSEPs can not detect mechanical insult immediately. Even with averaging more samples, Tsai and colleagues (1997) could obtain baseline in only 57.6% of the patients. Hence, it is suggested that DSSEPs may be an adjunct to improve the sensitivity and specificity for detecting individual nerve injury when free-run and/or stimulated EMG is concurrently recorded.

4.4 Clinical efficacy of SSEPs and MEPs

Research for over the past three decades supports that SSEPs can detect and prevent spinal cord injury in cervical and thoracic, lumbosacral spinal surgeries. No quadriplegia resulted in a group of 100 patients with SSEP monitoring, compared with 8 quadriplegic patients from a group of unmonitored 218 patients (Epstein et al., 1993). Five patients with persistent SSEP changes were associated with postoperative motor deficit among 20 patients undergoing cervical and thoracic intramedullary cervical cord tumor removal (Kearse et al., 1993). SSEPs could detect ischemia in 44 out of 210 patients undergoing anterior cervical surgery. With simultaneous monitoring of SSEPs and EMG during posterior lumbar spinal

fusion, bursts and trains of EMG activity were associated with a concurrent decrease in amplitudes of SSEPs (Chung, unpublished data).

However, SSEPs may not be sensitive to predict postoperative clinical status in anterior cervical spine surgery. Significant SSEP amplitude changes were observed in 33 out of 191 patients, and 50% of the patients developed postoperative neurological deterioration in anterior and/or posterior cervical spinal surgery (May et al., 1996). In a study with 871 patients undergoing anterior cervical deformity surgery, 26 patients had significant SSEP changes, and only 5 patients had postoperative neurological deficit (Leung et al., 2005). In 508 patients undergoing anterior cervical discectomy and fusion (ACDF) with corpectomy, 8 patients had postoperative deficits with preserved SSEPs (Khan et al., 2006). Seven patients developed new postoperative neurological deficit with preserved SSEPs in 758 patients undergoing ACDF. SSEPs showed 35% sensitivity and 100% specificity to predict postoperative neurological functions (Chung et al., 2011). A retrospective study with 1,055 patients demonstrated that SSEPs had a sensitivity of 52% and a specificity of 100% to predict postoperative neurological status in cervical spine and spinal cord surgery (Kelleher et al., 2008). Quadriplegia and paraplegia still resulted in patients with preserved SSEPs in anterior cervical fusion (Ben-David et al., 1987; Bose et al., 2004; Smith et al., 2007; Taunt et al., 2005).

Simultaneous monitoring of SSEPs and MEPs has proven that MEP monitoring is more reliable than SSEP monitoring to predict postoperative motor deficits. Hillbrand and colleagues (2004) reported that 12 out of 427 patients undergoing cervical surgery had substantial or complete MEP loss. Ten patients restored MEPs with surgical intervention, and did not develop new postoperative deficit. Two patients with persistent MEP loss developed new postoperative motor weakness. This study claimed that MEP monitoring showed 100% sensitivity and 100% specificity to predict postoperative neurological status, whereas SSEP monitoring had 25% sensitivity and 100% specificity (Hillbrand et al., 2004). Six patients with persistent MEP loss had new postoperative deficits, whereas significant SSEP loss without MEP changes observed in 2 patients did not have postoperative deficit in 69 intracranial and spinal surgeries (Weinzierl et al., 2007). MEPs were also more sensitive than SSEPs for detection of ischemia. MEPs were lost due to fluctuating blood pressure, and an increase in the mean arterial pressure above 90 mmHg restored them in 1 patient, but SSEPs were preserved during the entire surgical course in this patient (Wee et al., 1989). MEPs were superior to SSEPs for detection and prediction of postoperative neurological status. Whereas MEPs showed 100% sensitivity and 77% specificity, SSEPs had 35% sensitivity and 100% specificity to predict postoperative neurological outcomes in 758 patients receiving ACDF (Chung et al., 2011).

5. Anesthesia

Although EMG is minimally sensitive to anesthesia, muscle relaxants should not be used during EMG recordings (Minahan et al., 2000). Evoked potentials, especially MEPs are highly sensitive to anesthesia, but monitoring was still feasible with propofol/fentanyl/nitrous oxide and partial neuromuscular blocking agents. In animal studies, inhalant anesthetics significantly increased onset latency and amplitudes of MEPs (Haghighi et al., 1999a, 1999b, 1996). Under general anesthesia with fentanyl/propofol/nitrous oxide, 20% and 40~60% nitrous oxide attenuated MEPs by 40~60% and 50~70%, respectively (vanDongen et al., 1999), and 66% of nitrous oxide completely abolished MEPs

(Zentner & Ebner, 1989). Narcotics were also shown to depress MEPs. Following administration of equipotent intravenous bolus of fentanyl, alfentanil, or sufentanil, amplitudes of MEPs were decreased to 34%, 43%, and 53% of baseline values, respectively (Thees et al., 1999). Total intravenous anesthetic or TIVA technique comprising remifentanyl with minimally depressive agents such as ketamine and etomidate improved MEP recordings (Ghaly et al., 1999, 2001). Compared with sufentanil or fentanyl, remifentanyl infusion could always produce stable MEPs with faster emergence (Chung, unpublished data).

6. Conclusion

Free-run and stimulated EMG assesses spinal motor nerve roots and determines correct placement of hardware in cervical, thoracic, and lumbosacral spinal surgeries. Because SSEPs and MEPs provide additional information on functional integrity of the spinal cord and nerves, SSEPs and MEPs together with free-run and stimulated EMG should provide more accurate assessment of spinal cord and nerve function during spinal surgery.

7. References


- Balzer, JR.; Rose, RD.; Welch, WC.; Sclabassi, RJ. (1998) Simultaneous somatosensory evoked potential and electromyographic recordings during lumbosacral decompression and instrumentation. *Neurosurgery* 42:1318-1324
- Beatty, RM.; McGuire, P.; Moroney, JM.; Holladay, FP. (1995) Continuous intraoperative electromyographic recording during spinal surgery. *J Neurosurg* 82:401-405
- Ben-David, B.; Haller, G.; Taylor, P. (1987) Anterior spinal fusion complicated by paraplegia. A case report of a false-negative somatosensory evoked potential. *Spine* 12:536-539
- Berthold, CH.; Carlstedt, T.; Coeneliuson, O. 1984. Anatomy of the root at the central-peripheral transitional region, In: *Peripheral neuropathy*, Dyck PJ, Thomas PK, Lambert EH, Bunge R (Eds.), pp 156-170, W. B. Saunders, Philadelphia.
- Bose, B.; Sestokas, AK.; Schwartz, DM. (2004) Neurophysiological monitoring of spinal cord function during instrumented anterior cervical fusion. *Spine J* 4:202-207
- Bose, B.; Wierzbowski, LR.; Sestokas, AK. (2002) Neurophysiologic monitoring of spinal nerve root function during instrumented posterior lumbar spine surgery. *Spine* 27:1444-1450
- Calancie, B.; Harris, W.; Broton, JG.; Alexeeva, N.; Green, BA. (1998) "Threshold-level" multipulse transcranial electrical stimulation of motor cortex for intraoperative monitoring of spinal motor tracts: description of method and comparison to somatosensory evoked potential monitoring. *J Neurosurg* 88:457-470
- Calancie, B.; Madsen, P.; Lebowhl, N. Stimulus-evoked EMG (1994) monitoring during transpedicular lumbosacral spine instrumentation: Initial clinical results. *Spine (Phila Pa 1976)* 19:2780-2786
- Chung, I.; Glow, JA.; Dimopoulos, V.; Walid, S.; Smisson, HF.; Johnston, KW., et al (2009) Upper-limb somatosensory evoked potential monitoring in lumbosacral spine surgery: a prognostic marker for position- ulnar nerve injury. *Spine J* 9:287-295
- Chung, I.; Glow, JA.; Grigorian, AA.; Smisson, HF.; Johnston, KW.; Robinson, JS. (2011) Clinical efficacy of intraoperative somatosensory and motor evoked potential

- monitoring during anterior cervical discectomy and fusion (ACDF): A review of 758 cases. Submitted to *Global Spine J*
- Cinotti, G.; Gumina, S.; Ripani, M.; Postacchini, F. (1999) Pedicle instrumentation in the thoracic spine. A morphometric and cadaveric study for placement of screws. *Spine (Phila Pa 1976)* 15; 24:114-119
- Danesh-Clough, T.; Taylor, P.; Hodgson, B.; Walton, M. (2001) The use of evoked EMG in detecting misplaced thoracolumbar pedicle screws. *Spine (Phila Pa 1976)* 26:1313-1316
- Djurasovic, M.; Dimar, JR.; Glassman, SD.; Edmonds, HL.; Carreon, LY. (2005) A prospective analysis of Intraoperative electromyographic monitoring of posterior cervical screw fixation. *J Spinal Disord Tech* 18:515-518
- Donohue, M.; Murtagh-Schaffer, C.; Basta, J.; Moquin, RR.; Bashir, A.; Calancie, B. (2008) Pulse-train stimulation for detecting medical malpositioning of thoracic pedicle screws. *Spine* 33:E378-385
- Drake, J.; Zeller, R.; Kulkarni, AV.; Strantzas, S.; Holmes, L. (2010) Intraoperative neurophysiological monitoring during complex spinal deformity cases in pediatric patients: methodology, utility, prognostication, and outcome. *Childs Nerv Syst* 26:523-544
- Duffau, H. (2008) Intraoperative neurophysiology during surgery for cerebral tumors, In: *Intraoperative monitoring of neural function*, Nuwer, MR. (Ed.), pp 491-507, Elsevier, ISBN 978-0-444-51824-8, ISBN 1567-4231, Amsterdam, The Netherlands
- Epstein, NE.; Danto, J.; Nardi, D. (1993) Evaluation of intraoperative somatosensory-evoked potential monitoring during 100 cervical operations. *Spine* 18:737-747
- Fan, D. & Schwartz, DM. (2002) Intraoperative neurophysiologic detection of iatrogenic C5 nerve root injury during laminectomy for cervical compression myelopathy. *Spine* 22:2499-2502
- Friedman, WA.; Chadwick, GM.; Verhoeven, FJ.; Mahla, M.; Day, AL. (1991) Monitoring of somatosensory evoked potentials during surgery for middle cerebral artery aneurysms. *Neurosurgery* 29:83-88
- Ghaly, RF.; Lee, JJ.; Ham, JH.; Stone, JL.; George, S.; Raccforte, P. (1999) Etomidate dose-response on somatosensory and transcranial magnetic induced spinal motor evoked potentials in primates. *Neurol Res* 21:714-720
- Ghaly, RF.; Ham, JH.; Lee, JJ. (2001) High-dose ketamine hydrochloride maintains somatosensory and magnetic motor evoked potentials in primates. *Neurol Res* 23:881-886
- Glassman, DS.; Dimar, JR.; Puno, RM.; Johnson, JR.; Shields, CB.; Linden, RD. (1995) A prospective analysis of Intraoperative electromyographic monitoring of pedicle screw placement with computed tomographic scan configuration. *Spine* 20:1375-1379
- Haghighi, SS.; Green, KD.; Oro, JJ.; Drake, RK.; Kracke, GR. (1990) Depressive effect of isoflurane anesthesia on motor evoked potentials. *Neurosurgery* 26:993-997
- Haghighi, SS.; Madsen, R.; Green, KD.; Oro, JJ.; Kracke, GR. (1990) Suppression of motor evoked potentials by inhalation anesthetics. *J Neurosurg Anesthesiol* 2:73-78
- Haghighi, SS.; Sirintrapun, SJ.; Keller, BP.; Oro, JJ.; Madsen, R. (1996) Effect of desflurane anesthesia on transcortical motor evoked potentials. *J Neurosurg Anesthesiol* 8:47-51

- Hillbrand, AS.; Schwartz DM.; Sethurman, V.; Vaccaro, AR.; Albert, TJ. (2004) Comparison of transcranial electric motor and somatosensory evoked potential monitoring during cervical spine surgery. *J Bone Joint Surg* 86:1248-1253
- Holland, NR.; Lukaczyk, TA.; Kostuik, JP. (1998) A comparison of the stimulus thresholds required to evoke myogenic response from normal and chronically compressed nerve roots: implications for intraoperative testing during transpedicular instrumentation. *Spine* 23:224-227
- Holmes, JT. & Chappuis, JL. (1993) Monitoring of lumbosacral nerve roots during spinal instrumentation. *Spine* 18:2059-2062
- Kearse, LA, Jr.; Lopez-Bresnahan, M.; McPeck, K.; Tambe, V. (1993) Loss of somatosensory evoked potentials during intramedullary spinal cord surgery predicts postoperative neurologic deficits in motor function. *J Clin Anesth* 5:392-398
- Kelleher, MO.; Tan, G.; Sarjeant, R.; Fehlings, MG. (2008) Predictive value of intraoperative neurophysiological monitoring during cervical spine surgery: a prospective analysis of 1055 consecutive patients. *J Neurosurg Spine* 8:215-221
- Khan, MH.; Smith, PN.; Balzer, JR.; Crammond, D.; Welch, WC.; Gerszten, P. et al. (2006) Intraoperative somatosensory evoked potential monitoring during cervical spine corpectomy surgery: experience with 508 cases. *Spine* 15:E105-113
- Kuntz, C.; Maher, C.; Levine, N.; Kurokawa, R. (2004) Prospective evaluation of thoracic pedicle screw placement using fluoroscopic imaging. *J Spinal Disord Tech* 17:206-214
- Lam, AM.; Lam, AM.; Manninen, PH.; Ferguson, GG.; Nantau, W. (1991) Monitoring electrophysiologic function during carotid endarterectomy: a comparison of somatosensory evoked potentials and conventional electroencephalogram. *Anesthesiology* 75:15-21
- Leppanen, RE. (2008) Intraoperative monitoring of segmental nerve root function with free-run and electrically triggered electromyography and spinal cord function with reflexes and F-responses. In: *Position Statement by American Society of Neurophysiological Monitoring*, pp 1-46
- Leung, YL.; Grevitt, M.; Henderson, L.; Smith, J. (2005) Cord monitoring changes and segmental vessel ligation in the "at risk" cord during anterior spinal deformity surgery. *Spine* 30:1870-1874
- Maguire, J.; Wallace, S.; Madiga, R.; Leppanen, R.; Draper, V. (1995) Evaluation of intrapedicular screw position using intraoperative evoked electromyography. *Spine* 20:1068-1074
- May, DM.; Jones, SJ.; Crockard, A. (1996) Somatosensory evoked potential in cervical surgery: identification of pre- and intraoperative risk factors associated with neurological deterioration. *J Neurosurg* 85:566-573
- Matsuzaki, H.; Toiyama, Y.; Matsumoto, F.; Hoshino, M.; Kiuchi, T.; Toriyama, S. (1990) Problems and solutions of pedicle screw plate fixation of lumbar spine. *Spine* 15:1159-1165
- McDonald, DB. (2002) Safety of intraoperative transcranial electrical stimulation motor evoked potential monitoring. *J Clin Neurophysiol* 19:416-429
- McDonald, DB. (2006) Intraoperative motor evoked potential monitoring: overview and update. *J Clin Neurophysiol* 20:347-377

- Minahan, RE.; Riley, III LH.; Lukacyk, T.; Cohen, DB.; Kostuik, JP. (2000) The effect of neuromuscular blockade on pedicle screw stimulation thresholds. *Spine* 25:2526-2530
- Naito, M.; Owen, JH.; Bridwell, KH.; Sugioka, Y. (1992) Effects of distraction on physiologic integrity of the spinal cord, spinal cord blood flow, and clinical status. *Spine* 17:1154-1158
- Nuwer, MR. (1999) Spinal cord monitoring. *Muscle Nerve* 2:620-1630
- Prielipp, RC.; Morell, RC.; Walker, FO.; Santos, CC.; Bennett, J.; Butterworth, J. (1999) Ulnar nerve pressure: influence of arm position and relationship to somatosensory evoked potentials. *Anesthesiology* 91:345-354
- Raynor, BL.; Lenke, LG.; Kim, Y.; Hanson, DS.; Wilson-Holden, TJ.; Bridwell, KH., et al. (2002) Can triggered electromyograph thresholds predict safe thoracic pedicle screw placement? *Spine (Phila Pa 1976)* 27:2030-2035
- Sebastián, C.; Raya, JP.; Ortega, M.; Olalla, E.; Lemos, V.; Romero, R. (1997) Intraoperative control by somatosensory evoked potentials in the treatment of cervical myeloradiculopathy. *Eur Spine J* 6:316-323
- Shi, YB.; Binette, M.; Martin, WH.; Pearson, JM.; Hart, RA. (2003) Electrical stimulation of intraoperative evaluation of thoracic pedicle screw placement. *Spine* 28:595-601
- Skinner, SA.; Transfeldt, EE.; Savik, K. (2008) Surface electrodes are not sufficient to detect neurotonic discharges: observations in a porcine model and clinical review of deltoid electromyographic monitoring using multiple electrodes. *J Clin Monit Comput* 22:131-139
- Smith, PN.; Balzer, JR.; Khan, MH.; Davis, RA.; Crammond, D.; Welch, WC., et al. (2007) Intraoperative somatosensory evoked potential monitoring during anterior cervical discectomy and fusion in nonmyelopathic patients - a review of 1,039 cases. *Spine J* 7:83-87
- Taunt, CJ.; Sidhu, KS.; Andrew, SA. (2005) Somatosensory evoked potential monitoring during anterior cervical discectomy and fusion. *Spine* 30:1970-1972
- Tew, JM Jr. & Mayfield, FH. (1976) Complications of surgery of the anterior cervical spine. *Clin Neurosurg* 23:424-434
- Thees, C.; Scheufler, KM.; Nadstawek, J.; Pechstein, U.; Hanisch, M.; Juntke, R., et al. (1999) Influence of fentanyl, alfentanil, and sufentanil on motor evoked potentials. *J Neurosurg Anesthesiol* 11:112-118
- Thompson, JP. & Rowbotham, DJ. (1996) Remifentanil-an opioid for the 21st century. *Br J Anaesth* 76:341-343
- Toleikis, JR.; Carlvin, AO.; Shapiro, DE.; Schafer, MF. (1993) The use of dermatomal evoked responses during surgical procedures that use intrapedicular fixation of the lumbosacral spine. *Spine* 18:2401-2407
- Toleikis, JR.; Skelly, JP.; Carlvin, AO.; Toleikis, AC.; Bernard, TN.; Burkus, KJ., et al. (2000) The usefulness of electrical stimulation for assessing pedicle screw placements. *J Spinal Disorders* 13:283-289
- Tsai, RYC.; Yang, R.; Nuwer MR.; Kanim, LEA.; Delamarter, RB.; Dawson EG. (1997) Intraoperative dermatomal evoked potential monitoring fails to predict outcome from lumbar decompression surgery. *Spine* 17:1970-1975

- Ueta, T.; Owen, JH.; Sugioka, Y. (1992) Effects of compression on physiologic integrity of the spinal cord on circulation, and clinical status in four different directions of compression: posterior, anterior, circumferential, and lateral. *Spine* 17:S217-S226
- Vaccaro, AR.; Rizzolo, SJ.; Balderston, RA.; Allardyce, TJ.; Garfin, SR.; Dolinskas, C., et al. (1995) Placement of pedicle screws in the thoracic spine. Part II: An anatomical and radiographic assessment. *J Bone Joint Surg Am* 77:1200-1206
- van Dongen, EP.; ter Beek, HT.; Schepens, MA.; Morshuis, WJ.; de Boer, A.; Aarts, LP., et al. (1999) Effect of nitrous oxide on myogenic motor potentials evoked by a six pulse train of transcranial electrical stimuli: a possible monitor for aortic surgery. *Br J Anesth* 82:323-328
- Wee, AS. & Ashley, RA. (1989) Cortical somatosensory evoked potentials during acute hemorrhagic hypotension. *Eur Neurol* 29:284-286
- Weinzierl, MR.; Reinacher, P.; Gilsbach, JM.; Rohde, V. (2007) Combined motor and somatosensory evoked potentials for intraoperative monitoring: intra- and postoperative data in a series of 69 operations. *Neurosurg Rev* 30:109-116
- Welch, WC.; Rose, RD.; Balzer, JR.; Jacobs, GB. (1997) Evaluation with evoked and spontaneous electromyography during lumbar instrumentation: a prospective study. *J Neurosurg* 87:397-402
- West, JL III.; Ogilvie, JW.; Bradford, DS. (1991) Complications of the variable screw plate pedicle screw fixation. *Spine* 16:576-579
- Xu, R.; Ebraheim, NA.; Shepherd, ME.; Yeasting, RA. (1999) Thoracic pedicle screw placement guided by computed tomographic measurements. *J Spinal Disord* 12:222-226
- York, DH. (1985) Somatosensory evoked potentials in man: differentiation of spinal pathways responsible for conduction from forelimbs vs. hindlimb. *Prog Neurobiol* 25:1-25
- Zentner, J. & Ebner, A. (1989) Nitrous oxide suppresses the electromyographic response evoked by electrical stimulation of the motor cortex. *Neurosurgery* 24:60-62



EMG Methods for Evaluating Muscle and Nerve Function

Edited by Mr. Mark Schwartz

ISBN 978-953-307-793-2

Hard cover, 532 pages

Publisher InTech

Published online 11, January, 2012

Published in print edition January, 2012

This first of two volumes on EMG (Electromyography) covers a wide range of subjects, from Principles and Methods, Signal Processing, Diagnostics, Evoked Potentials, to EMG in combination with other technologies and New Frontiers in Research and Technology. The authors vary in their approach to their subjects, from reviews of the field, to experimental studies with exciting new findings. The authors review the literature related to the use of surface electromyography (SEMG) parameters for measuring muscle function and fatigue to the limitations of different analysis and processing techniques. The final section on new frontiers in research and technology describes new applications where electromyography is employed as a means for humans to control electromechanical systems, water surface electromyography, scanning electromyography, EMG measures in orthodontic appliances, and in the ophthalmological field. These original approaches to the use of EMG measurement provide a bridge to the second volume on clinical applications of EMG.

How to reference

In order to correctly reference this scholarly work, feel free to copy and paste the following:

Induk Chung and Arthur A. Grigorian (2012). EMG and Evoked Potentials in the Operating Room During Spinal Surgery, EMG Methods for Evaluating Muscle and Nerve Function, Mr. Mark Schwartz (Ed.), ISBN: 978-953-307-793-2, InTech, Available from: <http://www.intechopen.com/books/emg-methods-for-evaluating-muscle-and-nerve-function/emg-and-evoked-potentials-in-the-operating-room-during-spinal-surgery>

INTECH

open science | open minds

InTech Europe

University Campus STeP Ri
Slavka Krautzeka 83/A
51000 Rijeka, Croatia
Phone: +385 (51) 770 447
Fax: +385 (51) 686 166
www.intechopen.com

InTech China

Unit 405, Office Block, Hotel Equatorial Shanghai
No.65, Yan An Road (West), Shanghai, 200040, China
中国上海市延安西路65号上海国际贵都大饭店办公楼405单元
Phone: +86-21-62489820
Fax: +86-21-62489821

© 2012 The Author(s). Licensee IntechOpen. This is an open access article distributed under the terms of the [Creative Commons Attribution 3.0 License](#), which permits unrestricted use, distribution, and reproduction in any medium, provided the original work is properly cited.