

# Spatial Anatomical Variation of Segmental Hepatic Vasculature and Bile Duct Assessed by Integrated 3D CT Images for Right Lateral Sector Graft Liver Transplantation

Koji Okuda and Atsushi Yoshida

*Department of Surgery, Kurume University School of Medicine, Kurume  
Japan*

## 1. Introduction

In adult living donor liver transplantation (LDLT), a right lateral sector graft is newly introduced to overcome graft-size disparity of the right lobe graft or left lobe graft<sup>1-3</sup>. However, it is obvious that the procurement of right lateral sector has technical difficulties. High number of either unrecognized or extemporaneously handled biliary and vascular variants poses high risk both to the donor and the recipient<sup>4</sup>. Thus, understanding of the anatomical variations of sectoral and segmental bile duct, hepatic artery and portal vein of the donor and recipient are a prerequisite.

Diagnostic imaging with multidetector computed tomography (MD-CT) allows accurate and noninvasive preoperative evaluation of the hepatobiliary anatomy<sup>5,6</sup>. And, three-dimensional (3D) representation of anatomic structures is thought to improve understanding of complex spatial interactions<sup>7,8</sup>.

We investigate anatomical variations of the segmental portal vein, artery and bile duct for the right lateral sector, including not only variant of each structures but also 3D relationship, based on the integrated 3D images, for guideline of safe right lateral sector graft transplantation.

## 2. Patients

Seventy-three patients underwent contrast enhanced dynamic MD-CT and MD-CT cholangiography. Among these, 66 patients who met the following inclusion criteria were selected: age over 20 years, no tumor in the liver/hepatic hilum, no tumor located in peripheral sites in the liver which is more than 30mm in diameter, no previous hepatic or biliary surgery. 3D images of the portal vein, hepatic artery and bile duct were reconstructed in all. 14 patients were excluded from the study because of the poor quality of 3D images. Consequently, 52 patients were enrolled in this study. There were 40 men and 12 women with age ranged from 42- 78 (mean 65) years. There were 24 patients with hepatocellular carcinoma, 4 with cholangiocellular carcinoma, 7 with extrahepatic bile duct cancer, 3 pancreatic cancer, 1 papilla vater carcinoma, 5 with gall bladder cancer, 1 adenomyomatosis, 5 stone, , 1 chronic hepatitis, 1 liver hemangioma.

### 3. Imaging technique

All dynamic CT studies were performed with MD-CT (Asteon multi ver. 1.5 Toshiba, Tokyo or LightSpeed Plus, GE Yokogawa, Tokyo). Patients received 100 ml of iopamidol with an iodine concentration of 370 mg/ml (Iopamiron 370; Nihon Schering, Osaka, Japan) as intravenous contrast for vascular imaging. The contrast medium was injected at a rate of 4 ml/sec. with an automatic power injector. Three or four phase scanning was performed with a single breath-hold helical technique at 3 mm collimation, 3.5 helical pitch and 0.75 second gantry rotation speed. Data from the artery dominant phase and the portal vein dominant phase were used to reconstruct the 3 D images.

For biliary imaging, in 38 cases, CT scan was acquired 30 minutes after intravenous infusion of 100ml of biliary contrast agent (Meglumine isotraxate, Biliscopin; Shering, Berlin, germany) at a rate of 0.1ml/sec (DIC-CT). In all 38 cases, DIC-CT and dynamic CT scan were performed on different days because of the possible accelerated adverse effects of the vascular and the biliary cotarst media. Each scan was performed with the same focus of view. In 14 cases having percutaneous transhepatic biliary drainage (PTBD) tube, biliary enhanced CT was performed after administering 3- 15 ml of 6 % biliary contrast agent (Biliscopin) through the PTBD tube (PTBD-CT). The adequate volume of contrast agent was determined by the previously performed PTBD cholangiography. MDCT cholangiography was performed by intravenous injection of a biliary contrast agent in 38 cases, and by injection from percutaneous biliary drainage tube in 14.

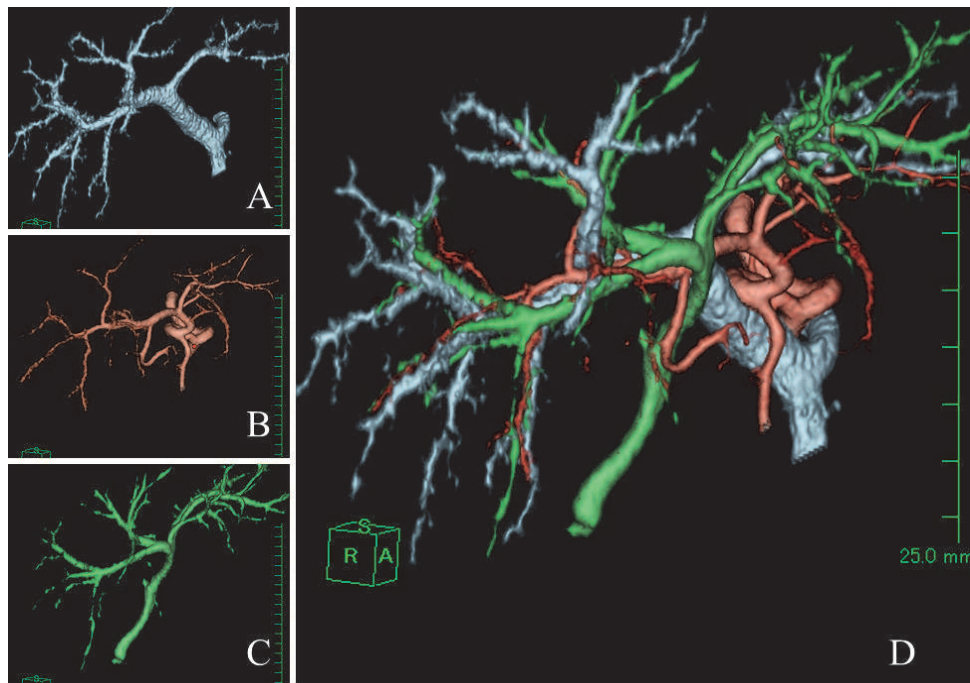
### 4. Image interpretation

Analysis of the image data was performed based on source images and 3D postprocessing images on commercially available workstations (Intage rvse, KGT, Tokyo and VirtualPlace, AZE, Osaka). 3D reconstruction of the hepatic vasculature was made using a volume rendering algorithm. The volume rendered images were obtained in projections selected to depict the course of hepatic vasculature best. The resulting 3D images of the hepatic artery, portal vein and the bile duct rendered for each step of the artery dominant phase, portal vein dominant phase and the DIC-CT/PTBD-CT respectively were carefully reviewed and compared with the axial source images to ensure that no important structure was inadvertently deleted from the 3D images. 3D images of the hepatic artery, portal vein and the bile duct (Fig 1-A, Fig 1-B, Fig 1-C) which were adjusted to position each other focusing at the hepatic hilum on 2D axillary, sagital and coronary imaging sequences, were further integrated into a single image (Fig 1-D).

### 5. Diagnostic examination

In 52 of the 66 evaluated patients, the MD-CT studies were considered as diagnostic. The study was not diagnostic in the remaining 14 patients because of the poor timing of the contrast and image acquisition. 5 patients had poor arterial phase images, 13 had poor biliary images and 4 had both. Portal imaging was satisfactory in all patients.

The advantages of MD-CT are mainly faster capability, improved temporal resolution, improved spatial resolution and increased effectiveness of the intravascular contrast agent. Reliability of the 3D MD-CT on the anatomical evaluation has been reported in several articles<sup>5,6,9,10</sup>. However, a problem is that 3D reconstruction imaging does not protect



A:portogram reconstructed from portal dominant phase data, B:angiogram reconstructed from artery dominant phase data, C:cholangiogram reconstructed from DIC-CT data, D:integrated image of the 3Dportogram, angiogram and cholangiogram

Fig. 1. Integrated 3D image of vasculature and biliary system

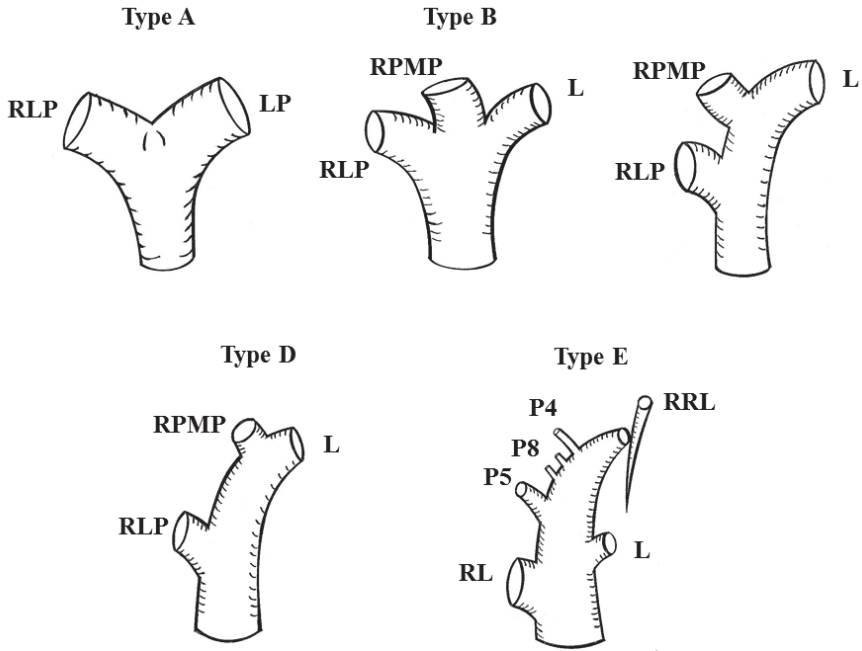
against potential misinterpretation during post-processing. To increase the reliability of vascular imaging, authors, who are an expert in the anatomy of hepatic structures, checked and pick up the missing branches on sequential 2D images after automatic reconstruction of 3D vascular images.

## 6. Anatomical variant of portal veins

Ramification pattern of the right portal vein was defined into 5 types according to Nakamura's classification<sup>11)</sup> (Figure 2). It is reported that ramification of the portal vein has a few anomalies compared with the bile duct and the artery<sup>6)</sup>. Nevertheless, as to the right lateral portal vein (RLP), the single portal vein cases were only 30 cases, 57.7% and others had dual RLPs with (10 cases, 19.2%) or without (12, 23.1%) a common ostia at origin (Fig. 3).

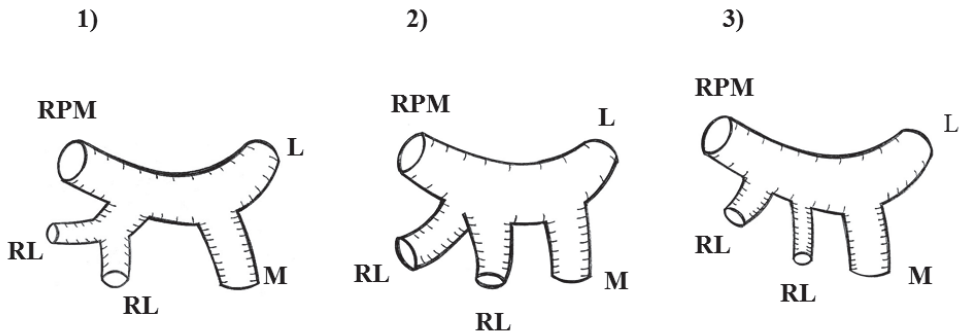
## 7. Anatomical variant of biliary system

The pattern of branching of the biliary system in the right lobe is classified into 7, based on tributary from the right lateral sector (Figure 4). 49 cases have single right lateral duct (RLD), and 3 have dual RLDs. Pattern I is normal anatomy in which RLD and the right



Type A: 42cases, 80.8%, type B: 3 cases, 5.8%, Type C: 6 cases, 11.5%, Type D: 1 cases, 1.9%, Type E: 0 cases  
 \*RPMP: right paramedian portal vein, RLP: right lateral portal vein, RP: right portal vein, LP: left portal vein, P5:portal vein for the segment 5, P8: portal vein for the segment 8, P4: portal vein for the segment 4, RRL: right sided round ligament

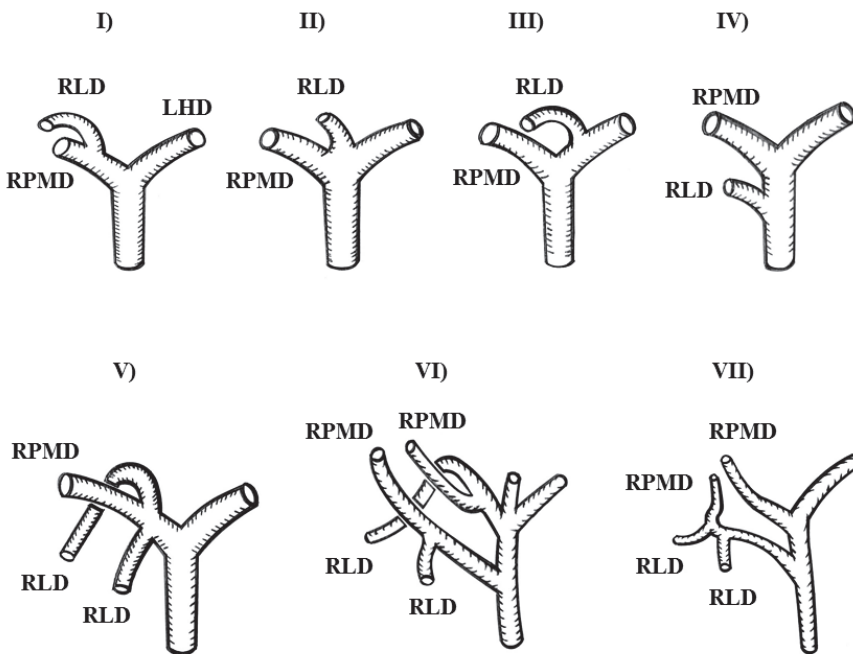
Fig. 2. Ramification pattern of portal vein for the right lobe



1) RLP originated from the right portal vein as a single trunk: 30 cases, 57.7%, 2) dual RLPs originate from the right portal vein by a common ostia: 10 cases, 19.2%, 3) dual RLPs originate from the right portal vein independently through separate ostia: 12 cases, 23.1%  
 \*RPMP: right paramedian portal vein, RLP: right lateral portal vein, MP: main portal vein, LP: left portal vein

Fig. 3. Anatomical variants of right lateral portal vein

paramedian duct (RPMD) join to form the right hepatic duct which further joins the left hepatic duct to form the common hepatic duct. Pattern II is trifurcation of RL, RPMD and the left hepatic duct. In Pattern III, RLD joins the left hepatic duct. Pattern IV is the joining of RLD to the common hepatic duct. Pattern V, VI and VII are dual RLDs. Pattern V is dual RLD insertion into RPMD independently. In Pattern VI, there are two right hepatic ducts each formed by the joining of separate RPMD and RLD. Pattern VII is multiple RLDs and RPMDs. Incidence of each type in our series were Pattern I: 33 patients, 63.5%, Pattern II: 8, 15.4%, Pattern III: 5, 9.6%, Pattern IV: 3, 5.8%, Pattern V: 1, 1.9%, Pattern VI: 1, 1.9% and Pattern VII: 1, 1.9%.



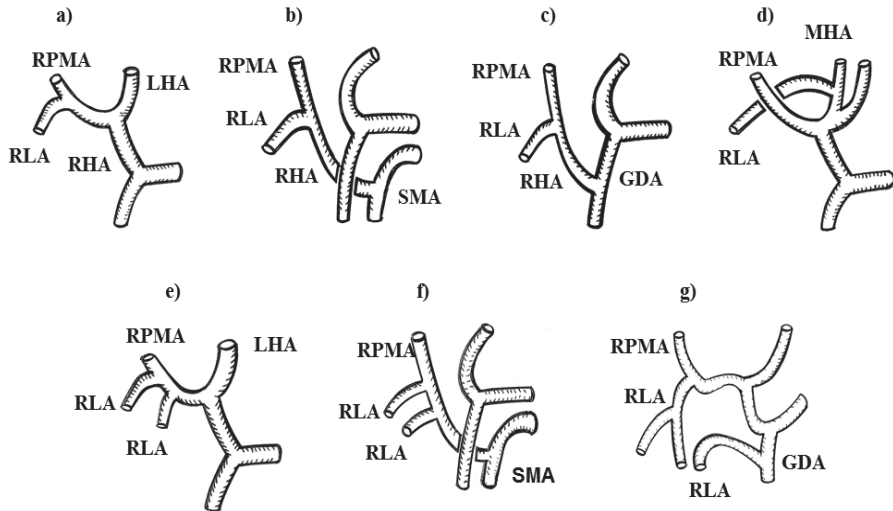
I) normal anatomy: 33 cases, 63.5%, II) trifurcation: 8 cases, 15.4%, III) RLD joins the left hepatic duct: 5 cases, 9.6%, IV) RLD joins the common hepatic duct: 3 cases, 5.8%, V) dual RLDs insert to RPMD independently: 1 case, 1.9%, VI) two right hepatic ducts each is formed by the joining of separate RPMD and RLD: 1 case, 1.9%, VII) multiple RLDs and RPMDs: 1 case, 1.9%  
 \*RPMD: right paramedian duct, RLD: right lateral duct, LHD: left hepatic duct

Fig. 4. Anatomical variants of right lateral bile duct

### 8. Anatomical variant of arteries

The branching pattern of the right lateral artery (RLA) is demonstrated in Figure 5. The single RLA was observed in 38 patients (73.1%) and dual RLAs in 14 (26.9%). A single RLA arising from the right hepatic artery was seen in 33 patients. RLA was originating from a replaced right hepatic artery from the superior mesenteric artery in 3 patients and from the gastroduodenal artery in one patient. RLA arising from the middle hepatic artery as an

accessory artery was seen in another patient (Fig.5-d). Among patients with dual RLAs, in 9, arteries were originating independently from the right hepatic artery (Fig.5-e). In 4 patients, dual arteries were taking off independently from the replaced right hepatic artery from the superior mesenteric artery (Fig.5-f). Combined supply from a right lateral branch of the right hepatic artery and a branch of the gastroduodenal artery was also seen in another patient (Fig.5-g).



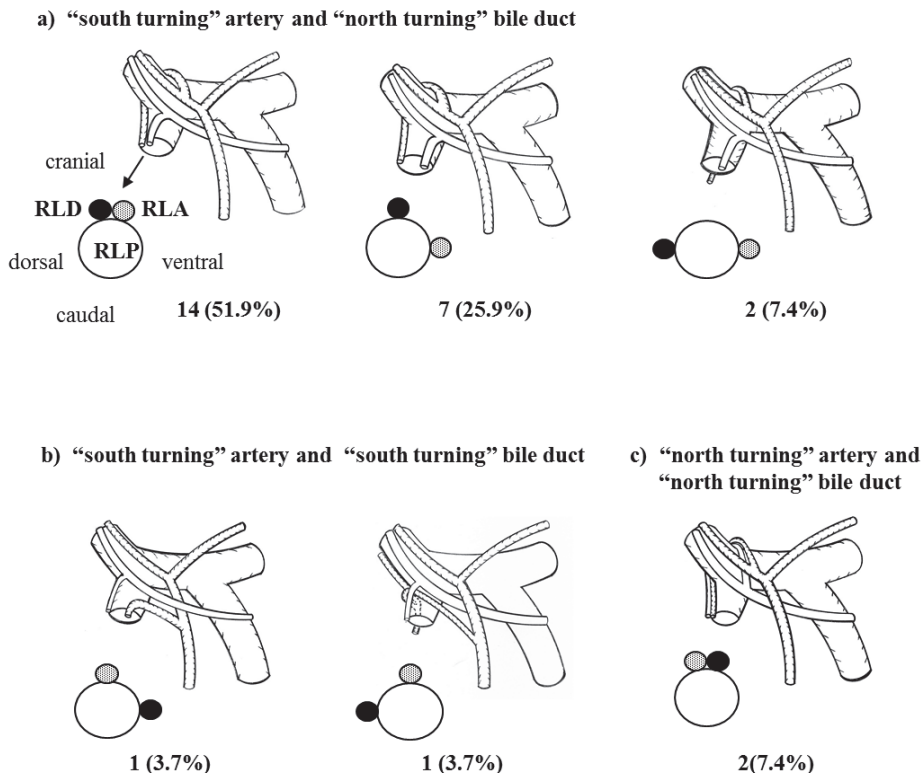
a) normal anatomy:33 cases, 63.5%, b) RLA from replaced RHA from SMA: 3 cases, 5.8%, c) RLA from replaced RHA from GDA: 1 cases, 1.9%, d) RLA from MHA: 1 case, 1.9%, e) dual RLAs from RHA: 9 cases, 17.3%, f) dual RLAs from replaced SMA: 4 cases, 7.7%, g) dual RLAs from RHA and from GDA: 1 case, 1.9%

\*RLA: right lateral artery, RPMA: right paramedian artery, RHA: right hepatic artery, SMA: superior or mesenteric artery, MHA: middle hepatic artery, GDA: gastroduodenal artery

Fig. 5. Anatomical variants of right lateral artery

### 9. 3D relationship of the artery, bile duct and portal vein for right lateral sector

3 D relationship of the artery and bile duct to the right lateral sector with reference to the portal vein branches were studied. We defined the right lateral bile duct/artery which run dorsally and superiorly to RMPV as a 'north-turning' duct/artery and the bile duct/artery which run ventrally and inferiorly to the right portal vein and RMPV was defined as a 'south-turning' duct/artery<sup>12)</sup> (Fig 6). In 49 patients with single RLD, 44 had the 'north-turning' duct and 5 had the 'south-turning' duct. In 3 patients with multiple RLDs, one had both of 'south-turning' variety and the other two showed a combination of 'north-turning' and 'south-turning' ducts. Among 38 cases of single RLA, 8 had 'north-turning' artery and 30 had 'south-turning' artery. Out of 14 dual RLAs cases, in 6, a combination of 'north-turning' and 'south-turning' arteries were observed. In the remaining 8 cases, all demonstrated 'south turning' arteries.



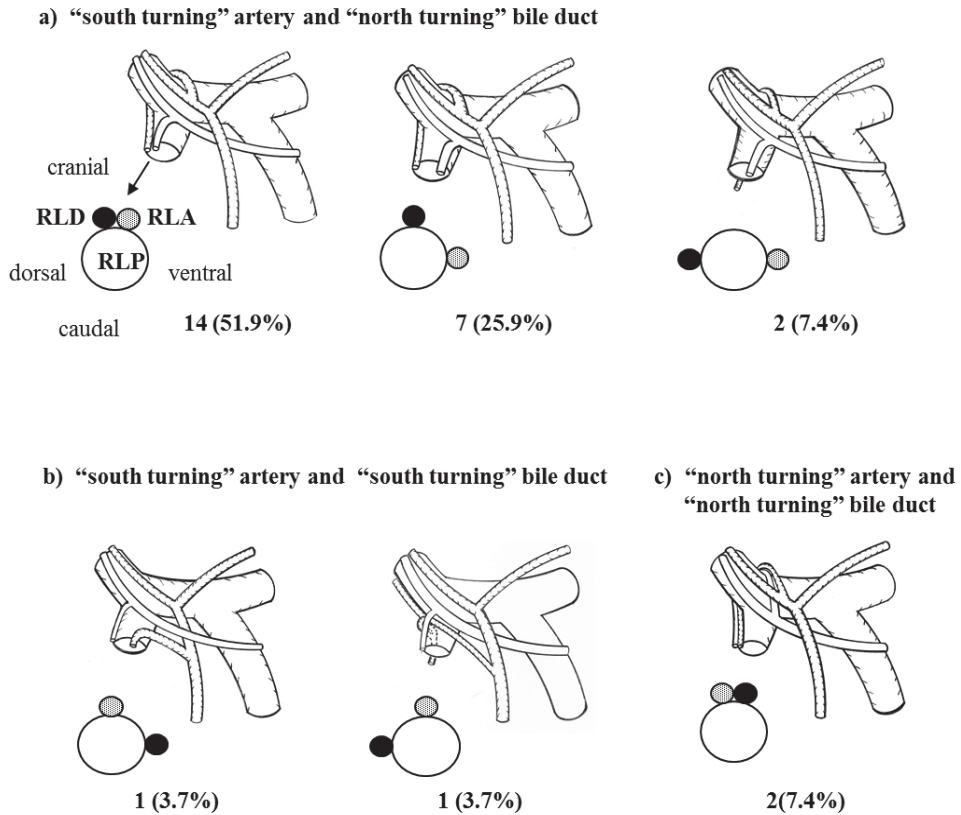
\*RPD: right paramedian duct, RLD: right lateral duct, RPMP: right paramedian portal vein, RLP: right lateral portal vein

Fig. 6. Running pattern of the right lateral duct/artery

In 27 patients of the single artery-bile duct-portal vein for the right lateral sector, the combination of "south-turning" artery and "north turning" bile duct was the most frequent pattern (22 cases) (Fig. 7). In all of them, the artery was running cranial or ventral to the bile duct and the portal vein at the sectional plane of origin of RLPV. The bile duct was sited cranial to the portal vein in 20 cases and dorsal in 2. The "south-turning" artery - "south-turning" bile duct combination was observed in 3 cases and the "north-turning" artery - "south-turning" bile duct combination in two. Among these patients with these two patterns, 4 had the artery sited dorsally or cranially to the bile duct.

## 10. Application for right lateral sector transplantation

Although reconstruction of multiple portal veins and bile ducts has been challenging in LDLT, it is recently reported that multiple branches can be reconstructed safely using technical modifications in the right lobe or left lobe graft transplantation. Kyoto team reported that dual portal branches can be reconstructed safely with or without interposed venous graft<sup>(11)</sup>. They also described that all the biliary variants were successfully reconstructed with an acceptable complication rate, those are 9.3% bile leaks and 8.5% of



- a) “south-turning” artery and “north-turning” bile duct; both artery and bile duct run through the cranial side of RLP: 13 cases, 48.1%, artery runs through the ventral side with bile duct running through cranial side: 7 cases, 25.9%, and with bile duct running through the dorsal side: 2 cases, 7.4%
- b) “south-turning” artery runs through the cranial side with “south-turning” bile duct running through the ventral side: 2 cases (7.4%), and with bile duct running through the dorsal side: 1 case, 3.7%
- c) “north-turning” artery runs through the cranial with “north-turning” bile duct running through the cranial side: 2 cases, 7.4%
- \*RLA: right lateral artery, RLD: right lateral duct, RLP: right lateral portal vein

Fig. 7. 3D relationship of artery, bile duct and portal vein for right lateral sector, Scheme of the sectional plane of the orifice of RLP are presented at the right inferior corner of each figure.

stenosis, in grafts with multiple biliary orifices. However, the branches of portal vein and bile duct for right lateral sector are smaller and its variants are more complicated. In dual duct cases especially when one duct runs dorsally to RLPV and other ventrally, reconstruction of dual ducts partitioned by the portal vein should be unacceptably difficult. We observed 2 cases with this anomaly. Even in the cases of single RLD, 3 cases had RLD run dorsal side of the RLPV. This anomaly is also difficult to be reconstructed because duct reconstruction should be interfered by the ventrally located RLPV.



This study revealed 14 cases, 26.9%, had dual RLA. The branch or branches for the right lateral sector are thinner and shorter than those of the right lobe graft or left lobe graft. Reconstruction of all dual arteries may be difficult in right lateral sector transplant. How to reconstruct multiple graft arteries remains controversial. Some institution recommended that livers with aberrant arteries should not to be used because these graft require multiple arterial reconstructions with high incidence of postoperative arterial thrombosis<sup>13-15</sup>. On the other hand, Ikegami et al.<sup>16</sup> recommended to reconstruct only thickest artery if intraoperative doppler shows pulsatile arterial flow and arterial signal in the corresponding segment of the non-anastomosed arteries. Even though, preoperative precise identification of the arterial variants by imaging and the accurate assessment of the feasibility are essential components of a successful right lateral graft LDLT.

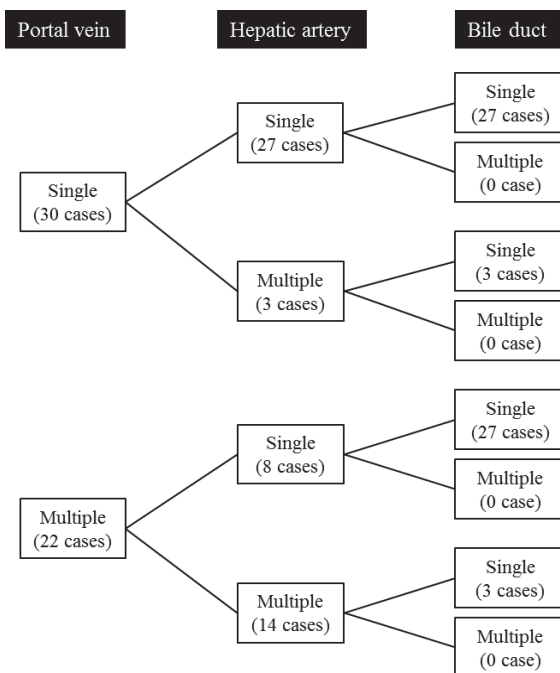


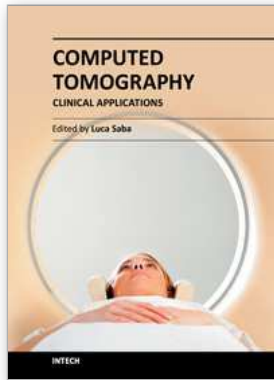
Fig. 8. Combination of anatomical variants of right lateral portal vein, bile duct and artery

### 11. Conclusion

In 9-18% of potential donors, the right lateral sector has volumetric advantage compared to the left lobe<sup>2,3</sup>. However, anomalies of the hepatic vasculature cause further limitation for the feasibility of transplantation. In our study, cases having single portal vein, single artery and single bile duct are only 27 among 52 (Fig.8). Therefore, to increase safe right lateral sector LDLT and to overcome donor shortage, accurate preoperative anatomical evaluation and excellent surgical technique coping with the particular anatomical variants are required. Anatomical understanding based on the 2D images is not sufficient<sup>8</sup>. The understanding of the 3D vascular and biliary anatomy will contribute to a better definition of the anatomical contraindications for transplantation, and to achieve successful right lateral sector LDLT.

## 12. References

- [1] Sugawara Y, Makuuchi M, Takayama T, Mizuta K, Kawarasaki H, Imamura H, Hashizume K. Liver transplantation using a right lateral sector graft from a living donor to her granddaughter. *Hepatogastroenterology*. 2001;48:261-263
- [2] Hwang S, Lee SG, Lee YJ, et al. Donor selection for procurement of right posterior segment graft in living donor liver transplantation. *Liver Transpl*. 2004;10:1150-1155.
- [3] Leelaudomlipi S, Sugawara Y, Kaneko J, Matsui Y, Ohkubo T, Makuuchi M. Volumetric analysis of liver Segment in 155 living donors. *Liver transpl*. 2002;8:612-614
- [4] Imamura H, Makuuchi M, Sakamoto Y, Sugawara Y, Kawasaki S, Takayama T. Anatomical keys and pitfalls in living donor liver transplantation. *J Hepatobiliary Pancreat Surg* 2000;7:380-394
- [5] Sakai H, Okuda K, Yasunaga M, Kinoshita H, Aoyagi S. Reliability of hepatic artery configuration in 3D CT angiography compared with conventional angiography--special reference to living-related liver transplant donors. *Transpl Int*. 2005;18:499-505
- [6] Schroeder T, Radtke A, Kuehl H, Debatin JF, Malago M, Ruehm SG. Evaluation of living liver donors with an all-inclusive 3D multi-detector row CT protocol. *Radiology*. 2006;238:900-910
- [7] Uchida M, Ishibashi M, Sakoda J, Azuma S, Nagata S, Hayabuchi N. CT image fusion for 3D depiction of anatomic abnormalities of the hepatic hilum. *AJR* 2007;189:W184-W191
- [8] Beermann J, Tetzlaff R, Bruckner T, et al. Three-dimensional visualization improves understanding of surgical liver anatomy. *Medical Education* 2010; 44: 936-940
- [9] Chen YF, Lee TY, Chen CL, Huang TL, Chen YS, Lui CC. Three-dimensional helical computed tomographic cholangiography: application to living related hepatic transplantation. *Clin Transplant*. 1997 11:209-213
- [10] Yeh BM, Breiman RS, Taouli B, Qayyum A, Roberts JP, Coakley FV. Biliary tract depiction in living potential liver donors: comparison of conventional MR, mangafodipir trisodium-enhanced excretory MR, and multi-detector row CT cholangiography--initial experience. *Radiology*. 2004;230:645-651.
- [11] Nakamura T, Tanaka K, Kiuchi T, et al. Anatomical variations and surgical strategies in right lobe living donor liver transplantation: lessons from 120 cases. *Transplantation* 2002;73:1896-1903.
- [12] Kawarada Y, Das BC, Taoka H. Anatomy of the hepatic hilar area: the plate system. *J Hepatobiliary Pancreat Surg* 2000;7:580-586
- [13] Soin AS, Friend PJ, Rasmussen A, et al. Donor arterial variations in liver transplantation: management and outcome of 527 consecutive grafts. *Br J Surg* 1996;83:637-41
- [14] Kosteric JK, Piper JB, Leef JA, et al. Angiographic selection criteria for living related liver transplantation. *Am J Roenterol* 1996;166:1103-1108
- [15] Broelsch CE, Whittington PF, Emond JC, et al. Liver transplantation in children from living related donors. Surgical techniques and results. *Ann Surg* 1991 214:428-437
- [16] Ikegami T, Hashikura Y, Nakazawa Y, et al. Risk factors contributing to hepatic artery thrombosis following living-donor liver transplantation. *J Hepatobiliary Pancreat Surg* 2006;13:105-109



## **Computed Tomography - Clinical Applications**

Edited by Dr. Luca Saba

ISBN 978-953-307-378-1

Hard cover, 342 pages

**Publisher** InTech

**Published online** 05, January, 2012

**Published in print edition** January, 2012

Computed Tomography (CT), and in particular multi-detector-row computed tomography (MDCT), is a powerful non-invasive imaging tool with a number of advantages over the others non-invasive imaging techniques. CT has evolved into an indispensable imaging method in clinical routine. It was the first method to non-invasively acquire images of the inside of the human body that were not biased by superimposition of distinct anatomical structures. The first generation of CT scanners developed in the 1970s and numerous innovations have improved the utility and application field of the CT, such as the introduction of helical systems that allowed the development of the "volumetric CT" concept. In this book we want to explore the applications of CT from medical imaging to other fields like physics, archeology and computer aided diagnosis. Recently interesting technical, anthropomorphic, forensic and archeological as well as paleontological applications of computed tomography have been developed. These applications further strengthen the method as a generic diagnostic tool for non-destructive material testing and three-dimensional visualization beyond its medical use.

### **How to reference**

In order to correctly reference this scholarly work, feel free to copy and paste the following:

Koji Okuda and Atsushi Yoshida (2012). Spatial Anatomical Variation of Segmental Hepatic Vasculature and Bile Duct Assessed by Integrated 3D CT Images for Right Lateral Sector Graft Liver Transplantation, *Computed Tomography - Clinical Applications*, Dr. Luca Saba (Ed.), ISBN: 978-953-307-378-1, InTech, Available from: <http://www.intechopen.com/books/computed-tomography-clinical-applications/spatial-anatomical-variation-of-segmental-hepatic-vasculature-and-bile-duct-assessed-by-integrated-3>

**INTECH**  
open science | open minds

### **InTech Europe**

University Campus STeP Ri  
Slavka Krautzeka 83/A  
51000 Rijeka, Croatia  
Phone: +385 (51) 770 447  
Fax: +385 (51) 686 166  
[www.intechopen.com](http://www.intechopen.com)

### **InTech China**

Unit 405, Office Block, Hotel Equatorial Shanghai  
No.65, Yan An Road (West), Shanghai, 200040, China  
中国上海市延安西路65号上海国际贵都大饭店办公楼405单元  
Phone: +86-21-62489820  
Fax: +86-21-62489821

© 2012 The Author(s). Licensee IntechOpen. This is an open access article distributed under the terms of the [Creative Commons Attribution 3.0 License](#), which permits unrestricted use, distribution, and reproduction in any medium, provided the original work is properly cited.