

# Colonic Pseudo-Obstruction

Abdulmalik Altaf and Nisar Haider Zaidi

*Department of Surgery, King Abdul Aziz University Hospital, K.A.A. University, Jeddah,  
Saudi Arabia*

## 1. Introduction

Colonic pseudo-obstruction is a condition of distention of colon with signs and symptoms of colonic obstruction in the absence of an actual mechanical cause of obstruction. It is a poorly understood disease that is characterized by functional large bowel obstruction.

Intestinal pseudo-obstruction was described in 1938 by the German surgeon W. Weiss who reported mega-duodenum in 6 persons in 3 generations of a German family and described it as an inherited subset of intestinal pseudo-obstruction<sup>[2]</sup>. A similar condition of pseudo-obstruction of intestine was described by Ingelfinger in 1943. Colonic pseudo-obstruction, however, was first described by Sir William Heneage Ogilvie in 1948 and named after him as "Ogilvie's Syndrome". His description was based on the findings of two patients who had non-mechanical obstruction due to retroperitoneal involvement of the celiac plexus by malignancy<sup>[1]</sup>. J. Dunlop in 1949 described a similar condition in men aged 56, 58, and 66 years where large bowel colic was the predominant symptom accompanied by constipation, abdominal distension, and progressive loss of weight, but with no evidence of mechanical obstruction to the intestinal flow<sup>[3]</sup>. In 1958, Dudley et al used the term pseudo-obstruction to describe the clinical appearance of a mechanical obstruction with no evidence of organic disease during laparotomy<sup>[4]</sup>.

Ogilvie's syndrome commonly occurs in patients who are critically ill, have electrolyte imbalance, or on anticholinergic medications. If left untreated, life threatening complications like bowel ischemia or perforation may occur in up to 15% of cases with a mortality of 50%<sup>[5]</sup>.

## 2. Epidemiology

The prevalence of colonic pseudo-obstruction is difficult to know but the disorder nearly always occurs in hospitalized patients. It is commonly found in patients undergoing major surgeries, patients with advanced malignancies, and in spinal trauma patients. It is usually associated with surgical procedures which require prolonged bed rest. As such, the development of colonic pseudo-obstruction is common in orthopedic procedures like total hip replacement (up to 1.5% of cases) and after total knee replacement (2.3%)<sup>[6]</sup>. The incidence is higher in hospitalized mentally-disabled patients reaching up to 18.5%<sup>[7]</sup>.

Middle aged or elderly patients are commonly diagnosed with the disorder. The mean age of affected patients is 56.5 years for males and 59.9 years for females with a male to female ratio of 2:1.

### 3. Physiology of colonic motility

The rate and extent of colonic motility is the accumulative result of neural signals that cause intrinsic rhythmic contraction of the smooth muscles of the colon. Hyperpolarizing action potentials coincide with peaks of fluctuating potential difference across the cell membrane and result in contraction of the muscle[8]. The contraction of colonic smooth muscles is integrated by the myenteric plexus whose neurons have vesicles that release neurotransmitters, such as acetylcholine, noradrenaline, 5HT, peptides and purines[9]. The neurotransmitters produce spike potentials and rhythmic contractions that have a fixed maximum rate<sup>[10]</sup>. Nicotinic cholinergic fibers mediate rapid inhibitory reflex while purinergic fibers mediate excitatory descending pathway<sup>[11]</sup>. The resulting interdigestive myoelectric complexes [IMC] are propagated by the myenteric plexus at an interval of 15 to 195 min., clearing the intestinal lumen<sup>[12]</sup>. The IMC are stimulated by the vagus nerve and motilin<sup>[13]</sup>. It is suppressed by ingestion of meals<sup>[14]</sup>.

### 4. Pathophysiology

Colonic pseudo-obstruction is a form of colonic dysmotility which is a final common pathway of various physiological, electrolyte and biochemical disturbances. There are primary and secondary pseudo-obstruction. Primary pseudo-obstruction is the familial visceral myopathy or hollow visceral myopathy syndrome, a diffuse motility disorder involving autonomous innervations of the intestinal wall. Secondary pseudo-obstruction is associated with other conditions such as the use of some medications, severe metabolic illness, diabetes, uremia, hyperparathyroidism etc.

Colonic pseudo-obstruction can be neurogenic or myogenic in origin. It is the imbalance between sympathetic and parasympathetic innervations supplying colonic smooth muscle that causes pseudo-obstruction. This enteric nervous system forms a neural network residing in the submucosa and intermuscular layer of the colonic wall. Sympathetic nerve supply arises from lower thoracic and lumbar ganglia. The preganglionic nerves from these ganglia form a synapse in preaortic ganglia. The sympathetic nerves arising from these ganglia supply the colon. The parasympathetic nerve supply comes from the vagus nerve to the right half of colon up to splenic flexure, while the rest of colon is supplied by sacral nerve roots. Functional obstruction of the colon can be caused by increased sympathetic tone or decreased parasympathetic tone <sup>[15]</sup>. This autonomic dysfunction occurs mainly in postganglionic pathways and controls of the enteric nervous system. Two types of neurotransmitters are secreted by this system which are acetylcholine which increases intestinal secretions and motility and noradrenaline which decreases both intestinal secretions and motility.

Some derangements also occur at the cellular and molecular levels and are thought to be part of the pathophysiology of this disorder. The interstitial cells of Cajal (ICC) are the pacemaker cells of the gastrointestinal tract and are essential for normal motility of the bowel. ICC form extensive network of electrically coupled cells some of which act as a pacemaker while others are involved in the relaxation of smooth muscles. ICC are either deranged or absent in patients of pseudo-obstruction.

Nitric oxide may have a role in the development of pseudo-obstruction. It is involved in muscle relaxation and produced by the oxidation of L-arginine, mediated by increased nitrous oxide synthase activity and deficiency of c-kit cells in the intestine <sup>[16]</sup>.

Migrating motor complexes (MMC) are waves of regular electromechanical activity observed in gastrointestinal smooth muscles and occur during fasting. In patients of pseudo-obstruction, there is uncoordinated intestinal contraction due to abnormal burst of MMC [17]. At the cellular level, there is deficiency of alpha actin in the inner circular layer of small bowel smooth muscle. Myosites are weak and undergo atrophy in myopathies and result in ineffective bowel propulsion. Anti-neuronal and anti-calcium channel antibodies cause enteral neuronal degeneration in patients who, in addition, have auto immune diseases and paraneoplastic conditions[18].

## 5. Etiology

Multiple disorders are associated with colonic pseudo-obstruction (Table 1). However, there is no single factor responsible for the development of pseudo-obstruction.

In a study that analyzed 400 cases of pseudo-obstruction, Vanek et al found the predisposing conditions associated with acute colonic pseudo-obstruction are: non-operative trauma (11.3%), infection [pneumonia,sepsis] (10%), Cardiac [MI, heart failure] (10%), Obstetric and Gynecological disorders (9.8%), abdominal/pelvic surgery (9.3%), Neurologic (9.3%), Orthopedic Surgery (7.3%), miscellaneous medical conditions [metabolic, cancer, respiratory failure, renal failure] (32%), and miscellaneous surgical conditions [Urology, Thoracic, Neurosurgery] (11.8%)[39].

<b>Disorders associated with colonic pseudo-obstruction</b>	
1.Surgical procedures- 1-Pelvic surgery. 2-Obstetric/gyne surgery. 3-Abdominal Surgery. 4-Hip Surgery. 5-Spinal surgery. 6-Thoracic/Cardiovascular Surgery. 7-Caesarean section. 8-Transplantation-Renal/Liver.  2-Drugs- 1-Opiates. 2-Calcium channel blockers. 3-Antidepressants. 4-Antiparkinson drugs. 5-Anticholinergic. 6-Phenothiazines. 7-Laxative Abuse. 8-Amphetamine. 9-Vincristine. 10-Interleukins. 11-Clonidine. 12-Benzodiazepines.	6-Malignancy- 1-Retroperitoneal cancer. 2-Leukemia. 3-Small cell lung cancer. 4-Pelvic radiotherapy. 5-Desseminated metastasis. 7-Neurologic- 1-Dementia. 2-Parkinson's disease. 3-Multiple sclerosis. 4-Cerebrovascular accident. 5-Nerve root compression. 6-Subarachnoid hemorrhage. 8-Pulmonary- 1-Pneumonia. 2-Mechanical ventilation. 3-COPD. 4-Thoracic surgery. 5-Pulmonary thrombus. 9-Cardiovascular - 1-Myocardial infarction. 2-Congestive Heart failure. 3-Peripheral vascular disease. 4-Cardiovascular surgery.

<p>3-Trauma-</p> <ol style="list-style-type: none"> <li>1-Abdominal trauma.</li> <li>2-Pelvic fracture.</li> <li>3-Spinal trauma.</li> <li>4-Femoral fracture.</li> <li>5-Burns.</li> </ol> <p>4-Metabolic Disorders-</p> <ol style="list-style-type: none"> <li>1-Electrolyte abnormalities.</li> <li>2-Alcoholism.</li> <li>3-Lead toxicity.</li> <li>4-Diabetes Mellitus.</li> <li>5-Uremia.</li> <li>6-Hepatic failure.</li> <li>7-Hypothyroidism.</li> </ol> <p>5-Infections-</p> <ol style="list-style-type: none"> <li>1-Appendicitis.</li> <li>2-Pancreatitis.</li> <li>3-Cholecystitis.</li> <li>4-Abdominal / pelvic abscess.</li> <li>5-Sepsis.</li> <li>6-Pseudomembranous colitis.</li> <li>7-Herpes zoster.</li> </ol>	<p>5-Aortic aneurysm.</p> <p>10-Obstetric-</p> <ol style="list-style-type: none"> <li>1-Post partum.</li> <li>2-Caesarean section.</li> </ol>
--	---

Table 1.

### 5.1 Etiological classification

The disorders linked to the development of colonic pseudo-obstruction can be classified according to the pathophysiological derangement they ensue (Table 2).

i. Dysfunction of nerve supply to the bowel

The nerve supply of the bowel is affected in many diseases such as diabetes mellitus, amyloidosis, and porphyria. While the motility of small bowel rarely gets affected, autonomic neuropathy commonly affects gastric emptying in diabetes. Colonic dilatation may be found in patients with severe diabetes [19]. In amyloidosis, amyloid deposition in nerves leads to abnormal response to cholinergic agents [20]. In secondary amyloidosis pseudo-obstruction occurs as a terminal manifestation [21]. Degenerative diseases of the myenteric plexus, such as Fabry's disease, also are associated with pseudo-obstruction [22].

Intestinal motility is inhibited by some drugs and result in acute pseudo-obstruction. These drugs include atropine like drugs, clonidine, tricyclic antidepressants and vincristine[23,24,25,26]. Varicella infection is associated with damage of myenteric plexus [27]. Kawasaki disease and Chaga's disease produce an abnormality of gut motility due to an inflammatory reaction in myenteric plexus [28].

ii. Dysfunction of colonic muscle

Colonic smooth muscle dysfunction has been found in many cases of pseudo-obstruction. Visceral as well as skeletal muscle disorders have been linked with pseudo-obstruction of colon. Hereditary visceral myopathy is a degenerative disease of the longitudinal muscle layer which presents as an autosomal dominant disease[29]. Skeletal muscle disorders, such

as dystrophia myotonica and polymyositis, may also result in abnormal gastric and bowel motility<sup>[30]</sup>.

<p>1-Dysfunction of nerve of bowel-</p> <p>1-Metabolic-</p> <ul style="list-style-type: none"> <li>- Diabetes Mellitus.</li> <li>- Amyloidosis.</li> <li>- Porphyria.</li> <li>- Paraneoplastic syndrome.</li> </ul> <p>2-Toxins-</p> <ul style="list-style-type: none"> <li>- Drugs.</li> <li>- Insecticides.</li> <li>- Heavy metals.</li> </ul> <p>3-Inflammatory-</p> <ul style="list-style-type: none"> <li>- Varicella.</li> <li>- Chagas disease.</li> <li>- Kawasaki disease.</li> </ul> <p>2-Dysfunction of muscle of bowel-</p> <p>1-Familial visceral myopathy.</p> <p>2-Dystrophia myotonica.</p> <p>3-Polymyositis.</p> <p>3-Combined nerve and muscle dysfunction of bowel-</p> <p>1-Pregnancy.</p> <p>2-Hypoparathyroidism.</p> <p>3-Myxoedema.</p> <p>4-Pheochromocytoma.</p> <p>5-Trauma.</p> <p>6-Enteroglucagonoma.</p> <p>7-Jejuno-ileal bypass.</p> <p>4-Disorders of collagen and Interstitium of bowel-</p> <p>1-Radiation.</p> <p>2-Mesenteric Panniculitis.</p> <p>3-Scleroderma.</p> <p>4-Ehlers-Danlos syndrome.</p> <p>5-Sarcoidosis.</p> <p>6-Strongyloidosis.</p>
---

Table 2. Etiological classification

iii. Combined nerve & muscles dysfunction of bowel

Dysfunction of the intrinsic nervous system of bowel and muscular disorders together have been found in many cases of pseudo-obstruction of colon. There is infrequent IMC and slow intestinal transit during pregnancy. There are reports of pseudo-obstruction following

cesarean section<sup>[31]</sup>. Congenital hypoparathyroidism has been associated with pseudo-obstruction<sup>[32]</sup>. Myxoedema also produces pseudo-obstruction<sup>[33]</sup>. Abdominal pain and vomiting is also associated with pseudo-obstruction caused by pheochromocytoma<sup>[34]</sup>. Blunt abdominal trauma is associated with pseudo-obstruction and often is linked with sepsis<sup>[35]</sup>.

#### iv. Disorders of colonic collagen and interstitium

Collagen metabolism is disturbed in colonic pseudo-obstruction. Irradiation to gut causes fibrosis which is more severe after pelvic irradiation<sup>[36]</sup>. Mesenteric panniculitis produces pseudo-obstruction by decreasing bowel wall compliance in addition to neural involvement<sup>[37]</sup>. Scleroderma produces excess collagen and causes pseudo-obstruction, volvulus, diverticulosis and perforation<sup>[38]</sup>.

## 6. Clinical features

Patients are typically middle aged who are hospitalized for systemic disease or an unrelated surgical problem. The typical presentation is a picture of large intestinal obstruction. The disease can present as acute or chronic pseudo-obstruction. Acute cases present as mild or severe abdominal distension often causing diaphragmatic splinting and difficulty in breathing and usually occur in elderly patients following surgery. Chronic pseudo-obstruction is associated with features of malabsorption and malnutrition.

In acute pseudo-obstruction, marked abdominal distension is the most consistent clinical finding. Frequent other findings include abdominal pain, nausea, and vomiting. Constipation is a frequent symptom but 40% of patients have diarrhea. The pain is usually colicky but may be dull and constant. Fifty percent of patients show abdominal tenderness mainly in right iliac fossa. Bowel sounds may be hyperactive, high pitched or even normal. Ischemia and perforation are the most feared complications of acute colonic pseudo-obstruction; spontaneous perforation has been reported in 3% to 15% of patients with a mortality rate of 50% or higher<sup>[39]</sup>. The rate of perforation and/or ischemia rapidly increases with a cecal diameters of >10 to 12 cm and also when the duration of distention exceeds 6 days<sup>[40]</sup>. Fever may be present in some cases. The digital rectal examination typically reveals an empty rectum. Post operative pseudo-obstruction of the colon has been reported in many series following orthopedic, gynecological, urologic and lumbar spine surgery<sup>[41,42,43]</sup>

## 7. Investigations

Diagnosis depends on clinical presentation and the results of investigations. Investigations are needed to exclude mechanical cause of obstruction. Electrolyte disturbance is usually found in majority of patients with hypocalcemia, hyponatremia and hypokalemia being the most common laboratory finding. Leukocytosis is a frequent finding in cases of perforation or necrosis of the colonic wall.

Plain abdominal X-rays (Figures 1, 2) is the initial radiological investigation for patients presenting with colonic obstruction. Distension of the colon, especially the caecum, is a common feature and its diameter measurement is essential (Figure 3). A caecal diameter of more than 12cm has been found to be associated more often with perforation, and at a diameter of 12 to 14cm the rate of perforation rose to 7% and climbed to 23% if caecal dilatation was more than 14cm<sup>[44]</sup>. Animal and retrospective data suggest a critical thresholds of 9 cm for the transverse colon and 12 cm for the cecum; however, many

patients present with dimensions greater than this without sequelae<sup>[45]</sup>. Colonic haustral and mucosal patterns are often maintained on X-rays. Transition from proximal dilated to decompressed colon is usually seen at the splenic flexure. Distension of colon follows Laplace's law which states that pressure required to stretch the walls of hollow viscus varies inversely with its radius <sup>[46]</sup>. Laplace's law is  $T=P*R/2$  where T is wall tension, P is transmural pressure and R is radius of bowel. Cecum is more vulnerable to distension and perforation as it is the widest part of the colon. Serial plain abdominal x-rays are useful in cases of chronic pseudo-obstruction as they are less likely to perforate than acute obstruction. Serial x-rays are needed to monitor the progress of conservative therapy and to guide further management.

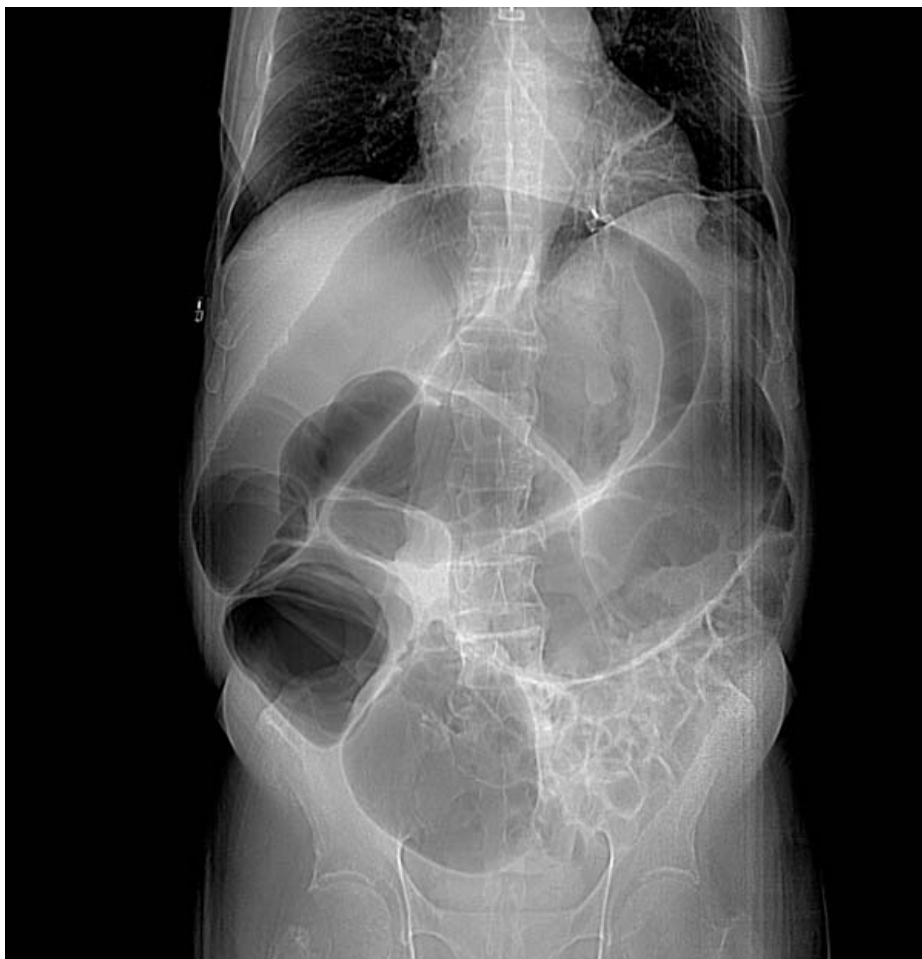

Fig. 1. Distension of colon in pseudo-obstruction

Low et al advised prone lateral view of the rectum to aid in diagnosis. He recommends placing the patient in the right lateral decubitus position for several minutes to allow

passage of gas into distal colon. This facilitates the gaseous filling of the rectum when the patient is positioned for a prone lateral view of the pelvis. He found 75% success rate in excluding mechanical obstruction when there was gaseous filling of rectum.

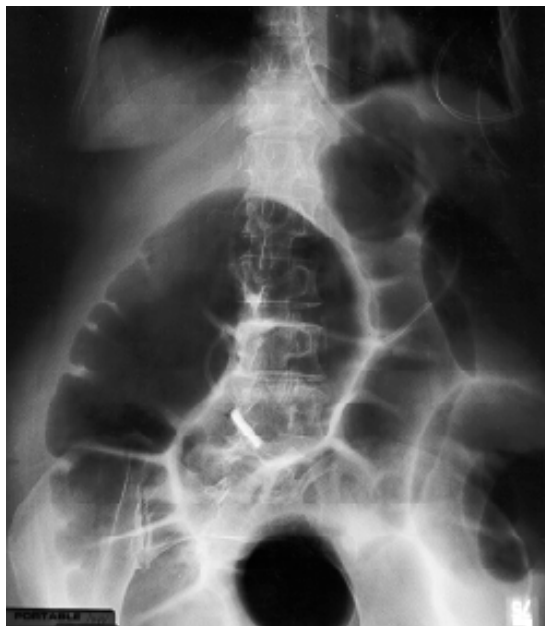

Fig. 2. Transverse colon distension in pseudo-obstruction

**Contrast enema** is very helpful when pseudo-obstruction of the colon is suspected. It is the investigation of choice to exclude mechanical obstruction and its sequel, perforation<sup>[47]</sup>. The contrast material should be introduced under low pressure. There is no need for air to be introduced and the examination should be terminated when dilated colon is reached. Gastrografin is water soluble, clear and can be easily washed at the time of colonoscopy. Because it is hyperosmolar, it causes shift of fluids into lumen and, thus, has a low risk of contaminating the peritoneum when there is a perforation. Gastrografin enema confirms the diagnosis if there is absent, decreased or disorganized motility in any part of colon with decreased haustrations in the absence of any stricture<sup>[48]</sup>.

**Computerized tomography [CT]** is used to exclude mechanical causes of obstruction and, when intravenous and luminal contrasts are used, the radiologist can comment on the condition of the wall of the colon and luminal pathology. The presence of perforation can be diagnosed when there is extra-luminal leakage of the luminal contrast. CT imaging can also show the presence of other intra-abdominal or retroperitoneal and solid organs pathology.

**Colonoscopy** is useful if done with caution as these patients may perforate. It can be both diagnostic and therapeutic as it can decompress the distended colon. Capsular endoscopy is not advised in pseudo-obstruction as it can be retained for long time<sup>[49]</sup>.

**Manometry and intestinal transit scintigraphy** is used commonly in children with Hirschprung's disease. Colonic dysmotility which may be segmental or global may cause massive colonic distension in these patients<sup>[50,51]</sup>.



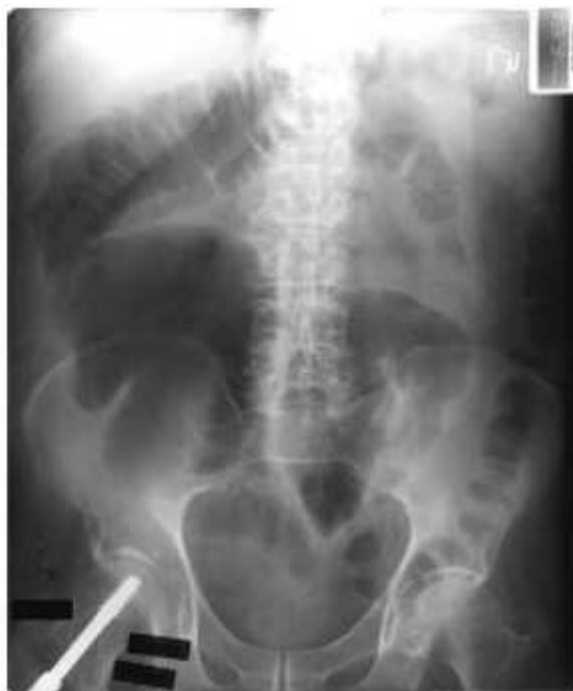

Fig. 3. Distension of the right colon post femoral fracture

## 8. Differential diagnosis

Colonic pseudo-obstruction must be differentiated from mechanical causes of large bowel obstruction where there is a true physical cause of obstruction including colonic volvulus, strictures and tumors. The differential diagnosis also includes various other causes of mechanical gastrointestinal obstruction as well as functional paralytic ileus and acute gastric distension. The clinical picture of colonic pseudo-obstruction may be confused with other causes of acute abdomen in patients who present late with symptoms and signs of perforation and peritonitis.

### 8.1 Conservative management

Patients of pseudo-obstruction are managed conservatively initially unless there are signs of mechanical obstruction or perforation. Initial management consists of correction of any precipitating factors that led to the development of pseudo-obstruction. Serial regular clinical examination should be performed for the development of abdominal tenderness or other signs of sepsis/peritonitis and abdominal x-rays should be repeated every twelve hours. Conservative measures can be used alone for 24-48 hours for patients without significant abdominal pain or signs of peritonitis and who have one or more potential underlying factors that are reversible. These patients are kept nil per orally with nasogastric tube suctioning for decompression. Rectal tube insertion has been used to aid in decompressing the distal colon. Body positioning (if feasible) often aid the spontaneous

evacuation of flatus. The patient is placed prone with the hips elevated on a pillow, in the knee-chest position with the hips high, or alternating right and left lateral decubitus position. The use of hyperbaric oxygenation may be effective in the management of chronic idiopathic intestinal pseudo-obstruction due to myopathy<sup>[52]</sup>.

Sloyer et al. reported successful resolution in 92% of his patients by conservative management, with a mean cecal diameter 11.7 cm and a mean time to resolution of 1.6 days<sup>[44]</sup>. There was no perforation or death and most patients who responded to the conservative management did so within 3 to 6 days. They recommended invasive therapy only to those who do not respond to this treatment.

Active intervention is indicated for patients who deteriorate despite conservative measures, those with clinical features of ischemia or perforation, and for patients with sepsis (significant pain, fever, leucocytosis), respiratory compromise, or hemodynamic instability.

## 8.2 Medical treatment

Neostigmine has been used widely for the treatment of colonic pseudo-obstruction. It is an acetylcholinesterase inhibitor which acts in reversible manner. It stimulates muscarinic receptors which in turn increases motor activity of colon and results in propulsion of feces in colon<sup>[53]</sup>. Its therapeutic effect is because of its parasympathomimetic effect. It increases parasympathetic activity which leads to hyperperistalsis. Neostigmine was first tried by Neely and Catchpole three decades ago in small bowel paralytic ileus<sup>[54]</sup>. Neostigmine is given intravenously and has a rapid onset [1-20 min] and short duration of action [1-2 hrs]<sup>[55]</sup>. Its half-life is 80 minutes.

A randomized double blinded trial evaluated neostigmine in 11 patients with acute colonic pseudo-obstruction with a cecal diameter of >10 cm and no response to conservative therapy for 24 hrs<sup>[55]</sup>. The criteria for exclusion were- suspected ischemia or perforation, pregnancy, renal failure, arrhythmias and severe active bronchospasm. Patients were randomized to receive neostigmine 2 mg or saline by intravenous infusion over 3-5 minutes. The primary end point was a clinical response that prompts a decrease in abdominal distension which as determined by physical examination. Secondary end point was the change in abdominal girth and the change in colonic diameter on abdominal radiographs. Patients not responding within 3 hours were eligible for open label neostigmine. A clinical response was observed in 91% of patients randomized to receive neostigmine compared to 0 receiving placebo. The median time to response was 4 minutes. The median reduction in cecal diameter [5 cm vs. 2 cm] and abdominal girth [7 cm vs. 1 cm] were significantly reduced in neostigmine group. Open label neostigmine was given in 8 patients who failed to respond to initial infusion [7 placebo, 1 neostigmine] and all had prompt decompression. The recurrence rate of colonic distension after neostigmine decompression was 11%. Common side effects were mild abdominal cramps and excessive salivation. Symptomatic bradycardia occurred in two patients who required atropine<sup>[55]</sup>. The side effects of neostigmine are due to excessive parasympathetic activity.

Many other studies also have recommended neostigmine for the treatment of colonic pseudo-obstruction<sup>[56, 57, 58, 59]</sup>. Neostigmine administration should be done with caution. Patient requires admission to a high dependency unit or cardiac unit for the administration of neostigmine. The medication should be given while the patient is supine on the bed with continuous electro-cardiac monitoring in place. The physician should clinically assess the patient periodically and vital signs measurement should be done every 15-30 minutes. There

are some contraindication for neostigmine use, like mechanical bowel obstruction, suspected bowel ischemia or perforation, uncontrolled cardiac arrhythmias, renal insufficiency and severe bronchospasm.

Neostigmine is a safe, effective and cheap medication in the management of colonic pseudo-obstruction and the current available data recommend its use as the initial therapy of choice for patients not responding to conservative treatment.

Erythromycin is another medication used in the management of colonic pseudo-obstruction. Erythromycin is a motilin receptor agonist that has been shown to decompress the bowel in a few case reports [60]. In one study erythromycin improved gastric emptying and intestinal transit measured by sulphamethizole methods and radio opaque markers, respectively [61]. Side effects include bloating, abdominal pain, nausea and vomiting. Repeated intravenous administration of erythromycin through a peripheral vein may cause phlebitis.

Somatostatin analogue, Octreotide, is used in scleroderma and paraneoplastic syndromes. Its action is independent of motilin. Octreotide increases MMC especially in scleroderma patients by an unknown mechanism. Plasmapheresis may be useful in selected cases of paraneoplastic syndromes where pseudo-obstruction is associated with autoantibodies. Cisapride and tegaseroid are also used in colonic pseudoobstruction [62,63].

Spinal anaesthesia has resolved some cases of intestinal pseudo-obstruction, which is due to blockade of sympathetic activity.

Hyperbaric oxygen has been used in chronic idiopathic intestinal pseudo-obstruction due to myopathy although the exact mechanism of action is not known.

Antibiotics can be used intermittently to suppress intestinal overgrowth and thus resolve pseudo-obstruction. Common antibiotics used are metronidazole, doxycycline, and ciprofloxacin. Table 3 summarizes the available medical treatment options.

### 8.3 Colonoscopic treatment

Many patients fail to respond to neostigmine and other conservative methods may need endoscopic decompression. The first use of colonoscopic decompression in cases of pseudo-obstruction was done in 1977 by Kukora et al [64]. These patients have a risk of perforation following bowel ischemia. Colonoscopic decompression is done in these patients to prevent such complications. However, some precautions should be exercised when performing colonoscopy in these patients. Specifically, no oral laxatives or bowel preparation should be given and minimal air insufflation should be used during the procedure. There is no need to attempt to examine whole length of the colon. Suctioning the gas decompresses the colon and mucosal viability is assessed while slowly withdrawing the colonoscope. A per rectal tube for decompression should be left in the colon at the end of the procedure.

The success of colonoscopic decompression has been reported in multiple studies. The initial extent bowel decompression is determined by a reduction in the cecal diameter by radiology. Less than half of the patients benefit from colonoscopic decompression without tube placement [65]. Placement of a tube following colonoscopy is strongly recommended as reported by many studies [66,67,68]. This seems to lower the recurrence rate although its value has not been evaluated in controlled trials. A perforation rate of 3% has been reported following colonic decompression by colonoscopy [69]. Despite of complications colonoscopic decompression in cases of colonic pseudo-obstruction is a useful tool [70]. Colonoscopic decompression of the colon is effective, causing decreased cecal diameter in 73% to 100% of cases [71]. The advantage of endoscopic decompression is that mortality rates for colonoscopic decompression were 1% to 5% compared with 12% to 20% for tube cecostomy [72]. However,

Drug	Dose	Mechanism of action	Advantage	Note
Erythromycin	0.5 g tds or qds	Motilin agonist	Cheap	Less effective if taking opioids
Domperidone	20 mg tds	Blocks dopaminergic receptors	Does not enter BBB	Can cause hyperprolactinemia
Metaclopramide	10 mg tds	Blocks dopaminergic (D2) receptors	Cheap	Can cause extra-pyramidal symptoms
Neostigmine	2 mg IV	Acetylcholinesterase inhibitor	Effective	Needs monitoring in ICU/high dependency

Table 3. Drugs used in the treatment of colonic pseudo-obstruction

Reference	Method used	Success rate (%)
Emmanuel et al	Erythromycin	40
Ponec et al	Neostigmine	91
Perlemuter et al	Octreotide in connective tissue disease	100
Lee et al	Epidural	62
Jetmore et al	Colonoscopic decompression	64

Table 4. Reports of success rate of various methods in pseudo-obstruction

Reference	Method	Recurrence (%)	Morbidity
Farinon et al	Colonoscopy	29	Pain, risk of perforation
Lee et al	Epidural	None	Epidural side effects
Ponec et al	Neostigmine	20	Abdominal pain, cardiac arrhythmia, excess salivation, vomiting
Dalgic et al	Erythromycin	50	Abdominal pain, liver function disturbance,

Table 5. Recurrence of pseudo-obstruction and morbidity associated with each method.

recurrence rates of 10% to 65% have been noted after initial success as documented by increased caecal diameter on radiography<sup>[73,74,75]</sup>.

Recently a randomized trial on the effect of oral Polyethylene Glycol (PEG) electrolyte balanced solution on the relapse of pseudo-obstruction after initial resolution with neostigmine or colonoscopic decompression showed sustained response rate and prevention of such episodes. Patients were randomized to receive PEG (29.5gm) or placebo and monitored for 7 days and it was found that 33% of recurrence rate in the patients who received placebo while none in PEG group. Therapy with PEG also resulted in significant increase in stool and flatus evacuations<sup>[76]</sup>.

#### **8.4 Surgical decompression**

Surgery is reserved for those patients who do not respond to nonoperative management and those who present in sepsis, perforation or peritonitis<sup>[77]</sup>. Early recognition and prompt conservative management of pseudo-obstruction of the colon can minimize complications as well as the need for surgical intervention. Surgical options include percutaneous endoscopic colostomy, cecostomy and colectomy. Cecostomy can be done via the open or laparoscopic methods. Tube cecostomy is useful in acute colonic pseudo-obstruction as it achieves successful decompression with fewer complications. It is also useful in patients of chronic intestinal pseudo-obstruction<sup>[78]</sup>.

Colectomy is performed when there is perforation or gangrene of the colon. Right or left colectomy can be offered depending on the site of gangrene or perforation, often with colostomy or end ileostomy. There is a higher risk of abdominal compartment syndrome post abdominal surgery in these cases due to edema of abdominal viscera. Therefore, if primary closure of abdominal wall is difficult then temporary closure with delayed secondary permanent closure should be considered. In the post operative period, attention should be given to improve the splanchnic circulation as a previously dilated colon is more susceptible to perforation. Complications of surgical intervention include abdominal sepsis, anastomotic dehiscence, fistulas and abdominal compartment syndrome. Surgical site infections are also common with subsequent fascial dehiscence and incisional hernia.

A chart summarizing the management of colonic pseudo-obstruction is shown in Figure 4.

### **9. Prognosis and prevention**

Most of the patients stay hospitalized for less than a week. Increased in morbidity and mortality has been shown when surgical treatment was needed<sup>[79]</sup>. The mortality rate in medically treated patients is 14% and surgically treated patients is 30%, with a higher mortality in patients with cecal perforation or ischemia<sup>[80]</sup>. The reported incidence of cecal perforation is 3-40% with an associated mortality of 40-50%. A cecal diameter of greater than 14 cm, a delay in colonic decompression and advanced age are the predictors of colonic perforation.

Colonic pseudo-obstruction is a preventable disease in certain occasions, so emphasis should be on preventing this disease rather than on treatment, whenever possible. This can be done by early mobilization of hospitalized patients, prevention of constipation and the development of new pharmacologic agents which can resolve colonic inertia and help in propulsion of feces.

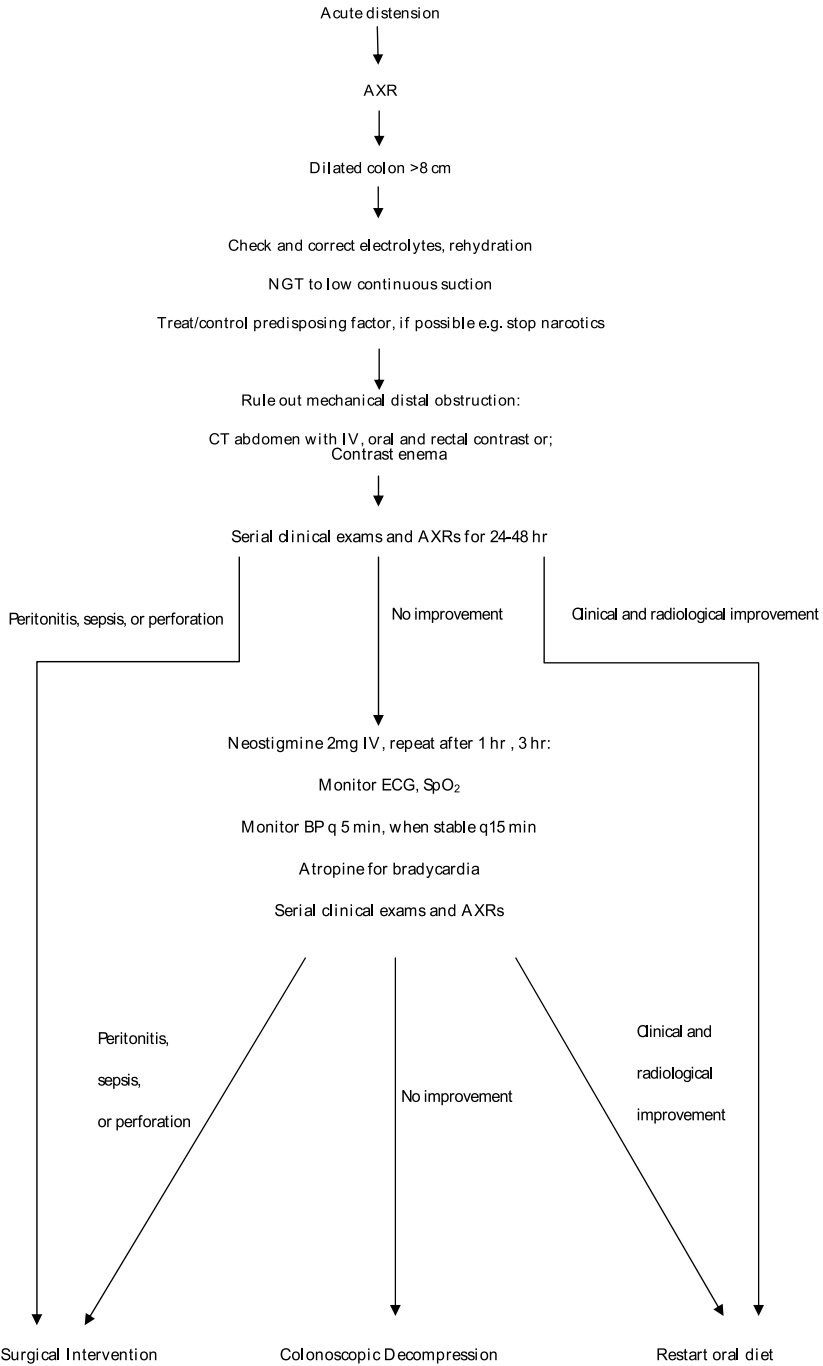


Fig. 4. Management flow chart.

## 10. References

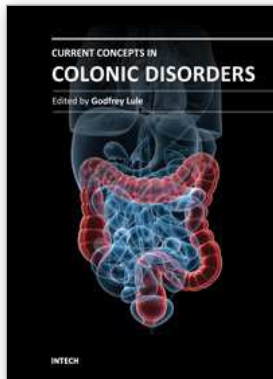
- [1] Ogilvie WH. Large intestine colic due to sympathetic deprivation:a new clinical syndrome. *Br Med J* 1948;2:671-673.
- [2] W. Weiss:Zur Ätiologie des Megaduodenums.*Deutsche Zeitschrift für Chirurgie, Leipzig, 1938, 251: 317-330.*
- [3] J. Dunlop:Ogilvie's syndrome of false colonic obstruction.*The British Medical Journal, 1949, 1: 890-891.*
- [4] H. O. Dudley, I. S. Sinclair, I. F. McLaren, T. J. McNair, J. E. Newsam:Intestinal pseudo-obstruction. *Journal of the Royal College of Surgeons of Edinburgh, 1958, 3: 206-217.*
- [5] Eisen GM, Baron TH, Dominitz JA, et al. Acute colonic pseudo-obstruction. *GastrointestEndosc* 2002;56:789-92.
- [6] Nelson JD, Urban JA, Salsbury TL, Lowry JK, Garvin KL. Acute colonic pseudo-obstruction (Ogilvie syndrome) after arthroplasty in the lower extremity. *J Bone Joint Surg Am* 2006; 88:604-10.
- [7] Khalid K, Al-Salamah SM. Spectrum of general surgical problems in the developmentally disabled adults. *Saudi Med J* 2006; 27:70-5.
- [8] Brading, A.F. (1979). Smooth muscle. Maintenance of ionic composition. *British Medical Bulletin, 35, 227.*
- [9] Burnstock G. (1982). Studies of autonomic nerves in the gut- past, present and future. *Scandinavian Journal of Gastroenterology, 17, suppl. 7, 135..*
- [10] Duthie, H.L. (1979). Links between basic and clinical studies of gastrointestinal smooth muscle. *British Medical Bulletin, 35, 301.* FAULK, D.L. (1978).
- [11] Hirst, G.D.S. (1979). Mechanisms of peristalsis. *British Medical Bulletin, 35, 263.*
- [12] Sarna, S., Stoddard, C., Belbeck, L. & McWade, D. (1981). Intrinsic nervous control of migrating myoelectric complexes. *American Journal of Physiology, 241, G16.*
- [13] Itoh, Z., Aizawa, I. & Sekiguchi, T. (1981). The interdigestive migrating complex and its significance in man. *Clinics in Gastroenterology, 11, 497.*
- [14] Heppell, J., Becker, J.M., Kelly, K.A. & Zinsmeister, A.R. (1983). Postprandial inhibition of canine enteric interdigestive myoelectric complex. *American Journal of Physiology, 244, G160.*
- [15] Mashour GA, Peterfreund RA. Spinal anesthesia and Ogilvie's syndrome. *J Clin Anesth* 2005; 17:122-3.
- [16] Wang ZQ, Watanabe Y, Toki A, et al. Involvement of endogenous nitric oxide and c-kit-expressing cells in chronic intestinal pseudo-obstruction. *J Pediatr Surg* 2000; 35:539-44.
- [17] Watanabe Y, Ito T, Ando H, Seo T, Nimura Y. Manometric evaluation of gastrointestinal motility in children with chronic intestinal pseudo-obstruction syndrome. *J Pediatr Surg* 1996; 31:233-8.
- [18] Simpson DA, Pawlak AM, Tegmeyer L, Doig C, Cox D. Paraneoplastic intestinal pseudo-obstruction, mononeuritis multiplex, and sensory neuropathy/neuronopathy. *J Am Osteopath Assoc* 1996; 96:125-8.
- [19] Paley, R.G., Mitchell, W. & Watkinson, G. (1961).Terminal colonic dilatation following intractable diarrhea in a diabetic. *Gastroenterology, 41, 401.*
- [20] Battle, W.M., Ruben, M.R., Cohen, S. & Snape, W.J. (1979). Gastrointestinal motility dysfunction in amyloidosis. *New England Journal of Medicine, 301, 24.*

- [21] Legge, D.A., Wollaeger E.F. & Carlson, H.C. (1970). Intestinal pseudo-obstruction in systemic amyloidosis. *Gut*, 11, 764.
- [22] Friedman LS, Kirkham SE, Thistlethwaite JR, Platika D, Kolodny EH, Schuffler MD. 3.; Jejunal diverticulosis with perforation as a complication of Fabry's disease *Gastroenterology*. 1984 Mar;86(3):558-63.
- [23] Bear, R. & Steer, K. (1976). Pseudo-obstruction due to Intestinal pseudo-obstruction 1037 clonidine. *British Medical Journal*, 1, 197.
- [24] Faulk, D.L. (1978). Approach to patients with intestinal pseudo-obstruction. *Gastroenterology*, 74, 1320.
- [25] Faulk, D.L., Anuras, S., Gardner, D., Mitros, F., Summers, R.W. & Cristensen J. (1978). A familial visceral myopathy. *Annals of Internal Medicine*, 89, 600.
- [26] Sriram, K., Schumer, W., Ehrenpreis, S., Camaty, J.E. & Scheller, L. (1979). Phenothiazine effect on gastrointestinal tract function. *American Journal of Surgery*, 137, 87.
- [27] Walsh, T.N. (1982). Pseudo-obstruction of the colon associated with varicella-zoster infection. *Irish Journal of Medicine*, 151, 318.
- [28] Smith, B. (1980). Changes in the myenteric plexus in Chagas' disease. *Journal of Pathology and Bacteriology*, 94, 642.
- [29] Schuffler, M.D. & Pope, C.E. (1977). Studies of idiopathic intestinal pseudo-obstruction. II. Hereditary hollow visceral myopathy: family studies. *Gastroenterology*, 73, 339.
- [30] Patterson, M. & Rios, G. (1959). Disturbed gastrointestinal motility - an unusual manifestation of a systemic muscular disorder: polymyositis or progressive muscular dystrophy. *Gastroenterology*, 36, 261.
- [31] Ravo, B., Pollane M. & Ger, R. (1983). Pseudo-obstruction of the colon following caesarean section. A review. *Diseases of the Colon and Rectum*, 26, 440.
- [32] Cockel, R., Hill, E.E. & Rushton, E.I. (1973). Familial steatorrhea with calcification of the basal ganglia and mental retardation. *Quarterly Journal of Medicine*, 42, 771.
- [33] Salerno, N. & Grey, N. (1978). Myxoedema pseudoobstruction. *American Journal of Roentgenology*, 130, 175.
- [34] Turner, C.E. (1983). Gastrointestinal pseudo-obstruction due to pheochromocytoma. *American Journal of Gastroenterology*, 78, 214
- [35] Addison, N.V. (1983). Pseudo-obstruction of the large bowel. *Journal of the Royal Society of Medicine*, 76, 252.
- [36] Lopez, M.J., Memula, N. & Doss, L.L. (1981). Pseudoobstruction of the colon during pelvic radiotherapy. *Diseases of the Colon and Rectum*, 24, 201
- [37] Tytgat, G.N., Roozendaal, K. & Winter, W. (1980). Successful treatment of a patient with retractile mesenteritis with prednisone and azathioprine. *Gastroenterology*, 79, 352.
- [38] Krishnamurthy, S., Kelly, M.M., Rohrmann, C.W. & Schuffler, M.D. (1983). Jejunal diverticulosis. A heterogeneous disorder caused by a variety of abnormalities of smooth muscle or myenteric plexus. *Gastroenterology*, 85, 538.
- [39] Vanek VW, Al-Salti M. Acute pseudo-obstruction of the colon (Ogilvie's syndrome): an analysis of 400 cases. *Dis Colon Rectum* 1986;29:203-10.
- [40] Rex DK. Colonoscopy and acute colonic pseudo-obstruction. *Gastrointest Endosc Clin N Am* 1997;7:499-508.
- [41] Johnson C, Rice R, Kelvin F, Foster W, Williford M. The radiographic evaluation of gross cecal distension: emphasis on cecal ileus. *AJR Am J Roentgenol* 1986;145:1211-7.



- [42] Caner H, Bavbeck M, Albayrak A, Calisanellar T, Altinors N. Ogilvie's syndrome as a rare complication of lumbar disc surgery. *Can J Neurol Sci* 2000;27:77-8.
- [43] O'Malley K, Flechner S, Kapoor A, Rhodes RA, Modlin CS, Goldfarb DA, et al. Acute colonic pseudo-obstruction (Ogilvie's syndrome) after renal transplantation. *Am J Surg* 1999;177:492-6.
- [44] Sloyer AF, Panella VS, Demas BE, Shike M, Lightdale CJ, Winawer SJ, et al. Ogilvie's syndrome: successful management without colonoscopy. *Dig Dis Sci* 1988;33:1391-6.
- [45] Chapman AH, McNamara M, Porter G. The acute contrast enema in suspected large bowel obstruction: value and technique. *Clin Radiol* 1992; 46:273-8.
- [46] Slam KD, Calkins S, Cason FD LaPlace's law revisited: cecal perforation as an unusual presentation of pancreatic carcinoma. *World J Surg Oncol*. 2007 Feb 2;5:14.
- [47] Abeyta BJ, Albrecht RM, Schermer CR. Retrospective study of neostigmine for the treatment of acute colonic pseudo-obstruction. *Am Surg* 2001.
- [48] Byrne WJ, Cipel L, Ament ME, Gyepes MT. Chronic idiopathic intestinal pseudo-obstruction syndrome. Radiologic signs in children with emphasis on differentiation from mechanical obstruction. *Diagn Imaging* 1981; 50:294-304.
- [49] Storch I, Barkin JS. Contraindications to capsule endoscopy: do any still exist? *Gastrointest Endosc Clin N Am* 2006; 16:329-36.
- [50] Martin MJ, Steele SR, Mullenix PS, et al. A pilot study using total colonic manometry in the surgical evaluation of pediatric functional colonic obstruction. *J Pediatr Surg* 2004; 39:352-9.
- [51] Panganamamula KV, Parkman HP. Chronic intestinal pseudo-obstruction. *Curr Treat Options Gastroenterol* 2005;8:3-11.
- [52] Yokota T, Suda T, Tsukioka S, et al. The striking effect of hyperbaric oxygenation therapy in the management of chronic idiopathic intestinal pseudo-obstruction. *Am J Gastroenterol* 2000; 95:285-8.
- [53] Law NM, Bharucha AE, Undale AS et al. Cholinergic stimulation enhances colonic motor activity, transit, and sensation in humans. *Am J Physiol Gastrointest Liver Physiol* 2001;281:G1228-37.
- [54] Neely J, Catchpole B. Ileus: The restoration of alimentary tract motility by pharmacologic means. *Br J Surg* 1971;58:21-8.
- [55] Aquilonius SM, Hartvig P. Clinical pharmacokinetics of cholinesterase inhibitors. *Clin Pharmacokinet* 1986;11:236-49.
- [56] Ponc R, Saunders MD, Kimmey MB. Neostigmine for the treatment of acute colonic pseudo-obstruction. *N Engl J Med* 1999;341:137-41.
- [57] Loftus CG, Harewood GC, Baron TH. Assessment of predictors of response to neostigmine for acute colonic pseudo-obstruction. *Am J Gastroenterol* 2002;97:3118-22.
- [58] Abeyta BJ, Albrecht RM, Schermer CR. Retrospective study of neostigmine for the treatment of acute colonic pseudo-obstruction. *Am Surg* 2001;67:265-8.
- [59] Ponc R, Saunders MD, Kimmey MB. Neostigmine for the treatment of acute colonic pseudo-obstruction. *N Engl J Med* 1999;341:137-41.
- [60] Armstrong DN, Ballantyne GH, Modlin IM. Erythromycin for reflex ileus in Ogilvie's syndrome. *Lancet* 1991;337:378.
- [61] Bonacini M, Smith OJ, Pritchard T. Erythromycin as therapy for acute colonic pseudo-obstruction (Ogilvie's syndrome). *J Clin Gastroenterol* 1991;13:475-6.

- [62] MacColl C, MacCannell KL, Baylis B et al. Treatment of acute colonic pseudo-obstruction (Ogilvie's syndrome) with cisapride. *Gastroenterology* 1990;98:773-6.
- [63] Camilleri M. Review article: tegaserod. *Aliment Pharmacol Ther* 2001;15:277-289.
- [64] Kukora JS, Dent TL. Colonic decompression of massive nonobstructive cecal dilation. *Arch Surg* 1977;112:512-517.
- [65] Rex DK. Colonoscopy and acute colonic pseudoobstruction. *Gastrointest Endosc Clin North Am* 1997;7:499-508.
- [66] Nivatvongs S, Vermeulen FD, Fang DT. Colonoscopic decompression of acute pseudo-obstruction of the colon. *Ann Surg* 1982;196:598-600.
- [67] Strodel WE, Nostrant TT, Eckhauser FE et al. Therapeutic and diagnostic colonoscopy in non-obstructive colonic dilatation. *Ann Surg* 1983;19:416-21.
- [68] Bode WE, Beart RW, Spencer RJ et al. Colonoscopic decompression for acute pseudo-obstruction of the colon (Ogilvie's syndrome): report of 22 cases and review of the literature. *Am J Surg* 1984;147:243-5.
- [69] Geller A, Petersen BT, Gostout CJ. Endoscopic decompression for acute colonic pseudo-obstruction. *Gastrointest Endosc* 1996;44:144-50.
- [70] Melange M, Van Gossum A, Houben JJ, de Ronde T, Vanheuverzwyn R, Adler M: Acute dilatation of the colon. *Acta Gastroenterol Belg* 1991;54:233-6.
- [71] Gosche JR, Sharpe JN, Larson GM. Colonoscopic decompression for pseudo-obstruction of the colon. *Am Surg* 1989;55:111-115
- [72] Bode WE, Beart RW, Spencer RJ, Culp CE, Wolff BG, Taylor BM. Colonoscopic decompression for acute pseudoobstruction of the colon (Ogilvie's syndrome). *Am J Surg* 1984;147:243-245
- [73] Nano D, Prindiville T, Pauly M, Chow H, Ross K, Trudeau W. Colonoscopic therapy of acute pseudoobstruction of the colon. *Am J Gastroenterol* 1987;82:145-148.
- [74] Duh QY, Way LW. Diagnostic laparoscopy and laparoscopic cecostomy for colonic pseudo-obstruction. *Dis Colon Rectum* 1993;36:65-70.
- [75] Thompson AR, Pearson T, Ellul J, Simson JN. Percutaneous endoscopic colostomy in patients with chronic intestinal pseudo-obstruction. *Gastrointest Endosc* 2004; 59:113-5.
- [76] Sgouros SN, Vlachogiannakos J, Vassiliadis K, Bergele C, Stefanidis G, et al. Effect of polyethylene glycol electrolyte balanced solution on patients with acute colonic pseudo-obstruction after resolution of colonic dilation: a prospective, randomised, placebo controlled trial. *Gut*. May 2006;55(5):638-42.
- [77] Ramage JI Jr, Baron TH. Percutaneous endoscopic cecostomy: a case series. *Gastrointest Endosc* 2003; 57:752-5.
- [78] Masetti M, Di Benedetto F, Cautero N, et al. Intestinal transplantation for chronic intestinal pseudo-obstruction in adult patients. *Am J Transplant* 2004; 4:826-9.
- [79] Pironi L, Spinucci G, Paganelli F, et al. Italian guidelines for intestinal transplantation: potential candidates among the adult patients managed by a medical referral center for chronic intestinal failure. *Transplant Proc* 2004; 36:659-61.
- [80] Saunders MD, Kimmey MB. Systematic review: acute colonic pseudo-obstruction. *Aliment Pharmacol Ther* 2005; 22:917-25.



## **Current Concepts in Colonic Disorders**

Edited by Dr. Godfrey Lule

ISBN 978-953-307-957-8

Hard cover, 276 pages

**Publisher** InTech

**Published online** 05, January, 2012

**Published in print edition** January, 2012

The 21st Century has seen a resurgence of research of the gastrointestinal tract, especially since it was established that it plays a central role as an immune system organ and consequentially has a huge impact on causation, impact and transmission of most human ailments. New diseases such as the Acquired Immunodeficiency Syndrome, hepatitis and tumours of the gastrointestinal tract have emerged and they are currently subjects of intensive research and topics of scientific papers published worldwide. Old diseases like diarrhea have become extremely complex to diagnose with new and old pathogens, drugs, tumours and malabsorptive disorders accounting for the confusion. This book has set out algorithms on how to approach such conditions in a systematic way both to reach a diagnosis and to make patient management cheaper and more efficient. "Current Concepts in Colonic Disorders" attempts to put all the new information into proper perspective with emphasis on aetiopathogenesis and providing rational approach to management of various old and new diseases. As the book editor, I have found this first edition extremely interesting and easy to understand. Comments on how to improve the content and manner of presentation for future editions are extremely welcome.

### **How to reference**

In order to correctly reference this scholarly work, feel free to copy and paste the following:

Abdulmalik Altaf and Nisar Haider Zaidi (2012). Colonic Pseudo-Obstruction, Current Concepts in Colonic Disorders, Dr. Godfrey Lule (Ed.), ISBN: 978-953-307-957-8, InTech, Available from:

<http://www.intechopen.com/books/current-concepts-in-colonic-disorders/colonic-pseudo-obstruction>

# **INTECH**

open science | open minds

### **InTech Europe**

University Campus STeP Ri  
Slavka Krautzeka 83/A  
51000 Rijeka, Croatia  
Phone: +385 (51) 770 447  
Fax: +385 (51) 686 166  
[www.intechopen.com](http://www.intechopen.com)

### **InTech China**

Unit 405, Office Block, Hotel Equatorial Shanghai  
No.65, Yan An Road (West), Shanghai, 200040, China  
中国上海市延安西路65号上海国际贵都大饭店办公楼405单元  
Phone: +86-21-62489820  
Fax: +86-21-62489821

© 2012 The Author(s). Licensee IntechOpen. This is an open access article distributed under the terms of the [Creative Commons Attribution 3.0 License](#), which permits unrestricted use, distribution, and reproduction in any medium, provided the original work is properly cited.