

# Optimal Treatment Strategy for Amyloid A Amyloidosis in Rheumatic Diseases – Anti-Interleukin-6 Receptor Therapy

Yasuaki Okuda

*Department of Internal Medicine,  
Center for Rheumatic Diseases, Dohgo Spa Hospital  
Japan*

## 1. Introduction

Among the complications of inflammatory rheumatic diseases, amyloid A (AA) amyloidosis is one of the most severe because of its poor prognosis. AA amyloidosis commonly affects the kidney and the gastrointestinal tract, and is characterized by various clinical symptoms such as progressive proteinuria and renal dysfunction and failure. Control of the underlying disease, i.e. suppression of serum amyloid A (SAA) levels, is the most critical step in the treatment of AA amyloidosis. An immunosuppressant such as methotrexate, azathioprine, or cyclophosphamide, and moderate doses of prednisolone are commonly used to accomplish this. However, in some active cases, satisfactory suppression of SAA levels cannot be achieved, and the function of the affected organs deteriorates. The prognosis is usually poor for patients in advanced stages of AA amyloidosis. The major causes of death are renal failure and infection. Some retrospective studies and case reports have shown anti-tumor necrosis factor (TNF) therapies to be useful against AA amyloidosis (Elkayam et al., 2002; Fernández-Nebro et al., 2010; Gottenberg et al., 2003; Kuroda et al., 2009; Nakamura et al., 2010). Although treatment with anti-TNF agents does reduce acute-phase reactants such as C-reactive protein (CRP) and SAA in chronic inflammatory diseases, unfortunately complete normalization of such acute-phase proteins is rarely observed.

On the other hand, several case reports and a retrospective comparative study have shown that tocilizumab, an anti-human interleukin-6 (IL-6) receptor monoclonal antibody, has an excellent ability to suppress SAA levels and improve clinical symptoms of AA amyloidosis with marked lasting regression of AA protein deposits (Inoue et al., 2010; Kishida et al., 2011; Nishida et al., 2009; Okuda & Takasugi, 2006; Okuda 2009; Sato et al., 2009; Ubara, 2009). Treatment with tocilizumab could, therefore, represent an important therapeutic strategy for AA amyloidosis secondary to rheumatic diseases.

## 2. Pathogenesis of AA amyloidosis in rheumatic diseases

AA amyloidosis resulting from deposition of AA protein in the extracellular matrices of various organs may lead to multiple organ dysfunction, and the prognosis is usually poor in patients with advanced AA amyloidosis.

Although formerly chronic infections such as tuberculosis were listed as the principal cause of AA amyloidosis, most cases of AA amyloidosis at present are closely associated with chronic inflammatory diseases such as rheumatoid arthritis (RA) (Sasatomi et al., 2007). SAA, the precursor of AA protein, is highly amplified in the liver under the stimulation of inflammation-associated cytokines such as IL-6, TNF, and IL-1 (Yamada, 1999). Prolonged elevation of SAA is the major inciting factor for AA amyloidosis developing in chronic inflammatory diseases. The extensive and persistent production of SAA under chronic active inflammatory conditions is the critical prerequisite for AA amyloidosis fibrillogenesis, and approximately 10–15% of Japanese RA patients have AA amyloidosis deposits in their gastroduodenal mucosa as shown by endoscopic biopsy (Kobayashi et al., 1996).

SAA is genetically polymorphic with four loci (SAA1, SAA2, SAA3, and SAA4) located on chromosome 11 (Yamada, 1999). The SAA gene products SAA1 and SAA2 are both elevated with acute inflammation and are therefore named acute-phase SAA. More than 90% of the precursor proteins of AA protein are derived from SAA1 (Liepnieks et al., 1995). SAA1 has several allelic variants, in which the exon 3 polymorphism generates three common isoforms in the Japanese population: *SAA1.1*:52Valine/57Alanine, *SAA1.3*:52Alanine/57Alanine, and *SAA1.5*:52Alanine/57Valine. It has been suggested that this polymorphism contributes to the susceptibility of the Japanese to RA-associated AA amyloidosis (Baba et al., 1995; Okuda et al., 1999; Moriguchi et al., 1999; Nakamura et al., 2006); *SAA1.3* may be a risk factor for AA amyloidosis, while *SAA1.1* acts as a defense. *SAA1.1*, however, has been reported to be a risk factor in Caucasians (Booth et al., 1998), suggesting a racial difference concerning the contribution of exon 3 polymorphism to the pathogenesis of AA amyloidosis in RA.

In animal model studies, elevated SAA was detected in ageing mice (Hsu et al., 1997), and organ extracts from aged mice had amyloid enhancing factor activity that accelerated experimental SAA production (Yokota et al., 1989). We examined the contributions of ageing to the induction of AA amyloidosis in RA in our large cohort (388 adult-onset RA patients with AA amyloidosis) including 144 patients who been analyzed for SAA1 polymorphism. We identified ageing as an independent risk factor for the formation of AA amyloidosis complicating RA (Okuda et al., 2011). Figure 1 shows the pathogenetic cascade of AA amyloidosis in rheumatic diseases.

### 3. Treatment of AA amyloidosis

The most rational treatment of AA amyloidosis is just to inhibit the production of SAA, the precursor of the AA proteins. As evidence of this, Gillmore et al. (2001) used serum amyloid P (SAP) scintigraphy to evaluate the level of amyloid deposits in organs in patients with AA amyloidosis associated with inflammatory diseases such as RA. They reported that when the SAA concentration in the blood was less than 10 mg/L, the level of amyloid deposits in the organs decreased and the 10 year survival rate was good at about 90%, whereas in patients with SAA levels of 10 mg/L or higher, the 10-year survival rate was about 40%. Maintenance of SAA concentrations within the normal range correlated significantly with reduced amyloid deposition and improved prognosis. The same group investigated 374 patients with AA amyloidosis and performed a more detailed analysis of the very close correlation between decreases in SAA concentration and improved survival prognosis. SAP scintigraphy revealed significant disappearance of AA protein in the low-concentration group compared with that in the high-concentration group. Control of the SAA

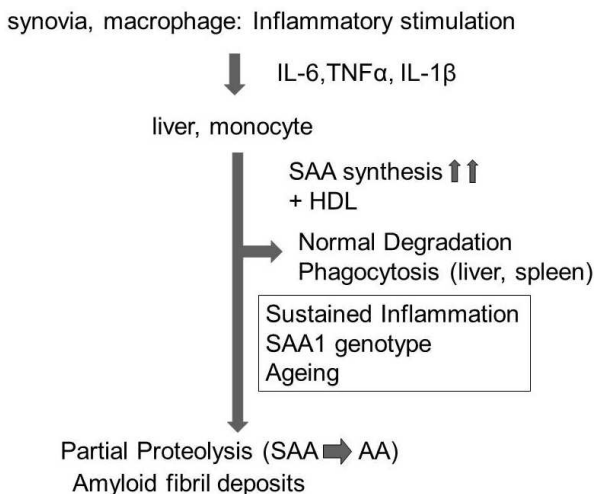


Fig. 1. SAA synthesis and pathogenesis of AA amyloidosis

concentration was stressed as the most important parameter in amyloidosis treatment (Lachmann et al., 2007). Therefore, it is very important to inhibit as much as possible the activity of the underlying disease itself. Rheumatic diseases are the most common underlying diseases of AA amyloidosis, and in the treatment of rheumatic disease patients, biologics show higher efficacy than do conventional treatments and can be used in current routine clinical practice. Anti-cytokine treatment is especially useful but there are certain characteristics and problems involved, which are discussed in detail in the next section. Among other treatments—when immunosuppressants and biologics are not adequate because of problems such as chronic infections or organ damage—there are often cases where moderate doses of corticosteroids (prednisolone 10–20 mg) are necessary. Because rheumatic diseases often affect elderly patients over the long term, complications can include onset of severe infections and thoracic and lumbar vertebral compression fractures due to osteoporosis.

For treatment of AA amyloidosis from a different standpoint, the organic solvent dimethyl sulfoxide (DMSO) is sometimes administered in an attempt to eliminate AA protein by increasing the degree of solubility of amyloid protein deposited in the tissues. Although not proven in controlled comparative studies, several case reports and case series reports suggesting its usefulness have appeared (Ravid et al., 1982, Gruys et al., 2005).

Eprodinate, a mimetic of glycosaminoglycan that serves as the extracellular scaffold for amyloid deposits in tissues, is expected to show therapeutic effects because it prevents accumulation of AA protein. A multicenter randomized double-blind placebo-controlled study was conducted mainly in Europe and the United States. It was reported that the risk of decline of renal function was lowered by 42%; however, no significant differences were found in the risk of decreases in the progression to end-stage renal failure and mortality (Dember et al., 2007). Applications were filed with the FDA, etc. as an orphan drug but they were not approved, and an additional international study is now in progress—International Randomized, Double-Blind, Placebo-Controlled, Phase 3 Study of the Efficacy and Safety of KIACTA™ in Preventing Renal Function Decline in Patients with AA Amyloidosis (Clinical Trials.gov Identifier: NCT01215747).

In the future we can expect to see the adjunctive or monotherapeutic use of biologics in patients who cannot undergo strong immunosuppressant treatment because of complications such as chronic infections.

- **Inhibition of SAA production**
  - Immunosuppressive drugs
  - Biologics: IL-6 , TNF inhibitor
  - Corticosteroids
- **Inhibition of AA aggregation and deposition**
  - Eprodisate (GAG mimic): GAG interaction
- **Amyloid fibril dissolution**
  - Dimethyl sulfoxide

SAA: serum amyloid A; GAG: glycosaminoglycan

Fig. 2. Treatment strategies for AA amyloidosis

#### 4. Treatment of AA amyloidosis with biologics

At present, reports of efficacy in the treatment of AA amyloidosis by biologics have stressed anti-TNF therapy and anti-IL-6 therapy, both of which are anti-cytokine therapies. First, anti-TNF therapy will be explained, and then anti-IL-6 therapy, which is the core topic of this overview, will be explained in detail.

##### 4.1 Anti-TNF therapy

Elkayam et al. (2002) first reported that nephrotic syndrome was rapidly improved using the anti-TNF antibody drug infliximab in patients with AA amyloidosis associated with RA. Thereafter, a multicenter study was performed in France, and Gottenberg et al. (2003) evaluated anti-TNF therapy for renal disorders in 15 patients with AA amyloidosis associated with inflammatory arthritis (10 patients were given infliximab, four were given etanercept, and one was given both agents). They observed decreased proteinuria or elevated glomerular filtration rate in three patients, no progression of renal disorders in five, and worsening or progression of renal dysfunction in seven patients. Anti-TNF therapy was effective in more than half of the patients with renal disorders (Gottenberg et al., 2003). Case reports and case series reports from many facilities then appeared showing the efficacy of this therapy against AA amyloidosis associated with chronic inflammatory diseases such as rheumatic diseases (Bosca et al., 2006; Drewe et al., 2004; Kobak et al., 2007; Smith et al., 2004).

In Japan, the efficacy of anti-TNF therapy has been reported in many papers and reports given at academic society meetings. Kuroda et al. (2009) and Nakamura et al. (2010) reported efficacy in a large number of patients over a short time. Kuroda et al. analyzed therapeutic results in 14 RA patients complicated with AA amyloidosis in whom RA treatment was effective (four were given infliximab and 10 were given etanercept; mean

observation period: 20.1 months). They found that 24-h creatinine clearance improved in three patients, was unchanged in five, and became worse in three. In a 24-h proteinuria assay, three patients showed decreased proteinuria, six were unchanged, and three became worse, indicating that progression of renal disorders was prevented in about 70% of patients. In nine patients subjected to serial gastroduodenal biopsies, the level of amyloid deposits in the tissue was reported to decrease significantly (Kuroda et al., 2009). Nakamura et al. (2010) used etanercept to treat 14 Japanese patients who had the *SAA1.3* allele and high susceptibility to AA amyloidosis (mean observation period: 19 months) and analyzed their renal function profiles. Significant improvements were found in RA disease activity, SAA concentrations, 24-h proteinuria levels, and serum albumin levels. Creatinine was analyzed by grouping patients into those with creatinine levels of less than 2.0 mg/dL at introduction of etanercept and those with creatinine levels of 2.0 mg/dL or higher; no improvement in creatinine levels was reported in the 2.0 mg/dL or higher group. Nakamura et al. (2010) stressed the necessity of introducing etanercept treatment in the early stages of declining renal function.

Fernández-Nebro et al. (2010) conducted a multicenter case-control study of the long-term treatment (mean observation period: 2.9 years) of many patients with an immune-mediated inflammatory disease complicated with AA amyloidosis. They evaluated 36 patients (29 given infliximab and seven given etanercept). A kidney response was observed in 12 of 22 patients (54.5%), kidney progression was observed in 6 of 36 patients (17%), and kidney amyloidosis remained stable in 16 of 36 patients (44%), which were considered good results. However, although proteinuria was significantly improved ( $p < 0.001$ ), serum creatinine levels ( $p = 0.783$ ) and creatinine clearance ( $p = 0.721$ ) showed no significant differences before and after treatment. Significant improvement was found in inflammatory markers, but the normal range was not achieved. The four-year continuation rate of anti-TNF agents was 52%, and no differences from the control group were observed. Severe proteinuria was a risk factor for treatment response and continuation and for survival. The incidences of adverse drug reactions also showed no differences from the control group, but the frequencies of septicemia and severe infections were three times as high. Eight patients in the amyloid group and one in the control group of rheumatic disease patients without AA amyloidosis died, and an increased risk of infections was noted in the amyloid group in terms of safety (Fernández-Nebro et al., 2010).

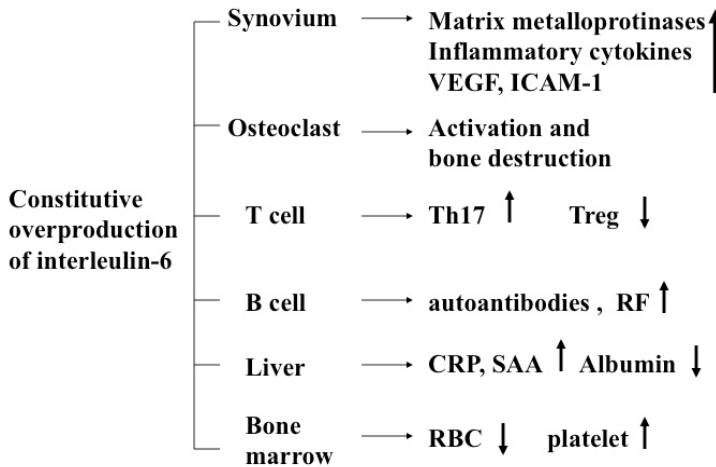
The above reports indicate that anti-TNF therapy is effective in patients with rheumatic diseases complicated with AA amyloidosis, but in patients with progressive renal dysfunction the possibility of irreversible changes is as high as in other chronic renal diseases and the risk of infections increases during the period up to multiple organ failure. Therefore, the utmost caution is necessary after introducing anti-TNF therapy and confirming the reduction in inflammatory markers, showing that the response to the underlying disease treatment is favorable.

## 4.2 Anti-IL-6 therapy

### 4.2.1 IL-6 and the mode of action of tocilizumab

IL-6 has a unique receptor system: although IL-6 receptor (IL-6R) specifically binds to IL-6, it is not directly involved in signal transduction. IL-6 forms a complex by binding to IL-6R on the cell membrane, which then combines with gp130, which also resides on the cell membrane, forming a homodimer and initiating intracellular signal transduction. Furthermore, IL-6R also exists in soluble form. After forming a complex with IL-6, soluble

IL-6R (sIL-6R) can also combine with gp130 on the cell membrane and enable signaling (Ward et al., 1994). sIL-6R is present in the blood of healthy individuals at a concentration of several tens of ng/mL, and if cells express gp130, IL-6 signaling can take place, even in the absence of IL-6R expression on the cell membrane. Reflecting this characteristic, the effects of IL-6 are diverse, and it is thought to have an extensive regulatory role, with involvement in the immune response, inflammation, bone metabolism, hematopoiesis, and the neuroendocrine system (Figure3).



Constitutive overproduction of interleukin-6, a pleiotropic cytokine that regulates the immune system, inflammation, hematopoiesis, and bone metabolism, is thought to play pathologic roles in rheumatic diseases. VEGF: vascular endothelial growth factor; ICAM-1: intercellular adhesion molecule-1; Th17: interleukin-17-producing CD4<sup>+</sup> T cell; Treg: CD4<sup>+</sup>CD25<sup>+</sup> regulatory T cell; RF: rheumatoid factor; CRP: C-reactive protein; SAA: serum amyloid A; RBC: red blood cell

Fig. 3. Pathological roles of interleukin-6 in rheumatic diseases

Tocilizumab is a recombinant monoclonal antibody that has been humanized by complementarity-determining region (CDR) grafting of a murine anti-human IL-6R antibody onto human IgG<sub>1</sub>. Tocilizumab inhibits the induction of IL-6-mediated biological activity in cells that have expressed both membrane-bound IL-6R and gp130 molecules, and also inhibits the induction of biological activity mediated by IL-6/sIL-6R complex formation in cells that express gp130 alone. Furthermore, since tocilizumab has the capacity to dissociate IL-6/IL-6R complexes that have already formed (Mihara et al., 2005), it exhibits an extremely effective blocking action on IL-6 signal transduction (Figure 4).

#### 4.2.2 Pivotal role of IL-6 in SAA synthesis

The signal transduction and transcription mechanisms of TNF-alpha, IL-1-beta, and IL-6 in the production of SAA have become clear. In a study using HepG2 cells, a cell line derived from hepatocytes, weak expression of SAA1 and SAA2 mRNA was induced by stimulation with IL-6 alone, but almost no expression was induced by stimulation with either IL-1-beta or TNF-alpha alone. However, synergistic induction of expression was observed by costimulation with IL-6 and IL-1-beta or with IL-6 and TNF-alpha (Hagihara et al., 2004).

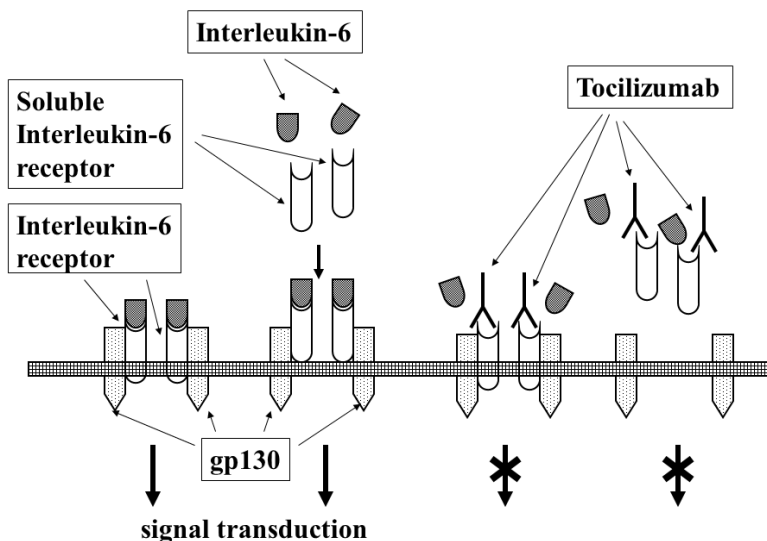


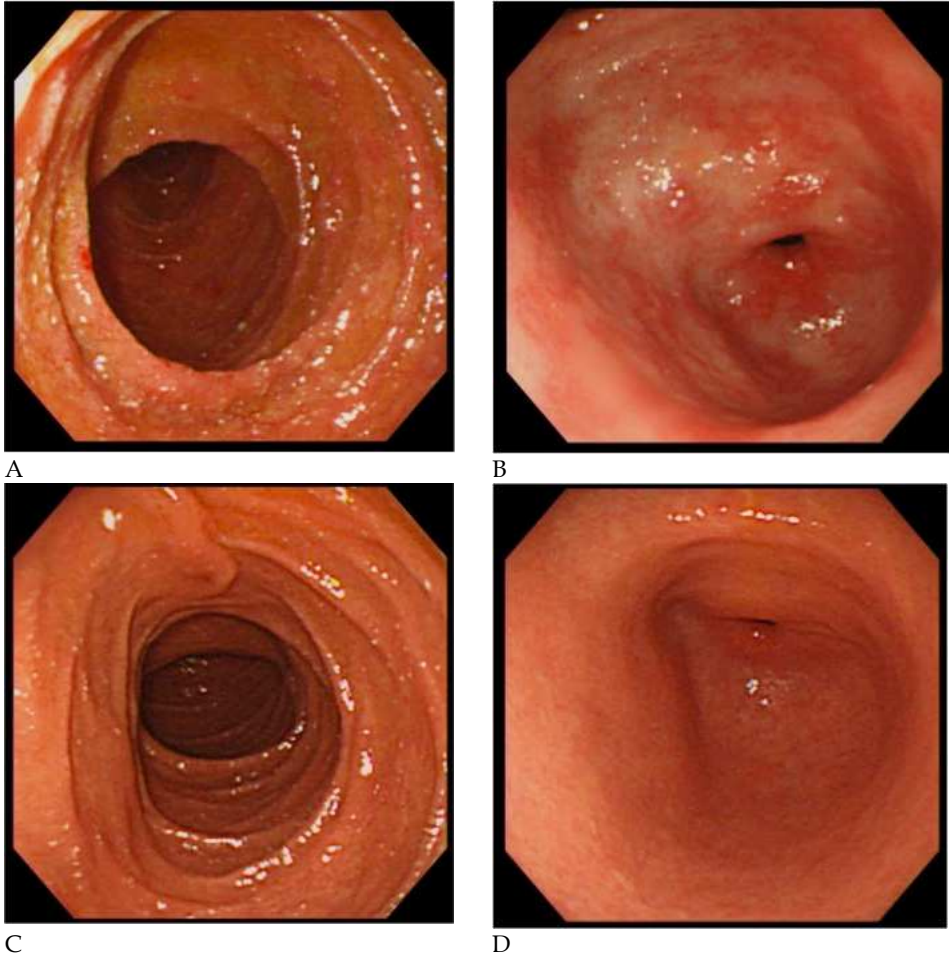
Fig. 4. Signal transduction of the interleukin-6/interleukin-6 receptor complex via gp130 and the mechanism of signal transduction blockade by tocilizumab.

Activation of STAT3 by IL-6 stimulation is essential in the production of SAA, and it is clear that SAA expression is strengthened by supplementation of NF-kappaBp65 activity by stimulation with TNF-alpha or IL-1-beta (Hagihara et al., 2005). Clinically, TNF inhibitors reduce SAA levels, but complete normalization is rare. However, tocilizumab can normalize SAA levels in almost all patients in whom a sufficient concentration of tocilizumab is maintained in the blood.

#### 4.2.3 AA amyloidosis treatment by anti-IL-6 receptor therapy

Tocilizumab, a humanized anti-IL-6 receptor antibody drug, was approved in Japan in 2008 for RA, polyarticular juvenile idiopathic arthritis (JIA), and systemic JIA. At present, tocilizumab is the most effective agent against AA amyloidosis by the mechanism of action based on SAA reduction described above. Almost all patients undergoing anti-IL-6 therapy are those who can maintain tocilizumab blood concentrations, and SAA normalization is possible. In contrast, although it is already clear from routine clinical practice that anti-TNF therapy does decrease SAA, the percentage of patients undergoing anti-TNF therapy who achieve complete normalization is not high. And recently tocilizumab is reported to be very effective in many autoimmune and inflammatory diseases including auto-inflammatory diseases such as TNF receptor associated periodic syndrome which may cause AA amyloidosis (Tanaka, 2011).

Before its approval in 2008, we provided compassionate use of tocilizumab to a patient with life-threatening JIA complicated with rapidly progressing AA amyloidosis in whom many drugs were ineffective. SAA was completely normalized by early administration of tocilizumab, digestive tract symptoms (intractable diarrhea) disappeared, renal symptoms (proteinuria and renal dysfunction) were normalized, and AA protein showed marked disappearance from the tissues. The clinical course and usefulness in this case have been reported (Okuda & Takasugi, 2006) (Figures 5 & 6).

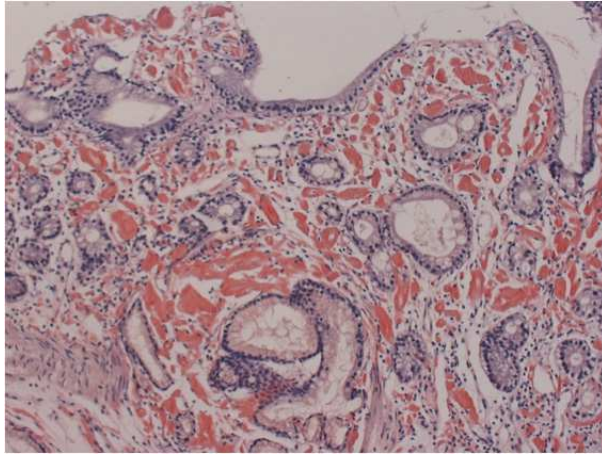


A: Before tocilizumab therapy was started, the appearance of the mucosa in the second portion of the duodenum was coarse, nodular, irregular, edematous, and reddish.  
 B: Before tocilizumab therapy, the appearance of the mucosa in the antrum of the stomach was coarse, with reddish and edematous changes.  
 C and D: After 18 months of tocilizumab therapy, no abnormality was observed in the second portion of the duodenum or in the antrum of the stomach, respectively  
 (Quoted from: Okuda Y, Takasugi K. (2006). Successful use of a humanized anti-interleukin-6 receptor antibody, tocilizumab, to treat amyloid A amyloidosis complicating juvenile idiopathic arthritis. *Arthritis Rheum.* Vol. 54, No. 9, pp. 2997-3000)

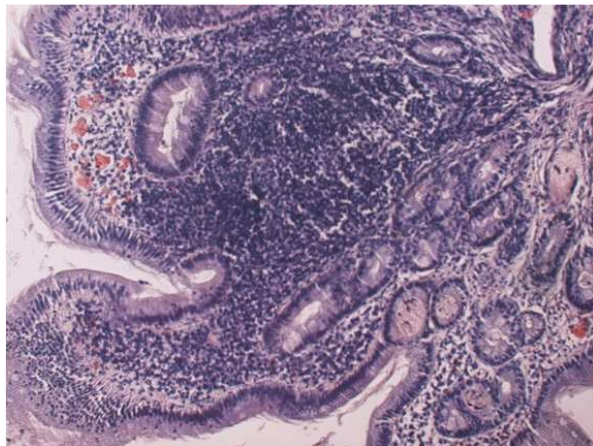
Fig. 5. Results of endoscopic examination before and after tocilizumab therapy (Case 1)

We have also reported that during a clinical study on tocilizumab, in a group of patients with RA complicated with AA amyloidosis, AA protein deposits disappeared from the digestive tract and renal function improved (Okuda, 2009). Figure 7 shows improved histological findings in a patient with RA complicated with AA amyloidosis obtained during the clinical study on tocilizumab. Many papers presented at meetings and case





Massive amyloid A protein deposits were observed in duodenal mucosa and submucosa before the start of tocilizumab therapy.



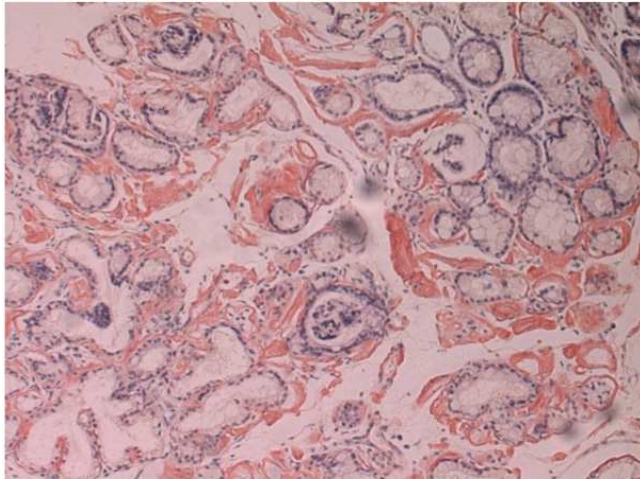
Lower: Marked regression of amyloid A protein deposits was seen in duodenal mucosa and submucosa after tocilizumab treatment. (Congo red stained; 200× magnification)

(Quoted from: Okuda Y, Takasugi K. (2006). Successful use of a humanized anti-interleukin-6 receptor antibody, tocilizumab, to treat amyloid A amyloidosis complicating juvenile idiopathic arthritis. *Arthritis Rheum.* Vol. 54, No. 9, pp. 2997-3000)

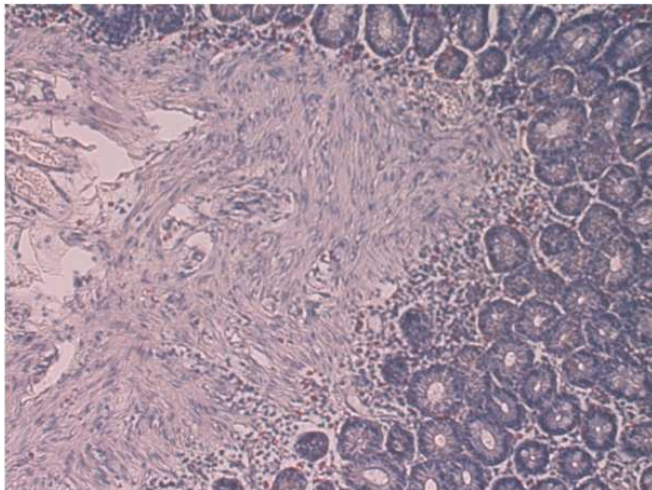
Fig. 6. Results of gastrointestinal biopsy before and after tocilizumab therapy (Case 1)

reports have since appeared suggesting the wide-ranging usefulness of tocilizumab in treating rheumatic diseases complicated with AA amyloidosis (Inoue et al., 2010; Kishida et al., 2011; Sato et al., 2009).

Even in patients that have switched to tocilizumab because of the insufficient effect or lack of effect of anti-TNF agents, it is reported that treatment with tocilizumab has marked effects on gastrointestinal disorders and histology (Nishida et al., 2009) and improves renal dysfunction (Ubara, 2009). Expectations related to the usefulness of tocilizumab are high.



Massive amyloid A protein deposits were observed in duodenal mucosa and submucosa before the start of tocilizumab therapy. (Creatinine: 1.4 mg/dL)



Complete regression of amyloid A protein deposits was seen in duodenal mucosa after 6.5 years of tocilizumab treatment. (Creatinine: 0.85 mg/dL) (Congo red stained; 200× magnification)

Fig. 7. Gastrointestinal biopsy before and after tocilizumab therapy (Case 2)

However, an all-case post-marketing survey for tocilizumab (Koike et al., 2010) found that, among patients with progressive renal disorders with multiple organ failure in whom tocilizumab was used for life-saving purposes, complications such as infections and deaths were reported. Therefore, considerable caution is required when tocilizumab is used. When considered from the standpoint of immunosuppression, it is desirable to use tocilizumab from an earlier stage when the risk of infections is lower, in the same way as anti-TNF therapy. At present, a multicenter investigator-initiated prospective clinical study

comparing clinical and histological improvements in the tocilizumab group with a control group is underway in Japan, and evidence that proves more objectively the usefulness of tocilizumab exceeding that of other drugs is expected.

## 5. Conclusion

Tocilizumab has an excellent ability to suppress SAA levels and improve clinical symptoms of AA amyloidosis with marked lasting regression of AA protein deposits. Treatment with tocilizumab could, therefore, represent an important therapeutic strategy for AA amyloidosis secondary to rheumatic diseases.

## 6. Acknowledgements

This work was supported by a grant from the Amyloidosis Research Committee of the Intractable Disease Division of the Ministry of Health, Labour and Welfare of Japan.

## 7. Key points

AA amyloidosis, tocilizumab, a humanized anti-IL-6 receptor antibody, anti-cytokine therapy, rheumatic diseases, RA, IL- 6, TNF-alpha, SAA

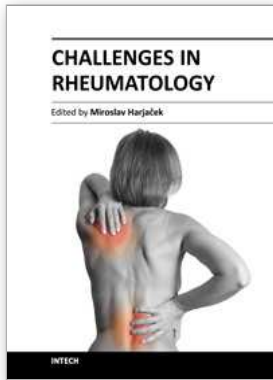
## 8. References

- Baba S, Masago SA, Takahashi T, Kasama T, Sugimura H, Tsugane S, et al. (1995). A novel allelic variant of serum amyloid A, SAA1 $\gamma$ : genomic evidence, evolution, frequency, and implication as a risk factor for reactive systemic AA-amyloidosis. *Hum Mol Genet.* Vol. 4, No. 6, pp. 1083–1087, ISSN 0964-6906
- Booth DR, Booth SE, Gillmore JD, Hawkins PN, Pepys MB. (1998). SAA1 alleles as risk factors in reactive systemic AA amyloidosis. *Amyloid.* Vol. 5, No. 4, pp. 262–265, ISSN 1350-6129
- Boscà MM, Pérez-Baylach CM, Solis MA, Antón R, Mayordomo E, Pons S, et al.. (2006). Secondary amyloidosis in Crohn's disease: treatment with tumor necrosis factor inhibitor. *Gut.* Vol. 55, No. 2, pp. 294–295, ISSN 1468-3288
- Dember LM, Hawkins PN, Hazenberg BP, Gorevic PD, Merlini G, Butrimiene I, et al. (2007). Eprodisate for treatment of renal disease in AA amyloidosis. *N Engl J Med.* Vol. 356, No. 23, pp. 2349–2360, ISSN 0028-4793
- Drewe E, Huggins ML, Morgan AG, Cassidy MJ, Powell RJ. (2004). Treatment of renal amyloidosis with etanercept in tumor necrosis factor receptor-associated periodic syndrome. *Rheumatology (Oxford).* Vol. 43, No. 11, pp. 1405–1408, ISSN 1462-0324
- Elkayam O, Hawkins PN, Lachmann H, Yaron M, Caspi D. (2002). Rapid and complete resolution of proteinuria due to renal amyloidosis in a patient with rheumatoid arthritis treated with infliximab. *Arthritis Rheum.* Vol. 46, No. 10, pp. 2571–2573, ISSN 1529-0131
- Fernández-Nebro A, Olivé A, Castro MC, Varela AH, Riera E, Irigoyen MV, et al. (2010). Long-term TNF-alpha blockade in patients with amyloid A amyloidosis complicating rheumatic diseases. *Am J Med.* Vol. 123, No. 5, pp. 454–461, ISSN 0002-9343

- Gillmore JD, Lovat LB, Persey MR, Pepys MB, Hawkins PN. (2001). Amyloid load and clinical outcome in AA amyloidosis in relation to circulating concentration of serum amyloid A protein. *Lancet*. Vol. 358, No. 9275, pp. 24–29, ISSN 0140-6736
- Gottenberg JE, Merle-Vincent F, Bentaberry F, Allanore Y, Berenbaum F, Fautrel B, et al. (2003). Anti-tumor necrosis  $\alpha$  therapy in fifteen patients with AA amyloidosis secondary to inflammatory arthritides: a followup report of tolerability and efficacy. *Arthritis Rheum*. Vol. 48, No. 7, pp. 2019–2024, ISSN 1529-0131
- Gruys R, Sijens S, Biewenga J. (2005). Dubious effect of dimethylsulphoxide (DMSO) therapy on amyloid deposits and amyloidosis. *VETRINARY RESEACH COMMUNICATIONS*. Vol.5, No. 1, 21-32, ISSN 0165-7380
- Hagihara K, Nishikawa T, Isobe T, Song J, Sugamata Y, Yoshizaki K. (2004). IL-6 plays a critical role in the synergistic induction of human serum amyloid A (SAA) gene when stimulated with proinflammatory cytokines as analyzed with an SAA isoform real-time quantitative RT-PCR assay system. *Biochem Biophys Res Commun*. Vol. 314, No. 2, pp. 363–369, ISSN 0006-291X
- Hagihara K, Nishikawa T, Sugamata Y, Song J, Isobe T, Taga T, et al. (2005). Essential role of STAT3 in cytokine-driven NF-kappaB-mediated serum amyloid A gene expression. *Genes Cells*. Vol. 10, No. 11, pp. 1051–1063, ISSN 1365-2442
- Hsu HC, Zhou T, Yang PA, Herrera GA, Mountz JD. (1997). Increased acute-phase response and renal amyloidosis in aged CD2-fas-transgenic mice. *J Immunol*. Vol. 158. No. 12, pp. 5988–5996, ISSN 0022-1767
- Inoue D, Arima H, Kawanami C, Takiuchi Y, Nagano S, Kimura T, et al. (2010). Excellent therapeutic effect of tocilizumab on intestinal amyloid A deposition secondary to active rheumatoid arthritis. *Clin Rheumatol*. Vol. 29, No. 10, pp. 1195–1197, ISSN 0770-3198
- Kishida D, Okuda Y, Onishi M, Takebayashi M, Matoba K, Jouyama K, et al. (2011). Successful tocilizumab treatment in a patient with adult-onset Still's disease complicated by chronic hepatitis B and amyloid A amyloidosis. *Mod Rheumatol*. Vol. 21, No. 2, pp. 215–218, ISSN 1439-7595
- Koike T, Harigai M, Inokuma S, Ishiguro N, Ryu J, Takeuchi T, et al. (2010) Post-marketing surveillance program of tocilizumab for RA in Japan interim analyses of 3,881 patients. [abstract]. *Arthritis Rheum*. Vol. 62, Suppl. 10, pp. 399 DOI: 10.1002/art.28168
- Kobak S, Oksel F, Kabasakal Y, Doganavsargil E. (2007). Ankylosing spondylitis-related secondary amyloidosis responded well to etanercept: a report of three patients. *Clin Rheumatol*. Vol. 26, No. 12, pp. 2191–2194, ISSN 0770-3198
- Kobayashi H, Tada S, Fuchigami T, Okuda Y, Takasugi K, Matsumoto T, et al. (1996). Secondary amyloidosis in patients with rheumatoid arthritis. diagnostic and prognostic value of gastroduodenal biopsy. *Br J Rheumatol*. Vol. 35, No. 1, pp. 44–49, ISSN 1462-0324
- Kuroda T, Wada Y, Kobayashi D, Murakami S, Sakai T, Hirose S, et al. (2009). Effective anti-TNF- $\alpha$  therapy can induce rapid resolution and sustained decrease of gastroduodenal mucosal amyloid deposits in reactive amyloidosis associated with rheumatoid arthritis. *J Rheumatol*. Vol. 36, No. 11, pp. 2409–2415, ISSN 0315-162X

- Lachmann HJ, Goodman HJ, Gilbertson JA, Gallimore JR, Sabin CA, Gillmore JD, et al. (2007). Natural history and outcome in systemic AA amyloidosis. *N Engl J Med*. Vol. 356, No. 23, pp. 2361-2371, ISSN 0028-4793
- Liepnieks JJ, Kluge-Beckerman B, Benson MD. (1995). Characterization of amyloid A protein in human secondary amyloidosis: the predominant deposition of serum amyloid A1. *Biochim Biophys Acta*. Vol. 1270, No. 1, pp. 81-86, ISSN 0925-4439
- Mihara M, Katsutani K, Okazaki M, Nakamura A, Kawai S, Sugimoto M, et al. (2005). Tocilizumab inhibits signal transduction mediated by both mIL-6R and sIL-6R, but the receptors of other members of IL-6 cytokine family. *Int Immunopharmacol* Vol. 5, No 12, pp. 1731-1740, ISSN 1567-5769
- Moriguchi M, Terai C, Koseki Y, Uesato M, Nakajima A, Inada S, et al. (1999). Influence of genotypes at SAA1 and SAA2 loci on the development and the length of latent period of secondary AA-amyloidosis in patients with rheumatoid arthritis. *Hum Genet*. Vol. 105, No. 4, pp. 360-366, ISSN 0340-6717
- Nakamura T, Higashi S, Tomoda K, Tsukano M, Baba S, Shono M. (2006). Significance of SAA1.3 allele genotype in Japanese patients with amyloidosis secondary to rheumatoid arthritis. *Rheumatology (Oxford)*. Vol. 45, No. 1, pp. 43-49, ISSN 1462-0324
- Nakamura T, Higashi S, Tomoda K, Tsukano M, Shono M. (2010). Etanercept can induce resolution of renal deterioration in patients with amyloid A amyloidosis secondary to rheumatoid arthritis. *Clin Rheumatol*. Vol. 29, No. 12, pp. 1395-1401, ISSN 0770-3198
- Nishida S, Hagihara K, Shima Y, Kawai M, Kuwahara Y, Arimitsu J, et al. (2009). Rapid improvement of AA amyloidosis with humanized anti-interleukin 6 receptor antibody treatment. *Ann Rheum Dis*. Vol. 68, No. 7, pp. 1235-1236, ISSN 0003-4967
- Okuda Y. (2009). Turnover and regression of amyloid A protein deposits in AA amyloidosis complicating rheumatoid arthritis. *Igaku no Ayumi*. Vol. 229. No. 5, pp. 337-340, ISSN 0039-2359 [Article in Japanese]
- Okuda Y, Takasugi K. (2006). Successful use of a humanized anti-interleukin-6 receptor antibody, tocilizumab, to treat amyloid A amyloidosis complicating juvenile idiopathic arthritis. *Arthritis Rheum*. Vol. 54, No. 9, pp. 2997-3000, ISSN 1529-0131
- Okuda Y, Yamada T, Takasugi K, Takeda M, Nanba S, Onishi M, et al. (1999). Serum amyloid A (SAA)1, SAA2 and apolipoprotein E isotype frequencies in rheumatoid arthritis patients with AA amyloidosis. *Ryumachi*. Vol. 39, No. 1, pp. 3-10, ISSN 0300-9157 [Article in Japanese]
- Okuda Y, Yamada T, Matsuura M, Takasugi K, Goto M. (2011). Ageing: a risk factor for amyloid A amyloidosis in rheumatoid arthritis. *Amyloid*. Vol. 18, No. 3, pp. 108-111, ISSN 1350-6129
- Ravid M, Shapira J, Lang R, Kedar I. (1982). Prolonged dimethylsulphoxide treatment in 13 patients with systemic amyloidosis. *Ann Rheum Dis*. Vol. 41, No. 6, pp. 587-592, ISSN 0003-4967
- Sasatomi Y, Sato H, Chiba Y, Abe Y, Takeda S, Ogahara S, et al. (2007). Prognostic factors for renal amyloidosis: a clinicopathological study using cluster analysis. *Intern Med*. Vol. 46, No. 5, pp. 213-219, ISSN 0918-2918
- Sato H, Sakai T, Sugaya T, Otaki Y, Aoki K, Ishii K, et al. (2009). Tocilizumab dramatically ameliorated life-threatening diarrhea due to secondary amyloidosis associated with rheumatoid arthritis. *Clin Rheumatol*. Vol. 28, No. 9, pp. 1113-1116, ISSN 0770-3198

- Smith GR, Tymms KE, Falk M. (2004). Etanercept treatment of renal amyloidosis complicating rheumatoid arthritis. *Intern Med J*. Vol. 34, No. 9-10, pp. 570-572, ISSN 1445-5994
- Tanaka T, Narazaki M, Kishimoto T. (2011). Anti-interleukin-6 receptor antibody, tocilizumab, for the treatment of autoimmune diseases. *FEBS Lett*. DOI: 10.1016/j.febslet.2011.03.023, ISSN 0014-5793
- Ubara Y. (2009). Renal amyloidosis. *Medicina*. Vol. 13, No. 13, pp. 2009-2012, ISSN 0025-7699 [Article in Japanese]
- Ward LD, Howlett GJ, Discolo G, Yasukawa K, Hammacher A, Moritz RL, et al. (1994). High affinity interleukin-6 receptor is a hexameric complex consisting of two molecules each of interleukin-6, interleukin-6 receptor, and gp-130. *J Biol Chem*. Vol. 269, No. 37, pp. 23286-23289, ISSN 0021-9258
- Yamada T. (1999). Serum amyloid A (SAA): a concise review of biology, assay methods and clinical usefulness. *Clin Chem Lab Med*. Vol. 37, No. 4, pp. 381-388, ISSN 1434-6621
- Yokota T, Ishihara T, Kawano H, Takahashi M, Fujinaga Y, Uchino F. (1989). Amyloid enhancing factor (AEF) in the aging mouse. *Virchows Arch A Pathol Anat Histopathol*. Vol. 414, No. 6, pp. 511-514, ISSN 0236-3636



## **Challenges in Rheumatology**

Edited by Dr. Miroslav Harjacek

ISBN 978-953-307-848-9

Hard cover, 190 pages

**Publisher** InTech

**Published online** 22, December, 2011

**Published in print edition** December, 2011

Rheumatology is a subspecialty of medicine that focuses on the biology, cause, diagnosis and the treatment of a variety of musculoskeletal and other systemic diseases. The field of rheumatology is expanding rapidly and several very exciting developments have occurred during the recent years. Firstly, there has been a new dramatic understanding of the nature of inflammation and the possibility of specifically regulating the aberrant immune inflammatory response. Secondly, an understanding of pathogenesis has led to the development of new, more targeted therapies. Challenges in Rheumatology has assembled an impressive group of international experts who have studied specific aspects of certain rheumatic diseases and have extensive experience either in pathophysiology, or with the in-depth diagnosis and/or management of rheumatic patients. They communicate their knowledge and experience to the reader in chapters that are conveniently organized as pathophysiology, clinical manifestations and diagnosis of selected rheumatic diseases, medical and perioperative orthopedic management, and the economic impact of rheumatic diseases. We hope that this book will help trainees become better physicians and scientists, and that it will help practicing rheumatologists to provide better care, and ultimately, improve the quality of life of our patients.

### **How to reference**

In order to correctly reference this scholarly work, feel free to copy and paste the following:

Yasuaki Okuda (2011). Optimal Treatment Strategy for Amyloid A Amyloidosis in Rheumatic Diseases – Anti-Interleukin-6 Receptor Therapy, Challenges in Rheumatology, Dr. Miroslav Harjacek (Ed.), ISBN: 978-953-307-848-9, InTech, Available from: <http://www.intechopen.com/books/challenges-in-rheumatology/optimal-treatment-strategy-for-amyloid-a-amyloidosis-in-rheumatic-diseases-anti-interleukin-6-recept>

**INTECH**  
open science | open minds

### **InTech Europe**

University Campus STeP Ri  
Slavka Krautzeka 83/A  
51000 Rijeka, Croatia  
Phone: +385 (51) 770 447  
Fax: +385 (51) 686 166  
[www.intechopen.com](http://www.intechopen.com)

### **InTech China**

Unit 405, Office Block, Hotel Equatorial Shanghai  
No.65, Yan An Road (West), Shanghai, 200040, China  
中国上海市延安西路65号上海国际贵都大饭店办公楼405单元  
Phone: +86-21-62489820  
Fax: +86-21-62489821

© 2011 The Author(s). Licensee IntechOpen. This is an open access article distributed under the terms of the [Creative Commons Attribution 3.0 License](#), which permits unrestricted use, distribution, and reproduction in any medium, provided the original work is properly cited.