

Juvenile Spondyloarthritis

Miroslav Harjaček¹, Lovro Lamot¹,
Lana Tambić Bukovac¹, Mandica Vidović¹ and Rik Joos²

¹*Division of Rheumatology, Children's Hospital Srebnjak, Zagreb*

²*Division of Rheumatology, University Hospital Gent, Gent*

¹*Croatia*

²*Belgium*

1. Introduction

Spondyloarthritis (SpA) is one of the most common chronic rheumatic diseases, with a prevalence of 0.3% in Western Europe (Braun, Bollow et al. 1998; Andersson Gare 1999; Saraux, Guedes et al. 1999; Fernandez-Sueiro, Alonso et al. 2004). Juvenile spondyloarthritis (jSpA) is a term that refers to a group of inflammatory disorders affecting children under the age of 16 years, with common clinical characteristics, all more or less HLA B27 associated, producing a continuum of clinical symptoms through adulthood. These diseases are characterized by enthesitis and arthritis affecting the joints of the lower extremities and seronegativity for IgM rheumatoid factor and antinuclear antibodies (Amor, Dougados et al. 1990; Dougados, van der Linden et al. 1991; Boyer, Templin et al. 1993; Fink 1995; Cury, Vilar et al. 1997; Petty, Southwood et al. 1998; Burgos-Vargas, Rudwaleit et al. 2002; Petty, Southwood et al. 2004; Heuft-Dorenbosch, Landewe et al. 2007; Colbert 2010). The SpA often begins as 'undifferentiated' disease, the presentation of which differs in children and adults; most notably, spinal involvement is uncommon, while hip arthritis is frequently seen in juvenile-onset disease. The SpA family of diseases includes ankylosing spondylitis (AS), reactive arthritis (ReA), psoriatic arthritis (PsA), arthritis associated with inflammatory bowel disease (IBD), undifferentiated SpA and a juvenile form of SpA. The latter are under ILAR (The International League of Associations for Rheumatology) classification of juvenile idiopathic arthritis (JIA) classified as enthesitis-related arthritis (ERA) or psoriatic arthritis (Petty, Southwood et al. 2004) Possible differences in the synovial immunopathologic features of jSpA, when compared to adult patients with SpA will be discussed. In addition, increasing evidence suggests that an anatomical zone referred to as the enthesitis is a primary target of the pathological process. Genetic and environmental factors play important roles in the pathogenesis of the SpA, and will be discussed extensively. An update on treatment, as well pharmacological and physical therapies, will be made.

2. Epidemiology

The prevalence of spondyloarthritis among whites is estimated at 0.7 to 1.2%, and the female-to-male ratio is 1:2 (Rutkowska-Sak, Slowinska et al. 2010).

Estimates of the prevalence of juvenile SpA, and ERA specifically, are based on figures for juvenile arthritis, which vary considerably depending on geographic location and case definition (Colbert 2010). The worldwide prevalence of juvenile arthritis is reported between 7 and 400 per 100,000 children (0.007% to 0.4%), although the latter figure seems to be an outlier overestimating the number of cases (Manners and Bower 2002). ERA and PsA each comprise 2– 11% of those cases, which would give an estimated combined total of 0.28–88 cases per 100,000 children. Whether these figures include juvenile AS is not clear. The frequency of childhood-onset among AS patients, is estimated between one and nine percent, (Gomez, Raza et al. 1997; Hofer and Southwood 2002). In Croatian children, frequency of jSpA among other rheumatic diseases was 8.2% (Prutki, Tambic Bukovac et al. 2008). These data are similar to the results of American, Canadian and British studies where approximately 7.9 - 9.8 of all children referred to the pediatric rheumatology clinics were children with jSpA (Bowyer and Roettcher 1996; Malleson, Fung et al. 1996; Symmons, Jones et al. 1996). SpA is seen in approximately 20% of first-degree relatives of patients with jSpA (Burgos-Vargas, 2002).

3. Immunopathogenesis

In this section the actual knowledge on immunopathogenesis in SpA is discussed and was possible with referral to juvenile disease.

SpA is a multifactorial disease in which a disturbed interplay occurs between the immune system and environmental factors on a predisposing genetic background. One of the predisposing environmental factors could be bacterial infection. There is a well established association with different enteric pathogens (Schiellerup, Krogfelt et al. 2008) but also with Chlamydia (Gerard, Whittum-Hudson et al. 2010) and Clostridium (Birnbaum, Bartlett et al. 2008). In juvenile patients we found a relationship with *Mycoplasma pneumoniae* infection (Harjacek, Ostojic et al. 2006).

Whether a key role is reserved for the innate immunity or the adaptive immune system or both is still not clear.

3.1 What is the possible role of the adaptive immune system?

Cellular infiltrates in SpA patients are localized at the sacroiliac joints, the synovium and the enthesal structures. The infiltrates are characterized by the presence of both CD4+ and CD8+ T lymphocytes, as well as B cells and macrophages (Saxena, Aggarwal et al. 2005; Singh, Aggarwal et al. 2007; Melis and Elewaut 2009). These infiltrated T cells are activated and require the active participation of costimulation pathways to play their role.

Dendritic cells (DCs) play a key role in discriminating between commensal microorganisms and potentially harmful pathogens as well as in maintaining the balance between tolerance and active immunity (Evans, Suddason et al. 2007). DCs as antigen-presenting cells, induce primary T cell activation. Upon activation, expansion, and maturation effector T helper (Th) cells derive from progenitor, naive CD4+ T cells. Committed CD4+ T cells may differentiate into Th1, Th2, Th 17 phenotypes (the effector Th cell triad), with distinct cytokine products and biological functions. They can also evolve into the inducible regulatory T (Treg) lineage, with immunomodulatory functions.

Treg's are important in the maintenance of immune homeostasis. Defects in Treg function or reduced numbers have been documented in several human autoimmune diseases, including RA and JIA (Nistala and Wedderburn 2009).

In patients with undifferentiated spondyloarthritis (e.g. ERA) the number of peripheral blood Th1, Th2, Th17, and Treg cells were found unchanged, but Th1 and Th17 cells were increased, and Th2 cells were reduced in the synovial fluid (SF) compared to blood. It appears that elevated levels of pro-inflammatory cytokines IL-1 and IL-6 in the SF may be responsible for increased Th17 cells in those patients (Mahendra, Misra et al. 2009).

3.2 What is the possible role of the innate immune system?

Accumulating evidence suggests that the majority of the IL-17 released in SpA arthritis is produced by innate immune cells rather than T cells, suggesting that the innate immune pathway might be of greater relevance than the Th17 mediated adaptive immune response in those patients (see below) (Appel, Maier et al. 2011).

In juvenile arthritis some differences in cytokine profile were noted compared to adults:

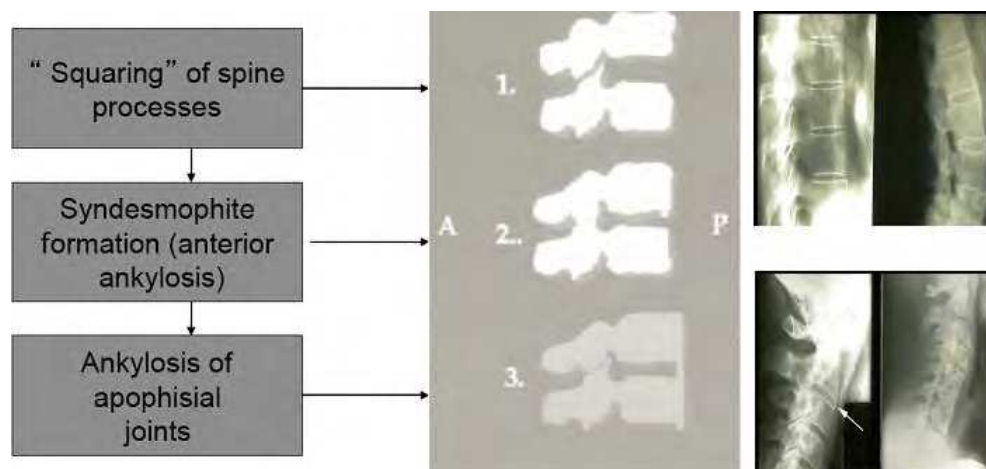
- SF levels of IL-1ss and IL-12p40 are increased in both Poly-JIA and ERA as compared to RA;
- IL-6 levels were higher in ERA compared to RA;
- the increase in IFN-g in children with ERA with undetectable IL-4 suggests a Th1-dominant immune response in this disease subset;
- additive or even synergistic effects with IL-1 and TNF-alpha in inducing cytokine expression and joint damage have been shown in vitro and in vivo;
- ERA patients with an antigen-specific response to pathogenic enteric bacteria had a higher ratio of SF/blood integrin, (CD103+) Treg's compared to those with no antigen-specific response. In those patients antigen-specific as well as mitogen-stimulated cytokine production showed a clear Th1 bias (Saxena, Misra et al. 2006).

Microbes initiate immune responses through Toll-like receptors (TLRs). TLRs are membrane-bound and frontline guardians in the human innate immune system. They primarily function to recognize pathogen-associated molecular patterns (PAMPs) of invading microorganisms, and on activation mount rapid, nonspecific innate responses and trigger sequential delayed specific adaptive cellular responses, which are mediated by complex signal transduction pathways involving adaptor molecules, costimulatory ligands and receptors, kinases, transcription factors, and modulated gene expression (Drexler and Foxwell 2010). Toll-like receptor 4 (TLR4) is a member of the Toll-like receptor family, and activation of the TLR4 signalling pathway may induce the release of proinflammatory cytokines such as tumour necrosis factor (TNF)-alpha and interleukin (IL)-12, which was considered to play an important role in pathogenesis of SpA. Serum TLR4 protein and mRNA levels, as well as *TLR-4* gene expression were found to be significantly higher in AS patients than in healthy controls (Yang, Liang et al. 2007; Assassi, Reveille et al. 2011). A bacterial trigger possibly causes disease exacerbation in ERA patients. A recent study has shown that increased TLR-2 and TLR-4 expression on PBMCs and SFMCs may recognize microbial/endogenous ligands and up-regulate IL-6 and MMP-3 leading to disease exacerbation (Myles and Aggarwal 2011).

3.3 Cartilage and bone destruction and bone remodeling

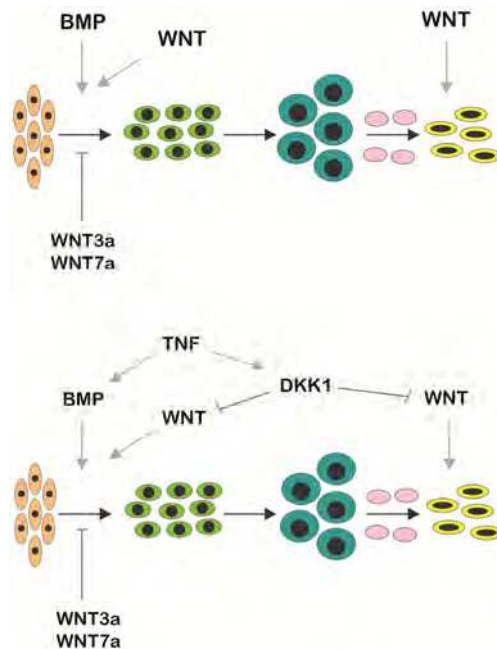
In chronic synovitis, cartilage and bone destruction occur as a consequence of synovial inflammation. Bone remodeling is a lifelong continuous process conducted by osteoblasts, synthesizing bone matrix, and its resorption by osteoclasts. Important regulators of osteoclast recruitment and function are the three key molecules Osteoprotegerin (OPG),

Receptor Activator of Nuclear factor κ B (RANK) and its ligand (RANKL). RANKL stimulates osteoclast production and survival via the membrane-bound receptor RANK, while OPG inhibits osteoclast differentiation and activation due to its function as a non-signaling decoy receptor for RANKL (Simonet, Lacey et al. 1997). The physiological balance between RANKL and OPG is regulated by various calcitropic cytokines and hormones, and alterations in their ratio are critical in the pathogenesis of bone diseases (Hofbauer and Schoppet 2004). Osteoblasts and T cells are important producer cells of RANKL. An inflammatory environment with T-cell activation may tilt the balance between OPG and RANKL and increase osteoclast activation and bone resorption. In SF of children ERA patients elevated soluble RANKL (sRANKL), reduced OPG levels, and elevated sRANKL/OPG ratio was found, resulting in an environment associated with bone loss (Schett 2009). Furthermore, ERA patients had a lower matrix metalloproteinase (MMP) level as well as a lower MMP/TIMP (tissue metalloproteinase inhibitors) ratio compared to poly JIA, which may partly explain the lesser degree of joint damage seen in ERA, as compared to poly JIA (Agarwal, Misra et al. 2009). In AS, a chronic and most severe form of SpA inflammation is associated with trabecular bone loss leading to osteoporosis, but also with cortical new bone formation (e.g. formation of bone spurs, such as syndesmophytes and enthesiophytes) leading to progressive ankylosis of the spine and sacroiliac joints. Excessive bone formation in AS leads to ankylosis of joints and poor physical function (Figure 1). This results in an apparent paradox of bone formation and loss taking place at sites closely located to each other. Osteoporosis can be explained by the impact of inflammation on the bone remodeling cycle. In contrast, new bone formation has been linked to aberrant activation of bone morphogenic protein (BMP) and Wnt-type like (WNT) signaling. (Figure 1 and Figure 2) (Lories, Derese et al. 2005; Lories, Luyten et al. 2009; Carter and Lories 2011). By contrast, tumor necrosis factor (TNF) does not appear to be the direct trigger for osteophyte formation in AS (Schett and Rudwaleit 2010).



1. "Squaring" of spine processes; 2. Syndesmophyte formation (*anterior ankylosis*); 3. Ankylosis of apophysial joints.

Fig. 1. The evolution of spine changes in jSpA patients with corresponding X-rays.



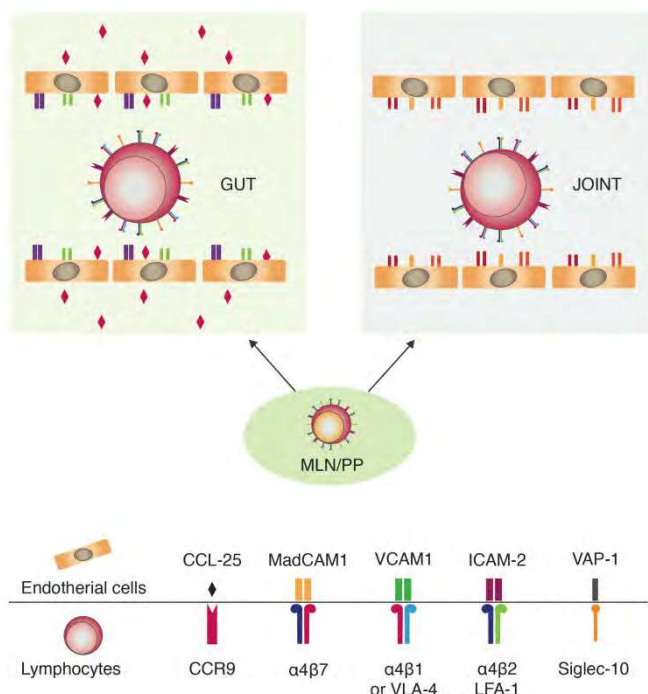
(a) Physiological endochondral bone formation is stimulated by bone morphogenetic proteins (BMPs). Wingless-type like (WNT) signaling plays a supportive role in relation to BMPs. However, some WNTs have a negative effect on early chondrocyte differentiation. (b) In the presence of inflammation, tumor necrosis factor (TNF) may stimulate BMP signaling but also the expression of DKK1, which acts a WNT antagonist. The balance between TNF, BMP and WNT signaling may determine the onset and progression of ankylosis. DKK, dickkopf. (Adapted from *Arthritis Res Ther.* 2009; 11(2): 221. Published online 2009 April 27. doi: 10.1186/ar2642.)

Fig. 2. Roles of BMPs and WNTs in ankylosis

3.4 Subclinical gut inflammation

Subclinical gut inflammation has been demonstrated in patients with all forms of SpA (Mielants, De Vos et al. 1996). In addition, several lines of evidence indicate that SpA may originate from the relocation to the joints of the immune process primarily induced in the gut (Fantini, Pallone et al. 2009). The transfer of the intestinal inflammatory process into the joints implicates that immune cells activated in the gut-draining lymph nodes can localize, at a certain point of the intestinal disease, either into the gut or into the joints. This is indicated by the overlapping expression of adhesion molecules observed on the surface of intestinal and synovial endothelial cells during inflammation. T cells activated in the Peyer's patches and mesenteric lymph nodes express the gut-addressing integrin $\alpha 4/\beta 7$ and the chemokine receptor CCR9 (Campbell and Butcher 2002). Once activated, these cells reach the bloodstream through the efferent lymphatic's and the thoracic duct. In the gut mucosa, the interaction between $\alpha 4/\beta 7$ integrin and its ligand, the mucosal addressin cell adhesion molecule 1 (MadCAM-1) expressed on the venular endothelial sheet (Berlin, Berg et al. 1993; Berlin, Bargatze et al. 1995) causes the initial rolling and subsequent arrest of activated T cells. MadCAM-1 is normally expressed on the intestinal mucosa and its expression is

further enhanced during inflammation (Souza, Elia et al. 1999; Salmi and Jalkanen 2001). Once arrested on the surface of the intestinal venules, activated T cells transmigrate through the endothelial layer and move into the lamina propria following the gradient formed by the CCR-9-specific ligand CCL-25 (Johansson-Lindbom, Svensson et al. 2003; Stenstad, Ericsson et al. 2006). Therefore, the specific interaction between $\alpha 4/\beta 7$ integrin with MadCAM-1, and CCR9 with CCL-25 is pivotal for T cell homing into the gut. However it is worth noting that other molecules mediate the cell-to-cell interaction in this process. For instance CD44, the very late antigen-4 (VLA-4, $\alpha 4\beta 1$) and the lymphocyte function associated antigen-1 (LFA-1, $\alpha L\beta 2$) expressed by activated T cells play a role in the recruitment of T cells into the gut (Salmi and Jalkanen 1998). (Figure 3).



CCR9: Chemokine receptor-9; CCL-25: Chemokine ligand 25; MadCAM1: Mucosal addressin cell-adhesion molecule-1; VCAM1: Vascular cell adhesion molecule-1; ICAM: intracellular adhesion molecule; VLA-4: Very late antigen-4; LFA-1: Lymphocyte function associated antigen-1; VAP-1: Vascular adhesion protein-1 (adapted modified from Fantini, Pallone et al. 2009, Kivi, Elima et al. 2009; Aalto, Autio et al. 2011)

Fig. 3. The heterogeneous expression of adhesion molecules allows T cells activated in the gut to home into joints.

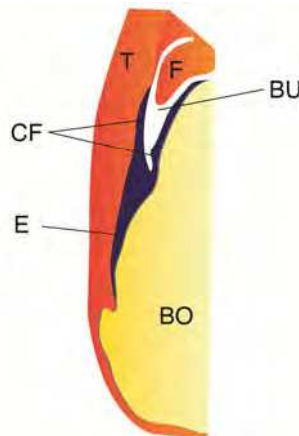
Conti *et al* (Conti, Borrelli et al. 2005) investigated a group of 129 children for suspected inflammatory bowel disease (IBD), 31 of whom had signs of axial and/or peripheral arthropathy, and after ileo-colonoscopy with biopsy, 7 children had classic IBD, 12 had indeterminate colitis, and 12 had lymphoid nodular hyperplasia of the distal ileum as the main feature. All children were HLA-B27 negative. These patients may be a population at

risk of developing a full IBD phenotype. A recent study has shown that active Treg cell response, mainly dominated by IL-10 production, occurs in the gut of AS patients and is probably responsible for the absence of a clear Th17 polarization in the ileum of AS patients. Interestingly, a 5-fold increase in the proportion of Treg cells was observed in the gut of patients with AS, as compared to healthy subjects, with 70-80% of these cells also producing IL-10 (Ciccia, Accardo-Palumbo et al. 2010).

4. Histopathology

4.1 Enthesitis

Enthesitis is a distinctive pathological feature of spondyloarthritis and may involve synovial joints, cartilaginous joints, syndesmoses and extra-articular entheses (Benjamin and McGonagle 2007). This has traditionally been viewed as a focal abnormality, even though the inflammatory reaction intrinsic to enthesitis may be quite extensive. Entheses together with adjacent tissues may form mini organs, dubbed "enthesis organs or complex". According to this scenario the enthesis fibrocartilages that occupy a location adjacent to synovium (in joint or bursae or tendons) are dependent on the synovium for lubrication, oxygenation and removal of microdebris. The enthesis insertion being itself fibrocartilagenous is avascular, and does not have a resident population of macrophages. Therefore derangements in the enthesis would be expected to trigger an inflammatory response in the adjacent vascular synovium (Braun, Khan et al. 2000) (Figure 4).



It consists of the enthesis itself (E), two complementary fibrocartilages (CF), an intervening bursa (BU) and a pad of synovium-covered protruding fat (F). The complementary fibrocartilages line the deep surface of the tendon (T) and cover the adjacent bone (BO) and protect these surfaces from compression when the foot is dorsiflexed. The bursa allows free movement of tendon relative to bone and the fat pad acts as a 'variable plunger' to prevent pressure changes from occurring in the bursa as the foot changes position. (adapted from (McGonagle and Benjamin 2009).

Fig. 4. A diagrammatic representation of an enthesis organ, modeled on that of the Achilles tendon.

This means that pathology related to the enthesis could trigger synovitis. Indeed, normal entheses are riddled with microdamage in aged subjects; this can be associated with

microscopic synovitis, including villus formation and microscopic inflammatory cell infiltration in the immediately adjacent synovium, which is conceptualized in relationship to a synovio-entheseal complex (Braun, Khan et al. 2000). In man, there is an anatomical, biomechanical and temporal uncoupling between the inflammatory phase of disease and new bone formation and it appears that the bone formation follows on from the inflammation and may be a distinct phase.

4.2 Synovitis

Synovitis in juvenile SpA is characterized by marked lining layer hyperplasia, clear hypervascularity, and pronounced inflammatory cell infiltration with lymphocytes and macrophages, independent of disease duration or time of sampling. Despite some similarities with adult SpA, the findings with regard to lining layer hyperplasia and CD163+ macrophage (defined by the expression of the group B scavenger receptor CD163) infiltration are indicative of important differences in the synovial immunopathologic features of juvenile-onset SpA. The partial overlap with other JIA subtypes, with the exception of slightly lower vascularity in juvenile polyarthritis and higher inflammatory cell infiltration in juvenile oligoarthritis, emphasizes the need for further biologic characterization of JIA in order to define pathophysiologic, rather than phenotypic, subgroups (Kruithof, Van den Bossche et al. 2006). It is of interest that resident tissue macrophages, PMNs, and lining layer thickness, did correlate with global disease activity in adult SpA, and that changes in expression of synovial macrophage subsets, PMNs, and MMP-3 clearly reflected response to treatment (Kruithof, De Rycke et al. 2006).

5. Genetics

5.1 MHC genes

The central genetic factor recognized in SpA is the major histocompatibility complex (MHC) (Figure 5). While the risk for specific HLA allele in SpA may vary from one population group to another, the association of HLA-B27, and SpA has been well known for over 30 years. The HLA-B27 represents a family of 38 closely related cell surface proteins (encoded by the alleles HLA-B*2701-39) called subtypes of HLA-B27, most of which have evolved from the ubiquitous HLA-B*2705 (specifically the B*27052 allele) (Reveille and Maganti 2009). More recently, similar role for the HLA-B-7 has been proposed (Reynolds and Khan 1988; Cedoz, Wendling et al. 1995). Both antigens display significant levels of polymorphism, and the region of amino acid positions 63-71 in HLA-B27 appears to participate in the formation of at least three distinct epitopes shared by B27 and B7 identified as ME1, GSP5.3 and GS145.2, respectively (el-Zaatari, Sams et al. 1990; el-Zaatari and Taurog 1992). The proportion of B27-positive patients in the different SpA forms decreases from 95% in primary AS; to 70–80% in ReA; 50% in PsA and IBD with sacroiliitis/spondylitis, and to 0–10% in undifferentiated SpA. Findings of human family studies of twins and sibpairs support the notion that genetic factors other than B27 determine which B27-positive individuals develop arthritis. In Croatian patients with jSpA we have shown that the odds ratio (OR) for HLA-B*07 was 2.61, while the highest OR for a single HLA specificity was found for HLA-B*27 (OR=5.60). The HLA-B*07/B*27 combination found in 6/74 children showed higher risk (OR=14.82), but the combination of specificities: HLA-B*07/HLA-B*27, and D6S273-134 microsatellite locus, located in the HSP70-2 region, demonstrated the highest risk (OR=26.83) (Table 1.) (Harjacek, Margetic et

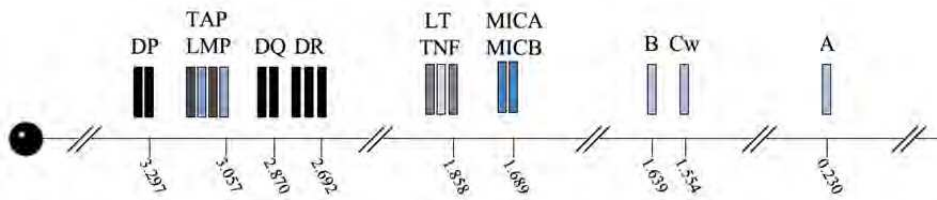


Fig. 5. HLA region on chromosome 6.

MARKER	OR	CI (95%)
B*07	2.61	1.40 - 4.87
B*27	5.69	2.93 - 11.06
D6S273-134	2.68	1.37 - 4.33
B*07; D6S273-134	2.72	1.34 - 5.53
B*27; D6S273-134	8.57	3.44 - 21.38
B*07/B*27	14.82	1.75 - 125.45
B*07/ B*27; D6S273-134	26.83	N/A*

OR – odds ratio; CI-confidence interval; * Not calculated due to the zero cell in table (Harjacek, Margetic et al. 2008).

Table 1. The odds ratio (OR) of 74 Croatian jSpA patients conferred by selected alleles alone or in combination.

al. 2008). During the genome-wide scan with polymorphic microsatellites, in addition to HLA-B27, D6S273 microsatellite locus was found to be highly relevant (LOD 3.8, $p < 0.00001$) in patients with AS (Brown, Pile et al. 1998).

Some recent progress has been made in understanding how B27 alleles confer such susceptibility, but the mechanism(s) continues to remain largely unknown, and may require new experimental approaches, and are beyond the scope of this review (Colbert, DeLay et al. 2010) (van der Heijde and Maksymowych 2010). B27-transgenic animals develop arthritis, and this directly involves B27 in the development of the disease (Khare, Bull et al. 1998). However, backcross studies in animal models of SpA suggest that multiple genes contribute to disease susceptibility (Laval, Timms et al. 2001; Brown, Brophy et al. 2003; Adarichev and Glant 2006). It is well known that the majority of SpA patients do not carry any of the known susceptibility HLA alleles. Furthermore, findings of human family studies in twins and sib pairs support the notion that genetic factors other than B27 determine which B27-positive individuals develop arthritis (Tsuchiya, Shiota et al. 1998; Brophy, Hickey et al. 2004).

5.2 Non MHC genes

There is little definitive knowledge about non- MHC in SpA. The ultimate goal in the mapping of diseases to particular genes is to isolate and clone the disease-causing gene itself. To clone such a gene successfully, it is necessary to map the disease gene to a very small region, which can be difficult in the case of complex diseases. In fact, it may require

analyzing several hundreds or even several thousands of individuals (affected and unaffected) to detect the genes that are involved in SpA. Global gene expression profiling is a molecular technique that measures in parallel genome-wide expression of thousands of genes in a sample of cells. Genome scanning using SNP's (Single nucleotide polymorphisms) has been carried out to identify regions of the genome that show evidence of linkage to SpA outside the MHC (Sharma, Choi et al. 2009; Vegvari, Szabo et al. 2009; Reveille, Sims et al. 2010) (Table 2). In adult SpA, many other regions and genes have been implicated in candidate gene or linkage mapping studies, but will not be reviewed in depth here. In one large study SNP'S were used in JIA patients (n = 1,054); subtype specific association of the *eraP1* gene (endoplasmic reticulum aminopeptidase 1) with ERA JIA, and the *IL23R* gene with juvenile-onset psoriatic arthritis (jPsA), were found (Hinks, Martin et al. 2011). *eraP1* encodes a multifunctional aminopeptidase, but its role in the pathogenesis in any of the associated diseases has yet to be determined. It may play a role in trimming peptides, in the endoplasmic reticulum, for binding to HLA class I molecules where they are transported to the cell surface for presentation to T cells. Alternatively it may be important through its function in cleaving pro-inflammatory cytokine receptors, such as tumor necrosis factor receptor 1 (TNFR1) to generate soluble TNFR1. It is also thought to play a role in the cleavage of interleukin 1 receptor 2 (IL1R2) and interleukin 6 receptor alpha (IL6R α), leading to increased soluble IL1R2 and IL6R α (Haroon and Inman 2010).

GENE:	Name of gene:
IL-1 β locus	Interleukin 1 beta
MMP	Matrix metalloproteinases
CASP1	Caspase 1
IL18	Interleukin 18
IL10R	Interleukin 10 receptor
TLR-4	Toll-like receptor 4
RGS1*	Regulator of G-protein signaling
eraP1	Endoplasmic reticulum aminopeptidase 1
IL23R	Interleukin 23 receptor
IL1R2	Interleukin 1 receptor, type II
ANTXR2**	Anthrax toxin receptor 2

Adapted from: (Gu, Wei et al. 2009; Sharma, Choi et al. 2009; Vegvari, Szabo et al. 2009; Haroon and Inman 2010; Reveille, Sims et al. 2010; Hinks, Martin et al. 2011).

Table 2. The list of genes found by genome-wide expression profiling in SpA patients using SNP's (with exception of RGS1 that was found in undifferentiated SpA all other genes were identified in AS patients).

Studies of gene expression with the use of DNA microarray technologies offers a novel approach to determining pathogenesis of disease. In two pediatric studies, ability of microarray-based methods (Affymetrix platform) to identify genes with disease-specific expression patterns in peripheral blood mononuclear cells (PBMC) and synovial fluid mononuclear cells (SFMC) of JIA patients (including ERA patients), and healthy controls

was used. When compared to healthy controls, they found relevant gene expression in JAK/STAT cascade and chemokine pathway, lower levels of angiostatic CXCL10 chemokine, higher levels of ELR⁺ angiogenic chemokines and VEGF (vascular endothelial growth factor) in ERA PBMC, and decreased adult hemoglobin gene expression (Barnes, Aronow et al. 2004). They concluded that expression analysis identified differentially expressed genes in PBMCs obtained early in the disease from patients with different subtypes of JIA and in healthy controls, providing evidence of immunobiologic differences between these forms of childhood arthritis (Barnes, Grom et al. 2009). Our preliminary data have shown that jSpA patients exhibit complex patterns of gene expression for functions related to inflammatory and defense response, MAP kinase and cell cycle, chromatin modulation and transcription, cell death, apoptosis, and interestingly, gene closely linked to autoinflammatory diseases (NLRP3) (Harjacek M. 2010).

However, one should be cautious because microarray analysis produces vast amounts of data that can be analyzed and interpreted in many different ways.

6. Classification

Classifying juvenile spondyloarthritis is a “work in progress” and clearly problematic (Burgos-Vargas 2002; Colbert 2010). Since the recognition in 1982 by Rosenberg and Petty of the seronegative enthesopathy and arthropathy (SEA) syndrome (Rosenberg and Petty 1982) many attempts have been made to classify JSpA or SpA like diseases in children. The International League of Associations for Rheumatology (ILAR) Taskforce on Classification of Childhood Arthritis included the category of enthesitis-related arthritis (ERA) in the 1995 classification of juvenile idiopathic arthritis (JIA) (Fink 1995; Petty, Southwood et al. 1998) among the seven subgroups of juvenile arthritides. However when psoriasis, or dactylitis and nail pits along with arthritis are present, these children are excluded from ERA and may be classified as psoriatic arthritis or even undifferentiated arthritis (Burgos-Vargas, Rudwaleit et al. 2002; Colbert 2010). The classification criteria for ERA are excluding psoriatic arthritis (PsA), while reactive arthritis is not even mentioned. Moreover IBD is only maintained as a descriptor of the disease (Burgos-Vargas 2002). So, quite early in the discussion this led to several propositions for revision (Fantini 2001; Manners, Lesslie et al. 2003).

Another set of criteria for spondyloarthritis was developed by the European Spondyloarthropathy Study Group (ESSG) (Dougados, van der Linden et al. 1991). The ESSG criteria have been validated in children, but the emphasis on inflammatory spinal pain is problematic because such a symptom is uncommon in children in the first five years of disease (Prutki, Tambic Bukovac et al. 2008). Also, their sensitivity, positive predictive value and accuracy are lower than in adults (Prieur 1990). This classification includes PsA, ReA, IBD arthropathies as part of the SpA group and ranks the two most important characteristics of adult-onset SpA - inflammatory spinal pain and synovitis as major criteria. Since spinal pain is a less common feature at the onset of the disease in younger children, these criteria may be limited in children with jSpA.

Amor and coworkers (Amor, Dougados et al. 1990) also developed criteria for the classification of spondyloarthritis in adults that could be applicable in children, but like ESSG classification have lower sensitivity in childhood. According to Amor the features of spondyloarthropathy are associated with points, and if six or more points are present the diagnosis of SpA is confirmed.

A recent study showed that Garmisch-Partenkirchen criteria have the highest sensitivity and proposed them for identifying spondyloarthritis in juvenile patients (Hafner 1987; Joos, Dehoorne et al. 2009). According to these criteria probable spondyloarthritis is considered if two major criteria or major criterion one or two plus two minor criteria are present.

SpA usually begins in children as an undifferentiated form of the disease: a peripheral asymmetric oligoarthritis predominantly involving the lower limbs and/or with peripheral enthesitis and/or with dactylitis, and progress to differentiated forms over time (Colbert 2010). Most of these children could be classified as undifferentiated SpA (uSpA) according to the Amor (Amor, Dougados et al. 1990) and the ESSG criteria (Dougados, van der Linden et al. 1991).

Children with the SEA syndrome or with ERA are at risk of developing the other manifestations of the B27 associated disease process including axial involvement. In 1989, Burgos-Vargas and Clark reported that 75% of their Mexican patients with the SEA syndrome met the New York criteria for ankylosing spondylitis (AS) after 5 years of disease (Burgos-Vargas and Clark 1989).

Experts from the Assessment of Spondyloarthritis International Society (ASAS), recently developed definition criteria for inflammatory back pain (IBP), which is an important clinical symptom in adult patients with SpA (Sieper, van der Heijde et al. 2009). In addition, although revisions to the ILAR criteria have addressed some weaknesses Burgos-Vargas, R., M. Rudwaleit, et al. (2002; (Duffy, Colbert et al. 2005) several problems remain, some of which might have been exaggerated by the recent development of criteria that identify pre-radiographic 'axial SpA' in adults. (Rudwaleit, Landewe et al. 2009; Rudwaleit, van der Heijde et al. 2009). To best of our knowledge, these criteria are still not validated in children.

Different classification criteria for SpA are shown in Table 3.

ESSG criteria (Dougados, van der Linden et al. 1991)
Inflammatory low back pain
OR Synovitis asymmetrical or predominantly of the lower limbs
AND at least one of the following criteria: familial history of spondyloarthropathy, uveitis or inflammatory bowel disease; psoriasis, inflammatory bowel disease, enthesopathy, radiological sacroiliitis
AMOR criteria (Amor, Dougados et al. 1991)
A. Clinical signs or history of:
1. nocturnal pain lumbar or dorsal and/or morning stiffness (1 point);
2. asymmetrical oligoarthritis (2 point);
3. Indefinite buttock pain or alternating buttock pain (1 or 2 point);
4. Sausage finger or toe (2 point);
5. heel pain or any other enthesopathy (2 point)
6. iritis (2 point);
7. non gonococcal urethritis or cervicitis within one month before the onset of the arthritis (1 point);
8. Diarrhea within one month before the onset of the arthritis (1 point);
9. Presence or history of psoriasis, and/or balanitis and/or chronic enterocolopathy (2 points).
B. Radiological signs:
10. Sacroiliitis (stage 2 ≥ if bilateral, or stage ≥ 3 if unilateral) (3 points)
C. Genetics:
11. Presence of HLA B27 and/or familial history of ankylosing spondylitis and/or Reiter's syndrome and/or psoriasis and/or uveitis and/or chronic enterocolopathy (2 points)
D. Reaction to treatment:
12. Improvement of pain within 48 hours by NSAIDs or relapse within 48 hours after stop of NSAIDs (2 points)

A spondyloarthropathy is declared in a patient having a score equal of greater than 6 as sum of the points on the 12 criteria.

SEA syndrome (Rosenberg and Petty 1982)

SERONEGATIVITY = absence of RF and ANA

ENTHESOPATHY = tendonitis of the Achilles tendon, fascia plantaris or quadriceps tendon

ARTHROPATHY = inflammatory arthritis of the axial skeleton or oligoarthropathy

ERA (Durban criteria) (Petty, Southwood et al. 1998)

Arthritis OR Enthesitis

PLUS two or more of the following:

A. Sacroiliac joint tenderness AND/OR inflammatory spinal pain;

B. Presence of HLA-B27;

C. Family history involving one or more first or second degree relatives with an HLA-B27 related disease, confirmed by a physician;

D. Anterior uveitis (typically with pain, redness and/or photophobia);

E. Onset of arthritis in a boy > 8 years of age

AND none of the following:

A. Presence of psoriasis in a first or second degree relative, confirmed by a dermatologist;

B. Presence of a systemic arthritis.

Atypical spondyloarthritis in children (Hussein, Abdul-Khaliq et al. 1989)

MAJOR CRITERIA:

1. SA or oligoarthritits in family;

2. enthesopathy;

3. Arthritis of digital joints;

4. Sacroiliitis;

5. HLA B27 positive;

6. Recurrent arthritis or arthralgia.

MINOR CRITERIA:

1. Begin after age od 10 years

2. Male sex;

3. Only lower extremities affected;

4. Acute iridocyclitis or conjunctivitis;

5. Arthritis of hips;

6. Begin following unproven enteritis.

Atypical spondyloarthritis was considered as probable when three major and two minor criteria were present.

Juvenile spondarthritis (Garmisch-Partenkirchen criteria) (Hafner 1987)

MAJOR CRITERIA:

1. Asymmetrical oligoarthritits with involvement of hip, knee or ankle joint;

2. Enthesopathy;

3. Pain of the lumbar spine or sacroiliac region;

4. acute idirocyclitis.

MINOR CRITERIA:

1. Peripheral arthritis of 5 or more joints;

2. Male sex;

3, Disease inset after the age of 6 years;

4. HLA B27 positivity;

5. (Suspicion of) spondarthritis in family history

Probable spondarthritis was considered if two major criteria or major criterion one or two plus two minor criteria were present.

ILAR = International League of Associations for Rheumatology; JIA = Juvenile Idiopathic Arthritis;

ERA = Enthesitis related arthritis; ESSG = European Spondyloarthropathy Study Group;

Table 3. Classification criteria for spondyloarthritis.

None of the criteria evaluated above are perfect for the classification of JSpA. However, the Garmisch-Partenkirchen criteria are the major candidates for future research in identifying spondyloarthritis in juvenile patients (Kasapcopur, Demirli et al. 2005; Joos, Dehoorne et al. 2009).

7. Clinical manifestations

In this section we will try to give an overview of the different characteristics of the diseases. The authors consider several subforms of jSpA:

1. Reactive arthritis: resulting from an infection or inflammation on a distant location of the arthritis. It is merely an acute phenomenon, possibly relapsing and in a part of the patients evolving chronically.
2. Undifferentiated SpA: a chronic form of asymmetrical oligoarthritis, affecting the lower limbs, often accompanied by entheitis and a number of extra-articular manifestations.
3. Juvenile ankylosing spondylitis: affecting preferentially the axial skeleton and can be considered as a clear precursor to the adult ankylosing spondylitis.
4. Juvenile psoriatic arthritis.
5. Inflammatory bowel disease-related arthritis
6. Juvenile ankylosing tarsitis
7. Clavicular cortical hyperostosis

These forms are discussed extensively below.

7.1 Reactive arthritis (ReA)

- a. **Reactive arthritis (ReA)** comprises a number of diseases following infection or inflammation on a distant location in the body. The term is usually restricted to HLA-B27 associated disease triggered in about 80% of patient by arthritogenic bacteria such as *Salmonella*, *Yersinia*, *Shigella*, and *Campylobacter*. *Mycoplasma pneumonia* and *Chlamydia pneumonia* are less frequently responsible for the disease. Primary infection, regardless of the triggering agent, may be completely asymptomatic or with mild symptoms, and it usually precedes arthritis onset up to four weeks.

Reactive arthritis commonly involves joints (knees, ankles) and entheses of the lower limbs. It can also affect temporomandibular joints and the cervical spine (Arabshahi, Baskin et al. 2007). It is marked with severe pain and swelling, sometimes with erythema over the affected joints, rarely with only mild symptoms. ReA following *Salmonella* or *Yersinia* infection sometimes presents with polyarthritis that affects small joints of the hands. Arthralgias may precede the onset of arthritis.

Extra-articular manifestations of ReA include conjunctivitis, anterior uveitis, balanopostitis, urethritis, cervicitis (occurring more frequently in adolescent age with sexually acquired ReA caused by *Chlamydia*), aphthous stomatitis, diarrhea (as part of a generalized mucositis), erythema nodosum (particularly in *Yersinia* triggered ReA), and keratoderma blenorrhagicum (which clinically and histologically resembles psoriasis)

- b. If arthritis, conjunctivitis and urethritis are present as a triad, reactive arthritis might be referred to as **Reiter's syndrome**.
- c. A number of children, particularly those with HLA-B27, develop a **chronic course**, and may even develop AS (Leirisalo, Skylyv et al. 1982; Hussein 1987; Artamonov, Akhmadi et al. 1991; Cuttica, Scheines et al. 1992; Yli-Kerttula, Tertti et al. 1995; Leirisalo-Repo,

Helenius et al. 1997; Leirisalo-Repo 1998). Children without HLA-B27 who have ReA, particularly when the disease is triggered by *Yersinia* or *Campylobacter*, usually have a rather short and benign course.

Diagnosis of ReA in children has usually been made in patients developing arthritis after a specific episode of infection, or those having positive serological tests against bacteria (Cassidy and Petty 2001). However, diagnostic tests (serology, PCR, etc.) may identify the etiologic agent in about 50% of the cases depending on the clinical picture and tests selected (Fendler, Laitko et al. 2001; Sieper, Rudwaleit et al. 2002). On the other hand, bacterial DNA has been identified in synovial fluid cells of patients with long-standing juvenile onset AS or undifferentiated SpA (Pacheco-Tena, Alvarado De La Barrera et al. 2001). In this sense, ReA constitutes a link rather than exclusion to ERA and SpA.

- d. **Poststreptococcal reactive arthritis (PSRA)** has been proposed as a homogeneous clinical entity, distinct from acute rheumatic fever (ARF) and from other forms of reactive arthritis. However, available literature at present supports the idea that PSRA is in reality a heterogeneous group of clinical entities, some of which share clinical features with ARF and others with HLA B27-related spondyloarthritis. The assumed causal role of streptococcal infection is far from proven. Joint involvement is typically non-migratory and affects the large joints, particularly those of the lower limb. Mono, oligo and polyarthritis are equally represented (Moorthy, Gaur et al. 2009). The published data support the possibility, however, that there may be a subset of patients with PSRA who are HLA-B27-positive and are more likely to develop sacroiliitis (Mackie and Keat 2004). Elevated antistreptolysin titers may support but not definitely diagnose a poststreptococcal complication. The more specific and expensive antibody tests may be warranted, including antihyaluronidase, antideoxyribonuclease B, and antistreptokinase antibodies. American Heart Association, and the Red Book of the AAP suggest that antibiotic prophylaxis be given to all proven PSRA patients for 1 year, and if no carditis is observed, then prophylaxis should be discontinued. Moreover, physicians should be aware that antibiotic therapy might prevent the development of an antibody response (Barash, Mashiach et al. 2008).

7.2 Undifferentiated spondyloarthritis (ERA)

The onset of ERA is usually insidious and characterized by intermittent musculoskeletal pain and stiffness or inflammation of peripheral joints, mostly of the lower limbs, with enthesitis at one or more sites around the knee or foot. Axial skeleton symptoms are not common at the disease onset, but might become manifest in the later course (Burgos-Vargas 2002).

Arthritis and enthesitis are the hallmark of jSpA. Peripheral joint involvement at onset is present in over 80% of these patients, while inflammatory spinal pain in only 20-25%. This is one of the major differences between adult- and juvenile-onset spondyloarthritis. In most patients arthritis is either unilateral or asymmetrical oligoarthritis at onset. Distal joints of lower extremities (knee, ankle, tarsus) are affected more frequently than proximal joints. Polyarthritis is not common at disease onset and its distribution is generally asymmetrical (Burgos-Vargas 2002). At this stage of the disease it is difficult to differentiate jSpA from other forms of juvenile arthritides.

The sites of attachment of ligament, tendon, fascia or joint capsule to bone are characteristic sites of inflammation in the jSpA. In contrast to arthritis its specificity and diagnostic value

are much more significant in jSpA. Enthesitis is frequently associated with tenosynovitis and bursitis, particularly of the foot, where arthritis also occurs. Foot enthesitis, including tarsal and calcaneal entheses (Achilles' tendon, plantar fascia), is the most common sign of jSpA and one of the most disabling conditions in these children. Its clinical manifestation is pain on standing and walking, and foot swelling, pressure tenderness at the insertion of tendons and ligaments to bone. Soft tissue swelling is the result of inflammation of tendon sheets and adjacent bursae. Enthesitis in the later course of the disease varies from rare episodes of active inflammation of one or few entheses to frequent recurrence of inflammation involving many sites, particularly the feet. Persistent enthesitis is associated with bone edema and overgrowth, cartilaginous proliferation, bone bridging and ankylosis. Subcortical bone cysts and erosions at tendon insertions are rare.

The severity, duration and consequences of arthritis and enthesitis may not parallel each other throughout the clinical course of the disease.

The most common extraarticular manifestation of ERA is uveitis, while mucositis, skin disease (excluding psoriasis), or cardiopulmonary and nervous system disease happens occasionally.

Uveitis in ERA is characterized by redness and pain in the eye with photophobia. It is usually unilateral, frequently recurrent and rarely leaves ocular residua. The occurrence of uveitis in children with ERA is less than 20% (lower incidence than in adults), but longer follow-ups reveal higher figures (Packham and Hall 2002; Petty, Smith et al. 2003).

Musculoskeletal examination should be focused on entheses, peripheral joints and axial skeleton including joints of the pelvis, spine and chest.

Marked localized tenderness on the patella at 2-, 6-, and 10-o'clock positions (Figure 6A), at the tibial tuberosity, at the attachment of the Achilles tendon (Figure 6B) or plantar fascia to the calcaneus (Figure 6C), at the attachment of the plantar fascia to the base of the fifth metatarsal (Figure 6C), and at the heads of the metatarsal bones (Figure 6C) suggests enthesitis. Tenderness as the sign of enthesitis is rarely demonstrable at the great trochanter of the femur, superior anterior iliac spine and iliac crest, pubic symphysis, ischial tuberosity, costochondral junctions, and entheses of the upper extremities. Walking on the toes and heels usually demonstrates altered weight bearing as the patient avoids pressure on inflamed entheses.

Peripheral joints in ERA are commonly affected asymmetrically and predominantly involve the lower limbs. Unilateral hip involvement is more likely to be a manifestation of ERA than the presenting feature of other forms of JIA. Knee involvement is often present both in ERA and oligoarticular JIA, but the child's age and sex, as well as the presence of HLA-B27, could be helpful in distinguishing the diagnosis. Small joint involvement of the foot and toes, especially intertarsal joints (tarsitis) may be characteristic of ERA, while polyarthritis with the involvement of small joints of the hands suggests another type of JIA (Berntson, Damgard et al. 2008).

Axial skeleton involvement is rarely present in the younger age and in the early stage of the disease. However, it is one of the major manifestations in the later course of ERA. Pain by direct pressure over one or both sacroiliac joints, compression of the pelvis, or distraction of the sacroiliac joints by Patrick test (Faber test) highly suggests sacroiliac inflammation. Lower back pain is usually present and associated with morning stiffness. Abnormalities in spine contour, such as reduction in the normal lumbar lordosis, exaggeration of the thoracic kyphosis, or increased occiput-to-wall distance can be revealed by simple inspection of the back. Restriction of hyperextension or inclination, loss of the normal curve in the lower part

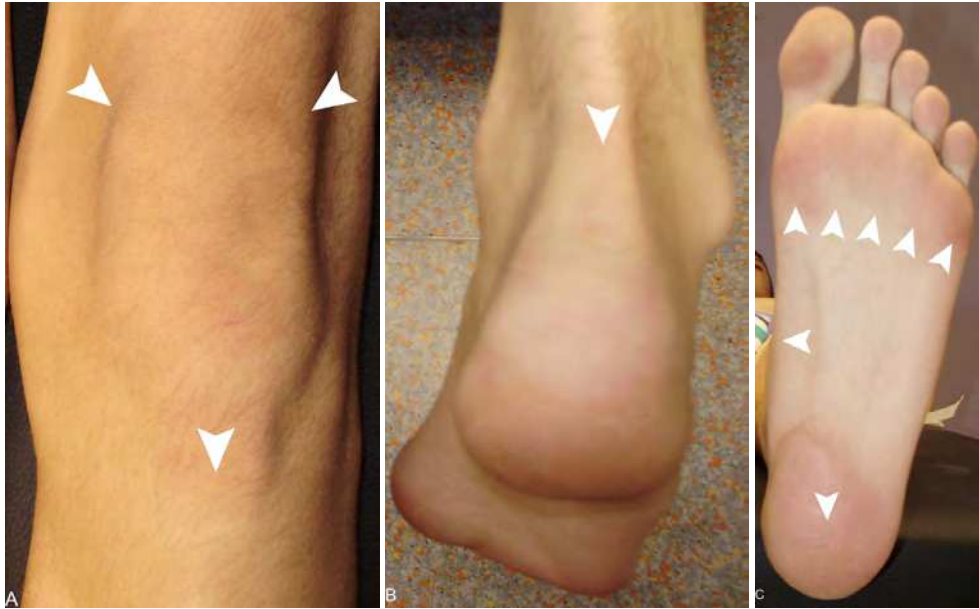


Fig. 6. A, Arrows indicate the most common sites of tenderness associated with enthesitis at the insertion of the quadriceps muscles into the patella and the attachments of the patellar ligament to the patella and tibial tuberosity. B, Arrow indicates the site of tenderness at the insertion of the Achilles tendon into the calcaneus. C, Arrows indicate the most common sites of tenderness associated with enthesitis at the insertion of the plantar fascia into calcaneus, base of the fifth metatarsal, and heads of the first through fifth metatarsals. Swelling in this area is best visualized by having the child lie prone on the examining table with the feet over the edge.

of thoracolumbar spine in the full forward flexion position is the usual sign of axial involvement. The rigid spine or cervical spine involvement are not common in children, especially in the early stage. The modified Schober test is a good tool for documenting thoracolumbar mobility. It is easily performed (Figure 7) and sequential measurements provide a useful parameter in the disease follow-up. With the child standing with the feet together, a line joining the iliac crests is used as a landmark for the lumbosacral junction. A mark is made 5 cm below (point A) and 10 cm above (point B) the lumbosacral joint. With the patient in maximal forward flexion with the knees straight, the increase in distance between points A and B is used as an indicator of lumbosacral joint mobility. In general, a distance less than 6 cm is regarded as abnormal. Measurement of the distance from the fingertips to the floor on maximal forward flexion is also used for quantification of spinal motion but it is poorly reproducible and does not correlate with Schober test. This measurement reflects hip flexion disturbances as well as back flexion. Nevertheless, because of lower height, measuring spine mobility with Schober test is potentially difficult in younger children.

Sequential measurements of thoracic excursions may be useful in documenting progressive loss of range. Since normal thoracic motion varies a lot depending on the age and sex of the patient, a single measurement is not useful. However, any chest excursion of less than 5 cm

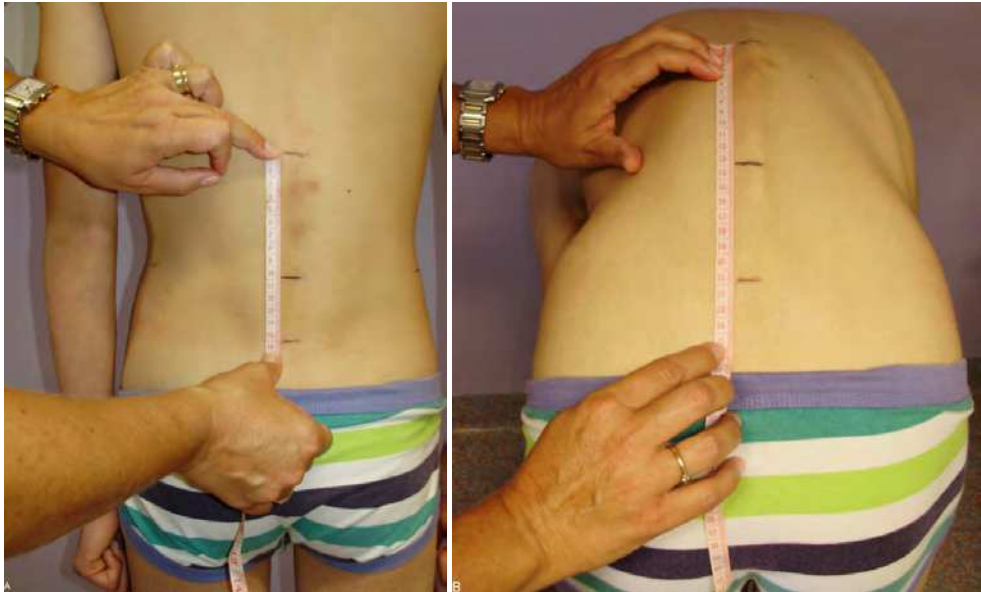

Fig. 7. Schober test. A, Measurement 10cm above and 5cm below the lumbosacral junction (the dimples of Venus) in the upright position. B, Measurement of the distance between the upper and the lower marks when the child is bending forward.

(maximum expiration and maximum inspiration measured at the fourth intercostal space) in the adolescent should be considered as abnormal (Burgos-Vargas, Castelazo-Duarte et al. 1993). In the late development of the disease it may be restricted to 1 or 2 cm, even in the absence of symptoms.

Pain and tenderness at costosternal and costovertebral joints, as well as sternoclavicular joints are often present, rarely at sternomanubrial junction and may be elicited by firm palpation.

Arthritis characteristics in the later course of jSpA are variable. Enteric bacteria may have a role in the exacerbation of disease in patients with ERA, implying that ERA could be a form of chronic reactive arthritis (Saxena, Misra et al. 2006). HLA-B27 negative patients usually have fewer episodes of arthritis and less symptoms of axial disease. HLA-B27 positive disease is associated with more severe and more frequent episodes of active oligoarthritis or polyarthritis, sacroillitis and axial involvement often. It also predicts evolution to ankylosing spondylitis (AS) (Leirisalo, Skylv et al. 1982; Leirisalo-Repo 1998).

The long-term follow-up of children with HLA-B27 who have JIA reveals that between 18,5% and 75% develop spondyloarthritis (Burgos-Vargas, Pacheco-Tena et al. 2002).

7.3 Juvenile-onset ankylosing spondylitis (jAS)

Juvenile-onset ankylosing spondylitis (jAS) is a definite form of jSpA characterized by inflammation of the sacroiliac and vertebral joints leading to stiffening of the spine.

Back pain is common in young people with one year prevalence rates varying from 7% to 58% (Smith 2007). Low back pain (LBP) in childhood and adolescence is a significant risk factor for LBP in adulthood (Jones and Macfarlane 2005; Hestbaek, Leboeuf-Yde et al. 2006).

However, most cases of back pain are non-specific and self-limiting. A recent prospective study of 73 children under age 18 years, with back pain of greater than 3 months duration found only 21% of the patients with positive findings after diagnostic evaluation or a minimum of 2 years follow-up. Spondylolysis with or without spondylolisthesis was the most common diagnosis (Bhatia, Chow et al. 2008).

Children with jAS may present with back or buttock pain, but the typical history of morning stiffness, gradual resolution of pain with activity and clinical exam findings of limited lumbar mobility (Figure 7, Figure 8), sacroiliac joint tenderness and peripheral enthesitis or arthritis, usually allow the practitioner to make the correct diagnosis (Cassidy and Petty 2006).

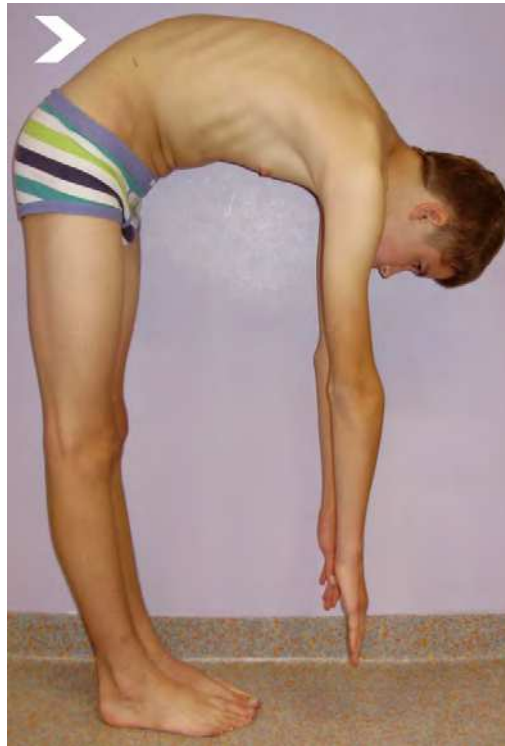

Fig. 8. Boy shown in the position of maximal forward flexion. Note the flattened back (arrow).

Inflammation in the caudal region of the sacroiliac joint is one of the earliest features of spinal disease in AS. Often this begins on the iliac side of the joint and then involves the sacral side as inflammation progresses (Bollow, Hermann et al. 2005). Frank erosions become evident, but may not appear for months to years after inflammation has begun. Sclerosis occurs and is often progressive, eventually resulting in fusion of the joint (Colbert 2010).

There is a less common subgroup of adult-like juvenile onset AS that is called genuine jAS, in which patients develop clinical and radiographic evidence of disease affecting the axial skeleton earlier than children progressing from SEA syndrome to AS. Seronegative enthesitis and arthritis (SEA) syndrome comprises the combination of enthesitis and arthritis, and

probably represents the early stage of jAS or ERA. Most patients with persistent arthritis and enthesitis, who are HLA-B27 positive, develop ankylosing spondylitis five to ten years after initial symptoms. (Burgos-Vargas, Vazquez-Mellado et al. 1996).

jAS differs from adult-onset AS in clinical features at onset, presenting with higher prevalence of peripheral joint involvement and lower prevalence of axial disease. In contrast to adults, spinal pain in children does not seem to improve with movement. The prevalence of HLA-B27 is similar in both groups (Lin, Liang et al. 2009).

Although the pattern of peripheral arthritis and enthesitis is similar to that of other jSpA, jAS is characterized by persistent axial involvement. Enthesitis is usually more severe and episodes last for a longer period of time. During the initial period of six months most patients have oligoarthritis possibly evolving into polyarthritis by the end of the first year.

Axial symptoms first appear in the lumbar and thoracic spine, and less frequently in the cervical spine and sacroiliac joints.

Fever, weight loss, muscle weakness and atrophy, fatigue, lymphadenopathy, leukocytosis and anemia may be present in up to 10% of patients with JAS. Cardiovascular and nervous system manifestations are rare, although radiculopathy may be present in the late course of the disease. Interestingly, up to 80% of patients with jAS might have nonspecific intestinal bowel disease (Mielants, Veys et al. 1993).

7.4 Juvenile-onset psoriatic arthritis (jPsA)

According to the ILAR criteria, jPsA represents approximately 7% of patients with JIA. It is defined as arthritis with onset before the 16th birthday that lasts for at least 6 weeks, and is associated either with psoriasis or two of the following: dactylitis, nail pitting, onycholysis, or psoriasis in a first-degree relative (Cassidy and Petty 2001). ILAR criteria exclude the diagnosis of jPsA in patients with positive rheumatoid factor, HLA-B27 positive boys over the age of 6 years, or patients with a first-degree family history of HLA-B27 associated disease. In our opinion, the majority of jPsA patients fits under the jSpA umbrella and only a minority of patients will belong to other subtypes of PsA as seen in children or adults (Mease 2011; Stoll and Punaro 2011).

While the disease can have a variable presentation (especially in a younger child), in general, 50% of patients will have arthritis at disease onset, 40% will have psoriasis, and 10% of patients will have a coincidence of arthritis and skin changes. Dactylitis is common in both groups (20% to 40% of patients with jPsA), and refers to swelling within a digit that extends beyond the joints, giving the typical "sausage-like" appearance. Index finger and second toe are most commonly affected. Axial disease in jPsA is milder than in jAS, the cervical spine being involved more than other spinal segments, with a tendency for asymmetric sacroiliac joint involvement and a failure to progress to spinal ankylosis. The latter patients are frequently associated with HLA-B27 antigen. Enthesitis is prevalent in the older onset subgroup of patients with jPsA, which is similar to the patients with adult PsA. Severe skin and nail disease is rare in children with arthritis. Most children have mild psoriatic skin lesions in the capilitium, retroauricular, umbilical and intergluteal regions, extensor surfaces of the extremities, and slight nail pitting or onycholysis. Most patients with skin disease have psoriasis vulgaris (80%), 30% have guttata, and a minority of 2% have pustular psoriasis (Burgos-Vargas 2002). The severity of the skin lesions does not usually parallel the severity of arthritis. Systemic manifestations are rare and reflect chronic inflammation: fever, loss of appetite, anemia, growth retardation, and very rarely pericarditis, inflammatory bowel disease, or amyloidosis.

In contrast, patients with early-onset jPsA bear similarities to early-onset oligoarticular and polyarticular JIA patients, including female preponderance and antinuclear antibody (ANA) positivity. The majority of those patients will have oligoarthritis or polyarthritis of the upper and lower extremities (Stoll, Zurakowski et al. 2006; Stoll and Punaro 2011). Psoriasis and adult PsA are strongly associated with HLA-Cw*0602 HLA-B38, and non-MHC genes *psors 1* and *psors 2*, but HLA associations in jPsA are inconsistent, probably due to great variability within jPsA across the pediatric age spectrum (Stoll and Punaro 2011). Other extra-articular manifestations include uveitis in about 15% of patients. The uveitis in psoriatic patients is heterogeneous in its aspect. Sometimes it resembles the acute anterior uveitis and is associated with the HLA B27 antigen, in other patients however it evolves as a chronic posterior and even panuveitis and needs regular ophthalmologic work out as well as preventive controls for relapse.

7.5 Inflammatory bowel disease-related arthritis (IBD)

Crohn's disease (CD) and ulcerative colitis (UC) are two major IBD associated with arthropathies. Peripheral or axial arthritis are the most common extraintestinal manifestations of these diseases, and are present in 7% to 21% of children with IBD, more frequently in UC than in CD (Burgos-Vargas 2002; Jose, Garnett et al. 2009). CD involves the mucosa and regional lymphatics of the colon, distal ileum and other segments of the intestinal tract, with characteristic noncaseating granulomas. UC is a diffuse inflammatory bowel disease with characteristic crypt abscesses in the colonic mucosa. Approximately one third of patients with CD and about 15% of those with UC have onset before the age of 20 years (Burbige, Huang et al. 1975; Hamilton, Bruce et al. 1979).

Initial gastrointestinal symptoms are cramping abdominal pain, often with localized tenderness, diarrhea, loss of appetite to anorexia, sometimes fever. Bloody diarrhea is more suggestive of UC, while perianal skin tags and fistulae are typical for CD. Gastrointestinal symptoms usually precede joint disease by months or even years and rarely they coincide.

Arthritis mostly affects peripheral joints with predominance on lower extremities (knees and ankles). Episodes of acute peripheral arthritis usually last not more than two weeks and rarely cause joint damage or functional loss. Axial disease and sacroillitis are rare, and association with HLA-B27 is common in the older age-onset patients with juvenile CD or juvenile UC.

Subclinical gut inflammation ("low-grade-IBD") is very common in jSpA and occurs in up to 80% of patients, and destructive arthritis of small joints is more common in biopsy proven "low-grade-IBD" children (Mielants, Veys et al. 1987). Peripheral arthritis (mono or oligo) improves with colectomy (disease control), but axial disease shows little improvement.

Erythema nodosum is commonly associated with IBD. Reddish, painful, nodular lesions usually occur in the pretibial region and persist for several weeks, recurring in crops sometimes for several months. Articular involvement often accompanies exacerbations of erythema nodosum.

Painful oral ulcerations could be a part of the initial clinical presentation, especially in CD, and should not be misdiagnosed as Behcet disease.

Children with IBD may also have asymptomatic uveitis.

7.6 Ankylosing tarsitis (AT)

Ankylosing tarsitis represents a set of clinical and radiological manifestations originally described in patients with HLA-B27 positive jSpA, and include inflammation from the ankle

to the metatarsophalangeal joints (synovitis, enthesitis, tenosynovitis, bursitis), followed by proliferative changes that finally lead to the fusion of tarsal bones) (Burgos-Vargas, Pacheco-Tena et al. 2002; Alvarez-Madrid, Merino et al. 2009)

Clinical features are usually midfoot swelling, swelling around the malleoli, Achilles tendon and plantar region of the feet, with decreased mobility of tarsal, ankle and metatarsophalangeal joints. The condition has a variety of radiologic features, which include osteopenia of the tarsal bones at the beginning, with the progression to erosions, osseous proliferation at enthesis, bone cysts, joint space narrowing and finally ankylosis.

Ankylosing tarsitis may occur in patients with undifferentiated jSpA, but it can also be a part of the clinical manifestations in children with jAS. There are some differences between children diagnosed with jSpA initially affected with tarsitis and those without it. It can be often misdiagnosed as soft tissue infection at the beginning of disease (Alvarez-Madrid, Merino et al. 2009).

7.7 Clavicular cortical hyperostosis (CCH)

Clavicular cortical hyperostosis (CCH) is characterized by unilateral sterno-clavicular swelling (Figure 9). Some authors described it as a variant of chronic recurrent multifocal osteomyelitis (CRMO) (Girschick, Krauspe et al. 1998), and some as a sternoclavicular syndrome (Kalke, Perera et al. 2001). Histopathology is characterized by osteitis, hyperostosis and bone edema, without signs of microorganisms, or evidence of CRMO features. Some patients have jSpA features, and some are HLA-B27 positive. In adults, it is associated with spondyloarthritis, but the possible association to jSpA is not well established. Our preliminary data of the gene expression profiling study of patients with CCH and jSpA showed significant concordance in expression of genes linked to autoinflammatory (TLR-4, PTPN12) and autoimmune diseases (STAT3, CD36) (Harjacek, Lamot et al. 2011).

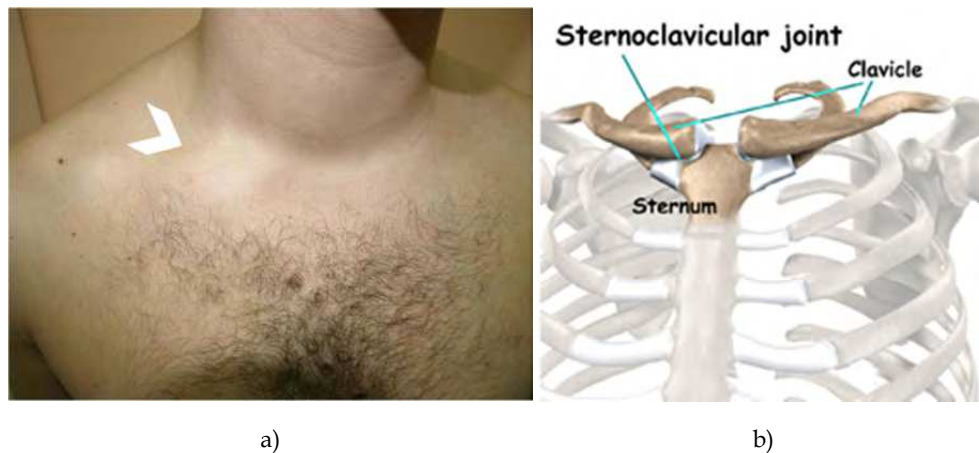


Fig. 9. Seventeen-year-old male patient with CCH. Note the unilateral sternoclavicular swelling (A). Schematic representation of the sterno-clavicular joint (B).

Basic characteristics of juvenile spondyloarthritis are shown in Table 4.

	Reactive arthritis (Reiter's syndrome) (RA)	Undifferentiated jSpA (ERA)	Juvenile ankylosing spondylitis (jAS)	IBD-related arthritis (IBD)	Psoriatic arthritis (PsA)	Ankylosing tarsitis (AT)	Clavicular cortical hyperostosis (CCH)
Familial clustering	+	+	+	+	+	?	?
HLA B27 association	+	-/+	+	+	-/+	?	-/+
Enthesitis (fibrocartilage entheses)	-	+	-/+	-/+	-/+	-	-
Synovitis (asymmetrical arthritis)	+	+	-/+	+	+	+	+
Axial involvement	-	-/+	+	-/+	+	-/+	-
Periostitis	-	-	-	-	-	+	+
Colitis (asymptomatic and symptomatic)	+	-/+	-/+	+	-/+	-	-
Symptomatic uveitis	+	-/+	-/+	-/+	-/+	-	-
Bone marrow edema / subchondral edema	-/+	-/+	-	-/+	-/+	-/+	+
Ankylosis	-	-	+	-	-	-/+	-
Tarsitis ("midfoot disease")	-	-	-	-	-	+	-
Dactylitis	-	-	-	-	+	-	-
Nail pitting and psoriatic plaques	-	-	-	-	+	-	-
Other extraarticular manifestations	+	-/+	-/+	+	-	-	-

Table 4. The basic characteristics of jSpA

8. Laboratory tests

There are no pathognomonic blood tests for spondyloarthritis. Erythrocyte sedimentation rate might be elevated though it is nonspecific. The negative ANA and rheumatoid factor ("seronegativity"), in combination with positive HLA-B27 in a child with asymmetric arthritis and enthesitis, would be helpful. However, less than 5 percent of people who are HLA-B27 positive ever develop spondyloarthritis, so diagnosis should not rely solely on this finding.

9. Imaging in jSpA

Imaging studies usually reveal osteopenia mostly in the foot and hip area in the early stage, joint space narrowing and ankylosis in the later course of the disease. Erosions and destruction are rare, but enthesophytosis and bone bridging, particularly in the feet, are common. Subchondral sclerosis and irregularities of the articular surface in the lower third of the sacroiliac joints on the iliac side are usually seen, and this may progress to erosions, joint space narrowing, bone bridging and complete fusion of the sacroiliac bones. Long lasting disease activity leads also to syndesmophytosis and ligamentous calcification of the spine. Magnetic resonance (MR) and ultrasound (US) are useful methods for disease activity monitoring. MR may even reveal sacroiliac joint inflammation in children with neither symptoms nor radiographic changes (Braun and Baraliakos 2011).

9.1 Ultrasound

Musculoskeletal US assessment in general is safe, noninvasive, and comparably cheap, showing itself as a complimentary tool to clinical evaluation in SpA. Nevertheless, it is very user dependent (D'Agostino, Aegerter et al. 2011). US has an increasing and relevant role in the evaluation of SpA mainly for its ability to assess joint and periarticular soft tissue involvement and in particular for its capacity to detect enthesitis, the clinical hallmark feature of SpA. A number of ultrasound studies have also shown that clinically unrecognised enthesitis is common in the lower limbs including those insertions amenable to sonographic assessment adjacent to the knee joint in patients with jSpA (Riente, Delle Sedie et al. 2007; D'Agostino, Aegerter et al. 2011). Since most cases of enthesitis are subclinical, addition of gray-scale US and Power-Doppler US (PDUS) appears to be a valuable first-line diagnostic tool to confirm a diagnosis in a patient with suspected SpA (D'Agostino, Aegerter et al. 2011). Changes include thickening and edema of the insertions, increased vascularity, bone erosion, and new bone formation (Borman, Koparal et al. 2006). Also, in cases of dactylitis, US can accurately delineate the underlying pathology. US allow clinicians to guide needle positioning within inflamed joints, tendon sheaths and entheses in order to inject steroids or other drugs. The clinical application of US in SpA extends to the monitoring of therapy efficacy, particularly when coupled with power Doppler imaging. Very slight changes in vascularity are easily detected in joints, entheses or tendons, aiding the rheumatologist in the assessment of the effects of local or systemic therapies. Subclinical Achilles enthesitis, detected with gray-scale US, is described in a subset of AS patients and a significant improvement can be demonstrated after 2 months of TNF-alpha antagonist therapy (Aydin, Karadag et al. 2010). In addition, in children with JIA subclinical synovitis detected by US is common, and often missed clinically (Magni-Manzoni, Epis et al. 2009).

9.2 MRI

Diagnosing spondyloarthritis (SpA) early in young patients with inflammatory back pain and normal findings on radiographs of the sacroiliac joints (SIJ) remains a challenge in routine practice. Magnetic resonance imaging (MRI) is regarded as the most sensitive imaging modality for detecting early SpA before the radiographic appearance of structural lesions (Figure 10). Single MRI lesions suggestive of inflammation can be found in the SIJ and the spine in up to one quarter of healthy controls and young patients with mechanical back pain (Weber and Maksymowych 2011).

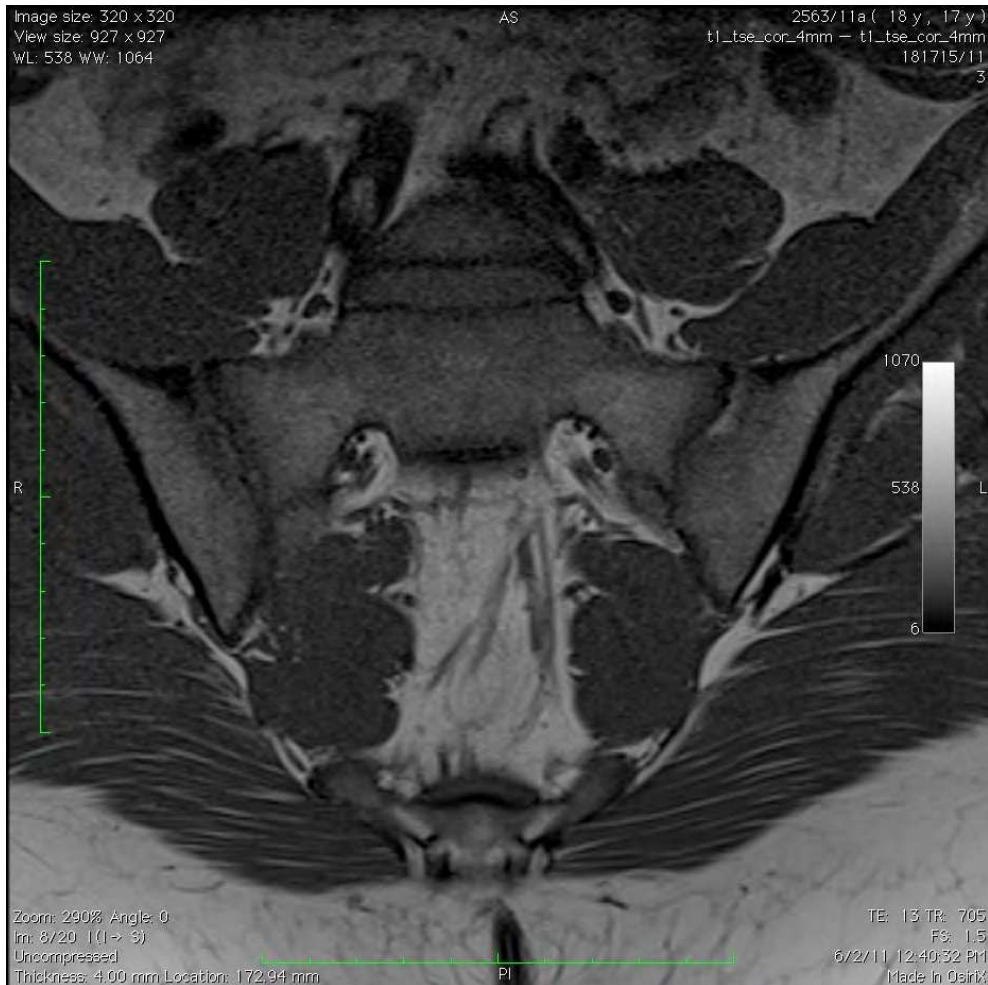

Fig. 10. MRI of the SI joints in a 12 year old boy with right-sided buttock pain. Coronal SE T1 WI shows erosive changes of articular facets of right sacroiliac joint with sclerotic subchondral bone.

MRI is highly sensitive for active enthesitis and depicts not only the enthesis itself but also associated findings such as soft-tissue involvement and bone marrow edema. Extensive and diffuse patterns of bone marrow edema are more closely related to inflammatory enthesitis, as shown in the hip. When soft-tissue involvement occurs in a synovial joint, synovitis may mask some, if not all, MRI features of enthesitis. Still, differentiation between the different causes of enthesitis (i.e., inflammatory, mechanical, metabolic) is only reliably possible in the context of the available clinical information. Despite these limitations, MRI represents a significant advance for the early diagnosis of ERA and for monitoring therapy that targets enthesal inflammation (Eshed, Bollow et al. 2007).

9.3 Conventional radiography

Imaging studies usually reveal osteopenia mostly in the foot and hip area in the early stage, joint space narrowing and ankylosis in the later course of the disease. Erosions and destruction are rare, but enthesophytosis and bone bridging, particularly in the feet, are common. Subchondral sclerosis and irregularities of the articular surface in the lower third of the sacroiliac joints on the iliac side are usually seen, and this may progress to erosions, joint space narrowing, bone bridging and complete fusion of the sacroiliac bones. Long lasting disease activity leads also to desmophytosis and ligamentous calcification of the spine. Plain radiography is insensitive to most of the early inflammatory changes in the sacroiliac joints in AS, yet to fulfill the modified New York criteria (van der Linden, Valkenburg et al. 1984), sacroillitis must be present as either grade 2 (erosion and sclerosis) or greater bilaterally, or grade 3–4 (erosion, sclerosis, and/or ankylosis) unilaterally (Figure 11). In one study, it took 5 years in 36%, and 10 years in 59% of patients with IBP and radiographically normal (or suspicious) sacroiliac joints to develop radiographic sacroillitis (Mau, Zeidler et al. 1988). Although conventional radiography is indicated in the initial evaluation of sacroiliac joints diseases, it is often insensitive for demonstrating the early changes of sacroillitis, so other imaging techniques typically are often necessary to clarify the pathology and for establishing the early diagnosis of seronegative SpA (Guglielmi, Scalzo et al. 2009).

We have to take into account that these New York criteria were designed for pathology in adult patients. In children the development of the skeleton does not allow us to interpret plain radiographs of the sacroiliac joints in a proper way until the Risser index reaches stage five. If that is not a case, sacroillitis may be misdiagnosed because of pseudowidening of the articular space and irregular margins.

10. Treatment of jSpA

In cases of juvenile-onset SpA, treatment decisions are based on clinical experience rather than on evidence from clinical trials (Burgos-Vargas, 2009). Medications and physical therapy are the mainstays of therapy. NSAIDs might be helpful to a degree, especially if there is inflammatory back pain or peripheral arthritis. Sulfasalazine can work well for peripheral arthritis, but it is not as effective for axial disease (Burgos-Vargas, Vazquez-Mellado et al. 2002). Methotrexate as second line agent is a good option in other forms of JIA, however its use in jSpA is limited. Steroids are used sparingly, mostly as intra-articular injections with triamcinolone hexacetonide. The combination of these conventional medications is often inadequate in controlling spondyloarthropathy.

The therapeutic value of low-energy lasers (LLLT) for enthesitis is controversial, and has not been systematically studied in children with spondyloarthritis. LLLT (Ga-Al-As laser) is a light source that generates extremely pure light, of a single wavelength. The effect is not thermal, but rather related to photochemical reactions in the cells (Brosseau, Robinson et al. 2005; Hawkins, Houreld et al. 2005). Laser therapy is used in many biomedical sciences to promote tissue regeneration (Mester, Mester et al. 1985; Karu 1999). Many studies involving the low-level laser therapy have shown that the healing process is enhanced by such therapy (Enwemeka 1988; Rochkind, Rousso et al. 1989; Nemeth 1993; Grossman, Schneid et al. 1998; O'Brien, Li et al. 1998; Lilge, Tierney et al. 2000; Maegawa, Itoh et al. 2000; Schlager, Kronberger et al. 2000; Sommer, Pinheiro et al. 2001; Wong-Riley, Bai et al. 2001; do Nascimento, Pinheiro et al. 2004; Eells, Wong-Riley et al. 2004; Pinheiro, Meireles et al. 2004; Hawkins, Houreld et al. 2005). In Table 5 we show the results of LLLT therapy in the pilot study of 38 children with jSpA diagnosed based on both ESSG and ILAR criteria, which we treated, in addition to standard NSAID therapy, with LLLT (Harjacek and Lamot 2008).

No. of patients	38
Cumulative dose	2.5 - 3 J/m ³
Treatment duration (days)	15,6 (10-40)
Enthesitis	
<i>Infrapatelar</i>	13
<i>Achilles</i>	20
AC	10
<i>Inguinal</i>	5
VAS before	5
VAS after	1,2

Table 5. LLLT (Ga-Al-As laser) treatment response.

In this pilot study we have shown that LLLT (Ga-Al-As laser) seems to be very effective in reducing pain in children with jSpA and enthesitis (76% VAS pain reduction). Visual analogue scales have become an acceptable measurement tool, and the use of a VAS to measure pain has been shown to have a high interclass correlation of 0.95. (Chow, Heller et al. 2006). This is in concordance with other studies that have found the lowering of VAS for the 2 points on a 10- point scale to be significant (Farrar, Portenoy et al. 2000; Farrar, Young et al. 2001; Chow, Heller et al. 2006; Van Breukelen 2006).

Currently, the best treatment for severe cases of juvenile-onset SpA is probably anti-TNF therapy. Anti-TNF alpha agents are also approved for use in Crohn's disease and psoriatic arthritis in children. Etanercept (Enbrel), infliximab (Remicade) and adalimumab (Humira) are in this group and work in the majority of patients. They have improved short-term outcomes in ankylosing spondylitis and psoriatic arthritis dramatically, and it seems they change the long-term disease course and outcome (Henrickson and Reiff 2004; Tse, Burgos-Vargas et al. 2005; Sulpice, Deslandre et al. 2009; Lamot, Bukovac et al. 2011). jSpA patients treated with TNF-blockers, such as infliximab and etanercept, have shown significant improvements in the number of active joints and tender entheses, ESR, CRP levels, and CHAQ scores (Henrickson and Reiff 2004; Tse, Burgos-Vargas et al. 2005; Sulpice, Deslandre

et al. 2009; Lamot, Bukovac et al. 2011). In addition, the results of a 3-month, randomized, double-blind, placebo-controlled trial to assess the efficacy of infliximab showed that this treatment significantly improved most measures of disease activity compared to placebo, including the number of active joints and tender entheses, pain intensity, patient and/or parent assessment of well-being and physician assessments of disease activity, health status, CHAQ score and CRP level (Burgos-Vargas 2007). There was no difference between groups in the frequency of adverse events. Regular exercises for stretching the spine and physical therapy are important to keep spinal and joint mobility in patients with jSpA. Basic principles in the treatment of jSpA are shown in Figure 12.

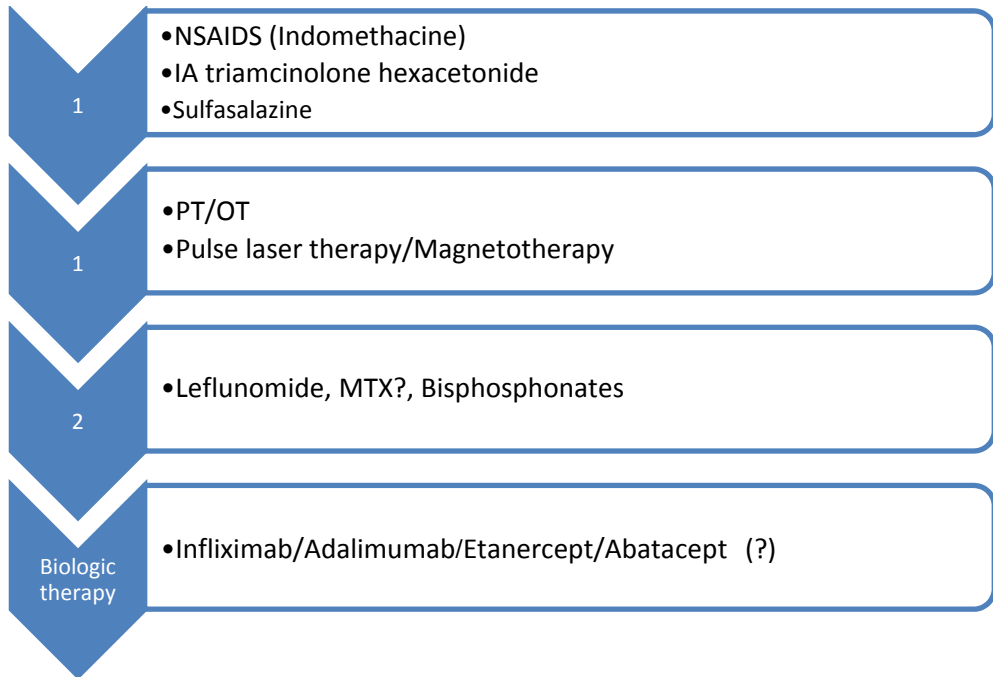


Fig. 12. Treatment of jSpA.

11. Prognosis

It is difficult to accurately estimate prognosis because the spectrum of jSpA is so broad. In comparison with other forms of juvenile arthritis, juvenile SpA tends to have a poorer outcome. While prognosis for ReA is clearly favorable, the majority of children who start out with undifferentiated jSpA (ERA), if not treated properly and early-enough, will eventually develop ankylosing spondylitis (Andersson Gare 1999; Burgos-Vargas 2002; Minden, Niewerth et al. 2002). In addition, patients might have long periods of remission, although “outgrowing” jSpA is not an expectation. In the pre-anti-TNF therapy reported remission rates of ERA following treatment and prior to adulthood range from 17% to 37%, and the risk of developing sacroillitis within the first 5 years after diagnosis ranges from 6% to approximately 50% across studies (Flato, Smerdel et al. 2002; Pagnini, Savelli et al. 2010;

Stoll, Bhore et al. 2010). Long term outcome is rather impaired as illustrated by a retrospective study by Flato *et al.* (Flato, Hoffmann-Vold et al. 2006) and by Minden *et al.* (Minden, Niewerth et al. 2002). Functional scores (measured by HAQ) are elevated and quality of life (measured by SF-36) is diminished. Remission rates varied from 18 % after 11 years (Minden, Niewerth et al. 2002) to 44 % after 15 years of disease (Flato, Hoffmann-Vold et al. 2006). In 35 % sacroillitis was found during the course of disease (Flato, Hoffmann-Vold et al. 2006) and in 39 % definite As developed (Minden, Niewerth et al. 2002). In older boys with JIA the positive HLA-B27 predicts increasingly extended disease within the first 3 years. It is also associated with involvement of small joints in the lower extremities (primarily subtalar and tarsal joints) in boys but not in girls, and with inflammatory back pain in both sexes (Berntson, Damgard et al. 2008). The new epidemiologic and outcome data in a “post-TNF- α ” era are clearly warranted.

12. Conclusions

The juvenile spondyloarthritis is a group of seronegative, immune-mediated inflammatory pediatric disorders characterized by enthesitis and arthritis, and a variety of extra-articular symptoms. They must be distinguished from JIA, however the distinction may not always be obvious. While the reactive arthritis is by far the most common form, in many children, the specific chronic disorder remains “undifferentiated”; most of these children fulfill criteria for ERA. Other children might develop more differentiated forms: jAS, jPsA, as well as, IBD-related arthritis. Although these are distinctive diseases, they have a number of clinical, radiologic, and genetic characteristics in common, which permit them to be classified under the unifying term “spondyloarthritis. There is not a specific test to be used since HLA-B27 is neither necessary nor sufficient, but clearly involved in the pathogenesis of disease. Since plain radiograph is often difficult to interpret in a growing child, the US is becoming the primary and most important imaging modality for the assessment of these diseases. Children with jSpA are at risk for sacroillitis, which may be present in the absence of suggestive symptoms or physical examination findings. Therefore, a routine screening by MRI has been recently proposed. Axial involvement is usually a late finding. The treatment decisions are based on clinical experience rather than on evidence from clinical trials; NSAID's and physiotherapy (including LLLT) are frequently used to manage symptoms. Sulphasalazine seems to be more effective on peripheral arthritis than on axial disease. New biologic therapies appear to improve outcomes, but education, exercise, physical and occupational therapy for stretching and maintaining range of motion are still the key components of management. Despite significant advances in the treatment of jSpA over the past few years, a better understanding of pathogenesis is likely to improve outcome by identifying ways to provide greater and more sustained clinical responses.

13. Key points

1. Juvenile spondyloarthritis (jSpA) is a term that refers to group inflammatory disorders affecting children under the age of 16 years, characterized by enthesitis and arthritis affecting predominantly the joints of the lower extremities.
2. The jSpA often begins as ‘undifferentiated’ disease (ERA), the presentation of which differs in children and adults; most notably, spinal involvement is uncommon, while hip arthritis is frequently seen in juvenile-onset disease.

3. jSpA are multifactorial diseases in which a disturbed interplay occurs between the immune system and environmental factors on a predisposing genetic background. The jSpA are polygenic in nature, both MHC genes (e.g. HLA-B27, etc.), and non-MHC genes (e.g. TLR-4, etc.) play a significant role in the disease pathogenesis.
4. Subclinical gut inflammation has been demonstrated in patients with all forms of juvenile spondyloarthritis.
5. While classification of juvenile spondyloarthritis is a "work in progress" and clearly problematic, the Garmisch-Partenkirchen criteria are the major candidates for future research in identifying spondyloarthritis in juvenile patients.
6. There are no pathognomonic blood tests for spondyloarthritis.
7. Magnetic resonance (MR) and ultrasound (US) are useful methods for disease activity monitoring, even in the asymptomatic patient.
8. In cases of juvenile-onset SpA, treatment decisions are based on clinical experience rather than on evidence from clinical trials; in addition to NSAID's and sulfasalazine, anti-TNF therapy has become the best treatment for severe cases of jSpA.
9. Education, exercise, physical and occupational therapy for stretching and maintaining range of motion are still the key components of management
10. Prognosis in the post "anti-TNF- α " era is largely unknown but clearly more favorable than before. Better understanding of pathogenesis is likely to improve outcome by identifying ways to provide greater and more sustained clinical responses.

14. References

- Aalto, K., A. Autio, et al. (2011). "Siglec-9 is a novel leukocyte ligand for vascular adhesion protein-1 and can be used in PET imaging of inflammation and cancer." *Blood* 118(13): 3725-3733.
- Adarichev, V. A. and T. T. Glant (2006). "Experimental spondyloarthropathies: animal models of ankylosing spondylitis." *Curr Rheumatol Rep* 8(4): 267-274.
- Agarwal, S., R. Misra, et al. (2009). "Synovial fluid RANKL and matrix metalloproteinase levels in enthesitis related arthritis subtype of juvenile idiopathic arthritis." *Rheumatol Int* 29(8): 907-911.
- Alvarez-Madrid, C., R. Merino, et al. (2009). "Tarsitis as an initial manifestation of juvenile spondyloarthropathy." *Clin Exp Rheumatol* 27(4): 691-694.
- Amor, B., M. Dougados, et al. (1991). "[Evaluation of the Amor criteria for spondylarthropathies and European Spondylarthropathy Study Group (ESSG). A cross-sectional analysis of 2,228 patients]." *Ann Med Interne (Paris)* 142(2): 85-89.
- Amor, B., M. Dougados, et al. (1990). "[Criteria of the classification of spondylarthropathies]." *Rev Rhum Mal Osteoartic* 57(2): 85-89.
- Andersson Gare, B. (1999). "Juvenile arthritis--who gets it, where and when? A review of current data on incidence and prevalence." *Clin Exp Rheumatol* 17(3): 367-374.
- Appel, H., R. Maier, et al. (2011). "Analysis of IL-17+ cells in facet joints of patients with spondyloarthritis suggests that the innate immune pathway might be of greater relevance than the Th17-mediated adaptive immune response." *Arthritis Res Ther* 13(3): R95.
- Arabshahi, B., K. M. Baskin, et al. (2007). "Reactive arthritis of the temporomandibular joints and cervical spine in a child." *Pediatr Rheumatol Online J* 5: 4.

- Artamonov, V. A., S. Akhmedi, et al. (1991). "[The clinical and immunogenetic characteristics of reactive arthritis in children]." *Ter Arkh* 63(5): 22-24.
- Assassi, S., J. D. Reveille, et al. (2011). "Whole-blood gene expression profiling in ankylosing spondylitis shows upregulation of toll-like receptor 4 and 5." *J Rheumatol* 38(1): 87-98.
- Aydin, S. Z., O. Karadag, et al. (2010). "Monitoring Achilles enthesitis in ankylosing spondylitis during TNF-alpha antagonist therapy: an ultrasound study." *Rheumatology (Oxford)* 49(3): 578-582.
- Barash, J., E. Mashiach, et al. (2008). "Differentiation of post-streptococcal reactive arthritis from acute rheumatic fever." *J Pediatr* 153(5): 696-699.
- Barnes, M. G., B. J. Aronow, et al. (2004). "Gene expression in juvenile arthritis and spondyloarthropathy: pro-angiogenic ELR+ chemokine genes relate to course of arthritis." *Rheumatology (Oxford)* 43(8): 973-979.
- Barnes, M. G., A. A. Grom, et al. (2009). "Subtype-specific peripheral blood gene expression profiles in recent-onset juvenile idiopathic arthritis." *Arthritis Rheum* 60(7): 2102-2112.
- Benjamin, M. and D. McGonagle (2007). "Histopathologic changes at "synovio-entheseal complexes" suggesting a novel mechanism for synovitis in osteoarthritis and spondylarthritis." *Arthritis Rheum* 56(11): 3601-3609.
- Berlin, C., R. F. Bargatze, et al. (1995). "alpha 4 integrins mediate lymphocyte attachment and rolling under physiologic flow." *Cell* 80(3): 413-422.
- Berlin, C., E. L. Berg, et al. (1993). "Alpha 4 beta 7 integrin mediates lymphocyte binding to the mucosal vascular addressin MAdCAM-1." *Cell* 74(1): 185-195.
- Berntson, L., M. Damgard, et al. (2008). "HLA-B27 predicts a more extended disease with increasing age at onset in boys with juvenile idiopathic arthritis." *J Rheumatol* 35(10): 2055-2061.
- Bhatia, N. N., G. Chow, et al. (2008). "Diagnostic modalities for the evaluation of pediatric back pain: a prospective study." *J Pediatr Orthop* 28(2): 230-233.
- Birnbaum, J., J. G. Bartlett, et al. (2008). "Clostridium difficile: an under-recognized cause of reactive arthritis?" *Clin Rheumatol* 27(2): 253-255.
- Bollow, M., K. G. Hermann, et al. (2005). "Very early spondyloarthritis: where the inflammation in the sacroiliac joints starts." *Ann Rheum Dis* 64(11): 1644-1646.
- Borman, P., S. Koparal, et al. (2006). "Ultrasound detection of enthesial insertions in the foot of patients with spondyloarthropathy." *Clin Rheumatol* 25(3): 373-377.
- Bowyer, S. and P. Roettcher (1996). "Pediatric rheumatology clinic populations in the United States: results of a 3 year survey. Pediatric Rheumatology Database Research Group." *J Rheumatol* 23(11): 1968-1974.
- Boyer, G. S., D. W. Templin, et al. (1993). "Evaluation of the European Spondylarthropathy Study Group preliminary classification criteria in Alaskan Eskimo populations." *Arthritis Rheum* 36(4): 534-538.
- Braun, J. and X. Baraliakos (2011). "Imaging of axial spondyloarthritis including ankylosing spondylitis." *Ann Rheum Dis* 70 Suppl 1: i97-103.
- Braun, J., M. Bollow, et al. (1998). "Prevalence of spondylarthropathies in HLA-B27 positive and negative blood donors." *Arthritis Rheum* 41(1): 58-67.
- Braun, J., M. A. Khan, et al. (2000). "Enthesitis and ankylosis in spondyloarthropathy: what is the target of the immune response?" *Ann Rheum Dis* 59(12): 985-994.

- Brophy, S., S. Hickey, et al. (2004). "Concordance of disease severity among family members with ankylosing spondylitis?" *J Rheumatol* 31(9): 1775-1778.
- Brosseau, L., V. Robinson, et al. (2005). "Low level laser therapy (Classes I, II and III) for treating rheumatoid arthritis." *Cochrane Database Syst Rev*(4): CD002049.
- Brown, M. A., S. Brophy, et al. (2003). "Identification of major loci controlling clinical manifestations of ankylosing spondylitis." *Arthritis Rheum* 48(8): 2234-2239.
- Brown, M. A., K. D. Pile, et al. (1998). "A genome-wide screen for susceptibility loci in ankylosing spondylitis." *Arthritis Rheum* 41(4): 588-595.
- Burbige, E. J., S. H. Huang, et al. (1975). "Clinical manifestations of Crohn's disease in children and adolescents." *Pediatrics* 55(6): 866-871.
- Burgos-Vargas, R. (2002). "The juvenile-onset spondyloarthritides." *Rheum Dis Clin North Am* 28(3): 531-560, vi.
- Burgos-Vargas, R. (2007). "Efficacy, safety, and tolerability of infliximab in juvenile-onset spondyloarthropathies (JO-SpA): results of the three-month, randomized, double-blind, placebo-controlled trial phase." *Arthritis Rheum* 56 (Suppl): S319.
- Burgos-Vargas, R., G. Castelazo-Duarte, et al. (1993). "Chest expansion in healthy adolescents and patients with the seronegative enthesopathy and arthropathy syndrome or juvenile ankylosing spondylitis." *J Rheumatol* 20(11): 1957-1960.
- Burgos-Vargas, R. and P. Clark (1989). "Axial involvement in the seronegative enthesopathy and arthropathy syndrome and its progression to ankylosing spondylitis." *J Rheumatol* 16(2): 192-197.
- Burgos-Vargas, R., C. Pacheco-Tena, et al. (2002). "A short-term follow-up of enthesitis and arthritis in the active phase of juvenile onset spondyloarthropathies." *Clin Exp Rheumatol* 20(5): 727-731.
- Burgos-Vargas, R., M. Rudwaleit, et al. (2002). "The place of juvenile onset spondyloarthropathies in the Durban 1997 ILAR classification criteria of juvenile idiopathic arthritis. International League of Associations for Rheumatology." *J Rheumatol* 29(5): 869-874.
- Burgos-Vargas, R., J. Vazquez-Mellado, et al. (1996). "Genuine ankylosing spondylitis in children: a case-control study of patients with early definite disease according to adult onset criteria." *J Rheumatol* 23(12): 2140-2147.
- Burgos-Vargas, R., J. Vazquez-Mellado, et al. (2002). "A 26 week randomised, double blind, placebo controlled exploratory study of sulfasalazine in juvenile onset spondyloarthropathies." *Ann Rheum Dis* 61(10): 941-942.
- Campbell, D. J. and E. C. Butcher (2002). "Rapid acquisition of tissue-specific homing phenotypes by CD4(+) T cells activated in cutaneous or mucosal lymphoid tissues." *J Exp Med* 195(1): 135-141.
- Carter, S. and R. J. Lories (2011). "Osteoporosis: A Paradox in Ankylosing Spondylitis." *Curr Osteoporos Rep*.
- Cassidy, J. T. and R. E. Petty (2001). *Textbook of pediatric rheumatology*. Philadelphia, W.B. Saunders.
- Cassidy, J. T. and R. E. Petty (2006). *Textbook of pediatric rheumatology*. Philadelphia, PA, Elsevier Saunders.
- Cedoz, J. P., D. Wendling, et al. (1995). "The B7 cross reactive group and spondyloarthropathies: an epidemiological approach." *J Rheumatol* 22(10): 1884-1890.

- Chow, R. T., G. Z. Heller, et al. (2006). "The effect of 300 mW, 830 nm laser on chronic neck pain: a double-blind, randomized, placebo-controlled study." *Pain* 124(1-2): 201-210.
- Ciccia, F., A. Accardo-Palumbo, et al. (2010). "Expansion of intestinal CD4+CD25(high) Treg cells in patients with ankylosing spondylitis: a putative role for interleukin-10 in preventing intestinal Th17 response." *Arthritis Rheum* 62(12): 3625-3634.
- Colbert, R. A. (2010). "Classification of juvenile spondyloarthritis: Enthesitis-related arthritis and beyond." *Nat Rev Rheumatol* 6(8): 477-485.
- Colbert, R. A. (2010). "Early axial spondyloarthritis." *Curr Opin Rheumatol* 22(5): 603-607.
- Colbert, R. A., M. L. DeLay, et al. (2010). "From HLA-B27 to spondyloarthritis: a journey through the ER." *Immunol Rev* 233(1): 181-202.
- Conti, F., O. Borrelli, et al. (2005). "Chronic intestinal inflammation and seronegative spondyloarthropathy in children." *Dig Liver Dis* 37(10): 761-767.
- Cury, S. E., M. J. Vilar, et al. (1997). "Evaluation of the European Spondylarthropathy Study Group (ESSG) preliminary classification criteria in Brazilian patients." *Clin Exp Rheumatol* 15(1): 79-82.
- Cuttica, R. J., E. J. Scheines, et al. (1992). "Juvenile onset Reiter's syndrome. A retrospective study of 26 patients." *Clin Exp Rheumatol* 10(3): 285-288.
- D'Agostino, M. A., P. Aegerter, et al. (2011). "How to diagnose spondyloarthritis early? Accuracy of peripheral enthesitis detection by power Doppler ultrasonography." *Ann Rheum Dis* 70(8): 1433-1440.
- do Nascimento, P. M., A. L. Pinheiro, et al. (2004). "A preliminary report on the effect of laser therapy on the healing of cutaneous surgical wounds as a consequence of an inversely proportional relationship between wavelength and intensity: histological study in rats." *Photomed Laser Surg* 22(6): 513-518.
- Douglas, M., S. van der Linden, et al. (1991). "The European Spondylarthropathy Study Group preliminary criteria for the classification of spondylarthropathy." *Arthritis Rheum* 34(10): 1218-1227.
- Drexler, S. K. and B. M. Foxwell (2010). "The role of toll-like receptors in chronic inflammation." *Int J Biochem Cell Biol* 42(4): 506-518.
- Duffy, C. M., R. A. Colbert, et al. (2005). "Nomenclature and classification in chronic childhood arthritis: time for a change?" *Arthritis Rheum* 52(2): 382-385.
- Eells, J. T., M. T. Wong-Riley, et al. (2004). "Mitochondrial signal transduction in accelerated wound and retinal healing by near-infrared light therapy." *Mitochondrion* 4(5-6): 559-567.
- el-Zaatari, F. A., K. C. Sams, et al. (1990). "In vitro mutagenesis of HLA-B27. Amino acid substitutions at position 67 disrupt anti-B27 monoclonal antibody binding in direct relation to the size of the substituted side chain." *J Immunol* 144(4): 1512-1517.
- el-Zaatari, F. A. and J. D. Taurog (1992). "In vitro mutagenesis of HLA-B27: single and multiple amino acid substitutions at consensus B27 sites identify distinct monoclonal antibody-defined epitopes." *Hum Immunol* 33(4): 243-248.
- Enwemeka, C. S. (1988). "Laser biostimulation of healing wounds: specific effects and mechanisms of action." *J Orthop Sports Phys Ther* 9(10): 333-338.
- Eshed, I., M. Bollow, et al. (2007). "MRI of enthesitis of the appendicular skeleton in spondyloarthritis." *Ann Rheum Dis* 66(12): 1553-1559.

- Evans, H. G., T. Suddason, et al. (2007). "Optimal induction of T helper 17 cells in humans requires T cell receptor ligation in the context of Toll-like receptor-activated monocytes." *Proc Natl Acad Sci U S A* 104(43): 17034-17039.
- Fantini, F. (2001). "Classification of chronic arthritides of childhood (juvenile idiopathic arthritis): criticisms and suggestions to improve the efficacy of the Santiago-Durban criteria." *J Rheumatol* 28(2): 456-459.
- Fantini, M. C., F. Pallone, et al. (2009). "Common immunologic mechanisms in inflammatory bowel disease and spondylarthropathies." *World J Gastroenterol* 15(20): 2472-2478.
- Farrar, J. T., R. K. Portenoy, et al. (2000). "Defining the clinically important difference in pain outcome measures." *Pain* 88(3): 287-294.
- Farrar, J. T., J. P. Young, Jr., et al. (2001). "Clinical importance of changes in chronic pain intensity measured on an 11-point numerical pain rating scale." *Pain* 94(2): 149-158.
- Fendler, C., S. Laitko, et al. (2001). "Frequency of triggering bacteria in patients with reactive arthritis and undifferentiated oligoarthritis and the relative importance of the tests used for diagnosis." *Ann Rheum Dis* 60(4): 337-343.
- Fernandez-Sueiro, J. L., C. Alonso, et al. (2004). "Prevalence of HLA-B27 and subtypes of HLA-B27 associated with ankylosing spondylitis in Galicia, Spain." *Clin Exp Rheumatol* 22(4): 465-468.
- Fink, C. W. (1995). "Proposal for the development of classification criteria for idiopathic arthritides of childhood." *J Rheumatol* 22(8): 1566-1569.
- Flato, B., A. M. Hoffmann-Vold, et al. (2006). "Long-term outcome and prognostic factors in enthesitis-related arthritis: a case-control study." *Arthritis Rheum* 54(11): 3573-3582.
- Flato, B., A. Smerdel, et al. (2002). "The influence of patient characteristics, disease variables, and HLA alleles on the development of radiographically evident sacroiliitis in juvenile idiopathic arthritis." *Arthritis Rheum* 46(4): 986-994.
- Gerard, H. C., J. A. Whittum-Hudson, et al. (2010). "The pathogenic role of Chlamydia in spondyloarthritis." *Curr Opin Rheumatol* 22(4): 363-367.
- Girschick, H. J., R. Krauspe, et al. (1998). "Chronic recurrent osteomyelitis with clavicular involvement in children: diagnostic value of different imaging techniques and therapy with non-steroidal anti-inflammatory drugs." *Eur J Pediatr* 157(1): 28-33.
- Gomez, K. S., K. Raza, et al. (1997). "Juvenile onset ankylosing spondylitis--more girls than we thought?" *J Rheumatol* 24(4): 735-737.
- Grossman, N., N. Schneid, et al. (1998). "780 nm low power diode laser irradiation stimulates proliferation of keratinocyte cultures: involvement of reactive oxygen species." *Lasers Surg Med* 22(4): 212-218.
- Gu, J., Y. L. Wei, et al. (2009). "Identification of RGS1 as a candidate biomarker for undifferentiated spondylarthritis by genome-wide expression profiling and real-time polymerase chain reaction." *Arthritis Rheum* 60(11): 3269-3279.
- Guglielmi, G., G. Scalzo, et al. (2009). "Imaging of the sacroiliac joint involvement in seronegative spondylarthropathies." *Clin Rheumatol* 28(9): 1007-1019.
- Hafner, R. (1987). "[Juvenile spondylarthritis. Retrospective study of 71 patients]." *Monatsschr Kinderheilkd* 135(1): 41-46.
- Hamilton, J. R., G. A. Bruce, et al. (1979). "Inflammatory bowel disease in children and adolescents." *Adv Pediatr* 26: 311-341.

- Harjacek, M. and L. Lamot (2008). The therapeutic value of low-energy laser (LLLT) for enthesitis in children with juvenile spondyloarthropathies. 15th Paediatric Rheumatology European Society (PreS) Congress, London, UK, BioMed Central.
- Harjacek, M., L. Lamot, et al. (2011). Clavicular cortical hyperostosis: new autoinflammatory entity or part of the juvenile spondyloarthropathies clinical picture? 18th European Pediatric Rheumatology Congress Bruges, Belgium
- Harjacek, M., T. Margetic, et al. (2008). "HLA-B*27/HLA-B*07 in combination with D6S273-134 allele is associated with increased susceptibility to juvenile spondyloarthropathies." *Clin Exp Rheumatol* 26(3): 498-504.
- Harjacek, M., J. Ostojic, et al. (2006). "Juvenile spondyloarthropathies associated with *Mycoplasma pneumoniae* infection." *Clin Rheumatol* 25(4): 470-475.
- Harjacek M., L. L., Frleta M., Bukovac L.T., Borovecki F. (2010). Distinctive gene expression in patients with juvenile spondyloarthropathy is related to autoinflammatory diseases. 17th Pediatric Rheumatology European Society Congress, Valencia, Spain.
- Haroon, N. and R. D. Inman (2010). "Endoplasmic reticulum aminopeptidases: Biology and pathogenic potential." *Nat Rev Rheumatol* 6(8): 461-467.
- Hawkins, D., N. Houreld, et al. (2005). "Low level laser therapy (LLLT) as an effective therapeutic modality for delayed wound healing." *Ann N Y Acad Sci* 1056: 486-493.
- Henrickson, M. and A. Reiff (2004). "Prolonged efficacy of etanercept in refractory enthesitis-related arthritis." *J Rheumatol* 31(10): 2055-2061.
- Hestbaek, L., C. Leboeuf-Yde, et al. (2006). "The course of low back pain from adolescence to adulthood: eight-year follow-up of 9600 twins." *Spine (Phila Pa 1976)* 31(4): 468-472.
- Heuft-Dorenbosch, L., R. Landewe, et al. (2007). "Performance of various criteria sets in patients with inflammatory back pain of short duration; the Maastricht early spondyloarthritis clinic." *Ann Rheum Dis* 66(1): 92-98.
- Hinks, A., P. Martin, et al. (2011). "Subtype specific genetic associations for juvenile idiopathic arthritis: ERAP1 with the enthesitis related arthritis subtype and IL23R with juvenile psoriatic arthritis." *Arthritis Res Ther* 13(1): R12.
- Hofbauer, L. C. and M. Schoppet (2004). "Clinical implications of the osteoprotegerin/RANKL/RANK system for bone and vascular diseases." *JAMA* 292(4): 490-495.
- Hofer, M. and T. R. Southwood (2002). "Classification of childhood arthritis." *Best Pract Res Clin Rheumatol* 16(3): 379-396.
- Hussein, A. (1987). "[Spectrum of post-enteritic reactive arthritis in childhood]." *Monatsschr Kinderheilkd* 135(2): 93-98.
- Hussein, A., H. Abdul-Khaliq, et al. (1989). "Atypical spondyloarthritis in children: proposed diagnostic criteria." *Eur J Pediatr* 148(6): 513-517.
- Johansson-Lindbom, B., M. Svensson, et al. (2003). "Selective generation of gut tropic T cells in gut-associated lymphoid tissue (GALT): requirement for GALT dendritic cells and adjuvant." *J Exp Med* 198(6): 963-969.
- Jones, G. T. and G. J. Macfarlane (2005). "Epidemiology of low back pain in children and adolescents." *Arch Dis Child* 90(3): 312-316.
- Joos, R., J. Dehoorne, et al. (2009). "Sensitivity and specificity of criteria for spondyloarthritis in children with late onset pauciarticular juvenile chronic arthritis as well as their characteristics." *Clin Exp Rheumatol* 27(5): 870-876.

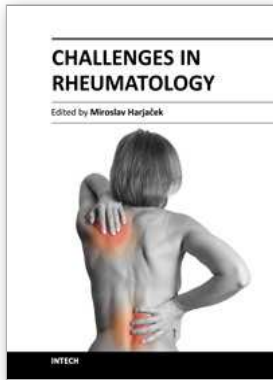
- Jose, F. A., E. A. Garnett, et al. (2009). "Development of extraintestinal manifestations in pediatric patients with inflammatory bowel disease." *Inflamm Bowel Dis* 15(1): 63-68.
- Kalke, S., S. D. Perera, et al. (2001). "The sternoclavicular syndrome: experience from a district general hospital and results of a national postal survey." *Rheumatology (Oxford)* 40(2): 170-177.
- Karu, T. (1999). "Primary and secondary mechanisms of action of visible to near-IR radiation on cells." *J Photochem Photobiol B* 49(1): 1-17.
- Kasapcopur, O., N. Demirli, et al. (2005). "Evaluation of classification criteria for juvenile-onset spondyloarthropathies." *Rheumatol Int* 25(6): 414-418.
- Khare, S. D., M. J. Bull, et al. (1998). "Spontaneous inflammatory disease in HLA-B27 transgenic mice is independent of MHC class II molecules: a direct role for B27 heavy chains and not B27-derived peptides." *J Immunol* 160(1): 101-106.
- Kivi, E., K. Elima, et al. (2009). "Human Siglec-10 can bind to vascular adhesion protein-1 and serves as its substrate." *Blood* 114(26): 5385-5392.
- Kruithof, E., L. De Rycke, et al. (2006). "Identification of synovial biomarkers of response to experimental treatment in early-phase clinical trials in spondylarthritis." *Arthritis Rheum* 54(6): 1795-1804.
- Kruithof, E., V. Van den Bossche, et al. (2006). "Distinct synovial immunopathologic characteristics of juvenile-onset spondylarthritis and other forms of juvenile idiopathic arthritis." *Arthritis Rheum* 54(8): 2594-2604.
- Lamot, L., L. T. Bukovac, et al. (2011). "The 'head-to-head' comparison of etanercept and infliximab in treating children with juvenile idiopathic arthritis." *Clin Exp Rheumatol* 29(1): 131-139.
- Laval, S. H., A. Timms, et al. (2001). "Whole-genome screening in ankylosing spondylitis: evidence of non-MHC genetic-susceptibility loci." *Am J Hum Genet* 68(4): 918-926.
- Leirisalo-Repo, M. (1998). "Prognosis, course of disease, and treatment of the spondyloarthropathies." *Rheum Dis Clin North Am* 24(4): 737-751, viii.
- Leirisalo-Repo, M., P. Helenius, et al. (1997). "Long-term prognosis of reactive salmonella arthritis." *Ann Rheum Dis* 56(9): 516-520.
- Leirisalo, M., G. Skylv, et al. (1982). "Followup study on patients with Reiter's disease and reactive arthritis, with special reference to HLA-B27." *Arthritis Rheum* 25(3): 249-259.
- Lilge, L., K. Tierney, et al. (2000). "Low-level laser therapy for wound healing: feasibility of wound dressing transillumination." *J Clin Laser Med Surg* 18(5): 235-240.
- Lin, Y. C., T. H. Liang, et al. (2009). "Differences between juvenile-onset ankylosing spondylitis and adult-onset ankylosing spondylitis." *J Chin Med Assoc* 72(11): 573-580.
- Lories, R. J., I. Derese, et al. (2005). "Modulation of bone morphogenetic protein signaling inhibits the onset and progression of ankylosing enthesitis." *J Clin Invest* 115(6): 1571-1579.
- Lories, R. J., F. P. Luyten, et al. (2009). "Progress in spondylarthritis. Mechanisms of new bone formation in spondyloarthritis." *Arthritis Res Ther* 11(2): 221.
- Mackie, S. L. and A. Keat (2004). "Poststreptococcal reactive arthritis: what is it and how do we know?" *Rheumatology (Oxford)* 43(8): 949-954.

- Maegawa, Y., T. Itoh, et al. (2000). "Effects of near-infrared low-level laser irradiation on microcirculation." *Lasers Surg Med* 27(5): 427-437.
- Magni-Manzoni, S., O. Epis, et al. (2009). "Comparison of clinical versus ultrasound-determined synovitis in juvenile idiopathic arthritis." *Arthritis Rheum* 61(11): 1497-1504.
- Mahendra, A., R. Misra, et al. (2009). "Th1 and Th17 Predominance in the Enthesitis-related Arthritis Form of Juvenile Idiopathic Arthritis." *J Rheumatol* 36(8): 1730-1736.
- Malleson, P. N., M. Y. Fung, et al. (1996). "The incidence of pediatric rheumatic diseases: results from the Canadian Pediatric Rheumatology Association Disease Registry." *J Rheumatol* 23(11): 1981-1987.
- Manners, P., J. Lesslie, et al. (2003). "Classification of juvenile idiopathic arthritis: should family history be included in the criteria?" *J Rheumatol* 30(8): 1857-1863.
- Manners, P. J. and C. Bower (2002). "Worldwide prevalence of juvenile arthritis why does it vary so much?" *J Rheumatol* 29(7): 1520-1530.
- Mau, W., H. Zeidler, et al. (1988). "Clinical features and prognosis of patients with possible ankylosing spondylitis. Results of a 10-year followup." *J Rheumatol* 15(7): 1109-1114.
- McGonagle, D. and M. Benjamin (2009). *Entheses, Enthesitis and Enthesopathy. Reports on the Rheumatic Diseases Series 6, Arthritis Research UK.* 4.
- Mease, P. J. (2011). "Psoriatic arthritis: update on pathophysiology, assessment and management." *Ann Rheum Dis* 70 Suppl 1: i77-84.
- Melis, L. and D. Elewaut (2009). "Progress in spondylarthritis. Immunopathogenesis of spondyloarthritis: which cells drive disease?" *Arthritis Res Ther* 11(3): 233.
- Mester, E., A. F. Mester, et al. (1985). "The biomedical effects of laser application." *Lasers Surg Med* 5(1): 31-39.
- Mielants, H., M. De Vos, et al. (1996). "The role of gut inflammation in the pathogenesis of spondyloarthropathies." *Acta Clin Belg* 51(5): 340-349.
- Mielants, H., E. M. Veys, et al. (1993). "Gut inflammation in children with late onset pauciarticular juvenile chronic arthritis and evolution to adult spondyloarthropathy--a prospective study." *J Rheumatol* 20(9): 1567-1572.
- Mielants, H., E. M. Veys, et al. (1987). "Late onset pauciarticular juvenile chronic arthritis: relation to gut inflammation." *J Rheumatol* 14(3): 459-465.
- Minden, K., M. Niewerth, et al. (2002). "Long-term outcome in patients with juvenile idiopathic arthritis." *Arthritis Rheum* 46(9): 2392-2401.
- Moorthy, L. N., S. Gaur, et al. (2009). "Poststreptococcal reactive arthritis in children: a retrospective study." *Clin Pediatr (Phila)* 48(2): 174-182.
- Myles, A. and A. Aggarwal (2011). "Expression of Toll-like receptors 2 and 4 is increased in peripheral blood and synovial fluid monocytes of patients with enthesitis-related arthritis subtype of juvenile idiopathic arthritis." *Rheumatology (Oxford)* 50(3): 481-488.
- Nemeth, A. J. (1993). "Lasers and wound healing." *Dermatol Clin* 11(4): 783-789.
- Nistala, K. and L. R. Wedderburn (2009). "Th17 and regulatory T cells: rebalancing pro- and anti-inflammatory forces in autoimmune arthritis." *Rheumatology (Oxford)* 48(6): 602-606.
- O'Brien, T. P., Q. Li, et al. (1998). "Inflammatory response in the early stages of wound healing after excimer laser keratectomy." *Arch Ophthalmol* 116(11): 1470-1474.

- Pacheco-Tena, C., C. Alvarado De La Barrera, et al. (2001). "Bacterial DNA in synovial fluid cells of patients with juvenile onset spondyloarthropathies." *Rheumatology (Oxford)* 40(8): 920-927.
- Packham, J. C. and M. A. Hall (2002). "Long-term follow-up of 246 adults with juvenile idiopathic arthritis: functional outcome." *Rheumatology (Oxford)* 41(12): 1428-1435.
- Pagnini, I., S. Savelli, et al. (2010). "Early predictors of juvenile sacroiliitis in enthesitis-related arthritis." *J Rheumatol* 37(11): 2395-2401.
- Petty, R. E., J. R. Smith, et al. (2003). "Arthritis and uveitis in children. A pediatric rheumatology perspective." *Am J Ophthalmol* 135(6): 879-884.
- Petty, R. E., T. R. Southwood, et al. (1998). "Revision of the proposed classification criteria for juvenile idiopathic arthritis: Durban, 1997." *J Rheumatol* 25(10): 1991-1994.
- Petty, R. E., T. R. Southwood, et al. (2004). "International League of Associations for Rheumatology classification of juvenile idiopathic arthritis: second revision, Edmonton, 2001." *J Rheumatol* 31(2): 390-392.
- Pinheiro, A. L., G. C. Meireles, et al. (2004). "Phototherapy improves healing of cutaneous wounds in nourished and undernourished Wistar rats." *Braz Dent J* 15 Spec No: S121-28.
- Prieur, L. V., Dougados M, et al. (1990). "Evaluation of the ESSG and the Amor criteria for juvenile spondyloarthropathies (JSA). Study of 310 consecutive children referred to one pediatric rheumatology center." *Arthritis Rheum* 33 (Suppl 9): D195.
- Prutki, M., L. Tambic Bukovac, et al. (2008). "Retrospective study of juvenile spondylarthropathies in Croatia over the last 11 years." *Clin Exp Rheumatol* 26(4): 693-699.
- Reveille, J. D. and R. M. Maganti (2009). "Subtypes of HLA-B27: history and implications in the pathogenesis of ankylosing spondylitis." *Adv Exp Med Biol* 649: 159-176.
- Reveille, J. D., A. M. Sims, et al. (2010). "Genome-wide association study of ankylosing spondylitis identifies non-MHC susceptibility loci." *Nat Genet* 42(2): 123-127.
- Reynolds, T. L. and M. A. Khan (1988). "B7 crossreactive antigens in spondyloarthropathies." *J Rheumatol* 15(9): 1454.
- Riente, L., A. Delle Sedie, et al. (2007). "Ultrasound imaging for the rheumatologist IX. Ultrasound imaging in spondyloarthritis." *Clin Exp Rheumatol* 25(3): 349-353.
- Rochkind, S., M. Rouso, et al. (1989). "Systemic effects of low-power laser irradiation on the peripheral and central nervous system, cutaneous wounds, and burns." *Lasers Surg Med* 9(2): 174-182.
- Rosenberg, A. M. and R. E. Petty (1982). "A syndrome of seronegative enthesopathy and arthropathy in children." *Arthritis Rheum* 25(9): 1041-1047.
- Rudwaleit, M., R. Landewe, et al. (2009). "The development of Assessment of SpondyloArthritis international Society classification criteria for axial spondyloarthritis (part I): classification of paper patients by expert opinion including uncertainty appraisal." *Ann Rheum Dis* 68(6): 770-776.
- Rudwaleit, M., D. van der Heijde, et al. (2009). "The development of Assessment of SpondyloArthritis international Society classification criteria for axial spondyloarthritis (part II): validation and final selection." *Ann Rheum Dis* 68(6): 777-783.
- Rutkowska-Sak, L., I. Slowinska, et al. (2010). "[Juvenile spondyloarthropathies]." *Ann Acad Med Stetin* 56 Suppl 1: 29-33.

- Salmi, M. and S. Jalkanen (1998). "Endothelial ligands and homing of mucosal leukocytes in extraintestinal manifestations of IBD." *Inflamm Bowel Dis* 4(2): 149-156.
- Salmi, M. and S. Jalkanen (2001). "Human leukocyte subpopulations from inflamed gut bind to joint vasculature using distinct sets of adhesion molecules." *J Immunol* 166(7): 4650-4657.
- Saraux, A., C. Guedes, et al. (1999). "Prevalence of rheumatoid arthritis and spondyloarthropathy in Brittany, France. Societe de Rhumatologie de l'Ouest." *J Rheumatol* 26(12): 2622-2627.
- Saxena, N., A. Aggarwal, et al. (2005). "Elevated concentrations of monocyte derived cytokines in synovial fluid of children with enthesitis related arthritis and polyarticular types of juvenile idiopathic arthritis." *J Rheumatol* 32(7): 1349-1353.
- Saxena, N., R. Misra, et al. (2006). "Is the enthesitis-related arthritis subtype of juvenile idiopathic arthritis a form of chronic reactive arthritis?" *Rheumatology (Oxford)* 45(9): 1129-1132.
- Schett, G. (2009). "Bone formation versus bone resorption in ankylosing spondylitis." *Adv Exp Med Biol* 649: 114-121.
- Schett, G. and M. Rudwaleit (2010). "Can we stop progression of ankylosing spondylitis?" *Best Pract Res Clin Rheumatol* 24(3): 363-371.
- Schiellerup, P., K. A. Krogfelt, et al. (2008). "A comparison of self-reported joint symptoms following infection with different enteric pathogens: effect of HLA-B27." *J Rheumatol* 35(3): 480-487.
- Schlager, A., P. Kronberger, et al. (2000). "Low-power laser light in the healing of burns: a comparison between two different wavelengths (635 nm and 690 nm) and a placebo group." *Lasers Surg Med* 27(1): 39-42.
- Sharma, S. M., D. Choi, et al. (2009). "Insights in to the pathogenesis of axial spondyloarthropathy based on gene expression profiles." *Arthritis Res Ther* 11(6): R168.
- Sieper, J., M. Rudwaleit, et al. (2002). "Diagnosing reactive arthritis: role of clinical setting in the value of serologic and microbiologic assays." *Arthritis Rheum* 46(2): 319-327.
- Sieper, J., D. van der Heijde, et al. (2009). "New criteria for inflammatory back pain in patients with chronic back pain: a real patient exercise by experts from the Assessment of SpondyloArthritis international Society (ASAS)." *Ann Rheum Dis* 68(6): 784-788.
- Simonet, W. S., D. L. Lacey, et al. (1997). "Osteoprotegerin: a novel secreted protein involved in the regulation of bone density." *Cell* 89(2): 309-319.
- Singh, R., A. Aggarwal, et al. (2007). "Th1/Th17 cytokine profiles in patients with reactive arthritis/undifferentiated spondyloarthropathy." *J Rheumatol* 34(11): 2285-2290.
- Smith, L. (2007). "Back pain in the young: a review of studies conducted among school children and university students." *Current Pediatric Reviews* 3: 69-77.
- Sommer, A. P., A. L. Pinheiro, et al. (2001). "Biostimulatory windows in low-intensity laser activation: lasers, scanners, and NASA's light-emitting diode array system." *J Clin Laser Med Surg* 19(1): 29-33.
- Souza, H. S., C. C. Elia, et al. (1999). "Expression of lymphocyte-endothelial receptor-ligand pairs, alpha4beta7/MAdCAM-1 and OX40/OX40 ligand in the colon and jejunum of patients with inflammatory bowel disease." *Gut* 45(6): 856-863.

- Stenstad, H., A. Ericsson, et al. (2006). "Gut-associated lymphoid tissue-primed CD4+ T cells display CCR9-dependent and -independent homing to the small intestine." *Blood* 107(9): 3447-3454.
- Stoll, M. L., R. Bhole, et al. (2010). "Spondyloarthritis in a pediatric population: risk factors for sacroiliitis." *J Rheumatol* 37(11): 2402-2408.
- Stoll, M. L. and M. Punaro (2011). "Psoriatic juvenile idiopathic arthritis: a tale of two subgroups." *Curr Opin Rheumatol* 23(5): 437-443.
- Stoll, M. L., D. Zurakowski, et al. (2006). "Patients with juvenile psoriatic arthritis comprise two distinct populations." *Arthritis Rheum* 54(11): 3564-3572.
- Sulpice, M., C. J. Deslandre, et al. (2009). "Efficacy and safety of TNFalpha antagonist therapy in patients with juvenile spondyloarthropathies." *Joint Bone Spine* 76(1): 24-27.
- Symmons, D. P., M. Jones, et al. (1996). "Pediatric rheumatology in the United Kingdom: data from the British Pediatric Rheumatology Group National Diagnostic Register." *J Rheumatol* 23(11): 1975-1980.
- Tse, S. M., R. Burgos-Vargas, et al. (2005). "Anti-tumor necrosis factor alpha blockade in the treatment of juvenile spondylarthropathy." *Arthritis Rheum* 52(7): 2103-2108.
- Tsuchiya, N., M. Shiota, et al. (1998). "MICA allele typing of HLA-B27 positive Japanese patients with seronegative spondylarthropathies and healthy individuals: differential linkage disequilibrium with HLA-B27 subtypes." *Arthritis Rheum* 41(1): 68-73.
- Van Breukelen, G. J. (2006). "ANCOVA versus change from baseline: more power in randomized studies, more bias in nonrandomized studies [corrected]." *J Clin Epidemiol* 59(9): 920-925.
- van der Heijde, D. and W. P. Maksymowych (2010). "Spondyloarthritis: state of the art and future perspectives." *Ann Rheum Dis* 69(6): 949-954.
- van der Linden, S., H. A. Valkenburg, et al. (1984). "Evaluation of diagnostic criteria for ankylosing spondylitis. A proposal for modification of the New York criteria." *Arthritis Rheum* 27(4): 361-368.
- Vegvari, A., Z. Szabo, et al. (2009). "The genetic background of ankylosing spondylitis." *Joint Bone Spine* 76(6): 623-628.
- Weber, U. and W. P. Maksymowych (2011). "Sensitivity and specificity of magnetic resonance imaging for axial spondyloarthritis." *Am J Med Sci* 341(4): 272-277.
- Wong-Riley, M. T., X. Bai, et al. (2001). "Light-emitting diode treatment reverses the effect of TTX on cytochrome oxidase in neurons." *Neuroreport* 12(14): 3033-3037.
- Yang, Z. X., Y. Liang, et al. (2007). "Increased expression of Toll-like receptor 4 in peripheral blood leucocytes and serum levels of some cytokines in patients with ankylosing spondylitis." *Clin Exp Immunol* 149(1): 48-55.
- Yli-Kerttula, T., R. Terhti, et al. (1995). "Ten-year follow up study of patients from a Yersinia pseudotuberculosis III outbreak." *Clin Exp Rheumatol* 13(3): 333-337.



Challenges in Rheumatology

Edited by Dr. Miroslav Harjacek

ISBN 978-953-307-848-9

Hard cover, 190 pages

Publisher InTech

Published online 22, December, 2011

Published in print edition December, 2011

Rheumatology is a subspecialty of medicine that focuses on the biology, cause, diagnosis and the treatment of a variety of musculoskeletal and other systemic diseases. The field of rheumatology is expanding rapidly and several very exciting developments have occurred during the recent years. Firstly, there has been a new dramatic understanding of the nature of inflammation and the possibility of specifically regulating the aberrant immune inflammatory response. Secondly, an understanding of pathogenesis has led to the development of new, more targeted therapies. Challenges in Rheumatology has assembled an impressive group of international experts who have studied specific aspects of certain rheumatic diseases and have extensive experience either in pathophysiology, or with the in-depth diagnosis and/or management of rheumatic patients. They communicate their knowledge and experience to the reader in chapters that are conveniently organized as pathophysiology, clinical manifestations and diagnosis of selected rheumatic diseases, medical and perioperative orthopedic management, and the economic impact of rheumatic diseases. We hope that this book will help trainees become better physicians and scientists, and that it will help practicing rheumatologists to provide better care, and ultimately, improve the quality of life of our patients.

How to reference

In order to correctly reference this scholarly work, feel free to copy and paste the following:

Miroslav Harjaček, Lovro Lamot, Lana Tambić Bukovac, Mandica Vidović and Rik Joos (2011). Juvenile Spondyloarthritis, Challenges in Rheumatology, Dr. Miroslav Harjacek (Ed.), ISBN: 978-953-307-848-9, InTech, Available from: <http://www.intechopen.com/books/challenges-in-rheumatology/juvenile-spondyloarthritis>

INTECH
open science | open minds

InTech Europe

University Campus STeP Ri
Slavka Krautzeka 83/A
51000 Rijeka, Croatia
Phone: +385 (51) 770 447
Fax: +385 (51) 686 166
www.intechopen.com

InTech China

Unit 405, Office Block, Hotel Equatorial Shanghai
No.65, Yan An Road (West), Shanghai, 200040, China
中国上海市延安西路65号上海国际贵都大饭店办公楼405单元
Phone: +86-21-62489820
Fax: +86-21-62489821

© 2011 The Author(s). Licensee IntechOpen. This is an open access article distributed under the terms of the [Creative Commons Attribution 3.0 License](#), which permits unrestricted use, distribution, and reproduction in any medium, provided the original work is properly cited.