

# Familial Catecholamine-Secreting Tumors - Three Distinct Families with Hereditary Pheochromocytoma

Shirin Hasani-Ranjbar, Azadeh Ebrahim-Habibi and Bagher Larijani  
*Endocrinology and Metabolism Research Institute, Shariati Hospital, Tehran University of  
Medical Sciences, Tehran,  
Iran*

## 1. Introduction

Phaeochromocytomas (PHEOs) and paragangliomas (PGLs) are catecholamine-secreting tumors, that arise from chromaffin cells of the adrenal medulla and extra-adrenal sites. Extra-adrenal phaeochromocytomas are called paragangliomas (Landers et al., 2005). The Prevalence of these tumors is 1:4500 and 1:1700 and an annual incidence of 3-8 cases per 1 million per year in the general population. PHEOs/PGLs arise from three anatomically parts of the neural crest derived sympathy-adrenal system: adrenal medulla, sympathetic, and parasympathetic paraganglia (Kantorovich et al., 2010). Extra-adrenal parasympathetic paragangliomas which are located predominantly in the head and neck are approximately 95% nonsecretory. Pheochromocytomas typically occur in about 85% of cases from adrenal medullary chromaffin tissue and in about 15% of cases from extra-adrenal chromaffin tissues (Elder et al., 2005).

### 1.1 Malignant pheochromocytoma

Malignant forms of catecholamine-secreting tumors are rare. The malignancy rate is variable, from 2.4-26%. There are no histological proofs of malignancy for such tumors to date and the only accepted criterion is the presence of metastasis. The distant metastases are usually of hematologic origin, mostly involving bone, liver and lung (Hasani-Ranjbar, 2009, 2010). The prevalence of metastasis is up to 36-50% for extra adrenal abdominal pheochromocytoma and 10% and 5% for adrenal and familial forms respectively (Whalen et al., 1992; O Riordan et al., 1996). Some studies have suggested that the presence of necrosis, vascular invasion, extensive local invasion, and high rate of mitotic figures may indicate a malignant behavior in pheochromocytoma. A recent study by Thompson used clinical features, histologic findings, and immunophenotypic studies for identifying parameters that may help distinguish benign from malignant pheochromocytoma. This is an Adrenal Gland scale Score (PASS) which is weighted for 12 specific histologic features that are more frequently identified in malignant pheochromocytoma. Tumors with PASS more than 4 were biologically more aggressive than tumors with a PASS less than 4. Some immunohistochemical markers such as Ki-67, P52, Bcl-2 were studied to differentiate malignant from benign pheochromocytoma too (Strong et al., 2008). But practically the

diagnosis of malignant pheochromocytoma can only be determined by presence of recurrence or metastatic disease at a site where chromaffin cells do not normally exist.

## **1.2 Familial pheochromocytoma**

Most pheochromocytomas represent sporadic tumors. However some patients have disease as part of a familial disorder (15-30%). Sporadic pheochromocytomas are usually unicentric and unilateral while familial pheochromocytomas are often multicentric and bilateral. Hereditary pheochromocytoma typically present at a younger age than sporadic forms (Nourmann et al 2002; Manger & Gifford, 2002).

There are several familial disorders associated with pheochromocytoma, these syndromes include von Hippel-Lindau (VHL) syndrome, multiple endocrine neoplasia type 2 (MEN2), neurofibromatosis type 1 and SDH mutation-related tumours. The approximate frequency of pheochromocytoma in these disorders is 50 percent in MEN2, 10 to 20 percent in VHL syndrome, and 0.1 to 5.7 percent with neurofibromatosis type 1 (Hasani-Ranjbar et al., 2009, Walter et al., 1999b; Dluhy, 2002). All of these syndromes have autosomal dominant inheritance (Table 1).

Multiple endocrine neoplasia type 1 (MEN1) is an autosomal dominant predisposition to tumors of the parathyroid glands, anterior pituitary, and pancreatic islet cells. pheochromocytoma is very rare in MEN1 syndrome (Brandi, 2001).

### **1.2.1 Multiple Endocrine Neoplasia Type 2 (MEN 2A and MEN 2B )**

The prevalence of MEN2 syndrome is 2.5 per 100,000 in the general population. MEN2 is sub classified into three syndromes: MEN2A; MEN2B; and familial medullary thyroid cancer (FMTC).

Multiple endocrine neoplasia type 2 (MEN2A) is characterized by pheochromocytoma (usually bilateral and may be asynchronous), medullary thyroid carcinoma (MTC), and hyperparathyroidism due to primary parathyroid hyperplasia (Noumann et al., 1993). The respective frequency of these tumors in MEN2 is over 90 percent for medullary thyroid cancer, approximately 40 to 50 percent for pheochromocytoma, and 10 to 20 percent for multigland.

MEN2A is a heritable predisposition to medullary thyroid cancer, pheochromocytoma, and primary parathyroid hyperplasia. MEN2B shares the inherited predisposition to medullary thyroid cancer and pheochromocytoma that occurs in MEN2A. But in patients with MEN2B other clinical disorders including mucosal neuromas, typically involving the lips and tongue, and intestinal ganglioneuromas have to be considered. FMTC is a variant of MEN2A, which is associated with medullary thyroid cancer but not the other clinical manifestations of MEN2 syndromes (Brandi et al., 2001; Pacak et al., 2005 ). In patients with MEN2B, Medullary thyroid cancer is often more aggressive and of earlier onset than in MEN2A; so, early diagnosis and prevention are particularly critical (Donovan et al., 1989; Mathew et al., 1987).

In contrast to MEN1, early diagnosis via screening of "at-risk" family members in MEN2A kindreds is essential because medullary thyroid cancer is a life-threatening disease that can be prevented by early thyroidectomy

DNA testing has been the best screening test for this disorder since it was recognized that affected patients have germ-line mutations in the RET proto-oncogene on chromosome 10.

	MEN2	VHL	NF1	PGL	CARNEY-triad
Major Features	MTC, PCC, Primary parathyroid hyperplasia	PCC, PGL, Retinal angiomas, Cerebellar hemangioblastoma, Epididymal cystadenoma, Renal and pancreatic cysts, neuroendocrine tumors, Renal cell carcinoma	café-au-lait macules, neurofibroma, Freckling, optic glioma. Lisch nodules (iris hamartomas), sphenoid dysplasia,	Head and neck, mediastinal, abdominal and pelvic PGL,	PGL, Gastric leiomyosarcoma, Pulmonary condromas
% PCC	50%	10-20%	Rare(0.1-5.7%)	-	-
Bilateral	50-80%	50%	16%	-	-
Benign	Almost Always	95%	Most cases	SDHB is more malignant	-
Extra-adrenal PGL	Rare	Rare	Can Occur	Usual manifestation	-
Inheritance	AD	AD	AD	SDHB & SDHC & SDH%(AD), SDHD(MI)	Unknown
Gene locus	10q11.2	3p25-26	17q11.2	SDHB1p35-36 SDHC 1q23 SDHD11q23	Unknown
catecholamine phenotype	E	NE	E	NE	Unknown

Abbreviations: VHL= von Hippel Lindau, MEN= multiple endocrine neoplasia, NF=Neurofibromatosis, PGL=Paraganglioma, PCC= Pheochromocytoma; MTC: Medullary thyroid cancer, SDH=succinate dehydrogenase type B,C,or D, AD=Autosomal Dominant, NE, norepinephrine; E, epinephrine,MT=Maternal Imprinting

Table 1. Genetic conditions associated with pheochromocytoma- Clinical, biochemical and genetic facts.

Numerous activating mutations throughout the RET proto-oncogene have been documented in persons with MEN 2A and pheochromocytoma is associated most frequently with mutations in codon 634 (in exon 11). MEN 2B is associated with mutations primarily in codon 918 (in exon 16) of the RET proto-oncogene (Mulligan et al., 1994; Carlson et al.,1994).

### 1.2.2 VHL syndrome

Von Hippel-Lindau (VHL) disease represents an alteration on VHL protein. The major physiological function of the VHL protein is to promote degradation of hypoxia-inducible factor (HIF1) that is a major factor involved in the regulation of hypoxia-related gene transcription (Figure 1).

Von Hippel-Lindau (VHL) disease is manifested by a variety of benign and malignant tumors. The VHL phenotype includes pheochromocytoma (frequently bilateral), paraganglioma (rarely), retinal angiomas, cerebellar hemangioblastoma, epididymal cystadenoma, renal

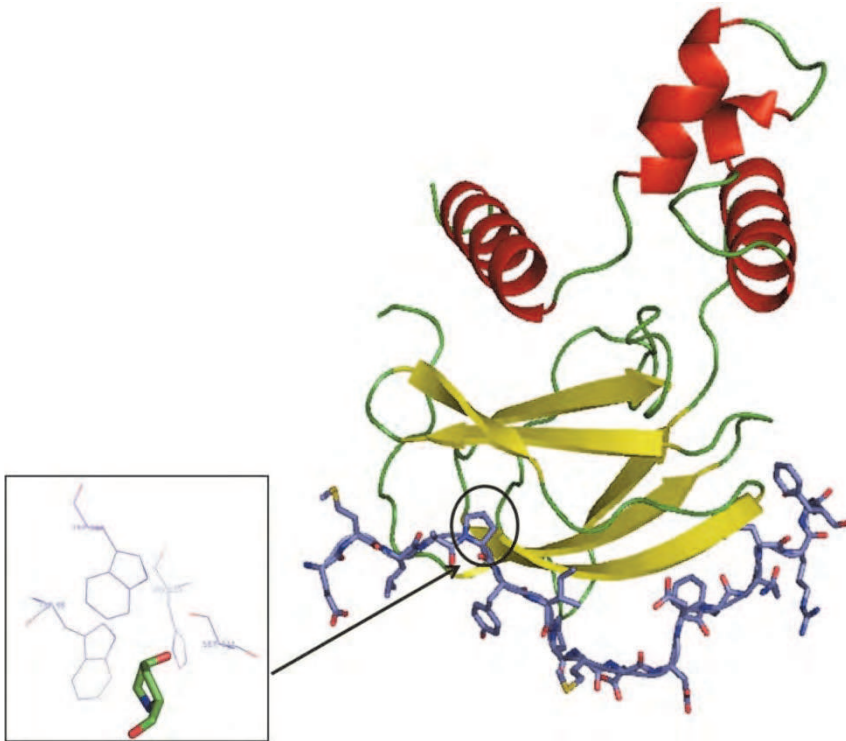


Fig. 1. pVHL (1LQB.PDB) is shown in cartoon representation, in the upper part of the picture, interacting with HIF (which residues are shown as sticks). The 564 hydroxyproline residue of HIF, which is believed to be important in the interactions between the two proteins [REF: *Science* 296, 1886 (2002); Jung-Hyun Min, *et al. Structure of an HIF-1 $\alpha$ -pVHL Complex: Hydroxyproline Recognition in Signaling* ] is indicated with a circle, and a view of the same hydroxyproline residue (stick) is shown in the inset image, alongside with some of the pVHL residues (labelled) that are located in its proximity. Mutations happening in these residues could be deleterious to the interaction between pVHL and HIF, and possibly involved in the disease phenotype. (This image has been created using PyMOL).

and pancreatic cysts, pancreatic neuroendocrine tumors, and renal cell carcinoma (RCC) (Hasani Ranjbar *et al.*, 2009; Lonser *et al.*, 2003; Patocs *et al.*, 2008) .

VHL disease is divided into types I and II, based upon the likelihood of developing pheochromocytoma (Zbar *et al.*, 1996). Type II families are more likely to carry a missense mutation in the VHL gene and are at higher risk for developing pheochromocytoma. Type II disease is subdivided based upon the risk of developing of RCC. Type IIA and IIB families have a low and high incidence of RCC, respectively, while type IIC kindreds are characterized by the development of pheochromocytomas only, without RCC or hemangioblastoma. Patients in kindreds with type I disease have a substantially lower risk of developing pheochromocytomas (Gomy *et al.*, 2010).

Clinical classification of VHL include: A. Classic VHL disease (A1: Families meeting current VHL diagnostic criteria with involvement of at least three VHL tumors in two distinct

organs; A2: Sporadic patients with involvement of at least two distinct tumors); B. nonclassic VHL disease, meeting criteria (B1:Families with less than 3 tumors in 2 distinct organs; B2: Cases meeting current diagnostic VHL criteria with limited VHL manifestations; C. Non classic, not meeting criteria(VHL-associated manifestations not meeting current diagnostic criteria) (Ciotti et al., 2009).

The VHL tumor suppressor gene is located on chromosome 3p25-26. More than 300 germline VHL mutations have been identified that lead to loss of function of the VHL protein (Kim & Kaelin,2004; Cruz et al., 2007). Missense, nonsense and splice site mutations, microdeletions and microinsertions are detected in approximately two-thirds of the families. Exon or entire gene deletions are found in 20-30% of the VHL families. Recently, real time quantitative PCR (RQ-PCR) and multiplex ligation-dependent probe amplification assay (MLPA) strategies have been proposed for detection of VHL deletions(Ciotti et al., 2009). Specific VHL gene mutations appear to correlate with clinical phenotype. About 95% of patients with VHL truncating or null mutations have VHL1 (without pheochromocytoma). In patients with VHL syndrome and pheochromocytoma(VHL2) 92-98% have missense mutations.

### 1.2.3 Neurofibromatosis type 1

Neurofibromatosis, or NF, is the term given to two neurocutaneous genetic conditions. Neurofibromatosis type 1, also known as von Recklinghausen's is the most common type of neurofibromatosis. The incidence of approximately 1 in 2600 to 1 in 3000 individuals (Lammert et al.,2005). Approximately one-half of the cases are familial; the remainder are new mutations (North K, 1993). The hallmarks of NF1 are the multiple café-au-lait spots (CALs) and associated cutaneous neurofibromas. Pheochromocytoma has been clinically identified in 0.1 to 5.7 percent of patients with NF. The NF1 gene has been mapped to chromosome 17q11.2 and cloned (ledbetter et al 1989; Shen et al., 1996; Feldkamp et al., 1998).

Mutations in the NF1 gene result in loss of functional protein, causing the wide spectrum of clinical findings including NF1-associated tumors.

No obvious genotype-phenotype correlation between small mutations (<20 base pairs) of the NF1 gene and a specific phenotype have been demonstrated, with the exception of the c.2970-2972 delAAT (p.M990del) mutation that is associated with a very mild phenotype in the majority of cases (Upadhyaya, et al., 2007).

Genetic testing for NF1 is available but is not routinely performed, as the diagnosis is made based upon clinical phenotype.

### 1.2.4 Familial paraganglioma

Initial suggestion of genetic clustering of paraganglioma tumors date back to 1930, but mode of inheritance which is to be autosomal dominant with maternal imprinting in some cases was found by Van Der Mey in 1989. Later, several familial clusters of pheochromocytoma/paraganglioma were described and defined as paraganglioma syndrome PGL1 through PGL4. PGL1 is to be related to mutation in the SDHD gene, PGL2 to SDH5, PGL3 to mutation in SDHC and PGL4 to SDHB. SDH-related tumorigenesis is believed to associate with hypoxia-inducible factor (HIF)/angiogenesis pathway (Kantorovich et al., 2010; López-Jiménez et al.,2010).

In this chapter three families with different forms of familial pheochromocytoma has been shown. All of the presented patients have had malignant pheochromocytoma and an unusual presentation.

## 2. Patients and data collection

Three families with familial pheochromocytoma were evaluated for past medical history and complete physical examination in endocrine ward, Shariati hospital, Tehran University of Medical science. The case-notes and hospital databases were examined for additional required data. The tumor size was taken as the widest diameter recorded on pathological report or radiological, if the tumor had not been removed. Operative reports were reviewed to determine intra operative findings and types of surgical procedures. If there was evidence of extra-adrenal disease and if additional organ resection was necessary, specific notes were made.

All pheochromocytomas in this study were arising from the adrenal gland and no extra adrenal or paraganglioma was included. Adrenal bed recurrence was not a criterion for malignancy. The metastases were documented in all malignant cases. Metastatic disease was defined as evidence of distant spread in tissue not normally containing chromaffin tissue i.e. bone, liver, lung or lymph nodes.

### 2.1 Biochemical testing and localization studies

Routine biochemical tests, evaluation of 24 hours urine catecholamine metabolites, abdominal computed tomography (CT) or magnetic resonance imaging (MRI) and/or 131 Iodine metaiodobenzylguanidine (MIBG) were done too. The malignant pheochromocytoma was diagnosed based on presence or absence of metastasis in radiological or pathological report.

### 2.2 Genetic analysis

#### 2.2.1 RET proto-oncogene mutation screening

Genetic screening tests were done in family members. RET proto-oncogene mutation screening for exons 10, 11, 13, 14, 15, 16 were examined by PCR and direct DNA sequencing. In patient 1, 4 and 5: Exons 10, 11, 13, 14, 15, and 16 RET proto-oncogene were examined by PCR and direct DNA sequencing (Alvandi et al., 2007).

#### 2.2.2 VHL gene mutation screening

For VHL gene mutation screening, analysis of VHL gene was performed using Cruz et al protocol (Hasani-Ranjbar et al., 2009; Cruz et al., 2007). Exons 1, 2, 3 of VHL gene was amplified by PCR with the following primers:

1F - 5' CCATCCTCTACCGAGCGCGCG 3';

1R - 5' GGGCTTCAGACCGTGCTATCG2;

3 F - 5' TGCCCAGCCACCGGTGTG 2;

3 R - 5' GTCTATCCTGTA CTTACCAACA;

3F - 5' CACACTGCCACATACATGCACTC 3';

3R - 5' ACTCATCAGTACCATCAAAAAGCTG 3'.

Both forward and reverse strands were subjected to direct sequencing after PCR amplification. (Hasani-Ranjbar et al., 2009).

### 2.3 Protein modeling

The PDB file 1LM8 and 1VCB were used in the modeling work in order to find the potential impact of the residue mutation on the protein structure. NCBI blast module was used to determine the degree of residue conservation. *In silico* mutation was achieved with Swiss-

PdbViewer v.4 and minimization of the structure was done with the use of NOMAD-Ref server (<http://lorentz.immstr.pasteur.fr/gromacs>) (Lindahl et al., 2006).

### 3. Results

#### 3.1 Family 1

The index patient was born to non related parents of Persian origin, Presented with thyroid nodule at the age of 48 years. His past medical history was unremarkable. He had no history of hypertensive crisis or headache. His daughter has had medullary thyroid cancer. And total thyroidectomy was done for her at the age of 23. Fine needle aspiration biopsy in the father was compatible with MTC and preoperational screening for pheochromocytoma was in favor of bilateral adrenal mass.

DNA was isolated from peripheral blood leucocytes using salting out method. Exons 10, 11, 13, 14, 15, 16 of RET proto-oncogene localized to 10q11.2 was examined by direct DNA sequencing. This resulted in identification of mutations in Exon 11, codon 634, TGC>CGC (Cystein>Arginine), which was indicative of hereditary MTC and Pheochromocytoma. The presence of this mutation was confirmed by sequencing of the complementary strand as well. This mutation was found in 2 other daughters and one of his sons and one of his nephews too.

One of the daughters (Figure 2, Patient 1) had thyroid nodule and complete evaluation was consistent with medullary thyroid cancer. Biochemical tests and radiological study for pheochromocytoma was done and the results were against adrenal mass. There was no evidence in favor of pheochromocytoma or Medullary thyroid cancer in three other RET proto-oncogen carriers. However total prophylactic thyroidectomy was done for all of them.

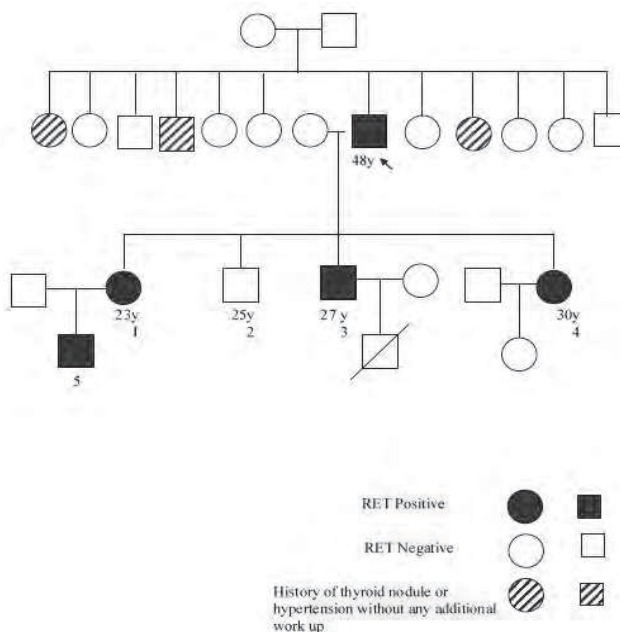


Fig. 2. Genetic relationship of multiple endocrine neoplasia type 2.

Bilateral adrenalectomy and then total thyroidectomy was done for the index patient (Figure 2, index patient). 2 years after bilateral adrenalectomy the patient presented with hypertention crisis and headache as he was on replacement therapy with prednisolon, Fludrocortisone and levothyroxine. Biochemical tests for pheochromocytoma and abdominal MRI was in favor of a 30 mm right adrenal mass. Evaluation for hyperparathyroidism was negative in all family members.

### 3.2 Family 2

Five sisters of Persian origin with grave clinical features of pheochromocytoma have been reported in our previous work (Hasani-Ranjbar et al, 2009). The index patient presented with cerebral hemorrhage and coma at the age of 29 years. After complete evaluation malignant metastatic pheochromocytoma confirmed and the patient was operated. Clinical manifestation of VHL, MEN syndrome and neurofibromatosis were negative in this patient and his family. Evaluation of other family members was consistent with malignant pheochromocytoma in four sisters. Bilateral adrenalectomy was done for them. 2 of these sisters died because of complication of pheochromocytoma.

#### 3.2.1 Genetic analysis

Genetic analysis of VHL gene was in favor of this syndromic pheochromocytoma. Sequence analysis of VHL gene exons showed presence of a missense mutation (499C>T in exon 3).

#### 3.2.2 Protein modeling

Arg 167 was found to be highly conserved among various species. Its mutation to tryptophan was observed to affect the hydrogen bondings of that residue within pVHL itself, and probably causing changes in the tertiary structure of the protein. *In silico* mutation of the residue and subsequent minimization of the Trp167 containing structure was performed and an overall RMSD of 0.519 Å was obtained for the mutated structure with the use of backbone only, and 0.597 Å with the use of all atoms. The most affected residue was found to be Leu 169 with RMSD of 1.902 (backbone) and 2.665 Å (all atoms). Figure 3 shows the position of Arg 167 in the pVHL tertiary structure (figure 3).

### 3.3 Family 3

A 45 year old man presented with abdominal pain and hypertension from 1 year ago. The patient was a known case of neurofibromatosis type 1 that presented at the age of 15 year with hyperpigmented and hypopigmented lesions in trunk, arms, feet and axillary areas. Family history was positive for neurofibromatosis in his mother and brother.

Biochemical tests and imaging was compatible with malignant pheochromocytoma. The size of mass was 120\*70 mm. Left adrenalectomy and nephrectomy and splenectomy were done for him. After surgery the symptoms improved and blood pressure was controlled. The patient had poor compliance in follow up.

After 5 years he was admitted again for evaluation of hypertensive crisis. Again biochemical tests were consistent with pheochromocytoma and relapse. Imaging study and liver biopsy confirmed metastatic pheochromocytoma to liver and para-aortic area. 131I-MIBG therapy was done for him.



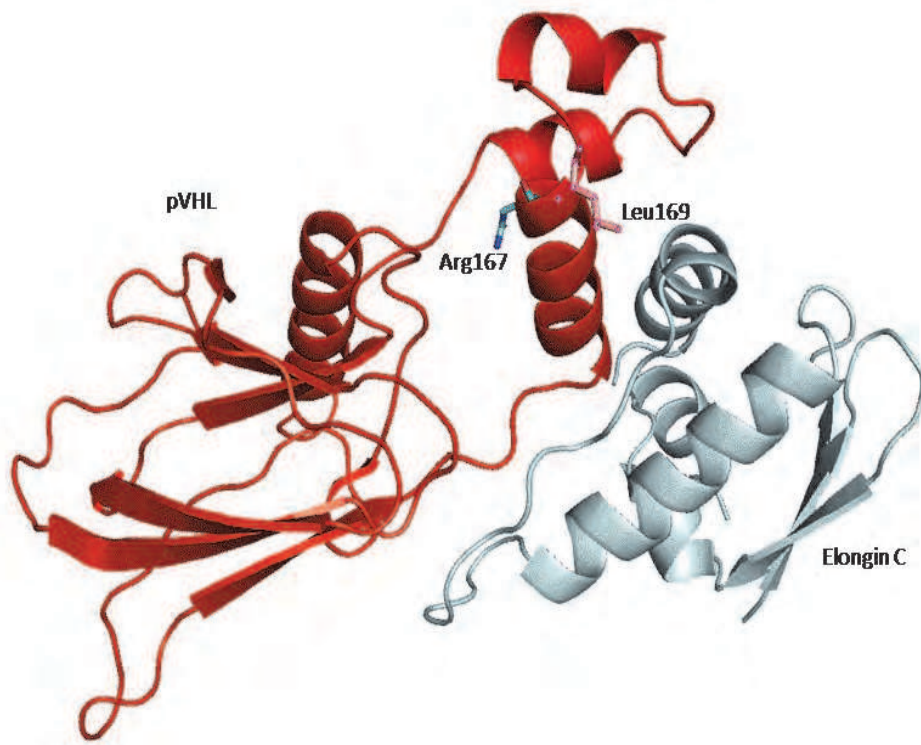


Fig. 3. pVHL (1LQB.PDB) is shown in cartoon representation, in the left part of the picture, interacting with Elongin C (right). The location of Arg 167 and Leu 169 residues is indicated with labels, and the residues are shown as sticks . Mutation of Arg 167 to Trp is suggested to affect both secondary and tertiary structure of pVHL. (This image has been created using PyMOL).

## 4. Discussion

Here we present three distinct families with intra adrenal pheochromocytoma (Table 2).

Subject	Family	Gender	Age at presentation	Clinical manifestation	Pheochromocytoma	Mutation	Treatment
1	1	M	48y	MTC	+	RET(codon 634, TGC>CGC)	Bilateral/Adrenalectomy/Total thyroidectomy
2	1	F	23y	MTC	-	RET(codon 634, TGC>CGC)	Total thyroidectomy
3	1	M	27y	No Symptom/No sign/MTC	-	RET(codon 634, TGC>CGC)	Prophylactic Total thyroidectomy
4	1	F	30y	No Symptom/No Sign	-	RET(codon 634, TGC>CGC)	Prophylactic Total thyroidectomy
5	1	M	2y	No Symptom/No Sign	-	RET(codon 634, TGC>CGC)	Prophylactic Total thyroidectomy
6	2	F	29y	Cerebral Hemorrhage	+ /Bilateral /Malignant	VHL Gene Mutation (499C>T)	Bilateral Adrenalectomy
7	2	F	23y	Malignant Hypertension	+ /Malignant	Died on Operation	-
8	2	F	21y	Cerebral Hemorrhage	+	Died before Operation	-
9	2	F	18y	Symptomatic and Hypertensive	+ /Bilateral/ malignant	VHL Gene Mutation (499C>T)	Bilateral Adrenalectomy
10	2	F	26y	Asymptomatic/biochemical tests+	+ /Bilateral/Malignant	VHL Gene Mutation (499C>T)	Bilateral Adrenalectomy
11	3	M	50y	Hypertensive	+ /Unilateral/Malignant	RET Negative VHL Negative	I131 MIBG Therapy

Abbreviations: VHL= von Hippel Lindau, MEN= multiple endocrine neoplasia, NF=Neurofibromatosis, Family 1=MEN2, Family 2= VHL, Family 3=NF, MTC=Medulary Thyroid Cancer, I131 MIBG = 131 Iodine\_metaiodobenzylguanidine

Table 2. Genetic mutations and disease phenotype in the MEN 2, VHL and NF1 families.

#### 4.1 Family 1

The index patient in family 1 who presented with thyroid nodule diagnosed as MEN 2 syndrome according to MTC and pheochromocytoma. The patient had no symptom or sign for pheochromocytoma. It is obviously known that when pheochromocytoma is associated with the multiple endocrine neoplasia type 2 (MEN2) syndrome, symptoms are present in only about one-half of patients and only one-third has hypertension (Pomares et al., 1998).

Evaluation for primary parathyroid hyperplasia was negative in him and his family. In addition no mucosal neuromas on the lips and tongue were detected. The patient had MEN2B phenotype. As we mentioned before, MEN2B shares the inherited predisposition to medullary thyroid cancer and pheochromocytoma that occurs in MEN2A. There are, however, important clinical differences. Patients with MEN2B tend to have mucosal neuromas and intestinal ganglioneuromas. Many of these patients have development abnormalities, a Marfanoid habitus, and myelinated corneal nerves. Furthermore, the tumor is often more aggressive and of earlier onset than in MEN2A; as a result, early diagnosis and prevention for other family members was very critical (Donovan et al., 1989; Mathew et al., 1987). Since MEN2B is caused by specific RET mutations we conducted genetic evaluation for categorization of the syndrome (MEN2A versus MEN2B) (Eng et al., 1996). The clinical feature was matched with MEN2B which is actually more aggressive. On the other hand genetic evaluation was consistent with a known mutation related to MEN2A in which prophylactic thyroidectomy is recommend to be done in carriers later. As we showed in results we identified mutations in Exon 11, codon 634, TGC>CGC (Cystein>Arginine), which was indicative of MEN2A syndrome.

The penetrance of hyperparathyroidism in those with mutations at this site is about 20 percent. Even with the same mutation the penetrance of hyperparathyroidism within families varies from 9 to 34 percent (Schunffenecker et al., 1998).

#### 4.2 Family 2

Family 2 is an unusual form of VHL syndrome with malignant intra adrenal pheochromocytoma and retinal angioma diagnosed as VHL type 2. Clinical manifestation of VHL, MEN syndrome and neurofibromatosis were negative in index patient and his family up to 9 years when retinal angioma was detected. All clinical manifestation and genetic and protein modeling methods have been described in our previous work which published in familial cancer journal (Hasani-Ranjbar et al., 2009).

In this paper we reported the presence of a novel single nucleotide mutation in exon 3 of VHL gene c499 C>T causing substitution of Arginine by Tryptophan at position 167 (R 167 W) (Hasani-Ranjbar et al., 2009). This family has been followed for at least 9 years as RET negative isolated familial pheochromocytoma, finally diagnosed as VHL disease according to retinal angioma and VHL gene mutation. As we noted before malignant pheochromocytoma is very rare in VHL disease and other familial forms of pheochromocytoma.

Although clinical criteria were originally developed for the diagnosis of VHL based upon the finding of more than one VHL-associated tumor, now detection of a germline mutation in the VHL gene is typically used to establish the diagnosis, particularly in patients with a single manifestation of the condition (Lonser et al., 2003).

On average about 10 to 20% of patients with VHL disease develop pheochromocytoma, but this incidence varies dramatically from family to family depending on the specific mutation (Koch et al., 2002; Karsdrop et al., 1994; Lamiell et al., 1989; Linehan et al., 1995)

In pheochromocytoma associated with von Hippel-Lindau disease, 35 percent of patients have no symptoms, a normal blood pressure, and normal laboratory values for fractionated catecholamines and metanephrines (Walter et al., 1999b). In our report all patients had aggressive disease and only one of the family members was asymptomatic diagnosed as adrenal pheochromocytoma based on screening tests (Table2)(Hasani-Ranjbar et al., 2009). Malignant pheochromocytomas are histologically and biochemically the same as benign ones. The only reliable clue to the presence of a malignant pheochromocytoma is local invasion or distant metastases, which may occur as long as 20 years after resection (Goldstein et al., 1999; Pattarino & Bouloux 1996).

A recent study showed high risk factors predictive factors of malignant pheochromocytoma include, large (5 cm or greater) or heavy (250 gm or greater) tumors, multifocal and extra-adrenal tumors, early onset postoperative hypertension and higher plasma or urine metadrenaline (Feng et al., 2011). An initial report suggests that inhibin/activin beta-B subunit expression may help distinguish between benign and malignant disease; expression was strong or moderate in almost all benign adrenal pheochromocytomas (Salmenkivi et al., 2001). Also, expression of the 3 angiogenesis or metastasis related genes VEGF, Cox-2 and MVD helps determine the diagnosis of malignancy and suggests strict followup (Gimenez-Roqueplo et al., 2003; Brouwers et al., 2006).

#### 4.2.1 Protein modeling

pVHL makes interactions with Elongin B and C, as well as HIF. The H1 helix of pVHL , where Arg 167 is located, is the interface between this protein and Elongin C, and a place where missense mutations occur frequently (Stebbinset et al., 1999). It seems that Arg 167 is involved in the correct positioning of the H1 helix, and that its mutation can also affect the hydrophobic interactions of Leu 168 with neighbour residues of Elongin C. the overall result is the disruption of some pVHL interactions with Elongin C (Figure 3).

#### 4.3 Family 3

Family 3 is a kindred with neurofibromatosis and a member (A 45 year old man) with hypertension diagnosed as malignant pheochromocytoma. Hypertension is a frequent finding in adults with NF1 and may develop during childhood but pheochromocytoma is a much less common etiology. In these patients, the catecholamine-secreting tumor is usually a solitary benign adrenal pheochromocytoma, occasionally bilateral adrenal pheochromocytoma, and rarely a peri adrenal abdominal paraganglioma . Although neurofibromatosis type 1 as an autosomal dominant disorder is the most common familial cancer syndrome predisposing to pheochromocytoma, the risk of pheochromocytoma in this disorder is about 1% (Huson et al 1989; Riccardi et al., 1991).

Pheochromocytomas in patients with neurofibromatosis type 1 occur at the fifth decade. Our patient was a 45 years old man with an unusual presentation of pheochromocytoma. Currently, except for the presence of the *SDHB* mutation, large size or an extra-adrenal location of the primary tumor, there are no reliable markers for predicting a high likelihood of developing metastatic disease. Pheochromocytoma in neurofibromatosis is usually benign and unilateral. Based on genetic background our expectation before surgery was a benign non metastatic tumor. As we mentioned before, the patient had a metastatic tumor and after 5 years metastasis to liver and para-aortic lymph nodes deteriorated the clinical course of disease. It seems to us that large mass (as detected in this patient firstly) beside local invasion is a critical predicting factor to malignancy and may have the highest impact for detecting metastasis in future.

At first we treated the patient with surgical resection of the adrenal mass, but in follow up for treatment of distant metastasis the only available modality was MIBG therapy. Considering positive MIBG scan we predicted that the tumor could up take iodine. To date, beside surgery, 131I-MIBG therapy is the single most valuable therapy for malignant pheochromocytomas. Results of a phase II trial using high dose I131 MIBG demonstrated 22% partial or complete response and 35% of patients having some degree of response (i.e. biochemical) without demonstrated progressive disease (Gonias et al.,2009). For future our plan could be chemoembolization of the liver if there is persistent disease.

## 5. Acknowledgment

We thank all the VHL, MEN and NF families and patients.

## 6. References

- Alvandi, E., Pedram, M., Soroush, A.R., Noori Naier, B., Akrami, S.M. (2007), Detection of RET Proto-oncogene Cys634Arg Mutation, the Cause of Medullary Thyroid Carcinoma, in an Iranian Child. *Iran J Pediatr Suppl*,2, 301
- Brandi, M.L., Gagel, R.F., Angeli, A., Bilezikian, J.P., Beck-Peccoz, P., Bordi, C., Conte-Devolx, B., Falchetti, A., Gheri, R.G., Libroia, A., Lips, C.J., Lombardi, G., Mannelli, M., Pacini, F., Ponder, B.A., Raue, F., Skogseid, B., Tamburrano, G., Thakker, R.V., Thompson, N.W., Tomassetti, P., Tonelli, F., Wells, S.A. Jr., Marx, S.J., (2001),Guidelines for diagnosis and therapy of MEN type 1 and type 2. *J Clin Endocrinol Metab*, 86,12,5658.
- Brouwers, F.M., Eisenhofer, G., Tao, J.J., Kant, J.A., Adams, K.T., Linehan, W.M., Pacak, K.,(2006), High frequency of SDHB germline mutations in patients with malignant catecholamine-producing paragangliomas: implications for genetic testing. *J Clin Endocrinol Metab*,91,11,4505.
- Carlson, K.M., Dou, S., Chi, D., Scavarda, N., Toshima, K., Jackson, C.E., Wells, S.A. Jr., Goodfellow, P.J., Donis-Keller, H., (1994),Single missense mutation in the tyrosine kinase catalytic domain of the RET protooncogene is associated with multiple endocrine neoplasia type 2B, *Proc Natl Acad Sci U S A*, 91,4,1579-83.
- Ciotti, P., Garuti, A., Gulli, R., Ballestrero, A., Bellone ,E., Mandich, P.,(2009), Germline mutations in the von Hippel-Lindau gene in Italian patients. *Eur J Med Genet.*,52,5,311-4. Epub 2009 May 21.
- Cruz, J.B., Fernandes, L.P., Clara, S.A., Conde, S.J., Perone, D., Kopp, P., Nogueira, C.R., (2007), Molecular analysis of the Von Hippel-Lindau (VHL) gene in a family with non-syndromic pheochromocytoma: the importance of genetic testing. *Arq Bras Endocrinol Metabol* , 51,1463-1467.
- Donovan, D.T., Levy, M.L., Furst, E.J., Alford, B.R., Wheeler, T., Tschen, J.A., Gagel, R.F. (1989),Familial cutaneous lichen amyloidosis in association with multiple endocrine neoplasia type 2A: a new variant. *Henry Ford Hosp Med J*,37,3-4,147.
- Dluhy, R.G.,(2002), Pheochromocytoma--death of an axiom. *N Engl J Med*, 346,19,1486.
- Elder, E.E., G. Elder, and C. Larsson, (2005),Pheochromocytoma and functional paraganglioma syndrome: no longer the 10% tumor. *J Surg Oncol*, 89,3, 193-201.
- Eng, C., Clayton, D., Schuffenecker, I., Lenoir, G., Cote, G., Gagel, R.F., van Amstel, H.K., Lips, C.J., Nishisho, I., Takai, S.I., Marsh, D.J., Robinson, B.G., Frank-Raue, K., Raue, F., Xue, F., Noll, W.W., Romei, C., Pacini, F., Fink, M., Niederle, B., Zedenius, J., Nordenskjöld, M., Komminoth, P., Hendy, G.N., Mulligan, L.M.,(1996), The

- relationship between specific RET proto-oncogene mutations and disease phenotype in multiple endocrine neoplasia type 2. International RET mutation consortium analysis. *JAMA*,276,19,1575.
- Eng, C., Guillausseau, P.J., Lenoir, G.M., (1998), Risk and penetrance of primary hyperparathyroidism in multiple endocrine neoplasia type 2A families with mutations at codon 634 of the RET proto-oncogene. Groupe D'etude des Tumeurs à Calcitonine. *J Clin Endocrinol Metab*,83,2,487.
- Feldkamp, M.M., Gutmann, D.H., Guha, A.,(1998), Neurofibromatosis type 1: piecing the puzzle together. *Can J Neurol Sci*, 25,3,181.
- Feng, F., Zhu, Y., Wang, X., Wu, Y., Zhou, W., Jin, X., Zhang, R., Sun, F., Kasoma, Z., Shen, Z. (2011), Predictive Factors for Malignant Pheochromocytoma: Analysis of 136 Patients. *J Urol*, Mar 16
- Gonias, S., Goldsby, R., Matthay, K.K., Hawkins, R., Price, D., Huberty, J., Damon, L., Linker, C., Sznewajcs, A., Shiboski, S., Fitzgerald, P.,(2009), Phase II study of high-dose [<sup>131</sup>I]metaiodobenzylguanidine therapy for patients with metastatic pheochromocytoma and paraganglioma. *J Clin Oncol* ,1,27,25,4162-8. Epub 2009 Jul 27
- Gimenez-Roqueplo, A.P., Favier, J., Rustin, P., Rieubland, C., Crespin, M., Nau, V., Khau, Van Kien, P., Corvol, P., Plouin, P.F., Jeunemaitre, X., (2003), COMETE Network ,Mutations in the SDHB gene are associated with extra-adrenal and/or malignant pheochromocytomas. *Cancer Res*,63,17,5615.
- Goldstein, R.E., O'Neill, J.A. Jr., Holcomb, G.W. 3rd, Morgan, W.M. 3rd, Neblett, W.W. 3rd, Oates, J.A., Brown, N., Nadeau, J., Smith, B., Page, D.L., Abumrad, N.N., Scott, H.W. Jr.,(1999), Clinical experience over 48 years with pheochromocytoma. *Ann Surg*,229,6,755-64; discussion 764-6
- Gomy, I., Molfetta, G.A., de Andrade Barreto, E., Ferreira, C.A., Zanette, D.L., Casali-da-Rocha, J.C., Silva, W.A. Jr.(2010), Clinical and molecular characterization of Brazilian families with von Hippel-Lindau disease: a need for delineating genotype-phenotype correlation. *Fam Cancer*, 2010 ,9,4,635-42.
- Hasani-Ranjbar, S., Amoli, M.M., Ebrahim-Habibi, A., Haghpanah, V., Hejazi, M., Soltani, A., Larijani, B.,(2009), Mutation screening of VHL gene in a family with malignant bilateral pheochromocytoma: from isolated familial pheochromocytoma to von Hippel-Lindau disease. *Fam Cancer*,8,4,465-71. Epub 2009 Aug 1.
- Hasani-Ranjbar, S., Amoli, M.M., Ebrahim-Habibi, A., Gozashti, M.H., Khalili, N., Sayyahpour, F.A., Hafeziyeh, J., Soltani, A., Larijani, B.,(2010), A new frameshift MEN1 gene mutation associated with familial malignant insulinomas. *Fam Cancer*, Dec 24.
- Hachen, R., Barnicoat, A., Li, H., Wallace, P., Van Biervliet, J.P., Stevenson, D., Viskochil, D., Baralle, D., Haan, E., Riccardi, V., Turnpenny, P., Lazaro, C., Messiaen, L., (2007), An absence of cutaneous neurofibromas associated with a 3-bp inframe deletion in exon 17 of the NF1 gene (c.2970-2972 delAAT): evidence of a clinically significant NF1 genotype-phenotype correlation. *Am J Hum Genet*, 80,1,140.
- Huson, S.M., Compston, D.A., Clark, P., Harper, P.S., (1989), A genetic study of von Recklinghausen neurofibromatosis in south east Wales. I. Prevalence, fitness, mutation rate, and effect of parental transmission on severity, *J Med Genet*, 26,11, 704-11.
- Kantorovich, V., King, K.S., Pacak, K.,(2010), SDH-related pheochromocytoma and paraganglioma. *Best Pract Res Clin Endocrinol Metab*,24,3,415-24.

- Karsdorp, N., et al., Von Hippel-Lindau disease: new strategies in early detection and treatment. *Am J Med*, 1994. 97(2): p. 158-68.
- Koch, C.A., Huang, S.C., Zhuang, Z., Stolle, C., Azumi, N., Chrousos, G.P., Vortmeyer, A.O., Pacak, K., (2002), Somatic VHL gene deletion and point mutation in MEN 2A-associated pheochromocytoma. *Oncogene*, 21,3, 479-82.
- Kim, W.Y., Kaelin, W.G. (2004) Role of VHL gene mutation in human cancer. *J Clin Oncol*, 22, 4991-5004 .
- Lammert, M., Friedman, J.M., Kluwe, L., Mautner, V.F.,(2005), Prevalence of neurofibromatosis 1 in German children at elementary school enrollment. *Arch Dermatol*, 141,1,71.
- Lamiell, J.M., Salazar F.G., & Hsia Y.E. (1989), von Hippel-Lindau disease affecting 43 members of a single kindred. *Medicine (Baltimore)*, 68,1, 1-29.
- Linehan, W., Lerman, M. & Zbar, B., (1995), Identification of the VHL Gene: Its Role in Renal Carcinoma, *JAMA*, 273, 564-570.
- Ledbetter, D.H., Rich, D.C., O'Connell, P., Leppert, M., Carey, J.C., (1989), Precise localization of NF1 to 17q11.2 by balanced translocation. *Am J Hum Genet*, 44,1,20.
- Lenders, J.W., Eisenhofer, G., Mannelli, M., Pacak, K., (2005), Pheochromocytoma. *Lancet*, 20-26,366(9486),665-75.
- Lindahl, E., Azuara, C., Koehl, P., Delarue, M., (2006) NOMAD-Ref: visualization, deformation and refinement of macromolecular structures based on all-atom normal mode analysis. *Nucleic Acids Res*, 34,W52-W56].
- Lonser, R.R., Glenn, G.M., Walther, M., Chew, E.Y., Libutti, S.K., Linehan, W.M., Oldfield, E.H. (2003), von Hippel-Lindau disease. *Lancet*, 361,9374,2059.
- López-Jiménez, E., Gómez-López, G., Leandro-García, L.J., Muñoz, I., Schiavi, F., Montero-Conde, C., de Cubas, A.A., Ramires, R., Landa, I., Leskelä, S., Maliszewska, A., Inglada-Pérez, L., de la Vega, L., Rodríguez-Antona, C., Letón, R., Bernal, C., de Campos, J.M., Díez-Tascón, C., Fraga, M.F., Boullosa, C., Pisano, D.G., Opocher, G., Robledo, M., Cascón, A. (2010), Research resource: Transcriptional profiling reveals different pseudohypoxic signatures in SDHB and VHL-related pheochromocytomas. *Mol Endocrinol*. 24,12,2382-91. Epub 2010 Oct 27.
- Mathew, C.G., Chin, K.S., Easton, D.F., Thorpe, K., Carter, C., Liou, G.I., Fong, S.L., Bridges, C.D., Haak, H., Kruseman, A.C., (1987), A linked genetic marker for multiple endocrine neoplasia type 2A on chromosome 10. *Nature*, 328,6130,527.
- Manger, W.M. & Gifford, R.W., (2002), Pheochromocytoma. *J Clin Hypertens*, 4,1, 62-72.
- Mulligan, L.M., Eng, C., Healey, C.S., Clayton, D., Kwok, J.B., Gardner, E., Ponder, M.A., Frilling, A., Jackson, C.E., Lehnert, H., (1994), Specific mutations of the RET proto-oncogene are related to disease phenotype in MEN 2A and FMTC. *Nat Genet*, 6,1,70.
- Neumann, H.P., Bausch, B., McWhinney, S.R., Bender, B.U., Gimm, O., Franke, G., Schipper, J., Klisch, J., Althoefer, C., Zerres, K., Januszewicz, A., Eng, C., Smith, W.M., Munk, R., Manz, T., Glaesker, S., Apel, T.W., Treier, M., Reineke, M., Walz, M.K., Hoang-Vu, C., Brauckhoff, M., Klein-Franke, A., Klose, P., Schmidt, H., Maier-Woelfle, M., Peçzkowska, M., Szmigielski, C., Eng, C., Freiburg-Warsaw-Columbus (2002), Pheochromocytoma Study Group, Germ-line mutations in nonsyndromic pheochromocytoma. *N Engl J Med*, 346,19,1459.
- Neumann, H.P., Berger, D.P., Sigmund, G., Blum, U., Schmidt, D., Parmer, R.J., Volk, B., Kirste, G., (1993), Pheochromocytomas, multiple endocrine neoplasia type 2, and von Hippel-Lindau disease. *N Engl J Med*, 329,21,1531.
- North, K. (1993), Neurofibromatosis type 1: review of the first 200 patients in an Australian clinic. *J Child Neurol*. 8,4,395.

- O'Riordain, D.S., Young, W.F. Jr., Grant, C.S., Carney, J.A., van Heerden, J.A., (1996), Clinical spectrum and outcome of functional extraadrenal paraganglioma. *World J Surg*, 20,7, 916-21.
- Pacak, K., Ilias, I., Adams, K.T., Eisenhofer, G., (2005), Biochemical diagnosis, localization and management of pheochromocytoma: focus on multiple endocrine neoplasia type 2 in relation to other hereditary syndromes and sporadic forms of the tumour. *J Intern Med*, 2005, 257,1,60-8.
- Pattarino, F., Bouloux, P.M. (1996), The diagnosis of malignancy in pheochromocytoma. *Clin Endocrinol (Oxf)*, 44,239.
- Patocs, A., Gergics, P., Balogh, K., Toth, M., Fazakas, F., Liko, I., Racz, K., (2008) Ser80Ile mutation and a concurrent Pro25Leu variant of the VHL gene in an extended Hungarian von Hippel-Lindau family, *BMC Med Genet*, 9, 29.
- Pomares, F.J., Cañas, R., Rodriguez, J.M., Hernandez, A.M., Parrilla, P., Tebar, F.J., (1998), Differences between sporadic and multiple endocrine neoplasia type 2A pheochromocytoma. *Clin Endocrinol (Oxf)*, 48,195.
- Riccardi, V.M., (1991), Neurofibromatosis: past, present, and future. *N Engl J Med*, 324,18, 1283-5.
- Salmenkivi, K., Arola, J., Voutilainen, R., Ilvesmäki, V., Haglund, C., Kahri, A.I., Heikkilä, P., Liu, J., (2001), Inhibin/activin betaB-subunit expression in pheochromocytomas favors benign diagnosis. *J Clin Endocrinol Metab*, 86,5,2231.
- Schuffenecker, I., Virally-Monod, M., Brohet, R., Goldgar, D., Conte-Devolx, B., Leclerc, L., Chabre, O., Boneu, A., Caron, J., Houdent, C., Modigliani, E., Rohmer, V., Schlumberger, M.,
- Shen, M.H., Harper, P.S., Upadhyaya, M., (1996), Molecular genetics of neurofibromatosis type 1 (NF1). *J Med Genet*, 33,1,2.
- Upadhyaya, M., Huson, S.M., Davies, M., Thomas, N., Chuzhanova, N., Giovannini, S., Evans, D.G., Howard, E., Kerr, B., Griffiths, S., Consoli, C., Side, L., Adams, D., Pierpont, M.,
- Strong, V.E., Kennedy, T., Al-Ahmadie, H., Tang, L., Coleman, J., Fong, Y., Brennan, M., Ghossein, R.A., (2008), Prognostic indicators of malignancy in adrenal pheochromocytomas: clinical, histopathologic, and cell cycle/apoptosis gene expression analysis. *Surgery*, 143,6,759-68. Epub 2008 Apr 14.
- Stebbins, C.E., Kaelin, W.G., Pavlevitch, N.P., (1999) Structure of the VHL-ElonginC-ElonginB complex: implications for VHL tumor suppressor function. *Science*, 284:455-461.
- Walther, M.M., Herring, J., Enquist, E., Keiser, H.R., Linehan, W.M., (1999a), von Recklinghausen's disease and pheochromocytomas. *J Urol*, 162,5,1582.
- Walther, M.M., Reiter, R., Keiser, H.R., Choyke, P.L., Venzon, D., Hurley, K., Gnarr, J.R., Reynolds, J.C., Glenn, G.M., Zbar, B., Linehan, W.M., (1999b), Clinical and genetic characterization of pheochromocytoma in von Hippel-Lindau families: comparison with sporadic pheochromocytoma gives insight into natural history of pheochromocytoma. *J Urol*, 162,3, (Pt 1),659-64.
- Whalen, R.K., Althausen, A.F., Daniels, G.H. (1992), Extra-adrenal pheochromocytoma. *J Urol*, 147, 1-10.
- Zbar, B., Kishida, T., Chen, F., Schmidt, L., Maher, E.R., Richards, F.M., Crossey, P.A., Webster, A.R., Affara, N.A., Ferguson-Smith, M.A., Brauch, H., Glavac, D., Neumann, H.P., Tisherman, S., Mulvihill, J.J., Gross, D.J., Shuin, T., Whaley, J., Seizinger, B., Kley, N., Olschwang, S., Boisson, C., Richard, S., Lips, C.H., Lerman, M., (1996), Germline mutations in the Von Hippel-Lindau disease (VHL) gene in families from North America, Europe, and Japan. *Hum Mutat*, 8,4,348.





## **Pheochromocytoma - A New View of the Old Problem**

Edited by Dr. Jose Fernando Martin

ISBN 978-953-307-822-9

Hard cover, 164 pages

**Publisher** InTech

**Published online** 16, December, 2011

**Published in print edition** December, 2011

The book is divided into six sections. The first three sections focus on the pathophysiology of the disease, showing anatomo- and histopathological aspects, experimental models and signaling pathways and programmed cell death related to pheochromocytoma. The fourth discusses some specific aspects of clinical presentation, with emphasis on clinical manifestations of headache and heart. The fifth section focuses on clinical diagnosis, laboratory and imaging, including differential diagnosis. Finally, the last section discusses the treatment of pheochromocytoma showing clinical cases, a case about undiagnosed pheochromocytoma complicated with multiple organ failure and other cases about catecholamine-secreting hereditary tumors. Thus, this book shows the disease "pheochromocytoma" in a different perspective from the traditional approach. Enjoy your reading.

### **How to reference**

In order to correctly reference this scholarly work, feel free to copy and paste the following:

Shirin Hasani-Ranjbar, Azadeh Ebrahim-Habibi and Bagher Larijani (2011). Familial Catecholamine-Secreting Tumors - Three Distinct Families with Hereditary Pheochromocytoma, Pheochromocytoma - A New View of the Old Problem, Dr. Jose Fernando Martin (Ed.), ISBN: 978-953-307-822-9, InTech, Available from: <http://www.intechopen.com/books/pheochromocytoma-a-new-view-of-the-old-problem/familial-catecholamine-secreting-tumors-three-distinct-families-with-hereditary-pheochromocytoma>

**INTECH**  
open science | open minds

### **InTech Europe**

University Campus STeP Ri  
Slavka Krautzeka 83/A  
51000 Rijeka, Croatia  
Phone: +385 (51) 770 447  
Fax: +385 (51) 686 166  
[www.intechopen.com](http://www.intechopen.com)

### **InTech China**

Unit 405, Office Block, Hotel Equatorial Shanghai  
No.65, Yan An Road (West), Shanghai, 200040, China  
中国上海市延安西路65号上海国际贵都大饭店办公楼405单元  
Phone: +86-21-62489820  
Fax: +86-21-62489821

© 2011 The Author(s). Licensee IntechOpen. This is an open access article distributed under the terms of the [Creative Commons Attribution 3.0 License](#), which permits unrestricted use, distribution, and reproduction in any medium, provided the original work is properly cited.