

Arthroscopy Following Total Knee Replacement

Vaibhav Bagaria¹, Jami Ilyas², Bhawan Paunipagar³,
Darshna Rasalkar⁴ and Rohit Lal⁵

¹Columbia Asia Hospital and ORIGYN Clinic, Ghaziabad,

²Royal Perth Hospital, Perth,

³Department of Diagnostic Radiology and
Organ Imaging Prince of Wales Hospital and Child Cancer Centre,

⁴Kokilaben Dhirubhai Ambani Hospital, Mumbai,

⁵ORIGYN Clinic, INDIRAPURAM, Ghaziabad,

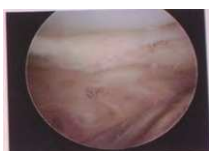^{1,4,5}India

²Australia

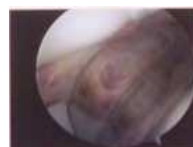³Hong Kong

1. Introduction

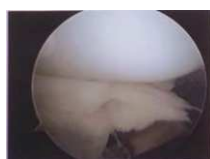
Total Knee replacement although an extremely successful procedure is occasionally complicated by conditions such as pain of unknown etiology, clunk and stiffness. Diagnosing and managing the patients with pain and dysfunction following joint replacement is difficult and can be challenging. The underlying cause could be impinging soft tissue under the patella with the clunk syndrome, impinging hypertrophic synovitis elsewhere in the knee, impinging PCL stump, prosthesis loosening and wear, arthrofibrosis and subclinical infections.



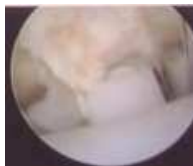a. Medial Aspect of knee



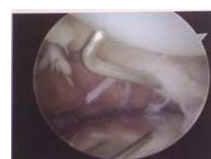b. Patella with femoral Component.



c. Hypertrophied
Synovium



d. Poly Insert with Cam



e. Suprapatellar pouch

Fig. 1a. Normal Arthroscopic appearance after TKR

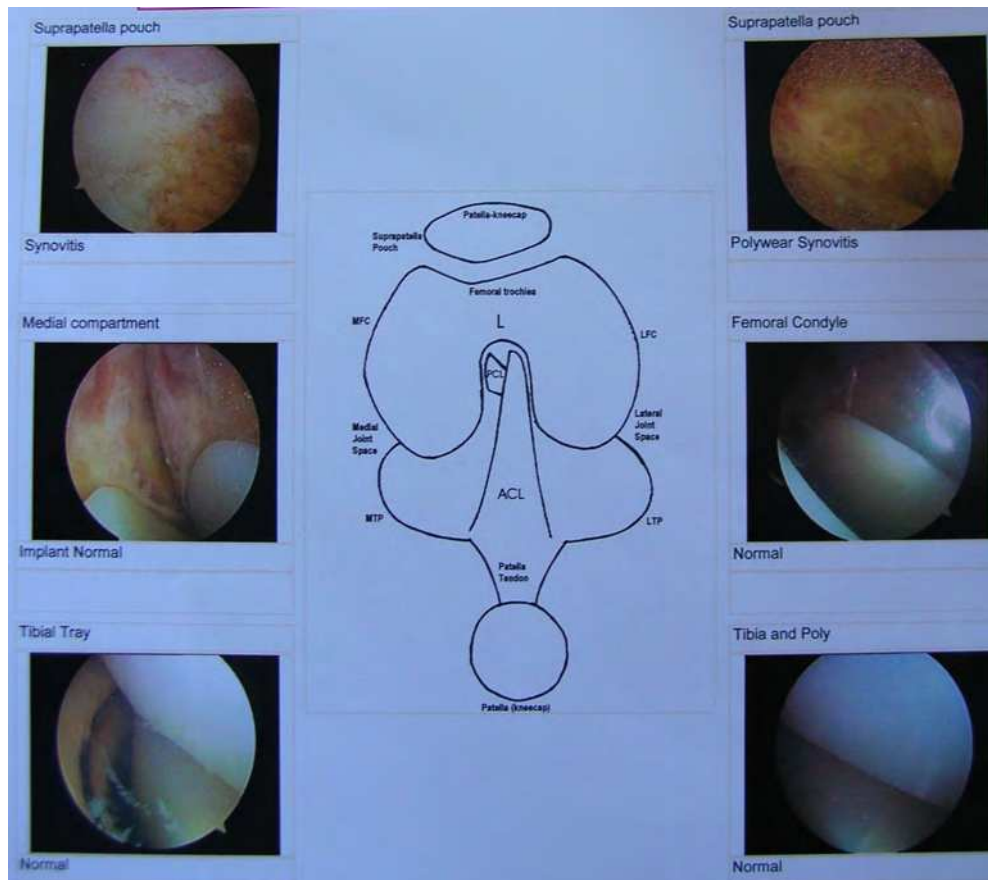


Fig. 1b. Sequence of arthroscopic examination of Knee post TKR is usually same as normal Knee - Patellofemoral joint, Medial compartment, Intercondylar notch, lateral compartment. Extra precaution needs to be taken while handling scope so as not to damage or scratch the metal surface. It could also be technically challenging in tight knees and due to scarring around knee.

Many of the problems can be diagnosed after clinical examination, radiography, bone scan and aspiration. Most of the remaining conditions can be resolved (except infection) using arthroscopic techniques. The chapter describes the indications and surgical techniques for arthroscopy following the knee replacement, along with a description of the various conditions that can be encountered. Arthroscopic images of arthroscopy after knee replacement are also included for teaching purposes.

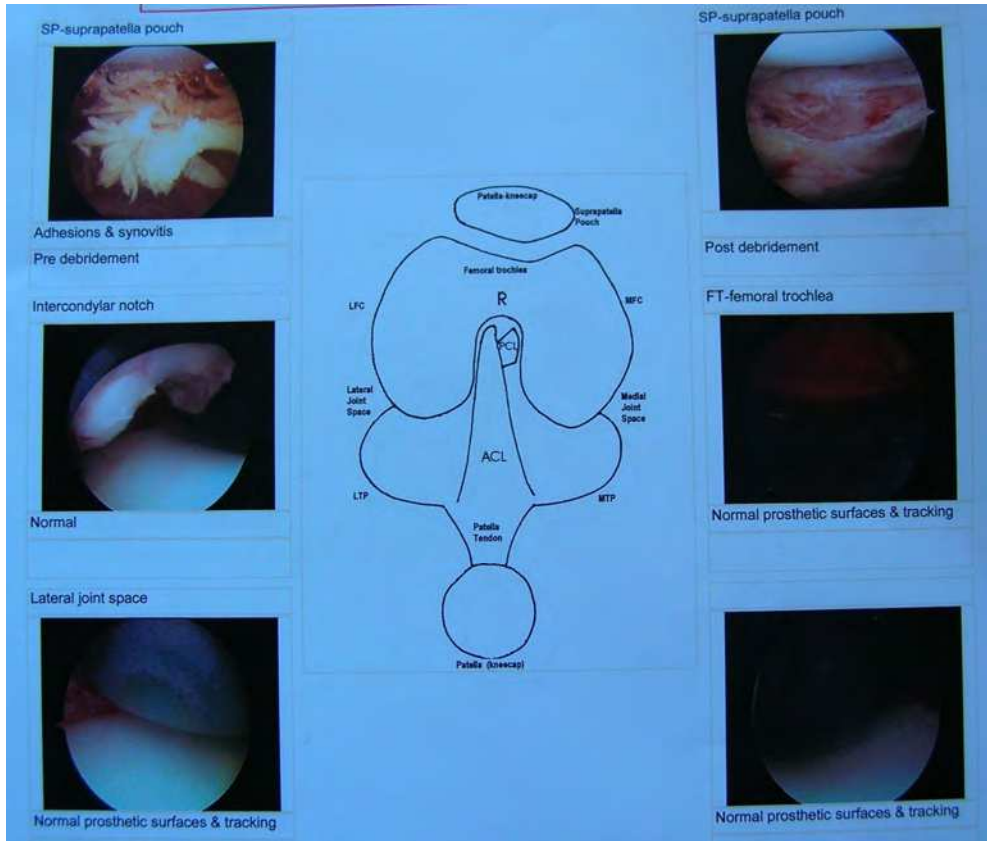


Fig. 2. Ceramic Knee – Arthroscopic appearance

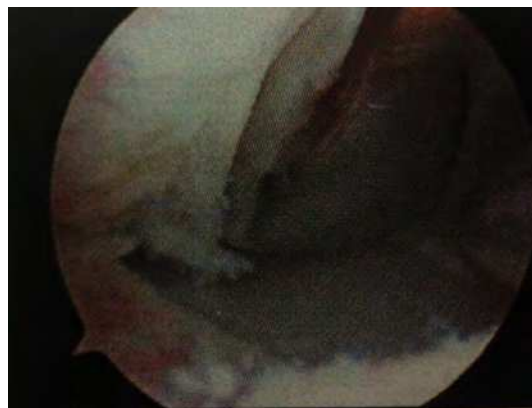

Fig. 3. Unicompartmental Knee Replacement – Arthroscopy Appearance.

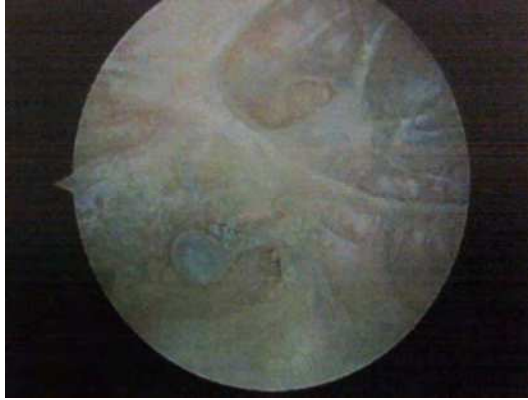

Fig. 4.1. Painful TKR without any clinically identifiable cause. O Arthroscopy synovium showed signs of metallosis.

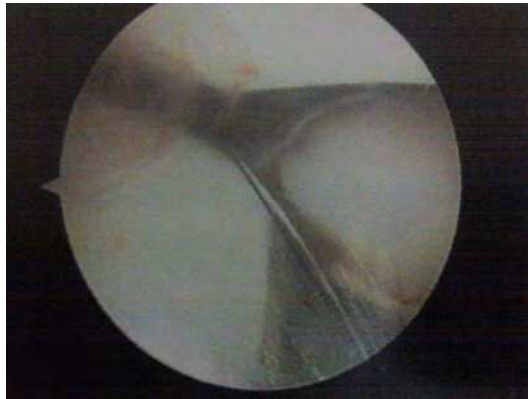

Fig. 4.2. Note the scratches on the metal surface of the same knee.



Fig. 4.3. Same knee implant at the time of revision. The knee was a part of global recall. Note the scratches on the tibial base plates

2. Arthrofibrosis

The incidence of arthrofibrosis or stiffness following TKR varies considerably and has been cited to be between 1 and 11%. Arthrofibrosis or knee stiffness is clinically defined as an inadequate range of movement that results in functional limitations affecting activities of daily living. The cutoff range of motion (ROM) for which stiffness requires surgical treatment is defined as having a flexion contracture of 15 degrees or flexion of less than 75 degrees. This decreased range of movement can severely affect the patient's ability to perform tasks of daily living such as walking, climbing stairs, or getting up from a seated position. Biomechanical studies and gait analysis have shown that patients required 67 degrees of knee flexion during the swing phase of gait, 83 degrees of flexion to climb stairs, 90- 100 degrees of flexion to descend stairs, and 93 degrees of flexion to stand from a seated position

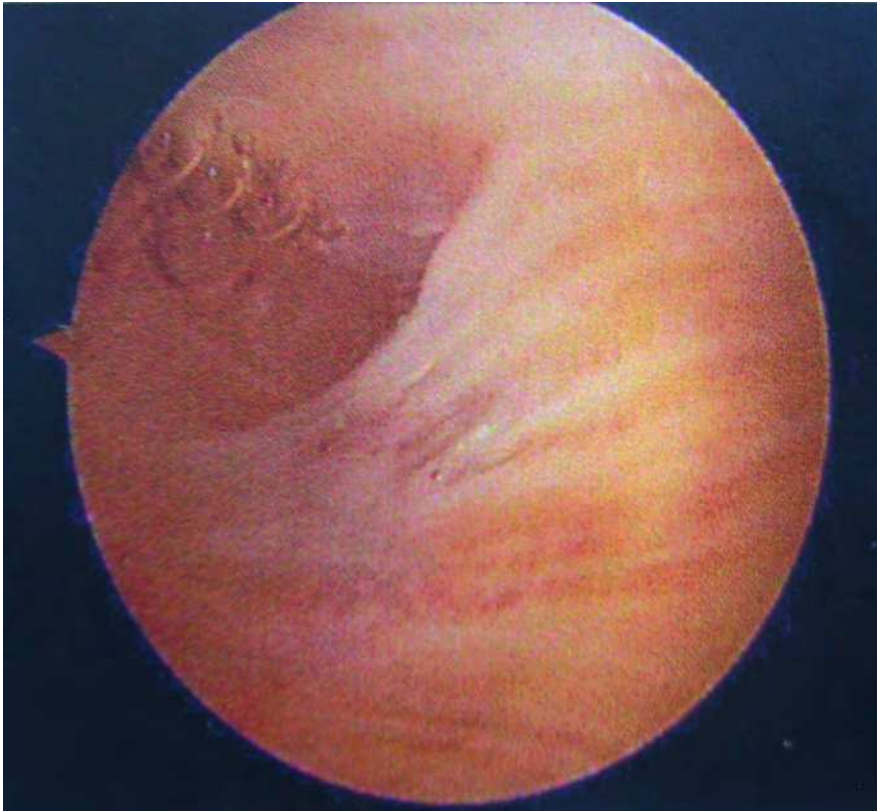

Fig. 5. Adhesion in suprapatellar pouch.

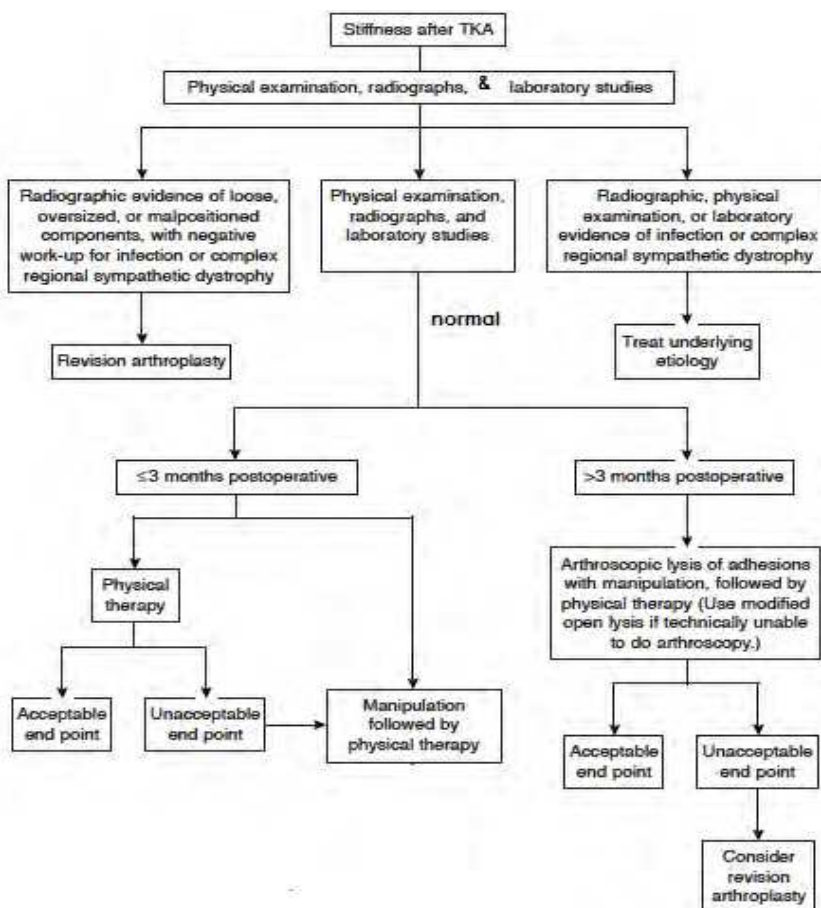
2.1

Arthrofibrosis may be secondary to numerous factors, including limited preoperative range of motion, faulty surgical technique, incorrect sizing, inappropriate implant placement, or inadequate postoperative rehabilitation and limiting motion until wound healing occurs. It could be also due to a biological predilection as some patients may be predisposed to

extensive scar tissue formation as a response to the tissue trauma itself, which occurs during total knee replacement.

2.2

Managing stiff knee involve a thorough clinical exam to rule out any extrinsic contributing factor, ruling out infection and revisiting the surgical notes to identify any surgery related causes. One of the important aspects is identifying or excluding low grade infections. Initial step in managing these cases is a step by step incremental rehabilitation program. If this fails, a closed manipulation may be the next step. Recalcitrant cases may require arthroscopic or open arthrolysis. Arthroscopic management allows minimally invasive access to focal lesions (e.g. nodules, loose bodies) and is helpful in addressing cases of severe diffuse arthrofibrosis refractory to closed methods as well as in avoiding potential catastrophic complications associated with manipulation alone. Arthroscopic treatment of painful knee arthroplasty provides reliable expectations for improvement in function, decrease in pain, and improvement in knee scores.



Flowchart for management of Arthrofibrosis after TKR

2.3

Performing arthroscopy for arthrofibrosis however may be a technically demanding. Insertion of the arthroscope into a markedly stiff knee with an arthro-fibrotic patello-femoral compartment can be challenging and one posing potential risk of damaging the prosthesis. Arthroscopic debridement of adhesions in combination with manipulation has been shown to substantially improve knee range of movement in patients with postoperative arthrofibrosis resulting from surgical procedures other than TKA. However, arthroscopic lysis of adhesions after TKA has not been as successful as lysis after procedures other than TKA. Bocell et al observed that only two of seven patients maintained pain-free improvements in range of movement after arthroscopic debridement of arthrofibrosis and manipulation after TKA. Campbell observed an increase in flexion of only 11° and an increase in extension of only 5.5° in eight patients 1 year after arthroscopy. Others have reported more marked improvements in range of movement. After arthroscopic debridement and manipulation, Diduch et al reported a 26° improvement in mean flexion in eight patients, and Scranton observed a 31° gain in mean range of movement; however, neither study examined the effect of arthroscopy on flexion contractures. Bae et al reported a mean improvement of 42° in the total arc of motion at 1-year follow-up in 13 knees; the improvement in flexion contractures was less clear. Patients with flexion limitations who receive a PCL-retaining total knee component may benefit from arthroscopic release of the PCL. Williams et. al observed an increase in mean flexion of 30° and an improvement in mean knee extension from 4° to 1.5° at 20-month follow-up in 10 knees after arthroscopic PCL release. When adhesions are more extensive, electro-cautery, arthroscopic scissors, and large-radius shavers can be used to debride the supra-patellar pouch and the medial and lateral gutters.

Study	Number of Patients (Knees)	Technique	Time from TKA to Secondary Surgery (Months)	Total Gain in Range of Motion (Degrees)	Time to Follow-up (Months)
Williams et al	9 (10)	PCL release	29	30°	20
Campbell	8 (8)	Lysis	11.6	16.5°	12
Diduch et al	8 (8)	Lysis	7.4	26°	20
Bae et al	11 (13)	Lysis	20	42°	12
Sprague et al	1 (1)	Lysis	12	23°	3
Scranton et al	7 (7)	Lysis	N/A	31°	12
Scranton et al	4 (4)	Modified Open	N/A	62°	12
Nicholls & Dorr	12 (13)	Revision	N/A	33°	N/A
Ries & Badalamente	5 (6)	Revision	20	50°	33
Babis et al	7 (7)	Open Lysis with Tib. Insert Exchange	12	28°	50

2.4

Loss of knee flexion often indicates involvement of the supra-patellar pouch, patello-femoral joint or anterior interval. Involvement of the intercondylar notch can affect both flexion and extension. Extension loss can result from intra-articular nodules and arthrofibrosis of the posterior capsule.

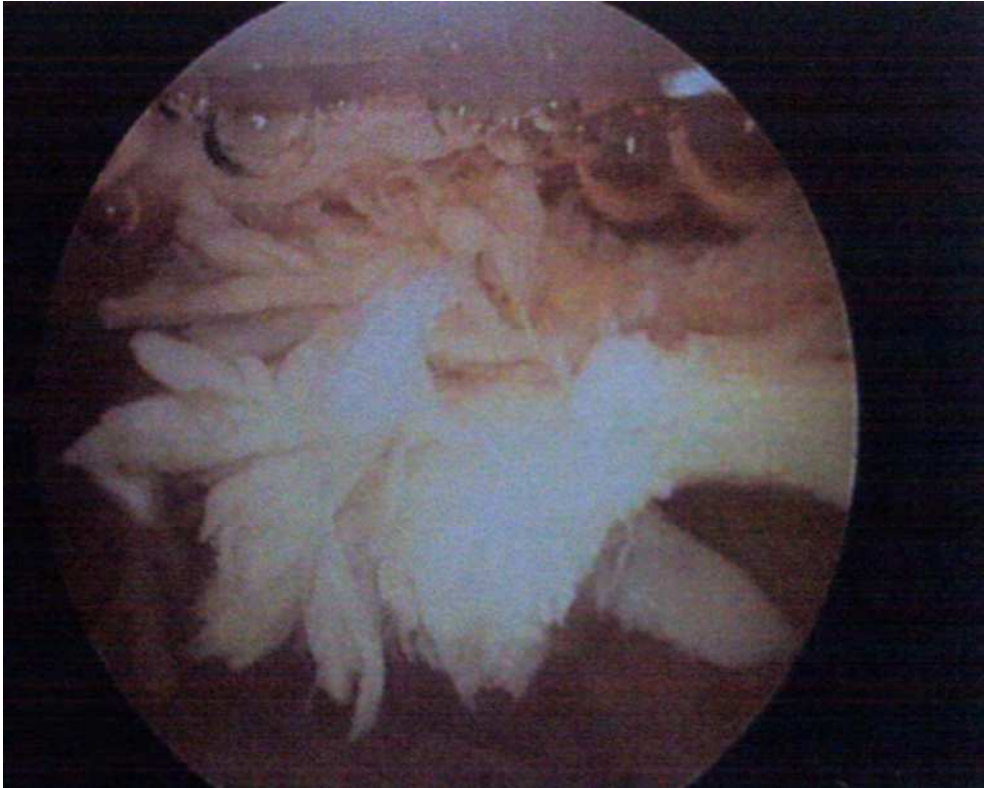

Fig. 6. Suprapatellar pouch with adhesion and synovitis

Kim et al (Ref) described a systematic approach when performing arthroscopic debridement of an arthrofibrotic knee. The use of regional anesthesia can effectively manage perioperative pain and facilitate postoperative rehabilitation (Ref: Millet). Prior to portal placement; capsular distention is achieved by saline injection into the supra-patellar pouch. Arthroscopy of prosthetic knees is initially approached through the conventional anterior-medial and anterior-lateral portals. If necessary, additional superolateral or superomedial portals can be utilized. Extreme care must be exercised when trocars and other instruments are inserted or manipulated in the joint, so as not to scratch the metallic surfaces or the polyethylene. Raab et al noted in an in vitro study, that a stainless steel cannulae could produce surface alterations in the femoral component with loads as small as 8 Newton. The supra-patellar pouch is reestablished first, followed by the medial and lateral gutters. The anterior interval is identified by releasing the infra-patellar fat pad from the anterior tibia,

allowing for reestablishment of the pretibial recess. Medial and/or lateral retinacular release may be required in the patient with reduced patellar mobility or a tight patello-femoral joint. Once in the intercondylar notch, the surgeon must evaluate notch stenosis. If present, a notchplasty is performed. Scar tissue, bony nodules, and loose bodies are removed. Depending on the severity of the scarring, release or excision is performed. Once complete, the knee should be ranged and motion reassessed. Persistent loss of extension usually indicates posterior capsular involvement. Care needs to be taken, as decreased joint space by intra-articular adhesions bands and hypertrophied synovium, iatrogenic damage to the prosthesis and polyethylene during arthroscopy may be the major disadvantage of arthroscopy following total knee replacement.

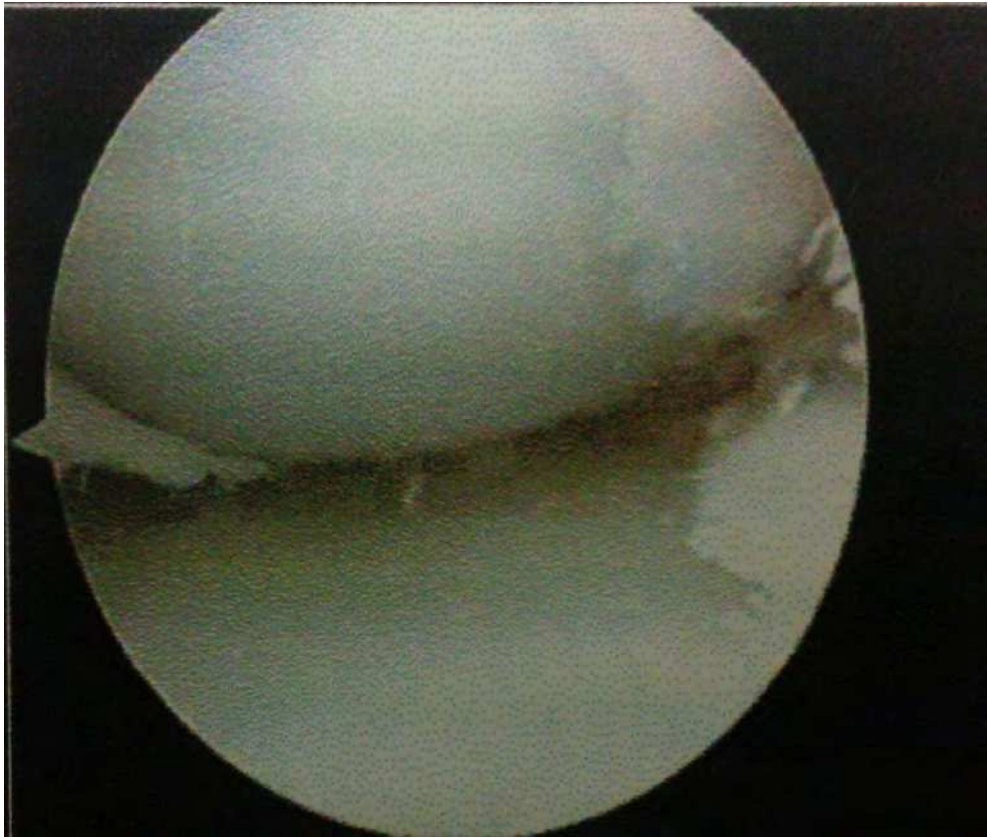

Fig. 7. Scar Tissue within joint space.

3. Patella clunk syndrome

This condition was first described by Insall in 1982 who termed it as “peripatellar nodule” caused by peripatellar soft-tissue impingement against the anterior margin of the intercondylar box of the femoral component”. The term “patellar clunk syndrome” however was coined by Hozack in 1989 who described the pathology as a prominent fibrous nodule at the junction of the proximal patellar pole and the quadriceps tendon which wedged into the inter-condylar notch during flexion and dislodged during extension, generating the symptoms. Thorpe and Bocell described a syndrome of similar presentation in 1990. The symptoms they described were “painful and usually visible popping, catching, or locking in the patello-femoral articulation as the knee was brought from flexion to extension.” They used the term “tethered patella syndrome” to describe this condition. Condition described by Insall, Hozack, and Thorpe is within the spectrum of the same disease entity. It was caused by peripatellar fibrous hyperplasia, especially prominent in the suprapatellar region and the lateral parapatellar gutter. It was actually a spectrum of disease, which ranged from painful crepitation to full-blown patellar clunk syndrome.

3.1

The exact cause of patellar clunk syndrome had not been identified. Most authors believed that it was multi-factorial. The design of prosthesis, extent of surgical trauma, change in joint line, patellar height, patellar thickness, and abnormal patellar tracking has been proposed as possible causes. The presence of unilateral patellar clunk syndrome in a patient with bilateral TKA of the same prosthesis provided a good model in examining this complex situation as some of the variables were controlled (i.e. same patient, same disease, and same prosthesis). The presence of excessive peri-patellar fibrosis is a prerequisite of this syndrome.

3.2

Patellofemoral synovial hyperplasia is a less well-described syndrome, characterized by a more diffuse proliferation of tissue proximal to the patella. Symptoms include pain and crepitus, most prominent during active knee extension from a 90° flexed position during stair climbing or rising from a chair. Knee range of motion (ROM) tends not to be affected and the lack of a discrete “clunk” is also criterion for this diagnosis.

3.3

Typically the syndrome appears 4 – 6 month after knee replacement surgery but the cases have been reported almost up to 4 years after surgical intervention. Posterior stabilized Knees are the ones that are commonly affected possibly due to nature of its design. The cases have been reported in cases where patella have been resurfaced and also in the cases where patella has not been resurfaced. The diagnosis is a clinical one, and the impressive clunking and jumping of the involved patella can often be seen or heard across the examining room. The fibrous nodule tends to lodge into the femoral component inter-condylar notch during flexion and displaces with an audible and often painful clunk at approximately 30° to 45° from full extension. The diagnosis can be reached based on the history and clinical examination although some surgeons may use a Doppler ultrasound to confirm the diagnosis.

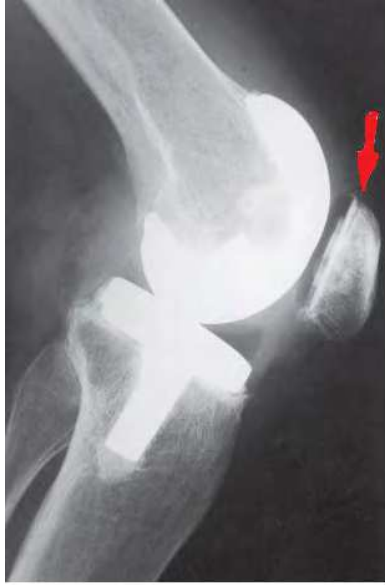

Fig. 8. Arrow denoting a narrow hair thin lucent line at the superior pole of patella. Also note that patella at the lower pole is thicker than the upper pole

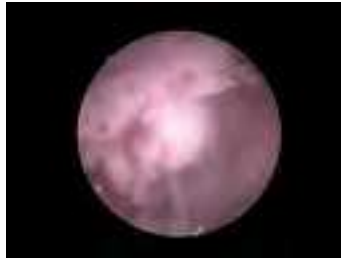

Fig. 9. Arthroscopic image of the nodule at the superior pole of the patella.

3.4 Causes of patellar clunk syndrome

1. Poor Patellar Tracking.
2. Peripatellar Fibrosis
3. Implant Design Related Issues
4. Implant malpositioning.
5. Quadriceps Impingement secondary to superior placement of patellar button.
6. Inadequate synovial tissue debridement at superior pole of patella during primary procedure.

3.5

Before 1990s, post-TKR patellar clunk syndromes were managed by open arthrotomy and excision of the offending fibrous nodule and adhesion. Although it has been effective in treating the symptoms of “clunk” and had successful results without recurrence, there are morbidities associated with this approach such as wound complication and delay in regaining range of motion. The requirement of postoperative analgesics for pain control is higher, and the length of hospitalization is often prolonged.

Advantages of using arthroscopy in treating patellar clunk syndrome included clear visualization of the pathology and few associated complications. The recovery period required for patients to regain full range of motion and normal activity is shorter. However, the synovitis itself could easily be removed with a motorized shaver. On the technical side, the supra-patellar joint space and the medial and lateral gutters are often contracted.

Arthroscopic debridement is an accepted treatment option for both patellar clunk syndrome and synovial hyperplasia; however, there is a paucity of functional outcome data in the literature, especially with respect to synovial hyperplasia.

Adhesions around the knee are usually debrided, first to make room for instrument insertion and then for the subsequent debridement of the dense fibrous nodules. Instrument insertion into the suprapatellar space and parapatellar gutters could therefore avoid causing iatrogenic damage to the surface of the prosthesis. The fibrous nodules are normally tough. Punch forceps and scissors are needed to shred them before the motorized shaver could debride them effectively. Care must be taken to avoid damaging the prosthesis components, as the potential risk of increasing the rate of wear of the prosthesis is theoretically possible.

Takahashi et al. classified the soft tissue impingement under patella after total knee arthroplasty into 3 categories [19]: Patella Clunk Syndrome

Type I	Fibrous firm nodule just proximal to the patella button without the other fibrous tissues causing the impingement
Type II	Impinging hypertrophic synovitis, generalized hypertrophic synovitis without fibrous nodule
Type III	Combination of a fibrous nodule proximal to the patella button and generalized hypertrophic synovitis

Arthroscopic Classification (Thorpe & Bocell): Tethered Patella Syndrome

Type I	Transverse fibrous band at the junction between the patella and quadriceps tendon
Type II	Longitudinal band in the lateral parapatellar gutter
Type III	Band in the infrapatellar region

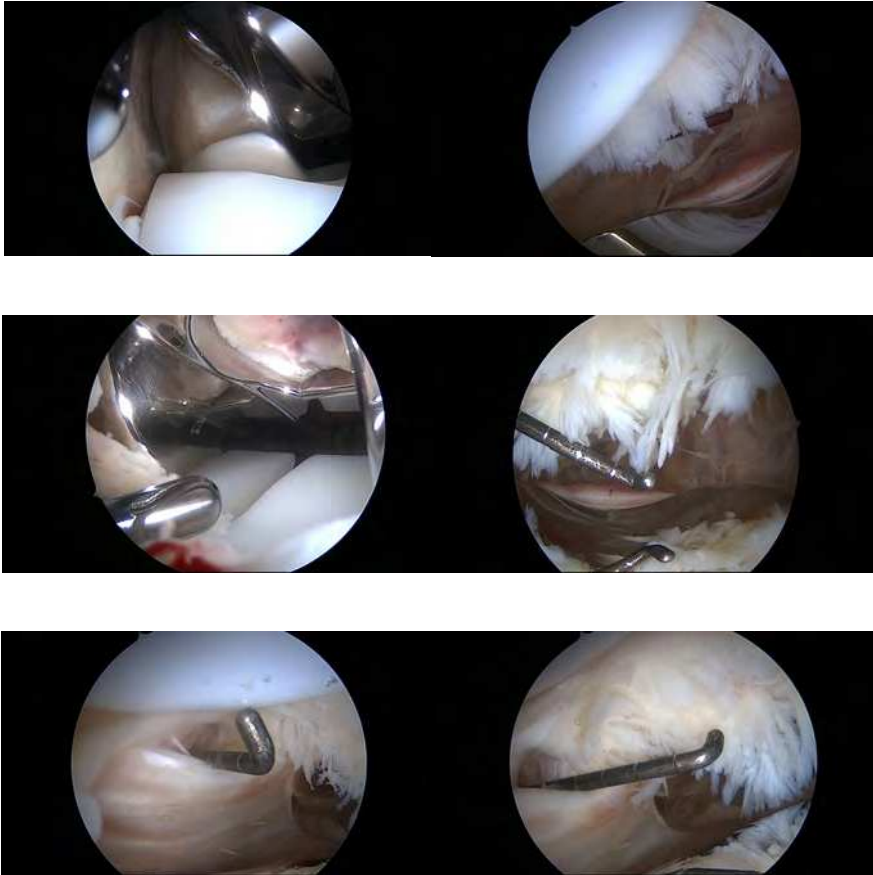


Fig. 10. Arthroscopic sequence of resection of the nodule.

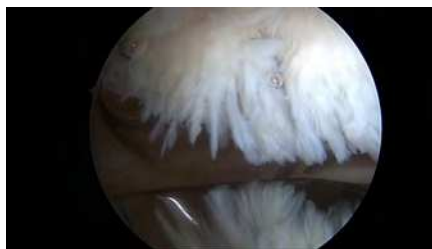

Fig. 11. Appearance after resection of the nodule

4. Posterior cruciate ligament stump impingement

Despite the clinical experience, most patients with symptomatic TKA complain about anterior knee pain, there is small number of patients with posterior knee pain. Although a rare scenario it can be painful and debilitating for the patients with total knee replacements. There is limited evidence in the literature regarding this particular impingement, probably because of difficulty in diagnosing the pathology. Diduch has reported only 4 cases of PCL stump impingement in his study on cruciate substituting knees. The posterior cruciate ligament stump may be quite prominent in the case of posterior cruciate sacrificing (PS) knees and are prone for impingement and interference with cam mechanism. Rarely, PCL impingement as a whole can also be seen after total knee replacement using cruciate retaining prosthesis, especially if the debridement around the notch and PCL is inadequate.

4.1 Pathogenesis

Generally in a routine total knee replacement using cruciate sacrificing prosthesis, removing the PCL makes it easier to balance the collateral ligaments. Since the evolution of high flexion mobile bearing posterior cruciate ligament substituting knee designs, it is necessary to completely resect the PCL. Any residual stump of the PCL may impinge in the cam/spine mechanism causing pain and limited motion. Keeping in mind, resection of the PCL may influence the height of the flexion and extension gaps. It has been postulated, that most likely, it is the postero-medial bundle of PCL stump, which is the main culprit. However, there have been only few reported cases of PCL impingement after cruciate retaining total knee replacements.

4.2 Clinical features

The patients usually come with severe posterior knee pain while flexing of the knee over 70° to 90°, which increases posterior translation of the tibia. This is seen when the PCL stump from the intercondylar notch gets entrapped in the medial tibio-femoral joint, resulting in severe posterior pain. This residual stump can get incarcerated and interfere with cam mechanism of the knee preventing any further flexion.

4.3 Investigations

It is very hard to diagnose PCL stump impingement clinically as the symptoms are not usually typical. Special scans like MRI and CT scans are also of limited value due to their scatter and artifacts associated with metallic implants. However, arthroscopy has an important role in this with regards to both diagnostic and therapeutic significance. If an arthroscopy is performed in these patients, it is recommended a complete inspection of the joint including the posterior compartments as is done in non-TKA patients with posterior knee pain.

4.4 Treatment

Non-operative treatments involve measures for pain relief and frequent visits to the physical therapists. These measures are effective only in few cases, since patients continue to be in a vicious cycle of increasing pain and reduced range of movement. As we know it is usually confirmed only on arthroscopy, it can certainly be treated at the same time. Diduch, in his

study, claims 75% success of pain relief after arthroscopic debridement of impinged PCL stump in total knee replacement patients.

4.5 Arthroscopy technique

Literature suggests that on few occasions' additional portals to assist adequate visualization of the posterior compartments and also to avoid iatrogenic damage to prosthetic component in a struggle to see at the back of total knee replacement is required. Although Diduch describes adequate view with standard anterior portals, there are suggestions of posteromedial and posterolateral portals in addition to the standard anterior ones (Landsiedl). Before attempting to see into posterior compartment, it is advised to release or resect any adhesions, which enables complete inspection of the anterior compartment of the knee joint, including soft tissue impingements, evaluation of the inlays and tracking of the patella.

It is recommended, through the standard anteromedial portal, a wide semicircular notchplasty should be performed (diameter of about 8 to 10 mm) in the posterior superolateral region of the notch just above the posterior condyle of the femoral component, to allow entrance of the arthroscope into the posterolateral compartment from the anteromedial portal. Due to the semicircular shape of the notchplasty, the arthroscope and the resecting instruments are mobile and otherwise inaccessible areas can be inspected and treated. A 1.2-mm can be inserted through posterolateral portal into the joint under arthroscopic control. A posterolateral portal is established with a stab incision. After blunt preparation down to the capsule, a working cannula is inserted using a sharp trocar for penetration parallel to the cannula to avoid slipping along the posterolateral capsule, frequently happens with blunt trocars. This usually provides an adequate view of the posterolateral compartment. Impingement of degenerated tissue in flexion can be seen much better from this portal than from the trans-fossa approach. Similarly, posteromedial portal can be established to work your way around the PCL stump. After resection of the PCL stump and its posterior synovial sheath, the posteromedial compartment can be inspected completely using the anteromedial or posterolateral portals.

4.6 Technical challenges

Technical problems lay in mirror images with problems in orientation, and the possibility of damaging the components by manipulation of the optic sheet or motorized instruments. The key points are the exact location of the portals and a smooth introduction of the trocar. For orientation, the use of a probe is mandatory to distinguish between reality and mirror image. The use of additional portals helps to avoid damaging the prosthesis components, especially by using motorized shavers and visualizing the tracing behavior of the patella. Alterations to the surface of cobalt-chromium femoral components can occur during arthroscopy with stainless-steel cannulae. Damage and degradation of the articulating surfaces of a total knee replacement have been associated with release of wear debris. There is a correlation between surface roughness of cobalt-chromium femoral components and polyethylene wear of the tibial component. In addition, studies have shown extensive foreign-body giant-cell reactions to polyethylene particles and synovial membrane reactions to loose cobalt chromium particles. To avoid this Raab recommends the use of plastic cannulae instead of metallic ones.

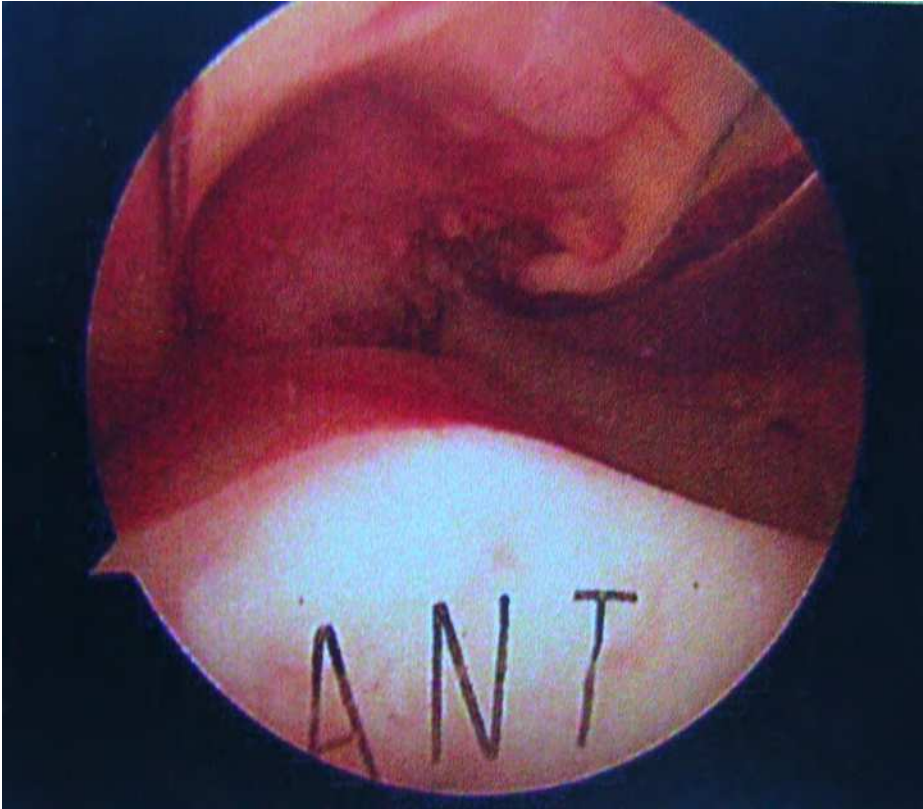


Fig. 12. PCL impingement seen during arthroscopic examination of PCL retaining prosthesis.

5. References


- [1] Daumer KM, Khan AU, Steinbeck MJ. Chlorination of pyridinium compounds. Possible role of hypochlorite, N-chloramines, and chlorine in the oxidation of pyridinoline cross-links of articular cartilage collagen type II during acute inflammation. *J Biol Chem.* 2000; 275:34681-92
- [2] Xavier S, Piek E, Fujii M, Javelaud D, Mauviel A, Flanders KC, Samuni AM, Felici A, Reiss M, Yarkoni S, Sowers A, Mitchell JB, Roberts AB, Russo A. Amelioration of radiation-induced fibrosis: inhibition of transforming growth factor-beta signaling by halofuginone. *J Biol Chem.* 2004; 279:15167-76.

- [3] Diamond JR, Ricardo SD, Klahr S. Mechanisms of interstitial fibrosis in obstructive nephropathy. *Semin Nephrol.* 1998; 18:594-602
- [4] Poli G, Parola M. Oxidative damage and fibrogenesis. *Free Radic Biol Med.* 1997; 22:287-305
- [5] Swindle EJ, Hunt JA, Coleman JW. A comparison of reactive oxygen species generation by rat peritoneal macrophages and mast cells using the highly sensitive real-time chemiluminescent probe pholasin: inhibition of antigen-induced mast cell degranulation by macrophage-derived hydrogen peroxide. *J Immunol.* 2002; 169:5866-73.
- [6] Baran CP, Zeigler MM, Tridandapani S, Marsh CB. The role of ROS and RNS in regulating life and death of blood monocytes. *Curr Pharm Des.* 2004; 10:855-66.
- [7] Jackson RW. The role of arthroscopy in the management of the arthritic knee. *Clin Orthop.* 1974;101:28-35.
- [8] Sprague N, O'Connor RL, Fox JM. Arthroscopic treatment of postoperative knee fibroarthrosis. *Clin Orthop.* 1982; 166:165-172.
- [9] Jens G. Boldt, Urs K. Munzinger, Arthrofibrosis Associated with Total Knee Arthroplasty: Gray-Scale and Power Doppler Sonographic Findings *AJR* 2004;182:337-340
- [10] Giovagnorio F, Martinoli C, Coari G. Power Doppler ultrasonography in knee arthritis: a pilot study. *Rheumatol Int* 2001; 20:101-104
- [11] Scranton PE Jr: Management of knee pain and stiffness after total knee arthroplasty. *J Arthroplasty* 2001; 16:428-435
- [12] Brassard MF, Scuderi GR: Complications of total knee arthroplasty, in Insall JN, Scott WN (eds): *Surgery of the Knee*, ed 3. New York, NY: Churchill Livingstone, 2001, pp 1814-1816
- [13] Fox JL, Poss R: The role of manipulation following total knee replacement. *J Bone Joint Surg Am* 1981; 63:357-362
- [14] Shoji H, Solomonow M, Yoshino S, D'Ambrosia R, Dabezies E: Factors affecting postoperative flexion in total knee arthroplasty. *Orthopedics* 1990; 13: 643-649
- [15] Sprague NF III, O'Connor RL, Fox JM: Arthroscopic treatment of postoperative knee fibroarthrosis. *Clin Orthop* 1982; 166:165-172.
- [16] Sprague NF III: Motion-limiting arthrofibrosis of the knee: The role of arthroscopic management. *Clin Sports Med* 1987; 6:537-549.
- [17] Bocell JR, Thorpe CD, Tullos HS: Arthroscopic treatment of symptomatic total knee arthroplasty. *Clin Orthop* 1991; 271:125-134.
- [18] Campbell ED Jr: Arthroscopy in total knee replacements. *Arthroscopy* 1987; 3: 31-35
- [19] Diduch DR, Scuderi GR, Scott WN, Insall JN, Kelly MA: The efficacy of arthroscopy following total knee replacement. *Arthroscopy* 1997; 13:166-171.
- [20] Bae DK, Lee HK, Cho JH: Arthroscopy of symptomatic total knee replacements. *Arthroscopy* 1995; 11:664-671
- [21] Williams RJ III, Westrich GH, Siegel J, Windsor RE: Arthroscopic release of the posterior cruciate ligament for stiff total knee arthroplasty. *Clin Orthop* 1996; 331:185-191

- [22] Kim DH, Gill TJ, Millett PJ: Arthroscopic treatment of the arthrofibrotic knee. *Arthroscopy* 2004;20(suppl 2): 187-194.
- [23] Millett PJ, Williams RJ III, Wickiewicz TL: Open debridement and soft tissue release as a salvage procedure for the severely arthrofibrotic knee. *Am J Sports Med* 1999;27:552-561
- [24] Beight JL, Yao B, Hozack WJ, et al: The patellar clunk syndrome after posterior stabilized total knee arthroplasty. *CORR* 299:139, 1994
- [25] Hozack WJ, Rothman RH, Booth RE, et al: The patellar clunk syndrome: a complication of posterior stabilized total knee arthroplasty. *CORR* 241:203, 1989
- [26] Diduch DR, Scuderi GR, Scott WN, et al: The efficacy of arthroscopy following total knee replacement. *Arthroscopy* 13:166, 1997
- [27] Insall JN, Lachiewicz F, Burstein AH: The posterior stabilized condylar design. Two to four year clinical experience. *J Bone Joint Surg A* 64A: 1317, 1982
- [28] Thorpe CD, Bocell JR, Tullos HS: Intra-articular fibrous bands patellar complications after total knee replacement. *J Bone Joint Surg A* 72A:811, 1990
- [29] Bocell JR, Thorpe CD, Tullos HS: Arthroscopic treatment of symptomatic total knee arthroplasty. *CORR* 271:125, 1991
- [30] Lintner DM, Bocell JR, Tullos HS: Arthroscopic treatment of intraarticular fibrous band after total knee arthroplasty. A follow-up note. *CORR* 309:230, 1994
- [31] Figgie HE, Goldberg VM, Heiple KG, et al: The Influence of tibial-patellofemoral location on function of the knee in patients with the posterior stabilized condylar knee prosthesis. *J Bone Joint Surg A* 68A:1030, 1986
- [32] Insall JN, Salvati E: Patella position in the normal knee joint. *Radiology* 101:101, 1971
- [33] Okamoto T, Fukani H, Atsui K, Fukunishi S, Kozuka A, Maruo S (2002) Sonographic appearance of fibrous nodules in patellar clunk syndrome: a case report. *J Orthop Sci* 7:590-593
- [34] Scott RD, Volatile TB (1986) 12 years experience with posterior cruciate retaining total knee arthroplasty. *Clin Orthop* 205: 100-107
- [35] Sculco TP, Martucci EA (2001) Knee arthroplasty, chapter 6. Patellofemoral joint. Springer, Berlin Heidelberg New York
- [36] Shoji H, Shimozaki E (1996) Patellar clunk syndrome in total knee arthroplasty without patella resurfacing. *J Arthroplasty* 11:198-201
- [37] Vertullo CJ, Easley ME, Scott N, Insall JN (2001) Mobile bearings in primary knee arthroplasty. *J Am Acad Orthop Surg* 9: 335-364 602
- [38] Callaghan JJ, Insall JN, Greenwald AS (2000) Mobile-bearing knee replacement: concepts and results. *J Bone Joint Surg Am* 82:1020-1041
- [39] Pollock DC, Ammeen DJ, Engh GA. Synovial entrapment: a complication of posterior-stabilized total knee arthroplasty. *J Bone Joint Surg* 2002; 84A:2174.
- [40] Takahashi M, Miyamoto S, Nagano A. Arthroscopic treatment of soft-tissue impingement under the patella after total knee arthroplasty. *Arthroscopy* 2002; 18:E20.
- [41] Brassard MF, Insall JN, Scuderi GR. Complications of total knee arthroplasty. In: Insall JN, Scott WN, editors. *Surgery of the Knee*. 4th ed. New York: Churchill Livingstone; 2006. p. 1752-3.

- [42] Ip D, Wu WC, Tsang WL. Comparison of two total knee prosthesis on the incidence of patella clunk syndrome. *Int Orthop* 2002;26:48-51.
- [43] Anderson MJ, Becker DL, Kieckbusch T. Patellofemoral complications after posterior-stabilized total knee arthroplasty: a comparison of 2 different implant designs. *J Arthroplasty* 2002; 17:422-6.
- [44] Lucas TS, DeLuca PF, Nazarian DG, et al. Arthroscopic treatment of patellar clunk. *Clin Orthop* 1999; 367:226.
- [45] Clarke HD, Fuchs R, Scuderi GR, et al. The influence of femoral component design in the elimination of patellar clunk in posterior-stabilized total knee arthroplasty. *J Arthroplasty* 2006; 21:167.
- [46] Lonner J, Jasko J, Bezwada H, et al. Incidence of patellar clunk with a modern posterior-stabilized knee design. *Am J Orthop* 2007; 36: 550.
- [47] Maloney WJ, Schmidt R, Sculco TP. Femoral component design and patellar clunk syndrome. *Clin Orthop* 2003; 410: 199.
- [48] Yau WP, Wong JWK, Chiu KY, Ng TP, Tang WM. Patellar clunk syndrome after posterior stabilized total knee arthroplasty. *J Arthroplasty* 2003; 18: 1023-8.
- [49] Larson CM, Lachiewicz PF. Patellofemoral complications with the Insall- Burstein II posterior-stabilized total knee arthroplasty. *J Arthroplasty* 1999; 14: 288-92.
- [50] Sringari T, Maheswaran SS. Patellar clunk syndrome in patellofemoral arthroplasty – a case report. *Knee* 2005; 12: 456-7.
- [51] Vernace JV, Rothman RH, Booth RE. Arthroscopic management of the patellar clunk syndrome following posterior stabilized total knee arthroplasty. *J Arthroplasty* 1989;4:179-82
- [52] Ranawat AS, Ranawat CS, Slamin JE, Slamin JE, Dennis DA. Patellar crepitation in the P.F.C. sigma total knee system. *Orthopedics* 2006; 29: S68-70.
- [53] Diduch. D, Giles. R. The efficacy of arthroscopy following total knee replacement. *Arthroscopy: The Journal of Arthroscopic and Related Surgery*, Vol 13, No 2 (April), 1997
- [54] Franz Landsiedl, M.D., Nicolas Aigner. A New Arthroscopic Technique for Revision of the Posterior Compartment in Symptomatic Total Knee Arthroplasty; *Arthroscopy: The Journal of Arthroscopic and Related Surgery*, Vol 21, No 4 (April), 2005
- [55] Dowson D, Taheri S, Wallbridge N. The role of counterface imperfections in the wear of polyethylene. *Wear*. 1987; 119:277.
- [56] Hood RW, Wright TM, Burstein AH. Retrieval analysis of total knee prostheses: a method and its application to 48 total condylar prostheses. *J Biomed Mater Res*. 1983;17:829-42.
- [57] Levesque M, Livingston BJ, Jones WM, Spector M. Scratches on condyles in normal functioning total knee arthroplasty. *Trans Orthop Res Soc*. 1998;23:247.
- [58] Howie DW, Vernon-Roberts B. The synovial response to intraarticular cobaltchrome wear particles. *Clin Orthop*. 1988; 232:244-54.
- [59] Mintz L, Tsao AK, McCrae CR, Stulberg SD, Wright T. The arthroscopic evaluation and characteristics of severe polyethylene wear in total knee arthroplasty. *Clin Orthop*. 1991; 273:215-22.

- [60] Damage to Cobalt-Chromium Surfaces During Arthroscopy of Total Knee Replacements, Raab, G, Christopher, J, The Journal of Bones and Joint Surgery, Vol 83-A · Number 1 · January 2001



Modern Arthroscopy

Edited by Dr Jason L. Dragoo

ISBN 978-953-307-771-0

Hard cover, 302 pages

Publisher InTech

Published online 09, December, 2011

Published in print edition December, 2011

Modern Arthroscopy will assist practitioners to stay current in the rapidly changing field of arthroscopic surgery. The chapters in this book were written by a panel of international experts in the various disciplines of arthroscopy. The goals of this text are to present the classical techniques and teachings in the fields of Orthopaedics and Dentistry, but also to include new, cutting-edge applications of arthroscopy, such as temporomandibular arthroscopy and extra-articular arthroscopy of the knee, just to name a few. We hope Modern Arthroscopy becomes a core reference for your arthroscopic surgery practice.

How to reference

In order to correctly reference this scholarly work, feel free to copy and paste the following:

Vaibhav Bagaria, Jami Ilyas, Bhawan Paunipagar, Darshna Rasalkar and Rohit Lal (2011). Arthroscopy Following Total Knee Replacement, Modern Arthroscopy, Dr Jason L. Dragoo (Ed.), ISBN: 978-953-307-771-0, InTech, Available from: <http://www.intechopen.com/books/modern-arthroscopy/arthroscopy-following-total-knee-replacement>

INTECH
open science | open minds

InTech Europe

University Campus STeP Ri
Slavka Krautzeka 83/A
51000 Rijeka, Croatia
Phone: +385 (51) 770 447
Fax: +385 (51) 686 166
www.intechopen.com

InTech China

Unit 405, Office Block, Hotel Equatorial Shanghai
No.65, Yan An Road (West), Shanghai, 200040, China
中国上海市延安西路65号上海国际贵都大饭店办公楼405单元
Phone: +86-21-62489820
Fax: +86-21-62489821

© 2011 The Author(s). Licensee IntechOpen. This is an open access article distributed under the terms of the [Creative Commons Attribution 3.0 License](#), which permits unrestricted use, distribution, and reproduction in any medium, provided the original work is properly cited.