

# A Comparison of NB-UVB and PUVA in the Treatment of Vitiligo

Jiun-Yit Pan<sup>1,2</sup> and Robert P.E. Sarkany<sup>2</sup>

<sup>1</sup>National Skin Centre, Singapore

<sup>2</sup>St John's Institute of Dermatology, London

<sup>1</sup>Singapore

<sup>2</sup>UK

## 1. Introduction

Vitiligo is an acquired, progressive depigmenting disorder of the skin and mucous membranes in which melanocytes in affected skin are selectively destroyed. Theories regarding the mechanism of melanocyte destruction include autoimmune, cytotoxic, oxidative, and neural mechanisms. Vitiligo affects 0.5-2% of the world's population and the usual age of onset is in the third decade of life.

Photochemotherapy, along with phototherapy and topical therapy, are the most commonly utilized and effective vitiligo treatment modalities. Photochemotherapy for the treatment of vitiligo was historically used in ancient India and Egypt, where Hindus and Egyptians applied psoralen-containing plant extracts to depigmented vitiligo lesions where were then exposed to sunlight. These plants were found to be *Ammi majus* and *Psoralen corylefolia*, which contain 8-methoxypsoralen (8-MOP) and 5-methoxypsoralen (5-MOP).

Phototherapy has been shown in many studies to induce effective repigmentation in more than 70% of patients with early and/or localized disease. Narrow-band ultraviolet B radiation (NB-UVB) with an emission spectrum of 310-312 nanometers (nm) is a safe treatment modality that is often used two to three times weekly as monotherapy, or combined with topical steroids. The treatment is safe in children, pregnant women and lactating mothers, and has minimal adverse effects (xerosis, pruritus, skin aging, and tanning). The risk of skin cancer is minimal even with multiple treatments although there is a greater risk of phototoxicity with depigmented skin. NB-UVB has also been used in combination with antioxidants such as vitamin E.

Photochemotherapy involves the usage of psoralens combined with natural sunlight or UV light, usually ultraviolet A radiation (PUVA). 8-MOP or 5-MOP can be applied topically or used orally, followed by light exposure. Psoralens may not be used in pregnancy and there is a need for photoprotection following their use; there is as well a higher risk of burns, eye injury, and cutaneous malignancy than NB-UVB that may limit their cumulative usage. A 10-year retrospective study showed that PUVA is only moderately effective in widespread vitiligo (Kwok et al, 2002). Another small study from India successfully combined PUVA with a keratinocyte-melanocyte graft technique for stable vitiligo (Kachhawa et al, 2008).

Head-to-head comparison studies using NB-UVB and PUVA found both to be effective therapies – however, NB-UVB has been shown to induce even more stable repigmentation, is more convenient, and has fewer adverse effects when compared to PUVA.

## 2. Ultraviolet B phototherapy

Ultraviolet B (UVB) phototherapy is one of the most common vitiligo treatments used in the world today, and has evolved from the use of broadband ultraviolet B (BB-UVB) lamps to narrow-band ultraviolet B (NB-UVB) machines (Figure 1) with an emission spectrum of 310-315 nm (e.g. Philips TL-01). Vitiligo was the second most frequently treated disease by NB-UVB reported in a review published from a major U.S. phototherapy referral centre.



Fig. 1. A Narrowband UVB body box

UVB therapeutic modalities remain the mainstay of treatment for vitiligo due to its simplicity, safety and efficacy – a meta-analysis showed that it was the safest and most effective treatment for generalized vitiligo, with fewer adverse effects compared to psoralen and ultraviolet A (PUVA) therapy (Ngoo et al, 1996). Sixty-three studies were found on therapies for localized vitiligo. Among randomized controlled trials on localized vitiligo, the pooled odds ratio vs. placebo was significant for topical class 3 corticosteroids (14.32; 95%

confidence interval [CI], 2.45-83.72). Topical class 3 and class 4 corticosteroids carried the highest mean success rates (56% [95% CI, 50%-62%] and 55% [95% CI, 49%-61%], respectively). Side effects were reported mostly with topical psoralen and intralesional and class 4 corticosteroids. In randomized controlled trials on generalized vitiligo, the odds ratio vs. placebo was significant for oral methoxsalen plus sunlight (23.37; 95% CI, 1.33-409.93), oral psoralen plus sunlight (19.87; 95% CI, 2.37-166.32), and oral trioxsalen plus sunlight (3.75; 95% CI, 1.24-11.29). In this series, the highest mean success rates were achieved with NB-UVB (63%; 95% CI, 50%-76%), BB-UVB (57%; 95% CI, 29%-82%), and oral methoxsalen plus UVA therapy (51%; 95% CI, 46%-56%). Oral methoxsalen plus UVA was associated with the highest rates of side effects. No side effects were reported with UVB therapy.

Critical reviews and guidelines recommend that UVB light be the primary phototherapy option for vitiligo, especially for generalized disease. A retrospective study done at a major referral centre in the United States administered NB-UVB phototherapy as monotherapy three times a week (Scherschun et al, 2001). The starting dose was 280 mJ/cm<sup>2</sup>, with 15% dose increments at each subsequent treatment. This treatment protocol resulted in rapid repigmentation in many patients, including those with skin phototypes IV and V.

Vitiliginous areas are considered to have a type 1 Fitzpatrick response to UV light. Treatments are usually 2-3 times weekly with initiation of dose at 50-70% of the average minimal erythema dose (MED) for NB-UVB treatment for type 1 skin (about 400 mJ/cm<sup>2</sup>). The minimal erythema dose is the minimum dosage of UVB that produces just perceptible redness 24 hours after exposure. Patients should be referred to a dermatologist for UV radiation therapy. A total of 75 to 150 treatments (e.g. three times a week for 6 to 12 months) may be necessary. The course of therapy is usually much longer compared to inflammatory skin disorders such as atopic dermatitis and psoriasis, and the treatment course may last for years as long as there is continued gradual improvement and follicular repigmentation. However, the benefits of the usage of MED compared with fixed starting doses remains controversial. Fixed starting doses based on type 1 Fitzpatrick skin phototype allow an easier and more convenient means of initiating phototherapy, but do not take into account racial variations in MED. Also, many centres propose a lower maximum dose for NB-UVB in vitiligo compared to other inflammatory disorders (2 J/cm<sup>2</sup> for vitiligo compared to 5 J/cm<sup>2</sup> for psoriasis in our phototherapy unit).

NB-UVB has certain limitations. Lesions in acral sites are less likely to respond well to treatment than lesions on the face, trunk, or limbs. Segmental vitiligo is also less responsive to treatment. Long-standing lesions may also exhibit a lower rate of success in some cases.

Combination therapy with topical corticosteroids and NB-UVB is both effective and safe. NB-UVB has been used in combination with topical calcineurin inhibitors, and most studies show better improvement and repigmentation compared to NB-UVB monotherapy. Sixty-eight patients with vitiligo enrolled in a randomized, double-blind, placebo-controlled study (Esfandiarpour et al, 2009) in which patients were randomized into two groups: NB-UVB plus pimecrolimus or NB-UVB plus placebo, both for three months. NB-UVB three times a week was initiated at 280 mJ/cm<sup>2</sup>, with 15% increments for each subsequent treatment until erythema was reported or a maximum of 800 mJ/cm<sup>2</sup> was achieved. At baseline, 6 weeks, and 12 weeks after commencement of therapy, vitiliginous patches were measured. No significant side effects were reported except self-limited erythema and pruritus. After 12 weeks of treatment, repigmentation of facial lesions was greater in patients treated with combined pimecrolimus and NB-UVB compared with the placebo plus NB-UVB group (64.3 vs. 25.1%,  $p < 0.05$ ). There was no statistically significant difference in the repigmentation

rate between the two groups on other body areas. This study showed that on the face, NB-UVB works better if combined with pimecrolimus 1% cream rather than when used alone.

Another prospective single-blind study (Majid I 2010) was performed on 80 patients with generalized vitiligo over 12 years of age who had symmetrically distributed vitiligo lesions on the face, trunk or limbs. The patients applied topical tacrolimus 0.1% ointment twice daily on selected symmetrically distributed lesions on the left side of the body. No topical agent was applied on the corresponding lesions on the right. The patients also received whole-body NB-UVB exposure three times every week on non-consecutive days according to a set protocol. Lesions selected for the comparison analysis were photographed serially and assessed by a single-blinded observer for the extent of repigmentation achieved. The extent of repigmentation achieved was calculated on the basis of VASI (Vitiligo Area Scoring Index) scoring. The VASI score is a composite estimate of the overall area of vitiligo patches at baseline and the degree of macular repigmentation within these patches over time, ranging from 0-100%. The time taken until initial repigmentation, as well as overall repigmentation achieved, and adverse effects were noted and compared between corresponding lesions on each side. Seventy-four patients with 234 symmetrical vitiligo lesions were available for comparison analysis at the end of the study period. The mean repigmentation achieved on the left-sided study lesions was approximately 71% (VASI score of 4.0) as compared to 60.5% on the symmetrically distributed right-sided lesions (VASI score of 3.4). Moreover, the repigmentation started earlier on the lesions on left side than on the right-side. No significant adverse events were reported with combination treatment. In this study, addition of topical tacrolimus increased the extent of overall repigmentation achieved with NB-UVB therapy in vitiligo and also reduced the cumulative NB-UVB dose needed to achieve a therapeutic benefit in affected patients.

NB-UVB treatment was given to 24 patients with generalized vitiligo three times weekly in a study from Turkey (Goktas et al, 2006). Topical calcipotriol cream was only applied to the lesions located on the right side of the body and treatment was continued for 6 months. Treatment efficacy was evaluated by determining the average response rates of the lesions at 3-month intervals. The average response rates of patients receiving combination of NB-UVB plus calcipotriol and NB-UVB alone were  $51 \pm 19.6\%$  and  $39 \pm 18.9\%$ , respectively. The median cumulative UVB dose and number of UVB exposures for initial repigmentation were  $6345 \text{ mJ/cm}^2$  (2,930-30,980  $\text{mJ/cm}^2$ ) and 18  $\text{mJ/cm}^2$  (12-67  $\text{mJ/cm}^2$ ) for the combination therapy, and  $8867.5 \text{ mJ/cm}^2$  (2,500-30,980  $\text{mJ/cm}^2$ ) and 24  $\text{mJ/cm}^2$  (15-67  $\text{mJ/cm}^2$ ) for the NB-UVB therapy, respectively. These findings indicated that concurrent topical calcipotriol potentiates the efficacy of NB-UVB in the treatment of vitiligo. This combination not only provided earlier pigmentation with lower total UVB dosage and less adverse UVB effects, but also reduced the duration and cost of treatment.

### 3. Psoralen with ultraviolet A (PUVA) therapy

Vitiligo was the first described indication for psoralen with ultraviolet A (PUVA) treatment (Parrish et al, 1976) PUVA (Figure 2) is less used now since NB-UVB has been described as a safe and effective alternative (Bhatnagar et al, 2007). Psoralens are phototoxic compounds that interact with various components of cells and absorb photons to produce photochemical reactions altering the function of cellular constituents – they may be consumed orally or applied topically to the skin, in combination with long-wave ultraviolet A (UVA) radiation. For topical application, the patient may bathe in a dilute methoxsalen

solution or have the solution directly applied to affected areas. Psoralens may not be used in pregnancy and there is a higher risk of burns, cutaneous malignancy and eye injury.

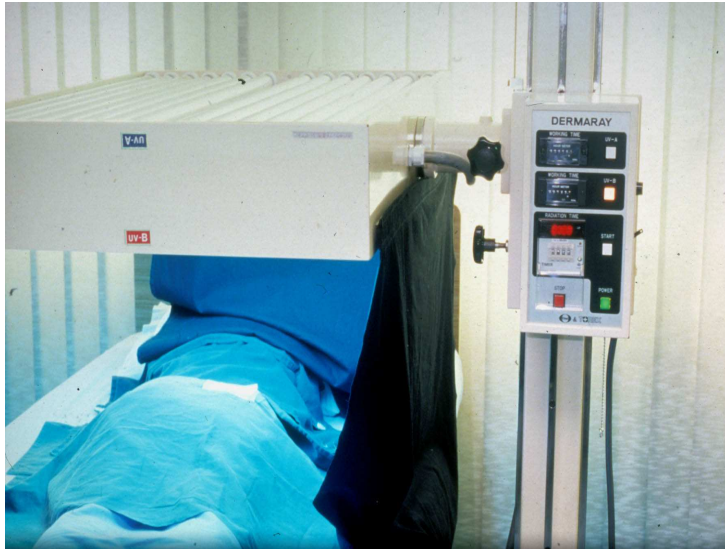

Fig. 2. A targeted UVA light source for PUVA therapy

Patients are treated as Fitzpatrick skin type I individuals and the therapeutic objective is to maintain minimal light pink reactions in patches of depigmented skin. About 100-200 exposures are required to produce maximal repigmentation and about 70% of patients respond. Sessions are usually 2-3 times weekly. Guidelines for psoralen administration and PUVA protocols for vitiligo are suggested below in Table 1 and Table 2. A comparison of PUVA and NB-UVB for the treatment of vitiligo can be found in Table 3.

Concurrent use of topical corticosteroids has been shown to enhance the response to PUVA therapy. There have been a number of recent publications combining topical vitamin D analogues with PUVA therapy which show a beneficial synergistic effect, but more studies are required.

A placebo-controlled double-blind study (Ermis et al, 2001) was done in Turkey to investigate whether the effectiveness of PUVA treatment could be enhanced by combination with topical calcipotriol. Thirty-five patients with generalized vitiligo enrolled in the study. Symmetrical lesions of similar dimensions and with no spontaneous repigmentation on arms, legs or trunk were selected as reference lesions. In this randomized left-right comparison study, calcipotriol cream or placebo was applied to the reference lesions an hour before PUVA treatment (oral 8-MOP and conventional UVA units) twice weekly. Patients were examined at weekly intervals. The mean number of sessions and the cumulative UVA dosage for initial and complete repigmentation were calculated for twenty-seven patients. The mean cumulative UVA dose and number of UVA exposures for initial repigmentation were  $52.52 \pm 6.10$  J/cm<sup>2</sup> and  $9.33 \pm 0.65$  on the calcipotriol side, and  $78.20 \pm 7.88$  J/cm<sup>2</sup> and  $12.00 \pm 0.81$  on the placebo side, respectively ( $P < 0.001$ ). For complete repigmentation, respective values were  $232.79 \pm 14.97$  J/cm<sup>2</sup> and  $27.40 \pm 1.47$  on the

calcipotriol side and  $259.93 \pm 13.71$  J/cm<sup>2</sup> and  $30.07 \pm 1.34$  on the placebo side ( $P = 0.001$ ). Treatment with calcipotriol and PUVA resulted in significantly higher percentages of repigmentation for both initial (81%) and complete pigmentation (63%), compared with placebo and PUVA (7% and 15%, respectively). These results showed that concurrent topical calcipotriol potentiates the efficacy of PUVA in the treatment of vitiligo, and that this combination achieved earlier pigmentation with a lower total UVA dosage.

Oral 8-Methoxypsoralen (8-MOP)	8-MOP is taken 2 hours before treatment, at a dose of 25 mg/m <sup>2</sup> (Ibbotson et al 2001). The body surface area is calculated using a normogram. Basing the dose on body surface area is preferable to basing the dose only on body weight.
Oral 5-Methoxypsoralen (5-MOP)	5-MOP is taken 3 hours before treatment at a dose of 50 mg/m <sup>2</sup> .
Bath PUVA (Halpern et al 2000)	30 mls of 8-MOP 1.2% solution is added to 100 mls of water (=3.6 mg/L at 37 °C), and the patient is immersed for 15 minutes. UVA exposure is given immediately. Patients do not need to shower afterwards but should have sunscreen applied to any areas that will be exposed to sunshine in the next 4 hours.
Hand-Foot Immersion PUVA (Halpern et al 2000)	1.3 mls of 8-MOP 1.2% solution is added to 4 litres of water (3.9 mg/L at 37 °C) and the patient's hands or feet are immersed for 15 minutes. UVA exposure is ideally given 30 minutes afterwards but can be given immediately. The hands / feet need not be washed afterwards, but should have sunscreen applied if they will be subsequently exposed to sunshine in the next few hours.
Gel PUVA (Halpern et al 2000)	A thin layer of 0.005% gel is applied to the diseased area using a gloved hand. UVA exposure is given 30 minutes later.

Table 1. Psoralen Administration

Psoralen and solar ultraviolet A (PUVASol) involves the exposure of the patient to sunlight after administration of oral or topical psoralen. A study (Pathak et al 1984) compared different psoralen compounds, doses and combinations, combined with exposure to sunlight. There was considerable regional variation in response, with the face showing the best response and the acral areas the worst response. Approximately 45% of participants treated with the combination of 8-methoxypsoralen (8-MOP) and trimethylpsoralen (TMP) achieved full repigmentation of the head and nearly 60% achieved 75 to 100% repigmentation of the head and neck, which was statistically significant when compared to placebo. However, 49% of all participants reported side effects including nausea, pruritus, dizziness, headaches, eye discomfort and gastrointestinal symptoms, with the rate of complications highest in the group which used 8-MOP and TMP in combination. Khalid et al (1995) showed that clobetasol propionate was significantly better than PUVASOL at achieving at least 75% repigmentation in vitiligo patients (RR 4.70 95%CI 1.14 to 19.39).

Siddiqui et al (1994) examined the effectiveness of a combination of oral L-phenylalanine (L-Phe) and UVA in an open trial and a small double-blind trial, which showed equivocal results. Phenylalanine is an amino acid that is the precursor of tyrosine, which is required for melanin pigment synthesis. Oral L-Phe loading resulted in peak plasma levels of L-Phe after 30-60 minutes and a slight increase in the plasma tyrosine level. Response to L-Phe plus UVA irradiation was positive, and various grades of repigmentation not exceeding 77% in the open and 60% in the blind trial were observed. An increased L-Phe dose resulted in increased L-Phe plasma levels but not in improved clinical results. The optimal L-Phe dose appeared to be lower than 50 milligrams/kilograms/day.

	Frequency of Treatment	Initial Dose	Incremental Doses	Maximum single dose
Oral PUVA	Twice a week	0.5 J/cm <sup>2</sup>	0.25 J/cm <sup>2</sup> increase at each visit until maximum dose reached. If erythema develops, omit treatment until settled and reduce to the previous dose, then use increments of 0.1-0.25 J/cm <sup>2</sup> if no erythema	5 J/cm <sup>2</sup>
Bath PUVA	Twice a week	0.05 J/cm <sup>2</sup> to face 0.1 J/cm <sup>2</sup> to other sites	0.05 J/cm <sup>2</sup> increase at each visit until maximum dose reached. If erythema develops, omit treatment until settled and reduce to the previous dose, then use increments of 0.02-0.05 J/cm <sup>2</sup> if no erythema	1 J/cm <sup>2</sup>
Gel PUVA	Twice a week	0.5 J/cm <sup>2</sup>	0.25 J/cm <sup>2</sup> increase at each visit until maximum dose reached. If erythema develops, omit treatment until settled and reduce to the previous dose, then use increments of 0.1-0.25 J/cm <sup>2</sup> if no erythema	1 J/cm <sup>2</sup>

Table 2. PUVA protocols for vitiligo

Camacho et al (2002) conducted an open trial on 70 patients with active vitiligo, where they were treated with oral and topical phenylalanine, clobetasol cream at night, sunlight in the spring and summer and UVA phototherapy in autumn and winter. Nearly 69% of patients achieved an improvement of 75% or more, but the improvement was only modest in patients with focal and segmental vitiligo.

PUVA has also been combined effectively with a keratinocyte-melanocyte graft technique for stable vitiligo in a study from India (Kachhawa et al 2008). This autologous, non-cultured, non-trypsinized, melanocyte plus keratinocyte grafting technique is a new and simple method of vitiligo surgery. In the trial, eighteen vitiligo patches underwent this procedure. The upper layer of epidermis was removed by superficial dermabrasion using a

dermabrader micromotor until the epidermis appeared wet and shiny. Then, antibiotic ointment was applied and dermabrasion was continued until the whitish area of the upper dermis was apparent. The paste-like material (ointment with entangled epidermal particles) was collected and spread over the dermabraded recipient site. Pigmentation usually started at 4-6 weeks, and then PUVA therapy was initiated. Complete uniform pigmentation took 16-20 weeks. For smaller vitiligo patches this method gives cosmetically acceptable results. It is fairly easy to perform and does not require specific laboratory setup.

	NB-UVB	PUVA
Ease of Administration	Simple, no prior preparation required	Requires topical / bath application or consumption of psoralen. PUVASOL allows patient to apply topical meladinine paint at home, followed by self-exposure to ambient sunlight.
Targeted therapy available for localized vitiligo?	Yes (Multiclear, Excimer lamp etc)	Yes
Efficacy	Both are equally effective for vitiligo. Acral and periorificial areas are more resistant to phototherapy. A meta-analysis (Ngoo et al, 1996) showed that NB-UVB is the safest and most effective treatment for generalized vitiligo, with fewer adverse effects compared to psoralen and ultraviolet A (PUVA) therapy.	
Adverse Effects	Sunburn, itch, tanning and skin ageing. Safe in pregnancy.	Adverse effects related to photosensitivity from psoralen administration – need for sun protection and sun avoidance, including eye protection for oral PUVA (risk of cataracts). Oral PUVA can cause nausea and vomiting and its safety has not been established during pregnancy.
Long-term safety	Minimal skin cancer risk even with multiple treatments.	Increased risk of non-melanoma skin cancer and melanoma with prolonged treatment, especially in Caucasian skin.

Table 3. Comparison between NB-UVB and PUVA



There has been a concern regarding the potential carcinogenicity of prolonged PUVA therapy, especially the increased incidence of non-melanoma skin cancer and malignant melanoma. Information from 4799 Swedish patients (2343 men, 2456 women) who had received PUVA between 1974 and 1985 was linked to the compulsory Swedish Cancer Registry in order to identify individuals with cancer (Lindelöf B et al 1999). The average follow-up period was 15.9 years for men and 16.2 for women. The authors did not find any increased risk for malignant melanoma in their total cohort of 4799 patients treated with PUVA or in a subcohort comprising 1867 patients followed for 15-21 years. For cutaneous SCC there was an increase in the risk: the relative risk was 5.6 (95% confidence interval, CI 4.4-7.1) for men and 3.6 (95% CI 2.1-5.8) for women.

However, the majority of research demonstrating an increased incidence of skin cancer with psoralen plus ultraviolet A (PUVA) therapy had mainly reflected the Caucasian experience. A study (Murase JE et al 2005) was done of 4,294 long-term PUVA patients in Japan, Korea, Thailand, Egypt, and Tunisia with a follow-up period of at least 5 years. The relative risk of PUVA patients developing non-melanoma skin cancer relative to general dermatology outpatients was 0.86 [CI 0.36-1.35]. The study showed that there does not appear to be an increased risk of nonmelanoma skin cancer with long-term PUVA therapy in Asian and Arabian-African populations. Thus, in phototherapy risk assessment, it is important to consider the patient's skin phototype and the potential protection that more pigmented skin may confer.

#### **4. Guidance from the British Association of Dermatologists guidelines and the Cochrane review**

The British Association of Dermatologists (BAD) published clinical guidelines on the management of vitiligo (2008) that recommend that NB-UVB phototherapy (or PUVA) should be considered only in patients who cannot be adequately managed with conservative topical treatments, have widespread disease, or have localized disease significantly impacting quality of life.

For non-segmental vitiligo, NB-UVB is preferred to PUVA because of greater efficacy. The BAD also recommends an arbitrary limit of 200 treatments with NB-UVB for patients with skin types I-III, and 150 treatments with PUVA for patients with skin types I-III. This is in view of the greater susceptibility of depigmented skin to sunburn and photodamage due to absence of melanin.

A Cochrane review on the management of vitiligo (2006, updated in 2010) showed limited-to-moderate evidence for various types and regimens of phototherapy (UVA and UVB) used alone or in combination with psoralens, calcipotriol, folic acid and vitamin B12, oral L-phenylalanine and topical pseudocatalase. Topical khellin combined with UVA is commonly used throughout the world but there is a lack of evidence of its benefit. This is also the case for topical tacrolimus and topical calcipotriol used in conjunction with ultraviolet light, oral Ginkgo biloba, and thin split-thickness grafts. The reviewers recommended that more randomized controlled trials are needed to fully establish the efficacy and safety of widely used interventions such as steroids, photochemotherapy using PUVA or khellin and NB-UVB monotherapy. In the future, these should also incorporate patient-centred outcomes such as quality of life indices.

## 5. Conclusion


Conventional therapies for vitiligo require months to years of treatment and sometimes result in disappointing outcomes, particularly in difficult areas in the extremities. Thus far, NB-UVB has remained as one of the most effective and safe treatments for vitiligo and the options of targeted phototherapy and combinations with various topical modalities provide additional choices in the dermatologist's armamentarium. PUVA therapy has also been clearly shown to be efficacious but is associated with a higher risk of the adverse effects due to psoralen administration, and an increased risk of skin cancer especially in Caucasian skin.

## 6. References

- [1] CL Hexsel, RH Huggins, HW Lim. Light-Based Therapies for Skin of Color 2009, 171-187, DOI: 10.1007/978-1-84882-328-0\_6.
- [2] Matz H, Tur E. Vitiligo. *Curr Probl Dermatol*. 2007;35:78-102.
- [3] Yashar SS, Gielczyk R, Scherschun L, Lim HW. Narrow-band ultraviolet B for vitiligo, pruritus, and inflammatory dermatoses. *Photodermatol Photoimmunol Photomed* 2003; 19: 164-168.
- [4] Njoo MD, Spuls PI, Bos JD, Westerhof W, Bossuyt MM. Nonsurgical repigmentation therapies in vitiligo. Metaanalysis of the literature. *Arch Dermatol* 1998;134:1532-40.
- [5] Asawanonda P, Charoenlap M, Korkij W. Treatment of localized vitiligo with targeted broadband UVB phototherapy: A pilot study. *Photodermatol Photoimmunol Photomed* 2006;22:133-6
- [6] Pravit Asawanonda, Jirasin Kijluakiat , Wiwat Korkij and Wannasri Sindhupak. Targeted Broadband Ultraviolet B Phototherapy Produces Similar Responses to Targeted Narrowband Ultraviolet B Phototherapy for Vitiligo: A Randomized, Double-blind Study. *Acta Derm Venereol* 2008; 88: 376-381
- [7] Njoo MD, Westerhof W, Bos JD, Bossuyt PM. The development of guidelines for the treatment of vitiligo. Clinical Epidemiology Unit of the Istituto Dermopatico dell'Immacolata-Istituto di Recupero e Cura a Carattere Scientifico (IDI-IRCCS) and the Archives of Dermatology. *Arch Dermatol* 1999; 135:1514.
- [8] Scherschun L, Kim JJ, Lim HW. Narrow-band ultraviolet B is a useful and well-tolerated treatment for vitiligo. *J Am Acad Dermatol* 2001; 44:999.
- [9] Anbar TS, Westerhof W, Abdel-Rahman AT, El-Khayyat MA. Evaluation of the effects of NB-UVB in both segmental and non-segmental vitiligo affecting different body sites. *Photodermatol Photoimmunol Photomed* 2006; 22:157.
- [10] Brazzelli V, Antoninetti M, Palazzini S, et al. Critical evaluation of the variants influencing the clinical response of vitiligo: study of 60 cases treated with ultraviolet B narrow-band phototherapy. *J Eur Acad Dermatol Venereol* 2007; 21:1369.
- [11] Esfandiarpour I, Ekhlasi A, Farajzadeh S, Shamsadini S. The efficacy of pimecrolimus 1% cream plus narrow-band ultraviolet B in the treatment of vitiligo: a double-blind, placebo-controlled clinical trial. *J Dermatolog Treat* 2009; 20:14.
- [12] Mehrabi D, Pandya AG. A randomized, placebo-controlled, double-blind trial comparing narrowband UV-B Plus 0.1% tacrolimus ointment with narrowband UV-B plus placebo in the treatment of generalized vitiligo. *Arch Dermatol* 2006; 142:927.

- [13] Majid I. Does topical tacrolimus ointment enhance the efficacy of narrowband ultraviolet B therapy in vitiligo? A left-right comparison study. *Photodermatol Photoimmunol Photomed* 2010; 26:230.
- [14] Sassi F, Cazzaniga S, Tessari G, et al. Randomized controlled trial comparing the effectiveness of 308-nm excimer laser alone or in combination with topical hydrocortisone 17-butyrate cream in the treatment of vitiligo of the face and neck. *Br J Dermatol* 2008; 159:1186.
- [15] Passeron T, Ostovari N, Zakaria W, et al. Topical tacrolimus and the 308-nm excimer laser: a synergistic combination for the treatment of vitiligo. *Arch Dermatol* 2004; 140:1065.
- [16] Lu-yan T, Wen-wen F, Lei-hong X, et al. Topical tacalcitol and 308-nm monochromatic excimer light: a synergistic combination for the treatment of vitiligo. *Photodermatol Photoimmunol Photomed* 2006; 22:310.
- [17] Goktas EO, Aydin F, Senturk N, et al. Combination of narrow band UVB and topical calcipotriol for the treatment of vitiligo. *J Eur Acad Dermatol Venereol* 2006; 20:553.
- [18] Tjioe M, Gerritsen MJ, Juhlin L, van de Kerkhof PC. Treatment of vitiligo vulgaris with narrow band UVB (311 nm) for one year and the effect of addition of folic acid and vitamin B12. *Acta Derm Venereol.* 2002;82(5):369-72.
- [19] Parrish JA, Fitzpatrick TB, Shea C, et al. Photochemotherapy of vitiligo. *Arch Dermatol* 1976;112:1531-4.
- [20] Lassus A, Halme K, Eskelinen A, et al. Treatment of vitiligo with oral methoxsalen and UVA. *Photodermatology* 1984;1:170-3.
- [21] Pathak MA, Mosher DB, Fitzpatrick TB, et al. Safety and therapeutic effectiveness of 8-methoxypsoralen, 4,5,8-trimethylpsoralen, and psoralen in vitiligo. *Natl Cancer Inst Monogr* 1984;66:165-73.
- [22] Bhatnagar A, Kanwar AJ, Parsad D. Comparison of systemic PUVA and NB-UVB in the treatment of vitiligo: an open prospective study. *J Eur Acad Dermatol Venereol* 2007; 21:638-42.
- [23] Grimes PE, Minus HR, Chakrabarti SG, Enterline J, Halder R, Gough JE, Kenney JA Jr. Determination of optimal topical photochemotherapy for vitiligo. *J Am Acad Dermatol.* 1982 Dec;7(6):771-8.
- [24] Ermis O, Alpsoy E, Cetin L, Yilmaz E. Is the efficacy of psoralen plus ultraviolet A therapy for vitiligo enhanced by concurrent topical calcipotriol? A placebo-controlled double-blind study. *Br J Dermatol* 2001; 145:472.
- [25] Parsad D, Saini R, Verma N. Combination of PUVASol and topical calcipotriol in vitiligo. *Dermatology* 1998; 197:167.
- [26] Khalid M, Mujtaba G, Haroon TS. Comparison of 0.05% clobetasol propionate cream and topical Puvasol in childhood vitiligo. *Int J Dermatol.* 1995 Mar;34(3):203-5
- [27] Siddiqui AH, Stolk LM, Bhaggoe R, Hu R, Schutgens RB, Westerhof W. L-phenylalanine and UVA irradiation in the treatment of vitiligo. *Dermatology.* 1994;188(3):215-8
- [28] Camacho F, Mazuecos J. Oral and topical L-phenylalanine, clobetasol propionate, and UVA/sunlight--a new study for the treatment of vitiligo. *J Drugs Dermatol.* 2002 Sep;1(2):127-31
- [29] Kachhawa D, Kalla G. Keratinocyte-melanocyte graft technique followed by PUVA therapy for stable vitiligo. *Indian J Dermatol Venereol Leprol.* 2008 Nov-Dec;74(6):622-4.

- [30] Lindelöf B, Sigurgeirsson B, Tegner E, Larkö O, Johannesson A, Berne B, Ljunggren B, Andersson T, Molin L, Nylander-Lundqvist E, Emtestam L. PUVA and cancer risk: the Swedish follow-up study. *Br J Dermatol.* 1999 Jul;141(1):108-12.
- [31] Murase JE, Lee EE, Koo J. Effect of ethnicity on the risk of developing nonmelanoma skin cancer following long-term PUVA therapy. *Int J Dermatol.* 2005 Dec;44(12):1016-21.
- [32] Gawkrödger DJ, Ormerod AD, Shaw L, Mauri-Sole I, Whitton ME, Watts MJ, Anstey AV, Ingham J, Young K; Therapy Guidelines and Audit Subcommittee, British Association of Dermatologists; Clinical Standards Department, Royal College of Physicians of London; Cochrane Skin Group; Vitiligo Society. Guideline for the diagnosis and management of vitiligo. *Br J Dermatol.* 2008 Nov;159(5):1051-76.
- [33] Whitton ME, Ashcroft DM, Barrett CW, Gonzalez U. Interventions for vitiligo. *Cochrane Database Syst Rev.* 2006 Jan 25;(1):CD003263.
- [34] Whitton ME, Pinart M, Batchelor J, Lushey C, Leonardi-Bee J, González U. Interventions for vitiligo. *Cochrane Database Syst Rev.* 2010 Jan 20;(1):CD003263.
- [35] Halpern SM, Anstey AV, Dawe RS, Diffey BL, Farr PM, Ferguson J, Hawk JL, Ibbotson S, McGregor JM, Murphy GM, Thomas SE, Rhodes LE. Guidelines for topical PUVA: a report of a workshop of the British photodermatology group. *Br J Dermatol.* 2000 Jan;142(1):22-31.
- [36] Ibbotson SH, Dawe RS, Farr PM. The effect of methoxsalen dose on ultraviolet-A-induced erythema. *J Invest Dermatol.* 2001 May;116(5):813-5.



## **Vitiligo - Management and Therapy**

Edited by Dr. Kelly KyungHwa Park

ISBN 978-953-307-731-4

Hard cover, 174 pages

**Publisher** InTech

**Published online** 14, December, 2011

**Published in print edition** December, 2011

Vitiligo: Management and Therapy is a practical guide to vitiligo that reflects current research related to the fundamentals of vitiligo and its management. Vitiligo experts and researchers from all over the world have contributed to this text, accounting for its comprehensive nature and diverse array of topics. The recent advances in medicine and technology have led to a better understanding of the disease and have broadened available treatment options. The essentials are captured in this book and are complemented by useful clinical photographs and reference tables. This concise tool will serve as an invaluable resource for clinicians in daily practice.

### **How to reference**

In order to correctly reference this scholarly work, feel free to copy and paste the following:

Jiun-Yit Pan and Robert P.E. Sarkany (2011). A Comparison of NB-UVB and PUVA in the Treatment of Vitiligo, Vitiligo - Management and Therapy, Dr. Kelly KyungHwa Park (Ed.), ISBN: 978-953-307-731-4, InTech, Available from: <http://www.intechopen.com/books/vitiligo-management-and-therapy/a-comparison-of-nb-uvb-and-puva-in-the-treatment-of-vitiligo>

# **INTECH**

open science | open minds

### **InTech Europe**

University Campus STeP Ri  
Slavka Krautzeka 83/A  
51000 Rijeka, Croatia  
Phone: +385 (51) 770 447  
Fax: +385 (51) 686 166  
[www.intechopen.com](http://www.intechopen.com)

### **InTech China**

Unit 405, Office Block, Hotel Equatorial Shanghai  
No.65, Yan An Road (West), Shanghai, 200040, China  
中国上海市延安西路65号上海国际贵都大饭店办公楼405单元  
Phone: +86-21-62489820  
Fax: +86-21-62489821

© 2011 The Author(s). Licensee IntechOpen. This is an open access article distributed under the terms of the [Creative Commons Attribution 3.0 License](#), which permits unrestricted use, distribution, and reproduction in any medium, provided the original work is properly cited.