

# Advances in Gastrostomy Placement and Care in Children

Stephen Adams and Anies Mahomed  
*Royal Alexandra Children's Hospital, Brighton  
United Kingdom*

## 1. Introduction

Gastrostomy Placement in Children has advanced much in recent years. We have experience in standard techniques of open and percutaneous endoscopic Gastrostomy placement and continue to expand our surgical portfolio to include minimally invasive techniques for gastrostomy placement. Over the past 2 years our department has placed 49 new gastrostomy devices, (Age: Median 2.6 years, Range 0-18) for a wide range of diagnoses. In this chapter we chart the history of the Gastrostomy in children, indications and methods for placement including an overview of more recent techniques, their risks and benefits.

## 2. Historical perspective

Gastrostomy is probably the first operation performed on the human stomach and was successfully practised in adults from the mid to late 1800s. The credit for being the first surgeon to describe and successfully establish a gastrostomy in a human belongs to Sédillot of Strasbourg. He published his article "De la Gastrostomie Fistuleuse" in France in 1846. The main initial complication of the procedure was development of peritonitis in the immediate post-operative phase. This was ameliorated somewhat by development of the technique to involve suturing a portion of the stomach to the peritoneum and leaving several days prior to opening the presenting area of the stomach. In these pre-Listerian days success was significantly limited and no patients were recorded as surviving until 1876. This is likely to have been affected by the underlying (usually malignant) conditions for which the procedure was being used.

Further developments were aimed at preventing leak and related skin excoriation. Notable amongst the earlier success were two French surgeons named Fontan and Pénieres who in the late 1800s described a new technique whereby all the layers of the stomach were used in the creation of a type of valve. A Belgian surgeon named Dépage also described the use of a mucous lined tube in the creation of the fistula. By 1899 a Japanese surgeon named Watsudjii had published a modification of these techniques such as to bring the gastrostomy to the skin through the rectus abdominus muscle, thus creating the first continent gastrostomy. Subsequent descriptions and modifications of what we now recognise as an open gastrostomy were made by many and names such as Janeway, Spivack and Stamm will come to mind when one considers this history further. (Cunha 1946)

The next significant change in technique came in 1980 when Gauderer and Ponsky first described a method for Gastrostomy placement which avoided the previously associated laparotomy. The Percutaneous Endoscopic Gastrostomy (PEG) was described in a cohort of high risk patients, around one third of whom were children. The technique which will be explored in more detail later in this chapter was to revolutionise our concept of gastrostomy placement. (Gauderer et al. 1980)

The first uses of Gastrostomy in children were for treating patients with caustic oesophageal strictures. Subsequently the incidence of such strictures has markedly reduced and the indication for gastrostomy has changed. Its use in neonates, which was more prevalent in the 1970s and 1980s, has now reduced as neonatal and peri-operative care has improved. The population of neuro-developmentally delayed children has increased dramatically as the capacity to provide advanced neonatal care has developed. This group now presents the most common requirement for gastrostomy placement in current paediatric practice. (Gauderer 1992)

### **3. Indications and assessment for gastrostomy placement**

The three main indications for gastrostomy placement in children are;

1. Long term feeding
2. Gastric decompression
3. A combination of the above

Additional uses include the administration of medication, gastric access for passage of oesophageal dilators and gastroscopy. (Gauderer 1992)

The European Society for Clinical Nutrition and Metabolism (ESPEN) has issued a consensus statement which provides guidelines in relation to Percutaneous Endoscopic Gastrostomy (Lo et al. 2005). These suggest that when oral feeding is no longer possible or adequate for an expected duration of greater than 2-3 weeks there is an indication for PEG placement. Additionally these guidelines suggest that a jejunal extension of the PEG tube be placed when there is a significant risk of aspiration. The placement of any form of adjuvant device for feeding requires careful consideration and planning and whilst the ESPEN statement does provide guidance, the authors feel that they should not be regarded as rules to follow, indeed many surgeons will not consider placing a surgical gastrostomy unless it will be required for 3 months or more. (Georgeson 1997)

Given that the most common group to present to the paediatric surgeon for consideration of Gastrostomy placement is the neurologically compromised child it is prudent to consider the issues of Gastro-Oesophageal Reflux (GOR) and upper GI dysmotility prior to proceeding. A combined anti-reflux procedure and Gastrostomy placement can be well advised in a proven case of GOR, since placement of Gastrostomy alone is known to potentially worsen the GOR. (Chung & Georgeson 1998). The main indications for Gastrostomy are listed in Table 1.

Assessment of the child presenting for Gastrostomy placement should commence with a comprehensive clinical history, taking particular note of Acute Life-Threatening Events (ALTEs) and progressive neurological disease likely to mandate an anti-reflux procedure in the future. Diagnostic imaging should involve an upper gastro-intestinal (GI) contrast study in the first instance, this provides both anatomical and functional information likely to influence decision making. In the absence of a clinical history to suggest GOR it may seem

reasonable to base the decision making on this evaluation alone, however a contrast study which does not demonstrate reflux certainly does not exclude it. There are several other investigations in the clinician's armamentarium to help in making this diagnosis.

<i>Indication</i>	<i>Underlying Disease</i>
Inability to swallow	Neurological Disorders (>50% all patients)
	Multiple Congenital Malformations
	Oropharyngeal dysmotility
	Epidermolysis Bullosa
	Others
Inadequate Caloric Intake	Cystic Fibrosis
	Congenital Heart Disease
	Chronic Respiratory Failure
	Chemotherapy in oncologic disease
	Others
Special Feeding Requirements	Unpalatable formula in multiple food allergies
	Unpalatable formula or reliable Gastric access in metabolic diseases
	Unpalatable medications in renal failure
Continuous Enteral Feeding	Short Bowel Syndrome
	Malabsorption

Table 1. Indications and underlying diseases in paediatric patients requiring a PEG - adapted from Frohlich et al (2010)

Twenty-four hour Oesophageal pH monitoring is considered the gold standard test for establishing a diagnosis of GOR. A pH probe is placed just above the lower oesophageal sphincter and recordings are made on a portable device for the ensuing day and night. Gastric-emptying can be assessed to a degree on an Upper GI contrast study, but quantification of emptying can only be made using a Nuclear Medicine "Milk Scan". The presence of significantly delayed gastric emptying may be an indication for a gastric outlet procedure possibly in addition to fundoplication and gastrostomy. Oesophageal manometry and oesophagoscopy, with biopsy, if required can prove a useful adjunct in complex clinical scenarios. (Chung & Georgeson 1998)

#### **4. Standard technique for PEG placement**

The most widely accepted modern technique for paediatric Gastrostomy placement is the Percutaneous Endoscopic Gastrostomy (PEG) as first described by Gauderer and Ponsky in 1980. This technique achieves a sutureless apposition of the stomach to the anterior

abdominal wall with a tube Gastrostomy being left in-situ. It was first described with equipment that was presently available, now there are many specialised kits available from multiple manufacturers to achieve a similar outcome. The basic premise is summarised in Figure 1.

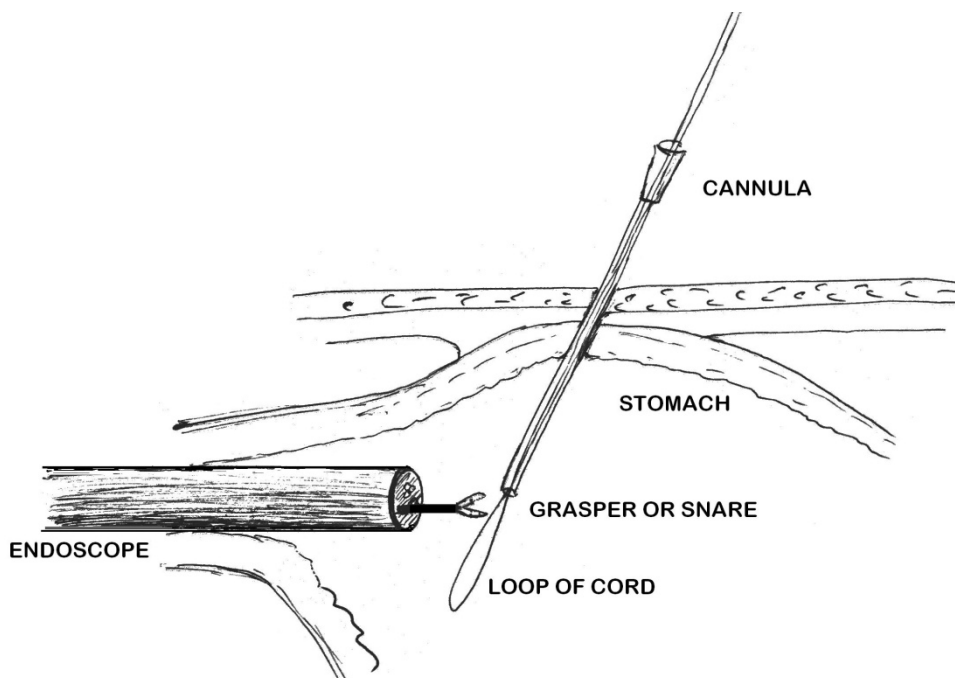


Fig. 1. Depiction of PEG placement – adapted from (Gauderer, Ponsky, & Izant, 1980, Fig 3)

The stomach is intubated with a flexible endoscope which has a working channel. It is insufflated with air in order to try to push the colon, liver and spleen away from the proposed gastrostomy site. A cannula is placed via the anterior abdominal wall into the stomach under endoscopic vision. A thread passed via the cannula is grasped by the endoscopist and withdrawn through the mouth. A catheter is attached to the string which is then used to pull the catheter down the oesophagus and out through the Gastrostomy site, the catheter is shaped such that the presenting portion is narrow but widens to the full catheter diameter and an internal flange resides against the anterior wall of stomach. A flange at skin level enables maintenance of apposition between the stomach and anterior abdominal wall.

The initial concern with this technique was the potential to pierce the colon and this is in fact a well documented risk, in a recent selection of paediatric case series the rate of this complication is 1 - 2%. The risk of the same complication when the gastrostomy is created in the traditional manner is probably minute and is rarely reported. (Cook 1969) The overall complication rate of standard PEG insertion is variously reported as between 5 and 17%. The major complications are summarised in Table 2 which is adapted from a single centre study of 448 standard paediatric PEG insertions.

<i>Major Complications</i>	<i>%</i>
Death (30 days post-PEG)	1.1
Procedure-related	0.2 (1/448 due to PEG related sepsis)
Oesophageal Perforation	0.2
Peritonitis	1.6
Gastrocolic fistula	1.1
Intra-abdominal bleeding	0.7
Necrosis (PEG Migration)	0.4
Major infection	0.9
GOR after PEG (new or more)	2.9
Major granulation tissue	1.8
Buried bumper	2.5
Miscellaneous (Mainly needle perforations of colon and stomach)	3.3
<b>Total</b>	<b>16.7</b>

Table 2. Major Complications of PEG insertion, adapted from (Vervloessem et al. 2009)

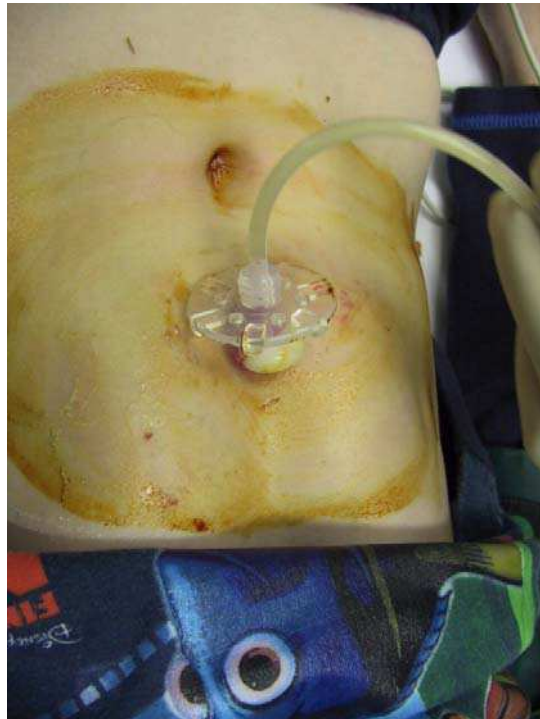


Fig. 2. Complication: extrusion of a Corflo® gastrostomy device

Common, but more minor, complications include minimal granulation tissue, tube migration, dislodgement (this can be a major complication if it occurs within the first 4-6 weeks), stomal enlargement, leakage, skin irritation/breakdown and tube blockage. The gastrostomy tube may be an annoyance to the child and some children with PEG avoid spending time prone, this may lead to developmental issues with upper torso and head control. When it is no longer required the Gastrostomy tube is removed and the stoma permitted to close. The stoma usually closes rapidly however occasionally this can take several weeks and be problematic due to profuse leakage of gastric content. Rarely a persistent gastro-cutaneous fistula will require surgical closure. (Borkowski 1998)

Contra-indications to traditional PEG placement are rarely absolute. Extreme kyphoscoliosis, previous upper GI surgery, hepato- or spleno-megaly, colonic interposition, presence of ventriculo-peritoneal shunt and Situs Inversus should all be considered to present significantly increased risk during PEG placement. In this scenario it is wise to consider whether additional measures should be taken for intra-operative imaging of at-risk structures. This can be achieved with laparoscopy or additional radiographical imaging at the time of PEG placement. Such techniques are discussed later in this chapter.

## 5. Gastrostomy devices

The Malecot, dePezzer and Foley catheters are examples of tubes used when creating an open gastrostomy. More recently specific gastrostomy balloon catheters have been produced. The type of Gastrostomy tube used in placing a PEG usually has a plastic internal disc, examples include the CorFlo® and Freka® PEG tubes (see figure 3).

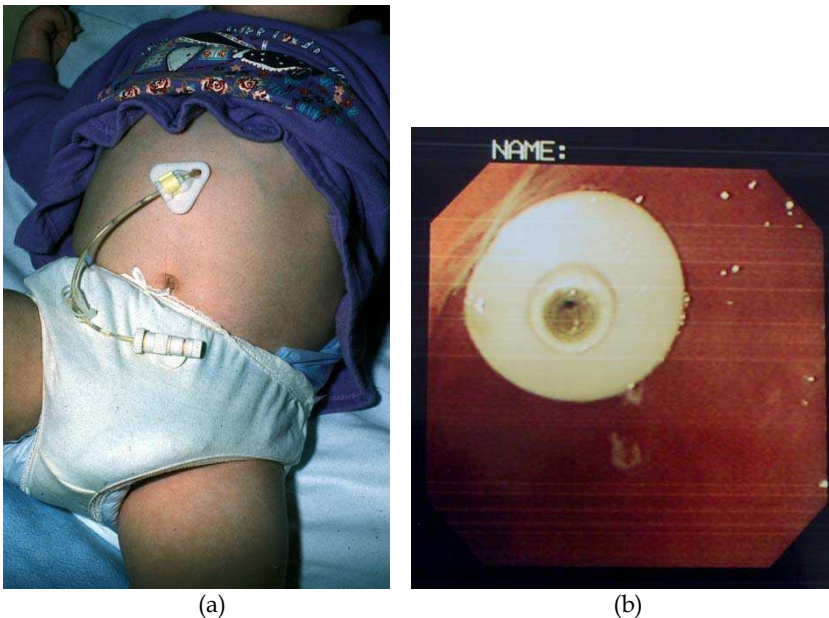


Fig. 3. FREKA® gastrostomy device - (a) External view and (b) endoscopic view demonstrating disc secured against anterior gastric wall

Button Gastrostomy devices (Figures 4 and 5) have emerged onto the market in the past number of years. They have a much lower profile to the patient's abdomen as there is no requirement for tubing to be connected at all times. Instead, the feed tubing is attached, usually via insertion of a plastic nipple into a valve on the button, only at times when feeding is required. The majority of buttons currently in use have a balloon internally holding them in the stomach. There are buttons however available with an internal plastic cage, these are felt by some surgeons to be more difficult to pull out by accident and may thus be more suitable for some patients.

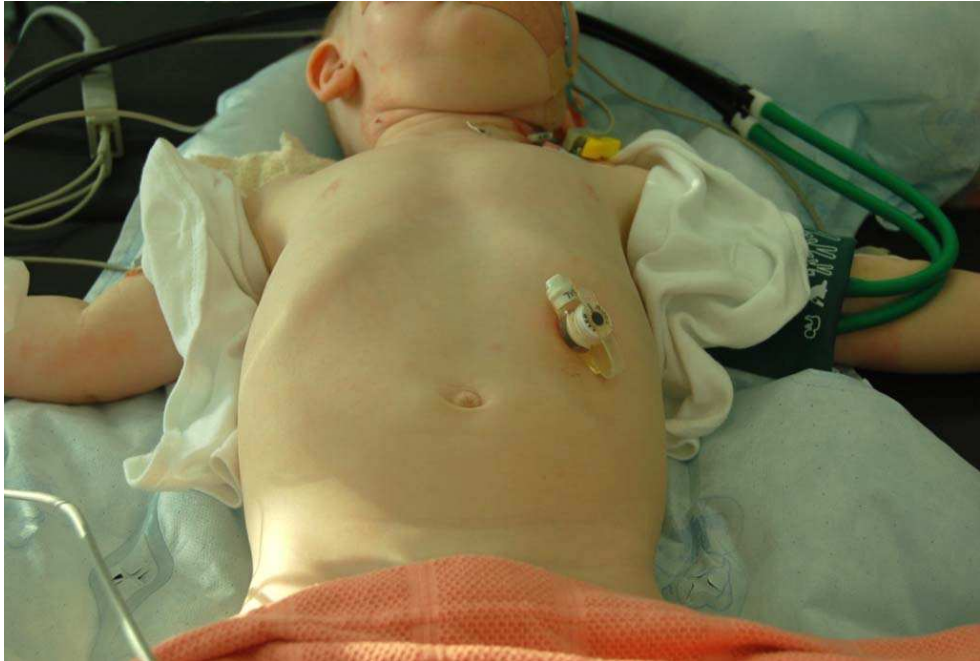

Fig. 4. Infant with button balloon gastrostomy device in situ

A variety of other specialised devices have been produced which enable radiological placement of a gastrostomy tube and also devices to access the jejunum via a gastrostomy, either as an extension to a gastrostomy device or as an exclusive gastro-jejunal tube.

The utility of these jejunal tubes as a long-term solution for enteral feeding, particularly for a child with severe gastro-oesophageal reflux, is debatable due to the high rate of associated morbidity and in particular the frequency of tube displacement. In one reported series of 14 patients with gastro-jejunal tubes there were 65 complications reported in 18 tube insertions (4.6 complications per child). The most common problem was tube migration/displacement (43 episodes). (Godbole et al. 2002)

The other disadvantage of jejunal feeding is the inability to bolus feed and thus feeds must be given continuously over at least 14 hours. These tubes can provide a stop-gap for enteral nutrition when necessary and there is supportive evidence for the nutritional benefits, however they will not usually be the best choice for ongoing nutrition.

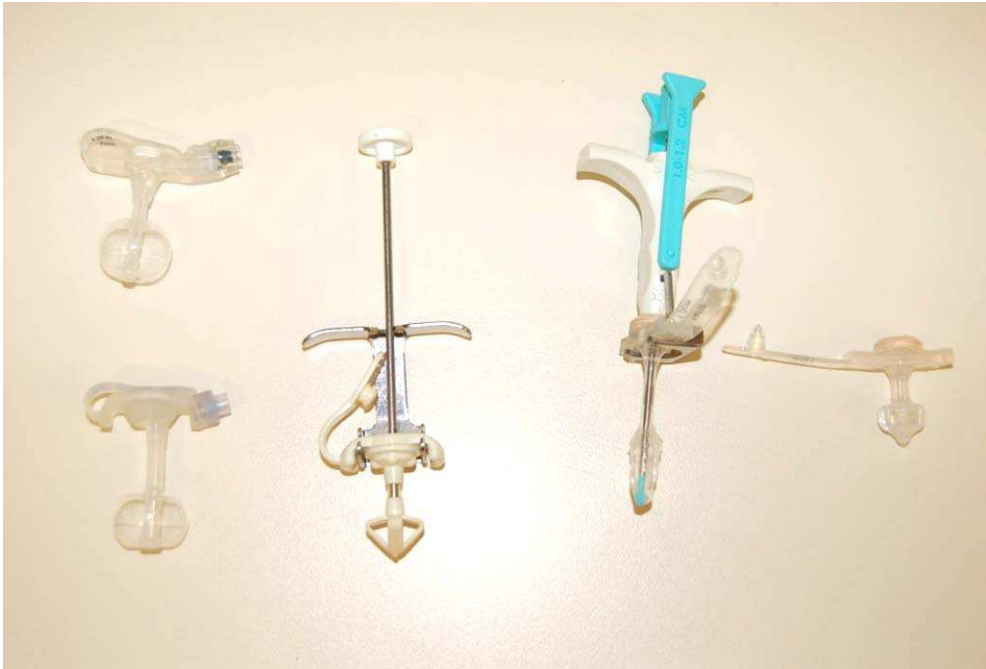

Fig. 5. A Selection of balloon and cage type button gastrostomy devices and their deployment/removal tools

The development of buttons and their better acceptance by parents has led to the development of techniques by which a button gastrostomy can be placed at the initial operation. This technique is addressed in detail in the next section. If this technique is not utilised, many surgeons will replace an initial PEG tube with a button only under a second anaesthetic, usually when the gastrostomy tract has matured and several months post initial PEG placement.

## 6. Changes in techniques for gastrostomy placement

Aside from the sea-change already described following the introduction of the PEG technique in 1979, there have been major developments in the area of minimal access surgery and interventional radiology. Here we discuss the methods and potential benefits of minimal access surgery and interventional radiology in the placement of gastrostomy devices.

### 6.1 Solely laparoscopic technique

Laparoscopy has developed a significant role in paediatric surgery, it is used widely for fundoplication of the stomach and many other operations that previously required a more invasive approach (Chung & Georgeson 1998). The visualisation of structures neighbouring the stomach when a laparoscope is used is felt by many to ameliorate the risks of collateral injury associated with PEG placement.



The purely laparoscopic technique was described initially in a porcine model and then utilised in children (G. Stringel et al. 1993). It requires placement of 1 laparoscopic camera and 2 working ports in an anaesthetised patient. The stomach is visualised and brought near to the anterior abdominal wall. A needle is introduced and seen to pass into the lesser curve of the stomach, apparently confirmed by a rush of air through the needle. The stomach is secured to the anterior abdominal wall with a T-fastener. A wire is then passed into the stomach and a series of dilators are used until the stoma is large enough to accept the gastrostomy tube. The system is tested by passing water into the stomach via NG tube and then aspirating it via the new gastrostomy.

The element of uncertainty remains in regard to intra-luminal placement of the gastrostomy with this method, hence the test with water as described, and the same authors also describe a similar technique for laparoscopic assisted placement.

## 6.2 Laparoscopic-assisted PEG +/- Laparoscopic fundoplication

This technique follows the original principles of PEG placement (Gauderer et al. 1980) with the addition of concurrent laparoscopic visualisation of the abdominal viscera. This enables avoidance of injury to neighbouring viscera and the other reported benefit is that PEG placement can be achieved specifically into the lesser curvature of the stomach which has been seen by some to decrease the risk of developing gastro-oesophageal reflux subsequent to PEG placement, this is of particular relevance in neuro-developmentally delayed children (B. G. Stringel et al. 1995).

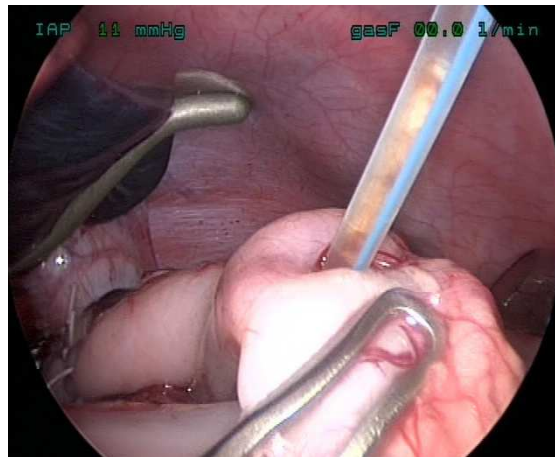

Fig. 6. Clear views obtained during Laparoscopic assisted FREKA® gastrostomy placement in a patient undergoing a fundoplication

This technique is performed by undertaking laparoscopy with a camera port in the umbilicus (5mm or 10mm) and a 5mm working port placed under vision in the upper abdomen or epigastrium. The oesophagus is then intubated with a flexible fibre-optic gastrostomy which is passed to the stomach. The stomach is held with a laparoscopic grasper and air is carefully insufflated endoscopically. The stomach is held up to the anterior abdominal wall and a needle is passed into its lumen under endoscopic and

laparoscopic vision (Figure 6). The wire or string is passed through the needle to the stomach, grasped and withdrawn through the mouth for attachment to the PEG tube and pulled back down into position as per Gauderer-Ponsky (Charlesworth et al. 2010).

Whilst the substantial benefits of this procedure are that neighbouring viscera can be clearly seen and thus avoided and the position of the site for PEG can be carefully chosen, the major potential pitfall is insufflation of too much air into the stomach prior to having laparoscopic control of the organ. In this scenario the proximal small bowel may dilate and obscure the laparoscopic view, potentially necessitating conversion to open gastrostomy formation.

The technique for insertion of PEG at the end of a laparoscopic anti-reflux procedure is similar to that described here. The obvious concern is that pulling a PEG tube and retaining disc through a freshly made fundoplication may impact on the safety and efficacy of the initial procedure. In our series of 20 patients undergoing laparoscopic fundoplication and placement of FREKA® PEG we demonstrated no obvious adverse impact of this procedure when compared to laparoscopic fundoplication alone. The placement, or indeed replacement, of a PEG at the conclusion of an anti-reflux procedure is occasionally mandated, particularly in neuro-developmentally delayed children, as it is safe and does not appear to impact on the efficacy of the fundoplication (Barber et al. 2009).

### 6.3 Primary Button

All the PEG insertion techniques described thus far involve an internal retaining disc, this usually precludes removal in the awake child and many surgeons routinely change the PEG to a balloon gastrostomy device (either Gastrostomy tube or Button) under anaesthetic some months, even up to two years, after the initial PEG placement. In order to avoid this first change of PEG to balloon device there has been a move in recent years toward primary placement of cage or balloon type button gastrostomy devices. (Figure 7)

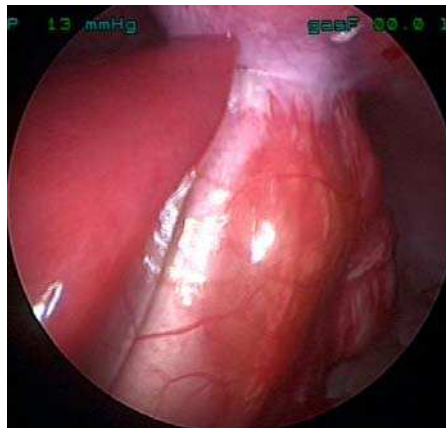


Fig. 7. Laparoscopic assisted primary Button gastrostomy placement in a newborn with oesophageal atresia without fistula

This technique was first presented in 1999. It involves placement of an umbilical laparoscopic camera port and a single (5mm) left upper quadrant working port placed under direct vision. A stitch is passed into the working port and an instrument is passed

down after it. The traction stitch is placed through the desired area of the stomach and the ends both brought out through the trocar. The trocar is then removed and if necessary the tract is dilated with a clamp, the suture is used to deliver the stomach up into the opening. Two stay sutures are placed on either side of the presenting portion and these are secured through anterior rectus fascia and are left loose until the button is in place. A single purse-string suture is placed on the stomach and a gastrostomy incision made in the centre. An appropriate button device is placed (the original description is with a balloon type gastrostomy button) and the purse-string and then the stay sutures are secured. If the wound was increased for access it is then closed. (Rothenberg et al. 1999)

The significant advantage of this procedure is the direct visualisation of the stomach and surrounding organs ensuring safety in placement. The technique as described is minimally invasive utilising only one incision in addition to the umbilical camera port, this makes it very suitable for use at the end of a laparoscopic procedure where-by an appropriately sited port-site can be used for gastrostomy placement. (Figure 8)

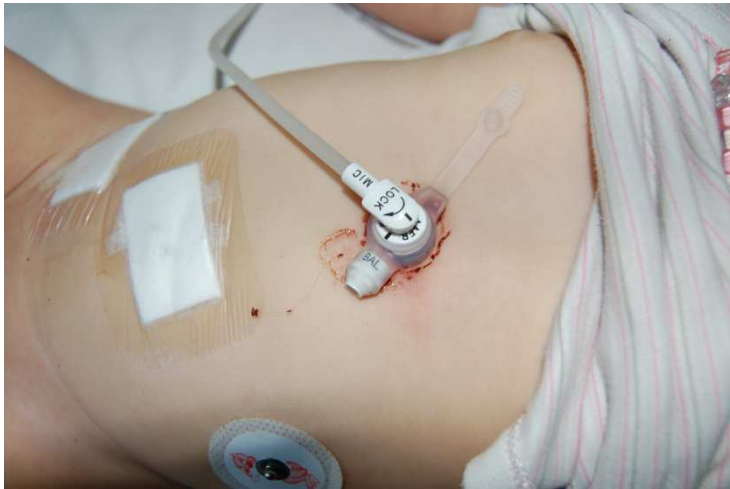


Fig. 8. Complex patient with Kabuki's Syndrome with lap assisted primary button placement. Patient underwent right nephrectomy and repair of right diaphragmatic eventration under the same anaesthetic

The associated complications in this group are certainly similar to most gastrostomy placement methods. Early displacement of the gastrostomy button, however, should be easy to manage since the stomach is well apposed to the abdominal wall with sutures. Nevertheless it is wise to ensure any early replacement tube or button is intra-luminal either endoscopically or with water-soluble contrast fluoroscopy.

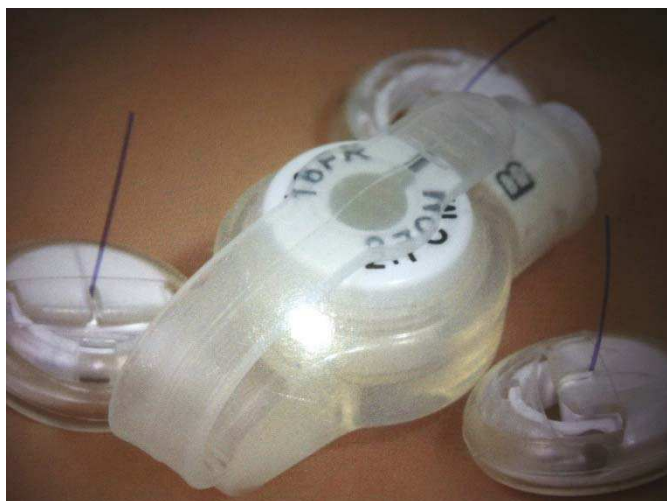#### 6.4 Radiologically placed gastrostomy

Radiologically Placed Gastrostomy (RPG) is a developing field driven mainly by the increasing demand for gastrostomy placement in adults. It has the significant advantage of requiring no anaesthetic and no tubes or wires need to be passed down the oesophagus. This is particularly helpful in the group of patients with head, neck or oesophageal tumours.

Its utility in children remains largely unproven, due to the increased requirement for anaesthesia for interventions in children removing one of the factors that recommend RPG. The reported complication rates in adults do appear significantly lower than for surgical gastrostomy techniques and we should consider whether there is a greater role for RPG in children. (Given et al. 2004)



(a)



(b)

Fig. 9. The MIC-KEY® percutaneous gastrostomy T-fastener and example of its use with a gastrostomy button for either radiological or endoscopic placement

Whilst the methods described for PEG placement have included a “pull technique”; RPG, in common with primary buttons and laparoscopic gastrostomy placement, requires a “push technique”. This means that a wire being passed into the stomach through the anterior

abdominal wall is used as a conduit for dilatation and subsequent passage of the gastrostomy device. It is possible, but more complex, to perform a "pull technique" RPG and it requires 2 operators. For safety it is widely practised that the patient being fasted for this procedure is given a quantity of dilute barium 12 hours prior so as to outline the colon. It is usual to perform a localised gastropexy with percutaneous T-fasteners (Figure 9) prior to insertion of the gastrostomy to ensure that the stomach wall remains approximated to the anterior abdominal wall.

One of the advantages of these techniques is that placement of gastro-jejunoscopy tubes as a primary procedure is possible. As remarked earlier in this chapter the utility of such tubes is up for debate, however if one does wish to place such a tube the modifications to the technique above are not major and there is a relatively high success rate (Given et al. 2005).

## 7. Conclusion

The history of gastrostomy is very long and there has been very significant progress since the introduction of the Percutaneous Endoscopic Gastrostomy in 1979. More recent developments in minimal access surgery have driven the production of new devices and description of new techniques further and faster still. The benefits to our young patients have been significant and our ability to treat more complex and more difficult cases has been greatly aided by this process.


## 8. Acknowledgment

We are grateful to the parents who consented to photographs of their children appearing in this chapter.

## 9. References

- Barber, N., Carden, C. & Mahomed, A., 2009. Does the placement of a FRECA gastrostomy at the time of laparoscopic fundoplication impact on outcome? *Surgical endoscopy*, 23(3), pp.598-601.
- Borkowski, S., 1998. PEDIATRIC STOMAS, TUBES, AND APPLIANCES. *Pediatric Clinics of North America*, 45(6), pp.1419-1435.
- Charlesworth, P., Hallows, M. & van der Avoirt, A., 2010. Single-Center Experience of Laparoscopically Assisted Percutaneous Endoscopic Gastrostomy Placement. *Journal of Laparoendoscopic & Advanced Surgical Techniques*, 20(1), pp.73-75.
- Chung, D.H. & Georgeson, K.E., 1998. Fundoplication and gastrostomy. *Seminars in pediatric surgery*, 7(4), pp.213-9.
- Cook, R., 1969. Gastrocolic fistula: A complication of gastrostomy in infancy. *Journal of Pediatric Surgery*, 4(3), p.346-349.
- Cunha, F., 1946. Gastrostomy: Its inception and evolution. *The American Journal of Surgery*, 72(4), pp.610-634.
- Fröhlich, T. et al., 2010. Review article: percutaneous endoscopic gastrostomy in infants and children. *Alimentary pharmacology & therapeutics*, 31(8), pp.788-801.
- Gauderer, M.W., 1992. Gastrostomy techniques and devices. *The Surgical clinics of North America*, 72(6), pp.1285-98.

- Gauderer, M.W., Ponsky, J.L. & Izant, R.J., 1980. Gastrostomy without laparotomy: a percutaneous endoscopic technique. 1980. *Journal of Pediatric Surgery*, 15(6), pp.872-875.
- Georgeson, K.E., 1997. Laparoscopic versus open procedures for long-term enteral access. *Nutrition in clinical practice : official publication of the American Society for Parenteral and Enteral Nutrition*, 12(1 Suppl), pp.S7-8.
- Given, M.F., Hanson, J.J. & Lee, M.J., 2005. Interventional radiology techniques for provision of enteral feeding. *Cardiovascular and interventional radiology*, 28(6), pp.692-703.
- Given, M.F., Lyon, S.M. & Lee, M.J., 2004. The role of the interventional radiologist in enteral alimentation. *European radiology*, 14(1), pp.38-47.
- Godbole, P. et al., 2002. Limitations and uses of gastrojejunal feeding tubes. *Archives of disease in childhood*, 86(2), pp.134-7.
- Lo, C. et al., 2005. Consensus Statement; ESPEN guidelines on Artificial enteral nutrition - percutaneous endoscopic gastrostomy (PEG). *Clinical Nutrition*, 24(5), pp.848-861.
- Rothenberg, S.S., Bealer, J.F. & Chang, J.H.T., 1999. Primary laparoscopic placement of gastrostomy buttons for feeding tubes. *Journal of Pediatric Surgery*, (March), pp.995-997.
- Stringel, B.G., Geller, E.R. & L, M.S., 1995. Laparoscopic-Assisted Percutaneous Endoscopic Gastrostomy. *New York*, 8(8), pp.1209-1210.
- Stringel, G., Robinson, E. & Maisel, S., 1993. Laparoscopic gastrostomy. *Pediatric Surgery International*, 8(5), pp.382-384-384.
- Vervloessem, D. et al., 2009. Percutaneous endoscopic gastrostomy (PEG) in children is not a minor procedure: risk factors for major complications. *Seminars in pediatric surgery*, 18(2), pp.93-7.



## **Gastrostomy**

Edited by Dr. Pavel Kohout

ISBN 978-953-307-365-1

Hard cover, 152 pages

**Publisher** InTech

**Published online** 02, December, 2011

**Published in print edition** December, 2011

The gastrostomy placement is a method of providing nutrition to the patients who are unable to eat. In this book you can find chapters focused on the use of gastrostomy in children, patients with neurological impairment and patients with head and neck tumours. Home enteral nutrition is suitable for all of these groups of patients and is far easier with gastrostomy. The new indications (especially in very young children) required new techniques such as: laparoscopic gastrostomy, laparoscopy assisted endoscopic gastrostomy with/without fundoplication, ultrasonography assisted gastrostomy. All information about these techniques can be found in this book. This book does not serve as a basic textbook, but as an interesting reading material and as an aid for physicians who are already familiar with the indication for gastrostomy and want to know more.

### **How to reference**

In order to correctly reference this scholarly work, feel free to copy and paste the following:

Stephen Adams and Anies Mahomed (2011). Advances in Gastrostomy Placement and Care in Children, Gastrostomy, Dr. Pavel Kohout (Ed.), ISBN: 978-953-307-365-1, InTech, Available from:  
<http://www.intechopen.com/books/gastrostomy/advances-in-gastrostomy-placement-and-care-in-children>

# **INTECH**

open science | open minds

### **InTech Europe**

University Campus STeP Ri  
Slavka Krautzeka 83/A  
51000 Rijeka, Croatia  
Phone: +385 (51) 770 447  
Fax: +385 (51) 686 166  
[www.intechopen.com](http://www.intechopen.com)

### **InTech China**

Unit 405, Office Block, Hotel Equatorial Shanghai  
No.65, Yan An Road (West), Shanghai, 200040, China  
中国上海市延安西路65号上海国际贵都大饭店办公楼405单元  
Phone: +86-21-62489820  
Fax: +86-21-62489821

© 2011 The Author(s). Licensee IntechOpen. This is an open access article distributed under the terms of the [Creative Commons Attribution 3.0 License](#), which permits unrestricted use, distribution, and reproduction in any medium, provided the original work is properly cited.