

Clinical Features of Infectious Conjunctivitis

Udo Ubani

*Dept of Optometry, Abia state university, Uturu
Nigeria*

1. Introduction

Conjunctivitis is the inflammation of the conjunctiva, a thin, translucent, relatively elastic tissue layer with bulbar, forniceal and palpebral portions (figure1). The bulbar portion lines the outer aspect of the globe, while the forniceal which is loose and redundant swells easily and is thrown into folds. The palpebral portion covers the inside of the eyelids firmly adherent to the tarsal plates.

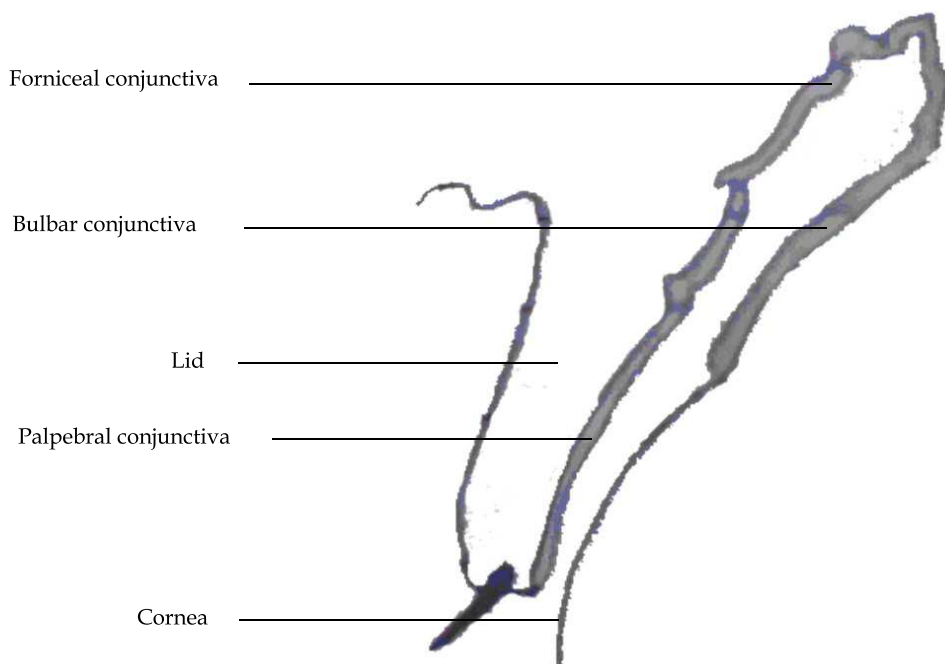


Fig. 1. Portions of the conjunctiva

Conjunctivitis usually presents with eye itching, burning and a sensation of foreign body. The other symptoms are blurred vision, photophobia and ocular pain. While the signs could be hyperaemia, injection, chemosis, hyperlacrimation, discharges, palpebral edema,

follicular and papillary hypertrophy, membrane formation and reactions of lymphatic system. On the cornea there is diminished sheen, transparency and reflexion; Horner-Trantas dots, corneal epithelial defects and scars. These signs and symptoms participate to varying degrees in the differential diagnosis of the various forms of conjunctivitis.

The forms of conjunctivitis are basically 1) Irritant- with a non-specific substance from an eyelash that got stuck to a chemical; 2) allergic- when an allergen comes into contact with the eye, such as dust mites, pollen or animal fur and; 3) Infectious - caused by a bacteria or virus. Others are forms associated with disorders of the ocular adnexia – the lacrimal system, the palpebral (skin, lashes and glands); and disorders of adjacent organs like nasal mucosa, paranasal sinuses and middle ear.

Infectious conjunctivitis accounts for 35% of all eye-related problems recorded by the health service schemes worldwide. This chapter focuses on the clinical features of infectious conjunctivitis

2. Ocular discharges

Ocular discharge can be divided into two main types, serous discharge or the 'wet eye', and purulent discharge. With the terms mucoïd (stringy or ropy) or mucopurulent further used to describe purulent discharge. A serous discharge is most commonly associated with viral or allergic ocular conditions. While a mucoïd discharge is highly characteristic of toxic, Chlamydial or dry eyes. A mucopurulent discharge, often associated with morning crusting and difficulty opening the eyelids, strongly suggests a bacterial infection.

Serous discharge: The ocular surface receives sensory innervation via the ophthalmic branch of the trigeminal nerve (cranial nerve V), except for the lateral canthal area which is supplied by the maxillary branch. Irritation of the ocular surface trigeminal nerve causes an increased production of the reflex tear volume which augments the conjunctival epithelium basal cells tear production. This will increase the total tear film volume which overloads the capacity of the nasolacrimal drainage apparatus and is thus manifested as a 'wet eye'.

Purulent discharge: Bacteriology and cytology should be performed in an eye with purulent discharge; with bacteriology samples ideally collected before antibiotic treatment is started. Differentiation of normal ocular flora from pathogenic flora may be difficult, however normal flora tend to be represented by more than one isolate and usually appear in lighter growth.

The most frequent causes of mucopurulent conjunctivitis are *Neisseria gonorrhoeae* and *Neisseria meningitidis*, with *N. gonorrhoeae* being by far the more common. Gonococcal ocular infection usually presents in neonates (ophthalmia neonatorum) and sexually active young adults. Affected infants typically develop bilateral discharge three to five days after birth. Transmission of the *Neisseria* organism to infants occurs during vaginal delivery. In adults, the organism is usually transmitted from the genitalia to the hands and then to the eyes.

3. Conjunctival reaction

The stroma or substantia propria layer of the conjunctiva is a richly vascularized connective tissue, divided into the deep thicker fibrous subconjunctival, which is continuous with the tarsal plates and the superficial adenoid lymphoid tissue.

Follicles consist of hyperplasia of the lymphoid tissue of the stroma. Follicular conjunctival responses appear as smooth, rounded nodules. These nodules are avascular at their apices and are surrounded by fine vessels at their bases (figure 2). They are usually most prominent in the forniceal conjunctiva. The main causes of follicular conjunctivitis include adenoviral infection, primary herpes simplex viral infection, molluscum contagiosum infection, enteroviral infection, chlamydial infection, and toxicity from certain medications.

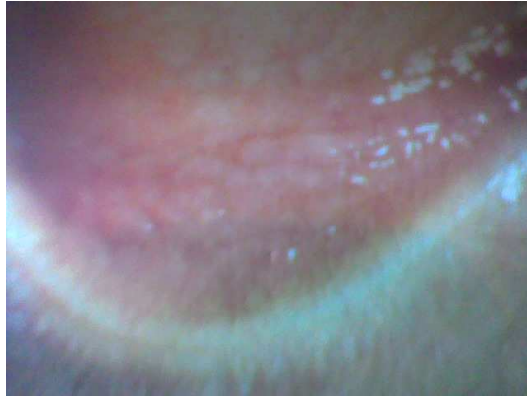

Fig. 2. Follicles at the lower fornix

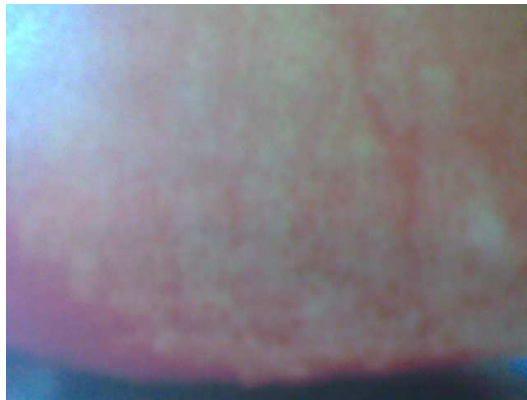

Fig. 3. Papillae reaction of the upper palpebral conjunctiva

In contrast to a follicular conjunctival response, a papillary conjunctival response is nonspecific and can be caused by many agents. It can occur in any nonspecific conjunctival inflammation, including mechanical irritation and allergic eye disease. It is usually seen on the upper tarsal conjunctiva, a papillary response is a fine mosaic pattern of dilated, telangiectatic blood vessels (figure 3). Papillae vary in size from tiny red dots to polygonal elevations. Each papilla has a central fibrovascular core that gives rise to a vessel branching outward in a spoke like pattern. The connective tissue septa surrounding the papillae are anchored in the conjunctival stroma, resulting in hyperemic areas surrounded by pale tissue

when papillary hypertrophy occurs. With prolonged inflammation, the septa may rupture, leading to either papillary confluence, as in infections of bacteria or giant papillae of vernal conjunctivitis.

4. Regional lymphadenopathy

Lymph via afferent lymphatic vessels circulates to and drains into the lymph node; a small ball or an oval-shaped organ ranging in size from a few millimeters to about 1–2 cm in their normal state. Lymph nodes are important in the proper functioning of the immune system. A lymph node can be very well described as a garrison of B, T and other immune cells. In this, during an infection, the lymph nodes function to monitor the lymph for foreign particles, filtering and catching viruses, bacteria, and other unknown materials which they then destroy. With this, the lymph nodes have the clinical significance of becoming inflamed or enlarged (lymphadenopathy) primarily because there is an elevated rate of trafficking of lymphocytes into the node, exceeding the efferent lymphatic vessel rate of outflow from the node, and secondarily as a result of the activation and proliferation of antigen-specific T and B cells.

Humans have approximately 500-600 lymph nodes distributed widely throughout the body, with clusters in the neck, armpits and groin regions. The lymphatic drainage of the conjunctiva is to the preauricular and the submandibular nodes (figure 4). In conjunctivitis, the patient is examined in a well-lit room for this regional lymphadenopathy.

Regional lymphadenopathy often coexists with follicular conjunctivitis representing a similar lymphoblastic proliferation.



Fig. 4. Lymphatic drainage of the conjunctiva

Viral or chlamydial inclusion conjunctivitis typically presents with a small, tender, preauricular or submandibular lymph node. Toxic conjunctivitis secondary to topical medications can also produce a palpable preauricular node. Palpable adenopathy is rare in acute bacterial conjunctivitis. The exception is hyperacute conjunctivitis caused by infection with *Neisseria* species.

Other facial clues to the etiology of conjunctivitis include the presence of herpes labialis or a dermatomal vesicular eruption suggestive of shingles. Either of these findings may indicate a herpetic source of conjunctivitis.

5. Membrane formation

Pseudomembranes consist of coagulated exudates which adhere loosely to the inflamed conjunctiva. They are typically not integrated with the conjunctival epithelium and can be removed by peeling, leaving the conjunctival epithelium intact (figure 5). Their removal produces little if any bleeding. Epidemic keratoconjunctivitis (EKC), ligneous conjunctivitis (a rare idiopathic bilateral membranous/pseudomembranous conjunctivitis seen in children with thick, ropy, white discharge on the upper tarsal conjunctiva), allergic conjunctivitis, and bacterial infections are the primary causes.

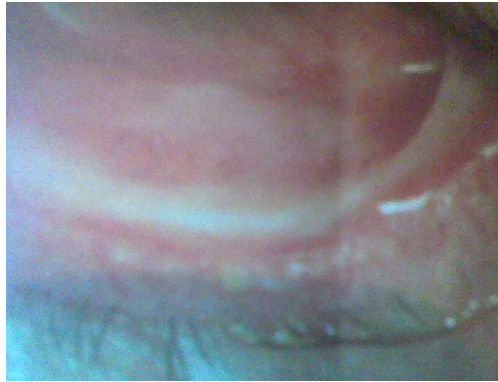

Fig. 5. Conjunctival pseudomembrane

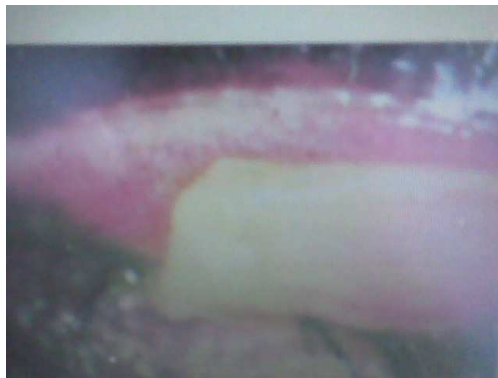

Fig. 6. Tarsal conjunctival True membrane

A **true membrane** forms when the fibrinous excretory or inflammatory exudate that is secreted by invading microorganisms or ocular tissues permeates the superficial layers of the conjunctival epithelium. True membranes become interdigitated with the vascularity of the conjunctival epithelium. They adhere firmly; tearing and bleeding often result when removed (figure 6). B-hemolytic streptococci, *Neisseria gonorrhoeae*, *Corynebacterium diphtheriae*, Stevens-Johnson syndrome (severe systemic vesiculobullous eruptions affecting the mucous membranes-erythema multiforme) and chemical or thermal burns are among the common etiologic sources.

5.1 Ecchymosis or subconjunctival haemorrhage

A subconjunctival hemorrhage is a bleeding underneath the conjunctiva. This varies in extent from small petechial hemorrhage to an extensive spreading under the bulbar conjunctiva; as a flat sheet of homogeneous bright red colour with well defined limits (figure 7). As the condition doesn't cause any pain or discomfort, the condition might be noticed by a colleague before the patient spots it. subconjunctival hemorrhage can look extremely ugly. However, like a bruise, it will start to fade, turning bluish, green, and yellowish before disappearing entirely. Petechial subconjunctival haemorrhages are usually associated with acute picornavirus and pneumococcal infections.

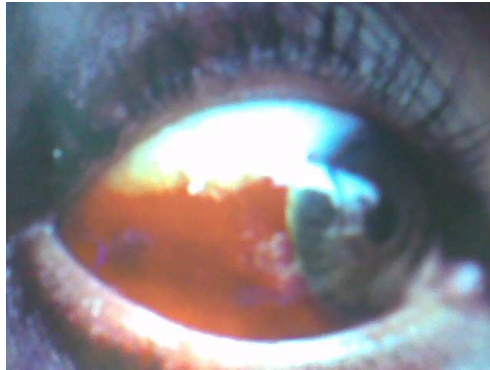


Fig. 7. Conjunctival hemorrhage

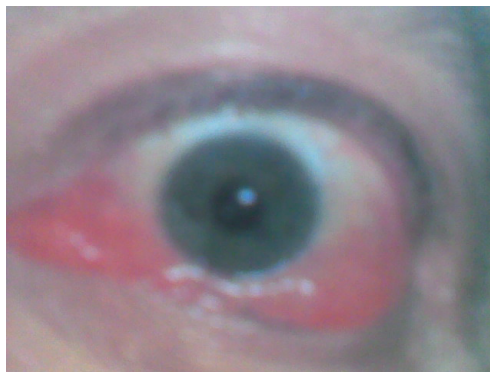

Fig. 8. Chemosis

5.2 Conjunctival injection

Conjunctival injection is an intense focal hyperemia that can outline the overlying rectus tendon.

5.3 Chemosis

Chemosis is an oedema of the conjunctiva that appears as a fold of redundant conjunctiva hanging over the mucocutaneous junction of the lowerlid (figure 8)

5.4 Corneal involvement

A complication of infectious conjunctivitis is the involvement of the layers of the cornea. The study is usually by staining with fluorescein [which stays outside the cells] and rose bengal [which has affinity for dead and degenerating cells]. Observation with slit lamp biomicroscope can describe some features-

5.5 Punctate epithelium keratitis

Punctate epithelium keratitis is characterized by a breakdown or damage of the epithelium of the cornea in a pinpoint pattern. Lesions stain well with Rose Bengal and poorly with fluorescein. It usually marks a viral infection.

5.6 Dendritic ulcer

Still on the epithelium a dendrite ulceration which is usually single or multiple can be described as an earlier opaque cells arranged in a dendritic, punctuate or stellate pattern. Later a linear branching ulcer begins to form following desquamation. The center of the ulcer stain with fluorescein and the virus laden cells of the margin of the ulcer stain with Rose Bengal. Occasionally, the continual enlargement of the dendritic leads to a larger epithelial defect termed geographical.

In the subepithelial space an ingrowth of fibrovascular tissue from the limbus may develop, this is called **Pannus**.

5.7 Interstitial keratitis

In the stroma, a cellular infiltration of leucocytes into the stroma layer of the cornea without involving the epithelium or endothelium is known as interstitial keratitis. It is most notably associated with congenital syphilis and tuberculosis.

5.8 Disciform keratitis

Deep on the posterior layer, disciform keratitis also called endothelitis describes a fold in the descemet's membrane. It is either caused by a reactivated viral infection of the corneal endothelium or a hypersensitive reaction to antigen.

5.9 Diagnostic procedures of infectious conjunctivitis

Cultures usually are not required in patients with mild conjunctivitis. But in patients who have severe inflammation (e.g., hyperacute purulent conjunctivitis), chronic or recurrent conjunctivitis and who do not respond to treatment; cytology and specimens for cultures are obtained by scraping the conjunctiva. This helps to diagnose allergic, chlamydial, other infectious conjunctivitis and certain atypical forms of conjunctivitis in which the clinical diagnosis is not immediately apparent.

In **hyperacute bacterial conjunctivitis** which is a sight-threatening, severe infection with abrupt onset and characterized by a copious yellow-green purulent discharge that reaccumulates after being wiped away an immediate ophthalmic work-up and management is needed.

The most frequent causes are *N. gonorrhoeae* and *Neisseria meningitidis*, with *N. gonorrhoeae* being by far the more common. These two infections have similar clinical presentations, and can be distinguished only in the microbiology laboratory.

Gonococcal conjunctival infection usually presents in neonates (ophthalmia neonatorum) and sexually active young adults. Affected infants typically develop bilateral discharge three to five days after birth if delivery was vaginal. In adults, the organism is usually transmitted from the genitalia to the hands and then to the eyes.

If a gonococcal ocular infection is left untreated, rapid and severe corneal involvement is inevitable. The resulting ulceration and, ultimately, perforation lead to profound and sometimes permanent loss of vision. Infected infants may also have other localized gonococcal infections, such as rhinitis or proctitis, or they may have disseminated gonococcal infection, such as arthritis, meningitis, pneumonia or sepsis.

The diagnostic work-up for a gonococcal ocular infection includes immediate Gram staining of specimens for gram-negative intracellular diplococci, as well as special cultures for *Neisseria* species. All patients should be treated with systemic antibiotics supplemented by topical ocular antibiotics and saline irrigation.

Over 30 percent of patients with gonococcal conjunctivitis have concurrent chlamydial venereal disease. For this reason, it is advisable to treat patients with supplemental oral antibiotics that are effective against *Chlamydia* species.

Acute bacterial conjunctivitis typically presents with burning, irritation, tearing and, usually, a mucopurulent discharge.

Patients with this condition often report that their eyelids are matted together on awakening in the morning. Conjunctival swelling and mild eyelid edema may be noted. The symptoms of acute bacterial conjunctivitis are less severe, less rapid in onset, and progress at a slower rate than hyperacute conjunctivitis.

The three most common pathogens in bacterial conjunctivitis are *Streptococcus pneumoniae*, *Haemophilus influenzae* and *Staphylococcus aureus*. Infections with *S. pneumoniae* and *H. influenzae* are more common in children, while *S. aureus* most frequently affects adults.

Acute bacterial conjunctivitis is usually self-limited and does not cause any serious harm; but there are several reasons for which treatment should be given. These include decreasing patient morbidity by shortening the course of the disease, reducing person-to-person spread, lowering the risk of sight-threatening complications such as corneal ulceration, and eliminating the risk of more widespread extra ocular disease.

Cultures need be obtained in young children and debilitated persons and empiric treatment with a topical medication is a safe and cost-effective approach in most patients with clinically mild acute bacterial conjunctivitis.

Chronic bacterial conjunctivitis is mostly caused by *Staphylococcus* species. This type of conjunctivitis often develops in association with blepharitis, which is often unrecognized. Some cases of chronic bacterial conjunctivitis are also associated with facial seborrhea.

The symptoms of chronic bacterial conjunctivitis vary and can include itching, burning, a foreign-body sensation and morning eyelash crusting. Signs of this conjunctival condition include flaky debris, erythema and warmth along the lid margins, as well as eyelash loss and bulbar conjunctival injection. Some patients with chronic bacterial conjunctivitis also have recurrent styes and chalazia of the lid margin.

Meibomian is the sebaceous glands that line the posterior lid margin behind the eyelashes. They secrete an important oily component of the tear film. When inflamed, the meibomian glands malfunction, producing chronic inflammation of the eyelid margins and the

conjunctiva, as well as irritating dry-eye symptoms. This condition is referred to as meibomianitis.

Blepharoconjunctivitis and meibomianitis are common in patients with acne rosacea.

The work-up of patients with chronic conjunctivitis and blepharoconjunctivitis involves culturing the conjunctiva and the eyelid margins to identify the predominant bacterial pathogen. Treatment includes the establishment of good eyelid hygiene using warm compresses and eyelid margin scrubs and the application of appropriate topical antimicrobials

Chlamydia trachomatis ocular infection occurs in two distinct clinical forms: - trachoma (associated with serotypes A through C) and inclusion conjunctivitis (associated with serotypes D through K).

Trachoma, a chronic keratoconjunctivitis, is the most common cause of ocular morbidity and preventable blindness throughout the world. It is a public health concern in the rural areas of developing countries. Patients who have emigrated from regions in which trachoma is endemic frequently present to with cicatricial ocular and eyelid changes secondary to previous recurrent infections.

Inclusion conjunctivitis is primarily a sexually transmitted disease that occurs in both adults (adult inclusion conjunctivitis) and newborns (ophthalmia neonatorum) exposed during vaginal delivery to *C. trachomatis* from the mother's infected cervix.

Neonatal inclusion conjunctivitis usually responds to topical antibiotics. However, this condition can be associated with otitis media, and respiratory and gastrointestinal tract infections. Adult inclusion conjunctivitis typically presents in young, sexually active persons between 18 and 30 years of age. Transmission most often occurs by self inoculation from infected genital secretions. The usual presentation is subacute or chronic infection characterized by unilateral or bilateral redness, mucopurulent discharge, a foreign-body sensation and preauricular adenopathy.

Laboratory tests are indicated in neonates and adults with suspected inclusion conjunctivitis. Most affected adults have concurrent, possibly asymptomatic chlamydial urethritis or cervicitis. There is also coinfection with pathogens that cause other sexually transmitted diseases like syphilis and gonorrhea. Therefore, once a diagnosis has been established, a genital work-up of the patient and his or her sexual contacts is indicated before antibiotic treatment is initiated.

Adenovirus is by far the most common cause of viral conjunctivitis. **Viral conjunctivitis** often occurs in community epidemics, with the virus transmitted in schools, workplaces and physicians offices. The usual modes of transmission are contaminated fingers, medical instruments and swimming pool water. Proper hand and instrument washing following patient contact can help to reduce the spread of this highly contagious infection.

Patients with viral conjunctivitis typically present with an acutely red eye, watery discharge, conjunctival swelling, a tender preauricular node, and, in some cases, photophobia and a foreign-body sensation. Occasionally, patients also have subconjunctival hemorrhage. Both eyes may be affected simultaneously, or the second eye may become involved a few days after the first eye. Some patients have an associated upper respiratory tract infection.

Since the ocular infection is contagious for at least seven days, patients should be instructed to avoid direct contact with other persons for at least one week after the onset of symptoms. Treatment is supportive. Cold compresses and topical vasoconstrictors may provide symptomatic relief. Topical antibiotics are rarely necessary, because secondary bacterial infection is uncommon.

Differential diagnosis of conjunctivitis	
Type of Conjunctivitis	Clinical features
Allergic	
Seasonal allergic	Bilateral. Conjunctival injection, chemosis, watery discharge, mild mucus discharge.
Vernal	Bilateral. Giant papillary hypertrophy of superior tarsal conjunctiva, bulbar conjunctival injection, conjunctival scarring, watery and mucoid discharge, limbal Trantas dots, limbal "papillae," corneal epithelial erosions, corneal neovascularization and scarring, corneal vernal plaque/shield ulcer.
Atopic	Bilateral. Eczematoid blepharitis; eyelid thickening, scarring; lash loss; papillary hypertrophy of superior and inferior tarsal conjunctiva; conjunctival scarring; watery or mucoid discharge; boggy edema; corneal neovascularization, ulcers, and scarring; punctate epithelial keratitis; keratoconus; subcapsular cataract.
Viral	
Adenoviral	Abrupt onset. Unilateral or bilateral. Varies in severity. Bulbar conjunctival injection, watery discharge, follicular reaction of inferior tarsal conjunctiva, chemosis.
	Distinctive signs: preauricular lymphadenopathy, petechial and subconjunctival hemorrhage, corneal epithelial defect, multifocal epithelial punctate keratitis evolving to anterior stromal keratitis, membrane/pseudomembrane formation, eyelid ecchymosis.
Herpes simplex virus	Unilateral. Bulbar conjunctival injection, watery discharge, mild follicular reaction of conjunctiva. May have palpable preauricular node.
	Distinctive signs: vesicular rash or ulceration of eyelids, pleomorphic or dendritic epithelial keratitis of cornea or conjunctiva.
Molluscum contagiosum	Typically unilateral but can be bilateral. Mild to severe follicular reaction, punctate epithelial keratitis. May have corneal pannus, especially if longstanding.
	Distinctive signs: Single or multiple shiny, dome-shaped umbilicated lesion(s) of the eyelid skin or margin.
Bacterial	
Nongonococcal	Unilateral. Bulbar conjunctival injection, purulent or mucopurulent discharge.
Gonococcal	Unilateral or bilateral. Marked eyelid edema, marked bulbar conjunctival injection, marked purulent discharge, preauricular lymphadenopathy.
	Important sign to detect: corneal infiltrate.

Differential diagnosis of conjunctivitis	
Type of Conjunctivitis	Clinical features
Chlamydial	Unilateral or bilateral.
Neonate/Infant	Eyelid edema, bulbar conjunctival injection, discharge may be purulent or mucopurulent, no follicles.
Adult	Bulbar conjunctival injection, follicular reaction of tarsal conjunctiva, mucoid discharge, corneal pannus, punctate epithelial keratitis, preauricular lymphadenopathy.
	Distinctive sign: bulbar conjunctival follicles.

Table 1.

Herpes simplex virus keratoconjunctivitis closely resemble the presentation of ocular adenovirus infection. In such patients, topical corticosteroid therapy can lead to severe ocular complications as a result of uncontrolled virus proliferation. Therefore, topical corticosteroids should not be used in the management of infectious conjunctivitis unless under the directive of a physician. Viral conjunctivitis is generally benign and self-limiting. Treatment with corticosteroids can prolong the course of the disease and also place the patient at risk for other steroid-induced ocular complications, such as glaucoma and cataracts.

Ocular infections due to herpes simplex and herpes zoster are becoming more prevalent as the incidence of human immunodeficiency virus infection continues to increase. Ocular herpes simplex and herpes zoster are managed with topical and/or systemic antiviral agents.

Conjunctivitis caused by an allergic reaction clears up once the allergen is removed. However, allergic conjunctivitis will likely recur if the individual again comes into contact with the particular allergen.

Ocular allergy encompasses a spectrum of distinct clinical conditions characterized by itching. The common of ones are seasonal allergic rhinoconjunctivitis, also called hay fever rhinoconjunctivitis and vernal in which a small, white, calcareouslike cellular infiltrates occurring on the edge of the conjunctiva (Horners trantas dot).

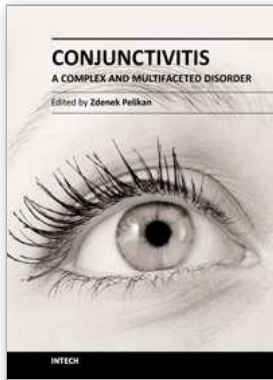
Seasonal allergic rhinoconjunctivitis is an IgE-mediated hypersensitivity reaction precipitated by small airborne allergens. The condition is usually, seasonal. Patients typically experience intermittent itching, tearing, redness and mild eyelid swelling. The personal or family history is often positive for other atopic conditions, such as allergic rhinitis, asthma or eczema.

Treatment measures for seasonal allergic rhinoconjunctivitis include allergen avoidance, cold compresses, vasoconstrictors, antihistamine drops, topical nonsteroidal anti-inflammatory agents and mast-cell stabilizers. Immunotherapy is also beneficial in some patients with allergic conjunctivitis.

6. References

American Academy of Ophthalmology Corneal/External Disease Panel. Preferred Practice Pattern: Conjunctivitis. San Francisco, Ca: AAO; 2003.

- Baum J, Barza M. The evolution of antibiotic therapy for bacterial conjunctivitis and keratitis: 1970-2000. *Cornea*. 2000;19:659-672.
- Block SL, Hedrick J, Tyler R, et al. Increasing bacterial resistance in pediatric acute conjunctivitis (1997-1998). *Antimicrob Agents Chemother*. 2000;44:1650-1654.
- Borel JF, Baumann G, Chapman I. In vivo Pharmacological Effects of Cyclosporin and Some Analogues. *Pharmacol* 1996;35:115-246.
- Greenberg MF, Pollard ZF. The red eye in childhood. *Pediatr Clin North Am*. 2003;50:105-124.
- Kanski JJ. Disorders of the conjunctiva. *Clinical ophthalmology: A systematic approach*. 3rd edition Butterworth-Heinemann. Oxford 1998; pp71-74
- Langley JM. Adenoviruses. *Pediatr Rev*. 2005;26:238-242.
- Rietveld RP, ter Riet G, Bindels JE. Predicting bacterial cause in infectious conjunctivitis: cohort study on informativeness of combinations of signs and symptoms. *Br Med J*. 2004;329:206-208.
- Rose PW, Harnden A, Brueggemann AB, et al. Chloramphenicol treatment for acute infective conjunctivitis in children in primary care: a randomized double-blind placebo-controlled trial. *Lancet*. 2005;8:37-43.
- Stem ME, Beuerman RW, Fox RI. The pathology of dry eye: The interaction between the ocular surface and lacrimal glands. *Cornea*. 1998;17:584-589.
- Wald ER. Periorbital and orbital infections. *Pediatr Rev*. 2004;25:312-319.
- Warwick, Roger; Peter L. Williams "Angiology (Chapter 6)". *Gray's anatomy*. illustrated by Richard E. M. Moore (Thirty-fifth ed.). London: Longman.1973; pp. 588-785.



Conjunctivitis - A Complex and Multifaceted Disorder

Edited by Prof. Zdenek Pelikan

ISBN 978-953-307-750-5

Hard cover, 232 pages

Publisher InTech

Published online 23, November, 2011

Published in print edition November, 2011

This book presents a number of interesting and useful aspects and facets concerning the clinical features, properties and therapeutical management of this condition. Dr. H. Mejía-López et al. present an interesting survey of the world-wide epidemiologic aspects of infectious conjunctivitis. Dr. U. Ubani evaluates conjunctival symptoms/signs participating in the clinical features of this disorder. Dr. A. Robles-Contreras et al. discuss immunologic aspects underlying possibly the conjunctivitis. Dr. Z. Pelikan presents the cytologic and concentration changes of some mediators and cytokines in the tears accompanying the secondary conjunctival response induced by the nasal challenge with allergen. Dr. S. Sahoo et al. summarize the treatment and pharmacologic control of particular clinical forms of conjunctivitis in general practice. Dr. S. Leonardi et al. explain the basic pharmacologic effects of leukotriene antagonists and their use for the treatment of allergic conjunctivitis. Dr. J.A. Capriotti et al. evaluate the therapeutical effects of various anti-adenoviral agents on the acute conjunctivitis caused by adenovirus. Dr. V. Vanzini-Zago et al. assess the prophylactic use and efficacy of "povidone-iodium solution", prior the ocular surgery. Dr. F. Abazi et al. present the clinical features, diagnostic and therapeutical aspects of "neonatal conjunctivitis". Dr. I.A. Chaudhry et al. review the special sub-form of conjunctivitis, being a part of the "Trachoma". Dr. B. Kwiatkowska and Dr. M. Maślińska describe the clinical, pathophysiologic and immunologic features of conjunctivitis. Dr. S. Naem reviews the conjunctivitis form caused by *Thelazia* nematodes, occurring principally in animals.

How to reference

In order to correctly reference this scholarly work, feel free to copy and paste the following:

Udo Ubani (2011). Clinical Features of Infectious Conjunctivitis, *Conjunctivitis - A Complex and Multifaceted Disorder*, Prof. Zdenek Pelikan (Ed.), ISBN: 978-953-307-750-5, InTech, Available from: <http://www.intechopen.com/books/conjunctivitis-a-complex-and-multifaceted-disorder/clinical-features-of-infectious-conjunctivitis>

INTECH
open science | open minds

InTech Europe

University Campus STeP Ri
Slavka Krautzeka 83/A
51000 Rijeka, Croatia
Phone: +385 (51) 770 447

InTech China

Unit 405, Office Block, Hotel Equatorial Shanghai
No.65, Yan An Road (West), Shanghai, 200040, China
中国上海市延安西路65号上海国际贵都大饭店办公楼405单元
Phone: +86-21-62489820

Fax: +385 (51) 686 166
www.intechopen.com

Fax: +86-21-62489821

© 2011 The Author(s). Licensee IntechOpen. This is an open access article distributed under the terms of the [Creative Commons Attribution 3.0 License](#), which permits unrestricted use, distribution, and reproduction in any medium, provided the original work is properly cited.