

New Insights into the Diagnosis and Management of Pregnancy-Related Diabetes Insipidus

Carmen Emanuela Georgescu

*Department of Endocrinology,
"Iuliu Hațieganu" University of Medicine and Pharmacy Cluj-Napoca
Romania*

1. Introduction

Diabetes insipidus in pregnancy (*diabetes insipidus gravidarum*, gestational diabetes insipidus or pregnancy-related diabetes insipidus) is considered to be a rare disease complicating up to 1 in 25000-30000 pregnancies; however, emerging evidence suggests that often the disease is under-diagnosed (Aleksandrov et al., 2010). As stated by the Italian E. Momigliano, in 1929, in his first monograph on 31 cases of pregnancy-related diabetes insipidus (Momigliano, 1929), the disease may occur in an apparently healthy woman, during any stage of pregnancy, usually in the latter half, or may aggravate during pregnancy when previously diagnosed. As a paradox, the disorder may disappear days to weeks after delivery, or may alleviate, or remain unaltered (Bleakley, 1938). Moreover, aggravated recurrence of the disorder in successive pregnancies is recognized (Blotner & Kunkel, 1942). Interest towards pregnancy-related diabetes insipidus revived about 20-30 years ago, once it became apparent that this clinical condition is closely associated with liver disease, HELLP syndrome and the wide spectrum of preeclampsia, all with potentially serious consequences on the maternal course of gestation and fetal health and development.

The aim of the present book chapter is to review the body water homeostasis during pregnancy as well as to insist on clinical conditions associated with the occurrence of diabetes insipidus in pregnancy and the early postpartum period. Not only true gestational diabetes insipidus will be addressed but, notably, maternal hypothalamic-pituitary diseases associated with diabetes insipidus presenting high incidence during pregnancy and the postpartum period will be detailed. It is the author's hope that at the end of the chapter, the reader will find answers to hot questions on the intimate mechanisms facilitating gestational diabetes insipidus, the need to screen or not for alterations in water metabolism in pregnant women at risk, the challenges in differential diagnosis of arginin-vasopressin (AVP) disturbances in a pregnant women and the associated clinical conditions including preeclampsia, acute fatty liver and HELLP (*Hemolysis-Elevated Liver enzymes-Low Platelets*) syndrome.

In addition, etiological considerations on AVP deficiency or defective hormone action in the fetus and neonate will be made.

2. General adaptations of the endocrine system and the maternal hypothalamic-pituitary axis to pregnancy

The fetal-placental unit develops as a unique endocrine organ in pregnancy to account for various endocrine changes. It synthesizes large amounts of hormones; in turn, these synthesis products are secreted into the fetal and maternal circulation. After 8 weeks of gestation, the placenta is the main source of progesterone, which derives from maternal LDL-cholesterol. Most of placental progesterone enters the maternal circulation and hence maternal progesterone plasma concentrations gradually raise during pregnancy up to 150 ng/ml. Likewise, 17β -estradiol and estrone are produced by the placenta *via* conversion from both maternal and fetal DHEA-S, whereas estriol is formed in the placenta from fetal adrenal DHEA-S as the primary source. In both mother and child, serum human chorionic gonadotropin (hCG) levels increase progressively to reach a peak at 10-14 weeks of pregnancy and thereafter fall until delivery. Undoubtedly, hCG is involved in steroidogenesis and maintenance of the corpus luteum activity during the first weeks of gestation. Unlike hCG, the plasma levels of human placental lactogen hormone (hPL) increase throughout the pregnancy to plateau at term. Human PL is secreted mostly into maternal circulation to induce lipolysis, resulting in increased availability of free fatty acids; it inhibits glucose uptake and gluconeogenesis in the mother, all these metabolic effects predisposing to maternal insulin resistance and hyperinsulinemia. Recently, human placental growth hormone (hPGH) synthesis was certified in pregnant women; it gradually replaces pituitary GH during pregnancy and is supposed to promote placental and fetal growth (Chellakooty et al., 2002).

In order to adapt to fetal requirements, pregnancy *per se* is associated with considerable changes in the maternal endocrine status, including physiological changes of the osmoregulatory system. Some of the most significant changes occur in the anterior pituitary and thyroid glands to meet the nutritional needs of the fetus. The pituitary gland enlarges during normal gestation due to estrogen- and to a lesser extent progesterone-induced hyperplasia of lactotroph cells, explaining 10-fold increased maternal prolactin (PRL) levels by the end of pregnancy. By the 6th to 7th week of pregnancy, basal and stimulated GH release from the maternal pituitary is suppressed *via* placental GH-induced IGF-1 synthesis (Chellakooty et al., 2002). By the same time, follicle-stimulating (FSH) and luteinizing hormone (LH) levels start to decrease along to their response to gonadotropin-releasing hormone (GnRH) stimulation.

Iodine requirements are increased in the pregnant woman up to 200-300 μ g daily due to accelerated renal clearance and transplacental passage of inorganic iodine to supply fetal needs. Additional mechanisms consist of increased thyroid hormones demands to compensate for high thyroxin binding globulin (TBG) levels in the mother, stimulation of the thyroid gland by the thyrotropin-like activity of hCG, and activity of the type 3 placental deiodinase (Glinoe, 1997).

The hypothalamic-pituitary-adrenal axis is subjected to significant changes during pregnancy as evidenced by increased maternal cortisol levels, mainly because of an increase in the concentration of corticosteroid binding globulin (CBG), and reduced cortisol clearance. But it is also observed that free cortisol levels are higher during the second trimester and plateau in the third. Several mechanisms are thought to be involved: an altered set point for ACTH, effects of placental ACTH on adrenal hormone production, antiglucocorticoid actions of progesterone, and cortisol resistance (Karaca et al., 2010).

Notably, the placental 11β -hydroxysteroiddehydrogenase efficiently protects the fetus from maternal hypercortisolism by cortisol inactivation. In addition, placental synthesis of CRH is demonstrated. Placental CRH is under the control of cortisol by positive feed-forward and behaves as a determinant of onset of parturition (Kalantaridou et al., 2003).

Both estrogen and progesterone activate synthesis of renin and, subsequently, production of angiotensin II and aldosterone, respectively. Nevertheless, the maternal vasculature becomes refractory to the pressor effects of angiotensin II, a phenomenon essential to blood volume expansion during pregnancy. Moreover, the physiological action of aldosterone is counteracted by progesterone, a competitive inhibitor of aldosterone in the distal tubule.

3. Water balance, arginin-vasopressin metabolism, aquaporin-2 expression and vasopressinase activity in pregnancy

3.1 Hemodynamic changes and water metabolism in normal pregnancy

Pregnancy is a physiological condition associated with water retention which is especially prominent in the last trimester. Studies of body fluid volume regulation in normal human pregnancy pointed out towards water retention leading subsequently to increased total blood volume and decreased plasma osmolality. In both humans and rats, a 30–50% increase in extracellular fluid, plasma and blood volume was reported (Schrier & Briner, 1991). At 6 weeks of pregnancy, an early decrease in systemic and renal vascular resistance with under-filling of the arterial system is documented. As compensatory mechanisms, this will induce sympathetic system stimulation and enhanced cardiac output as well as activation of the renin-angiotensin-aldosterone (RAA) system with associated renal sodium and water retention, leading to the abovementioned expansion of total plasma volume. Evidence of arterial vasodilatation as a primary event of the hyper-dynamic circulatory status in pregnancy is offered by animal studies, such as the rat. Indeed, this appears to be a hormone-triggered mechanism, since up-regulation of endothelial nitric oxide synthase (eNOS) by estradiol has been documented. In line with this finding, increased expression of the eNOS gene in the aorta wall, and elevated plasma nitrite and nitrate levels were detected in pregnant rats. Moreover, neural NOS expression was also found to be increased in the hypothalamus of pregnant rats. In turn, inhibition of the NOS activity has been shown to result in a reverse of renal and systemic vascular changes and normalization of cardiac output (Schrier & Ohara, 2010).

Pregnancy-mediated vasodilatation itself results in non-osmotic AVP release from the hypothalamus. During pregnancy, the osmotic threshold at which pregnant women manifest thirst and release AVP is shifted to a level lower to that of non-pregnant women (Lindheimer & Davison, 1995). Subsequently, a decrease of about 10 mOsm/kg in plasma osmolality ensues starting with the 6th week of pregnancy. Similar changes may be induced in non-pregnant women in whom exogenous hCG is administered (Davison et al., 1988).

Thus, reduction in arterial pressure of more than 10–20% releases AVP from the posterior pituitary by lowering the osmoregulatory system set point, an effect mediated by stimulation of baroreceptors located in the walls of the left atrium and large arteries and leading *via* the glossopharyngeal and vagal nerve to the CNS and then the hypothalamus. Nevertheless, non-osmotic AVP release is not unique during physiological pregnancy but also occurs in adrenal insufficiency, pathological low-output congestive cardiac failure or liver cirrhosis, in the last triggered by splanchnic arterial vasodilatation. Likewise, orally active non-peptide-selective V₂ receptor antagonists administered to patients with cardiac

failure or cirrhosis of the liver increase urinary water excretion while reversing hyponatremia (Schrier et al., 1998). Eventually, the non-osmotic AVP stimulation during pregnancy will promote water retention and increased body fluid volume with plasma hypoosmolality. Figure 1 presents hemodynamic changes and adaptations of water and AVP metabolism during normal pregnancy.

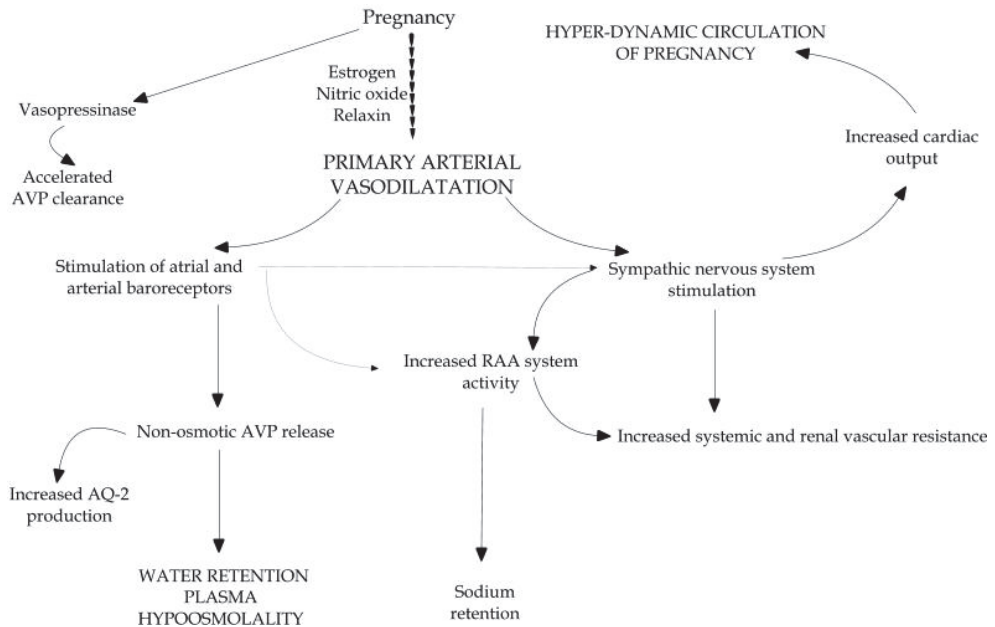


Fig. 1. Hemodynamic changes and adaptations of water and AVP metabolism in normal pregnancy.

3.2 Aquaporin-2 and vasopressinase activity in normal pregnancy

Water molecules transport across membranes is mediated by water channel proteins called aquaporins. Of the several isoforms of aquaporins identified in the kidney and other organs (brain, liver, pancreas, colon, spleen, lung, submandibular gland, testes, leukocytes), aquaporin-2 is abundant in the collecting duct principal cells and is the main target for AVP effects to mediate water transport across the apical membrane of the renal collecting duct. In response to AVP, aquaporin-2 is translocated from cytoplasmic vesicles to apical plasma membranes by shuttle trafficking to increase water permeability of the membrane. After ending AVP stimulation, aquaporin-2 is redistributed and stored into cytoplasmic vesicles.

Excretion of aquaporin-2 in the urine can be quantified and it appears that urinary aquaporin-2 may reflect the levels and/or activity of aquaporin-2 in the apical plasma membrane of the collecting duct. Analysis of urinary aquaporin-2 concentrations shows acute or long-term changes of the protein in a number of clinical conditions associated with water balance disorders. In that sense, low aquaporin-2 expression has been described in forms of nephrogenic diabetes insipidus (e.g. hypokalemia, hypercalcemia, lithium therapy, post-obstructive polyuria) as a mechanism for the inability of the kidney to concentrate

urine in these conditions. In the pregnant rat, up-regulation of aquaporin-2 expression and aquaporin-2 trafficking was described. Administration of the V₂ receptor antagonist in pregnant rats suppressed the increase in aquaporin-2 mRNA and aquaporin-2 protein levels despite normal levels of plasma vasopressin thus suggesting that in pregnancy the up-regulation of aquaporin-2 contributes to water retention in part through a V₂ receptor-mediated effect. In addition, vasopressin-independent factors (such as oxytocin) may be important for this up-regulation.

Likewise, in pregnant women, up-regulation of aquaporin-2 expression and enhanced urinary protein levels have been substantially documented (Froquier et al., 1998); accordingly, this effect on aquaporin-2 is reversed by a V₂ receptor antagonist (Schrier, 2010). In a study of healthy pregnant primiparas, urinary aquaporin-2 excretion, plasma oxytocin and atrial natriuretic peptide but not plasma AVP levels were significantly higher in all three trimesters of pregnancy compared to age-matched non-pregnant women (Buemi, 2001) thus suggesting possible effects of an AVP-independent factor to stimulate renal aquaporin-2 expression during pregnancy.

In healthy adults, AVP circulates in an unbound state and equilibrates within minutes between plasma and the extracellular fluid. Its concentration in these compartments decreases with an average half-time of approximately 20 minutes. Normally, AVP is cleared by the kidney or degraded by the liver; only a small quantity of AVP is taken up and stored by the platelets. During pregnancy, the increased AVP secretion is countered by a 3-fold to 6-fold increase in the metabolic clearance rate of vasopressin which is due to an enzyme, the vasopressinase. Vasopressinase is a plasmatic leucyl-cystinyl-aminopeptidase that degrades both AVP and oxytocin produced by the syncytiotrophoblast of the placenta. Because the placental trophoblastic mass increases about 1000-fold from 6 to 24 weeks of gestation, plasma vasopressinase levels may be 20-fold higher by the third trimester of pregnancy (Soule et al., 1995). Aside to vasopressinase, another enzyme of placental origin, leucine-aminopeptidase (oxytocinase) appears to contribute to AVP degradation during pregnancy. Plasma concentrations of leucine-aminopeptidase gradually increase during pregnancy until delivery, acting as an anti-uterotonic agent by degrading uterotonic peptides. Recently, preeclampsia was associated to low leucine-aminopeptidase levels (Landau et al., 2010). The accelerated AVP degradation resolves about 40 days post-delivery. Despite the increase in the clearance of AVP due to vasopressinase activity, in normal pregnancies, AVP levels remain unchanged thus suggesting a compensatory increase in synthesis and release. Nevertheless, it has to be pointed out that these adaptations are of no particular clinical relevance unless a pathological process is present.

Genetically AVP-deficient homozygous Brattleboro (BB) rats suffer from severe diabetes insipidus. The pregnant BB rat may serve as an animal model of central diabetes insipidus associated to pregnancy. Early studies have shown that the osmotic threshold for AVP during pregnancy is lower in both BB rats and controls and that, in the homozygous animal, chronic vasopressin treatment increased urine osmolality less compared with virgins (Barron et al., 1985). Nevertheless, the model does not apply to true gestational diabetes insipidus since this is induced by enhanced vasopressinase activity and metabolic AVP clearance. Besides AVP, oxytocin and relaxin may play a role in controlling water balance during physiological pregnancy. BB rats were found to significantly concentrate their urine upon severe dehydration, and the plasma level of oxytocin was found to be about 6-fold higher under these circumstances (Edwards & LaRochelle, 1984). An antidiuretic effect of

oxytocin was evidenced in both normal individuals and central diabetes insipidus. Oxytocin has an affinity for the V₂ receptor two orders magnitude lower compared to that of 1-desamino-8-D-arginine (DDAVP). However, in a small study of healthy and diabetic men, oxytocin infusion resulted in decreased urine outflow and free water clearance and increased urine osmolality and aquaporin-2 urinary excretion (Koo et al., 2003) thus suggesting that, in man, the antidiuretic effect of oxytocin may be mediated by regulation of aquaporin-2 levels in the collecting duct.

Relaxin is characterized as a pregnancy-related hormone secreted by the corpus luteum involved as a key player in maternal systemic and renal vasodilatation during pregnancy, as revealed by the vasodilatation obtained in non-pregnant rats in response to intravenous relaxin administration. In human, emerging evidence suggests that the effect of relaxin is mediated by the relaxin/insulin-like family peptide 1 receptor, RFXP1, through a G α -protein coupled to phosphatidylinositol-3kinase/Akt (protein kinase B)-dependent phosphorylation and activation of endothelial nitric oxide synthase to induce nitric oxide synthesis and, hence, important vasodilatation (Conrad, 2011).

4. Etiology and clinical presentation of pregnancy-related diabetes insipidus

4.1 Etiology of polyuria in pregnancy

Table 1 depicts potential causes of polyuria in pregnant women.

Solute Diuresis	Water Diuresis
Diabetes mellitus	Primary polyuria
Salt-losing tubulopathy	Diabetes insipidus
Saline loading	Hyperkalemia
Post-obstructive diuresis	Hypercalcemia
Osmotic iatrogenic diuresis	Primary or secondary tubulopathies
	Sickle cell anemia

Table 1. Causes of polyuria in pregnancy (adapted after Barbey et al., 2010).

Etiologic characterization of diabetes insipidus during pregnancy is complex and, in some cases, difficult to ascertain to one or the other related clinical conditions. Should diabetes predate pregnancy, in either overt or sub-clinical form, any disorder causing AVP-deficiency or AVP-resistance has to be taken into account. On the other hand, pregnancy itself may prone to development of pathological conditions of inadequate AVP synthesis or action, usually in a transient form during pregnancy and postpartum, but, occasionally, persisting thereafter. In synthesis, diabetes insipidus during pregnancy may reveal itself as:

- *Pre-gestational diabetes insipidus*, either central (AVP-deficient) or nephrogenic (AVP-resistant)
- *Latent (sub-clinical) central or nephrogenic diabetes insipidus*, unmasked by both increased vasopressinase activity and diminished renal responsiveness to vasopressin (Iwasaki et al., 1991)
- *True gestational diabetes insipidus*, as
 - *Transient gestational diabetes insipidus* which manifests in pregnancy and usually resolves 3-6 weeks after delivery. Multiple pregnancy acts as a risk factor. Transient gestational diabetes insipidus may be associated with preeclampsia, acute fatty liver disease or HELLP syndrome, or unmask prevalent liver disease such as in

hemochromatosis (Krysiak et al., 2010). As abovementioned, an underlying sub-clinical deficiency in AVP may also be involved in some, if not all, patients.

- *Recurrent diabetes insipidus of pregnancy* due to increased vasopressinase activity has been reported in subsequent pregnancies in several women. Both transient and recurrent gestational diabetes insipidus are vasopressin-resistant but respond well to desmopressin (DDAVP).
- *Transient, vasopressin- and DDAVP-resistant gestational diabetes insipidus* which is a consequence of the physiological increase in the concentration of prostaglandin E₂ in the kidney during gestation leading to inhibition of AVP action at the level of its receptor (Jin-No et al., 1998)
- *Postpartum diabetes insipidus* (i.e. lymphocytic hypophysitis, pituitary apoplexy, histiocytosis X, pituitary tumor, Sheehan's syndrome). Even though these pathological conditions clearly predominate within the first year after birth (postpartum period), concomitance with pregnancy is not excluded in any of them, except for Sheehan's syndrome.

In rare cases, gestational diabetes insipidus may develop as nephrogenic form manifested in pregnancy and complicated by preeclampsia (Goodman et al., 1984; Korbet et al., 1985). Diabetes insipidus may persist postpartum or may be a transient latent form of the disease.

4.2 Clinical features of pregnancy-related diabetes insipidus, and associated conditions

Clinical presentation of pregnancy-related diabetes insipidus is usually acute with symptoms developing in a few days. An abrupt change in the voiding pattern during the last trimester of pregnancy manifesting as hypotonic polyuria, and excessive water intake represent the hallmark of the disease. Fatigue, nausea, weight loss, and reduced skin turgor may be seen. Women in whom diabetes insipidus is associated to a more complex morbid status may present additional symptoms and clinical signs.

4.2.1 Pregnancy-related liver disease

Pregnancy-related liver disease comprises a large spectrum of liver disturbances specifically to pregnancy, with variable outcome potential. While liver dysfunction is transient and usually mild in *hyperemesis gravidarum* and intra-hepatic cholestasis of pregnancy, women with acute fatty liver disease or HELLP syndrome are at high risk to concomitantly develop preeclampsia and a less favorable prognosis. Differential diagnosis between pregnancy-related liver disease and preexistent or simultaneous hepatic disorder unrelated to pregnancy is mandatory and sometimes difficult.

Nevertheless, rarely, liver biopsy is employed as an ultimate differential diagnosis tool. Association of *de novo* diabetes insipidus with liver injury in pregnant women is suggested by polyuria and polydipsia syndrome and epigastric pain, nausea, vomiting, pruritus and jaundice. At least in some patients, acute fatty liver disease can be considered as an atypical form of preeclampsia because 30-40% of women with acute fatty liver also develop preeclampsia. In that sense, onset of diabetes insipidus in patients with acute fatty liver may highly indicate the likelihood of preeclampsia. Hence, early delivery and supportive care may considerably improve the overall prognosis of these individuals. Pathogenesis of diabetes insipidus in pregnant women with acute fatty liver can be easily explained by enhanced vasopressinase activity subsequent to liver dysfunction. Commonly, diabetes

insipidus responds well to DDAVP therapy and spontaneously resolves with delivery or may persist postpartum for another few weeks.

Recently, it has been found that acute fatty liver of pregnancy is associated with a defect of long-chain 3-hydroxyacyl coenzyme A dehydrogenase in the fetus with c1528G>C point mutation as the main cause (Gutiérrez Junquera et al., 2009). Therefore, genetic testing can be taken into consideration in both the mother and the fetus.

Association of advanced hepatocytolysis, hemolysis and thrombocytopenia gives birth to the HELLP syndrome, one component of systemic preeclampsia and eclampsia, often conjoined with diabetes insipidus, hypertension and cerebral edema. HELLP syndrome occurs in 10-20% of pregnancies with severe preeclampsia. The majority of cases (70%) develop in advanced pregnancy, between the 27th and 37th gestational week, and seldom later; the remainder within 48 hours after delivery, usually in women who developed proteinuria, hypertension, edema and excessive weight gain prior to delivery.

Recent studies hypothesized genetic predisposition as a risk factor for HELLP syndrome, mainly under the form of various disturbances in the process of blood coagulation. Therefore, some clinical studies investigated the association between hereditary thrombophilia and HELLP syndrome but results remain controversial (Ganzevoort et al., 2007; Larciprete et al., 2010). Several reports confirmed statistically higher incidence of antithrombin-III deficiency in patients with HELLP syndrome (Larciprete et al., 2010; Dogan et al., 2011). Apparently, women with elevated antiphospholipid antibodies titers are at risk to develop severe preeclampsia and HELLP syndrome (Heilmann et al., 2011).

Onset of HELLP syndrome is within days or weeks with headache, visual symptoms, malaise, nausea and vomiting and fluctuating abdominal pain. Most symptoms exacerbate during night. Para-clinical investigations will exhibit proteinuria, low hemoglobin levels and increased serum lactate dehydrogenase (LDH) concentrations to attest for onset of *microangiopathic hemolytic anemia* (Haram et al., 2009) in these patients. Elevated levels of liver enzymes (ASAT, ALAT and α -glutathione-S-transferase-a1) are documented. Thrombocytopenia is the result of subsequent increased platelet consumption and, thus, platelet turnover. If diabetes insipidus is present, hypernatremia, hemoconcentration and diminished urine/plasma osmolality ratio is expected. Table 2 summarizes the diagnosis criteria of HELLP syndrome according to the two major current definition systems.

	<i>Mississippi Classification Criteria</i>	<i>Tennessee Classification Criteria</i>
HELLP Syndrome	Platelet count $\leq 50 \times 10^9/L$ AST or ALT ≥ 70 IU/L LDH ≥ 600 IU/L	Platelet count $\leq 100 \times 10^9/L$ AST ≥ 70 IU/L LDH ≥ 600 IU/L

Table 2. Current diagnosis criteria for the HELLP syndrome.

Based on the platelet count, the Mississippi system categorizes the disorder into class 1 HELLP (table 2) and class 2 HELLP syndromes (*i.e.* platelet count $\leq 100 \times 10^9/L$ and $>50 \times 10^9/L$, serum liver enzymes ≥ 70 IU/L and serum LDH ≥ 600 IU/L). In addition, class 3 HELLP syndrome is defined according to Mississippi classification as platelet count $\leq 150 \times 10^9/L$ and $>100 \times 10^9/L$, serum liver enzymes ≥ 40 IU/L and serum LDH concentration ≥ 600 IU/L (Martin et al., 1999). Class 3 HELLP syndrome is considered a transitional group.

The clinical significance of HELLP syndrome is based upon severe maternal and fetal/neonatal complications that may occur in affected pregnancies. Biochemical

abnormalities associated with increased risk of maternal complications consist of serum LDH levels >1400 IU/L, serum AST >150 IU/L, serum ALT >100 IU/L and serum uric acid levels >7.8 mg% (Magann & Martin, 1999). In the mother, life-threatening complications are *abruptio placentae*, disseminated intravascular coagulation, cerebral or brain stem hemorrhage, cerebral edema and spontaneous rupture of subcapsular liver hematoma. Purtscher-like retinopathy can result in permanent visual loss (Stewart et al., 2007). Newborns from women with HELLP syndrome delivered before the 32th to 34th gestational week are at risk for intrauterine growth restriction, cardiovascular (*i.e.* persisting *ductus arteriosus*) and respiratory complications, and perinatal death due to prematurity, *abruptio placentae* or cerebral hemorrhage (*i.e.* caused by neonatal thrombocytopenia). Notably, complications in the newborn appear to be rather related to prematurity than to HELLP syndrome itself.

In women developing HELLP syndrome after the 34th week of pregnancy, vaginal delivery is the method of choice. Before the 34th gestational week, a single course of 12 mg betamethasone twice, 24 hours apart, is recommended to induce lung maturation. Repeated glucocorticoid courses may be more effective; however, they may lead to fetal growth restriction and prolonged adrenal suppression. High-dose dexamethasone treatment has been proposed as an alternative to improve maternal outcome, especially before 27th week of pregnancy, but there is no evidence of benefits compared to immediate delivery and thus should be individually addressed (Fonseca et al., 2005; Haram et al., 2009).

4.2.2 Lymphocytic (autoimmune) hypophysitis

Lymphocytic hypophysitis is a rare inflammatory disorder of the pituitary gland thought to have an autoimmune basis with predilection for women during the postpartum period and the late stage of pregnancy. Although lymphocytic hypophysitis should be always considered in the differential diagnosis of pituitary masses and/or pituitary insufficiency in women who are pregnant or in the early postpartum period, a definitive diagnosis of the disease requires pituitary biopsy. Nevertheless, a presumptive diagnosis of lymphocytic (autoimmune) hypophysitis is possible based on a history of gestational or postpartum pituitary insufficiency, rapid development of hypopituitarism in up to 75-80% of cases with early loss of adrenocorticotrophic hormone (ACTH) and TSH, and imagistic appearance of the pituitary gland and stalk including variable enlargement of the hypophysis with homogenous appearance and intact sella floor. Cystic appearance of the pituitary gland on magnetic resonance imaging (MRI), although rare, is not excluded in patients with autoimmune hypophysitis (Flanagan et al., 2002). In hypophysitis, the pituitary stalk is thickened but not displaced, an aspect that is opposed to the MRI of the displaced hypophyseal stalk that is described in macroadenomas with supra-sellar enlargement. A strong, homogenous enhancement of the anterior pituitary after gadolinium infusion, even though suggests inflammation, is not specific enough to differentiate between hypophysitis on one hand and pituitary adenoma on the other hand.

Autoimmune inflammation of the pituitary gland presents commonly as lymphocytic adenohypophysitis. The clinical presentation of autoimmune adenohypophysitis includes headache, pituitary insufficiency and central diabetes insipidus. Visual disturbances comprise visual field defects due to compression of the optic chiasm and diplopia due to compression of III, IV and VI cranial nerves by parasellar expansion of the autoimmune inflammatory process towards the cavernous sinus. Diabetes insipidus may be a component of pure lymphocytic adenohypophysitis because of inhibition of the axonal transport of

AVP by swelling of the *pars tuberalis* of the adenohypophysis which covers the infundibulum anterolaterally. From the clinical viewpoint, diabetes insipidus can be masked by coexistence of glucocorticoid deficiency in lymphocytic adenohypophysitis which is associated with stimulation of ADH release and aquaporin-2 synthesis (Caturegli et al., 2005) and is often revealed by glucocorticoid hormones replacement therapy. Long-term magnetic observation of few cases with a medical history of lymphocytic hypophysitis during pregnancy suggested that this clinical condition may evolve with pituitary atrophy and empty sella. Hence, it is believed that at least some cases with postpartum pituitary insufficiency (even Sheehan's syndrome) and empty sella may actually include lymphocytic adenohypophysitis (Ishihara et al., 1996).

Rarely, autoimmune inflammation of the pituitary gland may be limited to the posterior pituitary lobe and infundibular stem and termed lymphocytic infundibulo-hypophysitis. Lymphocytic infundibulo-hypophysitis has been reported as a cause of central diabetes insipidus in the postpartum period (VanHavenbergh et al., 1996). On MRI, infundibulo-hypophysitis is suspected on enlargement of the posterior pituitary lobe and thickening of the pituitary stalk greater than 3 mm at the level of the median eminence of the hypothalamus (Caturegli et al., 2005). Although loss of physiological T1 hyper-intensity in the posterior pituitary is suggestive, specificity of this aspect is low.

4.2.3 Pituitary apoplexy

Hemorrhagic or ischemic pituitary apoplexy is a rare neuro-endocrine emergency with a potentially severe outcome resulting even in hyponatremic coma and death. The main clinical symptoms are thunderclap headache, nausea and vomiting, fever, loss of consciousness, ophthalmoplegia, visual field impairment, monocular blindness and neck stiffness (meningeal irritation). The diagnosis is most challenging in apparently healthy subjects (Georgescu et al., 2009) in whom neurological complications such as stroke, meningitis, diffuse subarachnoid hemorrhage or optic tract hemorrhage may develop. Occasionally, pituitary apoplexy may present as isolated unilateral or bilateral IIIrd or VIth nerve palsy.

In most cases, pituitary apoplexy complicates the evolution of previously diagnosed adenomas. In a retrospective review of 28 cases with pituitary adenoma, 14% of patients were incidentally diagnosed after pituitary apoplexy (Dekkers et al., 2007) and in a follow-up of 42 patients with incidentally found non-functioning pituitary adenoma, apoplexy complicated the natural course of the disease in 9.5% of cases. On the other hand, in a large series of 45 cases of subjects with pituitary apoplexy, only 18% were known to have pituitary adenoma at presentation (Sibal et al., 2004). Likewise, in a larger series of 62 patients with this clinical condition, 81% of subjects had no previous medical history suggesting pituitary tumor (Semple et al., 2005).

Pituitary apoplexy in pregnancy and postpartum is even more rarely encountered with less than 50 cases reported in the medical literature. Occasionally, spontaneous abortion develops during the follow-up (Krull et al., 2010). To confirm diagnosis, pituitary hormones evaluation and MRI assessment of the hypothalamus-pituitary region is mandatory. MRI is revealing a sellar mass with fluid level or central component suggesting hemorrhage. Extrasellar expansion is common resulting in pituitary stalk displacement and optic chiasm compression.

Pituitary insufficiency of various degrees follows the onset of pituitary apoplexy. Note worthily, the association of pituitary apoplexy with permanent or transient diabetes

insipidus is rather rare, irrespective of gender and physiological status; in two larger studies, of 62 and 40 patients, respectively, only 8% of subjects developed AVP deficiency (Semple et al., 2005; Lubina et al., 2005). Artery surgery, other major surgery, pregnancy, gamma knife irradiation, anticoagulant therapy, and coagulopathy secondary to liver failure were identified as precipitating factors for pituitary apoplexy. Specific information on the prevalence of diabetes insipidus in women developing pituitary apoplexy in pregnancy and postpartum is not yet available.

With except of cases developing compression of the optic chiasm or severe neurological status, pituitary apoplexy in pregnancy should be treated preferably conservatively with high-dose glucocorticoid therapy and hormone replacement therapy including AVP- or DDAVP medication if diabetes insipidus is diagnosed. Monitoring by MRI is recommended. In advanced gestation delivery is preferred.

4.2.4 Sheehan's syndrome

Sheehan's syndrome describes postpartum pituitary necrosis; however, the exact pathogenic mechanism of the syndrome is not well understood because such endocrine abnormalities are not obvious in most women with severe hemorrhage in pregnancy and delivery. Although not a typical feature of Sheehan's syndrome, early postpartum diabetes insipidus may accompany postpartum pituitary necrosis in about 5% of cases and even more when systematically looked for. In a study on posterior pituitary function in 26 women with Sheehan's syndrome by both water deprivation and 5% hypertonic saline infusion test, partial diabetes insipidus was diagnosed in 29.6% of patients (Atmaca et al., 2007). Likewise, plasma AVP measurements after the 5% hypertonic saline infusion test in women with postpartum hypopituitarism but absent polyuria revealed, in 10 of 12 patients, the presence of various degrees of subnormal AVP responses to the increase in plasma osmolality (Iwasaki et al., 1989). Higher osmotic threshold for thirst perception was described in Sheehan's syndrome patients in comparison to controls; thus, besides AVP insufficiency, ischemic damage of the thirst center may contribute to increased osmotic threshold for the onset of thirst in Sheehan's syndrome (Atmaca et al., 2007).

Occasionally, in women with pre-pregnancy diagnosis of Sheehan's syndrome, latent central diabetes insipidus may become manifest during pregnancy (Briet et al., 1998) to be corrected with vasopressin therapy. Water metabolism disturbances in patients with Sheehan's syndrome depend on several factors such as the degree of pituitary damage, the time of onset since the pituitary injury, association of co-morbidities and/or concomitant medication. Emerging evidence shows that Sheehan's syndrome with or without diabetes insipidus is increasingly reported in association with antiphospholipid syndrome (Mehdi et al., 2011). In addition, in advanced pregnancy, contribution of enhanced vasopressinase activity to disturbed water balance should be considered and is suggested by incomplete response of polyuria and polydipsia to vasopressin but adequate control by desmopressin. Exceptionally, postpartum Sheehan's syndrome may evolve to acute renal failure.

5. Impact of pregnancy-related diabetes insipidus on maternal and fetal health

Pre-pregnancy confirmed, therapeutically controlled diabetes insipidus has normally no significant impact on pregnancy outcome and health status of the fetus. On the contrary, gestational diabetes insipidus is potentially related to a series of maternal-fetal

complications, of maximum severity in cases associated with HELLP syndrome and pre-eclampsia. Maternal complications may include severe hypernatremia, eclampsia, hepatic insufficiency and disseminated intravascular coagulation. In several cases, premature delivery of the fetus avoids fetal hypoxia and intrauterine fetal death (Wiser et al., 2008).

Generally, transient diabetes insipidus recovers about 4-6 weeks after delivery. Rarely, permanent central diabetes insipidus with or without definitive pituitary insufficiency of various degrees may occur in the mother, depending on the underlying clinical condition of pregnancy-related diabetes.

Gestational diabetes insipidus may associate *in utero* fetal complications such as oligohydramnios or polyhydramnios. Rapid-onset polyhydramnios and fetal polyuria were recently described by Weinberg (Weinberg et al., 2010) in a singleton pregnancy developing transient third trimester gestational diabetes insipidus in the mother. Nevertheless, the mechanism of fetal polyuria remains elusive in this case. The authors' speculated on either maternal over-hydration or an effect on fetal vasopressin of the increased maternal vasopressinase, for which transplacental passage has been described.

6. Fetal disorders/conditions associated with disturbances in ADH production or activity and their repercussions on the pregnancy course

Both AVP and oxytocin are synthesized by the hypothalamic supraoptic and paraventricular nuclei during the first weeks of fetal life. AVP is found in high concentrations in fetal plasma and neonate umbilical cord blood and thought to be involved in blood pressure regulation. The main stimulus of AVP release in the fetus is hypoxia but also hypotension, acidosis and hypercarbia may play a role. Aquaporin-2 metabolism in the fetus and neonate is not fully understood. Researches in both preterm and at term infants suggested that in early postnatal life aquaporin-2 urinary levels cannot serve as a marker of AVP renal action and renal capacity to concentrate urine (Nyul et al., 2002; Zelenina et al., 2006) although opposing results were reported (Iacobelli et al., 2006). Nevertheless, in the same studies urinary aquaporin-2 concentrations correlated adequately with the overall maturity of tubular renal function and decreased in conditions of impaired kidney activity. In the fetus and newborn, diabetes insipidus is a rare disorder with a complex pathogenesis (table 3).

Most cases of central diabetes insipidus are secondary to a known etiology while defective AVP action is often related to a pathological condition and/or specific medication in the pregnant mother.

Clinically, diabetes insipidus may be suspected in newborns presenting during the first days of life with polyuria and weight loss, and is confirmed by hypernatremia, high plasmatic osmolality and low urine osmolality and a good response to desmopressin. Nevertheless, diagnosis during the neonatal period may be difficult because of frequent lack of polyuria due to the decreased renal glomerular filtration that exists during the neonatal period. The increase in the glomerular filtration rate thereafter unmasks the later polyuria. Moreover, the low osmolarity of the breast milk may mask specific features of diabetes insipidus in neonates that are exclusively breastfed. The disorder may be suspected in infants with unexplained fever, irritability, lack of weight gain, hypernatremia. Often, the child can be calmed with water but not with milk. Rapid management is required to prevent potentially lethal complications such as intracranial bleeding and renal vein thrombosis.

Central diabetes insipidus	Nephrogenic diabetes insipidus
Perinatal asphyxia	Medication (in the mother) (e.g. lithium, angiotensin-converting enzyme inhibitors, angiotensin type 1 receptor blockers)
Intracranial hemorrhage (e.g. vitamin K deficiency)	Familial or sporadic congenital nephrogenic diabetes insipidus
Infection (e.g. congenital toxoplasmosis, congenital cytomegalovirus infection, meningitis: streptococcal, meningococcal, listeria meningitis, brain abscess)	
Congenital defects in the brain/pituitary morphogenesis (e.g. pituitary agenesis/hypogenesis, septo-optic dysplasia, holoprosencephaly, congenital nasal pyriform aperture stenosis, cleft lip/palate, meningomyelocele, hydrocephalus, facial diplegia (Mobius syndrome), Delleman syndrome, Kabuki syndrome etc.	
Cranio-cerebral trauma	
Intracranial tumors (e.g. teratoma, craniopharyngioma)	
Cysts	
Familial central diabetes insipidus	
Wolfram syndrome*	

Table 3. Etiology and pathogenesis of diabetes insipidus in the fetus and neonate.*onset of diabetes insipidus is confirmed after the age of 3 month.

6.1 Central diabetes insipidus in the fetus and neonate

Congenital isolated central diabetes insipidus may be of idiopathic nature (Bianchi, 2010) or due to various underlying pathological states (Table 3). Idiopathic central diabetes insipidus has been particularly reported in preterm very low birth weight infants (Stapleton & Di Geronimo, 2000). Central diabetes insipidus appears as a component of congenital anomalies, in particular midline developmental defects or genetic syndromes, of which the most important are represented by:

- midline craniofacial malformations (holoprosencephaly)
- septo-optic dysplasia (De Morsier's syndrome) is a complex disorder that consists in incomplete development of midline cranial structures such as hypoplasia/aplasia of the optic nerves, hypoplasia/absence of the *septum pellucidum* and/or pituitary hypoplasia/aplasia, with isolated or combined pituitary hormone deficiencies including AVP deficiency and in particular growth hormone deficiency. *HESX1* gene mutations have been associated with septo-optic dysplasia.
- Delleman syndrome associating somatic changes such as macrocephaly, micrognathia, anophthalmia, cleft lip and palate, *cutis aplasia*, diabetes insipidus and panhypopituitarism (Leichtman et al., 1994)
- Kabuki syndrome, a multiple malformation disorder caused by mutations in the *MLL2* gene (Ng et al., 2010), a histone methyltransferase ubiquitarily expressed among adult

human tissues; affected individuals may present with strabismus, long palpebral fissures, large ears, cardiac and immunological anomalies, dwarfism and mental retardation. Diabetes insipidus may develop.

In fact, any severe defect of brain development can be associated to diabetes insipidus due to alterations in pituitary embryogenesis.

- Pituitary agenesis/hypogenesis with absence of the pituitary stalk
- Wolfram syndrome or DIDMOAD with an autosomal recessive transmission pattern, which combines diabetes insipidus, diabetes mellitus, optic atrophy, deafness, atonia of the bladder, hydronephrosis, neurological and gastrointestinal anomalies, hypogonadotropic hypogonadism and depression. In contrast to diabetes mellitus which develops early, even during neonatal life, diabetes insipidus appears in up to 75% of affected individuals, with a peak incidence at age 15 (range 3 months - 40 years). Desmopressin treatment adequately controls diabetes insipidus. The gene involved in most Wolfram syndrome cases is called *WFS1* and located in the chromosomal region 4p16.1. The *WFS1* protein, also known as wolframin, appears to be involved in cell cycle regulation and apoptosis. Recently, another mutation associated with the *WSF2* locus on chromosome 4 has been identified in patients suffering from Wolfram syndrome (Amr et al., 2010).
- Familial central diabetes insipidus may be transmitted autosomal dominant, autosomal recessive or X-linked with variable penetrability.

Congenital toxoplasmosis may result in central diabetes insipidus. In that case, the serum and cerebrospinal fluid samples of the patient test positive for toxoplasmosis. Alternatively, etiology is suggested by cranial computed tomography revealing obstructive hydrocephalus and cranial disseminated calcifications. Anterior pituitary insufficiency is occasionally cited in neonates with congenital toxoplasmosis with central adrenal insufficiency and central hypothyroidism (Siahanidou et al., 2006). One case of prolonged fever, attributed to hypothalamic dysfunction (hypothalamic fever) has been reported in association to diabetes insipidus in a newborn diagnosed with congenital toxoplasmosis (Siahanidou et al., 2006).

Tumors of the hypothalamus-pituitary region may account for onset of central fetal/neonatal diabetes insipidus. Neonatal craniopharyngioma has been repeatedly reported as a suprasellar tumor with partially cystic appearance in MRI and variable outcome after radical neurosurgery (Müller et al., 2000). Arachnoid cysts with suprasellar localization may manifest with pituitary insufficiency and central diabetes insipidus when the cyst reaches a sufficient size. In Langerhans cell histiocytosis early infiltration of the hypothalamus and pituitary stalk causes central diabetes insipidus. Combined Langerhans cell histiocytosis and DiGeorge Syndrome displaying multisystemic involvement of Letterer-Siwe disease at birth has been reported (Levendoglu et al., 1996). Transiently, central diabetes insipidus in the neonate is described in association with hypotonia, dysmorphism and marked speech delay due to 22q13 deletion syndrome (Barakat et al., 2004).

6.2 Nephrogenic diabetes insipidus in the fetus and neonate

Congenital nephrogenic either sporadic or familial diabetes insipidus is caused in 90% of cases by X-linked transmitted mutations in the AVP receptor 2 gene that encodes for the AVP type 2 receptor. Until now, five types of molecular defects in the protein synthesis or action have been described. The other 10% of cases result from mutations in the aquaporin-2 gene. Autosomal recessive inheritance of the mutation results in proteins that remain

trapped in the endoplasmic reticulum and are rapidly degraded, whereas autosomal dominant inheritance results in synthesis of structurally normal proteins but unable to ensure intracellular transport within the tubular renal cell. In few cases of congenital nephrogenic diabetes insipidus neither the AVP gene nor the aquaporin-2 gene are affected. Note worthily, nephrogenic diabetes insipidus in the fetus may be a result of maternal medication such as lithium, angiotensin-converting enzyme inhibitors or angiotensin type 1 receptor blockers. Lithium is commonly used in the treatment of psychiatric disorders, specifically bipolar depression. Lithium causes polyhydramnios from fetal diabetes insipidus *in utero*. Clinical presentation of infants with *in utero* lithium exposure comprises transient neuro-developmental deficiencies such as hypoglycemia, hyperbilirubinemia, hypotonia, respiratory distress syndrome, cyanosis, lethargy, and weak suck and Moro reflexes in the neonatal period. Additionally, large-for-gestational age and prematurity, Ebstein's anomaly, cardiovascular toxicity and endocrine complications have been reported. Of endocrine disorders, newborns are at risk to develop nephrogenic diabetes insipidus and thyroid dysfunction (Kozma et al., 2005).

Alternatively, other congenital tubulopathies can associate a partial defect in the capacity to concentrate urine and usually present with a low degree of polyuria (e.g. Bartter syndrome, Fanconi syndrome, nephronophtosis, polycystic kidneys, obstructive nephropathy, nephritis, renal insufficiency).

7. Diagnostic challenges in pregnancy-related diabetes insipidus

Whatever etiology of diabetes insipidus, the main feature consists of excretion of high amounts of dilute, flavorless, hypotonic urine. Irrespective of the pathogenesis of the disorder (*i.e.* central, gestational or nephrogenic diabetes insipidus), a primary deficiency in urinary concentration will result in a rise of urine flow that produces a slight (1% to 2%) decrease in body water and a commensurate rise in basal plasma osmolality and sodium. Therefore, high urine output with low urine specific gravity (<1005) and low urine osmolality (50-300 mOsm/kg) in the presence of normal or elevated sodium (148 mmol/l) or plasma osmolality strongly suggests diabetes insipidus. Exclusion of other causes of polyuria such as diabetes mellitus, renal failure, hypokalemia, hypercalcemia and tubular renal acidosis is made by determination of fasting glucose and oral glucose tolerance test, urea, creatinine, creatinine clearance and electrolytes in blood and urine. Adrenal function tests, thyroid tests and basal and dynamic tests of pituitary function should be considered.

The practice of relating plasma to urine osmolality is useful; it can quickly differentiate diabetes insipidus from parenteral fluid excess. The urine osmolality is a measure of the concentration of the urine and is determined by AVP concentration. In a hypernatremic patient, a urine osmolality below that of the plasma suggests diabetes insipidus.

In contrast to women with primary polyuria, women with diabetes insipidus will not concentrate their urine osmolality during the water deprivation test. However, differential diagnosis from primary polydipsia may be difficult in women with partial AVP deficiency since fluid restriction can increase AVP secretion sufficiently to concentrate the urine. Additionally, the water deprivation test performed during pregnancy needs closed observation of the patient and may be problematic because the resulting plasma volume may lead to important dehydration and may increase the risk of utero-placental insufficiency. In this case diagnostic tests may be limited to measurement of urine and plasma osmolality and AVP or DDAVP administration.

Partial or mild forms of diabetes insipidus, however, cannot be clearly differentiated by indirect tests. In these cases, plasma AVP measurement with a high sensitivity assay, before and after water deprivation or osmotic stimulation during infusion of hypertonic 5% saline increases diagnosis accuracy (Zerbe & Robertson, 1981). Using a nomogram, AVP remains low after hypertonic saline infusion in patients with cranial diabetes insipidus while it increases normally in relation to plasma osmolality in patients with primary polyuria. Pregnant women with pre-existing central diabetes insipidus will respond by increased urine osmolality after intranasal delivery of AVP or AVP injection, as will patients developing hypothalamus-pituitary disorders during pregnancy. In contrast, vasopressin resistance is well-described in transient or recurrent gestational diabetes insipidus due to vasopressinase, however, patients will adequately respond to DDAVP. If there is a normal response to AVP or DDAVP that is urine osmolality obtained 30–60 min after injection increases, nephrogenic diabetes insipidus can be ruled out. All pregnant women with diabetes insipidus of unclear etiology should undergo magnetic resonance imaging of the hypothalamus-pituitary region to establish coexistence of disorders that may have affected AVP-producing neurons.

Notably, differential diagnosis of diabetes insipidus in pregnant women without pre-dating disease may be challenging and, occasionally, certainty with regard to the etiopathogeny is obtained after delivery. However, it has to be kept in mind that persistence of polyuria and polydipsia more than 6 weeks postpartum questions the diagnosis of true gestational diabetes insipidus and needs re-evaluation of the case.

8. Therapy of diabetes insipidus in pregnancy and lactation

Once the diagnosis is established, close monitoring of vital signs, fetal status, fluid balance, body weight and renal function are essential. Fluid intake must approximate urine volume and other fluid losses. Many patients require parenteral treatment, which usually consists of 5% glucose and normal saline infusion. Vaginal delivery with regional analgesia or, in the case of cesarean section, spinal anesthesia, are the methods of choice.

Earlier pituitary extracts of AVP contained oxytocin and precipitated uterine contractions and preterm labor. Chlorpropamide can stimulate secretion of AVP and potentiate its effects but it can cause fetal hypoglycemia and neonatal diabetes insipidus.

Because AVP degradation by vasopressinase is initiated by clipping the first amino-acid of the hormone, whereas its analog called DDAVP (1-deamino-8-D-arginine vasopressin, desmopressin acetate) is devoid of the first amino acid of AVP, the treatment of choice in patients with pregnancy-related diabetes insipidus is DDAVP. In contrast to the naturally occurring hormone, arginine-vasopressin, DDAVP exhibits practically no pressor activity and a prolonged antidiuretic activity lasting from 8 to 12 h (Fjellestad-Paulsen et al., 1993). There are several routes of administration of DDAVP. In pregnancy, the intranasal, oral or sublingual routes are preferred (Table 4).

<i>Intranasal</i>		<i>Oral</i>	<i>Sublingual (Melt)</i>
<i>Spray</i>	<i>Drops</i>	<i>Tablets</i>	<i>Tablets</i>
-	5 µg	100 µg	60 µg
10 µg	10 µg	200 µg	120 µg
20 µg	20 µg	400 µg	240 µg

Table 4. Dose comparison of different DDAVP (desmopressin acetate) formulations.

Decreased response to nasal DDAVP may occur during episodes of rhinitis. In these cases or when oral administration is not possible, and in the postoperative period, the parenteral form (4 µg/ml, intravenously, intramuscularly or subcutaneously) is preferred.

Experience with the use of DDAVP during pregnancy is increasing; it is safe for both the mother and the fetus. In fact, DDAVP appears not to cross the placenta within detectable limits (Ray et al., 2004). To be mentioned, however, there is large individual variation in the amplitude and duration of effect. Hence, doses have to be tailored individually for optimal efficacy.

Hyponatremia is reported to occur after first doses of DDAVP in patients who do not restrict oral water intake; therefore, desmopressin carries the potential hazard of dilutional hyponatremia if the patient continues to drink inappropriately despite persistent antidiuresis. Lower extremity edema and signs of water intoxication may develop in cases with excessive dosage.

9. Conclusion

Diabetes insipidus in pregnancy and postpartum is an endocrine disorder with potentially serious consequences on the maternal course of gestation and on fetal development and health when occurring in association with life-threatening clinical conditions such as preeclampsia, HELLP syndrome or pituitary insufficiency. Although described more than one hundred years ago, the disease is not fully understood from the pathophysiological point of view and appears to be under-diagnosed. Basically, most information available in this area of knowledge resulted from isolated case reports or case series reviews, while on the contrary few conclusions were drawn from systematic studies documenting disease prevalence and therapy. To improve knowledge in the diagnosis and multispecialty management of women with pregnancy-related diabetes insipidus and their offspring, further studies are warranted.

10. References

- Aleksandrov, N.; Audibert, F.; Bedard, M.J.; Mahone, M.; Goffinet, F. & Kadoch, I.J. (2010). Gestational diabetes insipidus: a review of an underdiagnosed condition. *J Obstet Gynaecol Can*, Vol.32, No.3, (April, 2011), pp. 225-231, ISSN 1701-2163.
- Momigliano, E. (1929). Diabete insipido e gravidanza. *Ann di Ostet e Ginec*, Vol.51, (1971), pp. 905-979, ISSN 0003-4657.
- Bleakley, J. (1938). A case of diabetes insipidus and twin pregnancy. *Proc R Soc Med*, Vol.31, No.9, (March, 2011), pp. 1062-1064, ISSN 0035-9157.
- Blotner, H. & Kunkel, P. (1942). Diabetes insipidus and pregnancy - report of two cases. *N Engl J Med*, Vol.227, No.8, (April, 2011), pp. 287-292, ISSN 0028-4793.
- Chellakooty, M.; Skibsted, L.; Skouby, S.O.; Andersson, A.M.; Petersen, J.H.; Main, K.M.; Skakkebaek, N.E. & Juul, A. (2002). Longitudinal study of serum placental GH in 455 normal pregnancies: correlation to gestational age, fetal gender, and weight. *J Clin Endocrinol Metab*, Vol.87, No.6, (April, 2011), pp. 2734-2739, ISSN 0021-972X.
- Glinoe, D. (1997). The regulation of thyroid function in pregnancy: pathways of endocrine adaptation from physiology to pathology. *Endocr Rev*, Vol.18, (April, 2011), pp: 404-433, ISSN 0163-769.

- Karaca, Z.; Tanriverdi, F.; Unluhizarci, K. & Kelestimur, F. (2010). Pregnancy and pituitary disorders. *Eur J Endocrinol*, Vol.162, No.3, (May, 2011), pp. 453-475, ISSN 0804-4643.
- Kalantaridou, S.N.; Makriganakakis, A.; Mastorakos, G. & Chrousos, G.P. (2003). Roles of reproductive corticotropin-releasing hormone. *Ann N Y Acad Sci*, Vol.997 (April, 2011), pp. 129-135, ISSN 0077-8923.
- Schrier, R.W. & Briner, V.A. (1991). Peripheral arterial vasodilation hypothesis of sodium and water retention in pregnancy: implications for pathogenesis of preeclampsia-eclampsia. *Obstet Gynecol*, Vol.77 (May, 2011), pp. 632-639, ISSN 0029-7844.
- Schrier, R.W. & Ohara, M. (2010). Dilemmas in human and rat pregnancy: proposed mechanisms relating to arterial vasodilation. *J Neuroendocrinol*, Vol.22, No.5 (May, 2011), pp. 400-406, ISSN 1365-2826.
- Lindheimer, M.D. & Davison, J.M. (1995). Osmoregulation, the secretion of arginine vasopressin and its metabolism during pregnancy. *Eur J Endocrinol*, Vol.132, No.2, (May, 2011), pp. 133-143, ISSN 0804-4643.
- Davison, J.M.; Shiells, E.A.; Philips, P.R. & Lindheimer, M.D. (1988). Serial evaluation of vasopressin release and thirst in human pregnancy. Role of human chorionic gonadotrophin in the osmoregulatory changes of gestation. *J Clin Invest*, Vol.81 (April, 2011), pp. 798-806, ISSN 0021-9738.
- Schrier, R.W.; Ohara, M.; Rogachev, B.; Xu, L. & Knotek, M. (1998). Aquaporin-2 water channels and vasopressin antagonists in edematous disorders. *Mol Genet Metab*, Vol.65, (April, 2011), pp. 255-263, ISSN 1096-7192.
- Frokiær, J.; Marples, D.; Knepper, MA. & Nielsen, S. (1998). Pathophysiology of aquaporin-2 in water balance disorders. *Am J Med Sci*, Vol.316, No.5, (May, 2011), pp. 291-299, ISSN 0002-9629.
- Buemi, M. (2001). Urinary excretion of aquaporin-2 water channel during pregnancy. *Cell Physiol Biochem*, Vol.11, (3-4, 2011), pp. 203-208, ISSN 1015-8987.
- Soule, S.G.; Monson, J.P. & Jacobs, H.S. (1995). Transient diabetes insipidus in pregnancy: a consequence of enhanced placental clearance of arginine vasopressin. *Hum Reprod*, Vol.10, (May, 2011), pp. 3322-3324, ISSN 0268-1161.
- Landau, R.; Laverrière, A.; Bischof, P.; Irion, O.; Morales, M. & Cohen, M. (2010). Alteration of circulating Placental Leucine Aminopeptidase (P-LAP) activity in preeclampsia. *Neuro Endocrinol Lett*, Vol.31, No.1, (February, 2011), pp. 63-66, ISSN 0172-780X.
- Barron, W.M.; Dürr, J.; Stamoutsos, B.A. & Lindheimer, MD. (1985). Osmoregulation and vasopressin secretion during pregnancy in Brattleboro rats. *Am J Physiol*, Vol.248 (May, 2011), pp. 29-37, ISSN 0363-6135.
- Edwards, B. & LaRochelle, FT Jr. (1984). Antidiuretic effect of endogenous oxytocin in dehydrated Brattleboro homozygous rats. *Am J Physiol*, Vol.247, (May, 2011), pp. 453-F465, ISSN 0363-6135.
- Koo, K.W.; Jeon, U.S.; Kim, G.H.; Park, J.; Oh, Y.K.; Kim, Y.S.; Ahn, C.; Kim, S.; Kim S.Y.; Lee, J.S. & Han, J.S. (2003). Antidiuretic action of oxytocin is associated with increased urinary excretion of aquaporin-2. *Nephrol Dial Transpl*, Vol.19, No.10, (April, 2011), pp. 2480-2486, ISSN 0931-0509.
- Conrad, K.P. (2011). Emerging role of relaxin in the maternal adaptations to normal pregnancy: implications for preeclampsia. *Semin Nephrol*, Vol.31, No.1, (March, 2011), pp. 15-32 ISSN 0270-9295.

- Barbey, F.; Bonny, O.; Rothuizen, L.; Gomez, F. & Burnier, M. (2003). A pregnant woman with de novo polyuria-polydipsia and elevated liver enzymes. *Nephrol Dial Transpl*, Vol.18, No.10, (April, 2011), pp. 2193-2196 ISSN 0931- 0509.
- Iwasaki, Y.; Oiso, Y.; Kondo, K., Takagi, S.; Takatsuki, K.; Hasegawa, H.; Ishikawa, K.; Fujimura, Y.; Kazeto, S.; Tomita, A. (1991). Aggravation of subclinical diabetes insipidus during pregnancy. *N Engl J Med*, Vol.324, (May, 2011), pp:522-526, ISSN 0028-4793.
- Krysiak. R.; Kobielsz-Gembala, I. & Okopien, B. (2010). Recurrent pregnancy-induced diabetes insipidus in a woman with hemochromatosis. *Endocr J*, Vol.57, No.12, (March, 2011), pp. 1023-1028, ISSN 0918-8959.
- Jin-no, Y.; Kamiya, Y.; Okada, M.; Watanabe, O.; Ogasawara, M. & Fujinami, T. (1998). Pregnant woman with transient diabetes insipidus resistant to 1-desamino-8-D-arginine vasopressin. *Endocr J*, Vol.45, No.5, (March, 2011), pp. 693-696, ISSN 0918-8959.
- Goodman, H.; Sachs, B.P.; Phillippe, M. & Moore, T. (1984). Transient, recurrent nephrogenic diabetes insipidus. *Am J Obstet Gynecol*, Vol.149, No.8, (April, 2011), pp. 910-912, ISSN 0002-9378.
- Korbet, S.M.; Corwin, H.L. & Lewis, E.J. (1985). Transient nephrogenic diabetes insipidus associated with pregnancy. *Am J Nephrol*, Vol.5, No.6, (6, 2011), pp. 442-444 ISSN 0250-8095.
- Gutiérrez Junquera, C.; Balmaseda, E.; Gil, E.; Martínez, A.; Sorli, M.; Cuartero, I.; Merinero, B.; Ugarte, M. (2009). Acute fatty liver of pregnancy and neonatal long-chain 3-hydroxyacyl-coenzyme A dehydrogenase (LCHAD) deficiency. *Eur J Pediatr*, Vol.168, No. 1, (May, 2011), pp. 103-106, ISSN 0340-6199.
- Ganzevoort, W.; Rep, A.; De Vries, J.I.; Bonsel, G.J.; Wolf, H. & PETRA-Investigators. (2007). Relationship between thrombophilic disorders and type of severe early-onset hypertensive disorder of pregnancy. *Hypertens Pregnancy*, Vol.26, No.4, (March-April, 2011), pp. 433-445, ISSN 1064-1955.
- Larciprete, G.; Rossi, F.; Deaibess, T.; Brienza, L.; Barbati, G.; Romanini, E.; Gioia, S. & Cirese, E. (2010). Double inherited thrombophilias and adverse pregnancy outcomes: fashion or science? *J Obstet Gynaecol Res*, Vol.35, No.5, (April, 2011), pp. 996-1002, ISSN 1341-8076.
- Dogan, OO.; Simsek, Y.; Celen, S. & Danisman, N. (2011). Frequency of hereditary thrombophilia, anticoagulant activity, and homocysteine levels in patients with hemolysis, elevated liver functions and low thrombocyte count (HELLP) syndrome. *J Obstet Gynaecol Res*, URL: 10.1111/j.1447-0756.2010.01397, ISSN 1341-8076.
- Heilmann, L.; Schorsch, M.; Hahn, T. & Fareed, J. (2011). Antiphospholipid syndrome and pre-eclampsia. *Semin Thromb Hemost*, Vol.37, No.2, (April, 2011), pp. 141-145, ISSN 0094-6176.
- Haram, K.; Svendsen, E. & Abildgaard, U. (2009). The HELLP syndrome: clinical issues and management. A Review. *BMC Pregnancy Childbirth*, Vol.26, No.9, (April, 2011), pp. 8, ISSN 1471-2393.
- Martin, J.N.Jr.; Rinehart, B.K.; May, W.L.; Magann, E.F.; Terrone, D.A. & Blake, P.G. (1999). The spectrum of severe preeclampsia: comparative analysis by HELLP (hemolysis,

- elevated liver enzyme levels, and low platelet count) syndrome classification. *Am J Obstet Gynecol*, Vol.180, No.6, (April, 2011), pp. 1373-1384, ISSN 0002-9378.
- Magann, E.F. & Martin, J.N.Jr. (1999). Twelve steps to optimal management of HELLP syndrome. *Clin Obstet Gynecol*, Vol.42, (Jun, 2011), pp.532-550, ISSN 0009-9201.
- Stewart, M.W.; Brazis, P.W.; Guier, C.P.; Thota, S.H. & Wilson, S.D. (2007). Purtscher-like retinopathy in a patient with HELLP syndrome. *Am J Ophthalmol*, Vol.143, No.5, (May, 2011), pp. 886-887, ISSN 0002-9394.
- Fonseca, J.E.; Méndez, F.; Cataño, C. & Arias F. (2005). Dexamethasone treatment does not improve the outcome of women with HELLP syndrome: a double-blind, placebo-controlled, randomized clinical trial. *Am J Obstet Gynecol*, Vol.193, No.5, (April, 2011), pp. 1591-1598, ISSN 0002-9378.
- Flanagan, D.E.; Ibrahim, A.E.; Ellison, D.W.; Armitage, M.; Gawne-Cain, M. & Lees, P.D. (2002). Inflammatory hypophysitis—the spectrum of disease. *Acta Neurochir (Wien)*, Vol.144, (May, 2011), pp. 47-56, ISSN 0001-6268.
- Caturegli, P.; Newschaffer C.; Olivi, A.; Pomper, M.G.; Burger, P.C. & Rose, N.R. (2005). Autoimmune hypophysitis *Endocr Rev*, Vol.26, No.5, (May, 2011), pp. 599-614, ISSN 0163-769X.
- Ishihara, T.; Hino, M.; Kurahachi, H.; Kobayashi, H.; Kajikawa, M.; Moridera, K.; Ikekubo K. & Hattori, N. (1996). Long-term clinical course of two cases of lymphocytic adenohypophysitis. *Endocr J*, Vol.43, No.4, (March, 2011), pp. 433-440, ISSN 0918-8959.
- VanHavenbergh, T.; Robberecht, W.; Wilm, G.; VanCalenbergh, F.; Goffin, J.; Dom, R.; Bouillon, R. & Plets, C. (1996). Lymphocytic infundibulohypophysitis presenting in the postpartum period: Case report. *Surg Neurol*, Vol.46, No.3, (December, 2009), pp. 280-284, ISSN 0090-3019.
- Georgescu, C.E.; Ilie, I.; Moldovan, F.; Stan, H.; Albu, S.; & Duncea, I. (2010). Thunderclap headache caused by a pituitary non-functioning tumour presenting as spontaneous pituitary apoplexy. *Rom J Neurol*, Vol.IX, No.1, (March, 2011), pp. 33-37, ISSN 1843-8148.
- Dekkers, O.M.; Hammer, S.; de Keizer, R.J.; Roelfsema, F.; Schutte, P.J.; Smith, J.W.; Romijn, J.A. & Pereira, A.M. (2007). The natural course of non-functioning pituitary macroadenomas. *Eur J Endocrinol*, Vol.156, No.2, (May, 2011), pp. 217-224, ISSN 0804-4643.
- Sibal, L.; Ball, S.G.; Connolly, V.; James, R.A.; Kane, P.; Kelly, W.F.; Kendall-Taylor, P.; Mathias, D.; Perros, P.; Quinton, R. & Vaidya, B. (2004). Pituitary apoplexy: a review of clinical presentation, management and outcome in 45 cases. *Pituitary*, Vol.7, No.3, (March, 2011), pp. 157-163, ISSN 1386-341X.
- Semple, P.L.; Webb, M.K.; de Villiers, J.C. & Laws, E.R.Jr. (2005). Pituitary apoplexy. *Neurosurgery*, Vol.56, No.1,(May, 2011), pp. 65-72, ISSN 0148-396X.
- Krull, I.; Christ, E.; Kamm, C.P.; Ganter, C. & Sahli, R. (2010). Hyponatremia associated coma due to pituitary apoplexy in early pregnancy: a case report. *Gynecol Endocrinol*, Vol.26, No.3, (May, 2011), pp. 197-200, ISSN 0951-3590.
- Lubina, A.; Olchovsky, D.; Brezin, M.; Ram, Z.; Hadani, M. & Shimon, I. (2005). Management of pituitary apoplexy: clinical experience with 40 patients. *Acta Neurochir (Wien)*, Vol.147, No.2, (May, 2011), pp. 151-157, ISSN 0001-6268.

- Atmaca, H.; Tanriverdi, F.; Gokce, C.; Unluhizarci, K. & Kelestimur, F. (2007). Posterior pituitary function in Sheehan's syndrome. *Eur J Endocrinol*, Vol.156, No.5, (May, 2011), pp. 563-567, ISSN0804-4643.
- Iwasaki, Y.; Oiso, Y.; Yamauchi, K.; Takatsuki, K.; Kondo, K.; Hasegawa, H.; Itatsu, T.; Niinomi, M.; Tomita, A. (1989). Neurohypophyseal function in postpartum hypopituitarism: impaired plasma vasopressin response to osmotic stimuli. *J Clin Endocrinol Metab*, Vol. 68, No.3, (June, 2011), pp:560-565, ISSN 0021-972X.
- Briet, J.W. (1998). Diabetes insipidus, Sheehan's syndrome and pregnancy. *Eur J Obstet Gynecol Reprod Biol*, Vol.77, No.2, (April, 2011), pp. 201-203, ISSN 0301-2115.
- Mehdi, A.A.; Salti, I. & Uthman, I. (2011). Antiphospholipid syndrome: endocrinologic manifestations and organ involvement. *Semin Thromb Hemost*, Vol.37, No.1, (April, 2011), pp. 49-57, ISSN 0094-6176.
- Wiser, A.; Hershko-Klement, A.; Fishman, A.; Nachasch, N. & Fejgin, M. (2008). Gestational diabetes insipidus and intrauterine fetal death of monochorionic twins. *J Perinatol*, Vol.28, No.10, (April, 2011), pp. 712-714, ISSN 0743-8346.
- Weinberg, L.E.; Dinsmoor, J.E.; Silver, R.K. (2010). Severe hydramnios and preterm delivery in association with transient maternal diabetes insipidus. *Obstet Gynecol* Vol.116, No.(Suppl.2), (May, 2011), pp: 547-549, ISSN 0029-7844.
- Nyul, Z.; Vajda, Z.; Vida, G.; Sulyok, E.; Frokiaer, J. & Nielsen, S. (2002). Urinary aquaporin-2 excretion in preterm and full-term neonates. *Biol Neonate*, Vol.82, No.1, (2, 2011), pp. 17-21, ISSN 0006-3126.
- Zelenina, M.; Li, Y.H.; Glorieux, I.; Arnaud, C.; Cristini, C.; Decramer, S.; Aperia, A. & Casper, C. (2006). Urinary aquaporin-2 excretion during early human development. *Pediatr Nephrol*, Vol.21, No.7, (June, 2011), pp. 947-952, ISSN 0931-041X.
- Iacobelli, S.; Addabbo, F.; Bonsante, F.; Procino, G.; Tamma, G.; Acito, A.; Esposito, L.; Svelto, M. & Valenti, G. (2006). Aquaporin-2 excretion and renal function during the 1st week of life in preterm newborn infants. *Nephron Physiol*, Vol.104, No.4, (4, 2011), pp. 121-125, ISSN 1660-2137.
- Bianchi, Y. (2010). Idiopathic central diabetes insipidus in a premature newborn successfully treated by sublingual desmopressin. *Swiss Med Wkly*, Vol.140, No.21-22, (April, 2011), pp. 22S-22S, ISSN 1424-7860.
- Stapleton, G. & DiGeronimo, R.J. (2000). Persistent central diabetes insipidus presenting in a very low birth weight infant successfully managed with intranasal dDAVP. *J Perinatol*, Vol.20, No.2, (April, 2011), pp. 132-134, ISSN 0743-8346.
- Ng, P.C.; Lee, C.H.; Fok, T.F.; Lam, S.T.; Chan, Y.L.; Wong, W.; Cheung, K.L. & Chan, W.K. (1997). Central diabetes insipidus in a newborn with deletion of chromosome 7q. *J Paediatr Child Health*, Vol.33, No.4, (4, 2011), pp. 343-345, ISSN 1034-4810.
- Leichtman, L.G.; Wood, B. & Rohn, R. (1994). Anophthalmia, cleft lip/palate, facial anomalies, and CNS anomalies and hypothalamic disorder in a newborn - a midline developmental field defect. *Am J Med Genet*, Vol.50, No.1, (May, 2011), pp.39-41, ISSN 0148-7299.
- Ng, S.B.; W.; Buckingham, K.J.; Hannibal, M.C.; McMillin, M.J.; Gildersleeve, H.I.; Beck, A.E.; Tabor, H.K.; Cooper, G.M.; Mefford, H.C.; Lee, C.; Turner, E.H.; Smith, J.D.; Rieder, M.J.; Yoshiura, K.; Matsumoto, N.; Ohta, T.; Niikawa, N.; Nickerson, D.A.; Bamshad, M.J. & Shendure J. (2010). Exome sequencing identifies MLL2 mutations

- as a cause of Kabuki syndrome. *Nat Genet*, Vol.42, No.9, (May, 2011), pp.790-793, ISSN 1061-4036.
- Amr, S.; Heisey, C.; Zhang, M.; Xia, X.J.; Shows, K.H. & Ajlouni, K. (2007). A homozygous mutation in a novel zinc-finger protein, ERIS, is responsible for Wolfram syndrome. *Am J Hum Genet*, Vol.81, (April, 2011), pp. 673-683, ISSN 1061-4036.
- Siahaniidou, T.; Tsoumas, D.; Kanaka-Gantenbein, C. & Mandyla, H. (2006). Neuroendocrine abnormalities in a neonate with congenital toxoplasmosis. *J Pediatr Endocrinol Metab*, Vol.19, No.11, (April, 2011), pp. 1363-1366, ISSN 0334-018X.
- Muller-Scholden, J.; Lehrnbecher, T.; Muller, H.L.; Bensch, J.; Hengen, R.H.; Sörensen, N. & Stockhausen, H.B. (2000). Radical surgery in a neonate with craniopharyngioma - Report of a case. *Pediatr Neurosurg*, Vol.33, No.5, (April, 2011), pp.265-269, ISSN 1016-2291.
- Levendoglu-Tugal, O.; Noto, R.; Juster, F.; Brudnicki, A.; Slim, M.; Beneck, D. & Jayabose, S. (1996). Langerhans cell histiocytosis associated with partial DiGeorge syndrome in a newborn. *J Pediatr Hematol Oncol*, Vol.18, No.4, (May, 2011), pp. 401-404, ISSN 1077-4114.
- Barakat, A.J.; Pearl, P.L.; Acosta, M.T. & Runkle, B.P. (2004). 22q13 deletion syndrome with central diabetes insipidus: a previously unreported association. *Clin Dysmorphol*, Vol.13, No.3, (April, 2011), pp.191-194, ISSN 0962-8827.
- Kozma, C. (2005). Neonatal toxicity and transient neurodevelopmental deficits following prenatal exposure to lithium: Another clinical report and a review of the literature. *Am J Med Genet*, Vol.132A, No.4, (May, 2011), pp. 441-444, ISSN 1552-4825.
- Zerbe, R.L.; Robertson, G.L. (1981). A comparison of plasma vasopressin measurements with a standard indirect test in the differential diagnosis of polyuria. *N Engl J Med*, Vol.305, No.26, (May, 2011), pp.1539-1546, ISSN 0028-4793.
- Fjellestad-Paulsen, P.; Høglund, S.; Lundin, S. & Paulsen, O. (1993). Pharmacokinetics of 1-desamino-8-D-arginine vasopressin after various routes of administration in healthy volunteers. *Clin Endocrinol (Oxf)*, Vol.38, (May, 2011), pp. 177-182, ISSN 0300-0664.
- Ray, J.G.; Boskovic, R.; Knie, B.; Hard, M.; Portnoi, G. & Koren, G. (2004). In vitro analysis of human transplacental transport of desmopressin. *Clin Biochem*, Vol.37, No.1, (April, 2011), pp. 10-13, ISSN 0009-9120.



Diabetes Insipidus

Edited by Prof. Kyuzi Kamoi

ISBN 978-953-307-367-5

Hard cover, 140 pages

Publisher InTech

Published online 14, November, 2011

Published in print edition November, 2011

The first chapter of the book reports on the management of Langerhans cell histiocytosis (LCH)-induced central diabetes insipidus and its associated endocrinological/neurological sequelae in the national survey. The next chapter addresses DI and head injuries. Next, the management of neuroendocrine instability during maintenance of potential organ donors is described. Organ transplants have gradually increased worldwide. To have maintenance of appropriate potential organs, AVP is needed. Furthermore, nephrogenic DI-the potential therapeutic drugs and analysis of membrane protein stability is the topic of the next two chapters, followed by new insights into the diagnosis and management of pregnancy-related DI. The seventh chapter reports on the problems with differential diagnosis in a case of central DI in a female patient with bipolar disorder. The lithium treatment usually resulted in nephrogenic DI. Finally, over the last years, the development of MRI imaging on the pituitary gland with the stalk and hypothalamus has advanced. The final chapter interprets imaging techniques in DI in detail.

How to reference

In order to correctly reference this scholarly work, feel free to copy and paste the following:

Carmen Emanuela Georgescu (2011). New Insights into the Diagnosis and Management of Pregnancy-Related Diabetes Insipidus, *Diabetes Insipidus*, Prof. Kyuzi Kamoi (Ed.), ISBN: 978-953-307-367-5, InTech, Available from: <http://www.intechopen.com/books/diabetes-insipidus/new-insights-into-the-diagnosis-and-management-of-pregnancy-related-diabetes-insipidus>

INTECH

open science | open minds

InTech Europe

University Campus STeP Ri
Slavka Krautzeka 83/A
51000 Rijeka, Croatia
Phone: +385 (51) 770 447
Fax: +385 (51) 686 166
www.intechopen.com

InTech China

Unit 405, Office Block, Hotel Equatorial Shanghai
No.65, Yan An Road (West), Shanghai, 200040, China
中国上海市延安西路65号上海国际贵都大饭店办公楼405单元
Phone: +86-21-62489820
Fax: +86-21-62489821

© 2011 The Author(s). Licensee IntechOpen. This is an open access article distributed under the terms of the [Creative Commons Attribution 3.0 License](#), which permits unrestricted use, distribution, and reproduction in any medium, provided the original work is properly cited.