

Appendicitis and Appendicectomy

Sami M. Shimi

*Department of Surgery, Ninewells Hospital and Medical School,
University of Dundee
Scotland, United Kingdom*

1. Introduction

The term appendicitis was first used by an epic publication by FITZ (Harvard Medical School) in 1886. FITZ outlined the clinical diagnosis and suggested early removal of the appendix. This new concept was not readily accepted. The first recorded appendicectomy was reported from Australia and was done on a kitchen table in Toowoomba in 1893. Appendicectomy in the UK did not gain early acceptance until 1902, when Sir Frederick Treves operated on King Edward VII twelve days before his coronation.

2. Epidemiology

The epidemiology of appendicitis has caused a lot of intrigue. Although appendicitis was unknown before the 18th Century, there was a striking increase in its prevalence from the end of the 19th Century. There were suggestions that it was a side effect of modern western life. Although evidence for this was lacking, the rapid emergence of appendicitis in developed countries in the 20th Century and its rarity in rural areas and in undeveloped countries was cited as evidence. By the mid 1920s appendicitis became sufficiently common. Several theories have been advanced to account for the prevalence of the disease. One theory suggested that diet was responsible for the geographical distribution of appendicitis. It was however clear that diet could not fully explain the epidemiology of appendicitis. An alternative hypothesis proposed that improved hygiene in developed countries reduced the exposure of infants to enteric organisms would, modify the immune response to virus infections which might then cause appendicitis. Although this theory was accepted for many years, the hygiene hypothesis does not adequately explain the recent decline in the frequency of appendicitis in the latter half of the 20th Century. It remains uncertain whether there has been a real change in the incidence of appendicitis or whether the presentation and course of the disease has indeed changed.

The current incidence of appendicitis is about 100 per 100,000 person-years in Europe/America. Whereas the appendectomy rate is still decreasing, the incidence of appendicitis is now nearly stable. During the last 30 years the incidence of perforated appendicitis has not changed (approximately 20 per 100,000 person-years). Established risk factors for acute appendicitis are age (peak: 10-19 years), sex, and ethnic group/race. Classical theories (diet, hygiene) present illuminating models to explain the rise and fall of incidence in the last century; however, from a contemporary perspective the evidence is insufficient. The study of the epidemiology of appendicitis is complicated by the influence

of referral, infrastructure, and surgical treatment strategy on the incidence of acute appendicitis. Therefore, there is a strong need for good prospective studies with high-quality data.

3. Pathology

Several factors are claimed to predispose to acute inflammation of the appendix, including faecolith, food residues, lymphoid hyperplasia (in children) and the presence of a carcinoid tumour. Specific viral and bacterial inflammation can also affect the appendix. In addition the appendix can be involved by ulcerative colitis and Crohn's disease. In early acute appendicitis there is acute inflammation of the mucosa which undergoes ulceration. Pus may be present in the lumen. At this stage the patient experiences an ill defined central abdominal pain. Microscopically, the appendix is usually swollen and the overlying vessels are dilated and prominent. As the acute inflammation develops, it spreads through the full thickness of the appendix wall to reach the serosal surface. This causes a localised acute peritonitis, which is perceived as a sharp pain localised to the right iliac fossa. At this stage the appendix microscopically shows dilated serosal vessels and a rough, yellow, fibrinous exudate on the surface. By this stage the inflammation and the infection has spread to involve all layers of the appendix wall. The build up of fluid exudate within the wall increases tissue pressure and this, together with the toxic damage to blood vessels and subsequent thrombosis can lead to superimposed ischemia. In addition the muscle layer is replaced by an acute inflammatory infiltrate with degranulation of neutrophils contributing to toxic damage. Both the ischemia, toxic products and infection contribute to weakness of the wall of the appendix and the distal part of the appendix can become gangrenous and perforate. This liberates bowel contents in to the peritoneal cavity and causes generalised peritonitis which leads to severe deterioration in the clinical condition. If the general condition of the patient is satisfactory, the omentum might cover the site of perforation and local abscess formation follows. Infiltration into blood vessels and lymphatics leads to the consequences of blood spread which is suppurative pylephlebitis (inflammation and thrombosis of the portal vein), liver abscess and septicaemia. The inflammation can also become chronic, or obstruction to the neck of the appendix may lead to mucus retention in its lumen causing a mucocoele of the appendix. This does not often give rise to clinical problems but on rare occasions may rupture and disseminate mucus secreting epithelial cells in to the peritoneal cavity - pseudomyxoma peritonei.

The presence of gangrene or perforation seems to be associated with the presence of faecoliths. These are intraluminal laminated appendiceal calculi. They result from dehydration and compaction of faecal pellets. Approximately 50% of cases of gangrenous or perforated appendicitis are associated with a faecolith in contrast with uncomplicated appendicitis in which a faecolith is rarely present. It is thought that a faecolith increases the likelihood of obstruction of the appendix and thereby allows the accumulation of pus. Overall about 20% of all patients with acute appendicitis have perforation at the time of operation. At the extremes of age (below 5 and above 60 years) the rate of perforation is in the region of 60%.

Perforation rates of 20% to 30% have been reported consistently over the past 70 years despite the technologic advances over this interval. Recent evidence suggesting that perforation precedes surgical evaluation in the majority of cases indicates that reduction of perforation rates will have to be addressed through encouraging earlier evaluation and greater access to care. However, modern surgical therapy has been responsible for reducing

the mortality of appendicitis from 26% overall to less than 1% over the same period. The mortality rate of 0.08% reported is testament to the benefits of advancing technology in managing a persistent rate of perforation and its attendant complications. Perforation continues to disproportionately affect those individuals at the extremes of age. This is most likely due to delays in presentation and diagnosis related to an inability to communicate in the younger population. In the older population, a combination of delayed presentation, confounding medical conditions and a decreased index of suspicion may contribute to this observation.

Emergency appendectomy was originally advocated because of the very high mortality of perforated appendicitis and the assumption that acute appendicitis evolved to perforated disease, a pathophysiologic hypothesis that has never been proven. This notion was first proposed by Reginald Fitz, the originator of the term appendicitis, in 1886. Fitz was the first to identify inflammation of the appendix as a cause for right lower quadrant infections, previously known as thyphilitis. In making the argument that the appendix causes this entity, however, Fitz incidentally noted that one-third of patients undergoing autopsy in the pre-appendectomy era had evidence of prior appendiceal inflammation, suggesting that appendicitis often resolved spontaneously without surgery. Later evidence from submariners who developed appendicitis while at sea and received delayed surgical therapy has shown that in most cases the acute disease can resolve with non-operative antibiotic and supportive therapy.

Perforated and non-perforated appendicitis have followed radically different epidemiologic trends over the past 2 decades. While perforated appendicitis slowly but steadily increased in incidence, non-perforated appendicitis stabilised or declined. If perforated appendicitis was simply the result of appendicitis that was not surgically treated early enough, the trends should have been more nearly parallel throughout all the time periods studied. Time series analysis showed that on a year-to-year basis, there was a significant positive correlation between perforated and non-perforated appendicitis for men but not for women. These unassociated epidemiologic trends suggest that the pathophysiology of these diseases is different. If true, it might follow that many patients presenting with non-perforated appendicitis might experience spontaneous resolution without perforation. There is historical, clinical, and immunologic evidence to support this hypothesis.

An alternative hypothesis suggests that several factors (ie, prehospital time, availability of operating room for emergency surgery, time of presentation) have been shown to be significantly associated with perforated appendicitis. Compared with uncomplicated appendicitis, perforated appendicitis is associated with a two- to tenfold increase in mortality

4. Diagnosis

The diagnosis of appendicitis is predominantly a clinical one. The history and examination are pivotal to determining the correct diagnosis. The pain can be a generalised colicky abdominal pain that became more localised to the right iliac fossa over the course of three days. Owing to the embryological origin of the appendix as a midline structure, the majority of patients with acute appendicitis first notice a pain which starts in the region of the umbilicus. This is usually a dull ache or it may be colicky pain when the appendix lumen is obstructed. The pain may change from an intermittent pain to a constant localised sharp pain. After a period of time the pain shifts to the right lower quadrant of the abdomen

owing to the inflamed appendix irritating the parietal peritoneum. Approximately 30% of patients do not experience this shift of pain and their symptoms commence in the right iliac fossa. Nausea and vomiting are common and anorexia is inevitable. About 20% of patients will also have diarrhoea especially when the appendix lies in the pelvis.

There can be other features in the history suggestive of appendicitis. This includes episodes of vomiting, fever and anorexia. Points to exclude in the history are changes to bowel habits and urinary symptoms. In some cases the inflamed appendix can irritate the bladder due to the close proximity. This however can be supported by a negative urinalysis. The possibility of mesenteric adenitis should be considered in children. This is triggered by viral pathogens and manifests initially as a respiratory tract infection or generalised malaise and fever prior to the onset of abdominal symptoms. Although mesenteric adenitis is more common in children, it still should be considered in young adults as such a diagnosis would not require surgical intervention. It presents very similarly to acute appendicitis however subtle differences do exist. Often the pain of mesenteric adenitis can move location when the patient moves whereas in appendicitis it is fixed to the right iliac fossa. Inflammatory bowel disease such as Crohn's often presents with ileocaecal disease and can present similarly to appendicitis. In such cases a mass could be palpated in the right iliac fossa, without any extraintestinal signs. The clinical history alone is not enough to diagnose the condition therefore examination and investigation are essential.

Most patients with appendicitis have a low grade fever and some tachycardia. A very high temperature (above 39 °C) indicates probable abscess formation or other cause of infection. The site of maximum tenderness is usually at McBurney's point. In patients with inflammation of a retro-caecal appendix the pain may be considerably higher and more lateral. Alternatively in pelvic appendicitis, the pain may be lower and almost midline. The abdomen may show signs of guarding in 90% of patients with acute appendicitis. In patients with perforation of the appendix they will have generalised peritonitis and the area of guarding may extend beyond the right iliac fossa. Rebound tenderness is a useful sign. In some patients an appendix mass could be felt on abdominal examination.

On general examination fever is an important sign indicative of an inflammatory condition. A foetor is also detected in 50 % of patients. In children, general observation of discomfort associated with movement or posture is also indicative. Abdominal examination should reveal tenderness over the right iliac fossa with or without rebound tenderness or guarding which indicates signs of peritonism. Specific signs of Appendicitis include McBurneys and Rovsing's signs. The appendix lies in the right iliac fossa and is attached to the posteromedial wall of the caecum where the teniae coli unite. The surface marking for the root of the appendix is relatively constant and is situated approximately one third of the distance from the anterior superior iliac spine to the umbilicus. This is referred to as McBurneys point as shown in the diagram (Figure 1).

In general, the clinical features of appendicitis can vary depending on the position of the appendix. The commonest position of the appendix is retrocaecal. In this position, psoas muscle irritation (exacerbation of pain on hip extension) can be evident. In the subcaecal and pelvic position, supra pubic pain and urinary frequency may be the predominant symptoms with right sided tenderness on rectal or vaginal examination. In the pre and post ileal position, diarrhoea or vomiting may be the presenting features due to irritation of the ileum. On examination for appendicitis it is important to determine if the pain is worst at McBurneys point. Furthermore the patient may describe pain over this area on coughing. Specific localisation of tenderness over this anatomical landmark is indicative that the inflammation is no longer limited to the lumen of the appendix which poorly localises pain.

It is suggestive that there is irritation at the peritoneum where it comes into contact with the appendix. Rovsing's sign can be demonstrated by palpating the left iliac area which results in stretching of the underlying peritoneum. This induces pain in the right iliac fossa due to irritation of the inflamed peritoneum. Digital rectal examination can elicit tenderness on the ipsilateral side to the appendix.

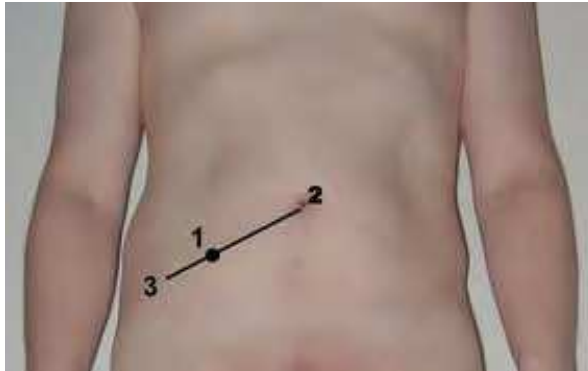

Fig. 1. Diagrammatic illustration of McBurney's point (1) with regards to the umbilicus (2) and the anterior superior iliac spine (3).

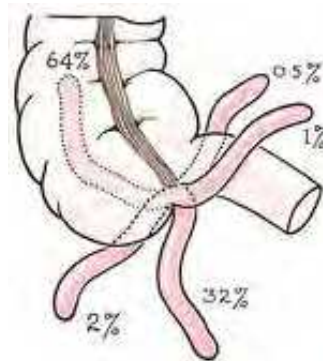


Fig. 2. Various positions of the vermiform appendix.

In females of child bearing age it is important to consider the possibility of pregnancy particularly if the patient was sexually active. An ectopic pregnancy should be considered in the potential differential diagnosis which can often present with pain in the lower quadrants. The pain associated with ectopic pregnancies often radiates to the shoulder. A history of the patient's menstrual cycle and sexual activity and contraception can help in elimination of this differential. It is important to assess beta HCG levels on admission as this would determine further management. Ultrasonography and CT scanning are the best non-invasive means of investigating appendicitis. The scan may show an abnormal appendix or an appendicolith with a diameter of over 6mm. The blood results will often have a rise in the inflammatory markers including white cell count and C-Reactive protein (CRP).

It is important to ensure that the patient has received adequate analgesia and has had blood tests to ensure clotting is normal before surgery. The patient would also require a 'group and save' due to a small risk of bleeding during or after surgery. Antibiotics are often prescribed as prophylaxis to help reduce the risk of wound infections. The patient may require an NG tube if vomiting to prevent the risk of aspiration.

In order to make the diagnosis of appendicitis and at the same time avoid unnecessary appendicectomies a variety of diagnostic modalities were advanced. A review of the literature suggested that the clinical diagnosis of acute appendicitis based on symptoms, physical findings, and serological tests is relatively inaccurate. Despite having high sensitivity (up to 100%), clinical evaluation has relatively low specificity (73%). This means that surgeons are likely to overestimate the presence of appendicitis in patients who present acutely. Several reports have found the use and diagnostic accuracy (specificity and sensitivity) of ultrasound and computed tomography (CT) to be limited in the preoperative evaluation of patients with suspected appendicitis especially in the emergency setting.

The most common US technique used to examine patients with acute abdominal pain is the graded-compression procedure. With this technique, interposing fat and bowel can be displaced or compressed by means of gradual compression to show underlying structures. Furthermore, if the bowel cannot be compressed, the noncompressibility itself is an indication of inflammation. Curved (3.5–5.0-MHz) and linear (5.0–12.0-MHz) transducers are used most commonly, with frequencies depending on the application and the patient's stature. The reported sensitivity of ultrasonic detection of appendicitis lies between 55 and 98% and the specificity between 78 and 100%.

Computed Tomography (CT) has a higher sensitivity and specificity for the diagnosis of appendicitis. The CT technique used to examine patients with acute abdominal pain generally involves scanning of the entire abdomen after intravenous administration of an iodinated contrast medium. Although abdominal CT can be performed without contrast medium, the intravenous administration of contrast material facilitates good accuracy with a positive predictive value of 95% reported for the diagnosis of appendicitis and a high level of diagnostic confidence, especially in rendering diagnoses in thin patients, in whom fat interfaces may be almost absent. Although rectal or oral contrast material may be helpful in differentiating fluid-filled bowel loops from abscesses in some cases, the use of oral contrast material can markedly increase the time to complete the test in the emergency setting and may be contraindicated for patients who potentially may require anesthesia and surgery. The lack of enteral contrast medium does not seem to hamper the accurate reading of CT images obtained in patients with acute abdominal pain as it does in postoperative patients. Exposure to ionizing radiation is a disadvantage of CT. This risk however should be weighed against the direct diagnostic benefit. CT has been shown to reduce the negative-finding appendectomy rate from 24% to 3%. However, only routine CT in comparison to selective use of CT would achieve such results. CT seems to be more sensitive (96% vs. 76%) and accurate (94% vs. 91%) than US in diagnosing acute appendicitis, whereas they are almost equal when it comes to specificity (89% vs. 91%). CT imaging tailored to evaluate acute appendicitis has proven to be particularly successful with a sensitivity of 100%, specificity of 95%, positive predictive value of 97%, negative predictive value of 100%, and accuracy of 98%.

Based on the clinical diagnosis, surgical exploration for suspected appendicitis is advocated early to prevent progression or perforation with its associated morbidity and mortality.

Active observation is advocated for patients with equivocal symptoms, signs and laboratory results. Surgical exploration has been accompanied by an incidental appendicectomy in a considerable number of cases. Authors of large prospective studies report a 15%-32% removal rate of normal appendices at surgery. The reported negative appendicectomy rate for men varies from 7 % to 15 %, whereas that for women of child bearing age lies between 22 % and 47 % . This high rate of unnecessary appendicectomies has considerable morbidity and high cost to the health care system. A large population based study found that patients undergoing negative appendicectomy have prolonged hospitalisation, increased infectious complications and higher rates of case fatality when compared with patients with appendicitis. The national cost of hospitalisation was also higher. This may be due to concomitant disease which necessitated the presentation of right iliac fossa pain which otherwise remains undiagnosed after appendicectomy.

A number of studies have emphasised the value of laparoscopy as a diagnostic and operative tool particularly in young women. Diagnostic laparoscopy has been found reliable in the assessment of the appendix and has reduced the number of unnecessary appendicectomies. In addition, it has been useful in the diagnosis of alternative pathology when it exists.

In order to reduce total costs, some studies have suggested a selective approach in the use of diagnostic laparoscopy. There is evidence however that unless diagnostic laparoscopy is used routinely, the number of negative appendicectomies remains high.

5. Management

Historically we have seen progression in the management of right iliac fossa pain from purgation to early appendicectomy. Early surgical dictum necessitated appendicectomy for patients with right iliac fossa pain admitted to hospital with convincing signs and symptoms. Appendicectomy was clearly overdone in the past as the delay in diagnosis of appendicitis contributed to an increase in morbidity and mortality. Indeed delayed diagnosis of appendicitis was the most common cause of litigation against emergency surgeons. In regard to laparoscopic appendicectomy, early reports suggested a high rate of complications particularly intra-abdominal abscess formation which was associated with laparoscopic appendicectomy. A more recent Cochrane review however, has found an equal rate of complications in open and laparoscopic appendicectomy. However, patients operated on by laparoscopy, realised the benefits of laparoscopy in terms of less pain, early discharge from hospital and return to normal activities.

Natural orifice transluminal endoscopic surgery (NOTES) has become an exciting area of surgical development. Significant limitations to this surgical concept include lack of surgical expertise and appropriate flexible instrumentation although both aspects are being addressed. An alternative and competing technology to NOTES is single-incision laparoscopic surgery (SILS). A number of reports have produced encouraging results for single incision appendicectomy but this technique remains in its infancy. A number of skeptics have expressed reservations about the applicability of these two techniques for appendicectomy and it will be a matter for the surgical community uptake and adoption of these two techniques over the next few years.

In terms of the cost of the utility of laparoscopic appendicectomy, the overall costs might be justified since the use of laparoscopy can increase diagnostic power, provide less postoperative pain and fewer wound infections, decrease hospital stay and return to normal

activities, and decrease the number of postoperative adhesions. At least six randomized studies have addressed the cost issue. Some found that overall costs for laparoscopic appendectomy were less (but not significantly so), most of the other studies have shown consistently that laparoscopy is more expensive. There was however a wide range of costs. One study found a mean difference of £148 in operating room charges, which does not compensate the costs for the mean difference in analgesics requirement between laparoscopic and open appendectomy. On the other hand, there is no doubt in the superiority of diagnostic laparoscopy and laparoscopic appendectomy in terms of quality but only if the incidence of post-operative complications could be reduced. The key to this dilemma lies in separating simple appendicitis from complicated appendicitis. The former will almost invariably have a low incidence of post-operative complications while those with complicated appendicitis (perforation or abscess) seem to have a higher rate of complications after laparoscopic appendectomy.

5.1 Management of appendix abscess

Patients presenting with an appendix mass should be treated non-surgically in the first instance. Once the abscess has been confirmed radiologically, percutaneous drainage is the best treatment of choice. Occasionally this drainage can be followed by the development of a faecal fistula but this is usually a low output fistula which normally heals spontaneously. If percutaneous drainage is inadequate, it may be necessary to carry out operative drainage. In patients who have had an appendix mass treated conservatively, about 15% will develop recurrent appendicitis. An interval appendectomy should be considered.

If appendix mass was found at laparoscopy or laparotomy an attempt should be made to drain the abscess and leave the appendix in situ. Old surgical dogma which continues to apply is that it is 'fool hardy to remove the appendix in the presence of an appendix abscess'. The main reasons for this is the generalised inflammation of the adjacent caecum and small bowel. Attempts at appendectomy in this scenario, invariably result with intra and post operative complications. Such attempts usually result in a more extensive resection of the adjacent small bowel and caecum. Given the emergency presentation of these patients, the potential for complications is large.

5.2 Negative, incidental and elective appendectomy

If a normal appendix was found at laparoscopy, most surgeons would leave the appendix in-situ as an appendectomy may carry some procedure specific complications. However some skilled surgeons have excellent results with removing a normal appendix laparoscopically. Based on the results of negative appendectomies published, the complication rate tends to be low. However, if a right iliac fossa incision has been made over the appendix for open appendectomy, it would seem reasonable to carry out an appendectomy. This is mainly due to a future assumption that appendectomy has been carried out when a patient presents at a later stage. It is also claimed that 20% of normal looking appendices may have evidence of mucosal appendicitis. Further, although rare, carcinoma of the appendix occurs in rare cases when the appendix looks microscopically normal.

There is little evidence to support the concept of chronic appendicitis. A number of patients mainly young females will have repeated acute presentations with right iliac fossa pain in the absence of raised inflammatory markers. Labels such as chronic appendicitis and

'grumbling appendix' have been applied to these patients. However, there is no evidence to support this diagnosis. In some of these patients a faecolith was found in the lumen of the appendix which could in theory account for some of the symptoms without necessarily causing full fledged appendicitis. However, elective appendicectomy does not necessarily obviate the long term symptoms of many of these patients any more than a placebo effect. Consequently, the concept of elective appendicectomy for chronic right iliac fossa pain seems unjustified.

5.3 Non-operative management

Acute appendicitis is considered a surgical emergency. The incidence decreases with increasing adult age, and the overall incidence in the general population has probably been decreasing during the last 50 years. Classically, appendectomy is performed to avoid perforation, which typically occurs within 48 hours. With the development of the preoperative use of antibiotics, early investigators reported that the peritonitis associated with appendicitis usually resolved before appendectomy. A number of publications have reported cases of appendicitis treated conservatively with a small number of deaths, a further number requiring abscess drainage, and a large number of failures requiring appendectomy. Several more recent studies have shown that perforated appendicitis can be treated nonoperatively with IV antibiotics with the performance of percutaneous drainage if an abscess is present. Success rates have been reported as between 88% and 100%, with the incidence of recurrent appendicitis 5% to 38%. The use of conservative (non-surgical) management of appendicitis is currently reserved to situations where access to surgical management is limited such as on board of ships, fishing vessels, submarines, space missions, polar and Antarctic expeditions . Medical evacuation is performed when possible, and is expedited if improvement does not occur. For some programs, prophylactic appendectomy has been considered. The benefits and long term risks of performing a prophylactic appendectomy in an otherwise healthy individual must however be carefully considered.

There are no studies that have looked at the complications associated with prophylactic appendectomy.

5.4 Management of acute appendicitis

Based on current evidence, all patients presenting with convincing symptoms and signs of appendicitis with raised serological markers of inflammation, should have a diagnostic laparoscopy to confirm the diagnosis where possible. Patients found to have evidence of appendicitis by virtue of serosal inflammation and / or the presence of fibrinous exudates should be considered for appendicectomy. The consideration for open or laparoscopic appendicectomy hinges on the experience of the surgeon, the availability of suitable assistance and appropriate instruments and the express wishes of the patient if these have been made in advance. In equivocal cases, all surgeons would search for an alternative source to account for the patient's symptoms and signs and in the absence of an alternative source, appendicectomy should be considered.

In patients found to have perforated appendicitis surgeons should attempt to evaluate the risks and benefits of laparoscopic surgery for the individual patient based on the amount of contamination of the peritoneal cavity, the spread and intensity of inflammation against the general condition of the patient together with surgical technical factors including the experience of the surgeon and the availability of appropriate instruments.

In all patients undergoing appendectomy, prophylactic antibiotics should be used. In patients who have had a perforated appendix, appendectomy should be followed by peritoneal lavage. When perforation has occurred it is common practice to continue intravenous antibiotics for a period postoperatively depending on the degree of infection and contamination. Recent evidence suggests that metronidazole would be sufficient for simple appendicitis. Additional broad-spectrum antibiotics may be necessary for complicated appendicitis. If an adequate peritoneal lavage has been carried out, abdominal drains do not confer any benefit.

5.4.1 Technique of open appendectomy

An open procedure involves a muscle splitting gridiron incision at McBurneys point. The muscle layers are separated along the line of the fibres allowing for the identification and opening of the peritoneum. Upon entry into the peritoneum the caecum is identified and appendix is located. This can be achieved through using the merging of the teniae coli as a reference point. The vessels in the meso-appendix are ligated until the appendix is free. The base of the appendix can then be ligated with two loops of absorbable sutures and the appendix divided between the two loops. The appendix can then be removed. Some surgeons invaginate the appendix stump either using a pursestring absorbable suture or a Z stitch. The majority of surgeons do not invaginate the appendix stump but use electro-coagulation on the visible edge of the mucosa. After ensuring haemostasis, a thorough wash is carried out. The wound is then closed in layers.

5.4.2 Laparoscopic appendectomy

In 1983, Semm performed the first laparoscopic appendectomy. Ever since then, the efficiency and superiority of laparoscopic approach compared to the open technique has been the subject of much debate. The idea of minimal surgical trauma, resulting in significantly shorter hospital stay, less postoperative pain, faster return to daily activities, and better cosmetic outcome has made laparoscopic surgery for acute appendicitis very attractive. However, several retrospective studies, several randomized trials and meta-analyses comparing laparoscopic with open appendectomy have provided conflicting results. Some of these studies have demonstrated better clinical outcomes with the laparoscopic approach, while other studies have shown marginal or no clinical benefit and higher surgical costs. The European Association of Endoscopic Surgeons have published their guidelines on laparoscopic appendectomy. In summary, the EAES have found that laparoscopic appendectomy is feasible and safe with a slightly longer operating time than open appendectomy. However, they expressly state that the safety of laparoscopic appendectomy during pregnancy is not established. Laparoscopic appendectomy has advantages over open appendectomy but there is potential for serious injuries. EAES recommends that at least 20 cases of laparoscopic appendectomy should be done before surgeon's accreditation for this procedure.

5.4.3 Technique of laparoscopic appendectomy

The patient is placed in a Trendelenburg position, with a slight rotation to the left. The surgeon should stand on the patients left side and the primary monitor should be placed on the right side of the patient (opposite the surgeon). The patients arms should be tucked at the sides to allow sufficient room for the surgeon and camera operator to move cephalad as required. Pneumoperitoneum is produced by continuous pressure of 10-12 mmHg of carbon

dioxide *via* a Verres canula, positioned in the sub-umbilical area. Following gas insufflation, a 12 mm canula for the 30 degree angled laparoscope should be placed in the periumbilical area (preferably on the left). Alternatively, a 12 mm canula can be introduced by the Hasson's technique (introduction of first trocar into the peritoneum through a sub-umbilical small incision) for initial insufflations of gas. Two additional canulae are required. A 12 mm canula should be placed in the suprapubic area at the midline point to accommodate the grasping or stapling device and/or to facilitate specimen extraction, and a third 5 mm canula in the right (or left) lower abdominal quadrant is introduced under direct vision. When the third cannula is placed on the right, it must be sufficiently far from the appendix to allow a safe and comfortable working distance. The abdominal cavity is thoroughly inspected in order to exclude other intra-abdominal or pelvic pathology. If the appendix is normal, it is important to seek other sources to account for the patient's presentation. If no other cause is identified, it will be up to the discretion of the surgeon at the operating table to decide on removing an apparently normal looking appendix. This has to be guided by prior knowledge of the patient's history, acute presentation, examination findings and serological markers of inflammation.

The appendix should be identified at the base of the caecum. Atraumatic bowel graspers should be used to lift the caecum. Part of the appendix should start coming to view. A second pair of atraumatic graspers (or blunt suction probe) should be used to separate the appendix from adherent tissue by blunt dissection. The mesoappendix should be identified and divided with bipolar forceps (or mono-polar diathermy and scissors). Alternatively, the meso-appendix could be divided using clips, *Ligature*, ultrasonic dissector or endoscopic stapler. The base of the appendix should then be identified and secured with one or two ligating loops of absorbable sutures placed at the base of the appendix close to the caecum. This is followed by blunt dissection distal to the second loop using a curved dissector. The appendix should then be divided between the 2 loops. The visible part of the mucosa is usually electro-coagulated. There is no need to bury the appendix stump. Alternatively, the base of the appendix could be stapled using one of the commercially available staplers. This achieves both closure and division of the appendix. In all cases, the specimen should be removed through the trocar without contact with the wound. Alternatively, if the appendix is too bulky, it should be placed in an endobag (a variety are available on the market) which can be extracted through one of the larger canulae sites. All removed tissue should be sent for histopathology. A thorough wash is then carried out. Although this should centre on the operative site, it should cover all sites of contamination encountered at the initial evaluation. Any faecoliths or necrotic material which have escaped from a perforated appendix should be removed if encountered. On occasion it may be necessary to look for inter-bowel fluid or pus collections and wash these out as well. The procedure should terminate by abdominal desufflation and removal of all cannulae. Patients should have two additional doses of antibiotics post operatively unless widespread contamination and peritonitis was evident. In these cases, antibiotics coverage should be continued for several days post operatively until the patient is no longer septic. If bleeding is encountered during the procedure, an additional trocar may be required to place a suction device while looking for the source of bleeding. Once this is identified, control of bleeding may be achieved using clips or ligatures. The use of staplers and more complex energy devices in appendicectomy saves time but adds to the cost of the operation. In general, they are not recommended unless time is a significant issue or these are used due to complexity or difficulty encountered during the procedure.

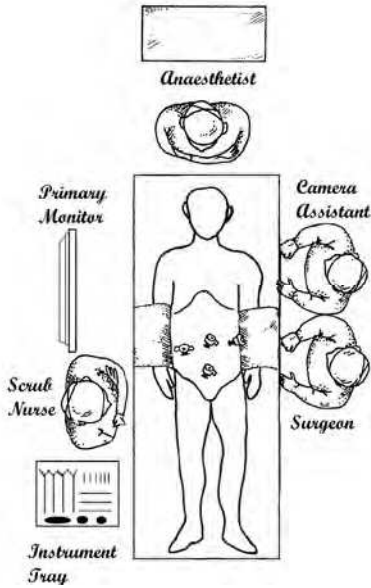


Fig. 3. Operating room set-up for diagnostic laparoscopy and appendicectomy.

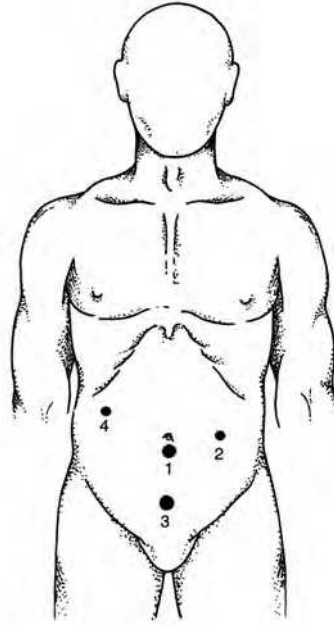


Fig. 4. Trocar positions for appendicectomy. Trocar 1 is used for the laparoscope. Trocars 2 and 3 are the main dissection sites. Trocar 4 can be added if necessary.

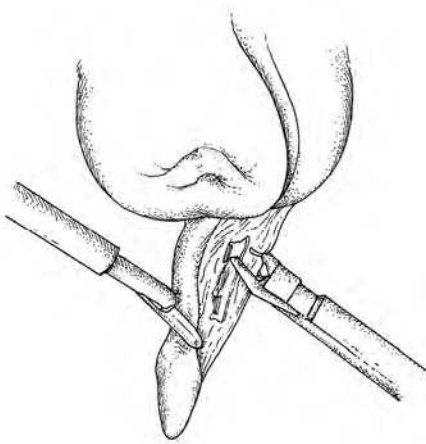


Fig. 5. Vessels in the meso-appendix are dissected and clipped.

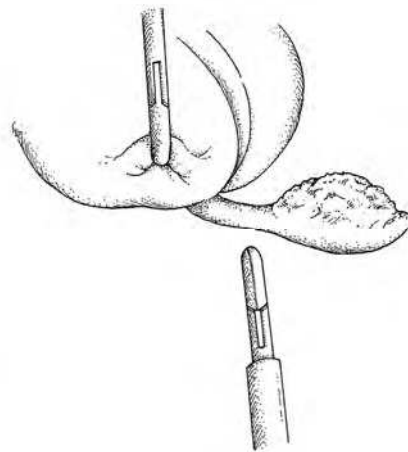


Fig. 6. The appendix is freed by blunt dissection to its base on the caecum.

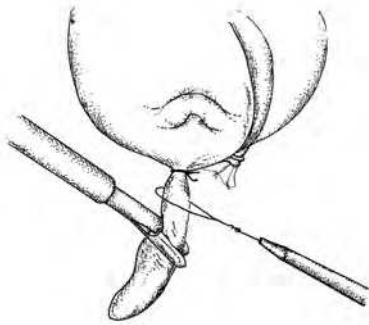


Fig. 7. Two pre-tied loops of absorbable sutures are applied to the base of the appendix.

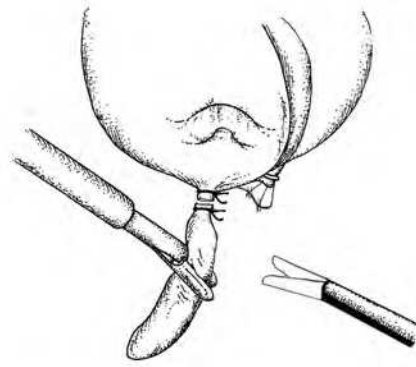


Fig. 8. The appendix is divided between loops and then delivered.

5.5 Laparoscopic versus open appendicectomy

Despite numerous prospective randomised trials, systematic reviews and meta-analysis the superiority of laparoscopic over open appendicectomy remains unclear particularly for complicated appendicitis. Previous studies have produced conflicting conclusions regarding the incidence of postoperative adverse events after laparoscopic and open appendicectomy. Retrospective cohort studies, randomised controlled trials and meta-analysis have demonstrated similar rates of overall morbidity. However, significant differences have been demonstrated in a few studies. With regards to operating time, there is a clear trend of extended operating time with laparoscopic appendicectomy in earlier studies with a further trend towards parity between the two procedures. This is a reflection of the experience of surgeons with the technique. With regards to hospital stay, the length of hospital stay after surgery was shortened in laparoscopic appendicectomy by a fraction of a day. This difference although numerically significant is of little practical significance.

Early return to full activity is accepted as an obvious advantage of laparoscopic appendicectomy which is supported by a large scale meta-analysis conducted by the Cochrane Colorectal Cancer Group. Clearly the smaller incisions of laparoscopic appendicectomy contribute to reduce trauma to the abdominal wall and less pain allowing faster recovery. Fast resumption of a normal diet following laparoscopic appendicectomy was another appealing advantage, resulting from minimal manipulation of bowel. The difference between laparoscopic and open appendicectomy in terms of resumption of normal diet intake represents a fraction of a day. Although this is significant numerically it is of doubtful practical significance. Reduced postoperative pain is another quality attribute of laparoscopic surgery. Although difficult to assess, a number of meta-analysis found that laparoscopic appendicectomy offered significant advantages in relieving postoperative pain mainly due to its minimal abdominal wall trauma. Reduction of wound infection is a significant advantage of laparoscopic appendicectomy. The chance of wound infection is greater in open appendicectomy partly because the inflamed appendix is removed from the abdominal cavity directly through the wound whereas in laparoscopic appendicectomy it is extracted via a bag or trocar. In addition the port-site wounds in laparoscopic

appendicectomy are considerably smaller with less potential space and less interruption of blood supply around wound.

Several explanations have been advanced for the reduction of ileus following laparoscopic appendicectomy. Firstly, decreased handling of the bowel during the procedure leads to less postoperative adhesion and such adhesions may be responsible for ileus. Secondly patients after laparoscopic appendicectomy had less opiate analgesics which inhibited bowel movements in the postoperative period. Thirdly earlier mobilisation after laparoscopic appendicectomy may also contribute to the reduction of ileus. Several meta-analysis have found that the incidence of intra-abdominal infections, intra-operative bleeding and urinary tract infections after laparoscopic appendicectomy was higher compared with open appendicectomy. It is not clear why intra-operative bleeding and urinary tract infections are higher after laparoscopic appendicectomy. With regards to intra-abdominal infections and abscess formation, there was suggestions that aggressive manipulation of the infected appendix and increased use of irrigation fluid might have increased the incidence of intra-abdominal infections after laparoscopic appendicectomy. The majority of studies however have not separated the results for simple uncomplicated appendicitis. It does however appear that patients with complicated appendicitis managed by laparoscopic appendicectomy have a higher tendency for intra-abdominal abscess formation.

The conversion rate from laparoscopic to open appendicectomy is around 10%. This is not surprising when considering the proportion of complicated appendicitis and the emergency setting of the procedure.

Appendicectomy carries a fairly low risk of mortality. Consequently many studies do not report mortality rates or multi-variate analysis on these rates. Amongst studies that do report mortalities, the event rate ranges between 0.16 and 0.24.

During pregnancy, laparoscopic appendectomy was found to be safe and effective and at least equivalent to open appendicectomy. Despite the raised intra-abdominal pressure associated with pneumoperitoneum, laparoscopic appendicectomy is associated with good maternal and fetal outcome. Further confirmatory studies are awaited before the safety of laparoscopic appendicectomy can be accepted.

5.6 Long-term complications and implications

Both the acute inflammatory condition of appendicitis and the surgical operation carried out to remove the appendix can potentially promote adhesion formation particularly around the fallopian tubes which may lead to tubal dysfunction in females of child bearing age. There is controversy surrounding the association between previous appendicectomy with subsequent infertility in females. Some reports found perforated appendicitis in childhood is not an appreciable cause of subsequent tubal infertility, while other reports found a high incidence of tubal infertility in women previously treated for appendicitis complicated by perforation, pelvic peritonitis or abscess. Three studies considered non-perforated appendicitis as well as perforated appendicitis on subsequent infertility and their result suggest that neither acute appendicitis nor perforation of the appendix was associated with a significant risk of infertility. Other studies, considered the question of the association between appendectomy and infertility. Some studies showed no association between a history of appendicectomy and subsequent infertility while others found a higher incidence of infertility in patients who have had a previous appendicectomy. One of these studies analysed fertility after removal of a normal appendix. This study found that women whose

appendix was found to be normal at appendectomy in childhood seem to belong to a subgroup with a higher fertility than the general population. The majority of these studies suffer from small numbers, selected populations, design or analysis flaws. A recent systematic review and appraisal of the evidence for evaluating if perforation of the appendix was a risk factor for tubal infertility and ectopic pregnancy found 4 studies with an appropriate epidemiological design with reasonable quality. It found that the risk of the association for perforation of the appendix ranged from a high of 4.8 % for tubal infertility to an insignificant association for ectopic pregnancy. The reviewed studies were consistent in demonstrating a modest increase in risk, with all results in the same direction of increased risk. Based on diagnostic tests for causation, the authors of the review did not accept a causal relationship between perforation of the appendix and tubal infertility or ectopic pregnancy although they have accepted the association and the risk of the exposure. A subsequently published case control study did not provide substantial evidence that perforation of the appendix was an important risk factor for female tubal infertility. A further study examined fertility after appendectomy during pregnancy. This study found that appendectomy during pregnancy of a normal, inflamed or perforated appendix did not affect subsequent fertility. A recent epidemiological study concluded that appendicitis appears to be low risk factor in subsequent infertility. However, Appendectomy is associated with increased fertility. On the basis of this data, a policy of liberal and prompt laparoscopy used routinely on young women presenting with signs and symptoms of appendicitis is encouraged. If the appendix is found to be inflamed or equivocal, then appendectomy is justified.

This epic study is likely to be cited for encouraging the practice of laparoscopic appendectomy for all cases presenting with right iliac fossa pain. This is based on the fact that early mucosal appendicitis is thought to be a real entity and this is not apparent at the time of laparoscopy. However, caution must be exercised due to apparent complications of laparoscopic appendectomy.

5.7 Post operative monitoring and management of complications

All patients require adequate post-operative monitoring. Those patients who had percutaneous drainage of appendix abscess also require monitoring. In addition to vital parameters, these patients require daily evaluation of the wound and abdomen by clinical examination. Serial measurement of inflammatory parameters is also useful in showing trends of improvement or otherwise. This should be continued until patients are discharged from hospital.

Superficial wound infection can start to manifest 48 hours after surgery. Patients who show signs of wound infection by virtue of inflammation of wound edges, should continue on antibiotics treatment until the wound inflammation settles. As a marker of progress of the inflammation, the area of cellulitis surrounding the wound should be marked on the skin and monitored for progression or regression. In addition, palpation of the wound itself may suggest accumulation of infected material under the wound, in the superficial tissues. In such cases, the wound should be opened either fully or partially to allow drainage of the infected material. In some cases, operative drainage under anaesthesia should be considered.

Patients who do not show signs of improvement after appendectomy or those who show further deterioration, either clinically or serologically, should be considered for three

dimensional imaging. In these patients, the attending surgeon is looking for evidence of intra-abdominal collection to account for the apparent lack of improvement. However, in rare cases, there may be evidence of iatrogenic injury particularly during laparoscopic appendectomy or other missed diagnosis. In such patients, there should be a low threshold for repeat laparoscopy or laparotomy. Any evidence of intra-abdominal collection should be managed by drainage and peritoneal lavage. Iatrogenic injuries will require expert surgical correction and appropriate post-operative management. A missed diagnosis will require appropriate management.

Patients who had either percutaneous or laparoscopic drainage of an appendix abscess require careful monitoring for resolution of the inflammation and regression of the abscess. This is done clinically in the first instance but repeat three-dimensional imaging using contrast enhanced CT is usually more accurate than clinical evaluation. Failure of resolution of the inflammatory abscess or phlegmon associated with the abscess indicates either insufficient drainage together with incomplete or inappropriate antibiotics treatment. In such cases, the three dimensional imaging as well as bacteriological sensitivity testing of retrieved purulent material will guide further management. In some patients, revision of antibiotics requirement is necessary and in others revision of drainage is essential. In some patients, operative intervention is necessary due to intra-abdominal spread or rupture of the abscess. In these patients, the objective of operative intervention whether by laparotomy or laparoscopy is adequate drainage of any collection together with peritoneal lavage. When the abscess has been adequately drained, there is usually an accompanying improvement in the general condition of the patient. The drain should be withdrawn when no further purulent material is obtained. The patients can usually return to normal activity and can be safely discharged from hospital. However, due to the relatively high incidence of recurrent appendicitis, patients should be given a date for appendectomy. This delayed appendectomy should be done when all signs of inflammation have disappeared and should be attempted laparoscopically by an experienced surgeon.

6. Conclusion

Despite the recent decline in the incidence of appendicitis, it remains the commonest surgical emergency. It is estimated that 10% of the population will have appendicitis during their life time. Approximately 20 % of those will have complicated appendicitis. The diagnosis of appendicitis remains clinical. However, reliance on clinical examination alone will result in an unnecessary number of patients having exploratory surgery. Clinical history and examination supplemented with routine inflammatory marker analysis improves the diagnostic accuracy. Although ultrasound and computed tomography are relatively accurate in the diagnosis of appendicitis, it is important to emphasise that CT is more accurate than ultrasound but carries a radiation burden. The use of both radiological investigations is limited in the emergency setting. The diagnosis of appendicitis is most difficult at the extremes of age and it is in these patients that additional investigations may be justified. In all other cases, if the history and examination is compatible with appendicitis with raised inflammatory markers, patients (both males and females) should have a diagnostic laparoscopy which can proceed to laparoscopic appendectomy if the appendix was found to be inflamed. If an appendix abscess was found, the abscess should be drained. If the appendix was found to be perforated, conversion to open appendectomy should be

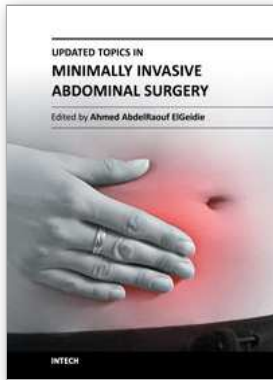
considered. In all cases, adequate peritoneal lavage should be carried out. Post-operatively, all patients should have antibiotics for different periods depending on the degree of inflammation and contamination found at operation. Post-operatively, all patients should be monitored for the emergence of adverse events. Patients who develop signs of peritoneal infection or who fail to improve should have a CT in the first instance. Wound infections should be managed by open drainage and antibiotics. Intra-abdominal infection should be managed by laparoscopy/ laparotomy, drainage of collection and peritoneal lavage together with systemic antibiotics.

Laparoscopic appendectomy is safe for the majority of cases of simple appendicitis. If at laparoscopy, the appendix is found to have perforated, the surgeon should make a careful evaluation of whether to continue with laparoscopic surgery or convert to open surgery. In either situation, the surgical objective is appendectomy together with adequate peritoneal lavage of all areas of the peritoneal cavity.

7. References

- Ball CG, Kortbeek JB, Kirkpatrick AW, and Mitchell P. Laparoscopic appendectomy for complicated appendicitis: an evaluation of postoperative factors. *Surgical Endoscopy*. 2004; 18: 969-973.
- Garbarino S, Shimi SM. Routine diagnostic laparoscopy reduces the rate of unnecessary appendectomies in young women. *Surg Endosc*. 2009 Mar;23(3):527-33. Epub 2008 Mar 26.
- Hale DA, Molloy M, Pearl RH, Schutt DC, Jaques DP. Appendectomy: a contemporary appraisal. *Annals of Surgery* 1997 Vol. 225, No. 3, 252-261
- Ingraham AM, Cohen ME, Bilimoria KY, Pritts TA, Ko CY, and Esposito TJ. Comparison of outcomes after laparoscopic versus open appendectomy for acute appendicitis at 222 ACS SQIP hospitals. *Surgery* 2010; 148: 625-37.
- Livingston EH, Woodward WA, Sarosi GA, and Haley RW. Disconnect Between Incidence of Nonperforated and Perforated Appendicitis: Implications for Pathophysiology and Management. *Ann Surg*. 2007 June; 245(6): 886-892.
- Stoker J, van Randen A, Lameris W, and Boermeester MA. Imaging patients with acute abdominal pain. *Radiology* 2009; 253: 31-46.
- Kirshtein B, Perry ZH, Avinoach E, Mizrahi S, Lantsberg L. Safety of laparoscopic appendectomy during pregnancy. *World J Surg*. 2009 Mar;33(3):475-80.
- Li X, Zhang J, Sang L, Zhang W, Chu Z, Li X, and Liu Y. Laparoscopic versus conventional appendectomy - a meta-analysis of randomised controlled trials. *BMC Gastroenterology* 2010; 10: 129.
- Markides G, Subar D, Riyad K. Laparoscopic versus open appendectomy in adults with complicated appendicitis: systematic review and meta-analysis. *World J Surg*. 2010 Sep;34(9):2026-40. Review.
- Needham PJ, Laughlan KA, Botterill ID, Ambrose NS. Laparoscopic appendectomy: calculating the cost. *Ann R Coll Surg Engl*. 2009 Oct;91(7):606-8.
- Park HC, Yang DH, Lee BH. The laparoscopic approach for perforated appendicitis, including cases complicated by abscess formation. *J Laparoendosc Adv Surg Tech A*. 2009 Dec;19(6):727-30.

Sauerland S, Jaschinski T, Neugebauer EA. Laparoscopic versus open surgery for suspected appendicitis. *Cochrane Database Syst Rev.* 2010 Oct 6;(10):CD001546. Review.



Updated Topics in Minimally Invasive Abdominal Surgery

Edited by Prof. Ahmed Elgeidie

ISBN 978-953-307-773-4

Hard cover, 246 pages

Publisher InTech

Published online 14, November, 2011

Published in print edition November, 2011

Updated topics in minimally invasive abdominal surgery provides surgeons interested in minimally invasive abdominal surgery with the most recent techniques and discussions in laparoscopic surgery. This book includes different topics covering a big variety of medical conditions with up-to-date information. It discusses many controversies in a clear and user-friendly manner. This book is made for young junior surgeons in training and also senior surgeons who need to know the most recent work in the field of laparoscopy. To make the material easily digested, we provided the book with many figures and illustrations for different procedures and technical pearls.

How to reference

In order to correctly reference this scholarly work, feel free to copy and paste the following:

Sami M. Shimi (2011). Appendicitis and Appendectomy, Updated Topics in Minimally Invasive Abdominal Surgery, Prof. Ahmed Elgeidie (Ed.), ISBN: 978-953-307-773-4, InTech, Available from:
<http://www.intechopen.com/books/updated-topics-in-minimally-invasive-abdominal-surgery/appendicitis-and-appendectomy>

INTECH

open science | open minds

InTech Europe

University Campus STeP Ri
Slavka Krautzeka 83/A
51000 Rijeka, Croatia
Phone: +385 (51) 770 447
Fax: +385 (51) 686 166
www.intechopen.com

InTech China

Unit 405, Office Block, Hotel Equatorial Shanghai
No.65, Yan An Road (West), Shanghai, 200040, China
中国上海市延安西路65号上海国际贵都大饭店办公楼405单元
Phone: +86-21-62489820
Fax: +86-21-62489821

© 2011 The Author(s). Licensee IntechOpen. This is an open access article distributed under the terms of the [Creative Commons Attribution 3.0 License](#), which permits unrestricted use, distribution, and reproduction in any medium, provided the original work is properly cited.